SIXTH EDITION

ORAL PATHOLOGY

CLINICAL PATHOLOGIC CORRELATIONS

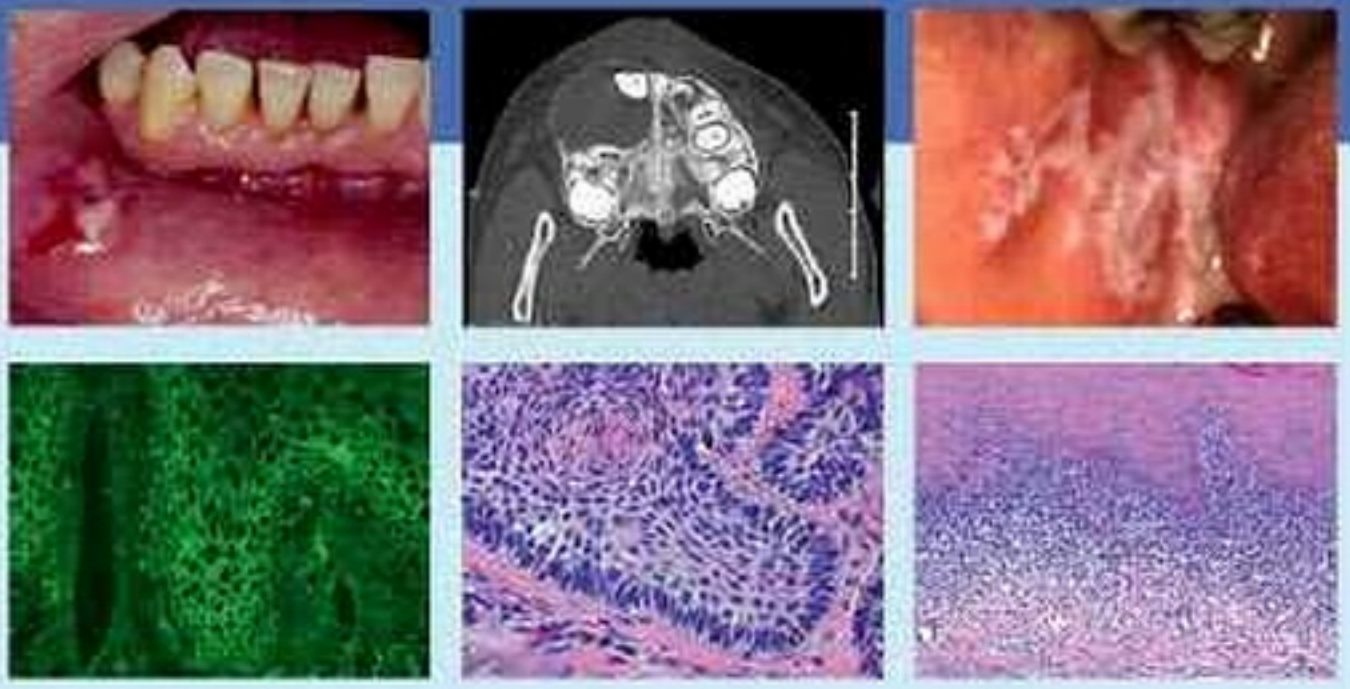

REGEZI
SCIUBBA
JORDAN

ELSEVIER
SAUNDERS

http://evolve.elsevier.com

SIXTH EDITION

ORAL PATHOLOGY

CLINICAL PATHOLOGIC CORRELATIONS

evolve learning system

ELSEVIER

YOU'VE JUST PURCHASED MORE THAN A TEXTBOOK



ACTIVATE THE COMPLETE LEARNING EXPERIENCE THAT COMES WITH YOUR BOOK BY REGISTERING AT

http://evolve.elsevier.com/Regezi/oralpathology

Evolve Student Learning Resources for Oral Pathology: Clinical Pathologic Correlations, sixth edition, OFFERS THE FOLLOWING FEATURES:

- Case studies demonstrating "unknown" cases. These cases provide excellent opportunities to become more familiar with diagnosing lesions and conditions based on clinical presentation
- Self-assessment exam (with 150 multiple choice questions created in the Board Review format) provides an excellent review for the NBDE
- Interactive Lecture Modules that walk you through decision-making practices and proper clinical identification of lesions and conditions
- 50 image-based questions provide an excellent way to test your skill at recognition and diagnosis
- A variety of weblinks are provided to pursue further study

REGISTER TODAY!

SIXTH EDITION

ORAL PATHOLOGY

CLINICAL PATHOLOGIC CORRELATIONS

JOSEPH A. REGEZI, DDS, MS
Professor Emeritus, Oral Pathology
University of California San Francisco
San Francisco, California

JAMES J. SCIUBBA, DMD, PHD
Professor (Ret), Otolaryngology, Pathology, Dermatology
The Johns Hopkins School of Medicine
Consultant, The Milton J. Dance Head & Neck Center
The Greater Baltimore Medical Center
Baltimore, Maryland

RICHARD C.K. JORDAN, DDS, PHD, FRCPATH
Professor of Oral Pathology & Pathology
University of California San Francisco
San Francisco, California

with 960 illustrations

ELSEVIER

ELSEVIER
SAUNDERS

3251 Riverport Lane
St. Louis, Missouri 63043

ORAL PATHOLOGY: CLINICAL PATHOLOGIC CORRELATIONS ISBN: 978-1-4557-0262-6

Copyright © 2012, 2008, 2003, 1999, 1993, 1989 by Saunders, an imprint of Elsevier Inc.

No part of this publication may be reproduced or transmitted in any form or by any means, electronic or mechanical, including photocopying, recording, or any information storage and retrieval system, without permission in writing from the publisher. Details on how to seek permission, further information about the Publisher's permissions policies and our arrangements with organizations such as the Copyright Clearance Center and the Copyright Licensing Agency, can be found at our website: www.elsevier.com/permissions.

This book and the individual contributions contained in it are protected under copyright by the Publisher (other than as may be noted herein).

Notices

Knowledge and best practice in this field are constantly changing. As new research and experience broaden our understanding, changes in research methods, professional practices, or medical treatment may become necessary.

Practitioners and researchers must always rely on their own experience and knowledge in evaluating and using any information, methods, compounds, or experiments described herein. In using such information or methods they should be mindful of their own safety and the safety of others, including parties for whom they have a professional responsibility.

With respect to any drug or pharmaceutical products identified, readers are advised to check the most current information provided (i) on procedures featured or (ii) by the manufacturer of each product to be administered, to verify the recommended dose or formula, the method and duration of administration, and contraindications. It is the responsibility of practitioners, relying on their own experience and knowledge of their patients, to make diagnoses, to determine dosages and the best treatment for each individual patient, and to take all appropriate safety precautions.

To the fullest extent of the law, neither the Publisher nor the authors, contributors, or editors, assume any liability for any injury and/or damage to persons or property as a matter of products liability, negligence or otherwise, or from any use or operation of any methods, products, instructions, or ideas contained in the material herein.

Library of Congress Cataloging-in-Publication Data or Control Number
Regezi, Joseph A.
Oral pathology : clinical pathologic correlations / Joseph A. Regezi, James J. Sciubba, Richard C.K. Jordan. – 6th ed.
p. ; cm.
Includes bibliographical references and index.
ISBN 978-1-4557-0262-6 (hardcover : alk. paper)
1. Mouth–Diseases. 2. Teeth–Diseases. I. Sciubba, James J. II. Jordan, Richard C. K. III. Title.
[DNLM: 1. Mouth Diseases–pathology. 2. Jaw Diseases–pathology. 3. Tooth Diseases–pathology. WU 140]
RC815.R39 2012
616.3′1–dc23

2011017827

Executive Editor: John Dolan
Senior Developmental Editor: Courtney Sprehe
Publishing Services Manager: Catherine Jackson
Senior Project Manager: Rachel E. McMullen
Design Direction: Kim Denando

Printed in the United States of America

Last digit is the print number: 9 8 7 6 5 4 3 2 1

Working together to grow libraries in developing countries
www.elsevier.com | www.bookaid.org | www.sabre.org
ELSEVIER BOOK AID International Sabre Foundation

CONTRIBUTORS

Eric R. Carlson DMD, MD, FACS
Professor and Chairman
Director of Oral and Maxillofacial Surgery Residency Program
Director of Oral/Head and Neck Surgery Fellowship Program
Department of Oral and Maxillofacial Surgery
University of Tennessee Graduate School of Medicine and the University of Tennessee Cancer Institute
Knoxville, Tennessee

John Kim, MD, FRCP(C)
Staff, Radiation Oncologist
Princess Margaret Hospital/University Health Network
Assistant Professor, Faculty of Medicine
University of Toronto
Toronto, Ontario, Canada

Jeffery C.B. Stewart, DDS, MS
Associate Professor
Department of Pathology
School of Dentistry
Oregon Health & Science University
Portland, Oregon

Richard J. Zarbo, DMD, MD
Kathleen D. Ward Endowed Chair of Pathology
Senior Vice President for Pathology and Laboratory Medicine
Henry Ford Health System
Detroit, Michigan

PREFACE

The sixth edition of *Oral Pathology: Clinical Pathologic Correlations* carries on the practice of presenting oral pathology in a clinically relevant format in which diseases and conditions are classified according to appearance and presentation. This practical approach to understanding oral diseases will assist the clinician in the recognition of specific conditions and in the development of differential diagnoses and a rational treatment approach. This edition contains new information on disease etiology, pathogenesis, and treatment. Discussions on the molecular basis of cancers reflect rapidly advancing knowledge in molecular medicine. Understanding this area of disease will help the clinician appreciate the current literature, and it will help in the further understanding of therapeutic strategies that are being developed. Recent, pertinent references can be found at the end of the chapter bibliographies.

WHO WILL BENEFIT FROM THIS BOOK?

Students of dentistry, residents and clinicians alike will benefit from the clear pathologic images and consistent format of this text. The supplemental study resources allow additional exploration within the field of oral pathology by way of PowerPoint modules, an assessment quiz, and more.

ORGANIZATION

Oral Pathology: Clinical Pathologic Correlations provides the basis of comprehensive study of oral and maxillofacial pathology. The sixth edition maintains a clinical approach to the identification of oral and maxillofacial diseases. At the beginning of each chapter is a list of diseases or conditions that present as indicated by the chapter title. Found within the chapter are detailed descriptions of etiology, pathogenesis, clinical features, histopathology, differential diagnosis, and treatment and prognosis of the listed diseases.

The Clinical Overview remains at the beginning of the book as a distillation of the clinical aspects found in the main text. This section is intended to be a quick reference for review of topics before exams or whenever a refresher is needed.

DISTINCTIVE FEATURES OF THIS BOOK

- The ***Clinical Overview*** section includes a quick summary of key diseases in a table format.
- Content is organized by clinical appearance of diseases and conditions.
- Clear, precise photomicrographs and clinical images show identifying details.
- Full-color illustrations explain concepts graphically.
- Boxes and tables throughout provide at-a-glance reference material relating to specific clinical conditions.

NEW TO THIS EDITION

- Important new information is presented on bisphosphonate-related osteonecrosis of the jaws (BRONJ) and HPV-associated carcinoma of the oropharynx.
- Addition of new radiographic images, cone beam CTs (CBCTs), regular CTs, and MRIs.

EVOLVE RESOURCES

The Evolve website provides additional features for classroom review, board preparation, and instructor resources.

For the Student

- Case studies—30 case studies demonstrate "unknown" cases. These cases provide excellent opportunities to become more familiar with diagnosing lesions and conditions based on clinical presentation.
- Self-assessment exam—150 multiple choice questions (created in the Board Review format) provide an excellent review for the NBDE.
- Interactive lecture modules—Each chapter features an accompanying module which walks you through decision-making practices and proper clinical identification of lesions and conditions. Each module contains case unknowns in which there are correlations of clinical and radiographic features with histopathology. Also included in each module are summary slides and additional examples of the diseases presented. To further assist in retaining this information, a self-assessment quiz is included at the end of each module.
- Image-based questions—50 image-based questions provide an excellent way to test your skill at recognition and diagnosis. An answer key is provided for the instructor.
- Weblinks—A variety of weblinks are provided for the reader to pursue further study.

For the instructor

Access to all the student material, plus …

- Image collection—An electronic image collection includes all the images from the text. These images are downloadable in various formats to create lectures and class exercises.
- Chapter specific testbank—Over 500 multiple choice questions are provided can be used to create quizzes or final exams. The questions follow the Board Review format.
- Answer key for image-based questions

ACKNOWLEDGMENTS

The authors gratefully acknowledge the contributions made by the talented and professional staff at Elsevier. In particular, we offer special thank yous to Courtney Sprehe, Senior Developmental Editor; Rachel McMullen, Senior Project Manager; and John Dolan, Executive Editor who were instrumental in making the production of this book possible.

CHAPTER 1



Vesiculobullous Diseases

VIRAL DISEASE

Herpes Simplex Infection
Varicella-Zoster Infection
Hand-Foot-and-Mouth Disease
Herpangina
Measles (Rubeola)

IMMUNOLOGIC DISEASE

Pemphigus Vulgaris
Mucous Membrane Pemphigoid
Bullous Pemphigoid
Dermatitis Herpetiformis
Linear Immunoglobulin A Disease (LAD)

HEREDITARY DISEASE

Epidermolysis Bullosa

VIRAL DISEASE

Oral mucous membranes may be infected by one of several different viruses, each producing a relatively distinct clinical pathologic picture (Table 1-1).

The herpesviruses are a large family of viruses characterized by a DNA core surrounded by a capsid and an envelope. Seven types of herpesviruses are known to be pathogenic for humans, with six of these linked to diseases in the head and neck area.

Herpes Simplex Infection

Herpes simplex virus (HSVs) infections are common vesicular eruptions of the skin and mucosa. They occur in two forms—primary (systemic) and secondary (localized)—and may be localized or secondary in nature. Both forms are self-limited, but recurrences of the secondary form are common because the virus can be sequestered within ganglionic tissue in a latent state. Control of symptoms rather than cure is the usual goal of treatment.

Pathogenesis. Physical contact with an infected individual or with body fluids is the typical route of HSV inoculation and transmission for a seronegative individual who has not been previously exposed to the virus, or possibly for someone with a low titer of protective antibody to HSV (Figure 1-1). The virus binds to the cell surface epithelium via heparan sulfate, which leads to transmembrane cytoplasmic insertion, followed by sequential activation of specific genes during the lytic phase of infection. These genes include immediate early (IE) and early (E) genes, coding for regulatory proteins and for DNA replication, and late (L) genes, coding for structural proteins. Documentation of the spread of infection through airborne droplets, contaminated water, or contact with inanimate objects is generally lacking. During the primary infection, only a small percentage of individuals show clinical signs and symptoms of infectious systemic disease, whereas a vast majority experience only subclinical disease. This latter group, now seropositive, can be identified

through the laboratory detection of circulating antibodies to HSV.

The incubation period after exposure ranges from several days to 2 weeks. In overt primary disease, a vesiculoulcerative eruption (primary gingivostomatitis) typically occurs in the oral and perioral tissues. The focus of eruption is expected at the original site of contact.

After resolution of primary herpetic gingivostomatitis, the virus is believed to migrate, through some unknown mechanism, along the periaxon sheath of the trigeminal nerve to the trigeminal ganglion, where it is capable of remaining in a latent or sequestered state. During latency, no infectious virus is produced; early, but not late, genes are expressed; and no free virus is present. No major histocompatibility (MHC) antigens are expressed, no T-cell response occurs during latency.

Reactivation of virus may follow exposure to sunlight ("fever blisters"), exposure to cold ("cold sores"), trauma, stress, or immunosuppression causing a secondary or recurrent infection.

An immunocompromised host may develop severe secondary disease. HSV-seropositive patients being prepared for bone marrow transplants with chemotherapeutic drugs such as cyclophosphamide (with or without total-body radiation) are at risk for a secondary herpes infection that is particularly severe. Post-transplant chemotherapy also predisposes seropositive patients to severe recurrent oral infection. HSV-seropositive patients infected with human immunodeficiency virus (HIV) may also exhibit intense secondary disease. Uncommonly, HIV-positive patients may have lesions that are coinfected by both HSV and cytomegalovirus. The pathogenesis of dually infected ulcers is unclear. Seronegative patients may rarely be affected with herpetic disease during immunosuppressive transplant states.

The reactivated virus travels by way of the trigeminal nerve to the originally infected epithelial surface, where replication occurs, resulting in a focal vesiculoulcerative eruption. Presumably because the humoral and cell-mediated arms of the immune system have been sensitized to HSV antigens, the lesion is limited in extent, and systemic symptoms usually do not occur. As the secondary lesion resolves, the virus returns to and remains in latent form within the trigeminal ganglion with no evidence of viral particles remaining within the previously involved epithelium. It is believed that nearly all secondary lesions develop from reactivated latent virus, although reinfection by different strains of the same subtype is considered a remote possibility.

Most oral-facial herpetic lesions are due to HSV type 1 (HSV1), although a small percentage may be caused by HSV

TABLE 1-1 VIRUSES RELEVANT TO DENTISTRY

Virus Family	Disease
Herpesviruses	
HSV1	Primary herpes gingivostomatitis Secondary herpes infections
HSV2	Genital herpes
Varicella-zoster	Varicella (chickenpox), zoster (shingles)
Epstein-Barr	Mononucleosis Burkitt's lymphoma Nasopharyngeal carcinoma Hairy leukoplakia
Cytomegalovirus	Salivary gland inclusion disease
HHV6	Roseola infantum
HHV8	Kaposi's sarcoma
Papillomaviruses (HPV)	Oral papillomas/warts, condyloma acuminatum, focal epithelial hyperplasia, nasopharyngeal carcinoma
Coxsackie viruses	Herpangina, hand-foot-and-mouth disease
Measles virus	Measles
Mumps virus	Mumps parotitis

HHV, Human herpesvirus; *HSV*, herpes simplex virus.

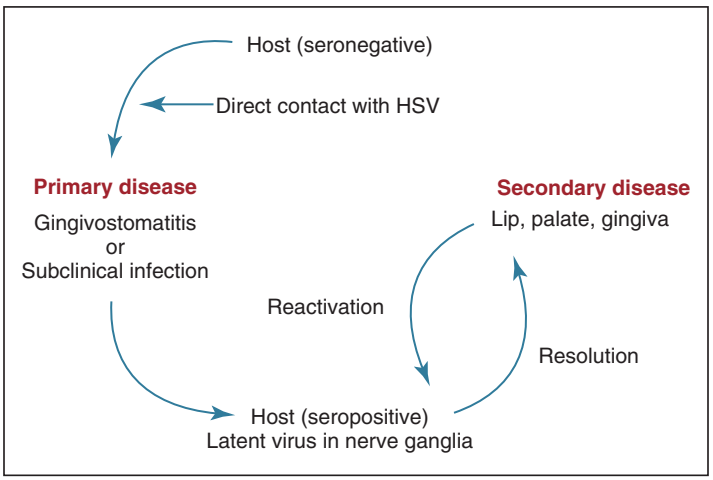

■ **FIGURE 1-1** Pathogenesis of herpes simplex infections.

type 2 (HSV2) as a result of oral-genital contact. Lesions caused by either virus are clinically indistinguishable. HSV2 has a predilection for genital mucosa, with infection having a pathogenesis similar to that of HSV1 infection of the head and neck. Latent virus, however, is sequestered in the lumbosacral ganglion. Previous HSV1 infection may provide some protection against HSV2 infection because of antibody cross-reactivity.

Viral shedding, a phenomenon in which previously infected individuals may be capable of transmitting the virus, has been reported, although the relationship between frequency of shedding, viral titer, and actual transmission is unknown. Asymptomatic shedding of intact HSV particles in saliva can be identified in approximately 2% to 10% of healthy adults in the absence of clinical disease. The level of risk of infection from "shedders" to others has not been measured, although it is probably low and dependent on the quantity of shed viral particles and the susceptibility of the new host.

Based on clinical observations, it was long believed that an association exists between HSV2 and carcinoma of the cervix. Although this virus can transform cervical epithelial cells in culture, it is not generally found in cervical carcinoma and is no longer thought to play a central role in the disease. Similarly, some sort of association between HSV1 and oral cancer was long suspected. For example, in experimental studies of oral tissues, evidence suggests that HSV1 is oncogenic in vitro, provided that cytolysis is inhibited by ultraviolet (UV) light or chemicals. In the hamster cheek pouch model, HSV can induce genetic changes, including chromosome translocations, mutations, and gene amplifications; in other animal models, HSV acts as a cocarcinogen with tobacco and other chemical carcinogens. A high prevalence of HSV antibodies and antibodies to the immediate early proteins has been noted among patients with oral cancer, but the significance of this is unclear. Despite this, it is generally believed that little evidence suggests that HSV1 is etiologically linked to oral cancer.

Clinical Features

Primary Herpetic Gingivostomatitis. Primary disease is usually seen in children, although adults who have not been previously exposed to HSV or who fail to mount an appropriate response to a previous infection may be affected. By age 15, about half the population is infected. The vesicular eruption may appear on the skin, vermilion, and oral mucous membranes (Box 1-1 and Figure 1-2). Intraorally, lesions may appear on any mucosal surface. This is in contradistinction to the recurrent form of the disease, in which lesions are confined to the lips, hard palate, and gingiva. The primary lesions are accompanied by fever, arthralgia, malaise, anorexia, headache, and cervical lymphadenopathy.

After the systemic primary infection runs its course of about 7 to 10 days, lesions heal without scar formation. By this time, the virus may have migrated to the trigeminal ganglion to reside in a latent form. The number of individuals with primary clinical or subclinical infection in which virus assumes dormancy in nerve tissue is unknown.

Secondary, or Recurrent, Herpes Simplex Infection. Secondary herpes represents the reactivation of latent virus. It is believed that only rarely does reinfection from an exogenous source occur in seropositive individuals. Antibodies to

BOX 1-1 PRIMARY HERPES SIMPLEX

CLINICAL FEATURES

Few primary infections result in clinical disease.
Oral and perioral vesicles rupture, forming ulcers.
Intraoral lesions may be found on any surface.
Systemic signs/symptoms include fever and malaise.
Self-limited disorder; symptomatic care is provided.
Immunocompromised patients have more severe disease.

TREATMENT

Acyclovir and analogs may control virus.
Treatment must be provided early to be effective.

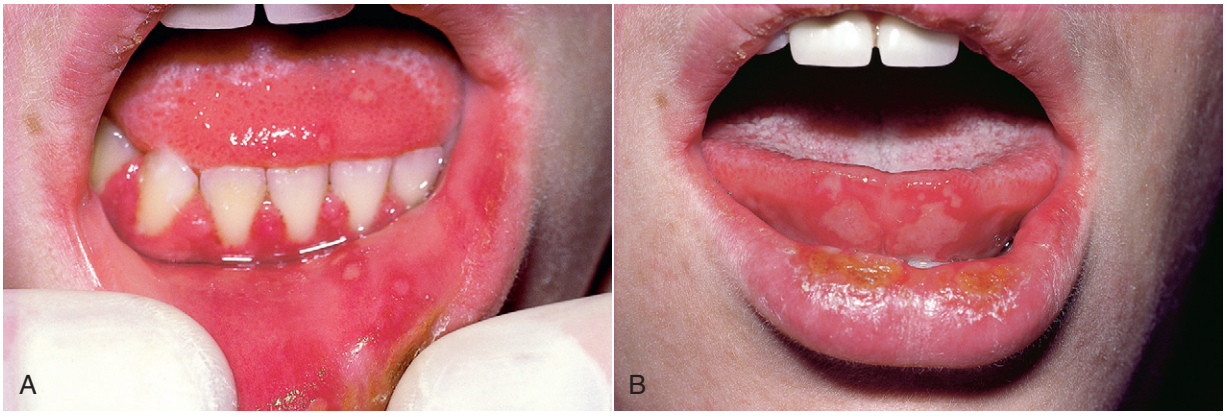

■ **FIGURE 1-2 A** and **B,** Primary herpes simplex infection.

BOX 1-2 SECONDARY HERPES SIMPLEX

ETIOLOGY
Reactivation of latent herpes simplex virus type 1
Triggers: sunlight, stress, immunosuppression
Reactivation common; frequency decreases with aging
Prodromal symptoms: tingling and burning

CLINICAL FEATURES
Affects perioral skin, lips, gingiva, palate
Self-limited

TREATMENT
Possible control with acyclovir and analogs
Must be administered early
Systemic treatment much more effective than topical treatment

DIFFERENTIAL DIAGNOSIS
Pemphigus vulgaris
Erosive lichen planus
Linear immunoglobulin (Ig)A disease
Contact allergy
Discoid lupus erythematosus
Epidermolysis bullosa acquisita



■ **FIGURE 1-3 A,** Secondary herpes simplex infection. **B,** Two weeks later.



■ **FIGURE 1-4** Herpes simplex labialis.

HSV are present in a large majority of the population (up to 90%), and up to 40% of this group may develop secondary herpes. The pathophysiology of recurrence has been related to a breakdown in local immunosurveillance or an alteration in local inflammatory mediators that allows the virus to replicate.

Patients usually have prodromal symptoms of tingling, burning, or pain in the site at which lesions will appear. Within a matter of hours, multiple fragile and short-lived vesicles appear. These become unroofed and coalesce to form maplike superficial ulcers. The lesions heal without scarring in 1 to 2 weeks and rarely become secondarily infected (Box 1-2; Figures 1-3 to 1-6). The number of recurrences is variable and ranges from one per year to as many as one per month. The recurrence rate appears to decline with age. Secondary lesions typically occur at or near the same site with each recurrence. Regionally, most secondary lesions appear on the vermilion and surrounding skin. This type of disease is usually referred to as *herpes labialis.* Intraoral recurrences are almost always restricted to the hard palate or gingiva.

Immunodeficiency. Secondary herpes in the context of immunosuppression results in significant pain and discomfort, as well as a predisposition to secondary bacterial and fungal infection. In contrast to those occurring in nonimmunocompromised patients, lesions in the immunodeficient patient are atypical in that they can be chronic and destructive. They also are not site restricted to the oral cavity.

Herpetic Whitlow. Herpetic whitlow is a primary or a secondary HSV infection involving the finger(s) (Figure 1-7). Before the universal use of examination gloves, this type of infection typically occurred in dental practitioners who had been in physical contact with infected individuals. In the case of a seronegative clinician, contact could result in a vesiculoulcerative eruption on the digit (rather than in the oral region), along with signs and symptoms of primary systemic disease. Recurrent lesions, if they occur, would be expected on the finger(s). Herpetic whitlow in a seropositive clinician (e.g., one with a history of HSV infection) is believed to be possible, although less likely because of previous immune stimulation by herpes simplex antigens.

Pain, redness, and swelling are prominent with herpetic whitlow and can be very pronounced. Vesicles or pustules eventually break and become ulcers. Axillary and/or epitrochlear lymphadenopathy may also be present. The duration of herpetic whitlow is protracted and may be as long as 4 to 6 weeks.

Histopathology. Microscopically, intraepithelial vesicles containing exudate, inflammatory cells, and characteristic virus-infected epithelial cells are seen (Figure 1-8). Virus-infected keratinocytes contain one or more homogeneous, glassy nuclear inclusions. These cells are also readily found on cytologic preparations. HSV1 cannot be differentiated from HSV2 histologically. After several days, herpes-infected keratinocytes cannot be demonstrated in biopsy or cytologic preparations. Herpes simplex lesions in HIV-positive patients may be coinfected with cytomegalovirus. The pathogenesis and significance of this phenomenon are undetermined.

Differential Diagnosis. Primary herpetic gingivostomatitis is usually apparent from clinical features. It can be confirmed by a virus culture (which requires 2 to 4 days for positive identification). Immunologic methods using monoclonal antibodies or DNA in situ hybridization techniques have become useful for specific virus identification in tissue sections.

Systemic signs and symptoms coupled with the oral ulcers may require differentiation from streptococcal pharyngitis, erythema multiforme, and acute necrotizing ulcerative gingivitis (ANUG, or Vincent's infection). Clinically, streptococcal pharyngitis does not involve the lips or perioral tissues, and vesicles do not precede the ulcers. Oral ulcers of erythema multiforme are larger, usually without a vesicular stage, and are less likely to affect the gingiva. ANUG also



■ **FIGURE 1-5** Secondary herpes simplex infection of the palate.

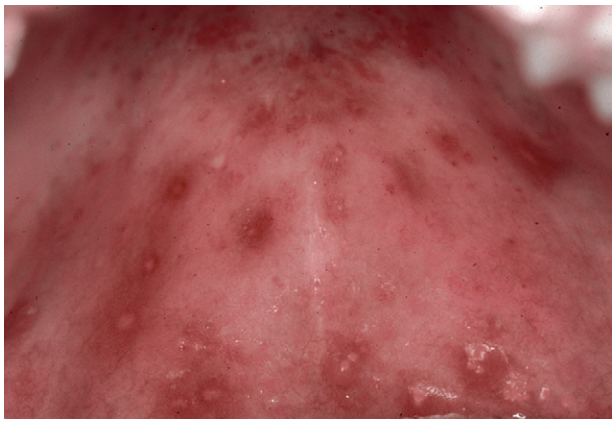

■ **FIGURE 1-6** Secondary herpes simplex infection of the palate.



■ **FIGURE 1-7** Herpetic whitlow.

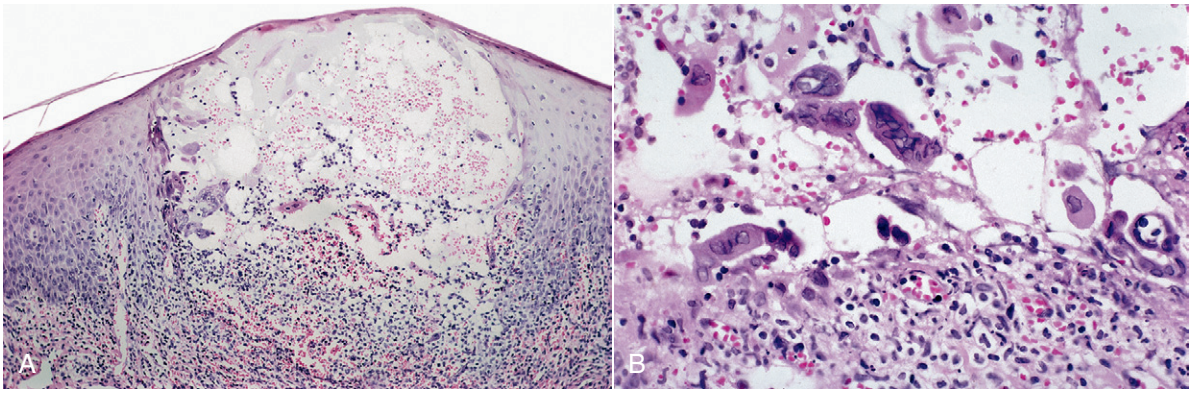

■ **FIGURE 1-8 A,** Herpes simplex–induced vesicle. **B,** Virus-infected multinucleated keratinocytes in the wall of a vesicle.

commonly affects young adults; however, oral lesions are limited to the gingiva and are not preceded by vesicles. Moreover, considerable pain and oral malodor are often reported with ANUG.

Secondary herpes is often confused with aphthous stomatitis but can usually be distinguished from it on the basis of clinical features. Multiple lesions, vesicles preceding ulcers, and palatal and gingival location are indicative of herpesvirus infection. In contrast to herpetic lesions, aphthae are found almost exclusively on nonkeratinized mucosa, such as the floor of the mouth, the alveolar mucosa, and the buccal labial mucosa.

Treatment. One of the most important factors in the treatment of HSV infection is timing. For any drug to be effective, it must be used as soon as possible after recognition of early or prodromal symptoms. No later than 48 hours from the onset of symptoms is generally regarded as the ideal time to start therapeutic measures. A number of virus-specific drugs have been developed. Acyclovir and its analogs have shown the greatest efficacy in the treatment of mucocutaneous infection.

The rationale for the use of topical agents resides in their ability to interrupt viral replication through inhibition of DNA polymerization (acyclovir, penciclovir) or by interference with virus-epithelial interaction and prevention of intracellular access (docosanol). In herpes-infected cells, acyclovir is converted by a virus-induced enzyme (thymidine kinase) and other cellular enzymes to a form that inhibits primarily viral DNA polymerase rather than host cell DNA polymerase. The end result is interruption of viral DNA synthesis and relative sparing of cellular DNA synthesis.

Systemic agents including acyclovir (200- to 400-mg tablets 5 times per day) and valacyclovir are effective in the control of primary genital herpes and, to a lesser degree, primary oral herpetic gingivostomatitis. Supportive therapy (fluids, rest, oral lavage, analgesics, and antipyretics) is an essential component of any primary herpes simplex regimen.

Secondary herpes can be controlled to some degree with systemic acyclovir. Recurrences are not prevented, but the course and severity of the disease are favorably affected. Prophylactic systemic acyclovir is effective in problematic cases and in immunosuppressed patients. In HIV-positive patients with severe disease, aggressive therapy that may include intravenous acyclovir or ganciclovir may be necessary.

Topical acyclovir, although only somewhat effective, has been advocated by some for the treatment of secondary or recurrent herpes. A 5% acyclovir (or analog) ointment applied 5 times per day when symptoms first appear slightly reduces the duration of herpes lesions and may abort some lesions. Also, topical n-docosanol (10%) has been used effectively, although randomized clinical trials are lacking. Topical management does not prevent recurrence, however, and may be ineffective in some patients.

The question of chronic viral suppression in relation to multiple recurrent herpes simplex infections in some individuals has been addressed. Within this paradigm, treatment approaches include the use of intermittent episodic, intermittent suppressive, or chronic suppressive therapy, in conjunction with an evidence-based dosing regimen.

BOX 1-3 VARICELLA-ZOSTER

PRIMARY DISEASE (VARICELLA, CHICKENPOX)
Self-limiting
Historically common in children
Vesicular eruption of trunk and head and neck occurring in crops
Systemic signs/symptoms: fever, malaise, other
Symptomatic treatment

SECONDARY DISEASE (ZOSTER, SHINGLES)
Self-limiting
Adults
Rash, vesicles, ulcers unilateral along dermatome
Possibly severe post-herpetic pain (~15% of cases)
Immunocompromised and lymphoma patients at risk
Treated with acyclovir and analogs

Varicella-Zoster Infection

The overall incidence of varicella infection the United States has been substantially reduced of late by 76% to 87% as a result of widespread vaccination programs. Primary varicella-zoster virus (VZV) infection in seronegative individuals is known as *varicella* or chickenpox; secondary or reactivated disease is known as *herpes zoster* or shingles (Box 1-3). Structurally, VZV is very similar to HSV, with a DNA core, a protein capsid, and a lipid envelope. Microscopically, striking similarities have been noted between herpes simplex conditions. A cutaneous or mucosal vesiculoulcerative eruption following reactivation of latent virus is typical of both VZV and HSV infections. Several signs and symptoms, however, appear to be unique to each infection.

Pathogenesis

Varicella. Varicella is believed to be transmitted predominantly through the inhalation of contaminated droplets. The condition is very contagious and is known to spread readily from person to person. Much less commonly, direct contact is an alternative way of acquiring the disease. During the 2-week incubation period, virus proliferates within macrophages, with subsequent viremia and dissemination to the skin and other organs. Host defense mechanisms of nonspecific interferon production and specific humoral and cell-mediated immune responses are also triggered. Overt clinical disease then appears in most individuals. As the viremia overwhelms body defenses, systemic signs and symptoms develop. Eventually, in a normal host, the immune response is able to limit and halt the replication of virus, allowing recovery in 2 to 3 weeks. During the disease process,

VZV may progress along sensory nerves to the sensory ganglia, where it can reside in a latent, undetectable form.

Herpes Zoster. Reactivation of latent VZV is uncommon but characteristically follows such occurrences as immunosuppressive states resulting from malignancy (especially lymphomas and leukemias), drug administration, or HIV infection. Radiation or surgery of the spinal cord or local trauma may also trigger secondary lesions. Prodromal symptoms of pain or paresthesia develop and persist for several days as the virus infects the sensory nerve of a dermatome (usually of the trunk or head and neck). A vesicular skin eruption that becomes pustular and eventually ulcerates. The disease lasts several weeks and may be followed by a troublesome post-herpetic neuralgia (in approximately 15% of patients) that takes several months to resolve. Local cutaneous hyperpigmentation may be noted on occasion.

Clinical Features

Varicella. Because of widespread vaccination, varicella is uncommon today in developed countries. Historically, a large majority of the population experienced primary infection during childhood. Fever, chills, malaise, and headache may accompany a rash that involves primarily the trunk and head and neck. The rash quickly develops into a vesicular eruption that becomes pustular and eventually ulcerates. Successive crops of new lesions appear, owing to repeated waves of viremia. This causes the presence, at any one time, of lesions at all stages of development (Figure 1-9). The infection is self-limiting and lasts several weeks. Oral mucous membranes may be involved in primary disease and usually demonstrate multiple shallow ulcers that are preceded by evanescent vesicles (Figure 1-10). Because of the intense pruritic nature of the skin lesions, secondary bacterial infection is not uncommon and may result in healing with scar formation. Complications, including pneumonitis, encephalitis, and inflammation of other organs, may occur in a very small percentage of cases. If varicella is acquired during pregnancy, fetal abnormalities may occur. When older adults and immunocompromised patients are affected, varicella may be much more severe and protracted, and more likely to produce complications.



■ **FIGURE 1-9** Varicella eruption on the trunk of a child.

Herpes Zoster. Zoster is essentially a condition of the older adult population and of individuals who have compromised immune responses. The incidence of herpes zoster infection increases with age, reaching approximately 10 cases per 100,000 patient-years by age 80.The sensory nerves of the trunk and head and neck are commonly affected. Involvement of various branches of the trigeminal nerve may result in unilateral oral, facial, or ocular lesions (Figures 1-11 and 1-12). Involvement of facial and auditory nerves produces the Ramsay Hunt syndrome, in which facial paralysis is accompanied by vesicles of the ipsilateral external ear, tinnitus, deafness, and vertigo.

After several days of prodromal symptoms of pain and/or paresthesia in the area of the involved dermatome, a well-delineated unilateral maculopapular rash appears. This may occasionally be accompanied by systemic symptoms. The rash quickly becomes vesicular, pustular, and then ulcerative. Remission usually occurs in several weeks. Complications include secondary infection of ulcers, post-herpetic neuralgia (which may be refractory to analgesics), motor paralysis, and ocular inflammation when the ophthalmic division of the trigeminal nerve is involved.

Histopathology. The morphology of the VZV and the inflammatory response to its presence in both varicella and herpes zoster are essentially the same as those with HSV. Microscopically, virus-infected epithelial cells show homogeneous nuclei, representing viral products, with



■ **FIGURE 1-10 A,** Varicella, perioral lesions. **B,** Intraoral lesions.



■ **FIGURE 1-11 A,** Herpes zoster of the nose. **B,** Intraoral lesions.



■ **FIGURE 1-12** Herpes zoster of the palate.

margination of chromatin along the nuclear membrane. Multinucleation of infected cells is also typical. Acantholytic vesicles eventually break down and ulcerate. In uncomplicated cases, epithelium regenerates from the ulcer margins with little or no scar.

Differential Diagnosis. Varicella is clinically diagnosed by the history of exposure and by the type and distribution of lesions. Other primary viral infections that may show some similarities include primary HSV infection and hand-foot-and-mouth disease.

Herpes zoster is most commonly confused with recurrent HSV infection and may be indistinguishable from it on clinical grounds. Longer duration, greater intensity of prodromal symptoms, unilateral distribution with abrupt ending at the midline, and post-herpetic neuralgia all favor a clinical diagnosis of herpes zoster. Equivocal cases can be definitively diagnosed through virus antigen typing using laboratory immunologic tests (e.g., immunohistochemistry, DNA in situ hybridization).

Treatment. For varicella in normal individuals, supportive therapy is generally indicated. However, for immunocompromised patients, more substantial measures are warranted. Virus-specific drugs that are effective in treating HSV infection have also shown efficacy in the treatment of VZV infection. These include systemically administered acyclovir, vidarabine, and human leukocyte interferon. Corticosteroids generally are contraindicated and, when given during the acute phase of the illness, have not been shown to reduce the incidence or severity of post-herpetic neuralgia. A highly effective, live attenuated vaccine has been available since 1995 and is now routinely given to children. Before the launch of a universal vaccination program, the United States had about 4 million cases of varicella per year; widespread vaccination has resulted in major reductions in hospitalization, mortality, and burden of disease.

Generally, patients with herpes zoster and intact immune responses have been treated empirically. However, it has been shown that oral acyclovir used at high doses (800 mg 5 times per day for 7 to 10 days) can shorten the disease course and reduce post-herpetic pain. Analgesics provide only limited relief from pain. Topically applied virus-specific drugs may have some benefit if used early. Topically applied substance P inhibitor (capsaicin) may provide some relief from post-herpetic pain. The use of topical or systemic corticosteroids cannot yet be recommended, and no evidence supports the use of tricyclic antidepressants or anticonvulsants in the management of herpes zoster. In patients with compromised immune responses, systemically administered acyclovir, vidarabine, or interferon is indicated, although success is variable.

Hand-Foot-and-Mouth Disease

Etiology and Pathogenesis. One of the subdivisions of the family of viruses known as picornavirus (literally, small [pico] RNA virus) is the Coxsackie group, named after the New York town where the virus was first identified. Certain Coxsackie subtypes cause oral vesicular eruptions: hand-foot-and-mouth (HFM) disease and herpangina.

HFM disease is a highly contagious viral infection that usually is caused by Coxsackie type A16 or enterovirus 71, although other serologic types of Coxsackie such as A5, A9, A10, B2, and B5 have been isolated with the disease. The virus is transferred from one individual to another through airborne spread or fecal-oral contamination. With subsequent viremia, the virus exhibits a predilection for mucous

membranes of the mouth and cutaneous regions of the hands and feet.

Clinical Features. This viral infection typically occurs in epidemic or endemic proportions and predominantly (about 90%) affects children younger than 5 years of age. After a short incubation period, the condition resolves spontaneously in 1 to 2 weeks.

Signs and symptoms are usually mild to moderate in intensity and include low-grade fever, malaise, lymphadenopathy, and sore mouth. Pain from oral lesions is often the patient's chief complaint. Oral lesions begin as vesicles that quickly rupture to become ulcers that are covered by a yellow fibrinous membrane surrounded by an erythematous halo. Lesions, which are multiple, can occur anywhere in the mouth, although the palate, tongue, and buccal mucosa are favored sites, while the lips and gingiva are usually spared. Multiple maculopapular lesions, typically on the feet, toes, hands, and fingers, appear concomitantly with or shortly after the onset of oral lesions (Figure 1-13). These cutaneous lesions progress to a vesicular state; they eventually become ulcerated and, finally, minimally encrusted without later scarring.

Histopathology. The vesicles of this condition are found within the epithelium because of obligate viral replication in keratinocytes. Eosinophilic inclusions may be seen within some of the infected epithelial cells. As the keratinocytes are destroyed by virus, the vesicle enlarges as it becomes filled with proteinaceous debris and inflammatory cells.

Differential Diagnosis. Because this disease may express itself primarily within the oral cavity, a differential diagnosis should include primary herpes gingivostomatitis and possibly varicella. The relatively mild symptoms, cutaneous distribution, and epidemic spread should help separate this condition from the others. Virus culture or detection of circulating antibodies may be done to confirm the clinical impression.

Treatment. Because of the relatively short duration, generally self-limiting nature, and general lack of virus-specific therapy, treatment for HFM disease is usually symptomatic. In some cases of enterovirus 71 (EV71) infection, severe dehydration and encephalitis have been reported, stressing the need for monitoring of disease severity. Bland mouth rinses such as sodium bicarbonate in warm water may be used to help alleviate oral discomfort. Some patients may require admission to hospital if they become dehydrated because of poor feeding and difficulty in hydrating as a result of painful mouth ulcers.

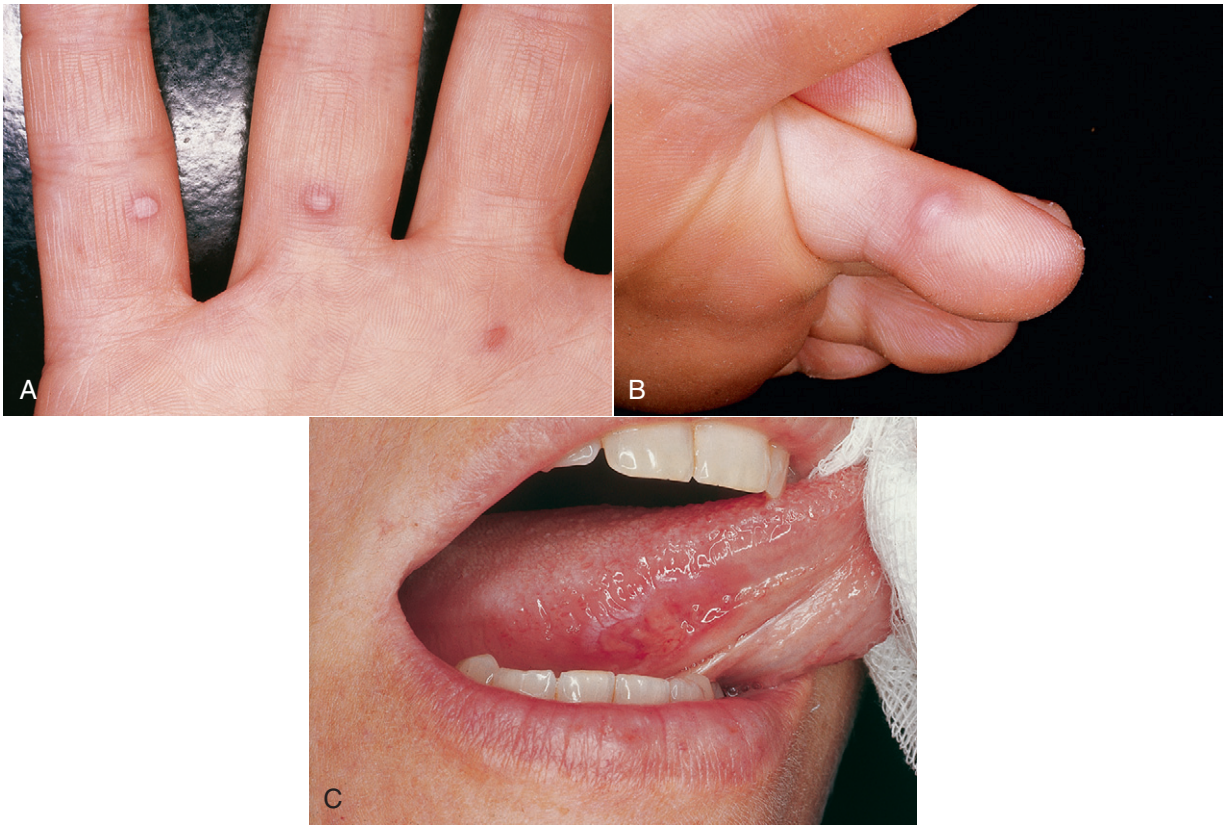

■ **FIGURE 1-13 A** to **C,** Hand-foot-and-mouth disease. (Courtesy Dr. Steven K. Young.)

Herpangina

Etiology and Pathogenesis. Herpangina is an acute viral infection caused by another Coxsackie type A virus (types A1-6, A8, A10, A22, B3, and possibly others). It is transmitted by contaminated saliva and occasionally through contaminated feces.

Clinical Features. Herpangina is usually endemic, with outbreaks occurring typically in summer or early autumn. It is more common in children than in adults. Those infected generally complain of malaise, fever, dysphagia, and sore throat after a short incubation period. Intraorally, a vesicular eruption appears on the soft palate, faucial pillars, and tonsils (Figure 1-14) and persists for 4 to 6 days. A diffuse erythematous pharyngitis is also present. No associated exanthem is typically seen.

Signs and symptoms are usually mild to moderate and generally last less than a week. On occasion, the Coxsackie virus responsible for typical herpangina may be responsible for subclinical infection or for mild symptoms without evidence of pharyngeal lesions, particularly among siblings or close contacts of herpangina patients.

Differential Diagnosis. Diagnosis is usually based on historical and clinical information. The characteristic distribution and short duration of herpangina separate it from other primary viral infections such as herpetic gingivostomatitis, HFM disease, and varicella. The vesicular eruption, mild symptoms, summer or early autumn presentation, and diffuse pharyngitis also distinguish the condition from streptococcal pharyngitis, and the systemic symptoms distinguish it from aphthous stomatitis. Laboratory confirmation can be made by virus isolation or by detection of serum antibodies.

Treatment. Because herpangina is self-limiting, is mild and of short duration, and causes few complications, treatment usually is not required.

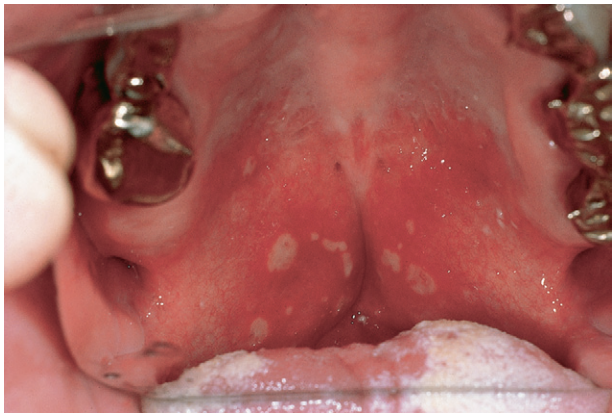

■ **FIGURE 1-14** Herpangina.

Measles (Rubeola)

Etiology and Pathogenesis. Measles is a highly contagious viral infection caused by a member of the paramyxovirus family of viruses. The virus, known simply as measles virus, is an RNA-enveloped virus that is related structurally and biologically to viruses of the orthomyxovirus family, which cause mumps and influenza. The virus is spread by airborne droplets through the respiratory epithelium of the nasopharynx, with peak incidence between March and April. The incubation period is between 10 and 11 days with a 1- to 7-day prodromal period.

Typically, an enanthem consists of early pinpoint elevations over the soft palate that coalesce with ultimate involvement of the pharynx with bright erythema; the tonsils may demonstrate bluish-gray areas, so-called Herman spots.

German measles, or rubella, is a contagious disease that is caused by an unrelated virus of the togavirus family. It shares some clinical features with measles, such as fever, respiratory symptoms, and rash. However, these features are very mild and short lived in German measles. In addition, Koplik's spots (see the following section) do not appear in German measles. The significance of the German measles virus lies in its ability to cause congenital defects in a developing fetus. The abnormalities produced are varied and may be severe, especially if the intrauterine infection occurs during the first trimester of pregnancy.

Clinical Features. Because of widespread vaccination programs in developed countries, cases of measles are now uncommon, and today those at risk of infection are individuals who have not been vaccinated. Historically, measles was a disease of children, often appearing seasonally in winter and spring. After an incubation period of 7 to 10 days, prodromal symptoms of fever, malaise, coryza, conjunctivitis, photophobia, and cough develop. In 1 to 2 days, pathognomonic small erythematous macules with white necrotic centers appear in the buccal mucosa (Figure 1-15). These



■ **FIGURE 1-15** Measles-associated Koplik's spots in buccal mucosa.

lesion spots, known as Koplik's spots, after the pediatrician who first described them, herald the onset of the characteristic maculopapular skin rash of measles. Koplik's spots generally precede the skin rash by 1 to 2 days. Similar lesions may be seen at the conjunctiva at the medial canthus. The rash initially affects the head and neck, followed by the trunk, and then the extremities. Complications associated with the measles virus include encephalitis and thrombocytopenic purpura. Secondary infection may develop as otitis media or pneumonia.

Histopathology. Infected epithelial cells, which eventually become necrotic, overlie an inflamed connective tissue that contains dilated vascular channels and a focal inflammatory response. Lymphocytes are found in a perivascular distribution. In lymphoid tissues, large characteristic multinucleated macrophages, known as Warthin-Finkeldey giant cells, are seen.

Differential Diagnosis. The diagnosis of measles is usually made on the basis of clinical signs and symptoms in an individual who has not been vaccinated for the disease. Prodromal symptoms, Koplik's spots, and rash should provide sufficient evidence of measles. If necessary, laboratory confirmation can be made through virus culture or serologic tests for antibodies to measles virus.

Treatment. No specific treatment for measles is known. Supportive therapy of bed rest, fluids, adequate diet, and analgesics generally suffices. An effective vaccine is widely available to prevent measles and is given to infants in conjunction with immunization against mumps and rubella. The vaccine is termed MMR (measles, mumps, rubella).

IMMUNOLOGIC DISEASE

Pemphigus Vulgaris

Pemphigus is a group of autoimmune mucocutaneous diseases characterized by intraepithelial blister formation. It results from a breakdown or loss of intercellular adhesion, thus producing epithelial cell separation known as *acantholysis.* Widespread superficial ulceration following rupture of the blisters leads to painful debilitation, fluid loss, and electrolyte imbalance. Before the use of corticosteroids, death was not an uncommon outcome for patients with pemphigus vulgaris. Four types of pemphigus are recognized: pemphigus vulgaris, pemphigus foliaceus, pemphigus erythematosus, and pemphigus vegetans. These differ in the level of intraepithelial involvement in the disease; pemphigus vulgaris and pemphigus vegetans affect the whole epithelium, and pemphigus foliaceus and pemphigus erythematosus affect the upper prickle cell layer/spinous layer. Only pemphigus vulgaris and pemphigus vegetans involve the oral mucosa. Pemphigus vegetans is very rare and generally is considered a variant of pemphigus vulgaris. Paraneoplastic pemphigus was recognized and defined as a separate form of this condition in the presence of neoplasia particularly.

Etiology and Pathogenesis. All forms of the disease retain distinctive presentations, both clinically and microscopically, but share a common autoimmune etiology. Evident are circulating autoantibodies of the immunoglobulin (Ig)G type that are reactive against components of epithelial desmosome-tonofilament complexes. The specific protein target has been identified as desmoglein 3, one of several proteins in the desmosomal cadherin family (Figure 1-16). Circulating autoantibodies are responsible for the earliest morphologic event: the dissolution or disruption of intercellular junctions and loss of cell-to-cell adhesion. The ease and extent of epithelial cell separation are generally directly proportional to the titer of circulating pemphigus antibody. Historically it was believed that the pemphigus antibody, once bound to the target antigen, activates an epithelial intracellular proteolytic enzyme or group of enzymes that acts at the desmosome-tonofilament complex. More recent evidence, however, favors a direct effect of the antibody on the desmoglein structure. In cases of paraneoplastic pemphigus, disturbances and alterations are noted both within the surface epithelium and within the basement membrane region. Patients with this syndrome have a lymphoma or other malignancy. The underlying malignancy is believed to be responsible for induction of the autoimmune response.

Clinical Features. Lesions of pemphigus present as painful ulcers preceded by bullae (Box 1-4 and Figure 1-17). The first signs of the disease appear in the oral mucosa in approximately 60% of cases (Figures 1-18 to 1-21). Such lesions may precede the onset of cutaneous lesions by periods of up to 1 year. Bullae rapidly rupture, leaving a red, painful, ulcerated base. Ulcers range in appearance from small aphthous-like lesions to large maplike lesions. Gentle traction on clinically unaffected mucosa may produce stripping of epithelium, a positive Nikolsky's sign. A great deal of discomfort often occurs with confluence and ulceration of smaller vesicles of the soft palate, buccal mucosa, and floor of the mouth.

The incidence of pemphigus vulgaris is unaffected by gender. Genetic and ethnic factors appear to predispose to the development of the disease. An increased incidence has been noted in Ashkenazi Jews and in individuals with certain histocompatibility antigen phenotypes (HLA-DR, HLA-A10, HLA-B, HLA-DQB, HLA-DRB1).

Other autoimmune diseases may occur in association with pemphigus vulgaris, such as myasthenia gravis, lupus erythematosus, rheumatoid arthritis, Hashimoto's thyroiditis, thymoma, and Sjögren's syndrome. A wide range has been noted from childhood to elderly age groups, although most cases are noted within the fourth and fifth decades of life.

Histopathology and Immunopathology. Pemphigus vulgaris appears as intraepithelial clefting with keratinocyte

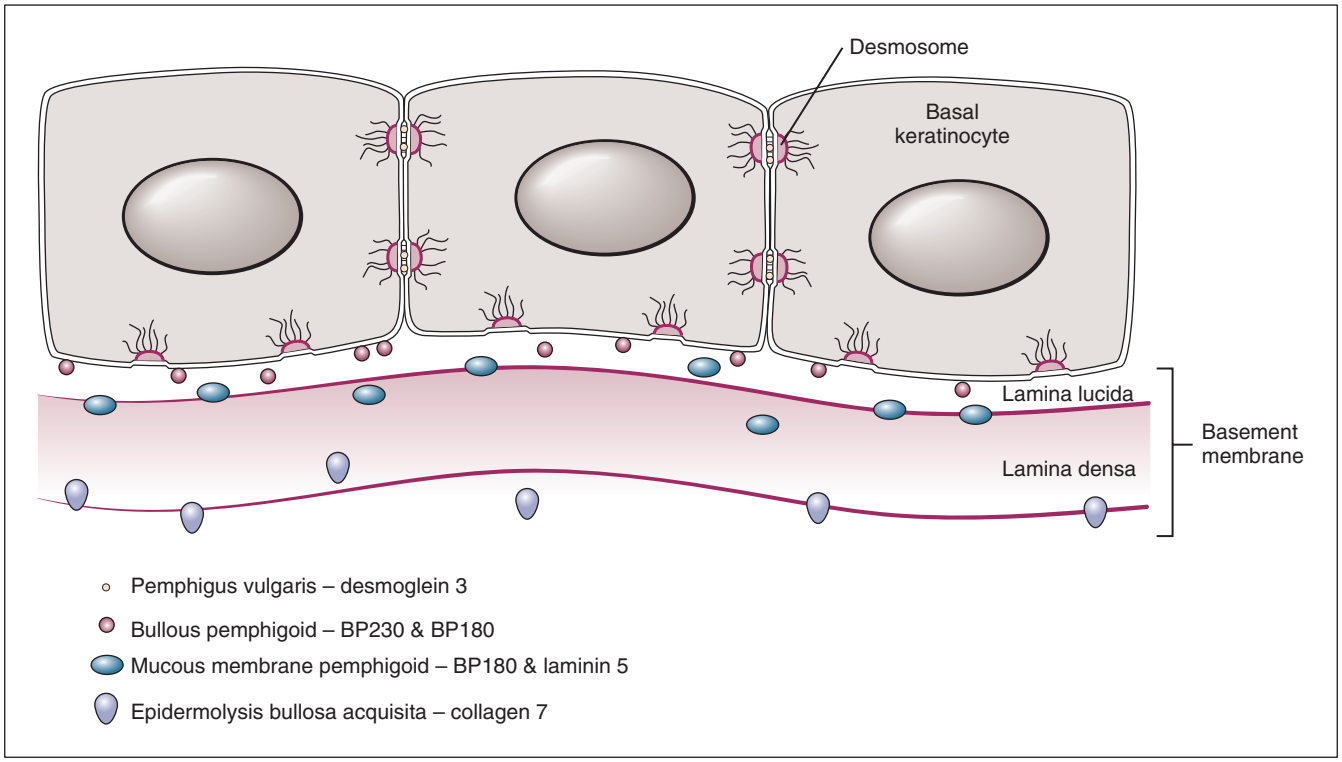

■ **FIGURE 1-16** Vesiculobullous diseases; antigenic targets.

BOX 1-4 PEMPHIGUS VULGARIS

ETIOLOGY

Autoimmune reaction to intercellular keratinocyte protein (desmoglein 3)

Intraepithelial blisters caused by antibodies

CLINICAL FEATURES

Affects skin and/or mucosa

50% or more of cases begin in the mouth ("first to show, last to go")

Presents as ulcers preceded by vesicles or bullae

Persistent and progressive

TREATMENT

Controlled with immunosuppressives (corticosteroids/azathioprine/cyclophosphamide/mycophenolate/biologics/IVIg/plasmapheresis)

High mortality when untreated (dehydration, electrolyte imbalance, malnutrition, infection)

IVIG, Intravenous immunoglobulin.

acantholysis (Figure 1-22). Loss of desmosomal attachments and retraction of tonofilaments result in free-floating, or acantholytic, Tzanck cells. Bullae are suprabasal, and the basal layer remains attached to the basement membrane.

In addition to standard biopsy, confirmation of pemphigus vulgaris can be made with the use of direct immunofluorescence (DIF) testing (Figures 1-23 and 1-24). DIF testing uses a biopsy specimen in an attempt to demonstrate



■ **FIGURE 1-17** Cutaneous pemphigus vulgaris.



■ **FIGURE 1-18** Oral pemphigus vulgaris.

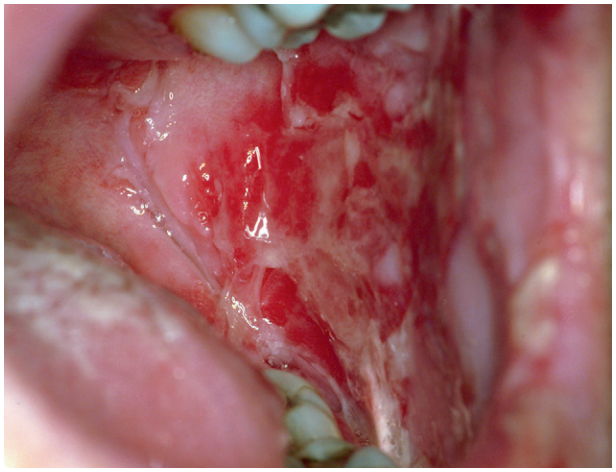

■ **FIGURE 1-19** Oral pemphigus vulgaris, buccal mucosa. Note surface slough with ulceration and bleeding.

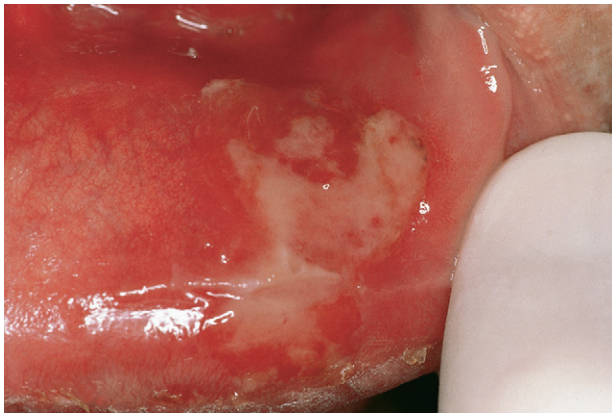

■ **FIGURE 1-20** Pemphigus vulgaris of the lower lip.



■ **FIGURE 1-21** Pemphigus bulla and ulcers. (Reproduced with permission from Regezi JA, Sciubba JJ, Pogrel MA: Atlas of Oral and Maxillofacial Pathology. Philadelphia: WB Saunders, 2000, Fig. 1-89.)

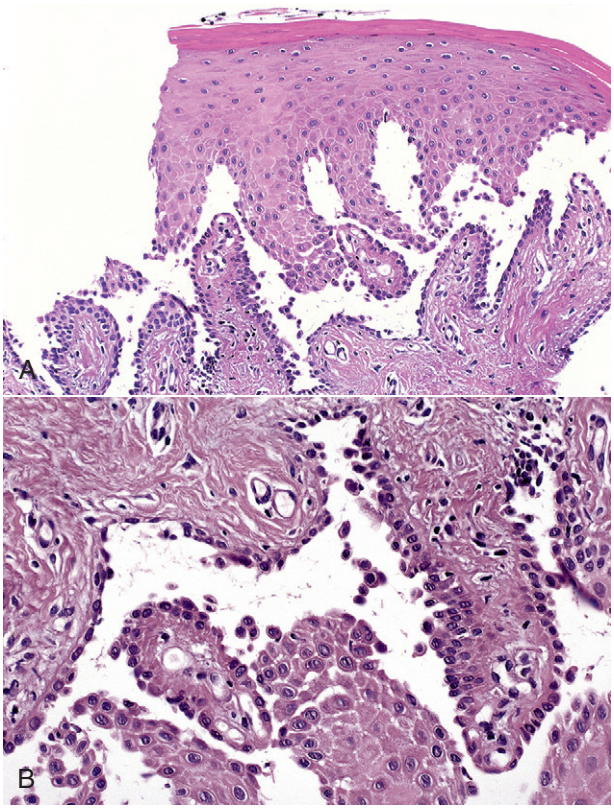

■ **FIGURE 1-22 A** and **B,** Oral pemphigus vulgaris showing intraepithelial separation and Tzanck cells.

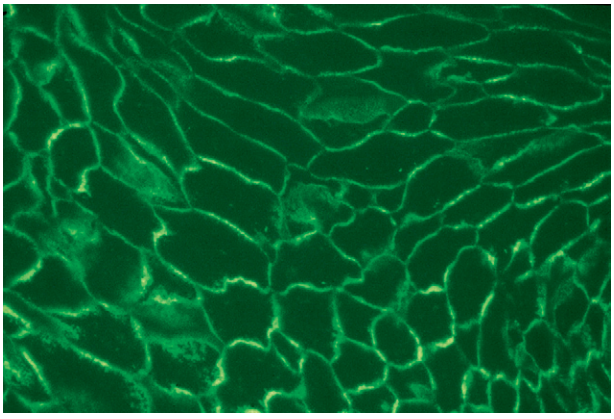

■ **FIGURE 1-23** Pemphigus vulgaris; immunofluorescence pattern. (Courtesy Dr. Troy E. Daniels.)

autoantibody already attached to the tissue. This is preferable to less sensitive indirect immunofluorescence, which uses patient serum to identify circulating antibody. In pemphigus vulgaris, DIF testing of perilesional tissue almost always demonstrates intercellular autoantibodies of the IgG type. C3 and, less commonly, IgA can be detected in the same intercellular fluorescent pattern. Paraneoplastic pemphigus demonstrates an antigen-antibody interaction and complement activation producing intraepithelial suprabasal acantholysis, as well as immunoglobulin deposition along the basement membrane zone. Of note, this form of immunopathology

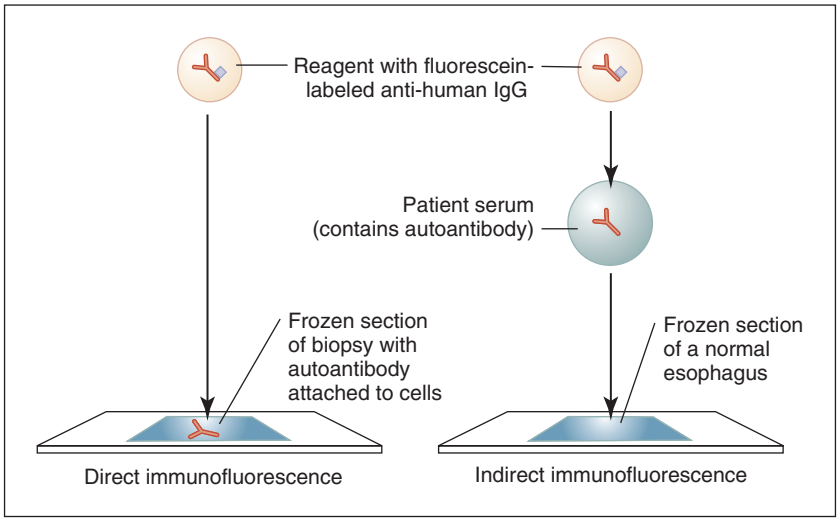

■ **FIGURE 1-24** Immunofluorescence; laboratory method.

extends to other tissues, including the heart, bladder, and liver, with autoantibodies attacking or denaturing components of the cytoplasmic portion of the desmosome (desmoplakins I and II).

Differential Diagnosis. Clinically, the oral lesions of pemphigus vulgaris must be distinguished from other vesiculobullous diseases, especially mucous membrane pemphigoid, erythema multiforme, erosive lichen planus, paraneoplastic pemphigus, and aphthous ulcers.

A diagnosis of *pemphigus vegetans,* a subset of pemphigus vulgaris, may be entertained in some situations. Although predominantly a skin disease, the vermilion and intraoral mucosa may be involved, often initially. Early acantholytic bullae are followed by epithelial hyperplasia and intraepithelial abscess formation. These pustular "vegetations" contain abundant eosinophils and can have a verrucous appearance. Pemphigus vegetans–type lesions may also be seen during a lull in the general course of pemphigus vulgaris. Spontaneous remission may occur in pemphigus vegetans, with complete recovery noted—a phenomenon not characteristic of pemphigus vulgaris.

Treatment and Prognosis. The high morbidity and mortality rates previously associated with pemphigus vulgaris have been reduced radically since the introduction of systemic corticosteroids. The reduction in mortality, however, does carry a degree of iatrogenic morbidity associated with long-term corticosteroid use. The cornerstone of initial pemphigus management is achieved with an intermediate dose of corticosteroid (prednisone). For more severely affected patients, a high-dose systemic corticosteroid regimen plus other nonsteroidal immunosuppressive agents with or without plasmapheresis may be necessary. More recently, immunoadsorption, intravenous immunoglobulin (IVIg), and biologic agents have gained a place in effective adjunctive management of this disease. A combined drug approach that includes alternate-day prednisone plus a steroid-sparing immunosuppressant agent such as azathioprine, dapsone, mycophenolate, or cyclophosphamide may also be used. A combined drug regimen helps reduce the complications of high-dose steroid therapy, such as immunosuppression, osteoporosis, hyperglycemia, and hypertension. Most recently the use of targeted therapy in the form of an anti-CD 20 monoclonal antibody (rituximab) has been very effective in cases of severe or unresponsive disease, with effective outcomes.

BOX 1-5 SIDE EFFECTS OF TOPICAL CORTICOSTEROIDS

Candidiasis
Epithelial atrophy
Telangiectasias
Additional effects on skin-striae, hypopigmentation, acne, folliculitis

Topical Steroids. Topical corticosteroids may be used intraorally as an adjunct to systemic therapy, with a possible concomitant lower dose of systemic corticosteroid. Side effects of topical steroids may occur after prolonged or intense dermatologic use (Box 1-5). However, with judicious intraoral use for short periods, it is unlikely that significant systemic effects will occur. Because topical steroids can facilitate the overgrowth of *Candida albicans* orally, antifungal therapy may be needed, especially with use of high-potency corticosteroids.

Systemic Steroids. Because the systemic effects and complications of glucocorticoids are numerous and can often be profound, it is recommended that they be prescribed by an experienced clinician (Box 1-6). Because the adrenals normally secrete most of their daily equivalent of 5 to 7 mg of prednisone in the morning, all prednisone should be taken, when possible, early in the morning to simulate the

physiologic process, thus minimizing interference with the pituitary-adrenal axis and side effects.

In patients requiring high-dose, prolonged, or maintenance steroid therapy, an alternate-day regimen may be used after initial therapy and an appropriate clinical response. A short-acting steroid (24 to 36 hours), such as prednisone, is desired because it allows recovery or near-normal functioning of the pituitary-adrenal axis on the "off" (no prednisone) days.

The prognosis for patients with pemphigus vulgaris is guarded because of the potential profound side effects of the drugs used for treatment. Once the disease has been brought under control, a probable lifelong treatment commitment to low-dosage maintenance therapy with these drugs will be required.

Mucous Membrane Pemphigoid

Mucous membrane pemphigoid (MMP) is a chronic blistering or vesiculobullous disease that affects predominantly oral and ocular mucous membranes (Figures 1-25 to 1-28).

BOX 1-6 EFFECTS: SIDE EFFECTS OF SYSTEMIC CORTICOSTEROIDS

Anti-inflammation: therapeutic
Immunosuppression: therapeutic
Gluconeogenesis: diabetes, bone/muscle loss
Redistribution of fat: buffalo hump, hyperlipidemia
Fluid retention: moon face, weight gain
Vasopressor potentiation: hypertension worse
Gastric mucosa effects: peptic ulcer worse
Adrenal suppression: adrenal atrophy
Central nervous system effects: psychological changes (e.g., euphoria)
Ocular effects: cataracts, glaucoma

It is also known as *cicatricial pemphigoid, benign mucous membrane pemphigoid, ocular pemphigus, childhood pemphigoid,* and *mucosal pemphigoid*; when it affects gingiva exclusively, it is referred to clinically as *gingivosis* or *desquamative gingivitis,* although these terms are imprecise and not specific in that desquamative gingival alterations are common to other oral mucosal diseases as well.

Etiology and Pathogenesis. MMP is an autoimmune process with an unknown stimulus. Deposits of immunoglobulins and complement components along the basement zone (on DIF testing) are characteristic. Antigenic targets include but are not restricted to laminin 5 (epiligrin) and a 180-kd protein that is also known as bullous pemphigoid antigen 180 (BP180). The specific site of the MMP antigen is in an extracellular location within the anchoring filaments component of the attachment apparatus. Circulating autoantibodies against basement membrane zone antigens in MMP are usually difficult to detect by routine methods, presumably because of relatively low serum levels.

Clinical Features. This is a disease of adults and the elderly and tends to affect women more than men. MMP has rarely been reported in children. Other mucosal sites that may be involved include the conjunctiva, nasopharynx, larynx, esophagus, and anogenital region. Oral mucosal lesions typically present as superficial ulcers, sometimes limited to attached gingiva (Box 1-7). Bullae are not commonly seen because the blisters are fragile and short lived. Lesions are chronic and persistent and may heal with a scar (cicatrix)—particularly lesions of the eye. Risks include scarring of the canthus (symblepharon), inversion of the eyelashes (entropion), and resultant trauma to the cornea (trichiasis). To prevent corneal damage, many patients with ocular pemphigoid have their eyelashes permanently removed by electrolysis. With laryngeal involvement, voice

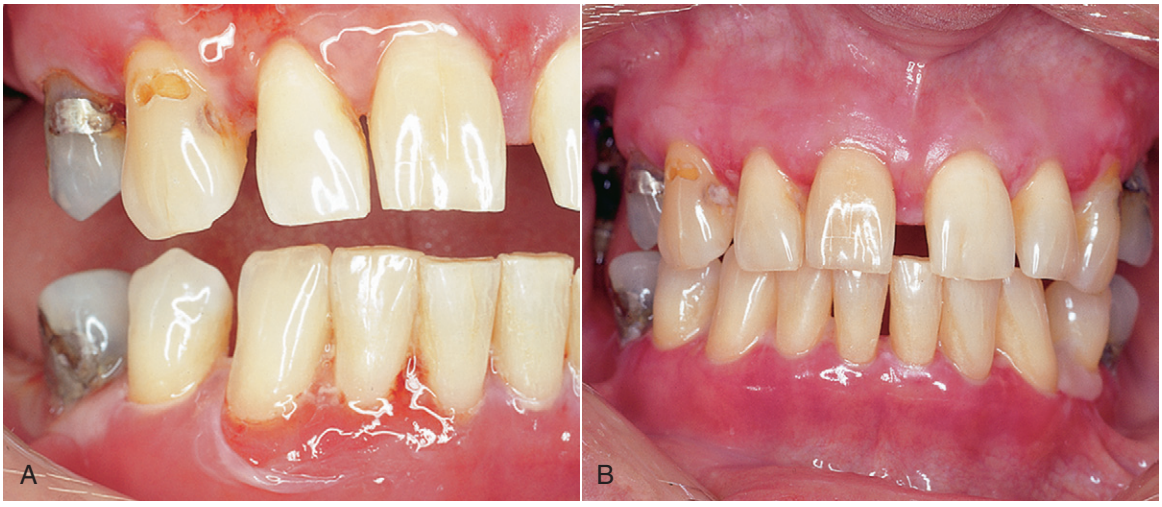

■ **FIGURE 1-25 A,** Mucous membrane pemphigoid of the gingiva. **B,** After control with corticosteroids, mandibular gingiva remains red and friable.



■ **FIGURE 1-26** Mucous membrane pemphigoid.

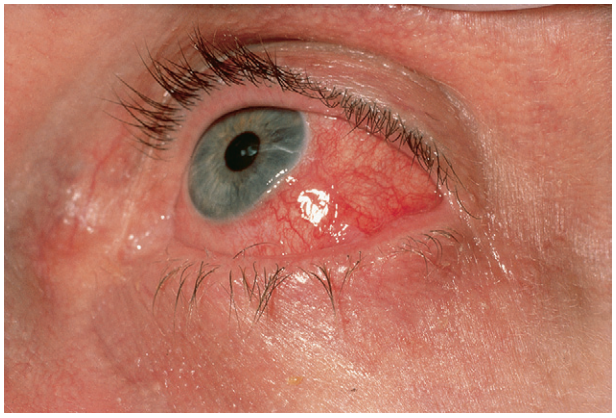

■ **FIGURE 1-27** Ocular pemphigoid.

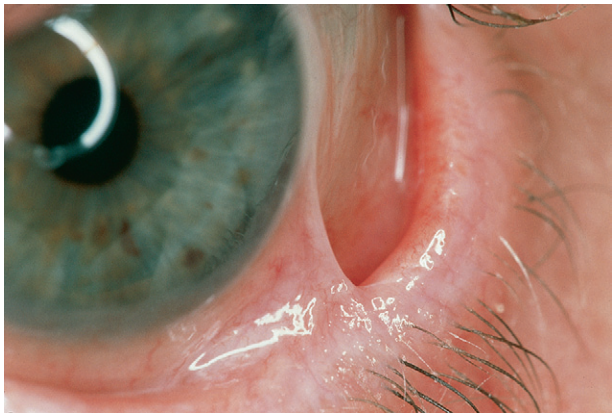

■ **FIGURE 1-28** Ocular pemphigoid; symblepharon resulting from chronicity.

alterations may result from supraglottic stenosis. Cutaneous lesions are uncommon and usually appear in the head and neck and extremities.

Gingival lesions often present as bright red patches or confluent ulcers extending to unattached gingival mucosa with mild to moderate discomfort. Concomitant ulcers and erosions may be seen on marginal and attached gingiva. Additionally, lesions may be seen on the buccal mucosa, palate, labial mucosa, and lips.

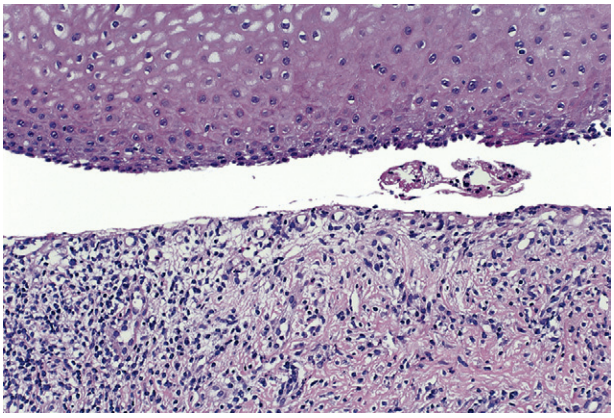

■ **FIGURE 1-29** Mucous membrane pemphigoid showing characteristic subepithelial separation.

BOX 1-7 MUCOUS MEMBRANE PEMPHIGOID

ETIOLOGY

Autoimmune reaction to basement membrane proteins (laminin 5, BP180, and others)

CLINICAL FEATURES

Oral mucosa (gingiva often only site) and conjunctiva; skin rarely affected

Subepithelial blisters caused by autoantibodies

Present as ulcers/redness in older adults (over 50 years of age)

Persistent, uncomfortable to painful

TREATMENT

Controlled with corticosteroids; sometimes resistant to systemic therapy; topical agents useful

Significant morbidity if untreated, including pain and scarring, especially of eye

BP, Bullous pemphigoid antigen.

With chronicity, the pain associated with oral MMP typically diminishes in intensity. Intact epithelium, especially adjacent to ulcers, can often be stripped away with ease, leaving denuded submucosa. This is one of several mucocutaneous diseases in which a positive Nikolsky's sign may be elicited. Because of patient discomfort, routine oral hygiene is often compromised. This results in dental plaque accumulation, which in turn superimposes an additional, but nonspecific, inflammatory response.

Histopathology and Immunopathology. MMP is a subepithelial clefting disorder with no acantholysis. In early stages, few lymphocytes are seen, but over time, the infiltrate becomes more dense and mixed (Figures 1-29 and 1-30).

DIF studies of intact oral mucosa demonstrate a linear pattern of homogeneous IgG fluorescence. C3 is commonly

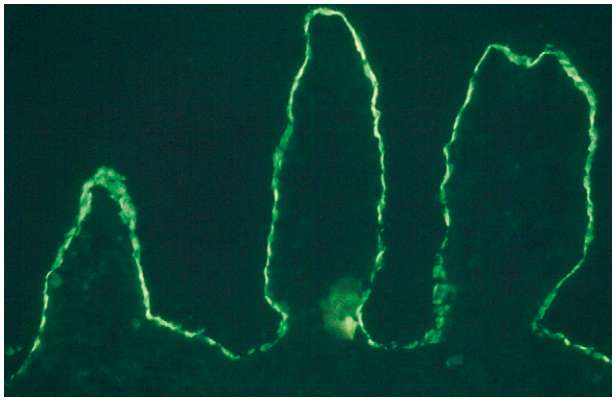

■ **FIGURE 1-30** Mucous membrane pemphigoid; basement membrane immunofluorescent staining. (Courtesy Dr. Troy E. Daniels.)

TABLE 1-2 PEMPHIGUS VULGARIS VERSUS MUCOUS MEMBRANE PEMPHIGOID

	Pemphigus	Pemphigoid
Tissue antibody	IgG, C3 Circulating auto-IgG	IgG, IgA, C3 No circulating auto-IgG
Target protein(s)	Desmoglein 3 (desmosomes)	Laminin 5 and BP180 (basement membrane)
Vesicles	Intraepithelial	Subepithelial
Sites	Oral and skin	Oral and eyes
Treatment	Corticosteroid	Corticosteroid
Prognosis	Fair, significant mortality if untreated	Good, significant morbidity

BP, Bullous pemphigoid antigen; *C*, complement; *Ig*, immunoglobulin.

found in the same distribution. Although the fluorescent pattern is not distinguishable from that of cutaneous bullous pemphigoid, the submicroscopic location of the antigenic target (lower part of the lamina lucida) is distinctive. Results of indirect immunofluorescence studies are usually negative, but IgG and, less commonly, IgA have occasionally been demonstrated.

Differential Diagnosis. The clinical differential diagnosis for this vesiculobullous disease must include pemphigus vulgaris and erosive lichen planus among others (Table 1-2). When the attached gingiva is the exclusive site of involvement, atrophic lichen planus, linear IgA disease, discoid lupus erythematosus, and contact allergy should be included. Final diagnosis may require DIF confirmation.

Treatment and Prognosis. Corticosteroids are typically used to control MMP (see Pemphigus Vulgaris, Treatment and Prognosis section for corticosteroid effects and side effects). Prednisone is used for moderate to severe disease, and topical steroids for mild disease and maintenance. Very high systemic doses occasionally are required to achieve significant results in some cases of recalcitrant gingival MMP. Because side effects of therapy may outweigh benefits, high-potency topical steroids are often used instead (e.g., clobetasol, betamethasone dipropionate, fluocinonide, desoximetasone). A custom-made, flexible mouth guard may be used to keep the topical medication in place. Scrupulous oral hygiene, including chlorhexidine rinses, further enhances the effectiveness of topical corticosteroids when gingival involvement is marked.

In cases in which standard therapy has failed, or with rapid progression to more severe disease, use of other systemic agents may be required. These have included the use of tetracycline and niacinamide, sulfapyridine, sulfones, antibiotics, gold injections, dapsone, and nutritional supplementation. In severe cases and cases in which other sites are affected (eye, esophagus, larynx), immunosuppressive agents (azathioprine, cyclophosphamide, methotrexate, mycophenolate, cyclosporine) may be added to the prednisone regimen to reduce steroid dose and thus help avoid steroid-associated complications.

Although oral MMP has a relatively benign course, significant debilitation and morbidity lasting for years can occur. Natural history is unpredictable; in some cases, slow spontaneous improvement may be noted, whereas in other cases, the course may be especially protracted, with alternating periods of improvement and exacerbation.

Of importance for patients with oral MMP is the possible appearance of ocular disease. If the eyes become affected, definitive early treatment is critical because conjunctival ulceration and scarring can lead to scarring and blindness. Therefore, ophthalmologic examination should be part of the treatment plan for patients with oral MMP.

Bullous Pemphigoid

Etiology and Pathogenesis. Bullous pemphigoid and its closely related mucosal counterpart, MMP, appear to share similar etiologic and pathogenetic factors. A difference from MMP is that titers of circulating autoantibodies to basement membrane zone antigens are usually detectable in bullous pemphigoid by routine methods.

Autoantibodies have been demonstrated against basement membrane zone laminin and so-called bullous pemphigoid antigens 230 (BP230) and 180 (BP180), which are found in hemidesmosomes and in the lamina lucida of the basement membrane region. Subsequent to binding of circulating autoantibodies to tissue antigens, a series of events occur, one of which is complement activation. This attracts neutrophils and eosinophils to the basement membrane zone. These cells then release lysosomal proteases, which in turn participate in degradation of the basement membrane attachment complex. The final event is tissue separation at the epithelium–connective tissue interface.

Clinical Features. This bullous disease is seen primarily in the elderly, with peak incidence in the seventh and eighth decades. Lesions characteristically appear on the skin, although concomitant lesions of mucous membranes occur in approximately one third of patients.

Skin lesions are characterized by a trunk and limb distribution. Although tense vesicles and bullae are typically noted in contrast to flaccid bullae of pemphigus vulgaris, they often are preceded by or associated with an erythematous papular eruption. Oral mucosal lesions of bullous pemphigoid cannot be distinguished from those of MMP. Bullae and erosions may be noted, especially on the attached gingiva—a commonly affected site. Other areas of involvement may include the soft palate, buccal mucosa, and floor of the mouth.

Histopathology and Immunopathology. Bullae are subepithelial and appear similar to those of MMP. Ultrastructurally, the basement membrane is cleaved at the level of the lamina lucida.

Circulating autoantibody titers neither correlate nor fluctuate with the level of clinical disease, as is usually the case with pemphigus vulgaris. DIF shows linear deposition of IgG and C3 along the basement membrane zone. The major bullous pemphigoid antigen is BP230 in size, and the minor antigen is BP180. Both antigens are synthesized by basal keratinocytes.

Treatment. Periods of clinical remission have been noted with bullous pemphigoid. Systemic corticosteroids generally are used to control this disease. Nonsteroidal immunosuppressive agents may also effect control. Antibiotics (tetracycline and erythromycin) and niacinamide have provided some clinical success.

Dermatitis Herpetiformis

Etiology and Pathogenesis. Dermatitis herpetiformis is a cutaneous vesiculobullous disease characterized by intense pruritus. The disease is associated with granular IgA deposits in the papillary dermis that precipitate with an epidermal transglutaminase, an enzyme not normally present in the papillary region of normal skin. Serum IgA in patients with dermatitis herpetiformis also binds epidermal transglutaminase. Dermatitis herpetiformis is frequently associated with the gluten-sensitive enteropathy, celiac disease, which is characterized by IgA-type autoantibodies to a closely related enzyme, tissue transglutaminase. It is now widely accepted that dermatitis herpetiformis is a cutaneous manifestation of celiac disease and affects approximately 25% of patients with celiac disease. Both dermatitis herpetiformis and celiac disease are closely linked to HLA class II locus in chromosome 6, with 90% of patients having HLA DQ2, and almost all the remainder HLA DQ8. A gluten-free diet is essential in the treatment of both conditions.

Clinical Features. Dermatitis herpetiformis is a chronic disease typically seen in young and middle-aged adults, with a slight male predilection. Periods of exacerbation and remission further characterize this disease. Cutaneous lesions are papular, erythematous, vesicular, and often intensely pruritic. Lesions are usually symmetric in their distribution over the extensor surfaces, especially the elbows, shoulders, sacrum, and buttocks. Of diagnostic significance is the frequent involvement of the scalp and face. Lesions usually are aggregated (herpetiform) but often are individually disposed. In some patients, exacerbations may be associated with ingestion of foods or drugs containing iodide compounds. In others, a seasonal (summer months) peak may be seen.

In the oral cavity, dermatitis herpetiformis is uncommon, with vesicles and bullae that rupture, leaving superficial nonspecific ulcers with a fibrinous base with erythematous margins. Lesions may involve both keratinized and nonkeratinized mucosa, and may be seen in a significant number of those with this disease.

Histopathology and Immunopathology. Collections of neutrophils, eosinophils, and fibrin are seen at the papillary tips of the dermis. Subsequent exudation at this location contributes to epidermal separation. A lymphophagocytic infiltrate is seen in perivascular spaces.

The immunologic finding of granular IgA deposits at the tips of the connective tissue papillae is specific for dermatitis herpetiformis. In addition, it is possible to localize the third component of complement (C3) in lesional and perilesional tissue in a distribution similar to that of IgA.

Treatment and Prognosis. Dermatitis herpetiformis generally is treated with dapsone, sulfoxone, and sulfapyridine. Because patients often have an associated enteropathy, a gluten-free diet may also be part of the therapeutic regimen. Elimination of gluten from the diet reduces small bowel pathology within months.

In most instances, dermatitis herpetiformis is a lifelong condition, often exhibiting long periods of remission. Many patients, however, may be relegated to long-term dietary restrictions or drug treatment or both.

Linear Immunoglobulin A Disease (LAD)

Linear IgA disease is principally a chronic autoimmune disease of the skin that commonly affects mucous membranes, including gingiva. Unlike dermatitis herpetiformis, LAD is not associated with gluten-sensitive enteropathy (and may not be responsive to dapsone therapy or dietary gluten restrictions). Skin lesions may be urticarial, annular, targetoid, or bullous. Oral lesions, present in a majority of cases, are ulcerative (preceded by bullae) or erosive, with ocular lesions similar to those noted in ocular pemphigoid. Patients respond to sulfones or corticosteroids.

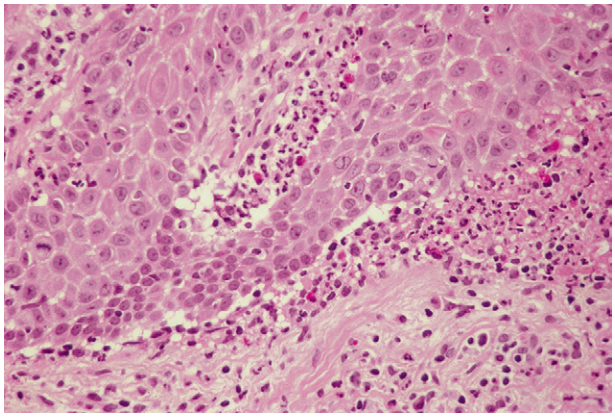

■ **FIGURE 1-31** Linear immunoglobulin (Ig)A disease showing subepithelial separation with neutrophils and eosinophils.



■ **FIGURE 1-32** Epidermolysis bullosa in a child. Note ulcers, constricted opening, and atrophic tongue mucosa.

The biological basis of linear IgA disease is not well understood. Central to the disease are autoantibodies to BP180 (collagen XVII), which normally functions as a cell matrix adhesion molecule through stabilization of the hemidesmosome complex, and whose extracellular portion is constitutively shed from the cell surface by ADAMs (proteinases that contain adhesive and metalloprotease domains). Similar to MMP, in vivo and in vitro studies provide experimental evidence for a central pathogenic role of BP180, but indicate that the serum level and epitope specificity of these antibodies influence phenotype and disease severity.

Microscopically, separation at the basement membrane is seen. Neutrophils and eosinophils often fill the separation (Figure 1-31). With DIF, linear deposits of IgA are found at the epithelium–connective tissue interface.

Linear IgA disease is managed in a similar manner to MMP with topical corticosteroids as the initial therapy. Systemic corticosteroids or other immunosuppressive agents (azathioprine, cyclophosphamide, cyclosporine) may be used in more severe or refractory cases.



■ **FIGURE 1-33** Epidermolysis bullosa patient with ulcers and dystrophic nails. (Reproduced with permission from Regezi JA, Sciubba JJ, Pogrel MA: Atlas of Oral and Maxillofacial Pathology. Philadelphia: WB Saunders, 2000, Fig. 1-108.)

HEREDITARY DISEASE

Epidermolysis Bullosa

Etiology and Pathogenesis. *Epidermolysis bullosa* is a general term that encompasses one acquired and as many as 20 genetic or hereditary varieties (dystrophic, junctional, simplex) of diseases that basically are characterized by the formation of blisters at sites of minor trauma. Various genetic types range from autosomal dominant to autosomal recessive in origin and are further distinguished by various clinical features, histopathology, and ultrastructure. The acquired nonhereditary autoimmune form, known as *epidermolysis bullosa acquisita,* is unrelated to the other types and often is precipitated by exposure to specific drugs. In this type, IgG deposits are commonly found in sub–basement membrane tissue and type VII collagen (the main constituent of anchoring fibrils) antibodies located below the lamina densa of the basement membrane.

In the hereditary forms of epidermolysis bullosa, circulating antibodies are not evident. Rather, pathogenesis appears to be related to genetic defects in basal cells, hemidesmosomes, or anchoring connective tissue filaments, depending on the disease subtype.

Clinical Features. The feature common to all subtypes of epidermolysis bullosa is bulla formation from minor trauma, usually over areas of stress such as the elbows and the knees (Figures 1-32 and 1-33). Onset of disease is seen during infancy or early childhood for the hereditary forms, and

during adulthood for the acquired type. Severity is generally greater with the inherited recessive forms. Blisters may be widespread and severe and may result in scarring and atrophy. Nails may be dystrophic in some forms of this disease.

Oral lesions are particularly common and severe in the recessive forms of this group of diseases and uncommon in the acquired form. Oral manifestations include bullae that heal with scar formation, a constricted oral orifice resulting from scar contracture, and hypoplastic teeth. These changes are most pronounced in the type known as *recessive dystrophic epidermolysis bullosa.*

Treatment and Prognosis. The prognosis is dependent on the subtype of epidermolysis bullosa. Behavior ranges from life threatening in one of the recessive forms, known as junctional epidermolysis bullosa, to debilitating in most other forms. Therapy includes avoidance of trauma, supportive measures, and chemotherapeutic agents (none of which is consistently effective). Corticosteroids, vitamin E, phenytoin, retinoids, dapsone, and immunosuppressive agents all have been suggested as providing some benefit to patients. More recently, IVIg and the monoclonal biologic agent, infliximab, have been associated with some therapeutic success.

BIBLIOGRAPHY

Viral Diseases

Andreoni M, Sarmati L, Nicastri E, et al: Primary human herpesvirus 8 infection in immunocompetent children. JAMA 287: 1295–1300, 2002.

Axell T, Liedholm R: Occurrence of recurrent herpes labialis in an adult Swedish population. Acta Odontol Scand 48:119–123, 1990.

Cernik C, Gallina K, Brodell RT, et al: The treatment of herpes simplex infections: an evidence-based review. Arch Intern Med 168:1137–1144, 2008.

Chatproedprai S, Theanboonlers A, Korkong S, et al: Clinical and molecular characterization of hand-foot-and-mouth disease in Thailand, 2008-2009. Jpn J Infect Dis 63:229–233, 2010.

Craythorne E, du Viver A, Mufti GJ, et al: Rituximab for the treatment of corticosteroid-refractory pemphigus vulgaris with oral and skin manifestations. J Oral Pathol Med Mar 9 doi, 2011.10.1111/j. 1600-0714.2011.01017.x Epub ahead of print.

Eversole RL: Viral infections of the head and neck among HIV-seropositive patients. Oral Surg Oral Med Oral Pathol 73:155–163, 1992.

Ficarra G, Shillitoe E: HIV-related infections of the oral cavity. Crit Rev Oral Biol Med 3:207–231, 1992.

Fiddian A, Ivanyi L: Topical acyclovir in the management of recurrent herpes labialis. Br J Dermatol 109:321–326, 1983.

Fiddian A, Yeo J, Stubbings R, et al: Successful treatment of herpes labialis with topical acyclovir. BMJ 286:1699–1701, 1983.

Flaitz CM, Nichols CM, Hicks MJ: Herpesviridae-associated persistent mucocutaneous ulcers in acquired immunodeficiency syndrome. Oral Surg Oral Med Oral Pathol Oral Radiol Endod 81:433–441, 1996.

Gershon AA, Gershon MD, Breuer J, et al: Advances in the understanding of the pathogenesis and epidemiology of herpes zoster. J Clin Virol 48(Suppl 1):S2–S7, 2010.

Harmenberg J, Oberg B, Spruance S: Prevention of ulcerative lesions by episodic treatment of recurrent herpes labialis: a literature review. Acta Derm Venereol 90:122–130, 2010.

Herbert A, Berg J: Oral mucous membrane diseases of childhood. Semin Dermatol 11:80–87, 1992.

Opstelten W, Neven AK, Eekof J: Treatment and prevention of herpes labialis. Can Fam Physician 54:1683–1687, 2008.

Pruksanonda P, Hall C, Insel R, et al: Primary human herpesvirus 6 infection in young children. N Engl J Med 326:1145–1150, 1992.

Raborn GW, Martel AY, Grace MGA, et al: Oral acyclovir in prevention of herpes labialis. Oral Surg Oral Med Oral Pathol Oral Radiol Endod 85:55–59, 1998.

Regezi JA, Eversole LR, Barker BF, et al: Herpes simplex and cytomegalovirus coinfected oral ulcers in HIV-positive patients. Oral Surg Oral Med Oral Pathol Oral Radiol Endod 81:55–62, 1996.

Rooney J, Bryson Y, Mannia M, et al: Prevention of ultraviolet light-induced herpes labialis by sunscreen. Lancet 338:1419–1422, 1991.

Sacks SL, Griffiths PD, Corey L, et al: Herpes simplex shedding. Antiviral Res 63(Suppl 1):519–526, 2004.

Schubert M, Peterson D, Flournoy N, et al: Oral and pharyngeal herpes simplex virus infection after allogenic bone marrow transplantation: analysis of factors associated with infection. Oral Surg Oral Med Oral Pathol 70:286–293, 1990.

Sciubba JJ: Oral mucosal diseases in the office setting. Part 1. Aphthous stomatitis and herpes simplex infections. Gen Dent 55:347–354, 2007.

Scott DA, Coulter WA, Biagioni PA, et al: Detection of herpes simplex virus type 1 shedding in the oral cavity by polymerase chain reaction and enzyme-linked immunosorbent assay at the prodromal stage of recrudescent herpes labialis. J Oral Pathol Med 26:305–309, 1997.

Spruance S, Stewart J, Freeman D: Early application of topical 15% idoxuridine in dimethyl sulfoxide shortens the course of herpes simplex labialis: a multicenter placebo-controlled trial. J Infect Dis 161:191–197, 1990.

Spruance S, Stewart J, Rowe N, et al: Treatment of recurrent herpes simplex labialis with oral acyclovir. J Infect Dis 161:185–190, 1990.

Triester NA, Woo SB: Topical n-docosanol for management of recurrent herpes labialis. Expert Opin Pharmacother 11:853–860, 2010.

Immunologic and Hereditary Diseases

Anhalt G: Pemphigoid: bullous and cicatricial. Dermatol Clin 8:701–716, 1990.

Anhalt GJ, Kim SC, Stanley JR, et al: Paraneoplastic pemphigus: an autoimmune mucocutaneous disease associated with neoplasia. N Engl J Med 323:1729–1735, 1990.

Bedane C, Prost C, Bernard P, et al: Cicatricial pemphigoid antigen differs from bullous pemphigoid antigen by its exclusive extracellular localization: a study by indirect immunoelectron microscopy. J Invest Dermatol 97:3–9, 1991.

Buxton RS, Cowin P, Franke WW, et al: Nomenclature of the desmosomal cadherins. J Cell Biol 121:481–483, 1993.

Bystryn JD, Rudolph JL: Pemphigus. Lancet 366:61–73, 2005.

Chan L, Regezi J, Cooper K: Oral manifestations of linear IgA disease. J Acad Dermatol 22:362–365, 1990.

Dayan S, Simmons RK, Ahmed AR: Contemporary issues in the diagnosis of oral pemphigoid. Oral Surg Oral Med Oral Pathol Oral Radiol Endod 88:424–430, 1999.

Elder MJ, Lightman S, Dart JKG: Role of cyclophosphamide and high dose steroid in ocular cicatricial pemphigoid. Br J Ophthalmol 79:264–266, 1995.

Ettlin DA: Pemphigus. Dent Clin North Am 49:107–125, 2005.

Fine JD, Bauer EA, Briggaman RA, et al: Revised clinical and laboratory criteria for subtypes of inherited epidermolysis bullosa. J Am Acad Dermatol 24:119–135, 1991.

Freedberg I: Fitzpatrick's Dermatology in General Medicine, 5th ed. New York: McGraw-Hill, 1999:2407–2409, 2398–2403.

Fullerton S, Woodley D, Smoller B, et al: Paraneoplastic pemphigus with autoantibody deposition after autologous bone marrow transplantation. JAMA 267:1500–1502, 1992.

Helm TN, Camisa C, Valenzuela R, et al: Paraneoplastic pemphigus. Oral Surg Oral Med Oral Pathol 75:209–213, 1993.

Humbert P, Pelletier F, Dreno B, et al: Gluten intolerance and skin diseases. Eur J Dermatol 16:4–11, 2006.

Ishi N, Hamada T, Dainichi T, et al: Epidermolysis bullosa acquisita: what's new? J Dermatol 37:220–230, 2009.

Jonsson R, Mountz J, Koopman W: Elucidating the pathogenesis of autoimmune disease: recent advances at the molecular level and relevance to oral mucosal disease. J Oral Pathol Med 19:341–350, 1990.

Kasperkiewicz M, Schmidt E: Current treatment of autoimmune blistering diseases. Curr Drug Discov Technol 6:270–280, 2009.

Knudson RM, Kalaaji AN, Bruce AJ: The management of mucous membrane pemphigoid and pemphigus. Dermatol Ther 23:268–280, 2009.

Koch PJ, Mahoney MG, Ishikawa H, et al: Targeted disruption of the pemphigus vulgaris antigen (desmoglein 3) gene in mice causes loss of keratinocyte cell adhesion with a phenotype similar to pemphigus vulgaris. J Cell Biol 137:1091–1102, 1997.

Marinkovich MP: The molecular genetics of basement membrane diseases. Arch Dermatol 129:1557–1565, 1993.

Murrell DF, Dick S, Ahmed AR, et al: Consensus statement on definitions of disease, end points, and therapeutic response for pemphigus. J Am Acad Dermatol 58:1043–1046, 2008.

Niimi Y, Zhu X-J, Bystryn JC: Identification of cicatricial pemphigoid antigens. Arch Dermatol 128:54–57, 1992.

Otley C, Hall R: Dermatitis herpetiformis. Dermatol Clin 8:759–769, 1990.

Oyama N, Setterfield JF, Powell AM, et al: Bullous pemphigoid antigen II (BP180) and its soluble extracellular domains are major autoantigens in mucous membrane pemphigoid: the pathogenic relevance to HLA class II alleles and disease severity. Br J Dermatol 54:90–98, 2006.

Porter S, Scully C, Midda M, et al: Adult linear immunoglobulin A disease manifesting as desquamative gingivitis. Oral Surg Oral Med Oral Pathol 70:450–453, 1990.

Sacher C, Hunzelmann N: Cicatricial pemphigoid (mucous membrane pemphigoid): current and emerging therapeutic approaches. Am J Clin Dermatol 6:93–103, 2005.

Scully C, Carrozzo M, Gandolfo S et al: Update on mucous membrane pemphigoid. Oral Surg Oral Med Oral Pathol Oral Radiol Endod 88:56–68, 1999.

Sklavounou A, Laskaris G: Paraneoplastic pemphigus: a review. Oral Oncol 34:437–440, 1998.

Vincent SD, Lilly GE, Baker KA: Clinical, historic, and therapeutic features of cicatricial pemphigoid. Oral Surg Oral Med Oral Pathol 76:453–459, 1993.

Williams DM: Non-infectious diseases of the oral soft tissue: a new approach. Adv Dent Res 7:213–219, 1993.

Woodley D: Clearing of epidermolysis bullosa acquisita with cyclosporine. J Am Acad Dermatol 22:535–536, 1990.

Wright J, Fine J, Johnson L: Oral soft tissues in hereditary epidermolysis bullosa. Oral Surg Oral Med Oral Pathol 71:440–446, 1991.

Yancey KB: The pathophysiology of autoimmune blistering diseases. J Clin Invest 115:825–828, 2005.

Zagorodniuk I, Weltfriend S, Shtruminger L, et al: A comparison of anti-desmoglein antibodies and indirect immunofluorescence in the serodiagnosis of pemphigus vulgaris. Int J Dermatol 44:541–544, 2005.

Zhu X, Niimi Y, Bystryn J: Identification of a 160kD molecule as a component of the basement membrane zone as a minor bullous pemphigoid antigen. J Invest Dermatol 94:817–821, 1990.



CHAPTER 2

Ulcerative Conditions

REACTIVE LESIONS

Traumatic Ulcerations

BACTERIAL INFECTIONS

Syphilis
Gonorrhea
Tuberculosis
Leprosy
Actinomycosis
Noma

FUNGAL INFECTIONS

Deep Fungal Infections
Subcutaneous Fungal Infections: Sporotrichosis
Opportunistic Fungal Infections: Phycomycosis (Mucormycosis) and Aspergillosis

IMMUNOLOGIC DISEASES

Aphthous Ulcers
Chronic Ulcerative Stomatitis
Behçet's Syndrome
Reiter's Syndrome
Erythema Multiforme
Drug Reactions
Contact Allergies
Wegener's Granulomatosis
Midline Granuloma
Chronic Granulomatous Disease
Cyclic Neutropenia

NEOPLASMS

Squamous Cell Carcinoma of the Oral Cavity
Carcinoma of the Maxillary Sinus
Basal Cell Carcinoma of the Skin
Squamous Cell Carcinoma of the Skin

An ulcer is defined simply as loss of epithelium. Ulcers that are preceded by blisters (vesicles or bullae) represent a distinct set of oral conditions, which are discussed in Chapter 1. Ulcerative lesions are commonly encountered in dental patients. Although many oral ulcers have similar clinical appearances, their etiologies encompass many disorders, including reactive, infectious, immunologic, and neoplastic diseases.

REACTIVE LESIONS

Traumatic Ulcerations

Etiology. Ulcers are the most common oral soft tissue lesions. Most are caused by simple mechanical trauma, and a cause-and-effect relationship is usually obvious. Many are a result of accidental trauma and generally appear in regions that are readily trapped or abraded between the teeth, such as the lower lip, tongue, and buccal mucosa. A traumatic ulcer in the anterior portion of the tongue of infants with natal teeth is known as *Riga-Fede disease.* Prostheses, most commonly dentures, are frequently associated with traumatic ulcers, which may be acute or chronic.

In unusual circumstances, lesions may be self-induced because of an abnormal habit, and in these circumstances there is some psychological problem. These so-called *factitial injuries* are often as difficult to diagnose as they are to treat. They may prove to be frustrating clinical problems, especially if there is no clinical suspicion of a self-induced cause. Psychological counseling may ultimately be required to help resolve the problem.

Traumatic oral ulcers may also be iatrogenic (induced inadvertently by a health care practitioner, by medical treatment, or by diagnostic procedures). Naturally, respect for the fragility of oral soft tissues is of paramount importance in the treatment of dental patients. Overzealous tissue manipulation or concentration on treating primarily hard tissues may result in accidental, and avoidable, soft tissue injury. Ulcers induced by the removal of adherent cotton rolls, by the negative pressure of a saliva ejector, or by accidental

BOX 2-1 TRAUMATIC ULCERS

ACUTE ULCER
Pain
Yellow base, red halo
History of trauma
Heals in 7 to 10 days if cause eliminated

CHRONIC ULCER
Little or no pain
Yellow base, elevated margins (scar)
History of trauma, if remembered
Delayed healing if irritated, especially tongue lesions
Clinical appearance mimics carcinoma and infectious ulcers

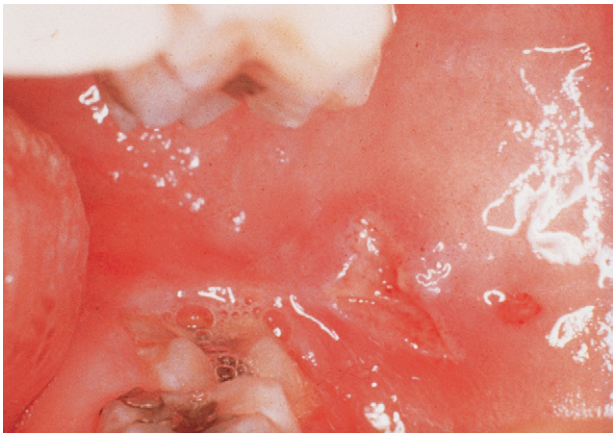

■ **FIGURE 2-1** Acute traumatic ulcer.

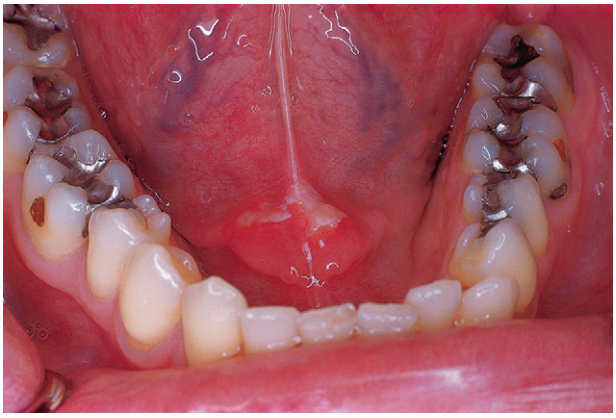

■ **FIGURE 2-2** Acute ulcer of the floor of mouth (saliva ejector injury).

striking of mucosa with rotary instruments are uncommon but entirely preventable.

Chemicals may also cause oral ulcers because of their acidity or alkalinity, or because of their ability to act as local irritants or contact allergens. These may be patient induced or iatrogenic. Aspirin burns are still seen, although they are much less common than in the past. When acetylsalicylic acid is placed inappropriately against mucosa in an attempt by the patient to relieve toothache, a mucosal burn or coagulative necrosis occurs. The extent of injury is dependent on the duration and number of aspirin applications. Many over-the-counter medications for toothache, aphthous ulcers, and denture-related injuries have the ability to damage oral mucosa if used injudiciously. Dental cavity medications, especially those containing phenol, may cause iatrogenic oral ulcers. Tooth-etching agents have been associated with chemical burns of mucosa. Endodontic and vital bleaching procedures, which use strong oxidizing agents such as 30% hydrogen peroxide, have also produced burns.

Intraoral ulcers following heat burns are relatively uncommon intraorally. Pizza burns, caused by hot cheese, have been noted on the palate. Iatrogenic heat burns may also be seen after injudicious use of thermoplastic tooth impression material.

Oral ulcerations are also seen during the course of therapeutic radiation and certain types of chemotherapy for head and neck cancers. In those malignancies—particularly squamous cell carcinoma—that require large (60 to 70 Gy) doses of radiation, oral ulcers are invariably seen in tissues within the path of the beam. Where chemotherapy is a component of treatment, a more widespread ulcer distribution is noted within the oral cavity and oropharynx. For malignancies such as lymphoma, in which lower (40 to 50 Gy) doses are tumoricidal, ulcers are likely but are less severe and of shorter duration. Radiation-induced ulcers persist throughout the course of therapy and for several weeks afterward. If the ulcers are kept clean, spontaneous healing occurs without scarring. The etiology of ulceration and mucositis is related to many factors and involves five biological phases: initiation, primary damage response, signal amplification, ulceration, and healing. The destructive tissue effects are related to the release of active biomolecules secondary to treatment that in turn induce a cascade of inter-related events affecting the extent of damage and repair.

Clinical Features. Acute reactive ulcers of oral mucous membranes exhibit the clinical signs and symptoms of acute inflammation, including variable degrees of pain, redness, and swelling (Box 2-1; Figures 2-1 to 2-7). The ulcers are covered by a yellow-white fibrinous exudate and are surrounded by an erythematous halo.

Chronic reactive ulcers may cause little or no pain. They are covered by a yellow membrane and are surrounded by elevated margins that may show hyperkeratosis. Induration, often associated with these lesions, is due to scar formation and chronic inflammatory cell infiltration.

Mucosal ulceration related to cancer management usually begins at approximately 10 days following initiation of radiation (at 20 to 30 Gy) and /or chemotherapy. With radiation, lesions are noted at all sites through which radiation passes, but with chemotherapy, lesions are seen predominantly in



■ **FIGURE 2-3** Anesthesia-associated acute tongue ulcer.

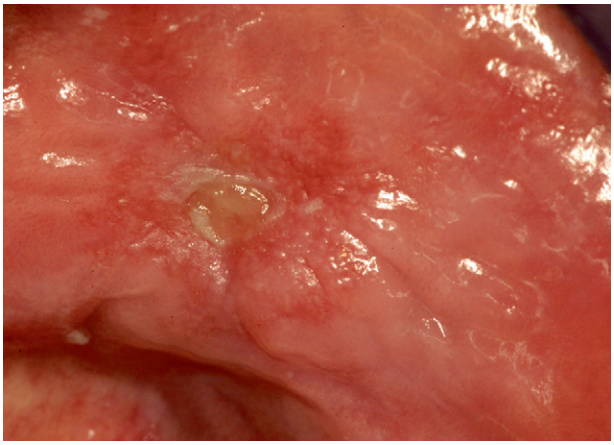

■ **FIGURE 2-4** Ulcer associated with excessive heat from hydrocolloid impression material.



■ **FIGURE 2-5** Chronic ulcer of the lateral tongue.



■ **FIGURE 2-6** Chronic ulcer of the palate.

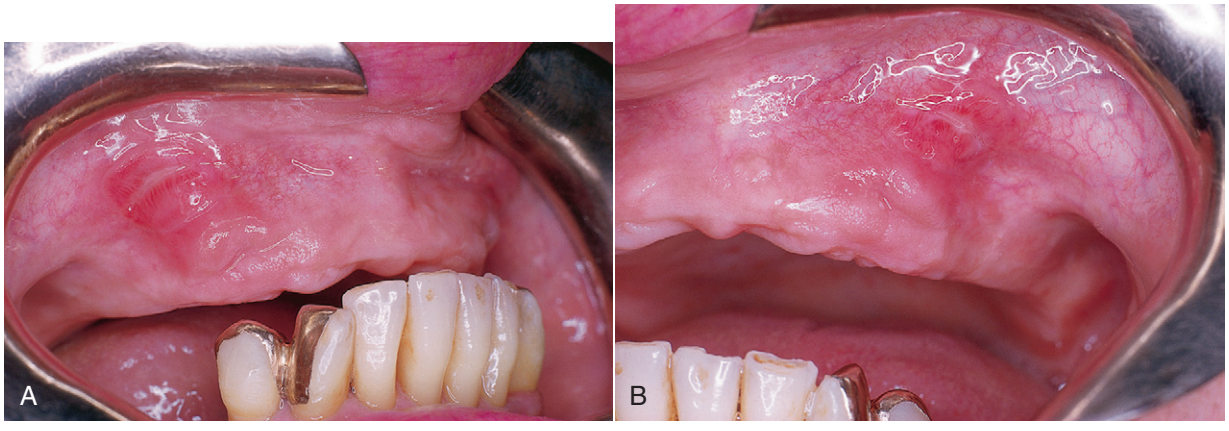

■ **FIGURE 2-7 A** and **B,** Ulcers and erythema caused by a denture flange.

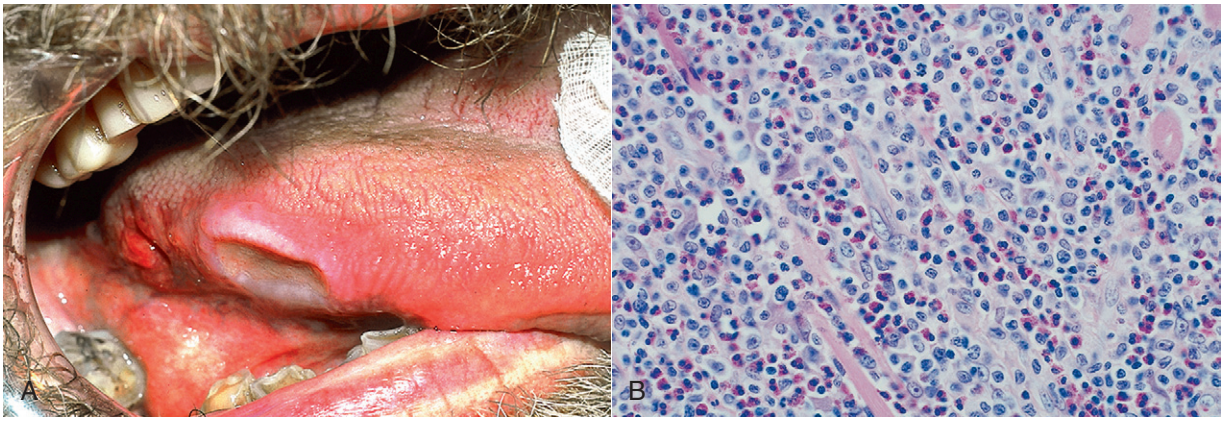

■ **FIGURE 2-8 A** and **B,** Traumatic granuloma. Note eosinophils and macrophages in skeletal muscle in the photomicrograph. (Reproduced with permission from Regezi JA, Sciubba JJ, Pogrel MA: Atlas of Oral and Maxillofacial Pathology. Philadelphia: WB Saunders, 2000, Figs. 1-18 and 1-19.)

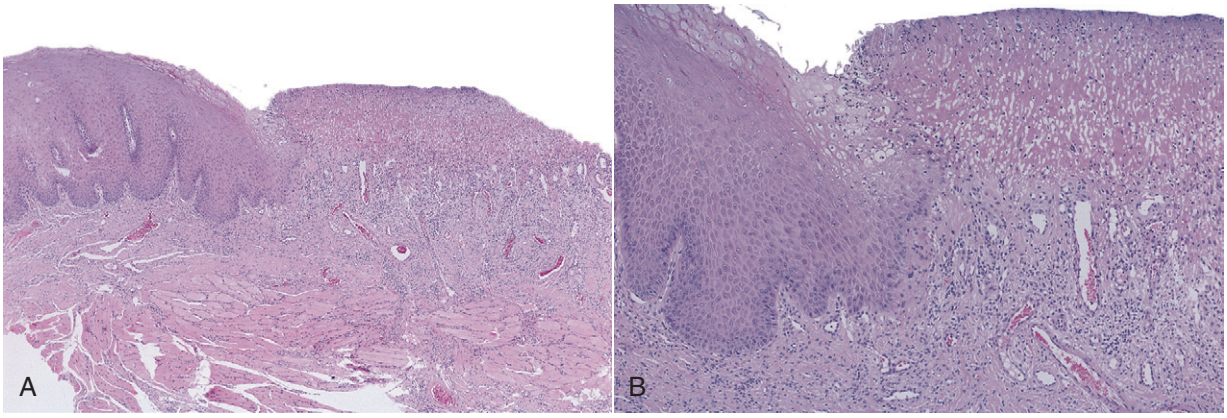

■ **FIGURE 2-9 A** and **B,** Chronic ulcer showing fibrin covering an inflamed granulation tissue base.

movable mucosa (buccal mucosa, lateral and ventral tongue, soft palate and oropharynx).

A particularly ominous-appearing but benign chronic ulcer known as *traumatic granuloma (traumatic ulcerative granuloma with stromal eosinophilia)* occasionally may be seen in association with deep mucosal injury (Figure 2-8). This crateriform ulcer may measure 1 to 2 cm in diameter, and healing may take several weeks to a few months. It is usually found in the tongue with an associated inflammatory infiltrate rich in eosinophils and a subpopulation of CD30+ T lymphocytes.

Another ominous-appearing chronic ulcer, characteristically seen in the hard palate, is known as *necrotizing sialometaplasia.* It is associated with trauma-induced ischemic necrosis of a minor salivary gland and heals spontaneously in several weeks (see Chapter 8).

Histopathology. Acute ulcers show loss of surface epithelium that is replaced by a fibrin network containing predominantly neutrophils (Figure 2-9). The ulcer base contains dilated capillaries and, over time, granulation tissue. Regeneration of the epithelium begins at the ulcer margins, with proliferating cells moving over the granulation tissue base and under the fibrin clot.

Chronic ulcers have a granulation tissue base, with scar found deeper in the tissue. A mixed inflammatory cell infiltrate is seen throughout. Epithelial regeneration occasionally may not occur because of continued trauma or because of unfavorable local tissue factors. It has been speculated that these factors are related to inappropriate adhesion molecule expression (integrins) and/or inadequate extracellular matrix receptors for the keratinocyte integrins. In traumatic granulomas, tissue injury and inflammation extend into subjacent skeletal muscle. Here a characteristic dense macrophage infiltrate with eosinophils may dominate the histologic picture. The term *granuloma* as used here reflects the large numbers of macrophages that dominate the infiltrate, but this is not a typical granuloma as seen in an infectious process, such as tuberculosis.

Diagnosis. With acute reactive ulcers, the cause-and-effect relationship is usually apparent from the clinical examination and history. When there is a factitial etiology, diagnosis becomes a challenge.

The cause of chronic reactive ulcers may not be as readily apparent. In this circumstance, it is important that a differential diagnosis be developed. Conditions to consider are infection (syphilis, tuberculosis, deep fungal infection) and malignancy. If the lesion is strongly suspected to be of traumatic origin, the cause should be sought. A 2-week observation period is warranted, together with an effort to keep the mouth clean using a bland mouth rinse such as sodium bicarbonate in water. If no change is seen, or if the lesion increases in size, a biopsy should be performed.

Treatment. Most reactive ulcers of oral mucous membranes are simply observed. If pain is considerable, topical treatment may be beneficial, such as in the form of a topical corticosteroid. Healing of traumatic granuloma is spontaneous, but topical and intralesional steroids can accelerate healing and reduce symptoms.

BACTERIAL INFECTIONS

Syphilis

Syphilis is a sexually transmitted disease that was virtually incurable until Dr. Paul Ehrlich developed his "magic bullet," arsphenamine, around the turn of the twentieth century. A stunning change in the control of syphilis followed the introduction of penicillin in the early 1940s. By then, approximately 600,000 new cases were reported annually in the United States; during the next 15 years, the rate declined to 6000 cases per year. An increase in the number of new cases (peaking at about 50,000 in 1990), due in part to an association with human immunodeficiency virus (HIV) infection and drug abuse, followed until today, when there seems to be some measure of control of this disease. A significant number of new cases of syphilis are reported in gay men, having a strong association with HIV coinfection and high-risk sexual behavior. In cases with concurrent HIV disease, an atypical clinical course may be noted, including more severe constitutional symptoms, necrotic cutaneous ulcerations, organ and ocular involvement, and a greater tendency to develop neurosyphilis.

Etiology and Pathogenesis. Syphilis is caused by the spirochete *Treponema pallidum* (Figure 2-10). It is acquired by sexual contact with a partner with active lesions, by transfusion of infected blood, or by transplacental inoculation of the fetus by an infected mother.

When the disease is spread through direct contact, a hard ulcer, or *chancre,* forms at the site of spirochete entry (Box 2-2). The ulceration is typically deep with a red, brown, or purple base and an irregular raised border, with resemblance to a chronic traumatic ulcer, squamous cell carcinoma, and non-Hodgkin's lymphoma. Later, a painless, nonsuppurative regional lymphadenopathy develops. The chancre heals spontaneously after several weeks without treatment, leaving the patient with no apparent signs of disease. After a latent period of several weeks, secondary syphilis develops (patients infected via transfusion bypass the primary stage and begin

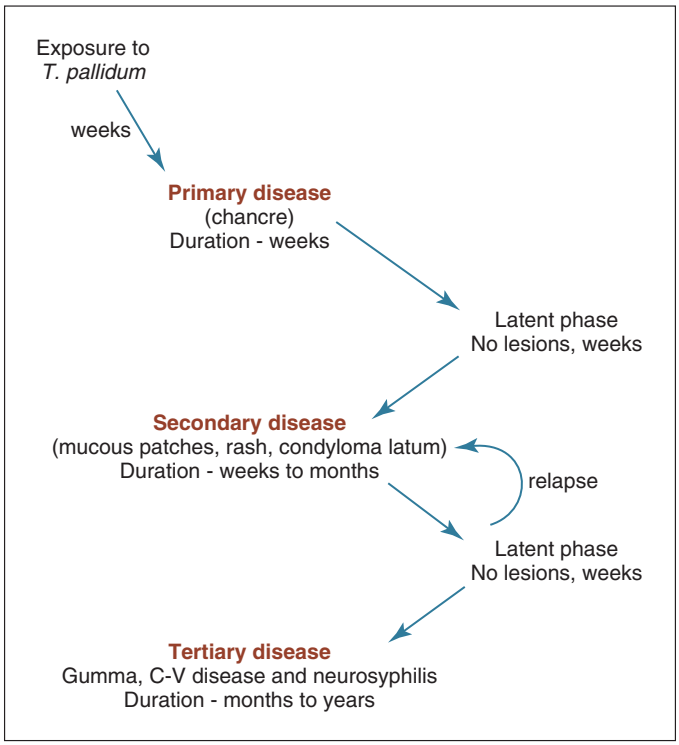

■ **FIGURE 2-10** Pathogenesis of syphilis (untreated).

BOX 2-2 CLASSIFICATION OF SYPHILIS

ACQUIRED SYPHILIS

Early

Primary (chancre)

Secondary (oral mucous patches, skin lesions, other organopathy)

Latency

Late

Latency

Tertiary (gumma, cardiovascular disease, neurosyphilis)

CONGENITAL SYPHILIS

Early

Secondary disease

Spirochetemia affecting many organ systems

Stigmata include dental defects, eighth-nerve deafness, ocular keratitis, bone and joint lesions, other organopathy

Late

Latency

BOX 2-3 SYPHILIS

CAUSE

Treponema pallidum, sexually transmitted

CLINICAL FEATURES

Primary phase: chancre, a chronic ulcer at the site of infection

Secondary phase: oral mucous patches, condyloma latum, maculopapular rash

Tertiary phase: gummas (destructive ulcers), central nervous system and cardiovascular diseases

Congenital form: abnormal shape of molars/incisors, deafness, ocular keratitis, skeletal defects

TREATMENT

Penicillin, tetracyclines

with secondary syphilis) as a result of hematogenous spread of the spirochete. This stage is marked by a spirochetemia with wide dissemination. Fever, flulike symptoms, mucocutaneous lesions, and lymphadenopathy are typical. In secondary disease, oral lesions are rarely deeply ulcerated, but rather show mucoid exudate (mucous patches). At the labial commissures, split papules may form, while lateral tongue lesions may manifest as deep fissures. This stage also resolves spontaneously, and the patient enters another latency period. Relapses to secondary syphilis may occur in some patients. In about one third of those who have entered the latency phase and have not been treated, tertiary, or late-stage, syphilis develops. These patients may have central nervous system (CNS) involvement, cardiovascular lesions, or focal necrotic inflammatory lesions, known as *gummas,* of any organ.

Congenital syphilis occurs during the latter half of pregnancy, when the *T. pallidum* organism crosses the placenta from the infected mother. The spirochetemia that develops in the fetus may cause numerous inflammatory and destructive lesions in various fetal organs, or it may cause abortion.

Clinical Features. Primary syphilis results in painless indurated ulcer(s) with rolled margins at the site of inoculation (Box 2-3; Figures 2-11 to 2-15). The lesion does not produce an exudate. The location is usually on the genitalia. Depending on the site of primary infection, lip, oral, and finger lesions also occur and exhibit similar clinical features. Regional lymphadenopathy, typified by firm, painless swelling, is also part of the clinical picture. The lesion heals without therapy in 3 to 12 weeks, with little or no scarring.

In untreated syphilis, secondary disease begins after about 2 to 10 weeks. The spirochetes are now disseminated widely and are the cause of a reddish brown maculopapular



■ **FIGURE 2-11** Primary syphilis (chancre). (From Kerr DA, Ash MM Jr, Millard HD: Oral Diagnosis, ed 3, St Louis, 1983, Mosby.)



■ **FIGURE 2-12 Secondary syphilis.** Cutaneous macular lesions.



■ **FIGURE 2-13** Condyloma latum of secondary syphilis.

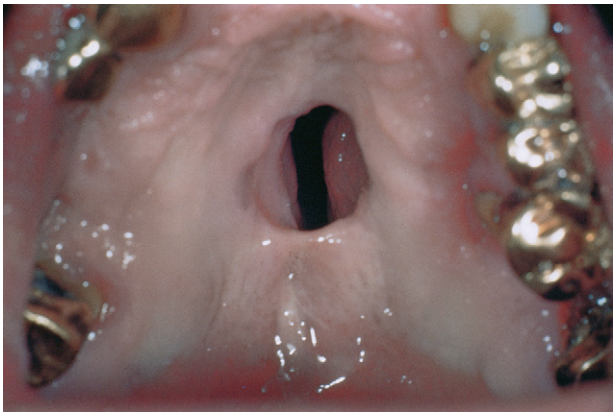

■ **FIGURE 2-14 Tertiary syphilis.** Palatal fistula resulting from a gumma.



■ **FIGURE 2-15 Congenital syphilis.** Mulberry molars and notched incisors.

cutaneous rash and mucosal ulcers covered by a mucoid exudate (mucous patches). Elevated broad-based verrucal plaques, known as *condylomata lata,* may appear on the skin and mucosal surfaces. Inflammatory lesions may occur in any organ during secondary syphilis.

Manifestations of tertiary syphilis take many years to appear and can be profound, because there is a predilection for the cardiovascular system and the CNS. Fortunately, this stage of syphilis has become a rarity because of effective antibiotic treatment. In untreated disease, approximately one third of patients progress into a tertiary stage.

Manifestations of neural syphilis include general paresis (paralysis) and tabes dorsalis (locomotor ataxia). Inflammatory involvement of the cardiovascular system, especially the aorta, may result in aneurysms. Focal granulomatous lesions (gummas) may involve any organ. Intraorally, the palate is typically affected, which can lead to palatal perforation. Development of generalized glossitis with mucosal atrophy has been well documented in the tertiary stage of this disease. Although patients with so-called syphilitic or luetic glossitis are thought to have an approximately fourfold increased risk of oral squamous cell carcinoma, it is unclear whether this is a result of the disease, or whether it is due to the carcinogenic agents that were formerly used to treat the condition, such as arsenicals and heavy metals.

The generalized spirochetemia of congenital syphilis may result in numerous clinical manifestations that may affect any organ system in a developing fetus. A mucocutaneous rash may be seen early. When the infectious process involves the vomer, a nasal deformity known as *saddle nose* develops; when periostitis of the tibia occurs, excessive anterior bone growth results in a deformity known as *saber shin.* Other late stigmata of congenital syphilis include conditions known collectively as *Hutchinson's triad:* (1) an inflammatory reaction in the cornea (interstitial keratitis), (2) eighth-nerve deafness, and (3) dental abnormalities consisting of notched or screwdriver-shaped incisors and mulberry molars, presumably occurring because of spirochete infection of the enamel organ of teeth during amelogenesis.

Histopathology. The basic tissue response to *T. pallidum* infection consists of a proliferative endarteritis and infiltration of plasma cells. Endothelial cells proliferate within small arteries and arterioles, producing a concentric layering of cells, which results in a narrowed lumen. Plasma cells, along with lymphocytes and macrophages, are typically found in a perivascular distribution. Spirochetes can be demonstrated in the tissues of various lesions of syphilis using silver stains, although they may be scant in tertiary lesions. Gummas may show necrosis and greater numbers of macrophages, resulting in a granulomatous lesion that is similar to other conditions, such as tuberculosis (TB).

Differential Diagnosis. Clinically, as well as microscopically, syphilis is said to be the great imitator or mimicker because of its resemblance to many other unrelated conditions. When it presents within the mouth, the chancre may be confused with and must be differentiated from squamous cell carcinoma, chronic traumatic lesions, and other infectious diseases, such as TB and histoplasmosis. The differential diagnosis of secondary syphilis would include many infectious and noninfectious conditions marked by a mucocutaneous eruption. Palatal gummas, although rarely seen,

may have a clinical appearance similar to the destructive lesions of NK/T-cell lymphoma.

Definitive diagnosis of syphilis is based on laboratory test confirmation of the clinical impression. Among several tests available are (1) darkfield examination of scrapings or exudate from active lesions; (2) special silver stain or immunologic preparation of biopsy tissue; (3) serologic tests for antibodies to *T. pallidum,* such as the Venereal Disease Research Laboratory test (VDRL), rapid plasmin reagin (RPR), and the enzyme-linked immunosorbent assay (ELISA); and (4) direct fluorescence microscopy of lesional tissue with fluorescein-labeled anti-*Treponema* serum.

Treatment. The drug of choice for treating all stages of syphilis is penicillin. Through the years, *T. pallidum* has remained sensitive to penicillin, as well as to other antibiotics such as erythromycin and tetracyclines.

Gonorrhea

Etiology. Gonorrhea is one of the most prevalent bacterial diseases in humans. It is caused by the gram-negative diplococcus *Neisseria gonorrhoeae,* which infects columnar epithelium of the lower genital tract, rectum, pharynx, and eyes. Infection is transmitted by direct sexual contact with an infected partner. Containment of the spread of infection in sexual partners is enhanced by the short incubation period of less than 7 days, permitting contact tracing, but is hampered by the absence of symptoms in many individuals, especially females.

Genital infections may be transmitted to the oral or pharyngeal mucous membranes through orogenital contact. Pharyngeal mucosa is more likely to be infected than oral mucosa because of the type of epithelium and its reduced resistance to trauma, with pharyngitis as the chief complaint. Developing this form of disease is apparently much more likely with fellatio than with cunnilingus. Individuals may have concomitant genital and oral or pharyngeal infections that result from direct exposure to these areas rather than from being spread through blood or lymphatics.

Transmission of gonorrhea from an infected patient to dental personnel is regarded as highly unlikely because the organism is very sensitive to drying and requires a break in the skin or mucosa to establish an infection. Gloves, protective eyewear, and a mask should provide adequate protection from accidental transmission.

Clinical Features. No specific clinical signs have been consistently associated with oral gonorrhea. However, multiple ulcerations and generalized erythema have been described. Symptoms range from none to generalized stomatitis.

In the more common pharyngeal gonococcal infection, presenting signs are usually seen as general erythema with associated ulcers and cervical lymphadenopathy. The chief complaint may be sore throat, although many patients are asymptomatic.

Differential Diagnosis. Because of the lack of consistent and distinctive oral lesions, other conditions that cause multiple ulcers or generalized erythema should be included in a differential diagnosis. Aphthous ulcers, herpetic ulcers, erythema multiforme, pemphigus, pemphigoid, drug eruptions, and streptococcal infection should be considered. Diagnosis of gonorrhea is traditionally based on demonstration of the organism with Gram stain or culture on Thayer-Martin medium. Rapid identification of *N. gonorrhoeae* with immunofluorescent antibody techniques and other laboratory tests may be used to support clinical impressions.

Treatment. Uncomplicated gonorrhea responds to a single dose of appropriately selected antibiotic. In the West, infections are susceptible to penicillins and treatment is effective with a single parenteral dose of 2.0 to 3.5 g of ampicillin. In the Far East and parts of Africa, up to 50% of cases are resistant to penicillins and can be managed with a single 500-mg dose of ciprofloxacin. This regimen is also appropriate for pharyngeal gonorrhea, for which ampicillin is generally ineffective. Concerns have been expressed about the development of gonococcal resistance to antibiotics. Some strains already have been reported to be resistant to cephalosporins and fluoroquinolone, including multidrug-resistant forms. Thus, fewer treatment options are available.

Tuberculosis

Etiology and Pathogenesis. Tuberculosis (TB) infects about one third of the world's population and kills approximately 3 million people per year, making it one of the most important cause of death in the world. In developed countries, a significant decrease in the incidence of TB has occurred as the result of improvements in living conditions, reductions in overcrowding, and antibiotic use. However, the 1980s saw a re-emergence of significant numbers of cases of TB, many in association with HIV infection and acquired immunodeficiency syndrome (AIDS), in Europe and Africa. In addition, the issue of multidrug resistance has proved to be a growing problem in management of the disease.

TB is caused by the aerobic, non–spore-forming bacillus *Mycobacterium tuberculosis* (Figure 2-16). The organism has a thick, waxy coat that does not react with Gram stains but retains the red dyes (Ziehl-Neelsen and Fite techniques). With these stains, the organisms do not decolor with acid-alcohol and therefore are also known as *acid-fast bacilli.* Two major forms of *Mycobacterium* are recognized: *M. tuberculosis* and *M. bovis. M. tuberculosis* is an airborne infection that is transmitted by inhalation of infected droplets. *M. bovis* is primarily a disease of cows that is transmitted to humans through infected milk, producing intestinal or tonsillar lesions. Two other closely related forms of *Mycobacterium* are recognized: *M. avium* and *M. intracellulare.* Both are nonvirulent in healthy individuals but cause disseminated disease in immunocompromised individuals, such as those with HIV infection or AIDS.

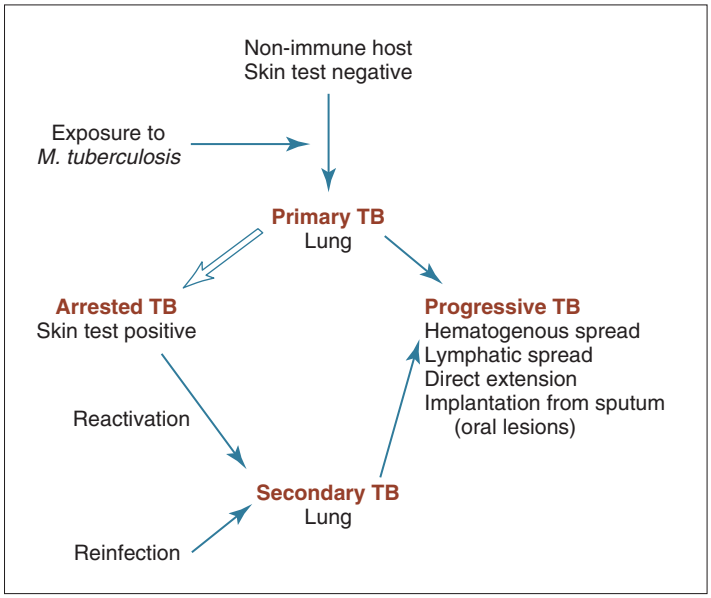

■ **FIGURE 2-16** Pathogenesis of tuberculosis.

M. tuberculosis infection is spread through small airborne droplets, which carry the organism to pulmonary air spaces. Phagocytosis by alveolar macrophages follows, and the battle between bacterial virulence and host resistance begins. The pathogenicity of *M. tuberculosis* is due both to its ability to resist degradation by macrophages and to the development of a type IV hypersensitivity reaction. This latter feature explains the destructiveness of lesions in the host tissues and the emergence of drug-resistant strains. As the immune system is sensitized by mycobacterial antigens, positive tuberculin reactivity develops. The Mantoux and tine skin tests, which use a tubercle bacillus antigen called *purified protein derivative (PPD)*, determine whether an individual is hypersensitive to antigen challenge. A positive inflammatory skin reaction indicates that the individual's cell-mediated immune system has been sensitized and signifies previous exposure and subclinical infection. It does not necessarily imply active disease.

A granulomatous inflammatory response to *M. tuberculosis* follows sensitization. In most cases, the cell-mediated immune response is able to control the infection, allowing subsequent arrest of the disease. Inflammatory foci eventually may undergo dystrophic calcification, but latent organisms in these foci may become reactivated at a later date. In a small number of cases, the disease may progress through airborne, hematogenous, or lymphatic spread, so-called miliary spread.

Oral mucous membranes may become infected through implantation of organisms found in sputum or, less commonly, through hematogenous deposition. Similar seeding of the oral cavity may follow secondary or reactivated TB.

Clinical Features. Unless the primary infection becomes progressive, an infected patient will probably exhibit no symptoms (Box 2-4; Figure 2-17). Skin testing and chest radiographs may provide the only indicators of infection. In reactivated disease, low-grade signs and symptoms of fever, night sweats, malaise, and weight loss may appear. With progression, cough, hemoptysis, and chest pain (pleural involvement) occur. As other organs become involved through the spread of organisms, a highly varied clinical picture appears and is dependent on the organs involved.

Oral manifestations that usually follow implantation of *M. tuberculosis* from infected sputum may appear on any mucosal surface. The tongue and the palate are favored locations. The typical lesion is an indurated, chronic, nonhealing ulcer that is usually painful. Bony involvement of the maxilla

BOX 2-4 TUBERCULOSIS

ETIOLOGY

Mycobacterium tuberculosis; oral lesions follow lung infections

Risk factors—overcrowding, debilitation, immunosuppression

Important public health disease

CLINICAL FEATURES

Chronic ulcers, nonhealing and indurated, often multiple

HISTOPATHOLOGY

Caseating granulomas (macrophages) with Langerhans giant cells

TREATMENT

Prolonged, multidrug therapy required (isoniazid, rifampin, ethambutol)

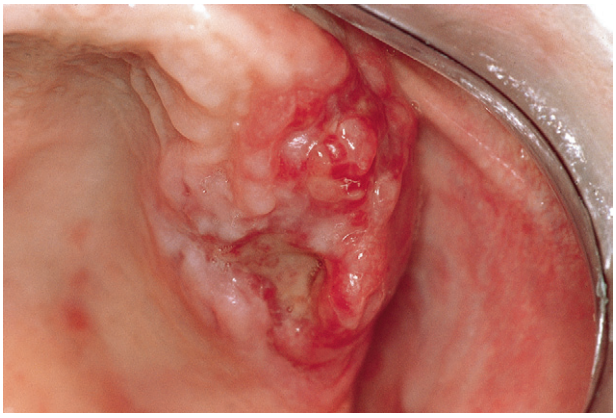

■ **FIGURE 2-17** Tuberculosis of the maxillary alveolar ridge.

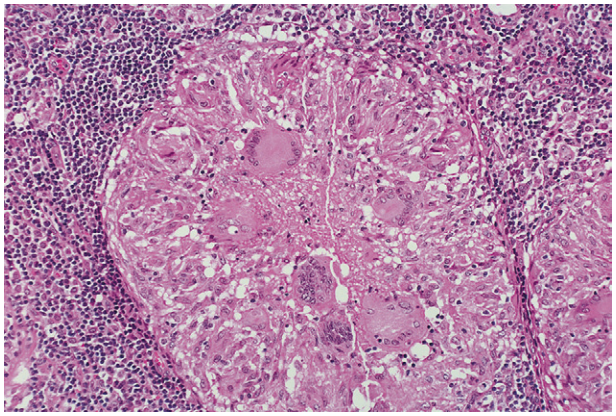

■ **FIGURE 2-18** Tuberculosis granuloma composed of macrophages and multinucleated giant cells.

and mandible may produce tuberculous osteomyelitis. This most likely follows hematogenous spread of the organism. Pharyngeal involvement results in painful ulcers, which may cause dysphagia, odynophagia, and voice changes.

Histopathology. The basic microscopic lesion of TB is granulomatous inflammation, in which granulomas show central caseous necrosis (Figure 2-18). In tissues, *M. tuberculosis* incites a characteristic macrophage response, in which focal zones of macrophages become surrounded by lymphocytes and fibroblasts. The macrophages develop an abundant eosinophilic cytoplasm, giving them a superficial resemblance to epithelial cells; for this reason, they are frequently called *epithelioid cells.* Fusion of macrophages results in the appearance of Langerhans giant cells, in which nuclei are distributed around the periphery of the cytoplasm. As the granulomas age, central necrosis occurs; this is usually referred to as *caseous necrosis* because of the gross cheesy texture of these zones.

A Ziehl-Neelsen or Fite stain must be used to confirm the presence of the organism in the granulomas, because several infectious and noninfectious conditions may produce a similar granulomatous reaction (Figure 2-19). In the absence

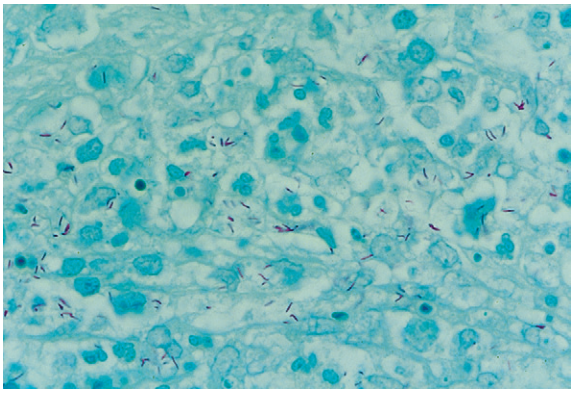

■ **FIGURE 2-19** Fite stain showing tuberculosis microorganisms (red rods). (Reproduced with permission from Regezi JA, Sciubba JJ, Pogrel MA: Atlas of Oral and Maxillofacial Pathology. Philadelphia, 2000, WB Saunders, Fig. 1-31.)

of acid-fast bacilli, other microscopic considerations would include syphilis, cat-scratch disease, tularemia, histoplasmosis, blastomycosis, coccidioidomycosis, sarcoidosis, and some foreign body reactions, such as those induced by beryllium.

Differential Diagnosis. On the basis of clinical signs and symptoms alone, oral TB cannot be differentiated from several other conditions. A chronic indurated ulcer should prompt the clinician to consider primary syphilis and oral manifestations of deep fungal diseases. Noninfectious processes that should be considered clinically are foreign body reaction, sarcoidosis, Crohn's disease, orofacial granulomatosis, squamous cell carcinoma, and chronic traumatic ulcer. Major aphthae might be included, although a history of recurrent disease should help separate this condition from the others. In approximately half of cases, the diagnosis or oral manifestation of oral tuberculosis has led to a diagnosis of undiagnosed systemic infection. Rarely, carcinomas may coexist at the same lesion site.

Treatment. First-line drugs likely to be used for treatment of TB include isoniazid, rifampin, pyrazinamide, and ethambutol. Drug combinations are often used in 6-, 9-, or 12-month treatment regimens that may be extended as long as 2 years. Streptomycin is rarely used for first-line treatment except in multidrug-resistant cases. Oral lesions would be expected to resolve with treatment of the patient's systemic disease. Unfortunately, infection with multidrug-resistant organisms is a serious clinical problem that appears to be on the increase. Development and testing of new classes of drugs are necessary to meet the challenge of resistant organisms.

Patients who convert from a negative to a positive skin test response may benefit from prophylactic chemotherapy, typically using isoniazid for 1 year. This decision is dependent on risk factors involved, such as age and immune status, and on the opinion of the attending physician.

Bacille Calmette-Guérin (BCG) vaccine is effective in controlling childhood TB, but it loses efficacy in adulthood. New vaccines that are under investigation offer hope for at-risk populations.

Leprosy

Etiology and Pathogenesis. Leprosy, also known as Hansen's disease, is a chronic infectious disease caused by the acid-fast bacillus, *Mycobacterium leprae*. Worldwide, 20 million individuals are thought to be infected. It is the most common cause of peripheral neuritis in the world. Because the causative organism is difficult to grow in culture, it has been maintained in the footpads of mice and in the armadillo, which has a low core body temperature. Leprosy is only moderately contagious; transmission of the disease requires frequent direct contact with an infected individual for a long period, with an incubation period ranging up to 5 years for the tuberculoid form versus up to 12 years in the lepromatous form of the disease. Inoculation through the respiratory tract is believed to be a potential mode of transmission.

Clinical Features. Oral lesions appear in the lepromatous form of the disease in 20% to 60% of cases as multiple nodules (necrotic and ulcerated) with associated slow healing and atrophic scarring. A clinical spectrum of disease ranges from a limited form (tuberculoid leprosy) in those with a well-functioning immune system, to a generalized form (lepromatous leprosy) in individuals with reduced levels of cell-mediated immune reactivity; the latter has a more seriously damaging course. Generally, skin and peripheral nerves are affected because the organism grows best in temperatures less than the core body temperature of 37° C. Cutaneous lesions appear as erythematous plaques or nodules, representing a granulomatous response to the organism. Similar lesions may occur intraorally or intranasally. In time, severe maxillofacial deformities may appear, producing the classic destruction of the anterior nasal spine and anterior maxillary alveolus, as well as intranasal inflammation and tissue destruction called *facies leprosa.* Damage to peripheral nerves results in anesthesia, leading to trauma to the extremities and consequent ulceration, as well as bone resorption.

Histopathology. Microscopically, a granulomatous inflammatory response, in which macrophages/epithelioid histiocytes and multinucleated giant cells predominate, is usually seen. Infiltration of nerves by mononuclear inflammatory cells is also noted. Well-formed granulomas, similar to those present in the tissue lesions of TB, are typically seen in tuberculoid leprosy. Poorly formed granulomas with sheets of macrophages reflect the pattern more typical of leproid leprosy. Acid-fast bacilli can be found within macrophages and are best demonstrated with the Fite stain. Organisms are most numerous in the lepromatous form of leprosy.

Diagnosis. A history of contact with a known infected patient or of living in a known endemic area is important for establishing a diagnosis. Signs and symptoms associated with skin and nerve involvement should provide additional clues to the nature of the disease. The appearance of oral lesions without skin lesions is highly improbable. The differential diagnosis includes late-stage syphilis, sarcoidosis, cutaneous leishmaniasis, lupus erythematosus, lymphoma, and neoplastic disease. A biopsy must be performed to confirm the diagnosis because no laboratory test for leprosy has been developed.

Treatment. Current treatment centers on a chemotherapeutic approach in which several drugs are used over a protracted period, typically years. The drugs most commonly used include dapsone, rifampin, clofazimine, and minocycline. The known teratogen thalidomide is useful for managing the complications of leprosy therapy, as are thalidomide analogs (e.g., lenalidomide) by virtue of their general immunomodulatory properties.

Actinomycosis

Etiology and Pathogenesis. Actinomycosis is a chronic bacterial disease that, as the name suggests, exhibits some clinical and microscopic features that are fungus-like. It is most commonly caused by *Actinomyces israelii,* an anaerobic or microaerophilic, gram-positive bacterium. On rare occasions, other *Actinomyces* species may be involved, or a related aerobic bacterium, *Nocardia asteroides,* may be responsible for a similar clinical picture. *A. israelii* is a normal inhabitant of the oral cavity in a majority of healthy individuals. It is usually found in tonsillar crypts, gingival crevices, carious lesions, and nonvital dental root canals. Actinomycosis is not regarded as a contagious disease because infection cannot be transmitted from one individual to another. Infection usually appears after trauma, surgery, or previous infection. Tooth extraction, gingival surgery, and oral infection predispose to the development of this condition. Evidence of other important predisposing factors has been slight, although actinomycotic infections have been recorded in osteoradionecrosis and bisphosphonate-related osteonecrosis of the jaw, and in patients with serious systemic illness.

Clinical Features. Most infections from *A. israelii* are seen in the thorax, abdomen, and head and neck; they are usually preceded by trauma or direct extension of a contiguous infection. When it occurs in the head and neck, the condition is usually designated *cervicofacial actinomycosis* (Figure 2-20). It typically presents as swelling of the mandible that may simulate a pyogenic infection. The lesion may become indurated and eventually may form one or more draining sinuses, leading from the medullary spaces of the mandible to the skin of the neck. The clinical course ranges from acute to chronic. The skin lesions are indurated and are described as having a "woody hard" consistency. Any



■ **FIGURE 2-20 Actinomycosis.** Cervicofacial actinomycosis. (Reproduced with permission from Regezi JA, Sciubba JJ, Pogrel MA: Atlas of Oral and Maxillofacial Pathology. Philadelphia, 2000, WB Saunders, Fig. 10-15.)

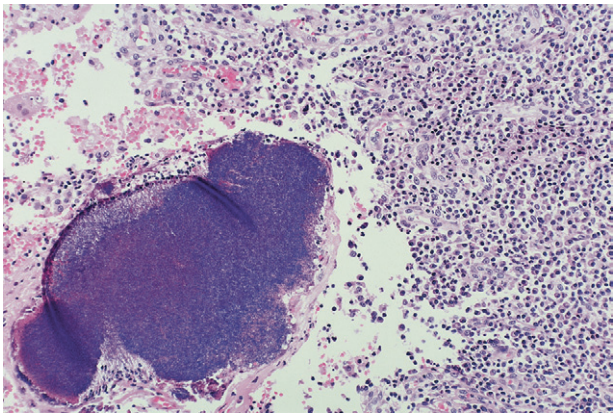

■ **FIGURE 2-21** Actinomycosis colony (sulfur granule) surrounded by pus.

mucosal site may be involved; bony sites are also commonly infected. Less commonly, the maxilla may be involved, resulting in an osteomyelitis that may drain through the gingiva via a sinus tract. Pus draining from the chronic lesion may contain small yellow granules, known as *sulfur granules,* which represent aggregates of *A. israelii* organisms. Radiographically, this infection presents as a lucency with irregular and ill-defined margins.

Histopathology. A granulomatous inflammatory response with central abscess formation is seen in actinomycosis (Figures 2-21 and 2-22). At the center of the abscesses, distinctive colonies of gram-positive organisms may be seen. Radiating from the center of the colonies are numerous filaments with clubbed ends.

Differential Diagnosis. Clinically, actinomycosis may have to be differentiated from osteomyelitis caused by other bacterial or fungal organisms. Infection of the soft tissue of the neck, such as scrofula, and staphylococcal infection, such as botryomycosis, may also be considered.

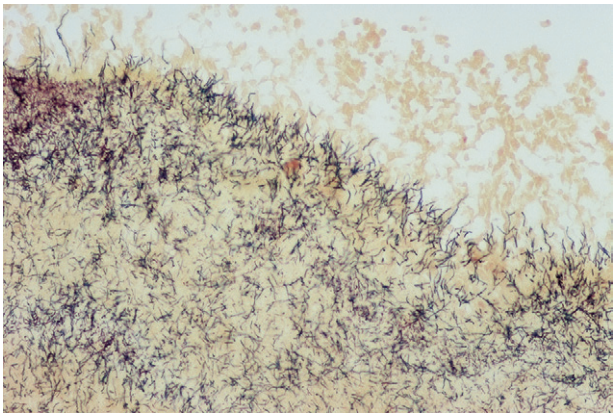

■ **FIGURE 2-22 Actinomycosis.** Gram stain of colony showing peripheral gram-positive filaments.

Definitive diagnosis is dependent on identification of the actinomycotic organism. This may be done through direct examination of exudate, microscopic evaluation of tissue sections, or microbiologic culture of pathologic material.

Treatment. Long-term, high-dose penicillin or penicillin analogs are the required antibiotic regimen for actinomycosis. In severe cases, intravenous penicillin followed by prolonged oral penicillin administration from several months to up to a year in deep, chronic disease is a standard regimen. Less severe cases require protracted courses of oral penicillin. Tetracycline and erythromycin have been used to effect cure. In addition, drainage of abscesses, debridement, and surgical excision of scar and sinus tracts are recommended to aerate tissue and to enhance penetration of antibiotics.

Noma

Noma, also known as *cancrum oris* and *gangrenous stomatitis,* is a devastating disease of malnourished children that is characterized by a destructive process of the orofacial tissues. The condition is rare in developed countries but is a relatively common cause of childhood mortality and morbidity in parts of Africa, South America, and Asia.

Etiology and Pathogenesis. Necrosis of tissue occurs as a consequence of invasion by anaerobic bacteria in a host whose systemic health is significantly compromised. It has been proposed that noma results from oral contamination by a heavy infestation of Bacteroidaceae, particularly *Fusobacterium necrophorum,* and a consortium of other microorganisms, including *Borrelia vincentii, Staphylococcus aureus,* and *Prevotella intermedia.* These opportunistic pathogens invade oral tissues whose defenses are weakened by malnutrition, acute necrotizing gingivitis, debilitating conditions, trauma, and other oral mucosal ulcers. Other

TABLE 2-1 DEEP FUNGAL INFECTIONS: MORPHOLOGIC FEATURES

Organism	Size, µm	Histology	Appearance
Histoplasmosis	2-5	Yeasts in macrophages	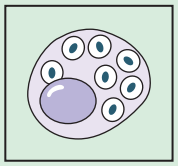
Coccidioidomycosis	30-60	Endospores in spherules	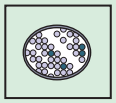
Blastomycosis	8-15	Budding yeasts	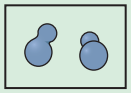
Cryptococcosis	2-15	Yeasts with thick capsule	

predisposing factors include debilitation caused by systemic disease, such as pneumonia or sepsis.

Clinical Features. Noma typically affects children. A related disorder, noma neonatorum, occurs in low-birth-weight infants who suffer from other debilitating diseases. The initial lesion of noma is a painful ulceration, usually of the gingiva or buccal mucosa, which spreads rapidly and eventually becomes necrotic. Denudation of involved bone may follow, eventually leading to necrosis and sequestration. Teeth in the affected area may become loose and may exfoliate. Penetration of organisms into the cheek, lip, or palate may also occur, resulting in fetid necrotic lesions.

Treatment. Therapy involves treating the underlying predisposing condition, as well as the infection itself. Therefore fluids, electrolytes, and general nutrition are restored, along with the introduction of antibiotics. Antibiotics of choice include clindamycin, piperacillin, and the aminoglycoside gentamicin. Debridement of necrotic tissue may be beneficial if destruction is extensive, with reconstructive surgery a late option following acute management and healing.

FUNGAL INFECTIONS

Deep Fungal Infections

Etiology and Pathogenesis. Deep fungal infections are characterized by primary involvement of the lungs. Infections may disseminate from this focus to involve other organs.

Deep fungal infections having a significant incidence of oral involvement include histoplasmosis, coccidioidomycosis, blastomycosis, mucormycosis, and cryptococcosis (Box 2-5; Table 2-1). Oral infections typically follow implantation of infected sputum in oral mucosa. Oral infections may also follow hematogenous spread of fungus from another site such as the lung, and may present as the initial sign of the disease.

BOX 2-5 DEEP FUNGAL INFECTIONS*

Pathogenesis: inhalation of spores
Symptoms: cough, fever, weight loss, other
Primary site: lung; may be asymptomatic
Oral lesions: chronic, nonhealing ulcers resulting from lung disease
Microscopy: granulomatous inflammation with organisms
Treatment: ketoconazole, fluconazole, itraconazole, amphotericin B

*Histoplasmosis *(Histoplasma capsulatum)*, coccidioidomycosis *(Coccidioides immitis)*, blastomycosis *(Blastomyces dermatitidis)*, cryptococcosis *(Cryptococcus neoformans)*.

Histoplasmosis is worldwide in distribution, although it is endemic in the Midwestern United States and has served as an indicator of HIV disease. Inhalation of yeast from the dust of dried pigeon droppings is regarded as the most common source of infection. Coccidioidomycosis is endemic in the Western United States, especially in the San Joaquin Valley of California, where it is known as *valley fever*. Blastomycosis is usually encountered in North America, especially in the Ohio-Mississippi River basin area. *Cryptococcus* infection may be transmitted through inhalation of avian excrement, but it also may occur in immunocompromised patients.



■ **FIGURE 2-23** Histoplasmosis-caused chronic ulcers.

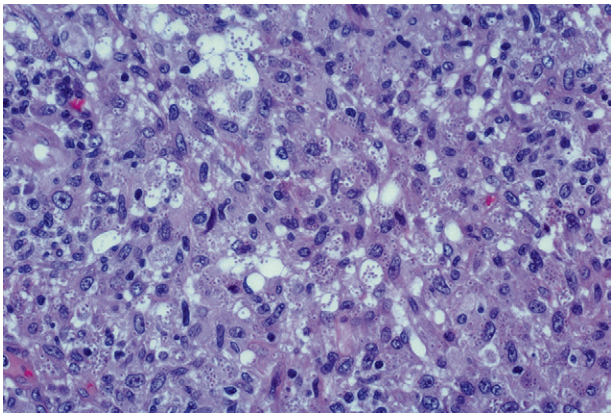

■ **FIGURE 2-24** Histoplasmosis showing macrophages with cytoplasmic microorganisms.

BOX 2-6 CHRONIC INFECTIOUS ULCERS

TYPES

Syphilis, tuberculosis, histoplasmosis, other deep fungal infections

CLINICAL FEATURES

Mimic carcinomas and traumatic ulcers
Nonhealing, persistent, often multiple

DIAGNOSIS

Biopsy necessary
Culture may be required

TREATMENT

Appropriate antimicrobial agent

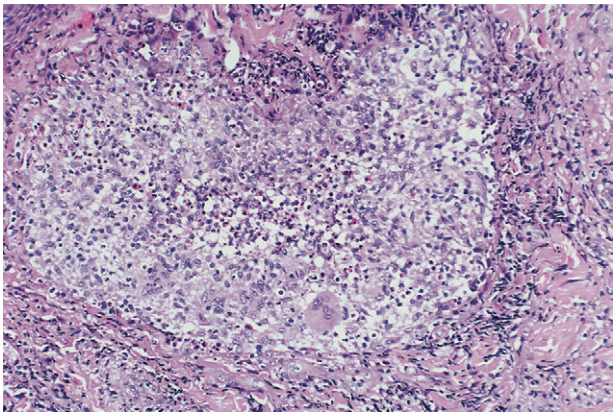

■ **FIGURE 2-25** Blastomycosis showing granuloma (macrophages) with a central abscess.

Clinical Features. Initial signs and symptoms of deep fungal infection are usually related to lung involvement and include cough, fever, night sweats, weight loss, chest pain, and hemoptysis. A skin eruption resembling erythema multiforme occasionally appears concomitantly with coccidioidomycosis infection (Box 2-6; Figure 2-23).

Oral lesions are usually preceded by pulmonary infection. Primary involvement of oral mucous membranes is a highly unlikely route of infection. Swallowed infected sputum may cause oral or gastrointestinal lesions. Also, erosion into pulmonary blood vessels by the inflammatory process may result in hematogenous spread to almost any organ. The usual oral lesion is ulcerative. Whether single or multiple, lesions are nonhealing, indurated, and frequently painful. Purulence may be an additional feature of blastomycotic lesions.

Histopathology. The basic inflammatory response in a deep fungal infection is granulomatous. In the presence of these microorganisms, macrophages and multinucleated giant cells dominate the histologic picture (Figures 2-24 and 2-25). Purulence may be a feature of blastomycosis and, less likely, of coccidioidomycosis and cryptococcosis. Peculiar to blastomycosis is pseudoepitheliomatous hyperplasia, associated with superficial infection in which ulceration has not yet occurred.

Differential Diagnosis. Clinically, the chronic, nonhealing oral ulcers caused by deep fungal infection may resemble those of oral squamous cell carcinoma, chronic trauma, oral TB, and primary syphilis. Blastomycosis may produce a clinical picture that simulates cervicofacial actinomycosis. Culture of organisms from lesions or microscopic identification of organisms in biopsy tissue is required to establish a definitive diagnosis.

Treatment. Treatment of deep mycotic infection generally consists of antimicrobials such as ketoconazole, fluconazole, and amphotericin B. Both ketoconazole and fluconazole can be administered orally. Amphotericin B is highly toxic, particularly to the kidneys, and side effects are relatively common. In immunocompromised transplant recipients or in debilitated patients, more aggressive medical management with newer agents such as echinocandins, posaconazole, and

voriconazole may be necessary. Surgical resection or incision and drainage may be used occasionally to enhance drug effects in treating some necrotic lung infections.

Subcutaneous Fungal Infection: Sporotrichosis

Etiology and Pathogenesis. Some fungal infections affect primarily subcutaneous tissues. One of these, sporotrichosis, is significant because it is a widely distributed worldwide infection that may have oral manifestations. It is caused by *Sporothrix schenckii* and results from inoculation of the skin or mucosa by contaminated soil or thorny plants. After an incubation period of several weeks, subcutaneous nodules, which frequently become ulcerated, develop. Systemic involvement is rare but may occur in individuals with defective or suppressed immune responses.

Clinical Features. Lesions appear at the site of inoculation and spread along lymphatic channels. On the skin, red nodules appear, with subsequent breakdown, exudate production, and ulceration. Orally, lesions typically present as nonspecific chronic ulcers. Lymphadenopathy may also be present.

Histopathology. The inflammatory response to *S. schenckii* is granulomatous. Central abscesses may be found in some of the granulomas, and overlying epithelium may exhibit pseudoepitheliomatous hyperplasia. The relatively small, round to oval fungus may be seen in tissue sections.

Diagnosis. Definitive diagnosis is based on culture of infected tissue on Sabouraud agar. Special silver stains may also be used to identify the organism in tissue biopsy specimens.

Treatment. Sporotrichosis usually is treated with a solution of potassium iodide and, less commonly, with systemic antifungal agents. In cases of toxicity or allergy to iodides, ketoconazole has been used with limited success. Generally, patients respond well to treatment, with little morbidity.

Opportunistic Fungal Infections: Phycomycosis (Mucormycosis) and Aspergillosis

Etiology and Pathogenesis. *Phycomycosis,* also known as *mucormycosis,* is a generic term that includes fungal infections caused by the genera *Mucor* and *Rhizopus,* and occasionally others. Organisms in this family of fungi, which normally are found in bread mold or decaying fruits and vegetables, are opportunistic, infecting humans when systemic health is compromised. *Aspergillus* is ubiquitous in the environment. Infection typically occurs in patients with poorly controlled ketoacidotic diabetes, immunosuppressed transplant recipients, patients with advanced malignancies, patients being treated with steroids or radiation, and those who are immunosuppressed for any other reason, including HIV infection and AIDS.

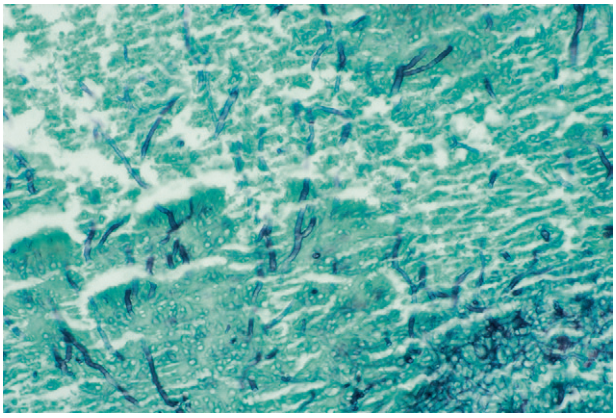

■ **FIGURE 2-26** Silver stain of *Aspergillus* in a tissue section with green counterstain.

The route of infection passes through the gastrointestinal tract or the respiratory tract, and infection may occur anywhere along these routes.

Clinical Features. In the head and neck, lesions are most likely to occur in the nasal cavity, paranasal sinuses, and possibly the oropharynx. Pain and swelling precede ulceration. Tissue necrosis may result in perforation of the palate. Extension into the orbit or brain is a common complication. The fungus has a propensity for arterial wall invasion, which may lead to hematogenous spread, thrombosis, or infarction. Rarely, a periodontal presentation may be noted, usually in association with a medical compromise.

Histopathology. Microscopically, an acute and chronic inflammatory infiltrate is seen in response to the fungus (Figure 2-26). The organism is usually readily identified in hematoxylin and eosin (H&E)-stained sections in areas of tissue necrosis. Characteristic necrotic vessel walls containing thrombi and fungi may be evident. Microscopically, the fungus consists of large, pale-staining, nonseptate hyphae that tend to branch at right angles. Mucormycosis is characterized by the presence of wide, flat non-septate fungal organisms.

Differential Diagnosis. It is important for clinicians to recognize that phycomycosis represents one of several opportunistic infections that may affect an immunocompromised host. Necrotic lesions of the nasal and paranasal sinuses should raise suspicion of this type of infection. Confirmation must be made by identification of the fungus in biopsy tissue, exudate, or culture. Because of the severity of the underlying disease and the often rapid course that this infection may take, diagnosis of phycomycosis may not be made until after death.

Perforating palatal lesions generally are rare but may be seen in association with other diseases such as gummatous

necrosis of tertiary syphilis, midline granuloma (T-cell lymphoma), and Wegener's granulomatosis. Rarely, malignancies of nasal and sinus origin (squamous cell carcinoma and salivary gland adenocarcinoma) may present through the palate. A biopsy is required to differentiate these lesions.

Treatment. Lipid-based formulations of amphotericin B are the drugs of choice for the treatment of phycomycosis and aspergillosis. Surgical debridement of upper respiratory tract lesions is often required. The prognosis is generally dependent on the severity of underlying disease and the institution of appropriate therapy. In selected patients, adjunctive treatment with hyperbaric oxygen, recombinant cytokines, and/or granulocyte transfusions may be considered. Death is a relatively frequent consequence of this infection. Generally, lung infections are more likely to be lethal than upper respiratory tract infections.

IMMUNOLOGIC DISEASES

Aphthous Ulcers

Of all the types of nontraumatic ulceration that affect oral mucosa, aphthous ulcers (canker sores) are probably the most common. The incidence ranges from 20% to 60%, depending on the population studied. Prevalence tends to be higher in professional persons, in those in upper socioeconomic groups, and in those who do not smoke.

Etiology. Although the cause of aphthous ulcerations is unknown, several possibilities have been postulated (Box 2-7).

There is considerable evidence that aphthous ulcers are related to a focal immune dysfunction in which T lymphocytes have a significant role. The nature of the initiating stimulus remains a mystery. The causative agent could be endogenous (autoimmune) antigen or exogenous (hyperimmune) antigen, or it could be a nonspecific factor, such as trauma in which chemical mediators may be involved. Neurogenic inflammation could result from an initiating stimulus. Focal release of a neuropeptide, such as substance P, could mediate lymphocytic infiltration and epithelial necrosis, generating an aphthous ulcer. Focal release of cytokines may affect delayed healing, which typifies the clinical course of these lesions.

BOX 2-7 APHTHOUS ULCERS: POSSIBLE CAUSES

Immunologic disorder: T cell mediated
Neurogenic inflammation: neuropeptide (e.g., substance P) induced
Mucosal healing defect: inhibition by cytokines
Microbiological: viral, bacterial
Nutritional deficiency: vitamin B_{12}, folic acid, iron
Chemical: preservatives, toothpaste components

TABLE 2-2 APHTHOUS ULCERS VS. SECONDARY HERPES SIMPLE INFECTION

	Aphthous Ulcers	Herpes Infection
Cause	Immune dysfunction	HSV1
Triggers	Stress, trauma, diet, hormones, depressed immunity	Stress, trauma, ultraviolet light, depressed immunity
Prodrome	Little prodrome	Prodromal symptoms
Appearance	Nonspecific microscopy	Viral cytopathic changes
	No vesicles	Vesicles precede ulcers
	Single, oval ulcer	Multiple, confluent ulcers
Sites	Nonkeratinized mucosa	Keratinized mucosa
Treatment	Corticosteroids, tetracycline	Antiviral treatment

HSV1, Herpes simplex virus type 1.

Because of the clinical similarity of oral aphthous ulcers to secondary herpes simplex virus (HSV) infection (Table 2-2), a viral cause has been investigated extensively, but this has not been substantiated. Hypersensitivity to bacterial antigens of *Streptococcus sanguis* has been suggested, but this theory has not been proven, although cross reactivity associated with microbial antigens and similarly structured oral epithelial peptides may be possible.

Deficiencies of vitamin B_{12}, folic acid, and iron as measured in serum have been found in only a small percentage of patients with aphthous ulcers. Correction of these deficiencies has produced improvement or cure in this small group. Patients with malabsorption conditions such as *celiac disease* (*gluten-sensitive enteropathy* or *nontropical sprue)* and *Crohn's disease* have been reported as having occasional aphthous-type ulcers, with the latter disease possibly related to an autoinflammatory process. In such cases, deficiencies of folic acid and factors related to underlying disease may be part of the cause.

Other causes of aphthous ulcers that have been investigated include hormonal alterations, stress, trauma, and food allergies to substances in nuts, chocolate, and gluten. Additionally, outbreaks have been stated to result from exposure to certain preservatives and toothpaste components. None of these is seriously regarded as being important in the primary causation of aphthous ulcers, although any of them may have a modifying or triggering role. Although HIV-positive patients may have more severe and protracted aphthous-like ulcers, the possible etiologic role of HIV and other agents is unknown.

Family history represents a risk factor. Over 40% of affected patients have a first-degree relative who is also

TABLE 2-3 APHTHOUS ULCERS: CLINICAL FEATURES

	Minor Aphthae	Major Aphthae	Herpetiform Aphthae
Size	<0.5 cm	>0.5 cm	<0.5 cm
Shape	Oval	Ragged oval, crateriform	Oval
Number	1-5	1-10	10-100
Location	Nonkeratinized mucosa	Nonkeratinized mucosa	Any intraoral site
Treatment	Topical corticosteroids, tetracycline mouth rinse	Topical/systemic/intralesional corticosteroids, immunosuppressives	Topical/systemic corticosteroids, tetracycline mouth rinse

affected by aphthous ulcers. A 90% degree of risk is present when both parents are affected. The role of HLA-B51 antigen may be an important factor in aphthous ulcer susceptibility.

Clinical Features. Three forms of aphthous ulcers have been recognized: minor, major, and herpetiform aphthous ulcers (Table 2-3). All are believed to be part of the same disease spectrum, and all are believed to have a common etiology. Differences are essentially clinical and correspond to the degree of severity. All forms present as painful recurrent ulcers. Patients occasionally have prodromal symptoms of tingling or burning before the appearance of lesions. The ulcers are not preceded by vesicles and characteristically appear on the vestibular and buccal mucosa, tongue, soft palate, fauces, and floor of mouth. Only rarely do these lesions occur on the attached gingiva and hard palate, thus providing an important clinical sign for the separation of aphthous ulcers from secondary herpetic ulcers. In patients with AIDS, however, aphthous-like ulcers may occur at any mucosal site.

Minor Aphthous Ulcers. Minor aphthous ulcers are the most commonly encountered form. This type usually appears as a single, painful, oval ulcer that is less than 0.5 cm in diameter, covered by a yellow fibrinous membrane and surrounded by an erythematous halo (Figures 2-27 and 2-28). Multiple oral aphthae may be seen. When the lateral or ventral surfaces of the tongue are affected, pain tends to be out of proportion to the size of the lesion (Figure 2-29). Minor aphthous ulcers generally last 7 to 10 days and heal without scar formation. Recurrences vary from one individual to another. Periods of freedom from disease may range from a matter of weeks to as long as years.

In some patients with recalcitrant aphthae, a diagnosis of Crohn's disease may be considered. This granulomatous disease may affect the gastrointestinal tract from mouth to anus. Oral manifestations include mucosal fissures and small, multiple, hyperplastic nodules on the buccal mucosa, producing a cobblestone appearance (Figures 2-30 and 2-31). Biopsy findings of these mucosal nodules show small, noncaseating granulomas characteristic of Crohn's disease. HIV-positive patients may develop minor aphthous ulcers, although proportionately more have major or herpetiform lesions. Aphthous-like ulcerations may be seen as an initial manifestation of the periodic fever syndromes; rare noninfectious disorders are related to genetic disturbances in the mechanisms/proteins that control inflammation.



■ **FIGURE 2-27** Minor aphthous ulcers.



■ **FIGURE 2-28** Minor aphthous ulcer of the floor of mouth.

Major Aphthous Ulcers. Major aphthous ulcers were previously thought to be a separate entity, and this form was referred to as *periadenitis mucosa necrotica recurrens* or *Sutton's disease.* It is now regarded as the most severe expression of aphthous stomatitis. Lesions are larger (>0.5 cm) and more painful and persist longer than minor aphthae (Figure

2-32). Because of the depth of inflammation, major aphthous ulcers appear crateriform clinically and heal with scar formation. Lesions may take as long as 6 weeks to heal, and as soon as one ulcer disappears, another one starts. In patients who experience an unremitting course with significant pain and discomfort, systemic health may be compromised because of difficulty in eating and psychological stress. The predilection for movable oral mucosa is as typical for major aphthous ulcers as it is for minor aphthae. HIV-positive patients may have aphthous lesions at any intraoral site.

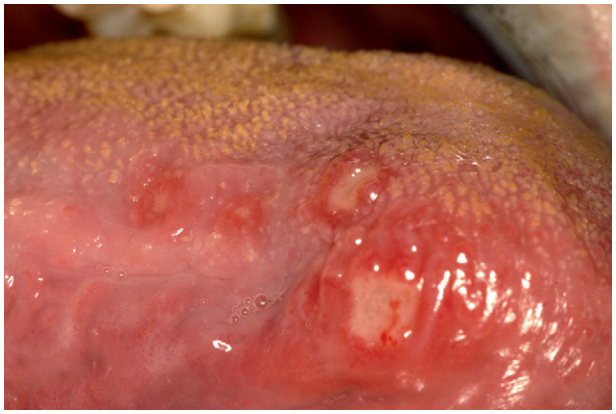

■ **FIGURE 2-29** Minor aphthous ulcers of the lateral tongue.

Herpetiform Aphthous Ulcers. Herpetiform aphthous ulcers present clinically as recurrent crops of small ulcers (Figures 2-33 and 2-34). Although movable mucosa is predominantly affected, palatal and gingival mucosa may also be involved. Pain may be considerable, and healing generally occurs in 1 to 2 weeks. Unlike herpes infection, herpetiform aphthous ulcers are not preceded by vesicles and exhibit no virus-infected cells. Other than the clinical feature of crops of oral ulcers, no finding can link this disease to a viral infection.

Histopathology. Because the diagnosis of these ulcers is usually evident clinically, biopsies usually are unnecessary and therefore are rarely performed. Aphthous ulcers have nonspecific microscopic findings, and no histologic features

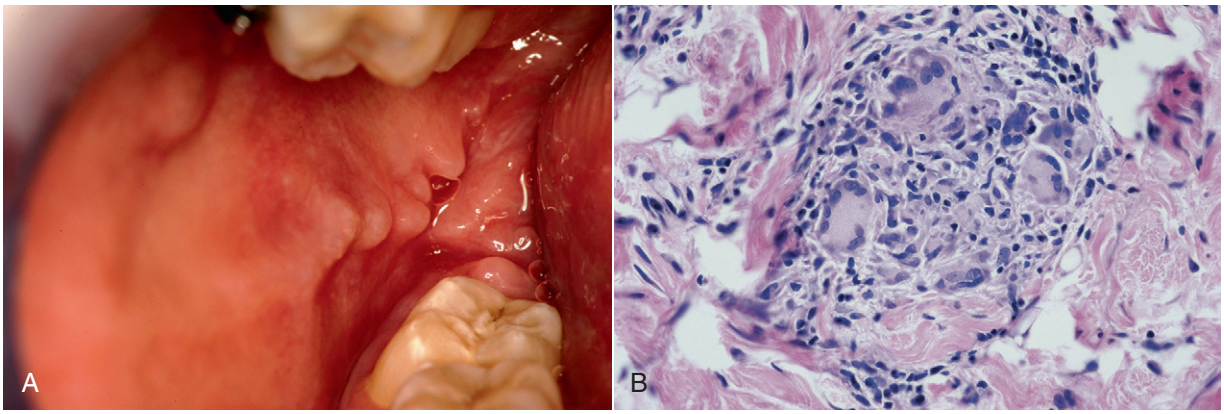

■ **FIGURE 2-30 A,** Nodules and ulcers of Crohn's disease. **B,** Subepithelial granuloma with multinucleated giant cells.

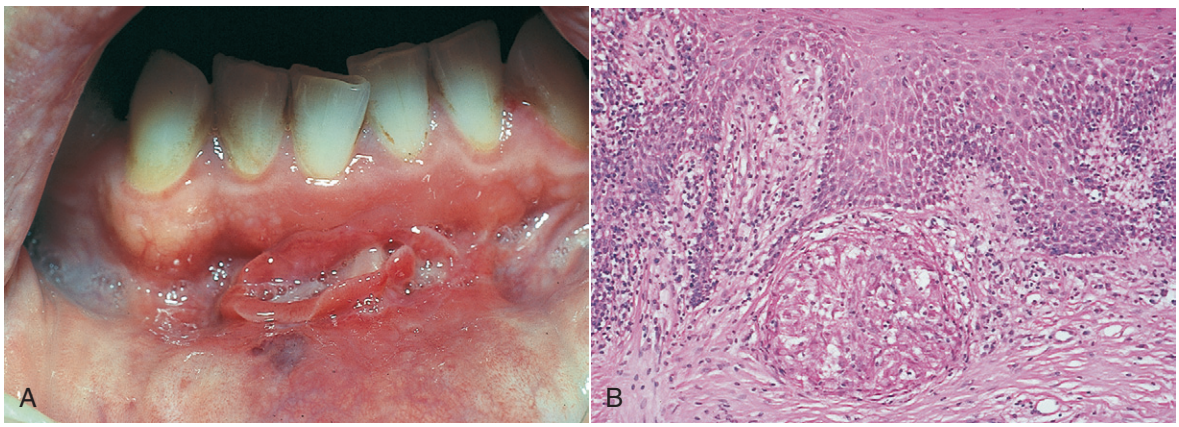

■ **FIGURE 2-31 A,** Crohn's-associated fissures in the labial vestibule. **B,** Biopsy specimen showing a granuloma. (From Regezi JA, Sciubba JJ, Pogrel MA: Atlas of Oral and Maxillofacial Pathology. Philadelphia, 2000, WB Saunders, Figs. 1-63 and 1-64.)

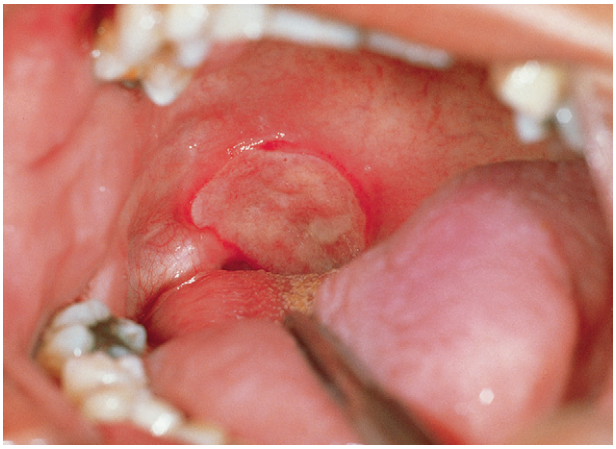

■ **FIGURE 2-32** Major aphthous ulcer.



■ **FIGURE 2-33 Herpetiform aphthous ulcers.** The patient also had numerous lesions of the lip and buccal mucosa.

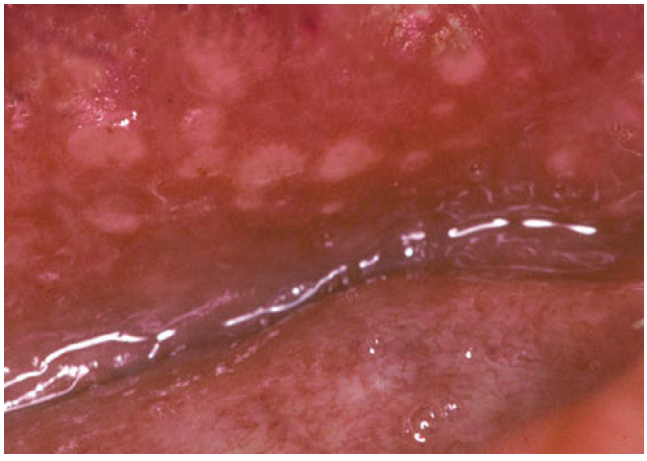

■ **FIGURE 2-34** Herpetiform aphthae of the tongue.

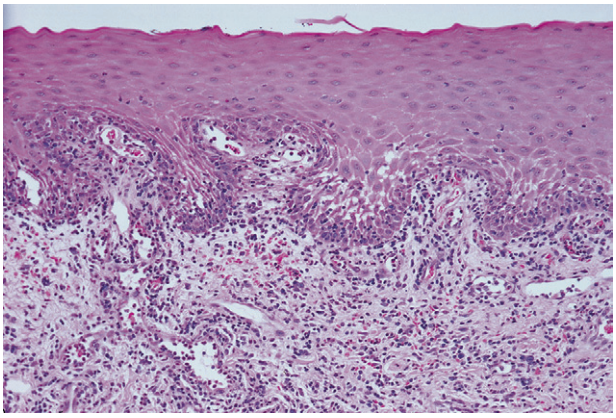

■ **FIGURE 2-35 Preaphthous ulceration.** Intense lymphocytic infiltrate and basilar epithelial edema seen in preulcerative stage of an aphthous lesion.

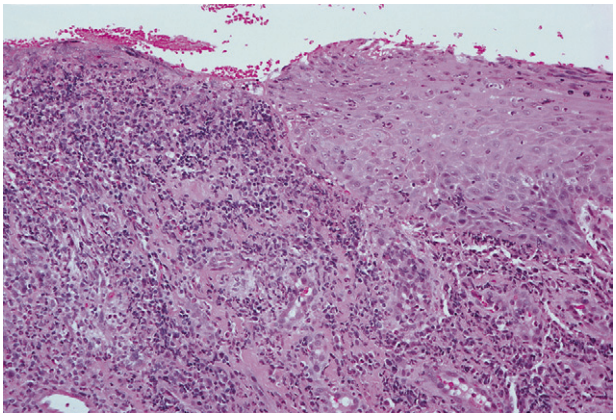

■ **FIGURE 2-36** Aphthous ulcer showing nonspecific changes.

are diagnostic (Figures 2-35 and 2-36). At no time are virus-infected cells evident. Essentially, the same microscopic changes are found in all forms of aphthous ulcers. Studies have shown that mononuclear cells are found in submucosa and perivascular tissues in the preulcerative stage. These cells are predominantly CD4 lymphocytes, which soon are outnumbered by CD8 lymphocytes as the ulcerative stage develops. Macrophages and mast cells are common inhabitants of the ulcer.

Differential Diagnosis. Diagnosis of aphthous ulcers is generally based on the history and clinical appearance (see Table 2-3). Lesions of secondary (recurrent) oral herpes are often confused with, but usually can be distinguished from, aphthous ulcers. A history of vesicles preceding ulcers, location on the attached gingiva and hard palate, and crops of lesions indicate herpetic rather than aphthous ulcers. Other painful oral ulcerative conditions that may simulate the various forms of aphthous ulcers include trauma, pemphigus vulgaris, mucous membrane pemphigoid, and neutropenia.

Treatment. In patients with occasional or few minor aphthous ulcers, usually no treatment is needed apart from a bland mouth rinse such as sodium bicarbonate in warm water to keep the mouth clean. However, when patients are more severely affected, some forms of treatment can provide significant control (but not necessarily a cure) of this disease.

Rational treatment would include drugs that can manipulate or regulate immune responses. In this category, corticosteroids currently offer the best chance for disease containment. In severely affected patients, systemic steroids may be used for immediate control. A low to moderate dose of prednisone for a short period is effective. A typical regimen might be 20 to 40 mg daily for 1 week, followed by another week at half the initial dose. However, for patients with mild to moderate disease, only topical therapy appears justified. Topical steroids, if used judiciously, can be relatively efficacious and safe (see section on treatment of pemphigus vulgaris for corticosteroid effects and side effects). Although nearly all topical compounds have been developed for use on the skin, it has been standard practice to prescribe these agents for use on mucous membranes (Box 2-8). Intralesional injection of triamcinolone may be used for individual or focal problematic lesions. In cases where repeated ulcerative episodes occur and use of systemic steroids is not possible and topical agents are not effective, systemic montelukast (a leukotriene receptor antagonist) administration may be useful.

Antibiotics. Antibiotics have been used in the treatment of aphthous ulcers with fair to good results. Tetracycline and tetracycline congener suspensions, used topically, often produce excellent results. In addition to their antibacterial effect of keeping the mouth clean, tetracyclines speed resolution of the ulcers through local inhibition of matrix metalloproteinases (MMPs). Because tetracyclines readily break down in solution, they must be used within a very short time span. A typical regimen for treating aphthous ulcers consists of emptying a 250-mg capsule of tetracycline into 30 mL (1 fluid ounce) of warm water and then rinsing the mouth for several minutes. This is repeated up to 4 times a day for 4 days. Results are best if this mouth rinse is used on the first day that the ulcers appear, or when they are in a prodromal stage.

Other Drugs. Because of their rather profound side effects, immunosuppressive drugs, such as azathioprine and cyclophosphamide, are generally justified only for the treatment of severely affected patients (to permit reduced prednisone dosages). Recent studies indicate that thalidomide may provide relief to severely affected patients, especially AIDS patients. Two other drugs that have shown some therapeutic efficacy are pentoxifylline and colchicine.

BOX 2-8 TOPICAL CORTICOSTEROID PREPARATIONS*

Clobetasol propionate (Temovate)
Clobetasol propionate plus "oral adhesive" (50% Temovate ointment plus 50% Orabase)
Betamethasone dipropionate (Diprosone)
Fluocinonide (Lidex)
Betamethasone plus clotrimazole (Lotrisone)

*Listed from high potency to intermediate potency.

Chronic Ulcerative Stomatitis

This is a debilitating rare mucocutaneous disorder that produces desquamation and ulceration of the oral mucosa. Clinically, it may resemble several other mucocutaneous conditions, including hypersensitivity reaction, lichen planus, mucous membrane pemphigoid, linear immunoglobulin (Ig) A disease and pemphigus vulgaris. The condition most commonly presents in older white women, typically on the tongue, buccal mucosa, or gingiva. Biopsy findings on H&E-stained sections can be nonspecific or may resemble lichen planus. Direct immunofluorescence examination shows perinuclear deposits of IgG in the basal and lower one-third epithelial layers (Figure 2-37), but with an absence of staining for other immunoglobulin types or fibrinogen. Tissue and circulating autoantibodies to the ΔNp63α protein have been associated with chronic ulcerative stomatitis, but their role in its etiology and pathogenesis remains unproven. In contrast to other immune-mediated mucocutaneous diseases, chronic ulcerative stomatitis has been reported to respond less well to corticosteroids but shows a good response to hydroxychloroquine. This condition has no relationship to

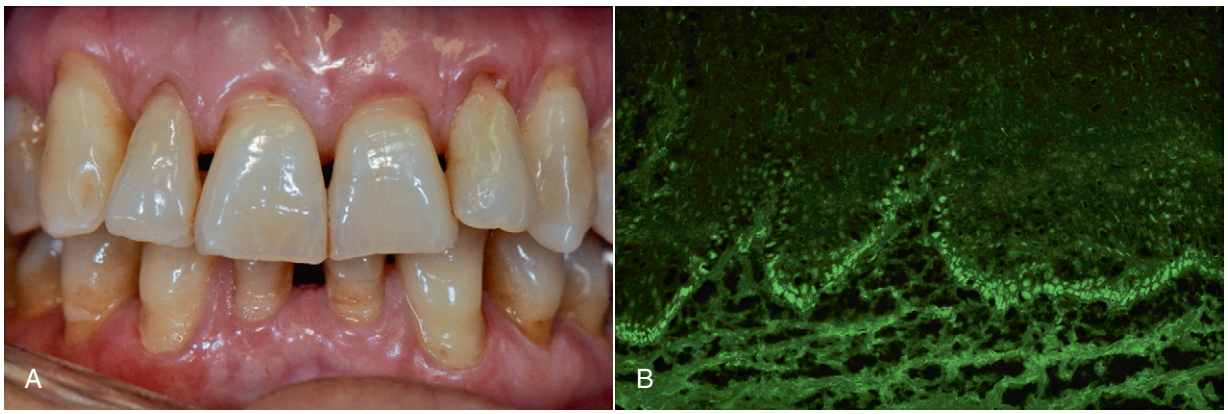

■ **FIGURE 2-37** Chronic ulcerative stomatitis. (Courtesy Dr. Troy E. Daniels.)

BOX 2-9 BEHÇET'S SYNDROME

ETIOLOGY
Immunodysfunction, vasculitis

ORGANS AFFECTED
Nonkeratinized oral mucosa (minor aphthae)
Genitals (ulcers)
Eyes (conjunctivitis, uveitis, retinitis)
Joints (arthritis)
Central nervous system (headache, nerve palsies, inflammation)

TREATMENT
Corticosteroids, other immunosuppressives

gastrointestinal or other autoimmune diseases, nor have systemic manifestations or malignant transformation been noted.

Behçet's Syndrome

Behçet's syndrome is a rare multisystem inflammatory disease (gastrointestinal, cardiovascular, ocular, CNS, articular, pulmonary, dermal) in which recurrent oral aphthae are a consistent feature. Although the oral manifestations are usually relatively minor, involvement of other sites, especially the eyes and CNS, can be serious.

Etiology. The cause of this noninfectious condition in which vasculitis is a primary feature is poorly understood, although it seems to be related to an immune dysfunction or to an abnormality within the innate immune system. Behçet's syndrome may have a genetic predisposition as well and a geographic prevalence (especially Turkey and other Eastern Mediterranean areas), particularly in reference to the frequent presence of human leukocyte antigen HLA-B51.

Clinical Features. Lesions of Behçet's syndrome typically affect the oral cavity (100% incidence), the genitalia (62% of cases), and the eyes (Box 2-9; Figures 2-38 and 2-39). Other regions or systems are less commonly involved. Recurrent arthritis of the wrists, ankles, and knees may be associated. Cardiovascular manifestations are believed to result from vasculitis and thrombosis. CNS manifestations are frequently seen in the form of headaches, although infarcts have been reported. Pustular erythema nodosum–like skin lesions have been described. Relapsing polychondritis (e.g., auricular cartilage, nasal cartilage) in association with Behçet's stigmata has been designated as the MAGIC syndrome (mouth and genital ulcers with inflamed cartilage).

Oral manifestations of this syndrome appear identical to the ulcers of aphthous stomatitis. The ulcers are usually the minor aphthous form and are found in the typical aphthous distribution.

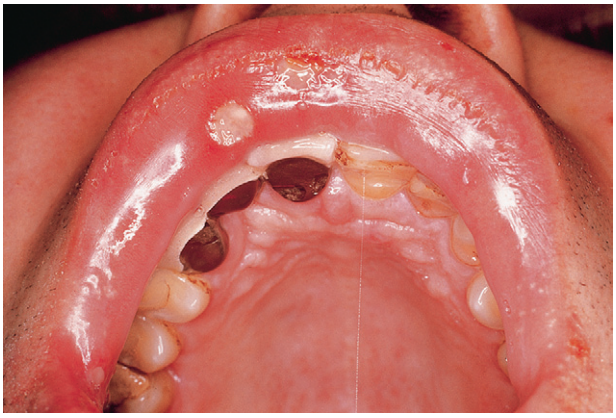

■ **FIGURE 2-38** Behçet's syndrome, oral component (aphthous ulcer).

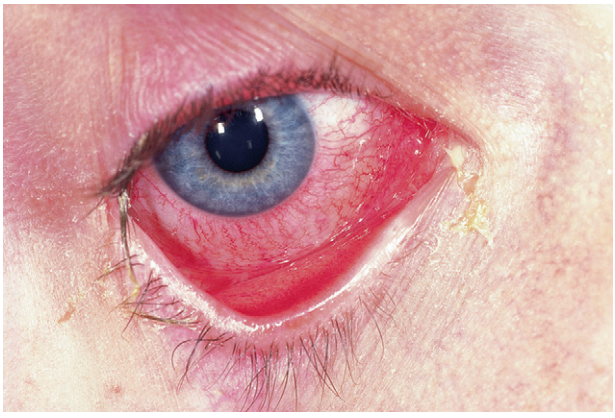

■ **FIGURE 2-39** Behçet's syndrome conjunctivitis.

Ocular changes are noted in most patients with Behçet's syndrome. Uveitis, conjunctivitis, and retinitis are among the more common inflammatory processes.

Genital lesions are ulcerative in nature and may cause significant pain and discomfort. Painful ulcerative lesions may occur around the anus. Inflammatory bowel disease and neurologic problems have been described in some patients.

Histopathology. T lymphocytes are prominent in the ulcerative lesions of Behçet's syndrome. However, neutrophilic infiltrates in which the cells appear within vessel walls (vasculitis) have been described. Immunopathologic support of a vascular target in this condition comes from the demonstration of immunoglobulins and complement within the vessel walls.

Diagnosis. The diagnosis of Behçet's syndrome is based on clinical signs and symptoms associated with the various regions affected. No specific findings are noted in biopsy tissue, and no supportive laboratory tests are available.

Treatment. No standard therapy is known for Behçet's syndrome. Systemic steroids are often prescribed, and

immunosuppressive drugs, such as chlorambucil and azathioprine, may be used instead of or in addition to steroids. Dapsone, cyclosporine, thalidomide, interferon, and biological anti–tumor necrosis factor (TNF) agents may play a role in the treatment of these patients, depending on the degree of disease severity.

Reiter's Syndrome

Etiology. Classically, Reiter's syndrome is a clinical tetrad of nonspecific urethritis, conjunctivitis, mucocutaneous lesions, and arthritis that follows bacterial dysentery (*Shigella, Yersinia, Salmonella, Clostridium,* and *Campylobacter* organisms) or exposure to a sexually transmissible disease, in particular, *Chlamydia trachomatis.* An abnormal immune response to microbial antigen(s) is now regarded as a likely mechanism for the multiple manifestations of this syndrome. A male with HLA-B27 has a 20% risk for Reiter's disease after an episode of *Shigella* dysentery.

Clinical Features. The onset of Reiter's syndrome is acute, with the simultaneous appearance of urethritis, conjunctivitis, and oligoarthritis affecting large and small joints of the lower limbs. This usually occurs 1 to 3 weeks after a sexual episode or following an attack of dysentery. Other features include fever, weight loss, vasomotor abnormalities in the feet, and skin lesions consisting of faint macules, vesicles, and pustules on the hands and feet. Bilateral conjunctivitis occurs and, in 10% of cases, acute iritis is seen. The arthritis is self-limiting, and remission occurs in 2 to 3 months.

Oral lesions have been described in up to 17% of cases as relatively painless aphthous-type ulcers occurring almost anywhere in the mouth. Tongue lesions resemble geographic tongue.

Highly characteristic of this syndrome is its occurrence predominantly in white men in their third decade. The duration of the disease varies from weeks to months, and recurrences are not uncommon.

Diagnosis. Diagnosis is dependent on recognition of the various signs and symptoms associated with this syndrome. The erythrocyte sedimentation rate (ESR) is elevated in the acute phase of the disease but persists after arthritis resolves. By tissue typing, more than 70% of patients will have the HLA-B27 genotype.

Treatment. Nonsteroidal anti-inflammatory agents are generally used in the treatment of this disease. Antibiotics have been added to the treatment regimen, with varied success. Systemic corticosteroids are rarely required.

Erythema Multiforme

Erythema multiforme (EM) is an acute self-limiting hypersensitivity reaction characterized by target skin lesions and/or ulcerative oral lesions. It has been divided into two subtypes: a minor form, usually associated with an HSV trigger, and a major severe form, triggered by certain systemic drugs.

Etiology and Pathogenesis. The basic cause of EM is unknown, although a hypersensitivity reaction is suspected. Some evidence suggests that the disease mechanism may be related to antigen-antibody complexes that are targeted for small vessels in the skin or mucosa. In about half of cases, precipitating or triggering factors can be identified. These generally fall into the two large categories of infections and drugs. Other factors, such as malignancy, vaccination, autoimmune disease, and radiotherapy, are occasionally cited as possible triggers. Infections frequently reported include HSV infection (due to HSV types 1 and 2), TB, and histoplasmosis. In cases of recurrent idiopathic forms of this disease, HSV DNA can be detected by use of polymerase chain reaction (PCR) analysis in 50% of cases. Various types of drugs have precipitated EM, with barbiturates, sulfonamides, and some antiseizure medications such as carbamazepine and phenytoin being among the more frequent offenders. Although these drugs are pharmacologically unrelated, the mechanism by which EM is precipitated is related to similar protein folds that expose regions that are antigenically similar.

Clinical Features. EM is usually an acute, self-limited process that affects the skin or mucous membranes or both (Box 2-10). Between 25% and 50% of patients with cutaneous EM have oral manifestations of this disease (Figures 2-40 and 2-41). It may on occasion be chronic, or it may be a recurring acute problem. In recurrent disease, prodromal symptoms may be experienced before any eruption. Young adults are most commonly affected. Individuals often develop EM in the spring or fall and may have such recrudescences chronically. The term *erythema multiforme* was coined to indicate the multiple and varied clinical appearances that are associated with cutaneous manifestations of this disease. The

BOX 2-10 ERYTHEMA MULTIFORME

ETIOLOGY

Minor (less severe) form usually triggered by herpes simplex virus

Major form (Stevens-Johnson syndrome) often triggered by drugs

Hypersensitivity reaction to infectious agents, drugs, or idiopathic

CLINICAL FEATURES

Multiple oral ulcers and/or target skin lesions

Self-limiting, but may recur

TREATMENT

Supportive therapy

Corticosteroids occasionally used for severe form

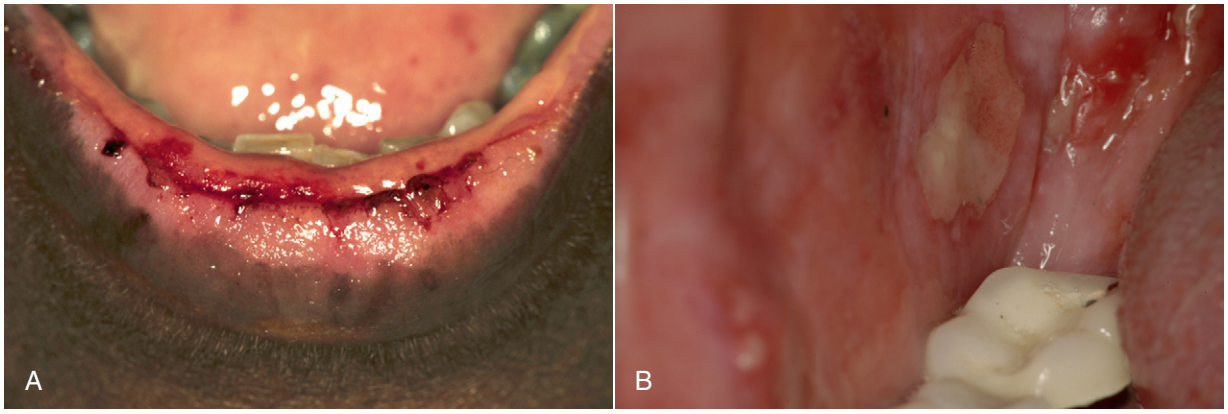

■ **FIGURE 2-40 A** and **B,** Erythema multiforme ulcers.



■ **FIGURE 2-41 A** and **B,** Erythema multiforme ulcers.



■ **FIGURE 2-42** Erythema multiforme cutaneous target lesions.

classic skin lesion of EM is the target or iris lesion. It consists of concentric erythematous rings separated by rings of near-normal color. Typically, the extremities are involved, usually in a symmetric distribution (Figure 2-42). Other types of skin manifestations of EM include macules, papules, vesicles, bullae, and urticarial plaques.

Orally, EM characteristically presents as an ulcerative disease, varying from a few aphthous-type lesions to multiple superficial, widespread ulcers in EM major. Short-lived vesicles or bullae are infrequently seen at initial presentation. Any area of the mouth may be involved, with the lips, buccal mucosa, palate, and tongue being most frequently affected. Recurrent oral lesions may appear as multiple painful ulcers similar to those of the initial episode or as less symptomatic erythematous patches with limited ulceration.

Symptoms range from mild discomfort to severe pain. Considerable apprehension may be associated with this condition initially because of occasional explosive onset in some patients. Systemic signs and symptoms of headache, slightly elevated temperature, and lymphadenopathy may accompany more intense disease.

At the severe end of the EM spectrum (EM major), intense involvement of the mouth, eyes (Figure 2-43), skin, genitalia, and occasionally the esophagus and respiratory tract may be seen concurrently. This form of EM major, sometimes called *Stevens-Johnson syndrome,* has a strong relationship to medications, in particular analgesics, where oxicams or propionic acid derivatives have been used.

Characteristically, the lips show crusting ulceration at the vermilion border that may cause exquisite pain. Superficial ulceration, often preceded by bullae, is common to all sites affected. Ocular inflammation (conjunctivitis and uveitis) may lead to scarring and blindness.

Histopathology. The microscopic pattern of EM consists of epithelial hyperplasia and spongiosis (Figure 2-44). Basal and parabasal apoptotic keratinocytes are usually seen. Vesicles occur at the epithelium–connective tissue interface, although intraepithelial vesiculation may be seen. Epithelial necrosis is a frequent finding. Connective tissue changes usually appear as infiltrates of lymphocytes and macrophages in perivascular spaces and in connective tissue papillae.

Immunopathologic studies are nonspecific for EM. The epithelium shows negative staining for immunoglobulins. Vessels have been shown, however, to have IgM, complement, and fibrin deposits in their walls. This latter finding has been used to support an immune complex vasculitis cause for EM. Autoantibodies to desmoplakins 1 and 2 have been identified in a subset of EM major–affected patients, suggesting that both cell-mediated and humoral immune systems may contribute to the pathogenesis of EM.

Differential Diagnosis. When target, or iris, skin lesions are present, clinical diagnosis is usually straightforward. However, in the absence of these or any skin lesions, several possibilities should be considered for oral expression of this disease, including primary HSV infections (Table 2-4), aphthous ulcers, pemphigus vulgaris, mucous membrane pemphigoid, and erosive lichen planus. The general lack of systemic symptoms; the favored oral location of the lips, buccal mucosa, tongue, and palate (rarely gingiva); the larger ulcers (usually not preceded by blisters); the presence of target skin lesions; and a history of recent drug ingestion or infection should favor a diagnosis of EM.



■ **FIGURE 2-43** Ocular lesions in patient with erythema multiforme major. (Reproduced with permission from Regezi JA, Sciubba JJ, Pogrel MA: Atlas of Oral and Maxillofacial Pathology. Philadelphia, 2000, WB Saunders, Fig. 1-71.)

TABLE 2-4 ERYTHEMA MULTIFORME VS. PRIMARY HERPES SIMPLEX INFECTION

	Erythema Multiforme	Herpes Infection
Appearance	Large oral and lip ulcers	Small oral/perioral ulcers
	Skin target lesions	Skin ulcers
Symptoms	Mild to severe	Moderate to severe
Sites	Buccal, tongue, lips, palate, extremities	Gingiva, lips, perioral skin
Age	Young adults	Children
Cause	Hypersensitivity	HSV
Treatment	Symptomatic, steroids	Acyclovir

HSV, Herpes simplex virus.

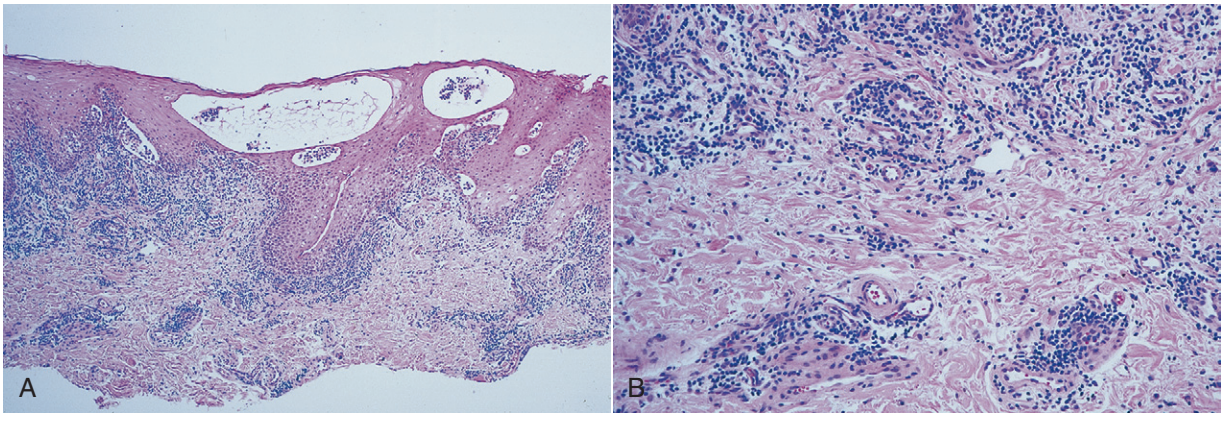

■ **FIGURE 2-44 A** and **B,** Oral erythema multiforme biopsy specimen showing epithelial edema and lymphoid infiltrate. Note perivascular distribution of lymphocytes in **B**. (Reproduced with permission from Regezi JA, Sciubba JJ, Pogrel MA: Atlas of Oral and Maxillofacial Pathology. Philadelphia, 2000, WB Saunders, Figs. 1-72 and 1-73.)

Treatment. In EM minor, symptomatic treatment, including keeping the mouth clean with bland mouth rinses, may be all that is necessary. In EM major, topical corticosteroids with antifungals may help control disease. The use of systemic corticosteroids remains controversial and is believed by some to be contraindicated, particularly as maintenance therapy. Acyclovir at 400 to 600 mg daily may be effective in preventing recurrences in patients who have an HSV-triggered disease, although the efficacy is not clear. Supportive measures, such as oral irrigation, adequate fluid intake, and use of antipyretics, may provide patients with substantial benefit.

Drug Reactions

Etiology and Pathogenesis. Although the skin is more commonly involved in adverse reactions to drugs, the oral mucosa may occasionally be the target. Virtually any drug has the potential to cause an untoward reaction, but some have a greater ability to do so than others. Also, some patients have a greater tendency than others to react to drugs. Some of the drugs that are more commonly cited as being involved in adverse reactions are listed in Box 2-11. The totality of drugs capable of or reported to be associated with oral mucosal side effects (stomatitis medicamentosa) is very extensive, with a range of manifestations including blistering, lichen planus–like (lichenoid) and lupus-like reactions, ulcerative lesions, and fixed (edema, erythema) eruptions. Careful review of a patient's drug profile in the face of oral mucosal alterations is crucial in establishing or ruling out an allergic or hypersensitivity-based etiology.

The pathogenesis of drug reactions may be related to immunologic or nonimmunologic mechanisms (Box 2-12). Immunologic mechanisms are triggered by an antigenic component (hapten) on the drug molecule, resulting in a hyperimmune response, or drug allergy. The potential for drug allergy is directly dependent on the immunogenicity of the drug, the frequency of exposure, the route of administration (topical more likely than oral), and the innate reactivity of the patient's immune system. Mechanisms involved in drug allergy include IgE-mediated reactions, cytotoxic reactions (antibody binds to a drug that is already attached to a cell surface), and circulation of antigen (drug)-antibody complexes.

Drug reactions that are nonimmunologic in nature do not stimulate an immune response and are not antibody dependent. In this type of response, drugs may directly affect mast cells, causing the release of chemical mediators. Reactions may result from overdose, toxicity, or side effects of the drugs.

Clinical Features. Cutaneous manifestations of drug reactions are widely varied. Changes may appear rapidly, as in anaphylaxis, angioedema, and urticaria, or after several days of drug use. Manifestations include urticaria, maculopapular rash, erythema, vesicles, ulcers, and target lesions (EM) (Figures 2-45 to 2-48).

BOX 2-11 ULCERATIVE AND ERYTHEMATOUS DRUG REACTIONS: REPRESENTATIVE CAUSATIVE DRUGS

ANALGESICS
Aspirin
Codeine
Oxicams
Propionic acid derivatives

ANTIBIOTICS
Erythromycin
Penicillin
Streptomycin
Sulfonamides
Tetracycline

ANTICONVULSANTS
Barbiturates
Phenytoin

ANTIFUNGALS
Ketoconazole
Anti-inflammatory
  Indomethacin
Antimalarial
Cardiovascular
Methyldopa
Oxprenolol
Psychotherapeutic
  Meprobamate
  Chlorpromazine
Other
  Retinoids
  Cimetidine
  Gold compounds
  Local anesthetics

BOX 2-12 DRUG REACTIONS: MECHANISMS

HYPERIMMUNE RESPONSE (ALLERGY)
Related to drug immunogenicity, frequency, route of delivery, patient's immune system
Mediated by:
  Mast cells coated with IgE
  Ab reaction to cell-bound drug
  Deposition of circulating Ag-Ab complexes

NONIMMUNOLOGIC RESPONSE (NOT AB DEPENDENT)
Direct release of inflammatory mediators by mast cells
Overdose, toxicity, side effects

Ab, Antibody; *Ag,* antigen; *IgE,* immunoglobulin E.



■ **FIGURE 2-45 Hypersensitivity reaction.** Cutaneous urticaria associated with hypersensitivity to metronidazole.



■ **FIGURE 2-47** Drug reaction to captopril.



■ **FIGURE 2-46** Acquired angioedema producing lip swelling.



■ **FIGURE 2-48** Lichenoid drug reaction.

Acquired angioedema is an IgE-mediated allergic reaction that is precipitated by drugs or foods such as nuts and shellfish. These substances may act as sensitizing agents (antigens) that elicit IgE production. On antigenic rechallenge, mast cells bound with IgE in the skin or mucosa release their contents to cause the clinical picture of angioedema. *Hereditary angioedema* produces similar clinical changes but through a different mechanism. Individuals who inherit this rare autosomal-dominant trait develop a spontaneous mutation, which results in a deficiency of the inhibitor of the first component of complement C1 esterase. Absent or dysfunctional C1 esterase inhibitor ultimately leads to release of vasoactive peptides and the often serious clinical manifestations that characterize this condition.

Angioedema, by an acquired or a hereditary pathway, appears as a soft, diffuse, painless swelling, usually of the lips, neck, or face. There is typically no color change. The condition generally subsides after 1 to 2 days and may recur at a later date. It is a curious note that minor trauma can also precipitate the swelling. Emergency treatment may be required if the process leads to respiratory distress because of glottic or laryngeal involvement. Antihistamines and, in problematic cases, corticosteroids are used to treat this form of allergy.

Oral manifestations of drug reactions may be erythematous, vesicular, or ulcerative. They may also mimic erosive lichen planus, in which case they are known as *lichenoid drug reactions* (Box 2-13). The widespread ulcers typical of EM are often representative of a drug reaction.

Histopathology. The microscopy of drug reactions includes such nonspecific features as spongiosis, apoptotic keratinocytes, lymphoid infiltrates, eosinophils, and ulceration. An interface pattern of mucositis (i.e., a lymphoid infiltrate focused at the epithelium–connective tissue interface) is often seen in mucosal allergic reactions. Although biopsy findings may not be diagnostic, they may be helpful in ruling out other diagnostic considerations.

Diagnosis. Because the clinical and histologic features of drug reactions are highly variable and nonspecific, the diagnosis of drug reaction requires a high index of suspicion and careful history taking. Recent use of a drug is important, although delayed reaction (up to 2 weeks) may occasionally

BOX 2-13 LICHENOID DRUG REACTIONS: DRUGS WITH CAUSATIVE POTENTIAL

Analgesic
NSAIDs
Antimicrobial
Hydroxychloroquine
Streptomycin
Tetracycline
Antidiabetic
Tolbutamide
Antihistamine
Triprolidine
Cardiovascular
Allopurinol
Enalapril
Methyldopa
Quinidine
Propranolol
Thiazides
Psychotherapeutic
Phenothiazine
Other
Gold salts
Mercury
Penicillamine

NSAIDs, Nonsteroidal anti-inflammatory drugs.

be noted (e.g., with ampicillin). Withdrawal of the suspected drug should result in improvement, and reinstitution of the drug (a procedure that is usually ill advised for the patient's safety) should exacerbate the patient's condition. If rechallenge is performed, minute amounts of the offending drug or a structurally related drug should cause a reaction.

Treatment. The most important measures in the management of drug reactions are identification and withdrawal of the causative agent. If this is impossible or undesirable, alternative drugs may have to be substituted, or the eruption may have to be dealt with on an empirical basis. Antihistamines and occasionally corticosteroids may be useful in the management of oral and cutaneous eruptions caused by drug reactions.

Contact Allergies

Etiology and Pathogenesis. Contact allergic reactions (stomatitis venenata) can be caused by antigenic stimulation by a vast array of foreign substances, including foods and flavoring agents, preservatives, oral care products, dental materials, and many other agents. The generated immune response is predominantly T cell mediated. In the sensitization phase, epithelial Langerhans cells appear to have a major role in the recognition of foreign antigen. These dendritic cells are responsible for processing antigens that enter the epithelium from the external environment. The Langerhans cells subsequently present the appropriate antigenic determinants to T lymphocytes. After antigenic rechallenge, local lymphocytes secrete chemical mediators of inflammation (cytokines) that produce the clinical and histologic changes characteristic of this process.



■ **FIGURE 2-49** Contact allergy resulting in erythematous gingiva.

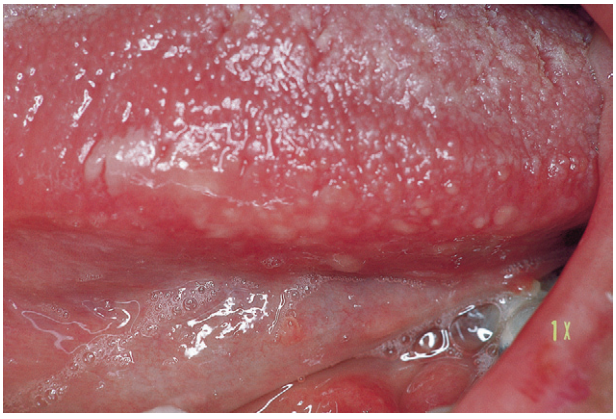

■ **FIGURE 2-50** Contact allergy resulting in erythema and ulcerations of the lateral tongue.

Clinical Features. Lesions of contact allergy occur directly adjacent to the placement or location of the causative agent. Presentation is varied and includes erythematous, erosive, vesicular, lichenoid, and ulcerative lesions (Figures 2-49 and 2-50).

Although contact allergy is frequently seen on the skin, it is relatively uncommon intraorally. Some of the many materials containing agents known to cause oral contact allergic reactions are toothpaste, mouthwash, candy, chewing gum, topical antimicrobials, topical steroids, iodine, essential oils, and denture base material. *Cinnamon* has been specifically identified as an etiologic agent in oral contact stomatitis. Lesions associated with this offender are usually white or

even lichenoid, although ulcerative and red lesions may be seen. A related lesion, plasma cell gingivitis, is another form of contact allergy to cinnamon-containing agents such as toothpastes and chewing gums. The condition primarily affects the attached gingiva as a bright red bilateral band. This lesion is discussed in Chapter 4.

Histopathology. Microscopically, the epithelium and connective tissue show inflammatory changes. Spongiosis and vesiculation may be seen within the epithelium, and perivascular lymphophagocytic infiltrate is found in the immediate supporting connective tissue. Blood vessels may be dilated, and occasionally eosinophils may be seen.

Diagnosis. Careful history taking to establish a cause-and-effect relationship is essential. Biopsy findings may be confirmatory. Patch testing of oral mucosa is difficult, and false-negative results may be problematic.

Treatment. Treatment should be directed at elimination of the offending material if it can be identified. In uncomplicated cases, lesions should heal in 1 to 2 weeks. Topical steroids may hasten the healing process.

Wegener's Granulomatosis

Etiology. Wegener's granulomatosis is an uncommon immune-based inflammatory necrotizing vasculitis whose exact cause is unknown. Efforts to identify an infectious agent have been unproductive.

Clinical Features. With an incidence of approximately 3 cases per 100,000, Wegener's granulomatosis has an equal gender distribution and a wide age range in which it occurs. White persons are affected in approximately 90% of cases.

Classically, the triad of upper respiratory tract, lung, and kidney involvement is seen in this condition. Occasionally, only two of the three sites are affected. Lesions may also present in the oral cavity and skin and potentially in any other organ system (Figures 2-51 and 2-52).

Initial presentation within the oral cavity is noted in 6% to 13% of cases in the form of painful cobblestone mucosal alterations of the palate and gingiva (hyperplastic, granular alterations) ("strawberry gingivitis"). The clinical differential diagnosis is broad and includes fungal disease, squamous cell carcinoma, lymphoma, infectious granulomatous disease, Langerhans cell disease, peripheral giant cell lesion, pyogenic granuloma, and, when involving the hard palate, necrotizing sialometaplasia. Wegener's granulomatosis is often associated with other head and neck manifestations, including parotid gland swelling, facial edema, sinusitis, rhinorrhea, nasal stuffiness, and epistaxis. In most cases, nasal or sinus (usually maxillary) ulcerations are present. Necrosis and perforation of the nasal septum or palate are occasionally seen.

Kidney involvement consists of focal necrotizing glomerulitis. Renal failure is the final outcome of kidney disease.



■ **FIGURE 2-51** Wegener's granulomatosis, gingival expression.

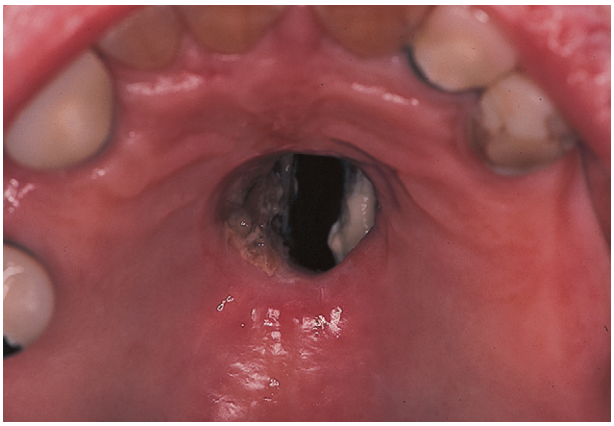

■ **FIGURE 2-52** Wegener's granulomatosis, palatal lesion. (Reproduced with permission from Regezi JA, Sciubba JJ, Pogrel MA: Atlas of Oral and Maxillofacial Pathology. Philadelphia, 2000, WB Saunders, Fig. 1-110.)

Inflammatory lung lesions, varying in intensity from slight to severe, may eventually lead to respiratory failure.

Histopathology. The basic pathologic process is granulomatous, with characteristic necrotizing vasculitis (Figure 2-53). Necrosis and multinucleated giant cells may be seen in granulomatous areas. Affected small vessels show a mononuclear infiltrate within their walls in the presence of fibrinoid necrosis. Diagnosis may be made by exclusion of other diseases, particularly midline granuloma (Table 2-5).

Diagnosis. Diagnosis is generally dependent on the finding of granulomatous inflammation and necrotizing vasculitis in biopsy tissue of upper respiratory tract lesions—evidence of involvement of lung and/or kidney lesions. Demonstration of antineutrophil cytoplasmic antibodies (cANCAs) from indirect immunofluorescence on blood adds confirmatory evidence, but negative results do not necessarily rule out the diagnosis. Antineutrophil perinuclear antibodies (pANCAs) represent antibodies to myeloperoxidases and are usually positive in many forms of vasculitis

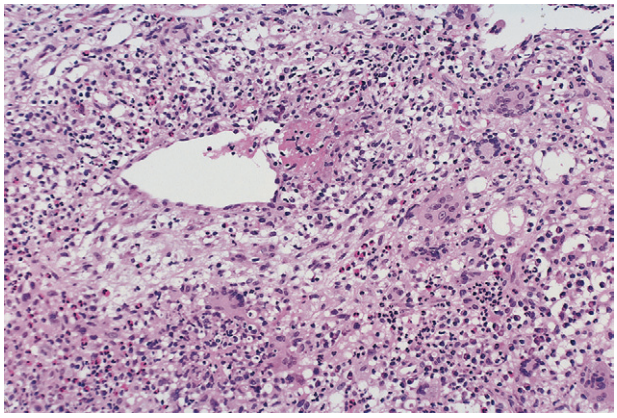

■ **FIGURE 2-53 Wegener's granulomatosis.** Granulomatous inflammation and necrotizing vasculitis.



■ **FIGURE 2-54** Midline granuloma presenting as oropharyngeal ulcers.

TABLE 2-5 WEGENER'S GRANULOMATOSIS VS. MIDLINE GRANULOMA (T-CELL LYMPHOMA)

	Wegener's Granulomatosis	Midline Granuloma
Etiology	Unknown? Infectious? Immune dysfunction	Malignancy of natural killer (NK)/T cells
Organs	Upper airways, lungs, kidneys	Upper airways, palate, gingiva
Pathology	Granulomatous and necrotizing vasculitis	NK/T-cell lymphoma (angiocentric)
Diagnosis	Biopsy, positive antineutrophil cytoplasmic antibodies (cANCAs)	Biopsy, immunologic studies
Treatment	Cyclophosphamide, prednisone	Radiation, chemotherapy

and polyarteritis; they therefore are not specific for Wegener's granulomatosis. Positive cANCA results should be confirmed by more specific studies, including ELISA testing for PR-3, a serine protease within neutrophil granules, and antimyeloperoxidase (MPO).

Treatment. Before the development of chemotherapeutic agents, renal failure and death were common outcomes of this disease process. Use of the cytotoxic agent cyclophosphamide combined with corticosteroids has provided afflicted patients with a relatively favorable prognosis. With treatment, remissions occur in approximately 75% of cases.

Midline Granuloma

Midline granuloma is a diagnosis made by exclusion of other granulomatous and necrotizing midfacial lesions. Because midline granuloma has many features that overlap with Wegener's granulomatosis, these two conditions were at one time classified together under the rubric *midline lethal granuloma.* Most, if not all, cases represent occult peripheral extranodal natural killer (NK)/T-cell lymphomas.

Clinical Features. Midline granuloma/extranodal NK/T-cell lymphoma is a unifocal destructive and aggressive process, generally in the midline of the oronasal region (Figure 2-54). Lesions appear clinically as necrotic ulcers that are progressive and nonhealing. Extension through soft tissue, cartilage, and bone is typical. Perforation of the nasal septum and hard palate may also be seen. Clinically, other diseases that produce destructive lesions of the midline of the nose or palate include Wegener's granulomatosis, infectious disease, and carcinoma.

Histopathology. Microscopically, the process appears as acute and chronic inflammation in partially necrotic tissue. Angiocentric inflammation is a common finding and is typical of many NK/T-cell lymphomas. Because of the almost trivial inflammatory appearance of this condition, several biopsies may be required before lymphoma can be diagnosed. Immunohistochemistry and molecular studies will establish NK/T-cell clonality consistent with lymphoma.

Treatment. The treatment of choice is local radiation. It is relatively effective and has produced a reasonably optimistic prognosis in limited disease. In advanced cases, the use of nonanthracycline combination chemotherapy may be helpful, although in such instances the prognosis remains poor.

Chronic Granulomatous Disease

Chronic granulomatous disease is a rare systemic (X-linked or autosomal recessive) disease, with the X-linked form demonstrating mutations in the *CYBB* gene, resulting in defects in the nicotinamide adenine dinucleotide phosphate

(NADPH)-oxidase complex and subsequent alterations in neutrophil and macrophage function. These cells, although they have the capacity to phagocytose microorganisms, lack the ability to kill certain bacteria and fungi because of inadequate superoxide and other oxygen metabolites that are toxic to organisms.

Manifestations appear during childhood and, because of the more frequent X-linked inheritance pattern, occur predominantly in males. The process may affect many organs, including the lymph nodes, lung, liver, spleen, bone, and skin, as recurrent or persistent infections. Oral lesions are frequently seen in the form of multiple ulcers that are also recurrent or persistent. Granulomatous disease and abnormal nitroblue tetrazolium neutrophil function test results would support clinical suspicions.

Cyclic Neutropenia

Cyclic neutropenia, a rare blood dyscrasia, is manifested as severe cyclic reduction or depletion of neutrophils from the blood and marrow, with a mean cycle, or periodicity, of about 21 days. Both autosomal-dominant and some sporadic forms are due to a mutation in the gene coding for neutrophil elastase *(ELA2)* located at chromosome 19p13.3. Fever, malaise, oral ulcers, cervical lymphadenopathy, and infections may appear during neutropenic episodes in early childhood. Patients are also prone to exaggeration of periodontal disease. Although treatment with granulocyte colony-stimulating factor may be effective, supportive care and strict oral hygiene measures are important. Early recognition of infection is important in management, as is judicious use of antibiotics.

NEOPLASMS

Squamous Cell Carcinoma of the Oral Cavity

Relative to the incidence of all cancers, oral and oropharyngeal squamous cell carcinomas represent about 3% of cancers in men and 2% of cancers in women. Annually, more than 36,000 new cases of oral and oropharyngeal cancer are expected to occur in men and women in the United States. The ratio of cases in men and women is now about 2 to 1. Previously, this ratio was 3 to 1; this shift has been attributed to an increase in smoking by women and to their longer life expectancy.

Deaths resulting from oral and oropharyngeal cancer represent approximately 2% of the total in men and 1% of the total in women. The total number of estimated annual deaths resulting from oral and oropharyngeal cancer is as high as 7880 in the United States, although a decrease of slightly more than 1.8% was noted in cancer death rates between 1991 and 2006 for this site.

The trend in survival of patients with this malignancy has been rather disappointing, although recently slight but significant improvement has been reported. The period between 1999 and 2005 reflects a 63% five-year relative survival rate as compared with a 55% rate in the years between 1984 and 1986 (Figure 2-55). Survival rates for African Americans have been lower than for other races, although a significant rise in survival was documented from 36% in the years between 1984 and 1986 to 46% from 1996 to 2005. Geographic variations in oral and oropharyngeal carcinoma survival rates exist in the United States and around the world and are most likely attributed to genetic and environmental differences unique to local populations.

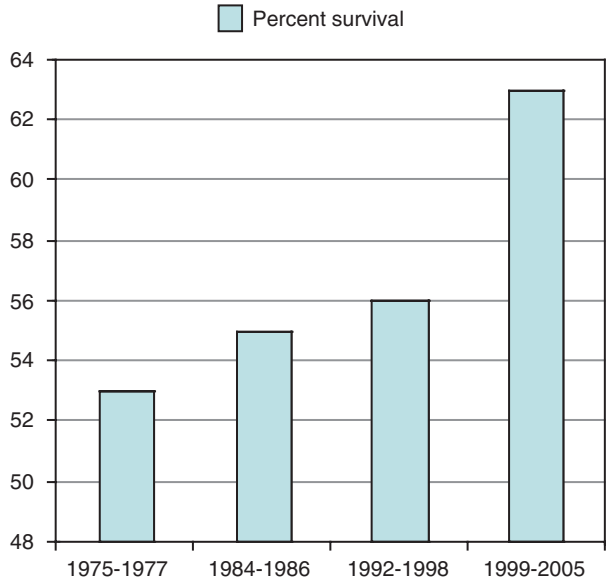

■ **FIGURE 2-55** Oral cancer 5-year survival rates. (From Jemal A, Siegal R, Xu J, Ward E: Cancer statistics, 2010, CA Cancer J Clin 60:277–300, 2010.)

In India and some other Asian countries, oral cancer is the most common type of malignancy and may account for more than 50% of all cancer cases. This finding is generally linked to the high prevalence of a unique smokeless tobacco habit. The tobacco, typically mixed with areca (betel) nut, slaked lime, and spices, is known as the quid, or paan, and is held in the buccal vestibule for long periods. This combination of ingredients, which may vary from one locale to another, is more carcinogenic than tobacco used alone.

Etiology. Of all factors believed to contribute to the etiology of oral cancer, tobacco is regarded as the most important. All forms of tobacco smoking have been strongly linked to the cause of oral cancer. Smoking of cigars and pipes is linked to greater risk for the development of oral cancer than that associated with cigarette smoking. "Reverse smoking," the habit of holding the lighted end of the cigarette inside the mouth, as may be the habit in India and some South American countries, is associated with a significantly high risk of oral cancer. This high risk is due to the intensity of tobacco combustion adjacent to palatal and lingual tissues. In any event, the time-dose relationship of carcinogens

found in tobacco is of paramount importance in determining the cause of oral cancer. In addition to an overall increased risk of development of cancer in all regions of the mouth, pipe smokers appear to have a special predilection for squamous cell carcinoma of the lower lip.

Long-term use of smokeless tobacco, whether in the form of snuff (ground and finely cut tobacco) or chewing tobacco (loose-leaf tobacco), is believed to increase the risk of oral cancer, although the risk level is probably low. In view of this lower oral cancer risk, some have advocated smokeless tobacco as an alternative to cigarettes, although the rationale for this is suspect when safe, alternative smoking cessation methods exist. In addition, many patients who use smokeless tobacco products also consume cigarettes and alcohol, thereby increasing their risk of oral cancer. Moreover, the use of smokeless tobacco carries with it other health risks, such as elevated blood pressure, physiologic dependence, and worsening periodontal disease.

Alcohol, although not generally believed to be a carcinogen itself, appears to add to the risk of oral cancer development. Identification of alcohol alone as a carcinogenic factor has proved to be somewhat difficult because of the combination of smoking and drinking habits seen in most patients with oral cancer. However, recent epidemiologic studies suggest that alcohol use alone may increase the risk for oral cancer. The effects of alcohol have been thought to occur through its ability to irritate the mucosa and to act as a solvent for carcinogens (especially those in tobacco). Contaminants and additives with carcinogenic potential that are found in alcoholic drinks have been thought to have a role in the development of oral cancer. Molecular studies have suggested that the carcinogenic risks associated with alcohol may be related to the effects of an alcohol metabolite, acetaldehyde, through alteration of keratinocyte gene expression.

Some microorganisms have been implicated in oral cancer. *Candida albicans* has been suggested as a possible causative agent because of its potential to produce a carcinogen, *N*-nitrosobenzylmethylamine. Epstein-Barr virus has been linked to Burkitt's lymphoma and nasopharyngeal carcinoma, but not to oral cancer.

Studies have demonstrated the occasional presence of human papillomavirus (HPV) subtypes 16 and 18 in oral squamous cell carcinomas, suggesting a possible role for this virus in oral cancers. However, more recent studies largely discount an etiologic role for HPV 16 and 18 in cancers of the oral cavity as compared with those of the oropharynx. This association is strongest for tonsil squamous cell carcinomas; up to 60% of tumors from this site may contain evidence of HPV, with most of these containing high-risk oncogenic subtypes. Of note is the difference in the molecular profile of HPV-associated squamous cell carcinoma versus HPV-negative tumors, with the former conferring a positive impact on survival. Verrucous carcinoma has been identified as a lesion possibly related to HPV infection. The mechanism by which HPV is thought to contribute to carcinogenesis is through protein (E6) inhibition of p53, leading to acceleration of the cell cycle and compromised DNA repair.

Although poor nutritional status has been linked to an increased rise in oral cancer, the only convincing nutritional factor that has been associated with oral cancer is iron deficiency of *Plummer-Vinson syndrome (Patterson-Kelly syndrome, sideropenic dysphagia)*. Typically affecting middle-aged women, the syndrome includes a painful red tongue, mucosal atrophy, dysphagia caused by esophageal webs, and a predisposition to the development of oral squamous cell carcinoma.

Ultraviolet (UV) light is a known carcinogenic agent that is a significant factor in basal cell carcinomas of the skin and squamous cell carcinomas of the skin and lip. The cumulative dose of sunlight and the amount of protection by natural pigmentation are of great significance in the development of these cancers. In the UV light spectrum, radiation with a wavelength of 2900 to 3200 nm (UVB) is more carcinogenic than light of 3200 to 3400 nm (UVA).

A compromised immune system puts patients at risk for oral cancer. This increased risk has been documented for bone marrow and kidney transplant recipients, who are iatrogenically immunosuppressed. The total-body radiation and high-dose chemotherapy that are used to condition patients for bone marrow transplants also put patients at lifelong risk for solid and lymphoid malignancies. It has long been suspected that AIDS predisposes patients to oral cancer, but evidence is mixed and has yet to be convincingly proven.

Chronic irritation is generally regarded as a modifier rather than an initiator of oral cancer. Mechanical trauma from ill-fitting dentures, broken fillings, and other frictional rubs is unlikely to cause oral cancer. If, however, a cancer is started from another cause, these factors will probably hasten the process. Poor oral hygiene is regarded as having a comparable modifying effect, although many patients with poor oral hygiene have other more important risk factors for oral cancer, such as tobacco habits and alcohol consumption.

Pathogenesis. Oral cancer, similar to most other malignancies, arises from the accumulation of a number of discrete genetic events that lead to invasive cancer (Figures 2-56 to 2-58). These changes occur in genes that encode for proteins that control the cell cycle, cell survival, cell motility, and angiogenesis. Each genetic mutation confers a selective growth advantage, permitting clonal expansion of mutant cells with increased malignant potential. This process is known as *clonal evolution*. The multistep genetic progression to cancer was first characterized in colonic mucosa, correlating with the sequential evolution of normal mucosa to adenomatous polyps and then adenocarcinoma. It was shown that a small number of genetic changes were required for acquisition of the malignant phenotype. For example, mutations of the *APC* and *K-ras* genes occur early in tumor progression, whereas alterations of *p53* and *DCC* occur more frequently in advanced tumors.

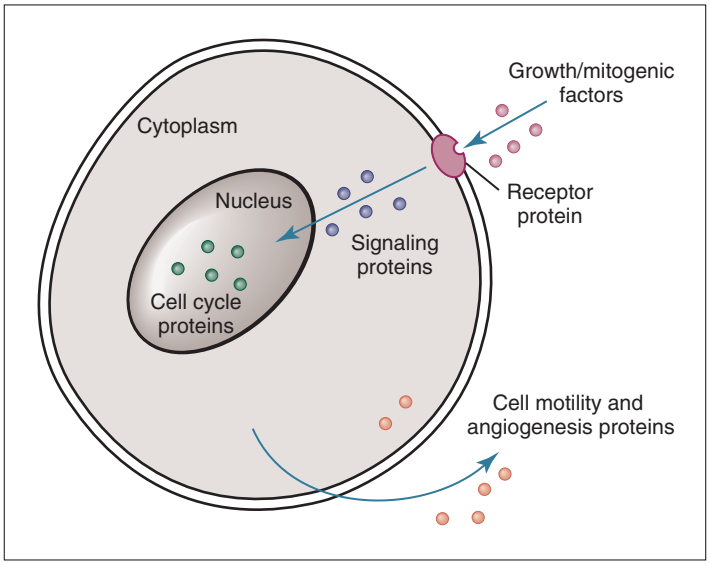

■ **FIGURE 2-56** Gene expression in oral cancer.

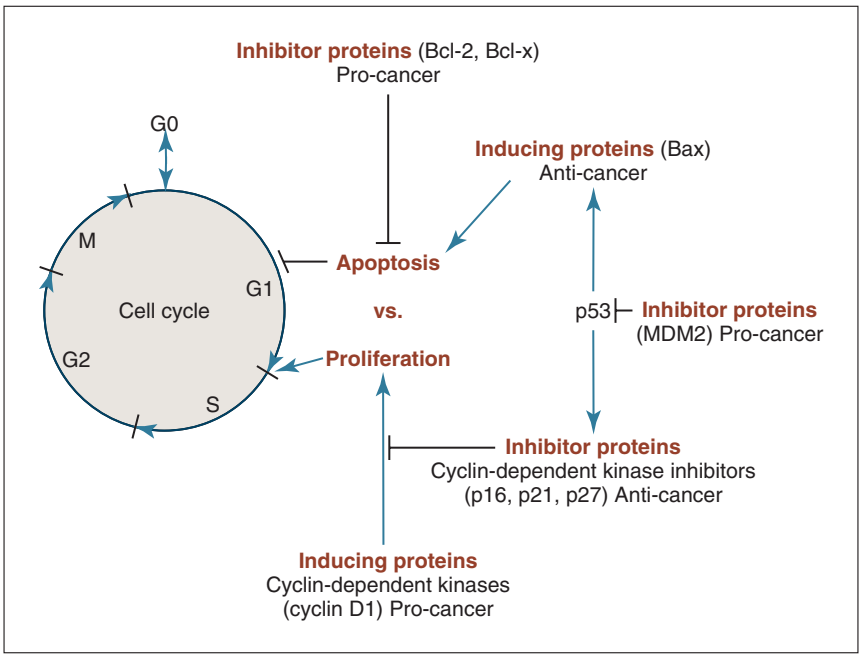

■ **FIGURE 2-57** Cell cycle regulation; controls at G1-S.

Cytogenetic analysis has shown a series of consistent alterations in squamous cell carcinoma, including but not limited to losses of 9p21—the site of two tumor suppressor genes (*p16* and *p14*ARF)—and 17p13—the site of the *p53* tumor suppressor gene—as well as 3p, 13q21, and 18q21. Loss of 9p inactivates the *p16* tumor suppressor gene, with a succession of losses of 3p and 17p as dysplasia develops and progresses.

Conceptually, oral cancers progress through two important biological stages. The first is loss of cell cycle control through increased proliferation and reduced apoptosis. Early in the carcinogenesis process, epidermal growth factor receptor (EGFR) and its principal or main ligand or binding protein, transforming growth factor-alpha (TGF-α), are upregulated, thus establishing an autocrine activation loop. Although levels of TGF-α remain stable with increasing degrees of dysplasia, EGFR expression increases and becomes markedly elevated in fully transformed squamous cell carcinoma. Histologically, the impact of the molecular alterations is most obvious in patients with in situ carcinoma, in which an increased number of dividing cells can be seen in all levels of the epithelium. The second stage is increased neoplastic

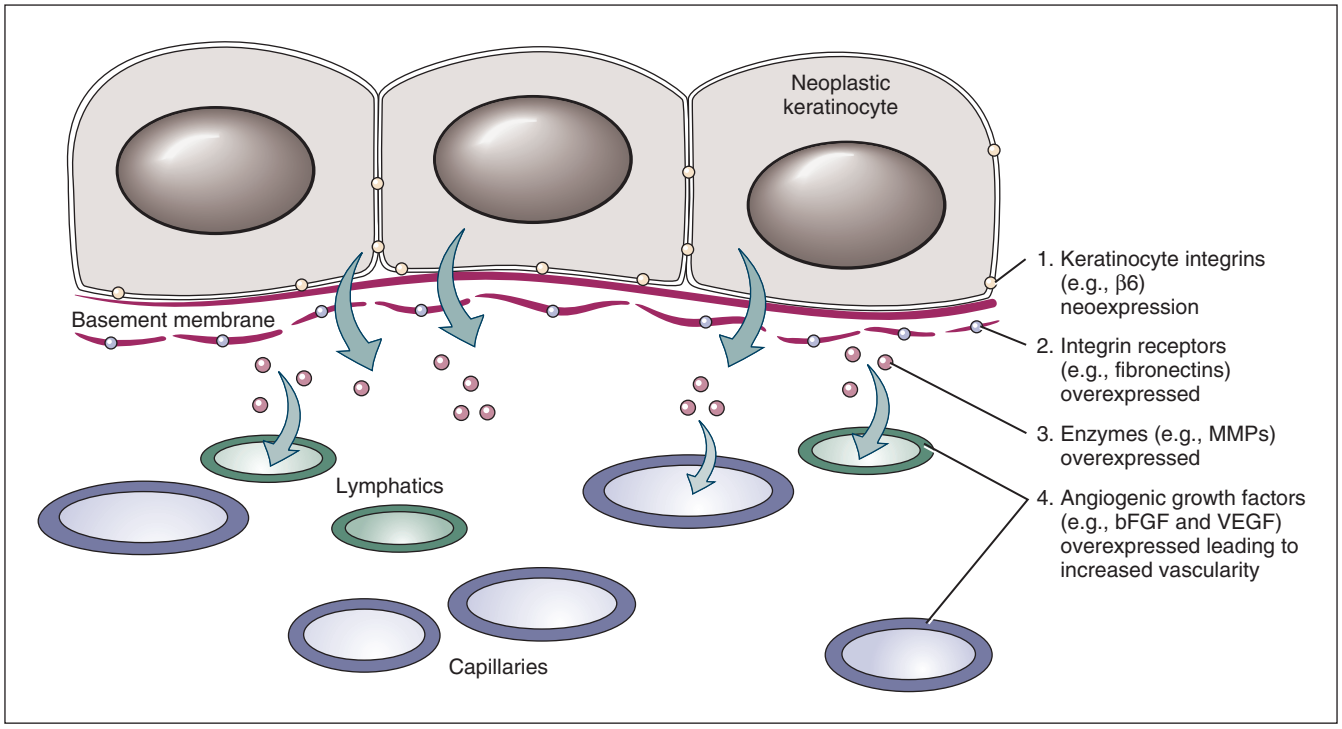

■ **FIGURE 2-58** Cancer cell invasion through enhanced cell motility and angiogenesis.

BOX 2-14 ORAL CANCER PATHOGENESIS

Oncogenes and tumor suppressor genes
- Mutation, amplification, or inactivation

Loss of control of:
- Cell cycle (proliferation vs. inhibition, signaling)
- Cell survival (apoptosis vs. antiapoptosis)
- Cell motility

cell motility, leading to invasion and metastasis. Here, neoplastic epithelial cells penetrate the basement membrane and invade underlying tissues, eventually reaching regional lymph nodes. Elements associated with local invasiveness and increased metastatic potential with corresponding poorer clinical outcomes are certain members of the MMP family, in particular MMPs 2, 9, and 13.

Both stages result from activation (upregulation) of oncogenes and inactivation (downregulation) of tumor suppressor genes (antioncogenes) (Box 2-14). Oncogenes, or proto-oncogenes under normal circumstances, encode proteins that positively regulate critical cell growth functions, such as proliferation, apoptosis, cell motility, membrane and internal cell signaling, and angiogenesis. If these genes are altered through one of several mechanisms (e.g., mutation), overexpression of the encoded protein occurs, giving rise to a clone of cells with a growth/motility advantage. Tumor suppressor genes encode proteins that negatively regulate or suppress proliferation. Alteration of these genes (changes in both maternal and paternal alleles are required) essentially "releases the brake" on proliferation for a clone of cells. Tumor suppressor genes are believed to play a more important role in oral cancer development than oncogenes.

Alterations of genes that control the cell cycle seem to be of critical importance in the development of oral cancer. Normally, cell division is divided into four phases: G1 (gap 1), S (DNA synthesis), G2 (gap 2), and M (mitosis). A key event is the progression from the G1 to the S phase. Genetic alterations, if unrepaired in the G1 phase, may be carried into the S phase and perpetuated in subsequent cell divisions. The G1-S "checkpoint" is normally regulated by a well-coordinated and complex system of protein interactions whose balance and function are critical to normal cell division. Overexpression of oncogenic proteins or underexpression of antioncogenic proteins can tip the balance in favor of proliferation and neoplastic transformation. For example, *p53* normally is a tumor suppressor gene and a key negative regulator at G1-S of the cell cycle. In about 50% of oral cancers, *p53* is mutated and its encoded protein is nonfunctional (Figure 2-59). Defective p53 protein allows cells to proceed into the S phase of the cell cycle before DNA can be repaired. The result is an accumulation of deleterious genetic defects that contribute to malignant transformation. This key protein may be dysregulated in oral precancer as well and may serve as an indicator of high-risk lesions. The MDM2 protein mediates the degradation of p53 and is frequently overexpressed in oral cancers.

Overexpression of the cyclin D1 protein can be identified in many oral cancers, leading to increased proliferation

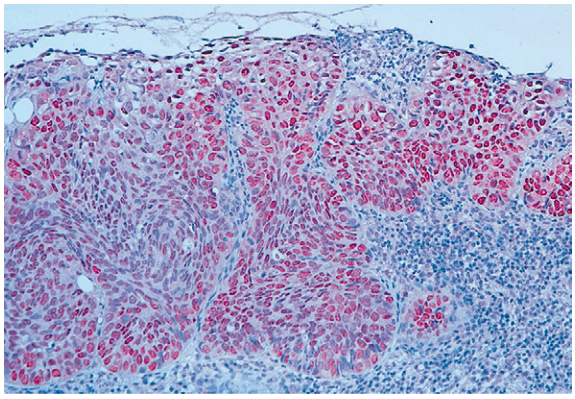

■ **FIGURE 2-59** Positive nuclear p53 staining in oral cancer. (From Regezi JA, Sciubba JJ, Pogrel MA: Atlas of Oral and Maxillofacial Pathology. Philadelphia, 2000, WB Saunders, Fig. 1-6.)

and premature progression through the G1-S checkpoint. Two important groups of intrinsic cell cycle proteins that regulate proliferation are cyclins and their catalytic binding enzymes, the cyclin-dependent kinases. In turn, these proteins are regulated by a class of inhibitory proteins known as cyclin-dependent kinase inhibitors. Reduced expression of the cyclin-dependent kinase inhibitors, $p16^{ink4a}$ and $p27^{kip1}$, is another important feature of oral cancer and is associated with loss of cell cycle control and increased proliferation.

The biological antithesis of proliferation is apoptosis (programmed cell death). If cells live longer, they may have a biological advantage that favors the development of neoplasia. Some genes that control apoptosis are altered in cancers (e.g., *BCL-2* gene, which is overexpressed in mantle cell lymphomas as a result of a chromosome translocation). In oral cancers, several proteins that regulate apoptosis (caspases, Bcl-2, and Bcl-X) are often dysregulated. The proapoptotic protein Bax has been positively correlated with increased sensitivity to chemotherapeutic agents in head and neck cancers.

Several other oncogenes that function in regulating cell growth and transporting signals from the cell membrane to the nucleus are frequently altered in many oral cancers. These include genes that code for *growth factors,* such as int-2 and hst-1 (fibroblast growth factor); *growth factor receptors,* such as HER1 (EGFR), HER2 (HER2/neu), HER3, and HER4; *proteins involved in signal transduction,* such as ras (guanosine triphosphate [GTP]-binding proteins); and *nuclear regulatory proteins,* such as myc (transcriptional activator proteins). Correlations have now been identified between growth receptor overexpression and patient outcome. Of particular importance is EGFR (HER1), a tyrosine kinase membrane receptor protein that is often overexpressed in oral cancers. Recently, molecules that are directed against component parts of the EGFR protein (cetuximab, erlotnib) have been shown to enhance the efficacy of radiation and chemotherapy in patients with head and neck cancers and to improve survival. These agents are in clinical use for several cancers, including oral and lung cancers.

Many oral cancers pass through a premalignant phase (dysplasia or in situ carcinoma), whereas others appear to arise de novo without clinical or microscopic evidence of a preexisting lesion. Invasive carcinomas have developed the ability to penetrate basement membrane and connective tissue, as well as enter the vascular system. These tumors are believed to have developed this biological advantage through molecular lesions in genes and proteins associated with cell movement and extracellular matrix degradation. Changes in the phenotype of cell adhesion molecules (e.g., cadherins, integrins) release cells from their normal environment and give them the ability to migrate. This, coupled with enzymatic degradation of the basement membrane and connective tissue, provides the necessary components for invasion of the proliferating tumor.

Critical cell adhesion proteins are frequently altered in invasive oral cancer. These include intercellular adhesion molecule (ICAM), e-cadherin, and the neoexpression of beta-6 integrin, a protein that assists keratinocyte motility. Matrix-related proteins produced by tumor cells and possibly by connective tissue elements (e.g., fibroblasts, macrophages) contribute to the breakdown of basement membrane and extracellular matrix proteins. Tenascin, an antiadhesion molecule not evident in normal mucosa, is frequently detected in oral squamous cell carcinomas. MMPs 1, 2, 9, and 13 have been demonstrated in invasive carcinomas and are believed to play a significant role in the degradation of connective tissue elements. In particular, MMPs 3 and 13 are associated with advanced head and neck carcinomas.

For tumors to grow much larger than 1 mm, a new blood supply is required (angiogenesis). This occurs through tumor-mediated induction or overexpression of angiogenic proteins (e.g., vascular endothelial growth factor [VEGF], basic fibroblastic growth factor [FGF]), and/or suppression of proteins that inhibit angiogenesis. VEGF, FGF, and interleukin 8 (IL-8), a proinflammatory cytokine, have been identified in head and neck cancers and are believed to be responsible, at least in part, for the angiogenesis associated with the progression of these tumors. The genetic alteration leading to overexpression of these proteins has not been fully determined, but it likely involves interactions with other critical oncogenes and immunosuppressor genes.

Another important feature of cancer cells is the increased replicative life span. Telomeres are DNA-protein complexes found at the ends of chromosomes that are required for chromosome stability. Normal cells have a finite life span related to telomere shortening that occurs with each successive cell division. When a critical telomere reduction is reached, the chromosome and subsequently the cell are subject to degradation. Cancer cells often develop a mechanism to maintain telomere length and chromosome integrity and thus long-term viability. This is associated with the production of telomerase, an intranuclear enzyme that is not present in normal adult cells but is found in cancer cells.



■ **FIGURE 2-60** Squamous cell carcinoma of the lip.



■ **FIGURE 2-62** Advanced squamous cell carcinoma of the posterior-lateral tongue.



■ **FIGURE 2-61** Exophytic squamous cell carcinoma of the lip.



■ **FIGURE 2-63** Squamous cell carcinoma of the lateral tongue in a 34-year-old man.

Most head and neck carcinomas have telomerase activity through neoexpression of the enzyme, giving the neoplastic cell extended life.

Clinical Features

Carcinoma of the Lips. From a biological viewpoint, carcinomas of the vermilion portion of the lower lip are separated from those of the upper lip. Carcinomas of the lower lip are far more common than upper lip lesions (Figures 2-60 and 2-61). UV light and pipe smoking are much more important in the cause of lower lip cancer than in the cause of upper lip cancer. The growth rate is slower for lower lip cancers than for upper lip cancers. The prognosis for lower lip lesions is generally very favorable, with more than 90% of patients alive after 5 years. By contrast, the prognosis for upper lip lesions is considerably worse.

Lip carcinomas account for 25% to 30% of all oral cancers. They appear most commonly in patients between 50 and 70 years of age and affect men much more often than women. Some components of lipstick may have sunscreen properties that account, in part, for this finding, although occupational exposure to sunlight is more of a factor in men. Lesions arise on the vermilion and typically appear as chronic nonhealing ulcers or as exophytic lesions that are occasionally verrucous in nature. Deep invasion generally appears later in the course of the disease. Metastasis to local submental or submandibular lymph nodes is uncommon but is more likely with larger, more poorly differentiated lesions.

Carcinoma of the Tongue. Squamous cell carcinoma of the tongue is the most common intraoral malignancy. Excluding lip lesions, it accounts for between 25% and 40% of oral carcinomas. It has a definite predilection for men in their sixth, seventh, and eighth decades. However, lesions may be found uncommonly in the very young. These lesions often exhibit particularly aggressive behavior.

Lingual carcinoma is typically asymptomatic. In later stages, as deep invasion occurs, pain or dysphagia may be a prominent patient complaint. Similar to other oral cancers, these present in one of four ways: as an indurated, nonhealing ulcer; as a red lesion; as a white lesion; or as a red-and-white lesion (Figures 2-62 to 2-65). The neoplasm may occasionally have a prominent exophytic, as well as endophytic, growth pattern. A small percentage of leukoplakias of the tongue represent invasive squamous cell carcinoma or



■ **FIGURE 2-64** Squamous cell carcinoma of the lateral tongue.



■ **FIGURE 2-66** Early squamous cell carcinoma of the floor of mouth.



■ **FIGURE 2-65** Squamous cell carcinoma of the ventral surface of the tongue.



■ **FIGURE 2-67** Early squamous cell carcinoma of the floor of mouth.

eventually become squamous cell carcinoma. Most erythroplakic patches that appear on the tongue are in situ or invasive squamous cell carcinomas at the time of discovery.

The most common location of cancer of the tongue is the posterior-lateral border, accounting for as many as 45% of tongue lesions. Lesions very uncommonly develop on the dorsum or on the tip of the tongue. Approximately 25% of tongue cancers occur in the posterior one third or base of the tongue. These lesions are more troublesome than the others because of their silent progression in an area that is difficult to visualize. Accordingly, these lesions more often are advanced or have metastasized regionally by the time they are discovered, reflecting a significantly poorer prognosis than for lesions of the anterior two thirds with the exception of HPV-positive tongue base carcinomas in those who do not smoke or consume excessive amounts of alcohol, where the overall prognosis is better than in smoking-alcohol-related carcinomas at this site.

Metastases from tongue cancer are relatively common at the time of primary treatment. In general, metastatic deposits from squamous cell carcinoma of the tongue are found in the lymph nodes of the neck, usually on the ipsilateral (same) side. The first nodes to become involved are the submandibular or jugulodigastric nodes at the angle of the mandible (anatomic levels I and II). Uncommonly, distant metastatic deposits may be seen in the lung or the liver.

Carcinoma of the Floor of Mouth. The floor of mouth is the second most common intraoral location of squamous cell carcinoma, accounting for 15% to 20% of cases. Again, carcinomas in this location occur predominantly in older men, especially those who are chronic alcoholics and smokers. The usual presenting appearance is that of a painless, nonhealing, indurated ulcer (Figure 2-66). It may appear as a white or red patch (Figure 2-67). The lesion occasionally may widely infiltrate the soft tissues of the floor of mouth, causing decreased mobility of the tongue (Figures 2-68 and 2-69). Metastasis to submandibular lymph nodes is not uncommon for lesions of the floor of mouth.

Carcinoma of the Buccal Mucosa and Gingiva. Lesions of the buccal mucosa and lesions of the gingiva each account for approximately 10% of oral squamous cell carcinomas. Men in their seventh decade typify the affected group. The presenting clinical appearance varies from a white patch to a nonhealing ulcer to an exophytic lesion (Figure 2-70). In



■ **FIGURE 2-68** Squamous cell carcinoma of the floor of mouth.

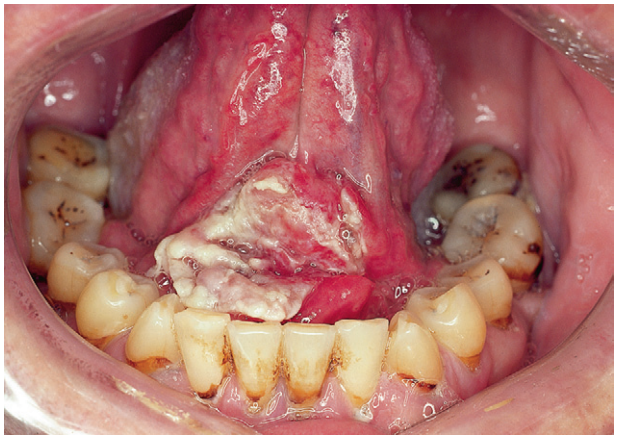

■ **FIGURE 2-69** Squamous cell carcinoma of the floor of mouth.



■ **FIGURE 2-70** Squamous cell carcinoma of the gingiva.

the latter group is the clinical pathologic entity *verrucous carcinoma*. This subset of squamous cell carcinoma, sometimes associated with the use of smokeless tobacco, presents as a broad-based, wartlike mass. It is slow growing and is very well differentiated, rarely metastasizes, and has a very favorable prognosis.



■ **FIGURE 2-71** Second primary squamous cell carcinoma of the palate in a 34-year-old man.



■ **FIGURE 2-72** Metastasis of squamous cell carcinoma of the tongue to a submandibular lymph node.

Carcinoma of the Palate. There is some justification for separation of cancers of the hard palate from those of the soft palate. In the soft palate and contiguous faucial tissues, squamous cell carcinoma is a fairly common occurrence, accounting for 10% to 20% of intraoral lesions. In the hard palate, squamous cell carcinomas are relatively rare. By contrast, salivary gland adenocarcinomas are relatively common in the palate. However, palatal carcinomas are commonly encountered in countries such as India, where reverse smoking is common.

Palatal squamous cell carcinomas generally present as asymptomatic red or white plaques or as ulcerated and keratotic masses (adenocarcinomas initially appear as nonulcerated masses) (Figure 2-71). Metastasis to cervical nodes or large lesions signifies an ominous course (Figures 2-72 and 2-73).

Histopathology. Most oral squamous cell carcinomas are moderately differentiated or well-differentiated lesions (Figures 2-74 and 2-75). Keratin pearls and individual cell keratinization are usually evident. Invasion into subjacent

structures in the form of small nests of hyperchromatic cells is typical. In situ carcinoma extension into salivary excretory ducts can be regarded as a high-risk microscopic indicator of potential recurrence. Considerable variation between tumors is seen relative to the numbers of mitoses, nuclear pleomorphism, and the amount of keratinization. In H&E-stained sections of poorly differentiated lesions, keratin is absent or is seen in minute amounts. However, it can be identified using immunohistochemical techniques for the demonstration of antigenic determinants on otherwise occult keratin intermediate filaments. A significant inflammatory host response is usually noted surrounding the nests of invading tumor cells. Lymphocytes, plasma cells, and macrophages may all be seen in large numbers.

Rarely, an oral squamous cell carcinoma appears as a proliferation of spindle cells that may be mistaken for a sarcoma. This type of tumor, known as *spindle cell carcinoma* or sarcomatoid carcinoma, arises from the surface epithelium, usually of the lips and occasionally of the tongue. Immunohistochemical staining can be used to identify keratin antigens in this lesion when H&E-stained sections show equivocal findings (Figure 2-76).

Verrucous carcinoma is characterized by very well differentiated epithelial cells that appear more hyperplastic than neoplastic. A key feature is the invasive nature of the lesion in the form of broad, pushing margins. The advancing front is usually surrounded by lymphocytes, plasma cells, and macrophages. Diagnosis based solely on microscopic features is often difficult; it is frequently necessary to consider the lesion in the context of clinical presentation. *Papillary squamous cell carcinoma* resembles verrucous carcinoma but is less differentiated and has a poorer prognosis.

Another microscopic variant or distinctive subset of squamous carcinoma that has a predilection for the base of the tongue and pharynx is biologically highly malignant and is known as *basaloid-squamous carcinoma.* In these tumors, a basaloid pattern of tumor cells is seen adjacent to tumor cells that exhibit squamous differentiation. This tumor may be confused microscopically with basaloid adenoid cystic carcinoma and adenosquamous carcinoma. Separation of this form of carcinoma into human papillomavirus 16 positive and negative forms by using in situ hybridization techniques has led to the recognition of a less aggressive pattern of behavior in HPV 16–positive cases as compared with their

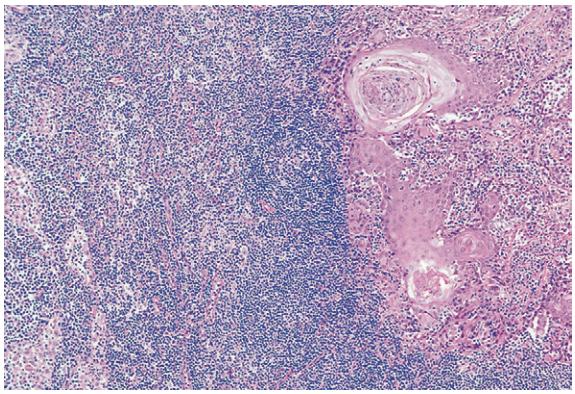

■ **FIGURE 2-73** Metastatic squamous cell carcinoma *(right)* in a lymph node. (Reproduced with permission from Regezi JA, Sciubba JJ, Pogrel MA: Atlas of Oral and Maxillofacial Pathology. Philadelphia, 2000, WB Saunders, Fig. 1-12.)

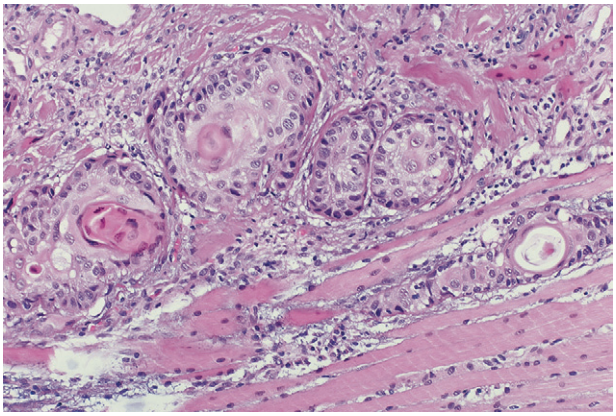

■ **FIGURE 2-75** Squamous cell carcinoma showing tumor nests invading skeletal muscle.

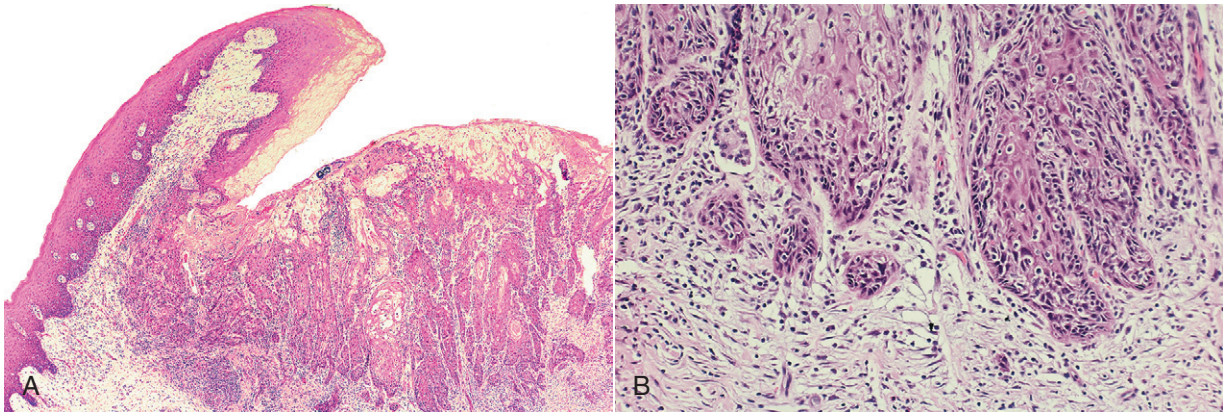

■ **FIGURE 2-74 A** and **B,** Squamous cell carcinoma of the tongue.

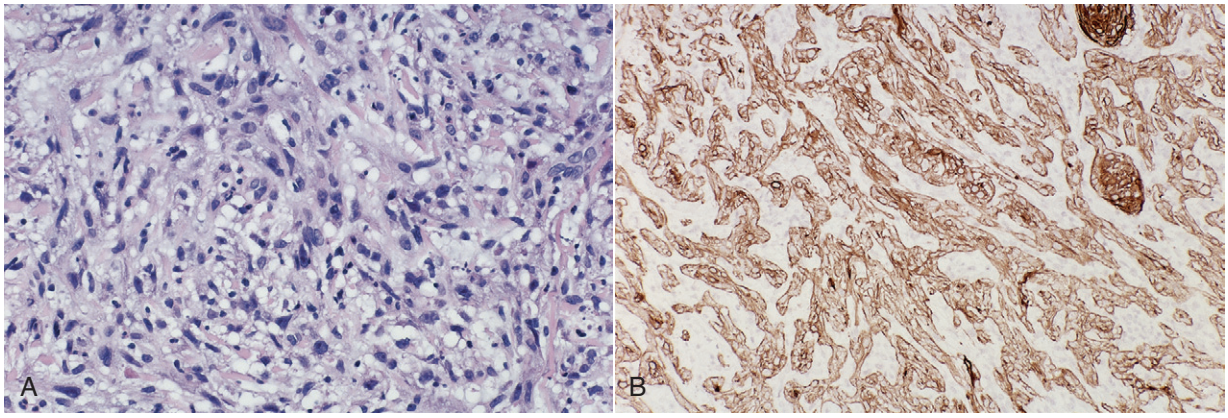

■ **FIGURE 2-76 A,** Spindle cell squamous cell carcinoma. **B,** Immunohistochemical stain for keratins showing positive staining of tumor cells.

HPV 16–negative counterparts, and thus an improved clinical outcome.

Differential Diagnosis. When oral squamous cell carcinomas present in their typical clinical form of chronic, nonhealing ulcers, other ulcerative conditions should be considered. An undiagnosed chronic ulcer must always be considered potentially infectious until biopsy findings prove otherwise. It may be impossible on clinical grounds to separate TB, syphilis, and deep (invasive) fungal infections expressing oral manifestations from oral cancer. Chronic trauma, including factitial or self-induced injury, may mimic squamous cell carcinoma. Careful history taking is especially important, and biopsy findings confirm the diagnosis. In the palate and contiguous tissues, midline granuloma and necrotizing sialometaplasia would be serious diagnostic considerations.

Surgical Management of Squamous Cell Carcinoma of the Oral Cavity

Eric Carlson, DMD, MD

General clinical experience with patients with squamous cell carcinoma of the oral cavity shows that they most commonly present with one of the four following clinical scenarios: early disease (T1-2, N0), locally advanced disease (T3-4, N0), locally and regionally advanced disease (T4, N1-2), or nonresectable disease. Treatment of resectable squamous cell carcinoma of the oral cavity is based on the location and stage of the primary tumor. As such, local surgery of the primary tumor, as well as regional surgery of the neck nodes, is considered and individually planned for each patient. Local surgery of the primary tumor must consider the removal of soft tissue and bone, as indicated. Removal of the cancer in soft tissue is referred to as a *wide local excision,* incorporating a 1.0- to 1.5-cm linear margin of clinically normal-appearing soft tissue at the periphery of the specimen. A partial glossectomy, or hemiglossectomy, is a specific type of wide local excision indicated for the management of malignant disease of the tongue. Removal of squamous cell carcinoma in bone is referred to as a *resection,* incorporating a 2-cm linear margin of radiographically normal-appearing bone at the periphery of the specimen. Mandibular resections are subclassified as marginal resections whereby the inferior border of the mandible is preserved, or as segmental resections whereby the full height of the mandible is sacrificed, thereby creating a defect in continuity of the mandible. Disarticulation resections are a variant of segmental mandibular resection whereby the temporomandibular joint is sacrificed. A composite resection, a commonly performed ablative surgery for oral squamous cell carcinoma, includes the sacrifice of hard and soft tissue. Typically, composite resections include a monobloc sacrifice of neck nodes, the mandible, and soft tissues corresponding to the primary tumor in the tongue or the floor of mouth, for example (Figure 2-77).

Management of the neck is perhaps one of the most interesting and controversial aspects of the surgical management of oral squamous cell carcinoma. Neck dissections are performed in one of three instances. The first is when palpable cervical lymphadenopathy exists. A neck examination must be performed before an incisional biopsy of a suspicious oral lesion is performed. This examination of the neck is one part of tumor, node, metastasis (TNM) staging and is performed even before a definitive diagnosis of squamous cell carcinoma is established. The N stage is entirely clinically based, and the TNM classification is not modified if computed tomography (CT) scan findings contradict the clinical examination.

The second indication for neck dissection includes positive lymphadenopathy divulged by special imaging studies (CT or magnetic resonance imaging [MRI]). It is possible that a clinical examination may result in an N0 classification, whereas the patient's imaging study may reveal enlarged lymph nodes with hypodense (necrotic) centers, likely indicative of metastatic squamous cell carcinoma. This scenario may occur in obese patients whose clinical neck examinations are unreliable. Nonetheless, under such circumstances,

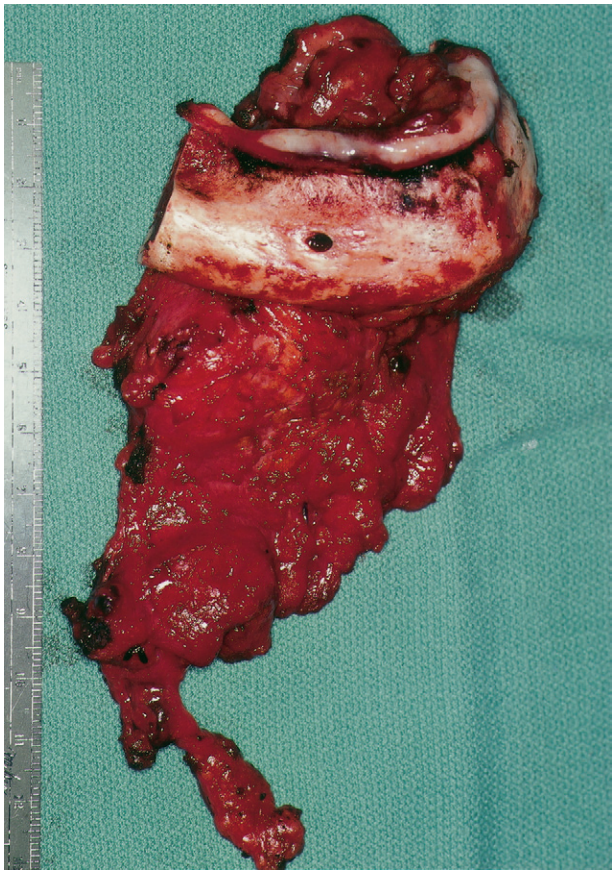

■ **FIGURE 2-77** Composite resection performed for T4, N0, M0 squamous cell carcinoma of the anterior floor of mouth. The specimen consists of a monobloc resection of the floor of mouth, mandible, and ipsilateral neck nodes.

neck staging remains N0 and a neck dissection is indicated. CT and MRI studies provide very sophisticated *anatomic* assessments of lymph nodes in the neck (Figure 2-78, *A*). Yet, in many patients, identification of mildly enlarged lymph nodes can be due to the incisional biopsy used to establish the diagnosis of the patient's cancer, or other causes. *Functional,* or molecular, imaging represents an opportunity to distinguish lymph nodes containing cancer from those that are mildly enlarged for another reason (Figure 2-78, *B*). Molecular imaging with positron emission tomography (PET) and a glucose biomarker ^{18}[F]-fluorodeoxyglucose (FDG) has become increasingly widely used to diagnose and stage malignant disease. The ability of PET to accurately stage malignant disease depends on the tumor size, the physical specifications of the PET scanner, and the avidity of cancer cells to take up FDG. Recently, fusion devices that image both anatomy (CT) and function (PET) have been developed, offering the best of both worlds: functional abnormalities can be localized accurately, and the functional status of anatomic abnormalities can be assessed immediately. Clinical observation using PET/CT scanning in oral/head and neck cancer patients indicates three advantages of this new technology:

1. Assessment of subclinical disease in the lymph nodes in the neck is possible, which might alter the neck surgery treatment plan (Figure 2-79).
2. Early assessment of synchronous second primary cancers is possible.
3. Assessment of distant metastatic disease is possible, which might result in the refinement of treatment recommendations. Identification of disseminated metastases might change a treatment plan from surgical to nonsurgical.

The third, and most thought-provoking, indication for neck dissection is management of the neck when lymphadenopathy is not apparent. *Occult neck disease* is defined as cancer present in lymph nodes in the neck that cannot be

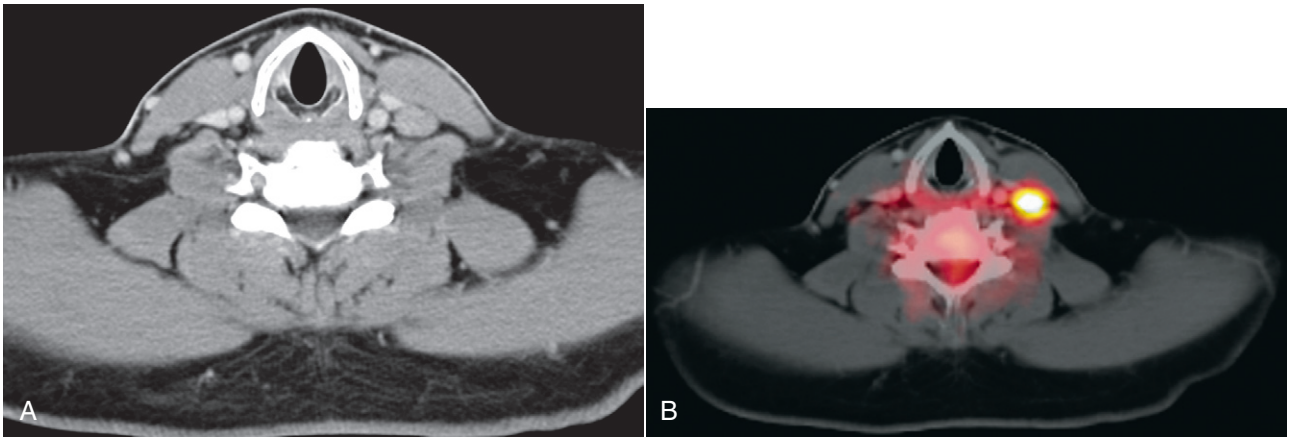

■ **FIGURE 2-78 A,** Computed tomography (CT) demonstrating an enlarged lymph node medial to the left sternocleidomastoid muscle. CT provides an anatomic assessment of this mildly enlarged lymph node. **B,** The positron emission tomography (PET)/CT image of the same patient shows increased metabolic activity of this lymph node, thereby supporting the presence of metastatic disease within the lymph node. PET/CT therefore provides an anatomic and functional assessment of the lymph node.



■ **FIGURE 2-79 A** and **B,** A 49-year-old woman previously diagnosed with squamous cell carcinoma of the tongue and a large metastatic lymph node in the left neck. **C,** The positron emission tomography (PET)/computed tomography (CT) scan obtained in this patient shows expected increased metabolic activity in the lymph node in the left neck, but also shows increased metabolic activity in a lymph node in the right neck that was not able to be palpated clinically. As such, the surgical treatment plan included bilateral neck dissections. Had the PET/CT scan not been obtained, the patient might have undergone only the left neck dissection.

palpated clinically and do not appear on special imaging studies. As such, these neck dissections are performed for N0 disease. Numerous studies have examined the likelihood of occult neck disease as a function of the anatomic site of the primary cancer and as a function of its size and thickness. These studies clearly show that early squamous cell carcinoma of the oral tongue (T1-2, N0) may be associated with occult neck disease in nearly 40% of cases. This explains why many surgeons advocate performing a neck dissection for early squamous cell carcinoma of the tongue. Early disease of the floor of mouth (followed by disease of the buccal mucosa, maxillary gingiva, mandibular gingiva, and lip) carries a quantitatively lower, yet significant, risk of occult neck disease. Therefore, prophylactic neck dissections play an important role in the management of many early squamous cell carcinomas of the oral cavity, and should be performed when the risk of occult neck disease is quantified as being greater than 20%.

Performance of bilateral neck dissections is occasionally required in the management of oral squamous cell carcinoma. Indications include midline primary cancers that are defined as being present in the affected anatomic structure (e.g., tongue, floor of mouth, gingiva) within 1 cm of the midline of the oral cavity and those cancers that cross the midline. Under such circumstances, the neck may be classified as bilateral N0 or ipsilateral N+ and contralateral N0. The bilateral N+ neck may also be encountered. In one study of 66 patients in whom elective dissection of the contralateral neck was performed, the rate of occult contralateral neck metastasis was found to be 21% when ipsilateral cervical lymph node metastasis was noted histologically. These data point to the need to consider contralateral neck surgery for patients in whom an ipsilateral N+ neck exists, particularly when managing midline or bilateral primary cancers.

Neck dissections may be classified as comprehensive or selective. *Comprehensive neck dissections* include the radical

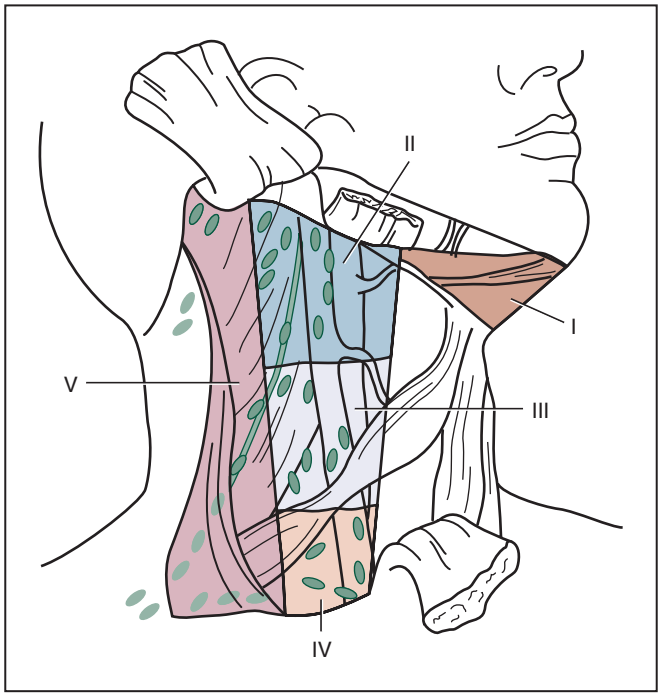

■ **FIGURE 2-80** Oncologic lymph node levels of the neck. Level I = submental/submandibular nodes; level II = upper jugular nodes; level III = middle jugular nodes; level IV = lower jugular nodes; level V = posterior triangle nodes.

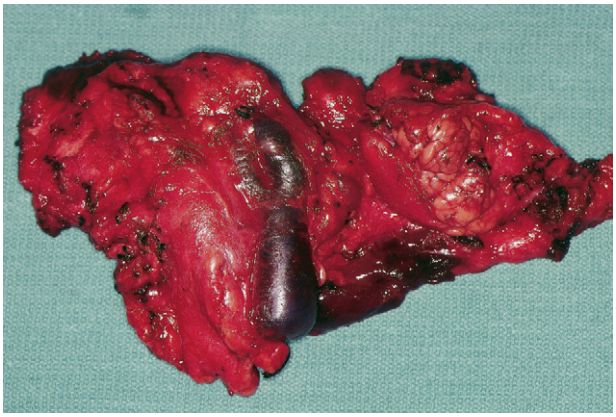

■ **FIGURE 2-81** Specimen from a type 1 modified radical neck dissection. The internal jugular vein is noted on the medial aspect of the sternocleidomastoid muscle. The spinal accessory innervation of the trapezius muscle remains intact in this type of neck dissection.

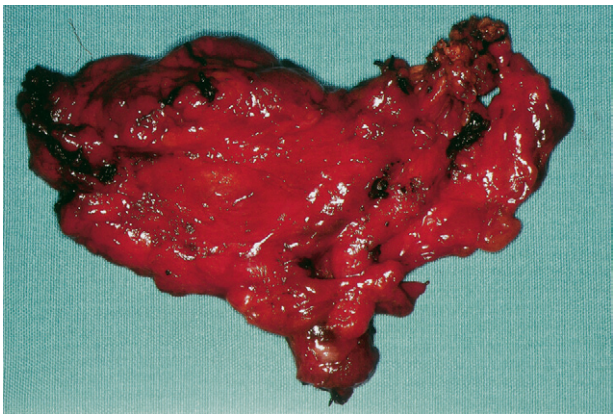

■ **FIGURE 2-82** Specimen from a supraomohyoid dissection.

neck dissection and the modified radical neck dissection (MRND). Both are performed when patients present with palpable (N+) cervical lymphadenopathy. By definition, the radical neck dissection removes lymph nodes in oncologic levels I to V of the neck (Figure 2-80), along with the sternocleidomastoid muscle, the internal jugular vein, and the spinal accessory nerve. Owing to the observation that the spinal accessory nerve is rarely involved in the cancer, the more commonly performed MRND is described. The MRND sacrifices lymph nodes in levels I to V, yet preserves the sternocleidomastoid muscle or the internal jugular vein or, commonly, the spinal accessory nerve. The type 1 MRND preserves the spinal accessory nerve while sacrificing all of the aforementioned structures (Figure 2-81).

Selective neck dissections, most commonly performed for the N0 neck, sacrifice lymph nodes exclusively. By definition, then, the sternocleidomastoid muscle, internal jugular vein, and spinal accessory nerve are intentionally preserved. The supraomohyoid neck dissection, the most common type of selective neck dissection, removes lymph node levels I to III (Figure 2-82). This neck dissection, therefore, is indicated in managing the N0 neck with a high likelihood of occult neck disease.

When bilateral neck dissections are required in the management of patients with oral squamous cell carcinoma, maintenance of at least one internal jugular vein is required to avoid intraoperative/postoperative complications such as superior vena cava syndrome, stroke, and a syndrome of inappropriate secretion of antidiuretic hormone (SIADH). If bilateral internal jugular veins must be sacrificed, staging neck dissections should occur following a 3-week period from the time of initial neck dissection. When a midline or bilateral primary cancer of the oral cavity exists in association with an ipsilateral N+ neck and a contralateral N0 neck, an ipsilateral comprehensive neck dissection ought to be performed in conjunction with a contralateral supraomohyoid neck dissection. When a midline or bilateral primary cancer of the oral cavity exists in association with a bilateral N0 neck, bilateral supraomohyoid neck dissections are indicated (Figure 2-83).

Surgical management of squamous cell carcinoma ultimately is based on decision making for optimal control of local disease while existing or potential lymph node drainage in the neck is addressed. The use of radiation therapy often plays a role in the sole management of squamous cell carcinoma of the oral cavity, with or without chemotherapy, or as an adjunct in the postoperative phase. It is sound practice

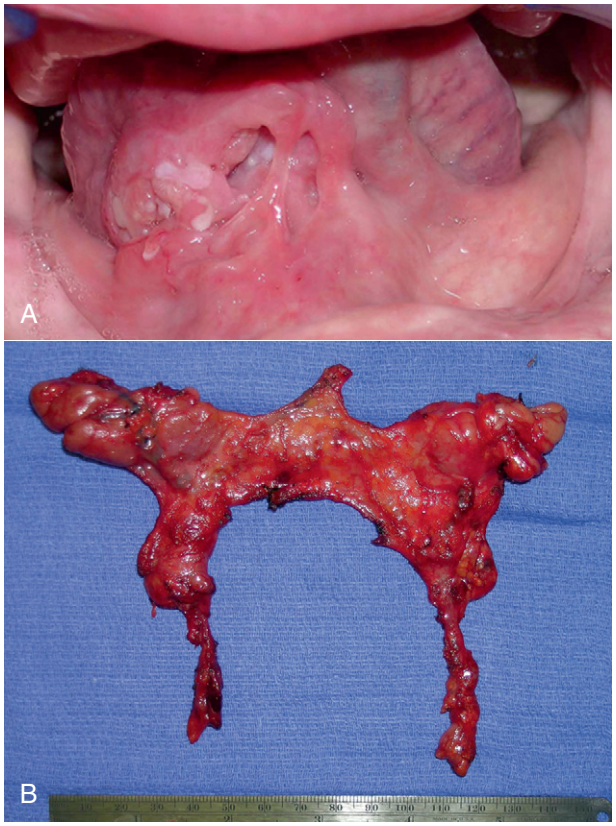

■ **FIGURE 2-83 A,** A squamous cell carcinoma of the right floor of mouth/ventral tongue that crosses the midline. **B,** This patient has N0 disease such that bilateral supraomohyoid neck dissections are performed.

that administration of radiation therapy should be planned after a thorough review of the patient's histopathology. General indications for postoperative administration of radiation therapy include the following:

- Positive soft tissue margin
- More than one positive lymph node without extracapsular invasion
- One or more lymph nodes with extracapsular invasion
- Bone invasion by the cancer, even with negative bone margins
- Perineural invasion in the specimen
- The presence of comorbid immunosuppressive disease, such as HIV/AIDS

This approach represents a departure from the previously accepted dogma that radiation therapy is administered to most, if not all, postoperative patients. Therefore, surgery and radiation therapy are tailored to each patient's specific cancer, rather than treating all patients in a similar fashion. Unfortunately, despite numerous refinements in surgery and radiation therapy, the 5-year survival rate for all patients with squamous cell carcinoma (including all sites and stages) has improved only minimally in the past 50 years.

Radiotherapy Management of Squamous Cell Carcinoma of the Oral Cavity

Clinical Evaluation.

John Kim, MD

Patients with biopsy-proven squamous cell carcinoma (SCC) of the oral cavity should undergo a complete history and physical examination. The clinical examination includes indirect mirror laryngoscopy and/or direct flexible fiberoptic laryngoscopy and pharyngoscopy to rule out synchronous head and neck primary cancers and to assess the airway of patients with large tumors. The primary site and regional lymph nodes are imaged with CT scan and/or MRI scan. PET scanning may help identify subclinical primary disease extension, occult neck nodal disease, and systemic metastases. PET scanning involves the injection of a metabolite that is normally taken up by normal tissues or tumors. These metabolites are labeled with radioactive isotopes that allow radiographic detection of these "tracer" compounds. FDG is most commonly used for head and neck cancers exploiting the active metabolism of glucose by tumors. Several investigational tracer compounds may have clinical application for head and neck cancers. An example is ^{18}[F]-misonidazole (FMISO). FMISO is preferentially taken up by hypoxic cells; therefore, hypoxic tumor regions can be detected. Hypoxic tumors may be less responsive to radiation. PET scans do not provide anatomic spatial details. Combining PET and CT imaging (registration) can provide more detailed anatomic correlation of areas of increased uptake that may represent tumor. PET scans can play a role in the assessment of tumor response following therapy; a novel role is the use of PET scanning in radiotherapy target delineation and planning.

A dental panoramic radiograph is obtained to assess both dental status and possible mandibular involvement of oral cavity tumors. Other staging and baseline investigations include blood work (complete blood count, electrolytes, renal function, liver enzymes, and thyroid function tests) and chest x-ray or CT scan of the thorax. CT scan or ultrasound of the liver and a bone scan are warranted in some patients with advanced disease or systemic symptoms (e.g., bone pain).

Patients are staged according to the American Joint Committee on Cancer (AJCC) Cancer Staging Manual or the International Union Against Cancer (UICC) Classification of Malignant Tumors. Radiotherapy patients require a pretreatment dental consultation regardless of whether they are dentate or edentulous. The attending dentist should have knowledge of the radiotherapy fields and high-dose radiotherapy volumes. Some patients will require dental extractions within the high-dose radiotherapy treatment volumes; this should be done before treatment is provided. Teeth that are loose or periodontally involved, those with large or unrestorable caries, those with apical pathology, and those that are impacted should be extracted before radiation therapy. Any questionable tooth should be extracted and should not be given the benefit of the doubt because osteoradionecrosis poses a serious problem for the patient.

Routine dental procedures should also take place before treatment. Fluoride carrier trays are constructed for dentate patients for the daily application of neutral pH topical fluoride, which continues for the remainder of the patient's life. Patients are also educated on the importance of maintaining meticulous dental hygiene, which is essential to minimize the risks of increased rates of dental caries in xerostomic (dry mouth) patients and osteoradionecrosis of the mandible post radiotherapy.

Primary Radiotherapy. Radiotherapy as the primary treatment modality is an option for patients with oral cavity carcinomas. Modalities of radiation treatment delivery include conventional or conformal external beam radiotherapy (EBRT), intensity-modulated radiation therapy (IMRT) and brachytherapy. EBRT is delivered with photons alone, or in combination with electrons. Usually, multiple treatment fields (or portals) are used. The principle of EBRT is to encompass the gross oral cavity (primary) disease and a surrounding margin. This additional margin allows the inclusion of potential local microscopic spread of cancer, day-to-day variation in treatment set-up, patient movement, organ movement (e.g., swallowing), and build-up of the radiation dose at the edge of the radiation beam (penumbra). Patient movement is minimized with the use of immobilization devices. All patients undergoing head and neck irradiation are immobilized with a neck rest and mask immobilization (Figure 2-84) or with bite block devices. Regional lymph nodes (primary echelon lymph nodes) at risk for harboring microscopic or occult disease are usually included in the radiotherapy fields, even for patients who present with clinical N0 necks. In one study, occult nodal metastases were detected in 49% of patients with clinical T1-T3, N0 carcinomas of the oral cavity who underwent elective neck dissection. Ipsilateral neck node levels I and II are at highest risk for occult metastases (see description of oncologic node region levels earlier in this chapter). Some oral cavity SCCs such as tongue cancers can metastasize to lower neck nodes without upper neck involvement. Midline lesions are at higher risk than unilateral lesions for bilateral occult nodal metastases. Areas of potential occult disease are treated to a lower dose than areas of gross disease. Gross nodal disease is usually treated with the same dose as the primary oral cavity cancer.



■ **FIGURE 2-84** Example of head and neck mask immobilization.

Radiotherapy side effects result from irradiation of normal tissues that cannot be excluded from the treatment portal. For all or part of the treatment, some critical normal tissues may be excluded from one or more of the radiation fields by the use of shielding or beam-shaping devices introduced in the radiation beam. Normal structures can be avoided by using beam geometries that completely avoid critical structures from one or more of the radiation fields. For example, ipsilateral EBRT techniques can be used to avoid the contralateral parotid and to preserve salivary function post radiotherapy (Figure 2-85). CT-based radiotherapy planning systems allow more accurate identification of gross disease and normal structures.

Conformal radiotherapy techniques such as three-dimensional conformal radiotherapy (3DCRT) and IMRT may offer better tumor coverage and sparing of normal tissues. State-of-the-art CT-based planning software and radiation treatment units are used to plan and deliver IMRT. IMRT is a form of 3DCRT. Unlike IMRT, the beam intensity across each radiation field is uniform in conventional EBRT and 3DCRT. The beam intensity across each IMRT treatment field is varied in a complex manner that enables shaping of the radiation dose, thus allowing for conformal target coverage while avoiding nearby normal tissues. A common IMRT planning goal is to preserve parotid gland function (parotid-sparing) and avoid permanent xerostomia. The ability to create a steep radiation dose gradient (high dose to low dose over a very small distance) is an important feature of IMRT. Tumors close to a critical normal structure, such as the spinal cord, can be treated adequately while avoiding serious toxicity to the nearby critical structure. For oral cavity carcinomas, parotid-sparing and limiting radiation dose to uninvolved oral mucosa and mandible are potential benefits of IMRT (Figure 2-86).

Ensuring daily accurate and precise treatment delivery is a critical quality assurance activity in radiotherapy. Sophisticated three-dimensional treatment delivery image verification systems are now available. Image-guided radiation therapy (IGRT) is becoming routine clinical practice and is currently an active area of research in radiation oncology.

Brachytherapy is a treatment method that delivers very high but localized radiation doses. It involves the placement of radioactive sources in the tumor bed. A type of brachytherapy called *interstitial implant,* or *interstitial radiotherapy (ISRT),* can be used to treat oral cavity carcinomas in the floor of mouth or tongue (alone or in combination with EBRT). This technique requires a general anesthetic. One method of ISRT involves the surgical placement of catheters

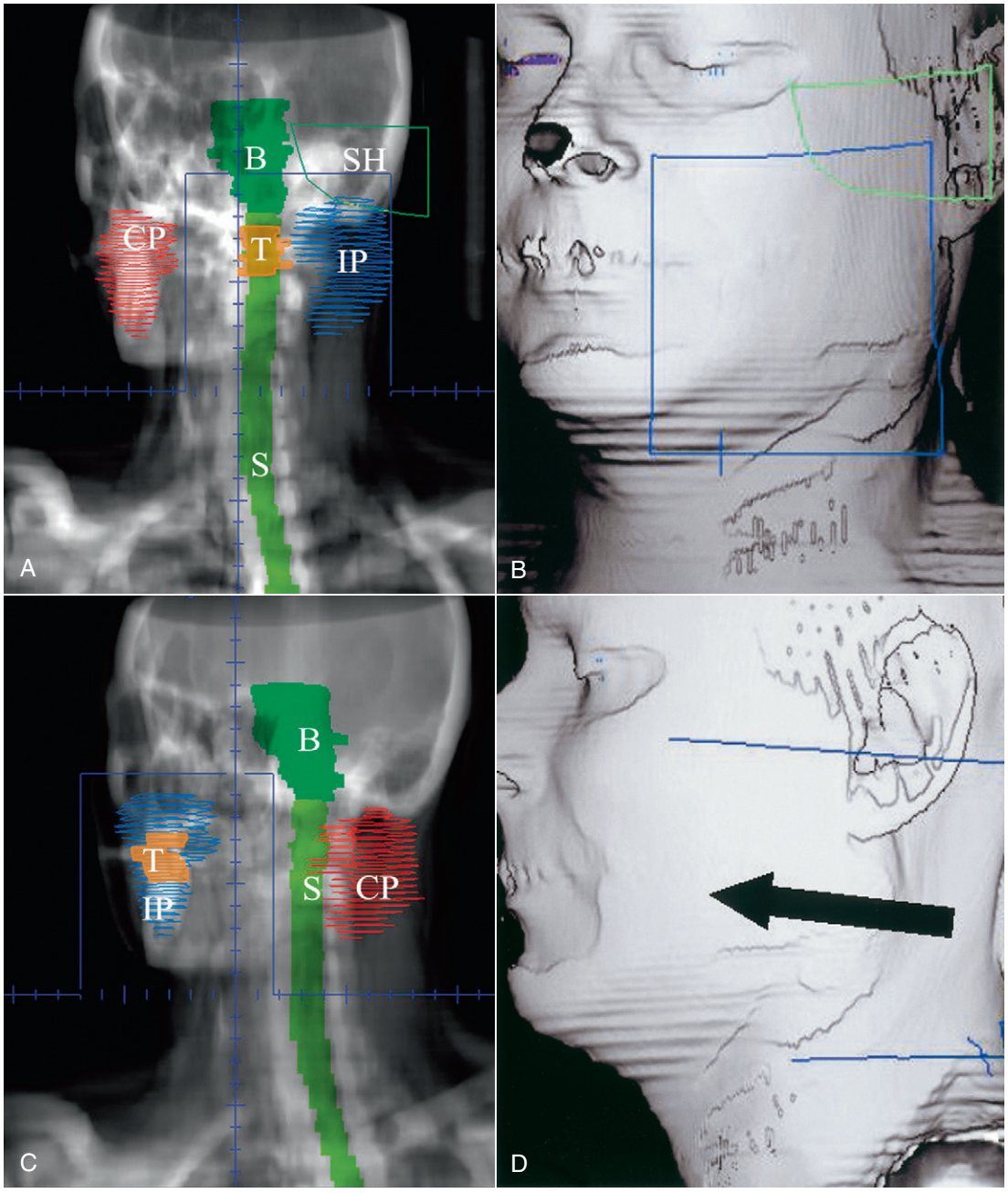

■ **FIGURE 2-85** Radiotherapy plan (computed tomography [CT] based) for a patient with an early squamous cell carcinoma of the left retromolar trigone. The two treatment portals (anterior oblique and posterior oblique) that encompass the primary lesion and the first-echelon regional lymph nodes are illustrated. *B,* brainstem; *CP,* contralateral right parotid; *IP,* ipsilateral left parotid; *S,* spinal cord; *SH,* normal tissue shield; *T,* tumor. **A,** Anterior oblique portal outlined on a digitally reconstructed radiograph. Note that the contralateral parotid is outside of the treatment field. **B,** Anterior oblique portal outlined on a three-dimensional reconstruction of the patient. **C,** Posterior oblique portal outlined on a digitally reconstructed radiograph. Note that the contralateral parotid and the spinal cord are outside of the radiotherapy field. **D,** Radiation beam orientation for posterior oblique portal on a three-dimensional reconstruction of the patient.

through the tumor bed, which can then be loaded with radioactive sources when the patient is transferred to a room with proper radiation protection (afterloading technique). Good 5-year local control rates (as high as 95%) have been achieved for early (T1, T2) oral tongue lesions, but a range of 50% to 95% has been reported. Some authors advocate the importance of ISRT in the radiotherapy management of tongue lesions. However, risks of soft tissue necrosis and osteoradionecrosis of the mandible have been well described with this technique. We now recommend primary surgery for these patients because of absence of risk of osteoradionecrosis of the mandible, good local control rates, good

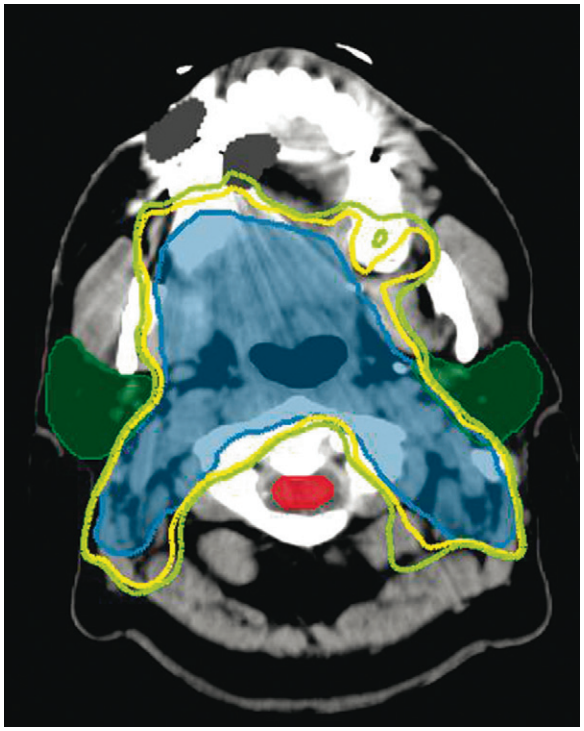

■ **FIGURE 2-86** Intensity-modulated radiation therapy (IMRT) radiation dose (isodose) distribution. Conformal radiotherapy target *(shaded blue)* is shown on an axial planning computed tomography (CT) scan image. Normal parotid glands *(shaded green)* and the spinal cord *(shaded red)* are also shown. Sample isodoses *(bold yellow and light green lines)* are shown conforming around the target while limiting radiation dose to the mandible, parotid glands, and spinal cord.

functional outcomes (speech and swallowing), and available surgical expertise within our institution. Primary radiotherapy for oral tongue carcinomas is an option for patients who are not suitable for primary surgery.

No randomized trials have compared primary radiotherapy with primary surgery for the management of oral cavity carcinomas. Both treatment methods are effective. The principle of therapy for patients with oral cavity SCC is to offer the greatest potential for cure while limiting early and long-term side effects. Treatment effects on normal organ function as well as cosmesis should be taken into account before therapy is recommended. For patients with oral cavity SCC, preservation of normal organ functions such as speech and swallowing and maintenance of salivary flow (parotid gland function) are important considerations. For example, patients with stage I or II retromolar trigone carcinomas can be managed effectively with primary radiotherapy, reserving surgery for salvage of radiotherapy failure. These patients can often be treated with EBRT alone with good local control rates. Use of an ipsilateral radiotherapy technique to avoid the contralateral parotid gland is often possible (see Figure 2-85).

Some patients will not be eligible for radiotherapy. Previous high-dose head and neck radiotherapy limits retreatment radiation doses. Relative contraindications for radiotherapy include extensive bone or cartilage invasion, collagen vascular disorders (particularly scleroderma), previous low-dose radiotherapy, and young age. Some patients will refuse radiotherapy.

Conventional (Standard) Dose-Fractionation Schedules. A course of conventional EBRT is fractionated over a protracted period because the dose per fraction is known to directly correlate with late normal tissue toxicity (side effects occurring after completion of radiotherapy). Standard or conventional fraction sizes range from 1.8 to 2.5 gray (Gy) per fraction. A common North American dose-fractionation schedule delivers a total of 66 to 70 Gy in 2 Gy per fraction over 6.5 to 7 weeks (not including weekends) to gross disease, and 50 Gy in 2 Gy per fraction over 5 weeks to potential occult microscopic disease.

Nonconventional (Altered) Fractionation Schedules. Hyperfractionation is a dose-escalation strategy used to spare late normal tissue toxicity by decreasing the dose per fraction. The total radiotherapy dose can be increased while late toxicity is not increased. Multiple doses per day are used so that the overall duration of treatment is not increased. Acceleration is the delivery of multiple courses of near conventional fraction sizes, but in an overall shorter treatment period. This strategy is used to overcome the potential detrimental effects of cancer cell repopulation that can occur during a course of radiotherapy. The Radiation Therapy Oncology Group (RTOG) conducted a randomized clinical trial that demonstrated the benefit of hyperfractionation and an acceleration variant (concomitant boost), compared with standard fractionation radiotherapy for head and neck SCC (HNSCC), including locally advanced (stage III and IV) carcinomas. A significant improvement in local-regional control for hyperfractionation and concomitant boost schedules was noted compared with the standard fractionation schedule. Two-year local-regional control rates were 54.4% ($P = .045$), 54.5% ($P = .05$), and 46%, respectively. A trend toward increased disease-free survival was noted for the hyperfractionation and accelerated (concomitant boost) schedules. A recent meta-analysis of altered fractionation randomized trials reported a survival benefit of 3.4% and a local-regional control benefit of 6.4% compared with conventional fractionated schedules.

Concurrent Chemotherapy (Chemoradiation). Individual clinical trials have produced conflicting results regarding the benefit of adding chemotherapy to radiotherapy. Despite this, meta-analyses of many randomized clinical trials of radiotherapy combined with neoadjuvant (before radiotherapy), concurrent (during radiotherapy), or adjuvant (after radiotherapy) chemotherapy have shown the most promising results for concurrent chemotherapy. Improvement in overall survival in the range of 8% to 10% has been demonstrated for locally advanced HNSCC. Cisplatin is the most active single agent; therefore, platinum-based regimens are most commonly used in the treatment of HNSCCs. A typical concurrent chemoradiation regimen combines 70 Gy

delivered in 2-Gy fractions over 7 weeks with single-agent cisplatin (100 mg/m^2) on days 1, 22, and 43 of the radiation schedule. Chemotherapy in combination with altered fractionation radiotherapy is being investigated in clinical trials.

No published randomized clinical trials have compared concurrent chemotherapy and radiation versus altered fractionation radiation schedules in patients with stage III and IV HNSCC. It should be noted that patients with oral cavity carcinomas make up a minority of the studied population of HNSCC patients managed with either approach. Both treatment approaches may be considered for individual patients with locally advanced carcinoma of the oral cavity, particularly those who are not candidates for surgery. However, chemoradiation is preferable for patients with advanced nodal disease. Both treatment strategies are associated with increased side effects.

Combined Surgery and Radiotherapy. Combined surgery and radiotherapy may improve local-regional control for patients who are candidates for both treatments. Planned combined therapy requires a coordinated multidisciplinary approach between the surgeon and the radiation oncologist. An example of planned combined therapy is the integration of neck dissection post radiotherapy for lymph nodes greater than 3 cm when the primary lesion is treated with radiation. Lymph nodes larger than 3 cm are suboptimally treated with radiotherapy alone.

Adjuvant Radiotherapy. Patients treated with primary surgery may require postoperative radiotherapy. Adjuvant radiotherapy is recommended based on operative or pathologic findings of the surgically removed primary lesion or regional lymph nodes. Postoperative radiotherapy is indicated for positive or close surgical resection margins, multiple positive lymph nodes, or extracapsular lymph node extension. Postoperative radiotherapy is also considered for intraoperative tumor rupture or cut-through, intraoperative revision of initially positive margins, presence of perineural invasion, presence of lymphatic or vascular involvement, and preoperative incisional biopsy of the neck. Patients with large nodes (>3 cm) and advanced primary lesions with cortical bone, skin, or muscle involvement may be managed with planned combined therapy (see section on combined surgery and radiotherapy). Preoperative radiotherapy indications are similar to those for postoperative radiotherapy.

Adjuvant Chemotherapy in Combination With Radiotherapy. Two collaborative groups have reported important results of large phase III trials investigating the addition of concurrent cisplatin to postoperative radiotherapy. The European Organization for Research and Treatment of Cancer (EORTC) radiotherapy group randomized high-risk HNSCC patients to receive a postoperative radiation dose of 6600 cGy in 6.5 weeks alone or radiation plus three cycles of concurrent cisplatin (100 mg/m^2). Estimated 5-year disease-free survival (36% vs. 47%) and overall survival (40% vs. 53%) favored the combined chemotherapy and radiotherapy arm. The RTOG/Intergroup conducted a similar trial in high-risk patients. Improvement in the estimated 2-year local-regional control (72% vs. 82%) favored chemoradiation. Disease-free survival was prolonged, but not overall survival with chemoradiation.

Molecular Targeted Agents in Combination With Radiation. The strategy of combining radiation with molecular targeted agents is an area of active preclinical and clinical research. These agents are typically antibodies or small molecules that modulate important signal transduction pathways. Molecular targeted agents are usually cytostatic on their own but may enhance the radiation response in tumors. The ideal molecular targeted agent enhances radiation response but does not increase radiation side effects that are already at or near clinically acceptable tolerance levels. An example of an important radiation response signaling pathway is the EGFR pathway. Cetuximab, an anti-EGFR antibody, in combination with radiation for HNSCC, has been reported to improve local-regional control and survival compared with radiation alone, without significantly increasing acute mucosal toxicity.

Palliative Radiotherapy. Patients who are not candidates for curative therapies because of very advanced incurable cancers, significant comorbid illnesses, or refusal of surgery may be candidates for palliative radiotherapy. The objective of palliative treatment should be to alleviate symptoms such as pain or bleeding. Particular attention should be paid to limiting morbidity from treatment.

Therapeutic Radiation Complications. Along with the therapeutic effects of radiation are dose-dependent side effects (Box 2-15). Some of these are reversible, whereas others are not (Figures 2-87 to 2-90). Radiation-induced mucositis and ulcers and the accompanying pain, xerostomia, loss of taste, and dysgeusia are common side effects. Radiation mucositis is a reversible condition that begins 1 to 2 weeks after the

BOX 2-15 THERAPEUTIC RADIATION SIDE EFFECTS

TEMPORARY SIDE EFFECTS
Mucosal ulcers/mucositis
Pain
Taste alterations
Candidiasis
Dermatitis
Erythema
Focal alopecia

PERMANENT SIDE EFFECTS
Xerostomia
Cervical caries
Osteoradionecrosis
Telangiectasias
Epithelial atrophy
Focal alopecia
Focal hyperpigmentation

start of therapy and ends several weeks after termination of therapy. Oral candidiasis often accompanies the mucositis. Use of antifungals, chlorhexidine rinses, or salt-soda rinses helps reduce morbidity.

Permanent damage to salivary gland tissue situated in the beam path may produce significant levels of xerostomia. Some recovery is often noted, especially at lower radiation levels. Xerostomia is frequently a patient's chief complaint during the postradiation period. Frequent use of water or artificial saliva is of minimal benefit to these patients. Pilocarpine, used during the course of radiation, may provide some protective measure of salivary function. With the dryness also comes the potential for the development of cervical, or so-called radiation, caries. This problem can be minimized with regular follow-up dental care and scrupulous oral hygiene. Custom-fitted soft trays are made for the fully or partially dentate patient to permit the nightly application of neutral pH fluoride directly to the teeth. This treatment is initiated at the start of cancer treatment and continues for the remainder of the patient's life. It has been shown to significantly reduce the incidence of cervical caries and thereby the need for future dental extractions.

Skin in the path of the radiation beam also suffers some damage. Alopecia is temporary at lower radiation levels but permanent at the higher levels required in the treatment of SCC. Skin erythema is temporary, but the telangiectasias and atrophy that follow are permanent. Cutaneous pigmentation in the line of therapy is also a late complication, and it, too, may be permanent.



■ **FIGURE 2-87 Radiation mucositis.** Note erythema and multiple mucosal ulcers.



■ **FIGURE 2-88** Postradiation scar in the floor of mouth, the site of the patient's primary squamous cell carcinoma.



■ **FIGURE 2-89** Postradiation telangiectasias in buccal mucosa.

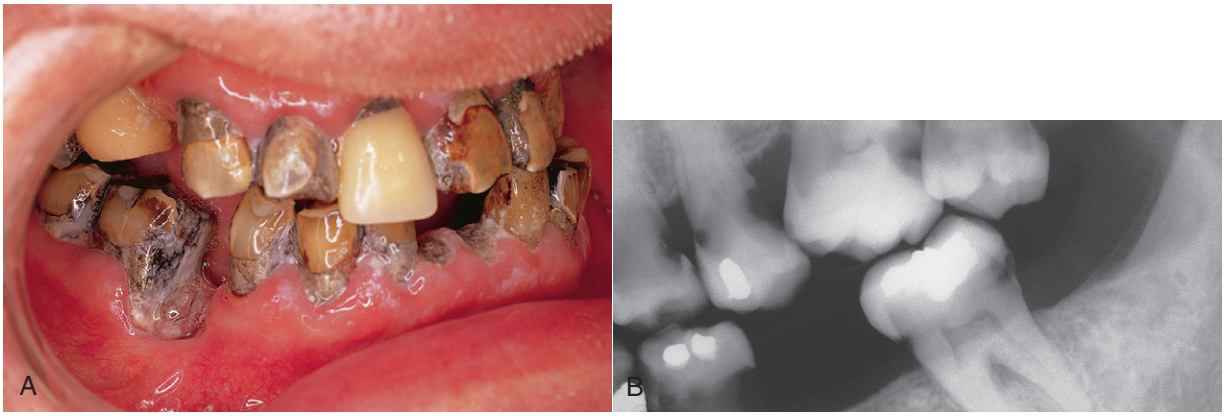

■ **FIGURE 2-90 A** and **B,** Radiation-associated cervical caries.



■ **FIGURE 2-91** Osteoradionecrosis of the lingual mandible precipitated by trauma.

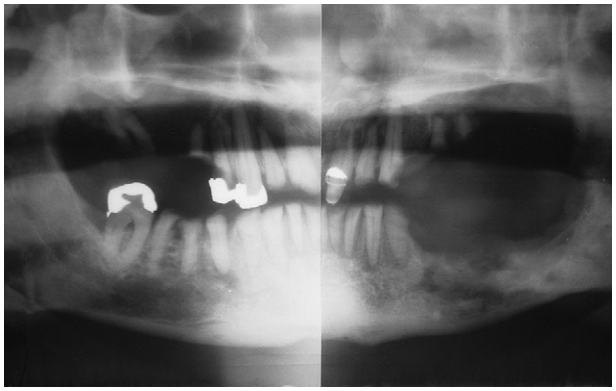

■ **FIGURE 2-92** Osteoradionecrosis of the mandible.

A more insidious problem lies in the damage that radiation causes to bone, which may result in osteonecrosis (Figures 2-91 and 2-92). Radiation apparently has deleterious effects on osteocytes, osteoblasts, and endothelial cells, causing reduced capacity of bone to recover from injury. Injury may come in the form of trauma (such as extractions), advancing periodontal disease, and periapical inflammation associated with nonvital teeth. Once osteonecrosis occurs, varying amounts of bone (usually in the mandible) are lost. This may be an area as small as a few millimeters to as large as half the jaw or more. The most important factor responsible for osteonecrosis is the amount of radiation directed through bone on the path to the tumor. Oral health is also of considerable significance. Poor nutrition and chronic alcoholism appear to be influential in the progression of this complication. Conservative surgical removal of necrotic bone may assist in the healing process. Also, if available, the use of a hyperbaric oxygen chamber may provide patients with a healing advantage.

Because osteonecrosis is a danger that is always present after radiation, tooth extractions should be avoided after therapy. If absolutely necessary, tooth removal should be performed as atraumatically as possible, using antibiotic coverage. It is preferable to commit to a treatment plan that schedules tooth removal before radiation therapy begins. Initial soft tissue healing before therapy is begun reduces the risk of nonhealing of the extraction sites. Prosthetic devices such as dentures and partial dentures, if carefully constructed and monitored, can be worn without difficulty. Xerostomia does not seem to cause difficulty in the wearing of these prostheses. Continued careful surveillance of the patient's oral health, during and after radiation therapy, helps keep complications to an acceptable minimum.

Prognosis. Similar to other cancers, the prognosis for patients with oral SCC is dependent on both the histologic subtype (grade) and the clinical extent (stage) of the tumor. Of the two, the clinical stage is significantly more important. Other, more abstract factors that may influence the clinical course include the patient's age, gender, general health, immune system status, and mental attitude.

Grading of a tumor is the microscopic determination of the level of differentiation of tumor cells. Well-differentiated lesions generally have a less aggressive biological course than poorly differentiated lesions. Of all SCC histologic subtypes, the best-differentiated lesion, verrucous carcinoma, has the most favorable prognosis. Less-differentiated lesions have a correspondingly poorer prognosis.

The most important indicator of prognosis is the clinical stage of the disease. Once metastasis to cervical nodes has occurred, the 5-year survival rate is reduced by approximately half. The overall 5-year survival rate for oral SCC ranges from 45% to 50%. If the neoplasm is small and localized, the 5-year cure rate may be as high as 60% to 70% (lower lip lesions may rate as high as 90%). However, if cervical metastases are present at the time of diagnosis, the survival figures drop precipitously to about 25%.

The TNM system mentioned earlier for the clinical staging of oral SCC was devised to provide clinical uniformity. *T* is a measure of the primary tumor size, *N* is an estimation of regional lymph node metastasis, and *M* is a determination of distant metastases (Box 2-16; Figure 2-93). Use of this system allows more meaningful comparison of data from different institutions and helps guide therapeutic decisions. As the clinical stage advances from I to IV, the prognosis worsens (Table 2-6).

Another factor that comes into play in the overall prognosis of oral cancer is increased risk for development of a second primary lesion. The risk of a second primary lesion in the head and neck region or upper airways is about 5% per year for the first 7 years following the initial tumor. The mechanism for this finding is not entirely known. It was thought for several decades that the mucosa lining the entire mouth and the upper aerodigestive tract was exposed to similar carcinogens from tobacco and alcohol and was in effect "condemned mucosa." This so-called field cancerization theory was used to explain the relatively high incidence of new primary tumors in patients who had oral or oropharyngeal cancer. Recently, the field cancerization theory has been called into question with the finding that many second

BOX 2-16 TNM CLINICAL STAGING SYSTEM FOR ORAL SQUAMOUS CELL CARCINOMA

T—Tumor
- T1: tumor <2 cm
- T2: tumor 2-4 cm
- T3: tumor >4 cm
- T4: tumor invades deep subjacent structures

N—Nodes
- N0: no palpable nodes
- N1: single ipsilateral node <3 cm
- N2A: single ipsilateral node 3-6 cm
- N2B: multiple ipsilateral nodes ≤6 cm
- N2C: contralateral or bilateral nodes ≤6 cm
- N3: node >6 cm

M—Metastasis
- M0: no distant metastasis
- M1: distant metastasis

TABLE 2-6 TNM CLINICAL STAGING OF ORAL SQUAMOUS CELL CARCINOMA

Stage	TNM Designation
I	T1, N0, M0
II	T2, N0, M0
III	T3, N0, M0
	T1-3, N1, M0
IV	T4, N0, M0
	T4, N1, M0
	T any, N2-3, M0
	T any, N any, M1

primary lesions, including some at unusual anatomic sites in the head and neck and lungs of patients with a history of oral cancer, are genetically very similar, if not identical, to the original tumor. This suggests that these second tumors may not in fact represent a new malignancy, but rather a metastasis or recurrence of the original tumor elsewhere. Because many of the second tumors develop in sites not normally connected anatomically to the primary tumor by known lymphatic pathways, it has been proposed that intraepithelial migration of malignant cells may occur. It is not yet clear which scenario is correct, or if indeed both mechanisms occur in different settings. It is perhaps more likely that in some patients secondary lesions do represent new primary tumors, but in others the secondary tumors may represent recurrent or metastatic disease.

Carcinoma of the Maxillary Sinus

Etiology. Malignancies of the paranasal sinuses occur most commonly in the maxillary sinus. The cause is unknown, although squamous metaplasia of sinus epithelium associated with chronic sinusitis and oral antral fistulas is believed by some investigators to be a predisposing factor.

Clinical Features. This is a disease of older age, affecting predominantly patients older than age 40. Men are generally afflicted more than women. Past history in these patients frequently includes symptoms of sinusitis. As the neoplasm progresses, a dull ache in the area occurs, with eventual development of overt pain. Specific signs and symptoms referable to oral structures are common, especially when the neoplasm has its origin in the sinus floor. As the neoplasm

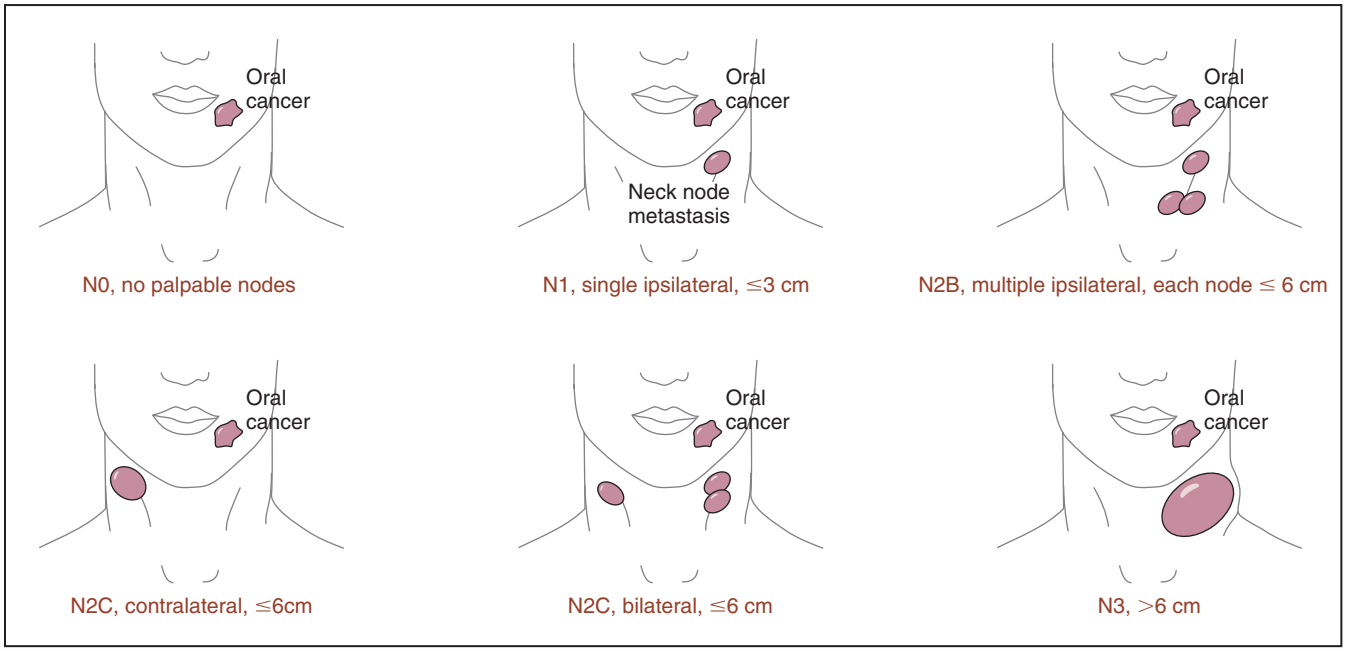

■ **FIGURE 2-93** Lymph nodes in tumor, node, metastasis (TNM) staging (N2A, single ipsilateral node 3 to 6 cm).

extends toward the apices of the maxillary posterior teeth, referred pain may occur. Toothache, which actually represents neoplastic involvement of the superior alveolar nerve, is not an uncommon symptom in patients with maxillary sinus malignancies. In ruling out dental disease by history and clinical tests, it is imperative that the dental practitioner be aware that sinus neoplasms may present through the alveolus. Without this suspicion, unfortunate delays in definitive treatment may occur. Other clinical signs of invasion of the alveolar process include recently acquired malocclusion, displacement of teeth, and vertical mobility of teeth (teeth undermined by neoplasm). Failure of a socket to heal after an extraction may be indicative of tumor involvement. Paresthesia should always be viewed as an ominous sign and should cause the clinician to consider intraosseous malignancy. Occasional maxillary sinus cancers may present as a palatal ulcer and mass representing extension through the bone and soft tissue of the palate (Figures 2-94 and 2-95).

Histopathology. Of malignancies that originate in the maxillary sinus, squamous cell carcinoma is the most common histologic type. These lesions are generally less differentiated than those occurring in oral mucous membranes. Infrequently, adenocarcinomas arising presumably from mucous glands in the sinus lining may be seen.

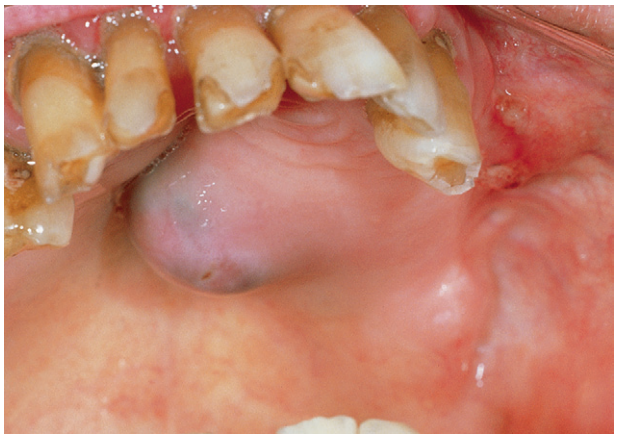

■ **FIGURE 2-94** Carcinoma of the maxillary sinus presenting through the palate.

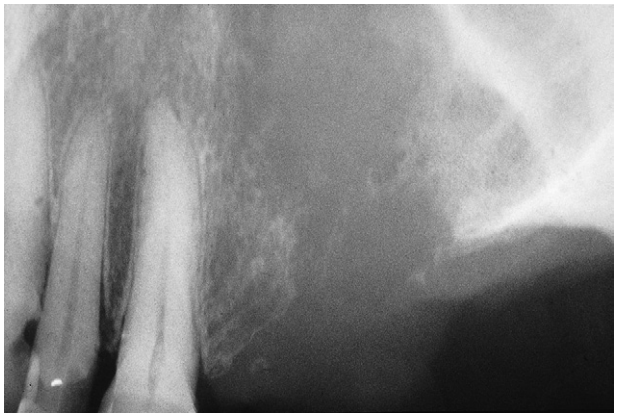

■ **FIGURE 2-95** Carcinoma of the maxillary sinus producing ill-defined maxillary radiolucency.

Diagnosis. From a clinical standpoint, when oral signs and symptoms appear to be related to antral carcinoma, a dental origin must be ruled out. This is best accomplished by the dental practitioner because of familiarity with normal tooth-jaw relationships and experience in interpretation of vitality tests. Other clinical considerations related to malignancies in the age group in which antral carcinomas occur are metastatic disease and plasma cell myeloma. Osteosarcoma and other, less common sarcomas that are usually found in a younger age group might be included. Palatal involvement should also cause the clinician to consider adenocarcinoma of minor salivary gland origin, lymphoma, and SCC.

Treatment and Prognosis. Maxillary sinus carcinomas are generally treated with surgery or radiation or both. A combination of the two seems to be somewhat more effective than either modality alone. Radiation is often completed first, with surgical resection following. Chemotherapy used in conjunction with radiation has been somewhat successful.

In any event, the prognosis is only fair at best. Cure is directly dependent on the clinical stage of the disease at the time of initial treatment. Compared with oral lesions, sinus lesions are discovered at a more advanced stage because of delays in seeking treatment and delays in making a definitive diagnosis. The anatomy of the area also influences the prognosis. The 5-year survival rate is about 25%. If the disease is discovered early, the likelihood of survival increases.

Basal Cell Carcinoma of the Skin

Basal cell carcinoma is the most prevalent cancer of the skin as well as of the head and neck. The lesion is most often encountered in older patients on non–hair-bearing skin. Men are more commonly affected than women, presumably because of greater cumulative sun exposure. This malignancy arises from basal cells of the skin. A vast majority of basal cell carcinomas occur on sun-exposed skin. Except in very rare instances, basal cell carcinoma does not occur on mucous membranes.

Individuals at increased risk for the development of basal cell carcinoma are those with lighter natural skin pigmentation, those with a long history of chronic sun exposure, and those with one of several predisposing hereditary syndromes. Among the latter is nevoid basal cell carcinoma syndrome, in which individuals have multiple odontogenic keratocysts, skeletal abnormalities, and numerous basal cell carcinomas.

Clinical Features. Basal cell carcinoma presents as an indurated pearly papule or nodule with telangiectatic vessels coursing over its surface (Figures 2-96 and 2-97). With time,

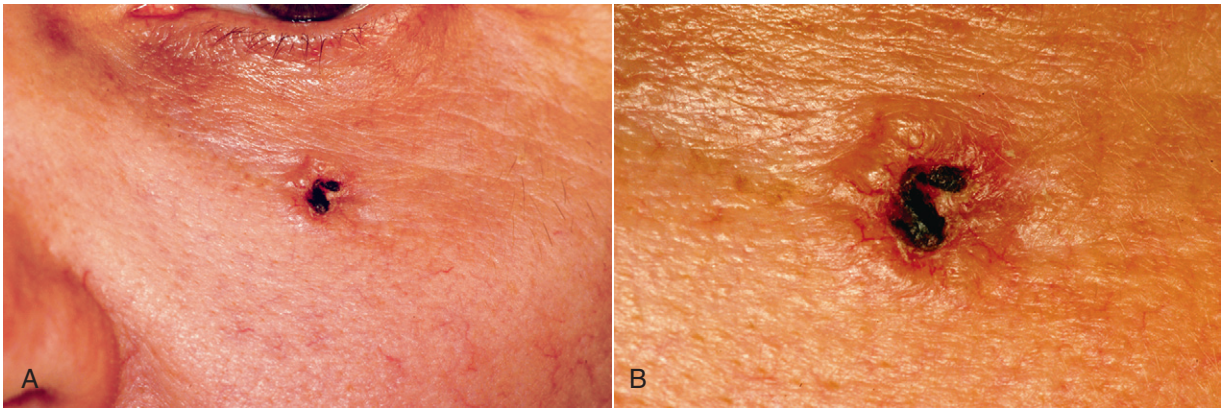

■ **FIGURE 2-96 A** and **B,** Basal cell carcinoma.

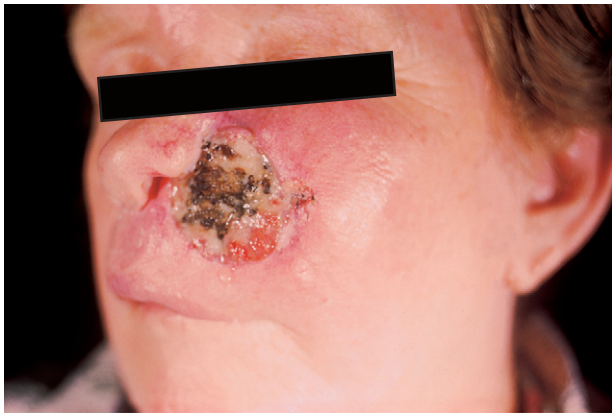

■ **FIGURE 2-97** Basal cell carcinoma.

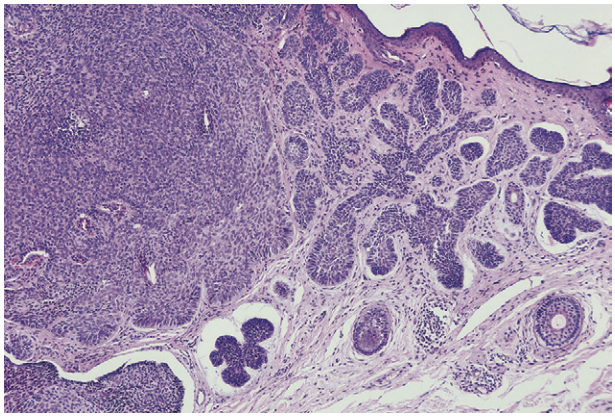

■ **FIGURE 2-98 Basal cell carcinoma.** Note solid tumor *(left)* and nested tumor *(right)*.

the center of the tumor becomes ulcerated and crusted. If untreated, the tumor exhibits a slow but relentless locally destructive nature. Other clinical forms may be seen on occasion. The pigmented form of basal cell carcinoma presents in a manner similar to that of the noduloulcerative type, with the addition of melanin pigmentation within or at the periphery. The superficial form presents as a scaly erythematous lesion flush with the skin surface, occasionally appearing as an atrophic scar–like process. The fibrosing form of basal cell carcinoma presents as an indurated yellowish plaque that may be slightly depressed or flat, resembling a slow or insidiously enlarging scar in the absence of trauma. Because basal cell carcinomas are generally slow growing and are rarely metastatic, the prognosis is very good.

Histopathology. In basal cell carcinoma, nests and cords of cuboidal cells arise from the region of the epidermal basal cells (Figure 2-98). Neoplastic cells around the periphery of the invading nests and strands are usually palisaded and often columnar. In some infiltrative basal cell carcinomas, tiny infiltrative nests are found in a fibroblastic stroma. This has been described as an aggressive growth pattern and may portend a more aggressive clinical course.

Treatment. Various surgical procedures (standard scalpel surgery, cryosurgery, electrosurgery, Mohs' microscopically guided surgery), and irradiation can be used to treat basal cell carcinoma. The type of treatment depends on the size and location of the neoplasm, as well as the experience and training of the clinician.

Squamous Cell Carcinoma of the Skin

In the vast majority of cases, squamous cell carcinoma of the face and lower lip arises from epidermal keratinocytes that have been damaged by sunlight. Unlike basal cell carcinoma, this neoplasm has significant potential to metastasize to regional lymph nodes and beyond. As with basal cell carcinoma, several factors contribute to the etiology of SCC; however, the chief factor remains repeated and chronic damage caused by sunlight. The highest incidence is noted in fair-skinned individuals after long-term exposure to sunlight. In addition, carcinogens such as tars, oils, and arsenicals; exposure to x-rays; and the presence of skin diseases that cause scarring, such as severe burns and discoid lupus erythematosus (DLE), predispose to malignant transformation of the epithelium.

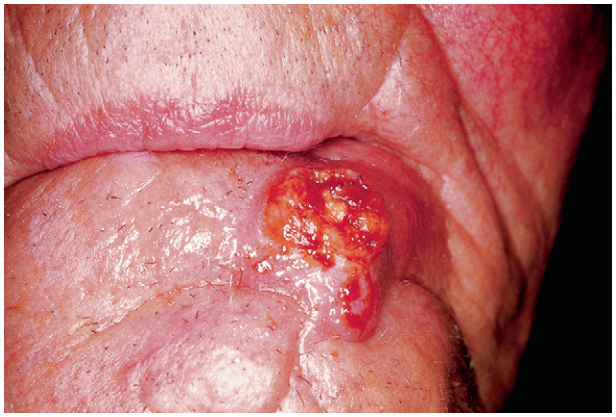

■ **FIGURE 2-99** Squamous cell carcinoma.

Clinical Features. The clinical course is insidious, evolving over months to years. A central ulcer with slightly raised indurated margins and surrounding erythema eventually forms. Lesions may occasionally appear as verrucous growths, papules, or plaques. Areas of the face most commonly affected include the lower lip, tip of the ear, forehead, and infraorbital/nasal bridge region (Figure 2-99). Lesions are firm and indurated, reflecting tumor infiltration of adjacent tissues.

Lesions that arise within actinic keratoses are less aggressive than those arising de novo or in some sun-protected locations. Squamous cell carcinomas arising at sites of irradiation, burns, or chronic degenerative skin disorders are more aggressive than their sun-exposure counterparts. A squamous cell carcinoma arising in solar cheilitis tends to invade and metastasize at an earlier point than its counterpart in sun-damaged skin. Intraoral squamous cell carcinomas are far more aggressive than cutaneous tumors.

Histopathology. This tumor consists of atypical keratinocytes that invade the dermis and beyond. As with intraoral squamous cell carcinoma, cytologic features include an increased nuclear-cytoplasmic ratio, nuclear hyperchromatism, individual cell keratinization, tumor giant cells, atypical mitotic figures, and an increased mitotic rate.

Treatment. The mainstay of therapy remains excision. The mode of excision, however, depends on the size and location of the lesion. Larger carcinomas may be treated with wide excision, often with reconstructive grafts, or irradiation therapy. Microscopically directed surgery (Mohs' surgery) may be used because of its advantage in tissue conservation. Nonsurgical options, such as chemotherapy and radiation therapy, are occasionally used to treat patients under special circumstances. The overall 5-year cure rate for squamous cell carcinoma of the skin is approximately 90%.

BIBLIOGRAPHY

Infectious Diseases

Barry PM, Klausner JD: The use of cephalosporins for gonorrhea: the impending problem of resistance. Expert Opin Pharmacother 10:555–577, 2009.

Bonifaz A, Vazquez-Gonzalez D: Sporotrichosis: an update. G Ital Dermatol Venereol 145:659–673, 2010.

Buchanan JA, Cedro M, Mirdin A, et al: Necrotizing stomatitis in the developed world. Clin Exp Dermatol 31:372–374, 2006.

Centers for Disease Control: Morbidity and mortality report: congenital syphilis, New York City, 1986-1988. Arch Dermatol 126:288–289, 1990.

Centers for Disease Control: Summaries of notifiable diseases in the United States. MMWR 39:10, 1991.

Chiandussi S, Luzatti R, Tirelli G, et al: Cancrum oris in developed countries. Aging Clin Exp Res 21:475–477, 2009.

Chimenos Kustner E, Pascual Cruz M, Pinol Dansis C, et al: Lepromatous leprosy: a review and case report. Med Oral Patol Oral Cir Bucal 11:E474–E479, 2006.

Cornely OA, Vehreschild JJ, Ruping MJ: Current experience in treating invasive zygomycosis with posaconazole. Clin Microbiol Infect 15(Suppl 5):77–81, 2009.

Daya M, Nair V: Free radial forearm flap lip reconstruction: a clinical series and case reports of technical refinements. Ann Plast Surg 62:361–367, 2009.

Economopoulou P, Laskaris G, Kittas C: Oral histoplasmosis as an indicator of HIV infection. Oral Surg Oral Med Oral Pathol Oral Radiol Endod 66:203–206, 1998.

Enwonwu CO, Falkler WA, Idibge EO, et al: Noma (cancrum oris): questions and answers. Oral Dis 5:144–149, 1999.

Ficarra G, Carlos R: Syphilis: the renaissance of an old disease with oral implications. Head Neck Pathol 3:195–206, 2009.

Frieden TR, Sterling T, Pablos-Mendez A, et al: The emergence of drug-resistant tuberculosis in New York City. N Engl J Med 328:521–532, 1993.

Ghanem KG, Gikles JA, Zenilman JM: Fluoroquinolone-resistant *Neisseria gonorrhoeae*: the inevitable epidemic. Infect Dis Clin North Am 19:351–365, 2004.

Gobel M, Iseman MD, Madsen LA: Treatment of 171 patients with pulmonary tuberculosis resistant to isoniazid and rifampin. N Engl J Med 328:527–532, 1993.

Haile M, Kallenius G: Recent developments in tuberculosis vaccines. Curr Opin Infect Dis 18:211–215, 2005.

Hasan A, Schinnick T, Mizushima Y, et al: Defining a T-cell epitope within HSP 65 in recurrent aphthous stomatitis. Clin Exp Immunol 128:318–325, 2002.

Kakisi OK, Kechagia AS, Kakisis IK, et al: Tuberculosis of the oral cavity: a systematic review. Eur J Oral Sci 118:103–109, 2010.

Ladizinski B, Shannon EJ, Sanchez MR, et al: Thalidomide and analogues: potential for immunomodulation of inflammatory and neoplastic dermatologic disorders. J Drugs Dermatol 9:814–826, 2010.

Lalloo UG, Naidoo R, Ambaram A: Recent advances in the medical and surgical treatment of multi-drug resistant tuberculosis. Curr Opin Pulm Med 12:179–185, 2006.

Leao Gueiros JC, Porter SR: Oral manifestations of syphilis. Clinics 61:161–166, 2006.

Marques SA: Fungal infections of the mucous membranes. Dermatol Ther 23:243–250, 2010.

McGonagle D, Aziz A, Dickie LJ, et al: An integrated classification of pediatric inflammatory diseases, based on the concepts of autoinflammation and the immunologic disease continuum. Pediatr Res 65(5 Pt 2):38R–45R, 2009.
Murray LA, Kramer MS, Hesson DP, et al: Serum P amyloid ameliorates radiation-induced oral mucositis and fibrosis. Fibrogenesis Tissue Repair 3:11–20, 2010.
Naik NH, Russo TA: Bisphosphonate-related osteonecrosis of the jaw: the role of Actinomyces. Clin Infect Dis 49:1729–1732, 2009.
Scheinfeld N: A review of the new antifungals: posaconazole, micafungin, and anidulafungin. J Drugs Dermatol 6:1249–1251, 2007.
Sedghizadeh PP, Kumar SK, Gorur A, et al: Microbial biofilms in osteomyelitis of the jaw and osteonecrosis of the jaw secondary to bisphosphonate therapy. J Am Dent Assoc 140:1259–1265, 2009.

Immunologic Diseases

Abdollahi M, Rahimi R, Radfar M: Current opinion on drug-induced oral reactions: a comprehensive review. J Contemp Dent Pract 9:1–15, 2008.
Alli N, Gur G, Yalcin B, et al: Patient characteristics in Behcet disease: a retrospective analysis of 213 Turkish patients during 2001-4. Am J Clin Dermatol 10:411–418, 2009.
Alpsoy E, Yilmaz E, Basaran E: Interferon therapy for Behçet's disease. J Am Acad Dermatol 31:617–619, 1994.
Aslanzadeh J, Heim K, Espy M, et al: Detection of HSV-specific DNA in biopsy tissue of patients with erythema multiforme by polymerase chain reaction. Br J Dermatol 126:19–23, 1992.
Byrd JA, Davis MD, Bruce AJ, et al: Response of oral lichen planus to topical tacrolimus in 37 patients. Arch Dermatol 140:1508–1512, 2004. Erratum in Arch Dermatol 141:370, 2005.
Calamia KT, Wilson FC, Icen M, et al: Epidemiology and clinical characteristics of Behcet's disease in the US: a population-based study. Arthritis Rheum 61:600–604, 2009.
Chudomirova K, Abadjieva T, Yankova R: Clinical tetrad of arthritis, urethritis, conjunctivitis and mucocutaneous lesions (HLA-B27-associated spondyloarthropathy, Reiter syndrome): report of a case. Dermatol Online J 14:4, 2008.
Devaney K, Travis W, Hoffman G, et al: Interpretation of head and neck biopsies in Wegener's granulomatosis. Am J Surg Pathol 14:555–564, 1990.
Edge S, et al: AJCC Cancer Staging Manual, New York, 2010, Springer.
Femiano F, Buonaiuto C, Gombos F, et al: Pilot study on recurrent aphthous stomatitis (RAS): a randomized placebo-controlled trial for the comparative therapeutic effects of systemic prednisone and systemic montelukast in subjects unresponsive to topical therapy. Oral Surg Oral Med Oral Pathol Oral Radiol Endod 109:402–407, 2010.
Gorsky M, Epstein JB, Rabinstein S, et al: Topical minocycline and tetracycline rinses in treatment of recurrent aphthous stomatitis: a randomized cross-over study. Dermatol Online J 13:1, 2010.
Hamuryudan V, Yurdakul S, Serdaroglu S, et al: Topical alpha interferon in the treatment of oral ulcers in Behçet's syndrome: a preliminary report. Clin Exp Rheumatol 8:51–54, 1990.
Harty S, Fleming P, Rowland M, et al: A prospective study of the oral manifestations of Crohn's disease. Clin Gastroenterol Hepatol 3:886–891, 2005.
Hoffman G, Kerr G, Leavitt R, et al: Wegener's granulomatosis: an analysis of 158 patients. Ann Intern Med 116:488–498, 1992.
Islam MN, Cohen DM, Ojha J, et al: Chronic ulcerative stomatitis: diagnostic and management challenges—four new cases and review of literature. Oral Surg Oral Med Oral Pathol Oral Radiol Endod 104:194–203, 2007.
Jurge S, Kuffer R, Scully C, et al: Mucosal disease series. Number VI: recurrent aphthous stomatitis. Oral Dis 12:1–21, 2006.
Kallenberg CG: Antineutrophil cytoplasmic antibodies (ANCA) and vasculitis. Clin Rheumatol 9(Suppl):132–135, 1990.
Khandwala A, VanInwegen RG, Alfano MC: 5% amlexanox oral paste, a new treatment for recurrent minor aphthous ulcers. I. Clinical demonstration of acceleration of wound healing and resolution of pain. Oral Surg Oral Med Oral Pathol Oral Radiol Endod 83:222–230, 1997.
Kohrt H, Advani RE: Extranodal killer T-cell lymphoma: current concepts in biology and treatment. Leuk Lymphoma 50:1173–1184, 2009.
Landesberg R, Fallon M, Insel R: Alterations of T helper/inducer and T suppressor/inducer cells in patients with recurrent aphthous ulcers. Oral Surg Oral Med Oral Pathol 69:205–208, 1990.
Lo Muzio L, della Valle A, Mignogna MD, et al: The treatment of oral aphthous ulceration or erosive lichen planus with topical clobetasol propionate in three preparations: a clinical and pilot study on 54 patients. J Oral Pathol Med 30:611–617, 2001.
Lozada-Nur F, Miranda C, Maliksi R: Double-blind clinical trial of 0.05% clobetasol propionate ointment in orabase and 0.05% fluocinonide ointment in orabase in the treatment of patients with oral vesiculoerosive diseases. Oral Surg Oral Med Oral Pathol 77:598–604, 1994.
MacPhail L, Greenspan D, Feigal D, et al: Recurrent aphthous ulcers in association with HIV infection. Oral Surg Oral Med Oral Pathol 71:678–683, 1991.
Mignogna MD, Russo LL, Fedele S: Gingival involvement of oral lichen planus in a series of 700 patients. J Clin Periodontol 32:1029–1033, 2005.
Miller R, Gould A, Bernstein M: Cinnamon-induced stomatitis venenata. Oral Surg Oral Med Oral Pathol 73:708–716, 1992.
Ng PP, Sun YJ, Tan HH, et al: Detection of herpes virus genomic DNA in various subsets of erythema multiforme by polymerase chain reaction. Dermatology 207:349–353, 2003.
O'Duffy J: Behçet's syndrome. N Engl J Med 323:326–327, 1990.
Orme R, Nordlund J, Barich L, et al: The MAGIC syndrome (mouth and genital ulcers with inflamed cartilage). Arch Dermatol 126:940–944, 1990.
Pedersen A: Recurrent aphthous ulceration: virologic and immunologic aspects. APMIS Suppl 37:1–37, 1993.
Phelan J, Eisig S, Freedman P, et al: Major aphthous-like ulcers in patients with AIDS. Oral Surg Oral Med Oral Pathol 71:68–72, 1991.
Plemons J, Rees T, Zachariah N: Absorption of a topical steroid and evaluation of adrenal suppression in patients with erosive lichen planus. Oral Surg Oral Med Oral Pathol 69:688–693, 1990.
Reimold AM: TNF-alpha as a therapeutic target: new drugs, more applications. Curr Drug Targets Inflamm Allergy 1:377–392, 2002.
Salisbury CL, Budnick SD, Li S: T-cell receptor gene rearrangement and CD30 immunoreactivity in traumatic ulcerative granuloma with stromal eosinophilia of the oral cavity. Am J Clin Pathol 132:722–727, 2009.
Scully C: Aphthous ulceration. N Engl J Med 355:165–172, 2006.
Scully C, Hodgson T: Recurrent oral ulceration: aphthous-like ulcers in periodic syndromes. Oral Surg Oral Med Oral Pathol Oral Radiol Endod 106:845–852, 2008.
Scully C, Sonis S, Diz PD: Oral mucositis. Oral Dis 12:229–241, 2006.
Shakeri R, Sotoudehmanesh R, Amiri A, et al: Gluten sensitive enteropathy in patients with recurrent aphthous stomatitis. BMC Gastroenterol 9:44, 2009.
Shetty SR, Chatra L, Shenai P, et al: Stevens-Johnson syndrome: as case report. J Oral Sci 52:343–346, 2010.
Ship JA: Recurrent aphthous stomatitis: an update. Oral Surg Oral Med Oral Pathol Oral Radiol Endod 81:141–147, 1996.

Sobin LH, Gospodarowicz MK, Wittekind CH, editors: TNM classification of malignant tumors, 7th edition, Oxford, 2009, Wiley-Blackwell.
Solomon LW: Chronic ulcerative stomatitis. Oral Dis 14:383–389, 2008.
Sonis ST: Mucositis: the impact, biology and therapeutic opportunities of oral mucositis. Oral Oncol 45:1015–1020, 2009.
Sonis S: New thoughts on the initiation of mucositis. Oral Dis 16:597–600, 2010.
Sonis ST: Pathobiology of oral mucositis: novel insights and opportunities. J Support Oncol 5(9 Suppl 4):3–11, 2007.
Spellberg B, Walsh TJ, Kontoyiannis DP, et al: Recent advances in the management of mucormycosis: from bench to bedside. Clin Infect Dis 48:1743–1751, 2009.
Stasia MJ, Li XJ: Genetics and immunopathology of chronic granulomatous disease. Semin Immunopathol 30:209–235, 2008.
Weeda LW, Coffey SA: Wegener's granulomatosis. Oral Maxillofac Clin N Am 20:643–649, 2008.
Wilson DT, Drew RH, Perfect JR: Antifungal therapy for invasive fungal diseases in allogeneic stem cell transplant recipients: an update. Mycopathologica 168:313–327, 2009.
Yamamoto M, Takahashi H, Suzuki C, et al: Facial cutaneous and parotid involvement in Wegener's granulomatosis. J Rheumatol 35:365–367, 2008.

Neoplasms

Bartek J, Lukas J, Bartkova J: Perspective: defects in cell cycle control and cancer. J Pathol 187:95–99, 1999.
Bartkova J, Kukas J, Muller H, et al: Abnormal patterns of D-type cyclin expression and G1 regulation in human head and neck cancer. Cancer Res 55:949–956, 1995.
Begum S, Westra WH: Basaloid squamous cell carcinoma of the head and neck is a mixed variant that can be further resolved by HPV status. Am J Surg Pathol 32:1044–1050, 2009.
Bernier J, Domenge C, Ozsahin M, et al: Postoperative irradiation with or without concomitant chemotherapy for locally advanced head and neck cancer. N Engl J Med 450:1945–1952, 2004.
Bonner J, Harari P, Giralt J, et al: Radiotherapy plus cetuximab for squamous-cell carcinoma of the head and neck. N Engl J Med 354:567–578, 2006.
Bourhis J, Overgaard J, Audry H, et al: Hyperfractionated or accelerated radiotherapy in head and neck cancer: a meta-analysis. Lancet 368:843–854, 2006.
Bourhis J, Pignon JP: Meta-analyses in head and neck squamous cell carcinoma: what is the role of chemotherapy? Hematol Oncol Clin North Am 13:769–775, 1999.
Brennan JA, Boyle JO, Koch WM, et al: Association between cigarette smoking and mutation of the p53 gene in squamous cell carcinoma of the head and neck. N Engl J Med 332:712–717, 1995.
Brinkman BM, Wong DT: Disease mechanism and biomarkers of oral squamous cell carcinoma. Curr Opin Oncol 8:228–233, 2006.
Browman GP, Hodson D, MacKenzie RW, et al: Choosing a concomitant chemotherapy and radiotherapy regimen for squamous cell head and neck cancer: a systematic review of the published literature with subgroup analysis. Head Neck 23:579–589, 2001.
Carlson ER, Cheung A, Smith B, et al: Neck dissections for oral/head and neck cancer. J Oral Maxillofac Surg 64:4–11, 2006.
Chernock RD, Lewis JS, Jr, Zhang Q, et al: Human papillomavirus-positive basaloid squamous cell carcinomas of the upper aerodigestive tract: a distinct clinicopathologic and molecular subtype of basaloid squamous cell carcinoma. Hum Pathol 41:1016–1023, 2010.
Chu PG, Weiss LM: Keratin expression in human tissues and neoplasms. Histopathology 40:403–439, 2002.
Cooper JS, Pajak TF, Forastiere AA, et al: Postoperative concurrent radiotherapy and chemotherapy for high-risk squamous-cell carcinoma of the head and neck. N Engl J Med 450:1937–1944, 2004.
Curran S, Murray GI: Matrix metalloproteinases in tumor invasion and metastasis. J Pathol 189:300–308, 1999.
Curtis RE, Rowlings PA, Deeg HJ, et al: Solid cancers after bone marrow transplantation. N Engl J Med 336:897–904, 1997.
Daley TD, Lovas JG, Peters E, et al: Salivary gland duct involvement in oral epithelial dysplasia and squamous cell carcinoma. Oral Surg Oral Med Oral Pathol Oral Radiol Endod 81:186–192, 1996.
Decroix Y, Ghossein NA: Experience of the Curie Institute in treatment of cancer of the mobile tongue: management of the neck nodes. Cancer 47:503–508, 1981.
Downey MG, Going JJ, Stuart RC, et al: Expression of telomerase RNA in esophageal and oral cancer. J Oral Pathol Med 30:577–581, 2001.
Eisbruch A: Intensity-modulated radiation therapy in the treatment of head and neck cancer. Nat Clin Pract Oncol 2:34–39, 2005.
Eisbruch A, Ship JA, Kim HM, et al: Partial irradiation of the parotid gland. Semin Radiat Oncol 11:234–239, 2001.
Fakhry C, Westra WH, Li S, et al: Improved survival of patients with human papilloma positive head and neck squamous cell carcinoma in a prospective clinical trial. J Natl Cancer Inst 100:261–269, 2008.
Ferlito A, Shaha AR, Rinaldo A: The incidence of lymph node micrometastases in patients pathologically staged N0 in cancer of oral cavity and oropharynx. Oral Oncol 38:3–5, 2002.
Ferretti G, Raybould T, Brown A, et al: Chlorhexidine prophylaxis for chemotherapy and radiotherapy-induced stomatitis: a randomized double-blind trial. Oral Surg Oral Med Oral Pathol 69:331–338, 1990.
Field JK: Oncogenes and tumor suppressor genes in squamous cell carcinoma of the head and neck. Eur J Cancer B Oral Oncol 28B:667–676, 1992.
Flaitz CM, Nichols CM, Adler-Storthz K, et al: Intraoral squamous cell carcinoma in human immunodeficiency virus infection. Oral Surg Oral Med Oral Pathol Oral Radiol Endod 80:55–62, 1995.
Franceschi S, Gloghini A, Maestro R, et al: Analysis of the p53 gene in relation to tobacco and alcohol in cancers of the upper aerodigestive tract. Int J Cancer 60:872–876, 1995.
Frank SA, Chao KSC, Schwartz DL, et al: Technology insight: PET and PET/CT in head and neck tumor staging and radiation therapy planning. Nat Clin Pract Oncol 2:526–533, 2005.
Fu KK, Pajak TF, Trotti A, et al: A Radiation Therapy Oncology Group (RTOG) phase III randomized study to compare hyperfractionation and two variants of accelerated fractionation to standard fractionation radiotherapy for head and neck squamous cell carcinomas: first report of RTOG 9003. Int J Radiat Oncol Biol Phys 48:7–16, 2000.
Fujita M, Hirokawa Y, Kashiwado K, et al: An analysis of mandibular bone complications in radiotherapy for T1 and T2 carcinoma of the oral tongue. Int J Radiat Oncol Biol Phys 34:333–339, 1996.
Ghali GE, Li BD, Minnard EA: Management of the neck relative to oral malignancy. Selected Readings Oral Maxillofac Surg 6:1–36, 2000.
Gillenwater A, Papadimitrakopoulou V, Richards-Kortum R: Oral premalignancy: new methods of detection and treatment. Curr Oncol Rep 8:146–154, 2006.
Gopalakrisnan R, Weghorst CM, Lehman TA, et al: Mutated and wild-type p53 expression and HPV integration in proliferative verrucous leukoplakia and oral squamous cell carcinoma. Oral Surg Oral Med Oral Pathol Oral Radiol Endod 83:471–477, 1997.

Grandis JR, Tweardy DJ: Elevated levels of transforming growth factor alpha and epidermal growth factor receptor messenger RNA are early markers of carcinogenesis in head and neck cancer. Cancer Res 53:3579–3584, 1993.

Gstaiger M, Jordan RCK, Lim MS, et al: The F-box protein Skp2 is the product of an oncogene and is overexpressed in human cancers. Proc Natl Acad Sci U S A 98:5043–5048, 2001.

Holley SL, Parkes G, Matthias C, et al: Cyclin D1 polymorphism and expression in patients with squamous cell carcinoma of the head and neck. Am J Pathol 159:1917–1924, 2001.

Horiot JC, Bontemps P, van den Bogaert W, et al: Accelerated fractionation (AF) compared to conventional fractionation (CF) improves loco-regional control in the radiotherapy of advanced head and neck cancers: results of the EORTC 22851 randomized trial. Radiother Oncol 44:111–121, 1997.

Inoue T, Inoue T, Yoshida K, et al: Phase III trial of high- vs. low-dose-rate interstitial radiotherapy for early mobile tongue cancer. Int J Radiat Oncol Biol Phys 51:171–175, 2001.

Jemal A, Siegel R, Xu J, et al: Cancer statistics, 2010. CA Cancer J Clin 60:277–300, 2010.

Johansson N, Airola K, Grenman R, et al: Expression of collagenase-3 (matrix metalloproteinase-13) in squamous cell carcinomas of the head and neck. Am J Pathol 151:499–508, 1997.

Jones J, Watt FM, Speight PM: Changes in the expression of alpha-V integrins in oral squamous cell carcinomas. J Oral Pathol Med 26:63–68, 1997.

Jordan RC, Bradley G, Slingerland J: Reduced levels of the cell cycle inhibitor $p27^{kip1}$ in epithelial dysplasia and carcinoma of the oral cavity. Am J Pathol 152:585–590, 1998.

Juweid ME, Cheson BD: Positron-emission tomography and assessment of cancer therapy. N Engl J Med 354:496–507, 2006.

Katayama A, Bandoh N, Kishibe K, et al: Expression of matrix metalloproteinases in early stage oral squamous cell carcinoma as predictive indicators of tumor metastasis and prognosis. Clin Cancer Res 10:634–640, 2004.

Ke LD, Adler-Storthz K, Clayman GL, et al: Differential expression of epidermal growth factor receptor in human head and neck cancers. Head Neck 20:320–327, 1998.

Kim JJ, Tannock IF: Repopulation of cancer cells during therapy: an important cause of treatment failure. Nat Rev Cancer 5:516–525, 2005.

Koo BS, Lim YC, Lee JS, et al: Management of contralateral N0 neck in oral cavity squamous cell carcinoma. Head Neck 28:896–901, 2006.

Kropveld A, van Mansfeld AD, Nabben N, et al: Discordance of p53 status in matched primary tumors and metastases in head and neck squamous cell carcinoma patients. Eur J Cancer B Oral Oncol 32B:388–393, 1996.

Lazarus P, Stern J, Zwiebel N, et al: Relationship between p53 mutation incidence in oral cavity squamous cell carcinomas and patient tobacco use. Carcinogenesis 17:733–739, 1996.

Leong PP, Rezai B, Koch WM, et al: Distinguishing second primary tumors from lung metastases in patients with head and neck squamous cell carcinoma. J Natl Cancer Inst 90:972–977, 1998.

Ma BB, Bristow RG, Kim J, et al: Combined-modality treatment of solid tumors using radiotherapy and molecular targeted agents. J Clin Oncol 21:2760–2776, 2003.

Matsuura K, Hirokawa Y, Fujita M, et al: Treatment results of stage I and II oral tongue cancer with interstitial brachytherapy: maximum tumor thickness is prognostic of nodal metastasis. Int J Radiat Oncol Biol Phys 40:535–539, 1998.

Mazeron JJ, Grimard L, Benk V: Curietherapy versus external irradiation combined with curietherapy in stage II squamous cell carcinomas of mobile tongue and floor of mouth. Recent Results Cancer Res 134:101–110, 1994.

McDonald JS, Jones H, Pavelic LJ, et al: Immunohistochemical detection of the H-ras, K-ras, and N-ras oncogenes in squamous cell carcinoma of the head and neck. J Oral Pathol Med 23:342–346, 1994.

Medina JE: A rational classification of neck dissections. Otolaryngol Head Neck Surg 100:169–176, 1989.

Mendenhall WM, Million RR, Cassisi NJ: T2 oral tongue carcinoma treated with radiotherapy: analysis of local control and complications. Radiother Oncol 16:275–281, 1989.

Michalides R, van Veelen N, Hart A, et al: Overexpression of cyclin D1 correlates with recurrence in a group of forty-seven operable squamous cell carcinomas of the head and neck. Cancer Res 55:975–978, 1995.

O'Shaughnessy JA, Kelloff GJ, Gordon GB, et al: Treatment and prevention of intraepithelial neoplasia: an important target for accelerated new agent development. Clin Cancer Res 8:314–346, 2002.

Ostwald C, Muller P, Barten M, et al: Human papillomavirus in oral squamous cell carcinomas and normal oral mucosa. J Oral Pathol Med 23:220–225, 1994.

Pena JC, Thompson CB, Recant W, et al: Bcl-xl and Bcl-2 expression in squamous cell carcinoma of the head and neck. Cancer 85:164–170, 1999.

Ramos D, Chen BL, Regezi J, et al: Tenascin-C matrix assembly in oral squamous cell carcinoma. Int J Cancer 75:680–687, 1998.

Regezi JA, Dekker NP, McMillan A, et al: p53, p21, Rb, and MDM2 proteins in tongue cancers in tongue carcinoma from patients <35 years versus >75 years. Oral Oncol 35:379–383, 1999.

Riethdorf S, Friedrich RE, Ostwald C, et al: P53 gene mutations and HPV infection in primary head and neck squamous cell carcinomas do not correlate with overall survival: a long-term follow-up study. J Oral Pathol Med 26:315–321, 1997.

Robbins KT, Medina JE, Wolfe GT, et al: Standardizing neck dissection terminology: official report of the academy's committee for head and neck surgery and oncology. Arch Otolaryngol Head Neck Surg 117:601–605, 1991.

Rose BR, Thompson CH, Tattersall MH, et al: Squamous carcinoma of the head and neck: molecular mechanisms and potential biomarkers. Aust N Z J Surg 70:601–606, 2000.

Rowley H: The molecular genetics of head and neck cancer. J Laryngol Otol 112:607–612, 1998.

Sankaranarayanan R: Oral cancer in India: an epidemiologic and clinical review. Oral Surg Oral Med Oral Pathol 69:325–330, 1990.

Saunders J: The genetic basis of head and neck carcinoma. Am J Surg 174:459–461, 1997.

Schoelch ML, Le QT, Silverman S, Jr, et al: Apoptosis-associated proteins and the development of oral squamous cell carcinoma. Oral Oncol 35:77–85, 1999.

Schoelch ML, Regezi JA, Dekker NP, et al: Cell cycle proteins and the development of oral squamous cell carcinoma. Oral Oncol 35:333–342, 1999.

Shah JP, Andersen PE: Evolving role of modifications in neck dissection for oral squamous carcinoma. Br J Oral Maxillofac Surg 33:3–8, 1995.

Shahnavaz SA, Bradley G, Regezi JA, et al: Patterns of CDKN2A gene loss in sequential oral epithelial dysplasias and carcinomas. Cancer Res 61:2371–2375, 2001.

Shahnavaz SA, Regezi JA, Bradley G, et al: p53 gene mutations in sequential oral epithelial dysplasias and carcinomas. J Pathol 190:417–422, 2000.

Shin DM, Kim J, Ro JY, et al: Activation of p53 gene expression in premalignant lesions during head and neck tumorigenesis. Cancer Res 54:321–326, 1994.

Stuschke M, Thames HD: Hyperfractionated radiotherapy of human tumors: overview of the randomized clinical trials. Int J Radiat Oncol Biol Phys 37:259–267, 1997.

Sugerman PB, Joseph BK, Savage NW: Review article: the role of oncogenes, tumor suppressor genes and growth factors in oral

squamous cell carcinoma: a case of apoptosis versus proliferation. Oral Dis 1:172–188, 1995.
Sumida T, Sogawa K, Sugita A, et al: Detection of telomerase activity in oral lesions. J Oral Pathol Med 27:111–115, 1998.
Tanaka N, Ogi K, Odajima T, et al: pRb/p21 protein expression is correlated with clinicopathologic findings in patients with oral squamous cell carcinoma. Cancer 92:2117–2125, 2001.
Timmons SR, Nwankwo JO, Domann FE: Acetaldehyde activates Jun/AP-1 expression and DNA binding activity in human oral keratinocytes. Oral Oncol 38:281–290, 2002.
Tsai CH, Yang CC, Chou LSS, et al: The correlation between alteration of p16 gene and clinical status in oral squamous cell carcinoma. J Oral Pathol Med 30:527–531, 2001.
Valdez IH, Wolff A, Atkinson JC, et al: Use of pilocarpine during head and neck radiation therapy to reduce xerostomia and salivary dysfunction. Cancer 71:1848–1851, 1993.
Vandenbrouck C, Sancho-Garnier H, Chassagne D, et al: Elective versus therapeutic radical neck dissection in epidermoid carcinoma of the oral cavity: results of a randomized clinical trial. Cancer 46:386–390, 1980.
Watts S, Brewer E, Fry T: Human papillomavirus DNA types in squamous cell carcinomas of the head and neck. Oral Surg Oral Med Oral Pathol 71:701–707, 1991.
Wilson GD, Richman PI, Dische S, et al: p53 status of head and neck cancer: relation to biological characteristics and outcome of radiotherapy. Br J Cancer 71:1248–1252, 1995.
Xia W, Lau YK, Zhang HZ, et al: Strong correlation between c-erbB-2 overexpression and overall survival of patients with oral squamous cell carcinoma. Clin Cancer Res 3:3–9, 1997.
Yeudall WA: Human papillomaviruses and oral neoplasia. Eur J Cancer B Oral Oncol 28B:61–66, 1992.

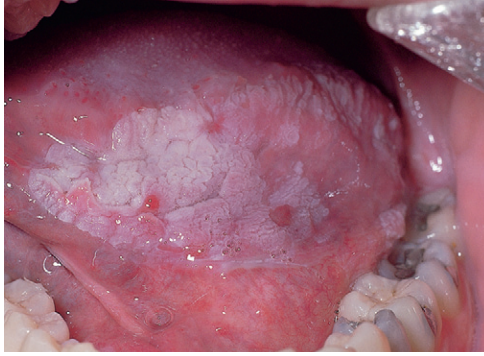

CHAPTER 3

White Lesions

HEREDITARY CONDITIONS

Leukoedema
White Sponge Nevus
Hereditary Benign Intraepithelial Dyskeratosis
Follicular Keratosis

REACTIVE LESIONS

Focal (Frictional) Hyperkeratosis
White Lesions Associated With Smokeless Tobacco
Nicotine Stomatitis
Hairy Leukoplakia
Hairy Tongue
Dentifrice-Associated Slough

PRENEOPLASTIC AND NEOPLASTIC LESIONS

Actinic Cheilitis
Actinic Keratoses (Solar Keratoses)
Idiopathic Leukoplakia

OTHER WHITE LESIONS

Geographic Tongue
Lichen Planus
Lupus Erythematosus

NONEPITHELIAL WHITE-YELLOW LESIONS

Candidiasis
Mucosal Burns
Submucous Fibrosis
Fordyce's Granules
Ectopic Lymphoid Tissue
Gingival Cysts
Parulis
Lipoma

Lesions of the oral mucosa, which are white, result from the scattering of light through a thickened layer of keratin, epithelial hyperplasia, intracellular epithelial edema, and/or reduced vascularity of subjacent connective tissue. White or yellow-white lesions may also be due to fibrinous exudate covering an ulcer, submucosal deposits, surface debris, or fungal colonies.

HEREDITARY CONDITIONS

Leukoedema

Leukoedema is a generalized mild opacification of the buccal mucosa that is regarded as a variation of normal. It can be identified in the majority of the population.

Etiology and Pathogenesis. To date, the cause of leukoedema has not been established. Factors such as smoking, chewing tobacco, alcohol ingestion, bacterial infection, salivary conditions, electrochemical interactions, and a possible association with cannabis use have been implicated, but none are specifically proven causes.

Clinical Features. Leukoedema is usually discovered as an incidental finding. It is asymptomatic and symmetrically distributed in the buccal mucosa, and to a lesser extent over the labial mucosa. It appears as a gray-white, diffuse, filmy, or milky surface alteration (Fig. 3-1). In exaggerated cases, a whitish cast with surface textural changes, including wrinkling or corrugation, may be seen. With stretching of the buccal mucosa, the opaque changes dissipate. It is more apparent in nonwhites, especially African Americans.

Histopathology. In leukoedema, the epithelium is parakeratotic and acanthotic, with marked intracellular edema of spinous cells. The enlarged epithelial cells have small, pyknotic (condensed) nuclei in optically clear cytoplasm.

Differential Diagnosis. White sponge nevus, hereditary benign intraepithelial dyskeratosis, and the response to

chronic cheek biting and lichen planus may show clinical similarities to leukoedema. The overall thickness of leukoedema, persistence on stretching, and specific microscopic features are distinctive.

Treatment and Prognosis. Treatment is not necessary because the changes are innocuous and no malignant potential exists. If the diagnosis is in doubt, a biopsy can be performed.

White Sponge Nevus

White sponge nevus (WSN) is an autosomal-dominant condition that is due to point mutations for genes coding for keratin 4 and/or 13. It affects oral mucosa bilaterally and symmetrically, and no treatment is generally required.

Clinical Features. WSN presents as an asymptomatic, folded, white lesion that may affect several mucosal sites (Fig. 3-2; Box 3-1). Lesions tend to be thickened and have a spongy consistency. The presentation intraorally is almost always bilateral and symmetric and usually appears early in life, typically before puberty. The characteristic clinical manifestations of this particular form of keratosis are usually best observed on the buccal mucosa, although other areas such as the tongue and vestibular mucosa may also be involved. The conjunctival mucosa is usually spared, but mucosa of the esophagus, anus, vulva, and vagina may be affected.

Histopathology. Microscopically, the epithelium is greatly thickened, with marked spongiosis, acanthosis, and parakeratosis (Fig. 3-3). Within the stratum spinosum, marked hydropic or clear cell change may be noted, often beginning in the parabasal region and extending very close to the surface. Perinuclear eosinophilic condensation of cytoplasm is characteristic of prickle cells in WSN. It is often possible to see columns of parakeratin extending from the spinous layer to the surface.

Differential Diagnosis. The differential diagnosis includes hereditary benign epithelial dyskeratosis, lichen planus, lichenoid drug reaction, lupus erythematosus (LE), cheek chewing, and possibly candidiasis (Table 3-1). Once tissue diagnosis is confirmed, no additional biopsies are necessary.



■ **FIGURE 3-1** Leukoedema.

BOX 3-1 WHITE SPONGE NEVUS: KEY FEATURES

Asymptomatic
Bilateral folded/shaggy white buccal mucosal change
Hereditary; appears early in life
Does not disappear when cheek is stretched
Intracellular edema with perinuclear condensation of keratin
No treatment, no malignant potential

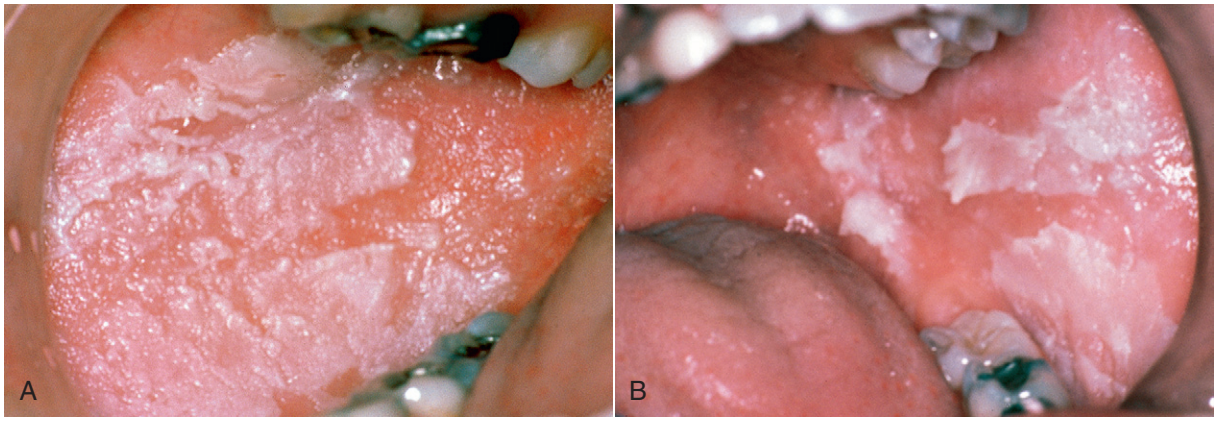

■ **FIGURE 3-2 A** and **B,** White sponge nevus.

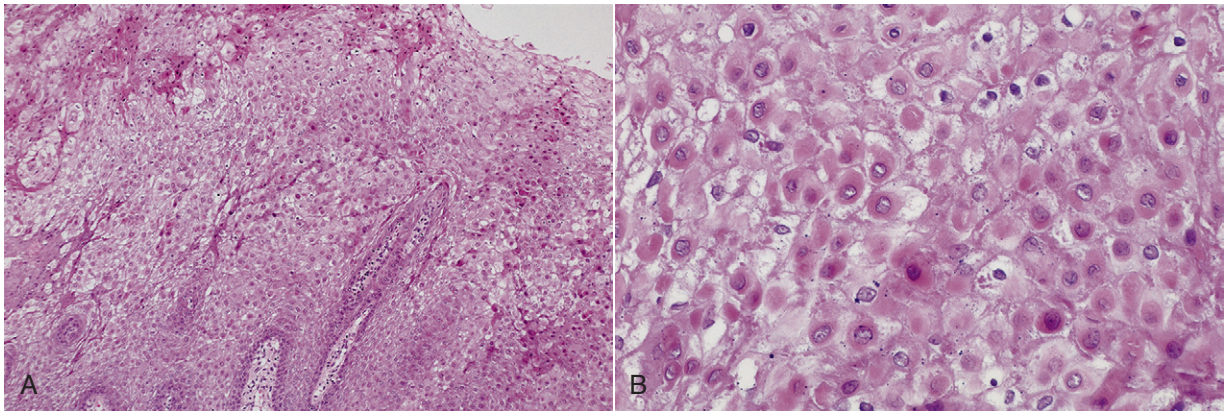

■ **FIGURE 3-3 A,** White sponge nevus showing edema and keratosis. **B,** High magnification of epithelium showing characteristic perinuclear condensation of keratin.

TABLE 3-1 BILATERAL BUCCAL MUCOSAL WHITE LESIONS: DIFFERENTIAL DIAGNOSIS

Disease	Features/Action
White sponge nevus and HBID	Hereditary; does not disappear when stretched; biopsy to confirm; HBID may also involve conjunctiva
Lichen planus	Look for white reticulations (striae) and skin lesions; biopsy
Lichenoid drug reaction	Look for white lesions in context of new drug history
Cheek chewing	White shaggy lesions along occlusal plane or trauma sites
Lupus erythematosus	Delicate radiating striae; biopsy
Candidiasis	Look for predisposing factors; can rub off; responds to antifungal therapy

HBID, Hereditary benign intraepithelial dyskeratosis.

Treatment. No treatment is necessary for this condition because it is asymptomatic and benign. Some may elect to manage this condition with tetracycline mouth rinses with good but transient effect.

Hereditary Benign Intraepithelial Dyskeratosis

Etiology. Hereditary benign intraepithelial dyskeratosis (HBID), also known as Witkop's disease, is a rare, hereditary condition (autosomal dominant). It was noted within a triracial isolate of white, Indian, and African American composition in Halifax County, North Carolina. The initial cohort of 75 patients was traced to a single common female ancestor who lived nearly 130 years earlier. With the use of genetic linkage and molecular analyses in two large families affected by HBID, one group localized the candidate causative genetic region to a telomeric region of chromosome 4q35, where three alleles for two linked markers exist. The precise gene that causes the condition has not been characterized.

Clinical Features. HBID presentation includes early onset (usually within the first year of life) of bulbar conjunctivitis, conjunctival plaques at the corneal limbus, and oral white lesions. Preceding the bulbar conjunctivitis are foamy gelatinous plaques that represent the ocular counterpart of the oral mucosal lesions.

Oral lesions consist of soft, asymptomatic, white folds and plaques of spongy mucosa. Areas characteristically involved include the buccal and labial mucosa and the labial commissures, as well as the floor of the mouth and lateral surfaces of the tongue, gingiva, and palate. The dorsum of the tongue is usually spared. Oral lesions are generally detected within the first year of life, with a gradual increase in intensity until mid-adolescence.

In some patients ocular lesions may vary seasonally, with spontaneous shedding of conjunctival plaques. Patients may complain of photophobia, especially in early life. Blindness, resulting from corneal vascularization, has been reported.

Histopathology. Similarities between oral and conjunctival lesions are noted microscopically. Epithelial hyperplasia and acanthosis are present with intracellular edema. Enlarged hyaline keratinocytes are the dyskeratotic elements that are present in the superficial half of the epithelium. Normal cellular features are noted within the lower spinous and basal layers. Inflammatory cell infiltration within the lamina propria is minimal, and the epithelium–connective tissue junction is well defined.

Treatment. No treatment is necessary because this condition is self-limiting and benign. It appears to pose no risk of malignant transformation. Genetic counseling may be sought.

Follicular Keratosis

Etiology and Pathogenesis. Follicular keratosis (Darier's disease, Darier-White disease) is an autosomal-dominant disorder that results in desmosomal defects and dysfunction by way of altered epithelial cell adhesion. Many cases appear

sporadically as new mutations. Screening of candidate genes has led to the discovery that mutations in *ATP2A2,* a gene that encodes the sarcoplasmic/endoplasmic reticulum calcium–adenosine triphosphatase (Ca2-ATPase) isoform 2, cause this condition. It has been proposed that abnormalities in this calcium pump function interfere with cell growth and differentiation of calcium-dependent processes. To date at least 140 different mutations of the *ATP2A2* gene have been identified as the genetic basis of Darier's disease.

Clinical Features. Onset occurs between the ages of 6 and 20 years. The disease has a predilection for the skin, with 13% of patients demonstrating oral lesions. Skin manifestations are characterized by small, skin-colored papular lesions symmetrically distributed over the face, trunk, and intertriginous areas. The papules eventually coalesce and feel greasy because of excessive keratin production. The coalesced areas subsequently form patches of vegetating to verrucous growths that have a tendency to become infected and malodorous. Lesions may also occur unilaterally or in a zosteriform pattern. Thickening of the palms and soles (hyperkeratosis palmaris et plantaris) by excessive keratotic tissue is not uncommon. Fingernail changes may include fragility, splintering, and subungual keratosis. Nail changes are often helpful in establishing a diagnosis.

The extent of the oral lesions may parallel the extent of skin involvement. Favored oral mucosal sites include the attached gingiva and hard palate. Lesions typically appear as small, whitish papules, producing an overall cobblestone appearance. Papules range from 2 to 3 mm in diameter and may become coalescent. Extension beyond the oral cavity into the oropharynx and pharynx may occur.

Histopathology. Oral lesions closely resemble the cutaneous lesions. Features include (1) formation of suprabasal lacunae (clefts) containing acantholytic epithelial cells, (2) basal layer proliferation immediately below and adjacent to the lacunae or clefts, (3) formation of vertical clefts that show a lining of parakeratotic and dyskeratotic cells, and (4) the presence of specific benign dyskeratotic cells—corps ronds and grains. Corps ronds are large, keratinized squamous cells with round, uniformly basophilic nuclei and intensely eosinophilic cytoplasm. Grains are smaller parakeratotic cells with pyknotic, hyperchromatic nuclei.

Treatment and Prognosis. Vitamin A analogs or retinoids have been used effectively, but long-term therapy is tolerated poorly. The disease is chronic and slowly progressive; remissions may be noted in some patients.

REACTIVE LESIONS

Focal (Frictional) Hyperkeratosis

Etiology. Focal (frictional) hyperkeratosis is a white lesion that is related to chronic rubbing or friction against an oral mucosal surface. This results in a presumably protective hyperkeratotic white lesion that is analogous to a callus on the skin.

Clinical Features. Friction-induced hyperkeratoses occur in areas that are commonly traumatized, such as the lips, lateral margins of the tongue, buccal mucosa along the occlusal line, and edentulous alveolar ridges (Figs. 3-4 to 3-7;



■ **FIGURE 3-4** Focal hyperkeratosis caused by cheek chewing.



■ **FIGURE 3-5** Focal hyperkeratosis caused by chronic rubbing of the lip against teeth.



■ **FIGURE 3-6** Focal hyperkeratosis related to tongue-thrusting habit.



■ **FIGURE 3-7** Focal hyperkeratosis and erythema associated with an ill-fitting lower denture.

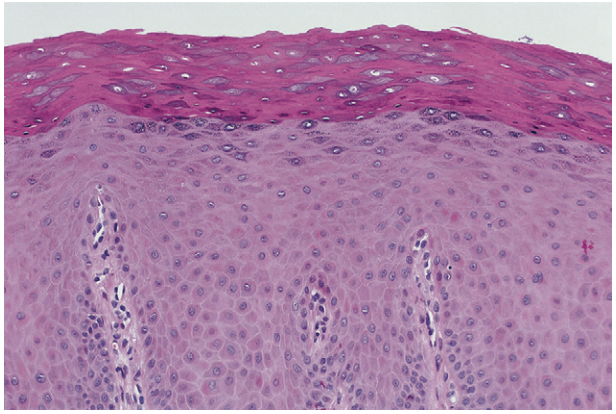

■ **FIGURE 3-8** Focal hyperkeratosis biopsy specimen. Note that the epithelial maturation pattern is otherwise normal.

BOX 3-2 FRICTIONAL HYPERKERATOSIS: KEY FEATURES

It appears in sites commonly traumatized: lips, lateral tongue, buccal mucosa.
Edentulous ridges and vestibules may be affected in denture wearers.
Hyperkeratosis results in opacification (white lesion) of traumatized area.
Microscopically, hyperkeratosis is noted without dysplastic change.
If cause is removed, lesion should subside. When in doubt, perform a biopsy.

Box 3-2). Chronic cheek or lip chewing may result in opacification (keratinization) of the affected area. Chewing on edentulous alveolar ridges produces the same effect.

Histopathology. As the name indicates, the primary microscopic change is hyperkeratosis (Fig. 3-8). A few chronic inflammatory cells may be seen in the subjacent connective tissue.

TABLE 3-2 SOLITARY WHITE LESION: DIFFERENTIAL DIAGNOSIS

Disease	Features/Action
Frictional keratosis	Look for cause (e.g., ill-fitting denture, trauma); biopsy
Dysplasia, in situ carcinoma, squamous cell carcinoma	Assess risk factors; biopsy
Burn	History of aspirin or other agent application at site of lesion—discontinue use
Lupus erythematosus	Delicate radiating striae; biopsy
Hairy leukoplakia	Lateral borders of tongue; look for irregular surface architecture; often bilateral; biopsy

Diagnosis. Careful history taking and examination should indicate the nature of this lesion. If the practitioner is clinically confident of a traumatic cause, no biopsy may be required. Patients should be advised to discontinue the causative habit, or the offending tooth or denture should be smoothed. The lesion should resolve or at least should be reduced in intensity over time, confirming the clinical diagnosis. Resolution of the lesion would allow unmasking of any underlying lesion that may not be related to trauma (Table 3-2). If the clinical diagnosis is in doubt, a biopsy should be taken.

Treatment. Observation is generally all that is required for simple frictional hyperkeratotic lesions. Control of the habit causing the lesion should result in clinical improvement. No malignant potential exists.

White Lesions Associated With Smokeless Tobacco

Marked geographic and gender differences in tobacco use have been identified. In the United States, a relatively high prevalence of smokeless tobacco users is found in the southern and western states. Use by men in New York and Rhode Island is less than 1% of the population, but in West Virginia, use exceeds 20%. Among teenagers, whites are the predominant users of smokeless tobacco, with males making up nearly this entire group. Smokeless tobacco is also used in Sweden in the form of snus, a nonfermented type of tobacco with lower concentrations of harmful nicotine and tobacco derivatives versus those types of fermented smokeless tobaccos traditionally used in the United States. In regions such as the Indian subcontinent and Southeast Asia, use is even more common and the materials more destructive. The tobacco-containing preparations generally are of a higher (alkaline) pH and often are mixed with other ingredients, including shredded areca (betel) nut; they may also contain lime, camphor, and spices.

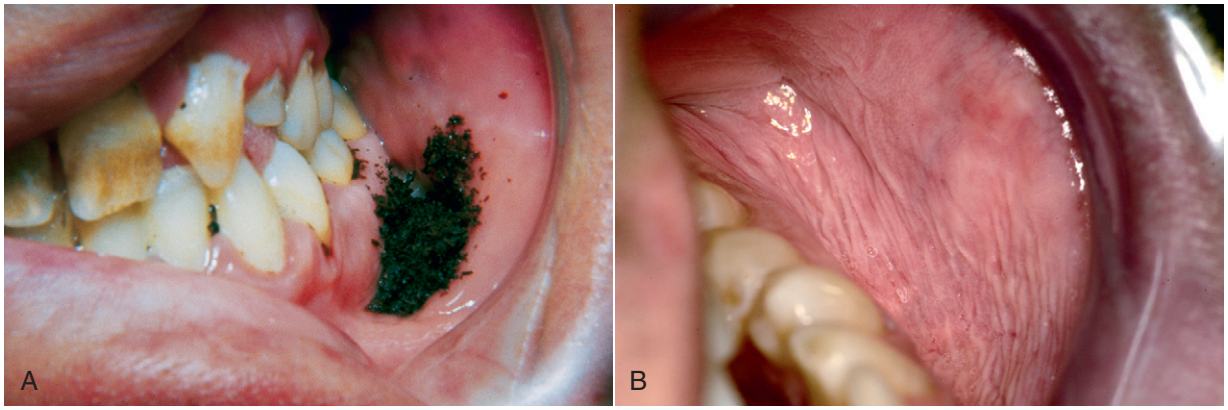

■ **FIGURE 3-9 A,** Smokeless tobacco in the vestibule. **B,** Keratotic pouch induced by tobacco contact.

The general increase in smokeless tobacco consumption has been related to both peer pressure and increased media advertising, which often glamorizes the use of smokeless tobacco, or snuff dipping. In addition, individuals who have been intense smokers and those who wish to avoid smoking may gravitate to this alternative. The clinical results of long-term exposure to smokeless tobacco include the development of oral mucosal white patches with a slightly increased malignant potential, dependence, alterations of taste, acceleration of periodontal disease, and significant amounts of dental abrasion.

Etiology. A causal relationship has been documented between smokeless tobacco and white tissue changes. Although all forms of smokeless tobacco may cause alterations in the oral mucosa, snuff (particulate, finely divided, or shredded tobacco) appears to be much more likely to cause oral lesions than does chewing tobacco. Oral mucosa responds to the topically-induced effects of tobacco with inflammation and keratosis. At the molecular level, altered cell signaling and subsequent cell damage have been demonstrated. Dysplastic changes may follow, with a low potential risk of malignant change. Smokeless tobacco–induced alterations in tissues are thought to be a response to tobacco constituents and perhaps other agents that are added for flavoring or moisture retention. Carcinogens such as nitrosonornicotine, an organic component of chewing tobacco and snuff, have been identified in smokeless tobacco. The pH of snuff, which ranges between 8.2 and 9.3, may be another factor that contributes to the alteration of mucosa.

Duration of exposure to smokeless tobacco that is necessary to produce mucosal damage is measured in terms of years. It has been demonstrated that leukoplakia can be predicted with the use of three tins of tobacco per week or duration of the habit of longer than 2 years.

Clinical Features. White lesions associated with smokeless tobacco develop in the immediate area where the tobacco is habitually placed (Figs. 3-9 and 3-10; Box 3-3). The most common area of involvement is the mucobuccal fold of the



■ **FIGURE 3-10 Snuff dipper's pouch.** Note incisal edge abrasion wear and periodontal disease.

BOX 3-3 SMOKELESS TOBACCO–ASSOCIATED LESIONS

ETIOLOGY

Direct contact of mucosa with smokeless tobacco and contaminants

Snuff form of tobacco most likely to induce lesions

CLINICAL FEATURES

Prevalence associated with regional use (e.g., 1% of New York population, 20% of West Virginia population)

Mostly seen in white males

Asymptomatic white lesion in mucosa where tobacco is held

Most commonly seen in the mandibular vestibular mucosa surrounding tobacco (snuff dipper's pouch)

Damage seen in adjacent teeth and periodontium

TREATMENT

Discontinue use

Biopsy if ulcerated, indurated, or persistent

Slight risk of malignant transformation with long-term use (decades)

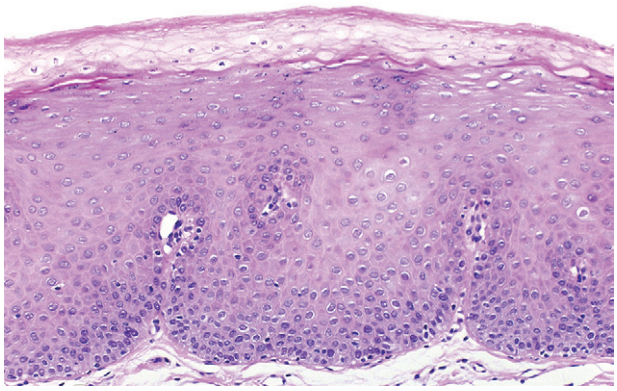

■ **FIGURE 3-11** Smokeless tobacco lesion biopsy specimen showing acanthosis and edematous parakeratosis.



■ **FIGURE 3-12** Nicotine stomatitis.

mandible in the incisor or the molar region. The mucosa develops a granular to wrinkled appearance. In advanced cases, a heavy, folded character may be seen. Less often, an erythroplakic or red component may be admixed with the white keratotic component. The lesions are generally painless and asymptomatic, and their discovery is often incidental to routine oral examination.

Histopathology. Slight to moderate parakeratosis, often in the form of spires or chevrons, is noted over the surface of the affected mucosa (Fig. 3-11). Superficial epithelium may demonstrate vacuolization or edema. A slight to moderate chronic inflammatory cell infiltrate is typically present. Epithelial dysplasia may occasionally develop in these lesions, especially among long-time users of smokeless tobacco. On occasion, a diffuse zone of basophilic stromal alteration may be seen, usually adjacent to inflamed minor salivary glands.

Treatment and Prognosis. With discontinuation of smokeless tobacco use, some lesions may disappear after several weeks. It would be prudent to perform a biopsy on persistent lesions. A long period of exposure to smokeless tobacco increases the risk of transformation to verrucous or squamous cell carcinoma, although this risk is probably low.

Nicotine Stomatitis

Etiology. Nicotine stomatitis is a common tobacco-related form of keratosis. It is typically associated with pipe and cigar smoking, with a positive correlation between intensity of smoking and severity of the condition. The importance of the direct topical effect of smoke can be appreciated in instances in which the hard palate is covered by a removable prosthesis, resulting in sparing of the mucosa beneath the appliance and hyperkeratosis of exposed areas. The combination of tobacco carcinogens and heat is markedly intensified in reverse smoking (lit end positioned inside the mouth), adding significant risk for malignant conversion (see Fig. 3-13).

BOX 3-4 NICOTINE STOMATITIS

ETIOLOGY

Caused by pipe, cigar, and cigarette smoking

Opacification of the palate caused by heat and carcinogens

Most severe changes seen in patients who "reverse smoke"

CLINICAL FEATURES

Generalized white change (hyperkeratosis) seen in hard palate

Red dots in the palate represent inflamed salivary duct orifices

TREATMENT

Discontinue tobacco habit

Observe and examine all mucosal sites

Little risk of malignant transformation in palate, except for "reverse smokers"

Clinical Features. The palatal mucosa initially responds with an erythematous change followed by keratinization (Box 3-4). Subsequent to opacification or keratinization of the palate, red dots surrounded by white keratotic rings appear (Figs. 3-12 and 3-13). The dots represent inflammation surrounding the minor salivary gland excretory ducts.

Histopathology. Nicotine stomatitis is characterized by epithelial hyperplasia and hyperkeratosis (Fig. 3-14). The minor salivary glands in the area show inflammatory change, and excretory ducts may show squamous metaplasia.

Treatment and Prognosis. This condition rarely evolves into malignancy, except in individuals who reverse smoke. Although the risk of carcinoma development in the palate is minimal, nicotine stomatitis is a marker or indicator of intense tobacco use and hence may indicate increased risk of epithelial dysplasia and neoplasia elsewhere in the oral



■ **FIGURE 3-13** Reverse smoker's palate.

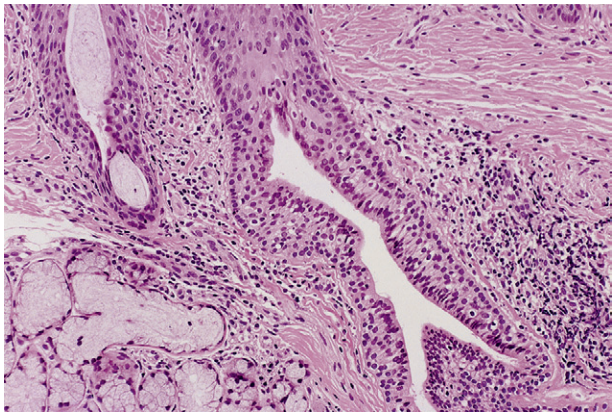

■ **FIGURE 3-14** Nicotine stomatitis biopsy specimen showing salivary duct metaplasia and inflammation.

cavity, oropharynx, and respiratory tract. Therefore, nicotine stomatitis should be viewed as a potential indicator of significant epithelial change at sites other than the hard palate.

Hairy Leukoplakia

Etiology and Pathogenesis. In 1984 an unusual white lesion along the lateral margins of the tongue, predominantly in gay men, was first described. Evidence indicates that this particular form of leukoplakia, known as hairy leukoplakia, represents an opportunistic infection that is related to the presence of Epstein-Barr virus (EBV) and is found almost exclusively in human immunodeficiency virus (HIV)–infected individuals. In a small percentage of cases, hairy leukoplakia may be seen in patients with other forms of immunosuppression, particularly those associated with organ transplantation (medically-induced immunosuppression), hematologic malignancy, and long-term use of systemic corticosteroids. A few cases have been reported in patients who are taking corticosteroids, and a few patients who are purported to be otherwise healthy.

The prevalence of hairy leukoplakia in HIV-infected patients has been declining as a result of new chemotherapeutic regimens for HIV. Of importance is that this lesion has been associated with subsequent or concomitant development of clinical and laboratory features of acquired immunodeficiency syndrome (AIDS) in as many as 80% of cases. A positive correlation with depletion of peripheral CD4 cells and with the presence of hairy leukoplakia has been noted. Several other oral conditions have been described as having greater than expected frequency in patients with AIDS (Box 3-5).

BOX 3-5 ORAL MANIFESTATIONS OF AIDS

INFECTIONS
Viral: herpes simplex, herpes zoster, hairy leukoplakia, cytomegalovirus, warts
Bacterial: tuberculosis, bacillary angiomatosis
Fungal: candidiasis, histoplasmosis

NEOPLASMS
Kaposi's sarcoma (HHV8)
Lymphomas, high grade

OTHER
Aphthous ulcers
Xerostomia
Gingivitis and periodontal disease

AIDS, Acquired immunodeficiency syndrome; *HHV8*, human herpesvirus 8.

The presence of EBV in hairy leukoplakia, as well as in the normal epithelium of patients with AIDS, has been confirmed. Through the use of molecular methods and ultrastructural analysis, viral particles have been localized within the nuclei and cytoplasm of the oral epithelial cells of hairy leukoplakia. Studies further indicate that this particular virus replicates within the oral hairy leukoplakia lesion. It is not understood why the lateral surface of the tongue is the favored site.

Clinical Features. Hairy leukoplakia presents as a well-demarcated white lesion that varies in architecture from a flat and plaquelike to a papillary/filiform or corrugated lesion (Figs. 3-15 and 3-16; Box 3-6). It may be unilateral or bilateral. A vast majority of cases have been located along the lateral margins of the tongue, with occasional extension onto the dorsal surface. Rarely, hairy leukoplakia may be seen on the buccal mucosa, the floor of the mouth, or the palate. Lesions have not been seen in the vaginal or anal mucosa.

In general, no associated symptoms have been reported, although associated infection with *Candida albicans* might call attention to the presence of this condition. In more severe cases, the patient may become visually aware of the lesion.

Histopathology. The characteristic microscopic feature of hairy leukoplakia is found in the nuclei of upper level keratinocytes (Fig. 3-17). Viral inclusions or peripheral displacement of chromatin with a resultant smudgy nucleus is

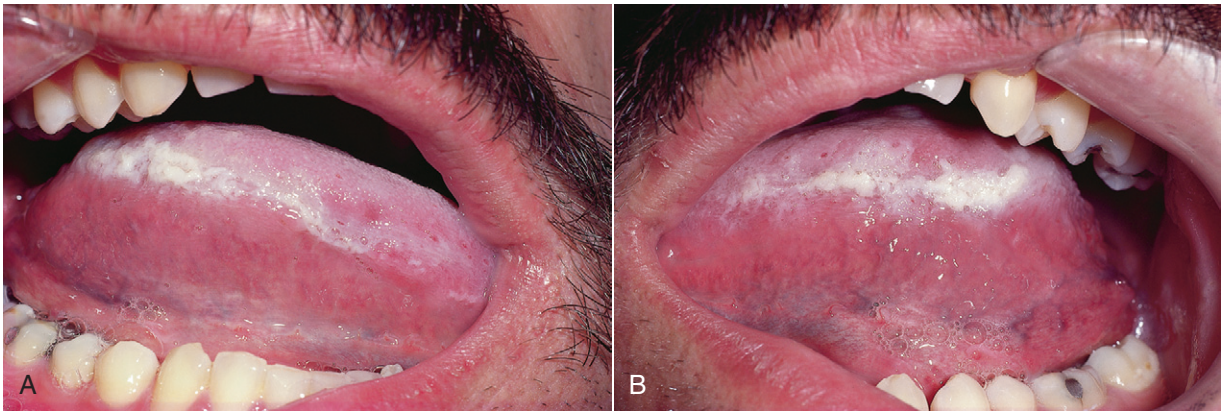

■ **FIGURE 3-15 A** and **B,** Hairy leukoplakia, bilateral.



■ **FIGURE 3-16** Hairy leukoplakia of the lateral and ventral tongue.

BOX 3-6 HAIRY LEUKOPLAKIA

ETIOLOGY

Associated with immunosuppression (esp. AIDS and organ transplantation)

Represents an opportunistic infection by Epstein-Barr virus

CLINICAL FEATURES

Most commonly seen on lateral tongue, often bilateral

Asymptomatic white lesion

Papillary, filiform, or plaquelike architecture

May occur before or after the diagnosis of AIDS

May be secondarily infected by *Candida albicans*

TREATMENT

None, unless cosmetically objectionable

Antiviral and antiretroviral agents likely to cause lesion to regress

evident. This is seen in the context of a markedly hyperparakeratotic surface, often with the formation of keratotic surface irregularities and ridges. *C. albicans* hyphae are often seen extending into the superficial epithelial cell layers. Beneath the surface, within the spinous cell layer, cells show ballooning degeneration and perinuclear clearing. A general paucity of subepithelial inflammatory cells has been noted, and Langerhans cells are scant.

In situ hybridization studies have demonstrated the presence of EBV within cells, showing nuclear inclusions and basophilic homogenization. Further confirmation has been accomplished by ultrastructural demonstration of intranuclear virions of EBV.

Differential Diagnosis. The clinical differential diagnosis of hairy leukoplakia includes idiopathic leukoplakia, frictional hyperkeratosis (tongue chewing), and leukoplakia associated with tobacco use. Other entities that might be considered are lichen planus, lupus erythematosus, and hyperplastic candidiasis.

Treatment and Prognosis. No specific treatment is available for hairy leukoplakia. For patients whose immune status is unknown and in whom biopsy findings indicate hairy leukoplakia, investigation for HIV infection or other causes of immunosuppression should be undertaken. Some discretion is required because a small percentage of patients with hairy leukoplakia is not associated with AIDS.

For cosmetic reasons, patients may request treatment of their lesions. Responses to acyclovir, ganciclovir, famciclovir, tretinoin, and podophyllum have been reported, with return of lesions often noted on discontinuation of therapy.

Approximately 10% of individuals with diagnosed hairy leukoplakia have AIDS at the time of diagnosis, and an additional 20% develop this disease in the following year. The probability that AIDS will develop in untreated HIV-positive individuals with HIV-associated hairy leukoplakia is approximately 50% within 1.5 years; within 2.5 years the probability is 80%.

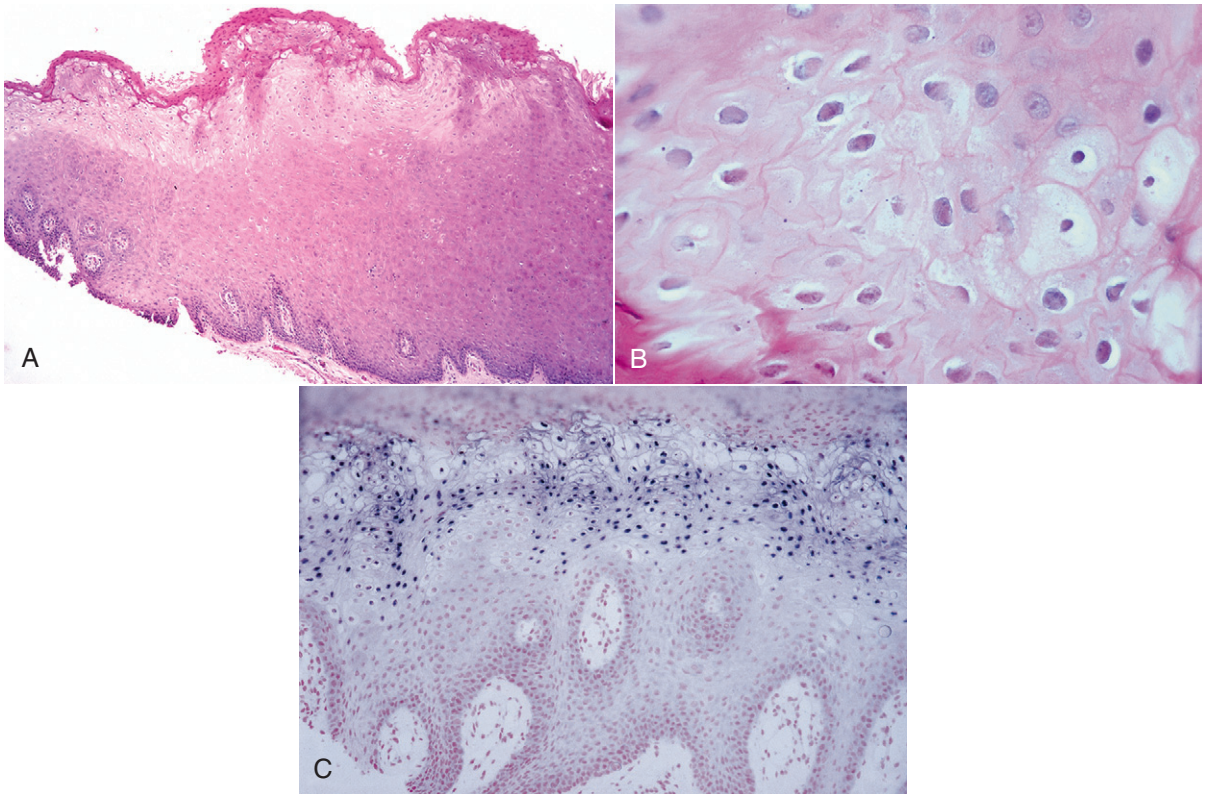

■ **FIGURE 3-17 A,** Hairy leukoplakia showing acanthosis, parakeratosis, and edema. **B,** Upper level keratinocytes showing nuclear viral inclusions. **C,** In situ hybridization for Epstein-Barr virus (EBV). Messenger RNA (mRNA) showing positive nuclear signal.

Hairy Tongue

Hairy tongue is a clinical term referring to a condition of filiform papillary overgrowth on the dorsal surface of the tongue of variable color.

Etiology. Numerous initiating or predisposing factors for hairy tongue have been identified. Broad-spectrum antibiotics, such as penicillin, and systemic corticosteroids are often identified in the clinical history of patients with this condition. In addition, oxygenating mouth rinses containing hydrogen peroxide, sodium perborate, and carbamide peroxide have been cited as possible etiologic agents in this condition. Hairy tongue may also be seen in individuals who are intense smokers, in those who have undergone radiotherapy to the head and neck region for malignant disease, and in patients who have undergone hematopoietic stem cell transplantation. The basic problem is believed to be related to an alteration in microbial flora, with attendant proliferation of fungi and chromogenic bacteria, along with papillary overgrowth.

Clinical Features. The clinical alteration translates to asymptomatic hyperplasia of the filiform papillae, with concomitant retardation of the normal rate of desquamation. The result is a thick, matted surface that serves to trap bacteria, fungi, cellular debris, and foreign material (Fig. 3-18; Box 3-7).



■ **FIGURE 3-18** Hairy tongue.

Hairy tongue is predominantly a cosmetic problem because symptoms are generally minimal. However, when extensive elongation of the papillae occurs, a gagging or a tickling sensation may be felt. The color may range from white to tan to deep brown or black, depending on diet, oral hygiene, oral medications, and the composition of the bacteria inhabiting the papillary surface.

BOX 3-7 HAIRY TONGUE

ETIOLOGY

Not well understood, believed to be related to alterations in oral flora

Initiating Factors

Use of broad-spectrum antibiotics, systemic corticosteroids, hydrogen peroxide

Intense smoking

Head and neck therapeutic radiation

CLINICAL FEATURES

Represents overgrowth of filiform papillae and chromogenic microorganisms

Dense hairlike mat formed by hyperplastic papillae on the dorsal tongue surface

Usually asymptomatic

May be cosmetically objectionable because of color (usually black)

TREATMENT

Identify and eliminate initiating factor identified and eliminated

Brush/scrape tongue with baking soda

Little significance other than cosmetic appearance

Histopathology. Microscopic examination of a biopsy specimen confirms the presence of elongated filiform papillae over the dorsum of the tongue, with surface contamination by clusters of microorganisms and fungi. The underlying lamina propria is generally mildly inflamed.

Diagnosis. Because the clinical features of this lesion are usually quite characteristic, confirmation by biopsy is not necessary. Cytologic or culture studies are of little value.

Treatment and Prognosis. Identification of a possible etiologic factor, such as antibiotics or oxygenating mouth rinses, is helpful. Discontinuing one of these agents should result in improvement within a few weeks. In other patients, brushing with a slurry of sodium bicarbonate (baking soda) in water or gentle once-daily scraping of the dorsum of the tongue may be beneficial. In individuals who have undergone radiotherapy with resultant xerostomia and altered bacterial flora, management is more difficult. Brushing the tongue and maintaining fastidious oral hygiene should be of some benefit (application of a 1% solution of podophyllum resin with thorough rinsing has also been described as a useful treatment). It is important to emphasize to patients that this process is entirely benign and self-limiting, and that the tongue should return to normal after physical debridement and proper oral hygiene have been instituted.

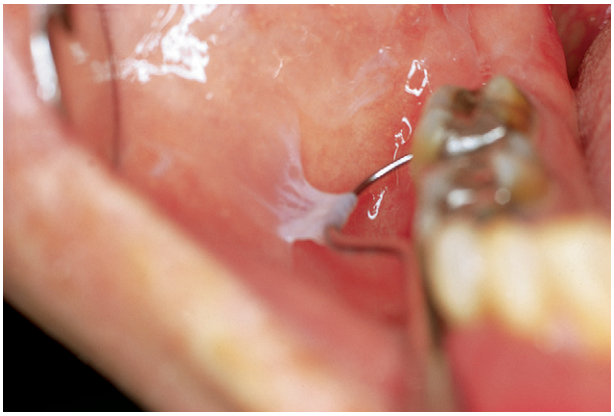

■ **FIGURE 3-19** Dentifrice-associated slough.

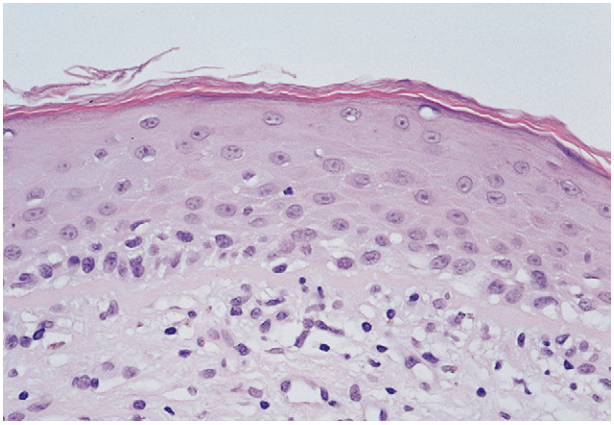

■ **FIGURE 3-20** Sanguinaria-associated keratosis, maxillary vestibule. (Reproduced with permission from Regezi JA, Sciubba JJ, Pogrel MA: Atlas of Oral and Maxillofacial Pathology. Philadelphia, 2000, WB Saunders, Figure 2-18.)

Dentifrice-Associated Slough

Dentifrice-associated slough is a relatively common phenomenon that has been associated with the use of several different brands of toothpaste. It is believed to be a superficial chemical burn or a reaction to a component in the dentifrice, possibly the detergent or flavoring compounds. This process may be related to the use of essential oil–containing mouth rinses. Clinically, it appears as a superficial whitish slough of the buccal mucosa, typically detected by the patient as oral peeling that easily swipes away (Fig. 3-19). The condition is painless and is not known to progress to anything significant. The problem resolves with a switch to another, blander toothpaste or mouth rinse.

White mucosal changes have been described in association with the use of toothpaste and mouthwashes containing the substance sanguinaria (Fig. 3-20). The alteration is typically seen in the maxillary vestibule, although other sites may be affected.

PRENEOPLASTIC AND NEOPLASTIC LESIONS

Actinic Cheilitis

Actinic, or solar, cheilitis represents accelerated tissue degeneration of the vermilion (dry mucous membrane) of the lips, especially the lower lip, as a result of chronic exposure to sunlight; it is considered to represent a potentially premalignant condition. This condition occurs almost exclusively in whites and is especially prevalent in those with fair skin.

Etiology and Pathogenesis. The wavelengths of light most responsible for actinic cheilitis and, in general, other degenerative actinically-related skin conditions are usually considered to be those between 2900 and 3200 nm (ultraviolet B [UVB]). This radiant energy affects not only the epithelium, but also the superficial supporting connective tissue.

Clinical Features. The affected vermilion of the lips takes on an atrophic, pale to silvery gray, glossy appearance, often with fissuring and wrinkling at right angles to the cutaneous-vermilion junction (Fig. 3-21; Box 3-8). Slightly firm, bilateral swelling of the lower lip is common. In advanced cases, the junction is irregular or totally effaced, with a degree of epidermization of the vermilion. Mottled areas of hyperpigmentation and keratosis are often noted, as well as superficial scaling, cracking, erosion, ulceration, and crusting (Fig. 3-22).

Histopathology. The overlying epithelium is typically atrophic and hyperkeratotic (Fig. 3-23). Basophilic changes in the submucosa (altered elastin that replaces normal collagen) and telangiectasia are also seen.

Treatment. Because of the positive relationship between exposure to UV light and carcinoma, lip protection is indicated. The use of lip balm containing a sunscreen agent such as para-aminobenzoic acid (PABA) or its derivatives is indicated during periods of sun exposure in high-risk patients.

BOX 3-8 ACTINIC CHEILITIS

ETIOLOGY
Overexposure to ultraviolet light (esp. UVB [2900 to 3200 nm])
Represents a premalignant lesion

CLINICAL FEATURES
Lower lip affected because of exposure to sun; upper lip usually with minimal change
More severe in light-skinned individuals
Atrophic, finely wrinkled, and often swollen appearance of lip
Possible presence of white and/or pigmented foci
Poorly defined vermilion–skin junction
Possible chronic ulceration in more severely damaged lips

TREATMENT
Avoidance of direct sunlight
Use of sunscreen/sun blocking agent
Biopsy of persistent ulcers and indurated lesions
Vermilionectomy possibly needed in problematic cases

UVB, Ultraviolet B.



■ **FIGURE 3-22** Actinic cheilitis with chronic ulcer.



■ **FIGURE 3-21** Actinic cheilitis.

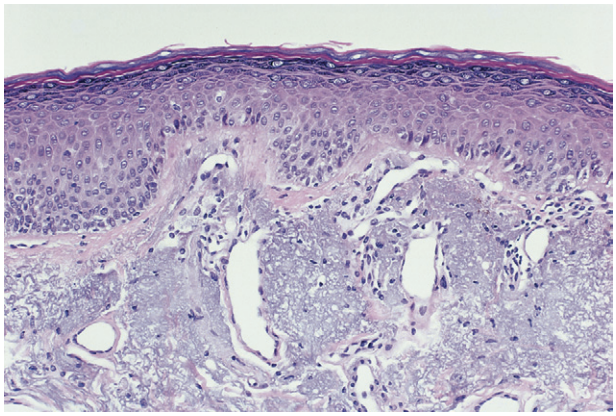

■ **FIGURE 3-23** Actinic cheilitis showing hyperkeratosis, basophilic change of collagen, and telangiectasias.

Sun-blocking agents such as titanium dioxide or zinc oxide provide complete protection from both ultraviolet A (UVA) and UVB rays.

Chronic sun damage mandates periodic examination and a biopsy if ulceration persists or if induration occurs. If atypical changes are noted within the epithelium, a vermilionectomy may be performed in association with mucosal advancement to replace the damaged vermilion. This operation is associated with some morbidity, primarily related to lip paresthesia, therefore prompting some to advocate wedge excision for suspicious lesions. Acceptable results are attainable with the use of laser surgery or cryosurgery, as well as with topical 5-fluorouracil. Topical imiquimod, an immune stimulant, has been used with clearing of lesions noted within 4 weeks of treatment completion.

Actinic Keratoses (Solar Keratoses)

Actinic keratoses of the skin, the cutaneous counterpart of actinic cheilitis, are epithelial changes noted typically in light-complexioned individuals who have had long-term exposure to sunlight. A small percentage of these lesions develop into squamous cell carcinoma. Outdoor workers and individuals participating in extensive outdoor recreation are particularly prone to the development of actinic keratoses.

Oval plaques, usually smaller than 1 cm in diameter, are typically found on the forehead, cheeks, temples, ears, and lateral portions of the neck. The color may vary from yellow-brown to red, and the texture is usually rough and sandpaper-like.

Common to the many actinic keratosis microscopic subtypes are nuclear atypia, an increased nuclear-cytoplasmic ratio, and atypical proliferation of basal cells. The dermis generally contains a lymphocytic inflammatory cell infiltrate. Elastotic or basophilic changes in collagen and irregular clumps of altered elastic fibers and regenerated collagen are noted in these areas.

Individual actinic keratoses may be treated with cryotherapy. However, in patients with confluent actinic keratoses, the therapeutic mainstay is topical application of 5-fluorouracil. Additional treatment modalities include curettage and surgical excision. For lesions that are indurated or nodular, or that demonstrate marked inflammation, a biopsy to rule out invasive squamous cell carcinoma is necessary.

Idiopathic Leukoplakia

Leukoplakia is a clinical term indicating a white patch or plaque of oral mucosa that cannot be rubbed off and cannot be characterized clinically as any other disease. This excludes lesions such as lichen planus, candidiasis, leukoedema, WSN, and obvious frictional keratosis. Leukoplakias may have similar clinical appearances but have a considerable degree of microscopic heterogeneity. Because leukoplakia may range microscopically from benign hyperkeratosis to invasive squamous cell carcinoma, a biopsy is mandatory to establish a definitive diagnosis.

Etiology and Pathogenesis. Many cases of leukoplakia are etiologically related to the use of tobacco in smoked or smokeless forms and may regress after discontinuation of tobacco use. Other factors, such as alcohol abuse, trauma, and *C. albicans* infection, may have a role in the development of leukoplakia. Nutritional factors have been cited as important, especially relative to iron deficiency anemia and development of sideropenic dysphagia (Plummer-Vinson or Paterson-Kelly syndromes).

Rates of transformation to squamous cell carcinoma have varied from study to study as a result of differences in the underlying pathology and differences in the use of putative carcinogens such as tobacco. Geographic differences in the transformation rate, as well as in the prevalence and location of oral leukoplakias, are likely related to differences in tobacco habits in various parts of the world. In U.S. populations, a majority of oral leukoplakias are benign and probably never become malignant. Approximately 5% of leukoplakias are malignant at the time of first biopsy, and approximately 5% of the remainder undergo subsequent malignant transformation. From 10% to 15% of dysplasias that present as clinical leukoplakia will develop into squamous cell carcinoma (Figs. 3-24 and 3-25). Wide ranges in risk of transformation have been observed from one anatomic site to another, such as the floor of the mouth, where transformation rates are comparatively high, although paradoxically many show only minimal amounts of epithelial dysplasia.

Clinical Features. Leukoplakia is a condition associated with middle-aged and older populations. A vast majority of cases occur after the age of 40 years. Over time, a shift in gender predilection has been noted, with near parity in the incidence of leukoplakia, apparently as a result of the change in smoking habits of women.

Predominant sites of occurrence have changed through the years (Box 3-9). At one time, the tongue was the most common site for leukoplakia, but this area has given way to

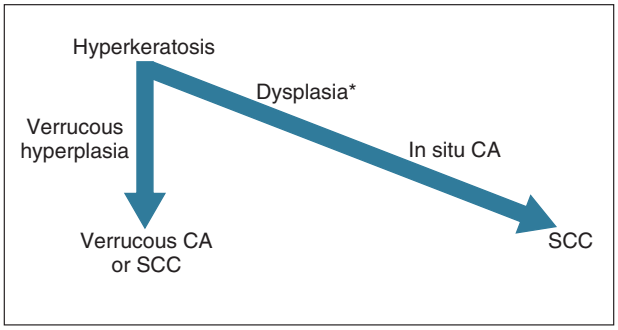

■ **FIGURE 3-24** Idiopathic leukoplakia pathogenesis. *Malignant transformation 10% to 15%.

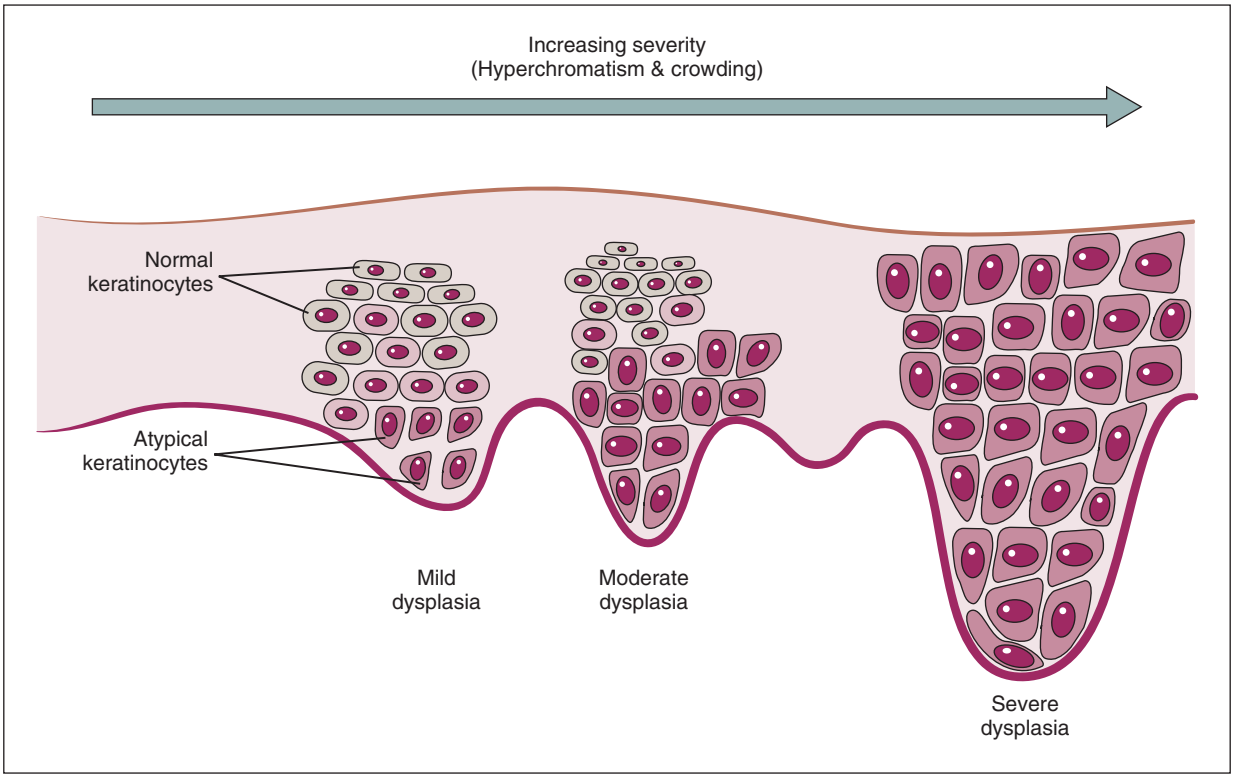

■ **FIGURE 3-25** Progression of dysplasia.

BOX 3-9 IDIOPATHIC LEUKOPLAKIA

RISK FACTORS
Tobacco, alcohol, nutrition, unknown

SITES OF OCCURRENCE
Vestibule, buccal > palate, alveolar ridge, lip > tongue, floor

HIGH-RISK SITES FOR MALIGNANT TRANSFORMATION
Floor > tongue > lip > palate > buccal > vestibule > retromolar

AGE
Usually over 40 years

MICROSCOPIC DIAGNOSES AT FIRST DIAGNOSIS
Hyperkeratosis—80%
Dysplasia—12%
In situ carcinoma—3%
Squamous cell carcinoma—5%

TRANSFORMATION RATES
All idiopathic leukoplakias—5% to 10%
All dysplasias—10% to 15%

>, More frequently affected.



■ **FIGURE 3-26** Idiopathic leukoplakia of the floor of the mouth. The microscopic diagnosis was hyperkeratosis.

the mandibular mucosa and the buccal mucosa, which account for almost half of leukoplakias (Figs. 3-26 to 3-29). The palate, maxillary ridge, and lower lip are somewhat less often involved, and the floor of the mouth and retromolar sites are involved less often.

The relative risk of neoplastic transformation varies from one region to another. Although the floor of the mouth accounts for a relatively small percentage (10%) of leukoplakias, a large percentage of leukoplakias at this site are found to be dysplasia, carcinoma in situ, or invasive carcinoma when examined microscopically. Leukoplakia of the lips and

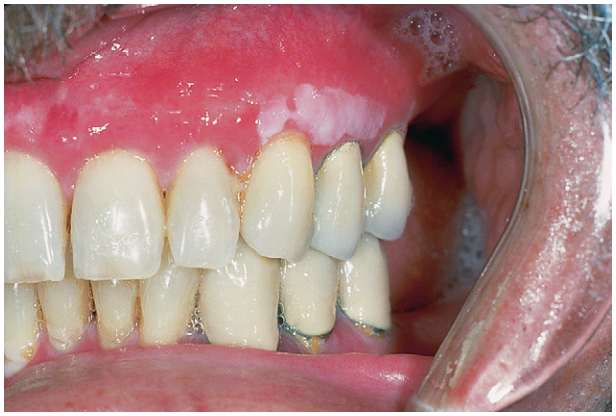

■ **FIGURE 3-27** Idiopathic leukoplakia of the gingiva. The microscopic diagnosis was hyperkeratosis.



■ **FIGURE 3-28** Idiopathic leukoplakia of the lateral tongue. The microscopic diagnosis was dysplasia.



■ **FIGURE 3-29** Idiopathic leukoplakia of the lateral tongue. The microscopic diagnosis was squamous cell carcinoma.

tongue also exhibits a relatively high percentage of dysplastic or neoplastic change. In contrast to these sites, the retromolar area exhibits these changes in only about 10% of cases.

On visual examination, leukoplakia may vary from a barely evident, vague whiteness on a base of uninflamed, normal-appearing tissue to a definitive white, thickened, leathery, fissured, verrucous (wartlike) lesion. Red zones may also be seen in some leukoplakias, prompting use of the term *speckled leukoplakia (erythroleukoplakia)*. Risk of malignant transformation of speckled leukoplakia is greater than lesions that are homogeneous. On palpation, lesions may be soft, smooth, or finely granular. Other lesions may be roughened, nodular, or indurated.



■ **FIGURE 3-30** Proliferative verrucous leukoplakia.

Proliferative verrucous leukoplakia (PVL) has been segregated from other leukoplakias. This type of leukoplakia begins as simple keratosis and eventually becomes verrucous in nature (Fig. 3-30). Lesions tend to be persistent, multifocal, recurrent, and sometimes locally infiltrative. Metastasis to regional lymph nodes is uncommon. The cause of PVL is unknown, although early reports suggest a relationship in some lesions with human papillomavirus, but this has not been substantiated. The typical patient with PVL more often is female than male, and traditional risk factors attributed to oral cancer such as tobacco and alcohol use are strongly lacking. The diagnosis is determined clinicopathologically and usually is made retrospectively. Malignant transformation to verrucous or squamous cell carcinoma from precursor lesions is greater than in epithelial dysplasia and may occur in up to 80% of cases.

Histopathology. Histologic changes range from hyperkeratosis, dysplasia, and carcinoma in situ to invasive squamous cell carcinoma (Figs. 3-31 to 3-33). The term *dysplasia* indicates abnormal epithelium and disordered growth, whereas *atypia* refers to abnormal nuclear features (Box 3-10). Increasing degrees of dysplasia are designated as mild, moderate, and severe and are subjectively determined microscopically. Specific microscopic characteristics of dysplasia include (1) drop-shaped epithelial ridges, (2) basal cell crowding, (3) irregular stratification, (4) increased and abnormal mitotic figures, (5) premature keratinization, (6) nuclear pleomorphism and hyperchromatism, and (7) an increased nuclear-cytoplasmic ratio.

It is generally accepted that the more severe the epithelial changes, the more likely a lesion is to evolve into cancer.

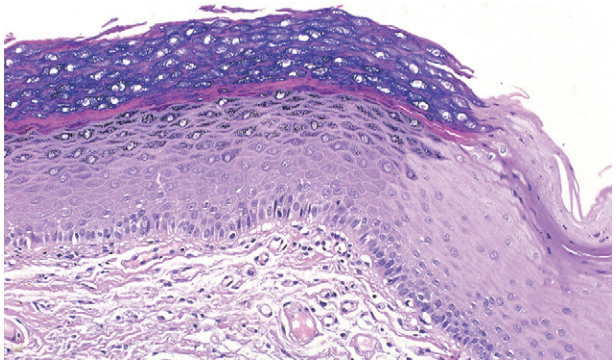

■ **FIGURE 3-31** Idiopathic leukoplakia diagnosed as hyperkeratosis.

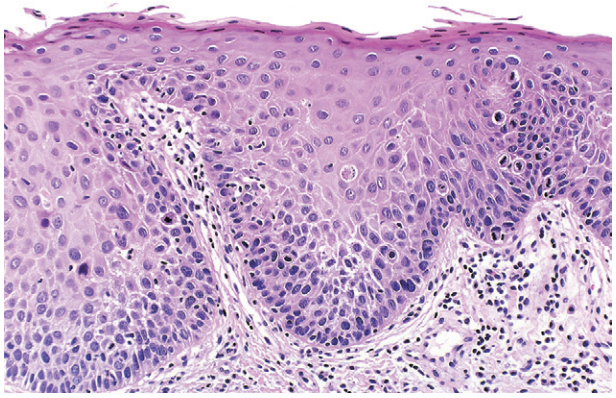

■ **FIGURE 3-32** Idiopathic leukoplakia diagnosed as moderate dysplasia.

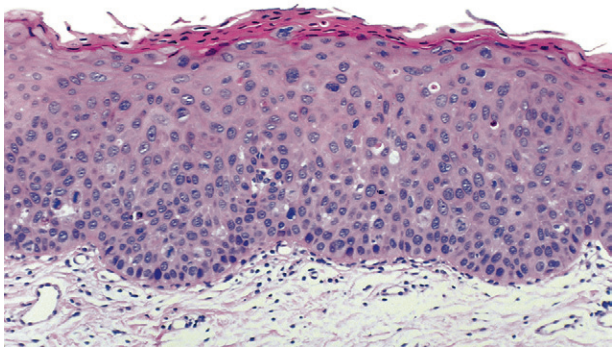

■ **FIGURE 3-33** Idiopathic leukoplakia diagnosed as severe dysplasia.

However, no way is known to predict microscopically which dysplasias, mild to severe, will progress to squamous cell carcinoma. To date, no consistently reliable molecular or chemical biomarkers are used to further identify those dysplasias that are more likely to progress to invasive cancer. When the entire thickness of epithelium is involved with these changes in a so-called top-to-bottom pattern, the term *carcinoma in situ* may be used. Carcinoma in situ may also be designated when cellular atypia is particularly severe, even though changes may not be evident from basement membrane to surface. Carcinoma in situ is not regarded as a reversible lesion, although it may take many years for invasion to occur. A majority of squamous cell carcinomas of the upper aerodigestive tract, including the oral cavity, are preceded by epithelial dysplasia. Conceptually, invasive carcinoma begins when a microfocus of epithelial cell invades the lamina propria 1 to 2 mm beyond the basal lamina. At this early stage, the risk of regional metastasis is low.

BOX 3-10 DYSPLASIA: MICROSCOPIC FEATURES

EPITHELIAL ARCHITECTURE
Drop-shaped epithelial ridges
Basal cell crowding
Irregular stratification
Reduced intercellular adhesion

CYTOLOGIC ATYPIA
Pleomorphic nuclei—hyperchromatic, smudgy, angular
Increased nuclear-cytoplasmic ratios
Increased and abnormal mitoses

Differential Diagnosis. The first step in developing a differential diagnosis for a white patch (leukoplakia) on the oral mucosa is to determine whether the lesion can be removed with a gauze square or a tongue blade. If the lesion can be removed, it may represent a pseudomembrane, a fungus colony, or debris. If bilateral buccal mucosal disease is evident, hereditary conditions, cheek chewing, lichen planus, and LE should be considered. Concomitant cutaneous lesions would give weight to the latter two. If chronic trauma or tobacco use is elicited in the patient's history, frictional or tobacco-associated hyperkeratosis, respectively, should be considered. Elimination of a suspected cause should result in some clinical improvement. Hairy leukoplakia and geographic tongue would also be included in a differential diagnosis for tongue leukoplakia.

If the lesion in question is not removable and is not clinically diagnostic, it should be considered an idiopathic leukoplakia and a biopsy should be performed. For extensive lesions, multiple biopsies may be necessary to avoid sample error. The clinically most suspicious areas (red, ulcerated, or indurated areas) should be included in the area to be biopsied.

Clinical investigators have suggested that *alveolar ridge keratosis* is a distinct entity and should be separated from other oral (premalignant) leukoplakias. Alveolar ridge keratoses appear to be caused by chronic friction and when biopsied are diagnosed as benign keratosis (more than 97% have been found to represent hyperkeratosis without dysplasia). Lesions present as asymptomatic white plaques or papules on the mandibular or maxillary alveolar ridges, attached gingiva or retromolar pad, or areas of frictional or occlusal trauma. Microscopically, simple hyperorthokeratosis without

significant underlying inflammation is seen. Studies using immunomarkers specific for dysplasia have been negative. Clinical judgment is necessary to determine whether biopsy is in the best interest of the patient.

Treatment and Prognosis. In the absence of dysplastic or atypical epithelial changes, periodic examination and rebiopsy of new suspicious areas of leukoplakia are recommended. If a lesion is mildly dysplastic, some clinical judgment should be exercised in patient management. Removal of mildly dysplastic lesions is in the patient's best interest if no causative factor is apparent and the lesion is small (Fig. 3-34). If considerable morbidity would result because of the lesion's size or location, follow-up surveillance is acceptable, provided the degree of epithelial dysplasia is mild.

Surgical excision and other physical forms of ablation are the currently preferred treatment modalities, although these strategies may not eliminate or significantly reduce the risk of recurrence or malignant transformation. Medical management of dysplastic lesions with the use of topical agents has not proved effective. If leukoplakia is diagnosed as moderate to severe dysplasia, excision becomes obligatory. Although surgical excision may not alter the natural history of the disease and is often followed by recurrence, excision offers the opportunity to examine the lesion histologically in its entirety for the presence or absence of higher grades of dysplasia or carcinoma. Various surgical methods such as scalpel excision, cryosurgery, electrosurgery, and laser surgery seem to be equally effective in ablating these lesions. For large lesions, grafting procedures may be necessary after surgery. It is important to note that many idiopathic leukoplakias may recur after complete removal. It is impossible to predict which lesions will return and which will not. Although the risk of malignant transformation of oral leukoplakia is low, long-term follow-up is mandatory, and repeat biopsy should be considered if the clinical findings dictate.

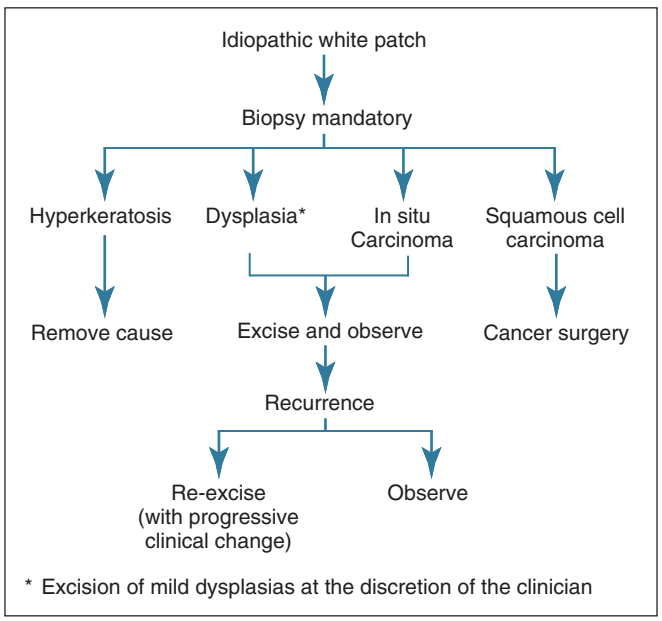

■ **FIGURE 3-34** Idiopathic leukoplakia: diagnosis and management.

OTHER WHITE LESIONS

Geographic Tongue

Etiology. Geographic tongue, also known as *erythema migrans* and *benign migratory glossitis,* is a condition of unknown cause. Geographic tongue is more prevalent among whites and blacks than Mexican Americans, and it is strongly associated with fissure tongue but is inversely associated with cigarette smoking. In a few patients, emotional stress may enhance the process. Geographic tongue has been associated, coincidentally, with several different conditions, including psoriasis, seborrheic dermatitis, Reiter's syndrome, and atopy.

Clinical Features. Geographic tongue is seen in approximately 2% of the U.S. population and affects women slightly more often than men (Box 3-11). It is more prevalent in the young, in nonsmokers, and in allergic or atopic individuals. Children between infancy and 10 years of age may be affected in up to 18% of cases. Geographic tongue is characterized initially by the presence of atrophic patches surrounded by elevated keratotic margins. The desquamated areas appear red and may be slightly tender (Figs. 3-35 to 3-38). When followed over a period of days or weeks, the pattern changes, appearing to move across the dorsum of the tongue. A strong association has been noted between geographic tongue and

BOX 3-11 GEOGRAPHIC TONGUE

ETIOLOGY
Unknown

CLINICAL FEATURES
Usually discovered as incidental finding on oral examination
Common; 2% of U.S. population affected
Appears as red atrophic patches surrounded by hyperkeratotic (white) margins
Dorsum and lateral surfaces of tongue usually affected; rarely other mucosal sites
Pattern changes with time (migratory glossitis)
Often seen in company with fissured tongue
Spontaneous regression/worsening
Usually asymptomatic, but may be slightly painful

TREATMENT
Usually none
When painful, baking soda rinses, antifungals, or topical corticosteroids may help.



■ **FIGURE 3-35** Geographic tongue.



■ **FIGURE 3-36** Geographic tongue.



■ **FIGURE 3-37** Geographic tongue.

fissured (plicated) tongue. The significance of this association is unknown, although symptoms may be more common when fissured tongue is present, presumably because of secondary fungal infection in the base of the fissures.

Rarely, similar alterations have been described in the floor of the mouth, the buccal mucosa, and the gingiva. Red atrophic lesions and white keratotic margins mimic the lingual counterparts.



■ **FIGURE 3-38** Geographic tongue.

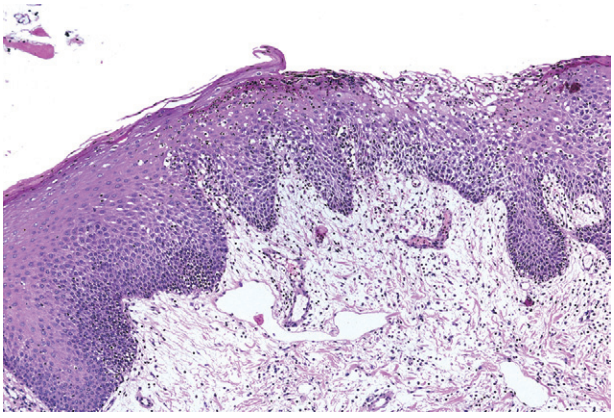

■ **FIGURE 3-39** Geographic tongue biopsy specimen showing hyperkeratotic epithelium adjacent to edematous and inflamed epithelium.

Although most patients with geographic tongue are asymptomatic, patients occasionally report irritation or tenderness, especially in relation to the consumption of spicy foods and alcoholic beverages. The severity of symptoms varies over time and is often an indicator of the intensity of lesional activity. Lesions periodically disappear and recur for no apparent reason.

Histopathology. Filiform papillae are atrophic, and the margins of the lesion demonstrate hyperkeratosis and acanthosis (Fig. 3-39). Closer to the central portion of the lesion, corresponding to the circinate erythematous areas, loss of keratin is noted, along with intraepithelial neutrophils and lymphocytes. Leukocytes are often noted within a microabscess near the surface. An inflammatory cell infiltrate within the underlying lamina propria, consisting chiefly of neutrophils, lymphocytes, and plasma cells, is seen. Although the histologic picture is reminiscent of psoriasis, a clinical link between geographic tongue and cutaneous psoriasis has not been substantiated and is likely coincidental.

Differential Diagnosis. Based on clinical appearance, geographic tongue is usually diagnostic. Only rarely might a

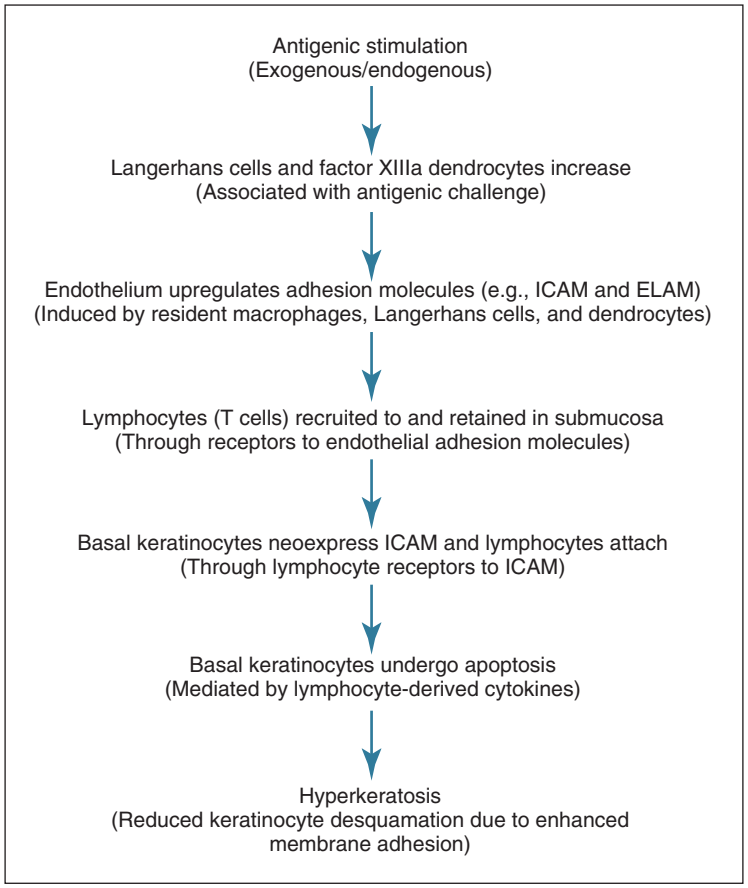

■ **FIGURE 3-40** Lichen planus: hypothetical molecular events.

biopsy be required for a definitive diagnosis. In equivocal cases, clinical differential diagnosis might include candidiasis, leukoplakia, lichen planus, and lupus erythematosus.

Treatment and Prognosis. Because of the self-limiting and usually asymptomatic nature of this condition, treatment is not required. However, when symptoms occur, treatment is empirical. Considerable benefit may be gained by keeping the mouth clean using a mouth rinse composed of sodium bicarbonate in water. Topical steroids, especially those containing an antifungal agent, may be helpful in reducing symptoms. Reassuring patients that this condition is totally benign and does not portend more serious disease helps relieve anxiety.

Lichen Planus

Lichen planus is a chronic mucocutaneous disease of unknown cause, with oral lesions occurring most commonly in women between 30 and 60 years of age. It is relatively common, affecting between 0.2% and 2% of the population. In the oral mucosa, it typically presents as bilateral white lesions, occasionally with associated ulcers. The importance of this disease is related to its frequency of occurrence, its occasional similarity to other mucosal diseases, its occasionally painful and persistent nature, and its possible relationship to squamous cell carcinoma.

Etiology and Pathogenesis. Although the cause of lichen planus is unknown, it is generally considered to be an immunologically-mediated process that microscopically resembles a hypersensitivity reaction (Fig. 3-40). In a minority of patients, possible initiators include dental materials, stress, drugs, and infectious agents. It is characterized by an intense T-cell infiltrate (CD4 and especially CD8 cells) localized along the epithelial–connective tissue interface. Other immune-regulating cells (macrophages, factor XIIIa–positive dendrocytes, Langerhans cells) are seen in increased numbers in lichen planus tissue. The disease mechanism appears to involve several steps that could be described as follows: an initiating factor/event, focal release of regulatory cytokines, upregulation of vascular adhesion molecules, recruitment and retention of T cells, and cytotoxicity of basal keratinocytes mediated by T cells.

The factor that initiates lichen planus is unknown. It is apparent, however, that recruitment and retention of lymphocytes is a requisite process. From what is known of leukocyte kinetics in tissue, attraction of lymphocytes to a

particular site would require cytokine-mediated upregulation of adhesion molecules on endothelial cells and concomitant expression of receptor molecules by circulating lymphocytes. In oral lichen planus, increased expression of several vascular adhesion molecules is in fact noted (known by acronyms ELAM-1 [endothelial leukocyte adhesion molecule 1], ICAM-1 [intercellular adhesion molecule 1], and VCAM-1 [vascular cell adhesion molecule 1]), along with infiltrating lymphocytes that express reciprocal receptors (known as L-selectin, LFA-1 [lymphocyte function–associated antigen], and VLA-4 [very late activation antigen 4]), supporting the hypothesis that a lymphocyte homing mechanism is activated in lichen planus. Induction of TH1 cytokines appears to be an early and important event in this process. Some of the cytokines believed to be responsible for the upregulated adhesion molecules are tumor necrosis factor-alpha (TNF-α), interleukin-1, and interferon-α. The source of these cytokines is thought to be resident macrophages, factor XIIIa–positive dendrocytes, Langerhans cells, or the lymphocytes themselves.

The overlying keratinocytes in lichen planus have a significant role in disease pathogenesis. They may be another source of the chemoattractive and proinflammatory cytokines mentioned earlier; more important, they appear to be the immunologic target of the recruited lymphocytes. This latter role seems to be enhanced through keratinocyte expression of the adhesion molecule ICAM-1, which would be attractive to lymphocytes with corresponding receptor molecules (LFA-1). This could set up a favorable relationship between T cells and keratinocytes for cytotoxicity. The T cells appear to mediate basal cell death through the triggering of apoptosis.

Clinical Features. Lichen planus is a disease of middle age that affects women more frequently, with children rarely affected (Box 3-12). The severity of the disease often parallels the patient's level of stress, although no evidence suggests that stress alone is a cause of this condition; it appears to be a modifying factor in some cases. An association between lichen planus and hepatitis C infection has been suggested, with a concomitant geographic influence or cofactor proposed. No relationship between lichen planus and hypertension or diabetes mellitus, as was previously proposed, has been noted. Many of these cases likely represent lichenoid drug reactions to the medications used to manage these conditions, which may mimic lichen planus clinically.

Several types of lichen planus within the oral cavity have been described. The most common type is the *reticular form,* which is characterized by numerous interlacing white keratotic lines or striae (so-called Wickham's striae) that produce an annular or lacy pattern. The buccal mucosa is the site most commonly involved (Figs. 3-41 to 3-46). Striae, although occurring typically in a symmetric pattern on the buccal mucosa bilaterally, may also be noted on the tongue and less commonly on the gingiva and the lips. Almost any mucosal tissue may demonstrate manifestations of lichen planus. This form generally presents with minimal clinical symptoms and is often an incidental discovery.

BOX 3-12 LICHEN PLANUS

CAUSE
Unknown; basal keratinocyte destruction by T cells

CLINICAL FEATURES
Adults; relatively common (0.2% to 2% of population); persistent
White keratotic striae characteristic
Types—reticular, erosive (ulcerative), plaque, papular, erythematous (atrophic)
Pain—erosive form (occasionally erythematous form)

POSSIBLE RISK OF CARCINOMA
Transformation
May be slightly increased with erosive form (0.4% to 2.5% of cases)

PATHOLOGY
Interface mucositis with hyperkeratosis

TREATMENT
Observation, topical and systemic corticosteroids, or other immunosuppressive agents

The *plaque form* of lichen planus tends to resemble leukoplakia clinically but has a multifocal distribution. Such plaques generally range from slightly elevated to smooth and flat. The primary sites for this variant are the dorsum of the tongue and the buccal mucosa.

The *erythematous* or *atrophic* form of lichen planus appears as red patches with very fine white striae. It may be seen in conjunction with reticular or erosive variants. The proportion of keratinized areas to atrophic areas varies from one area to another. The attached gingiva, commonly involved in this form of lichen planus, exhibits a patchy distribution, often in four quadrants. Patients may complain of burning, sensitivity, and generalized discomfort.

In the *erosive form* of lichen planus, the central area of the lesion is ulcerated. A fibrinous plaque or pseudomembrane covers the ulcer. The process is a rather dynamic one, with changing patterns of involvement noted from week to week. Careful examination usually demonstrates keratotic striae peripheral to the site of erosion, along with erythema.

A rarely encountered form of lichen planus is the *bullous variant.* Bullae range from a few millimeters to centimeters in diameter. Such bullae are generally short lived and, on rupturing, leave a painful ulcer. Lesions are usually seen on the buccal mucosa, especially in the posterior and inferior regions adjacent to the second and third molars. Lesions are less common on the tongue, gingiva, and inner aspect of the lips. Reticular or striated keratotic areas should be seen with this variant of lichen planus.

On the skin, lichen planus is characterized by the presence of small, violaceous, polygonal, flat-topped, pruritic

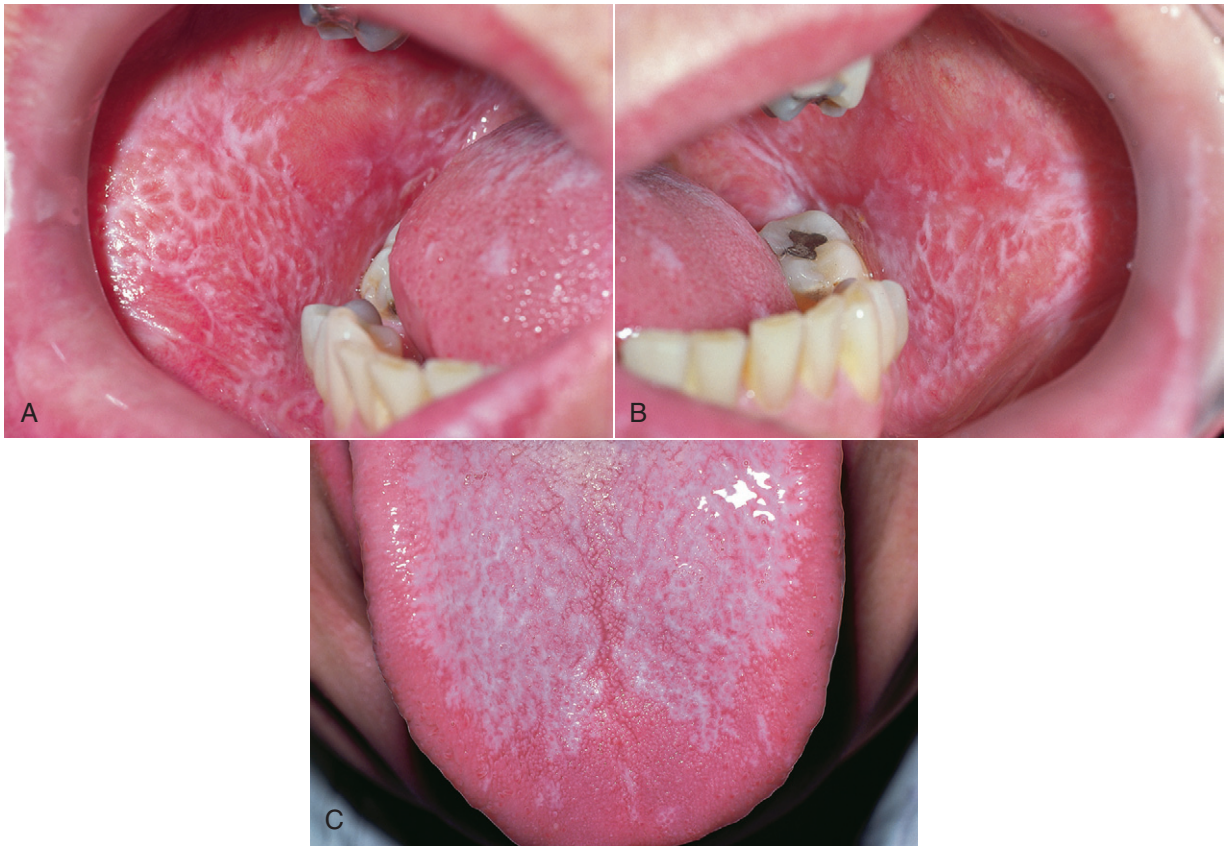

■ **FIGURE 3-41 A** through **C,** Oral lichen planus, reticular form.



■ **FIGURE 3-42** Oral lichen planus, erosive form.



■ **FIGURE 3-43** Erosive lichen planus of the lip.

papules on the flexor surfaces of the forearm and anterior tibial surfaces. Other clinical varieties include hypertrophic, atrophic, bullous, follicular, and linear forms. Cutaneous lesions have been reported in 20% to 60% of patients with oral lichen planus. Although the oral changes are relatively persistent over time, corresponding skin lesions tend to wax and wane and exhibit a relatively short natural history (1 to 2 years).

Histopathology. The microscopic criteria for lichen planus include hyperkeratosis, basal layer vacuolization with apoptotic keratinocytes, and a lymphophagocytic infiltrate at the epithelium–connective tissue interface (Figs. 3-47 to 3-50). Over time, the epithelium undergoes gradual remodeling, resulting in reduced thickness and occasionally a sawtooth rete ridge pattern. Within the epithelium are increased numbers of Langerhans cells (as demonstrated by

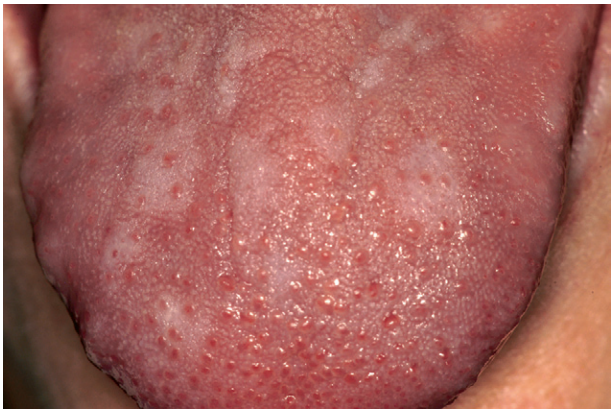

■ **FIGURE 3-44** Oral lichen planus, plaque form.



■ **FIGURE 3-45** Erythematous lichen planus of the gingiva.



■ **FIGURE 3-46** Cutaneous lichen planus of the ankle.

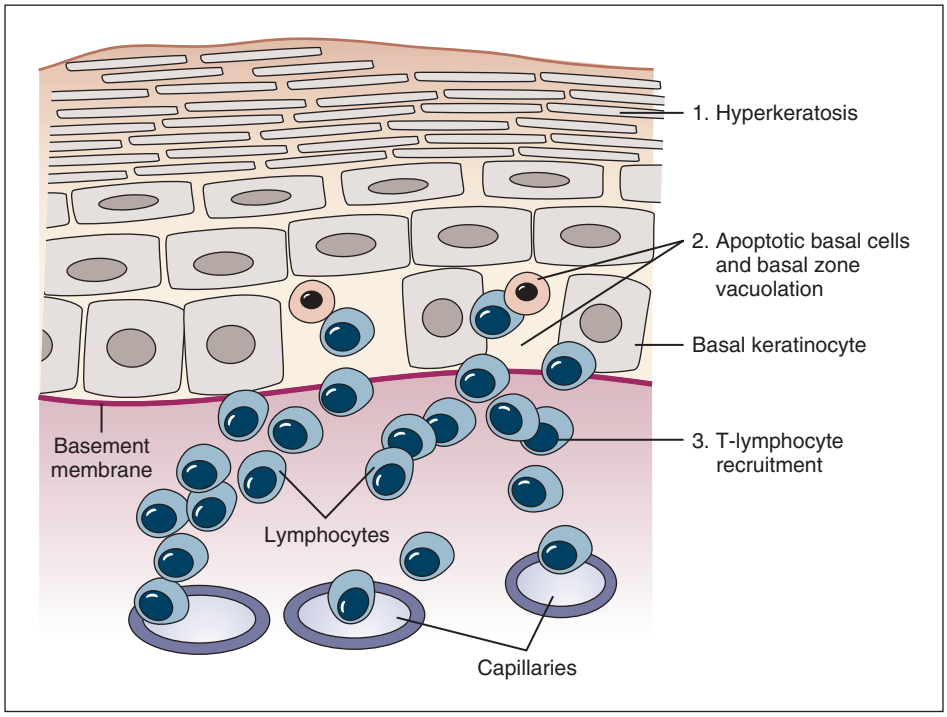

■ **FIGURE 3-47** Lichen planus: diagnostic features.

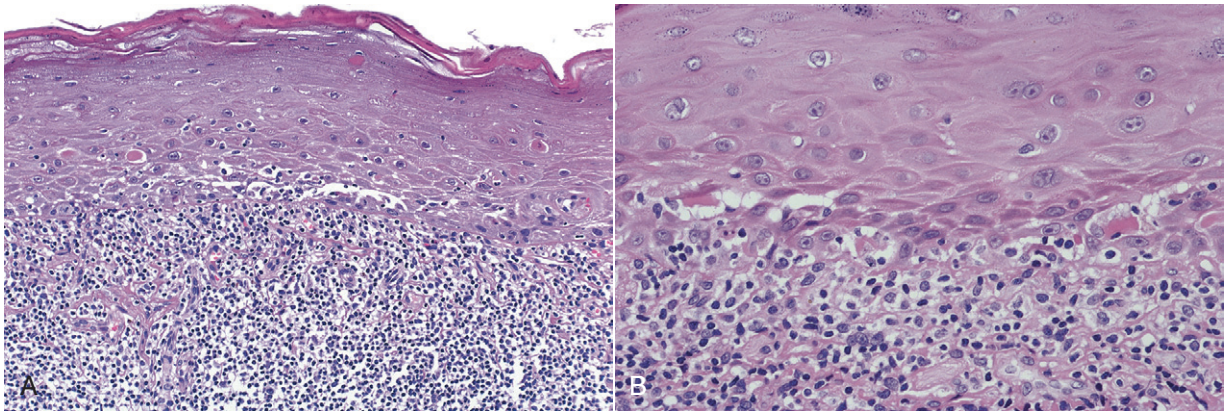

■ **FIGURE 3-48** Lichen planus biopsy specimen showing hyperkeratosis, interface lymphocytic infiltrate, and basilar vacuolization with apoptosis.

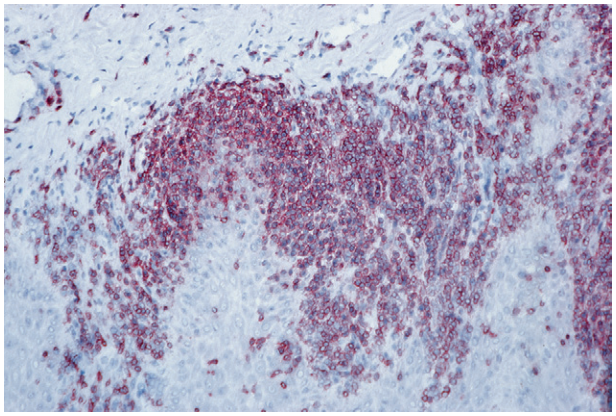

■ **FIGURE 3-49 Lichen planus.** Immunohistochemical stain for CD3 antigen demonstrating that infiltrate consists of predominantly T cells.

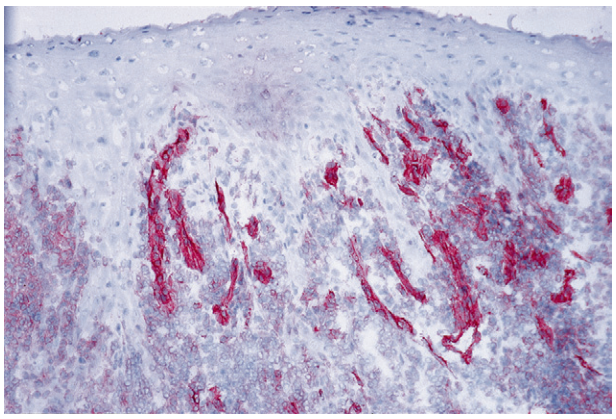

■ **FIGURE 3-50 Lichen planus.** Immunohistochemical stain for platelet endothelial cell adhesion molecule (PECAM; CD31) antigen showing adhesion molecule overexpression on capillaries *(dark red)* and lymphocytes.

immunohistochemistry), presumably processing and presenting antigens to subjacent T cells. Discrete eosinophilic ovoid bodies representing the apoptotic keratinocytes are noted at the basal zone. These colloid, or Civatte, bodies are seen in other conditions such as drug reactions, contact hypersensitivity, LE, and some nonspecific inflammatory reactions.

Direct immunofluorescence demonstrates the presence of fibrinogen in the basement membrane zone in 90% to 100% of cases. Although immunoglobulins and complement factors may be found as well, they are far less common than fibrinogen deposits.

Differential Diagnosis. Other diseases with a multifocal bilateral presentation that should be included in a clinical differential diagnosis are lichenoid drug reaction, LE, white sponge nevus, hairy leukoplakia, cheek chewing, graft-versus-host disease, and candidiasis. Idiopathic leukoplakia and squamous cell carcinoma might be considered when lesions are plaquelike. Erosive or atrophic lichen planus affecting the attached gingiva must be differentiated from cicatricial pemphigoid, pemphigus vulgaris, chronic LE, contact hypersensitivity, and chronic candidiasis.

Treatment and Prognosis. Although oral lichen planus generally cannot be cured, some drugs can provide satisfactory control. Corticosteroids are the single most useful group of drugs in the management of lichen planus. The rationale for their use is their ability to modulate inflammation and the immune response. Topical application and local injection of steroids have been used successfully in controlling but not curing this disease. In circumstances in which symptoms are severe, systemic steroids may be used for initial management. The addition of antifungal therapy to a corticosteroid regimen typically enhances clinical results. This is likely a result of elimination of secondary *C. albicans* growth in lichen planus–involved tissue. Antifungals also prevent the overgrowth of *C. albicans* that may be associated with topical

corticosteroid use. Application of topical calcineurin inhibitors such as tacrolimus and pimecrolimus can be used in steroid-resistant cases, although the response tends to be less dramatic than with topical steroids.

Because of their antikeratinizing and immunomodulating effects, systemic and topical vitamin A analogs (retinoids) have been used in the management of lichen planus. Reversal of white striae can be achieved with topical retinoids, although the effects may be only temporary. Systemic retinoids have been used in cases of severe lichen planus with various degrees of success. The benefits of systemic therapy must be weighed carefully against the rather significant side effects, that is, cheilitis, elevation of serum liver enzyme and triglyceride levels, and teratogenicity. In cases with significant tissue involvement, more than one drug may be indicated. Various combinations of systemic steroids, topical steroids, calcineurin inhibitors, and retinoids may be used with some success. Some cases of oral lichen planus may respond to systemic hydroxychloroquine.

Clinical overdiagnosis of lichen planus, coincidental occurrence of lichen planus and oral cancer, and microscopic confusion with dysplasias that have lichenoid features have contributed to the controversy over malignant potential of this disease. Nonetheless, it appears that there is a bona fide risk that oral squamous cell carcinoma will develop in oral lichen planus, but this risk is very low (approximately 1% at 5 years) and probably is lower than reported rates. If malignant transformation occurs, it is more likely to be associated with erosive and atrophic forms of the disease. Because lichen planus is a chronic condition, patients should be observed periodically and should be offered education about the clinical course, rationale of therapy, and possible risk of malignant transformation.

Lupus Erythematosus

Lupus erythematosus (LE) may be seen in one of two well-recognized forms—systemic (acute) lupus erythematosus (SLE) and discoid (chronic) lupus erythematosus (DLE)—both of which may have oral manifestations. A third form, known as *subacute lupus,* has also been described. In the spectrum of LE, SLE is of particular importance because of the profound impact it has on many organs. DLE is the less aggressive form, predominantly affecting the skin and rarely progressing to the systemic form. It may, however, be of great cosmetic significance because of its predilection for the face. Subacute cutaneous LE, described as lying intermediate between SLE and DLE, results in skin lesions of mild to moderate severity. It is marked by mild systemic involvement and the appearance of some abnormal autoantibodies.

Etiology and Pathogenesis. LE is believed to be an autoimmune disease involving both humoral and cell-mediated arms of the immune system.

Autoantibodies directed against various cellular antigens in the nucleus and the cytoplasm have been identified. These antibodies may be found in the serum or in tissue, bound to antigens. Circulating antibodies are responsible for the positive reactions noted in the antinuclear antibody (ANA) and LE cell tests that are performed to help confirm the diagnosis of lupus. Also circulating in serum are antigen-antibody complexes that mediate disease in many organ systems.

Clinical Features.

Discoid Lupus Erythematosus. DLE is characteristically seen in middle age, especially in women. Lesions commonly appear solely on the skin, most commonly on the face and scalp (Table 3-3; Figs. 3-51 to 3-54). Oral and vermilion lesions are commonly seen, but usually in the company of cutaneous lesions. On the skin, lesions appear as disc-shaped erythematous plaques with hyperpigmented margins. As the lesion expands peripherally, the center heals, and formation of scar and loss of pigment are noted. Involvement of hair follicles results in permanent hair loss (alopecia).

Mucous membrane lesions appear in about 3% to 25% of patients with cutaneous DLE. The buccal mucosa, gingiva, and vermilion are most commonly affected. Lesions may be erythematous or ulcerative with delicate white, keratotic striae radiating from the periphery. The diagnosis of oral lesions may not be evident on the basis of clinical appearance. Progression of DLE to SLE is very unlikely, although the potential does exist.

Systemic Lupus Erythematosus. In SLE, skin and mucosal lesions are relatively mild, and patients' complaints are dominated by multiple organ involvement (Fig. 3-55). Numerous autoantibodies directed against nuclear and cytoplasmic antigens are found in SLE-affected patients. These antibodies, when complexed to their corresponding antigens in serum or in the target organ, can cause lesions in nearly any tissue, resulting in a wide variety of clinical signs and symptoms.

TABLE 3-3 LUPUS ERYTHEMATOSUS

	Discoid	Systemic
Organs	Skin and oral only	Skin, oral, heart, kidneys, joints
Symptoms	No	Fever, malaise, weight loss
Serology	No detectable antibodies	Positive ANA, anti-DNA antibodies
Histopathology	Basal cell loss, lymphocytes at interface and perivascular, keratosis	Similar to discoid
DIF	Granular/linear basement membrane deposits of IgG and C3	Similar to discoid

ANA, Antinuclear antibody; *C,* complement; *DIF,* direct immunofluorescence; *IgG,* immunoglobulin G.

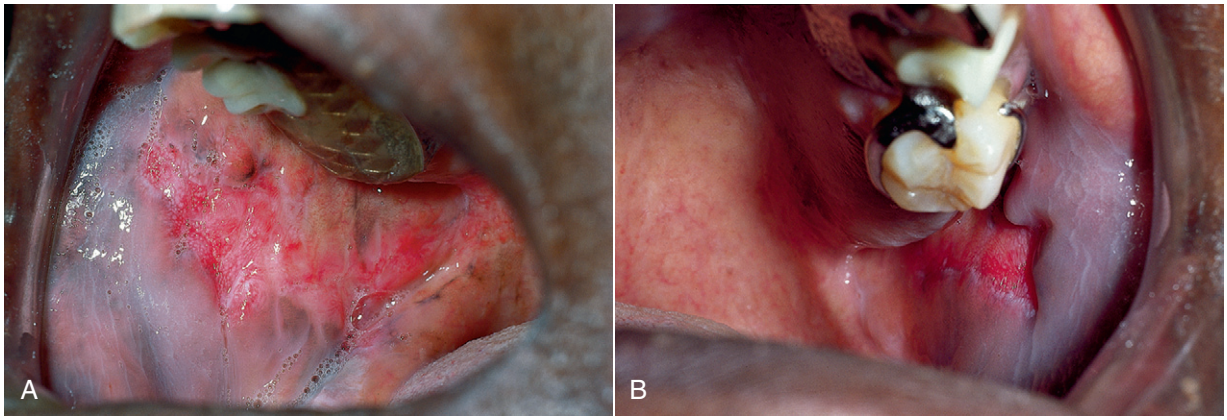

■ **FIGURE 3-51 A** and **B,** Discoid (chronic) lupus erythematosus.



■ **FIGURE 3-52** Discoid lupus erythematosus of the maxillary gingiva.

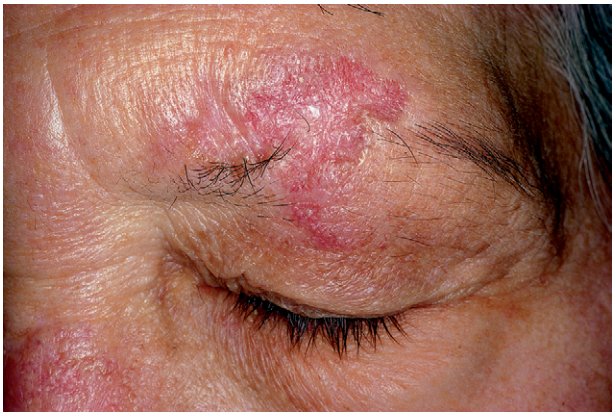

■ **FIGURE 3-54** Discoid lupus erythematosus of the face.



■ **FIGURE 3-53** Discoid lupus erythematosus of the lip.



■ **FIGURE 3-55** Systemic lupus erythematosus, oral lesion.

Involvement of the skin results in an erythematous rash, classically seen over malar processes and the bridge of the nose. This "butterfly" distribution is usually associated with SLE. Other areas of the face, trunk, and hands may also be involved. The lesions are nonscarring and may flare as systemic involvement progresses.

Oral lesions of SLE are generally similar to those seen in DLE and are noted in 9% to 45% of cases. Ulceration, erythema, and keratosis may be seen. In addition to the vermilion, the labial and buccal mucosa, gingiva, and palate are often involved.

Systemic symptoms of SLE may initially consist of fever, weight loss, and malaise. Typically, with disease progression many organ systems become involved. The joints, kidneys, heart, and lungs are most commonly affected, although many other organs may express manifestations of this

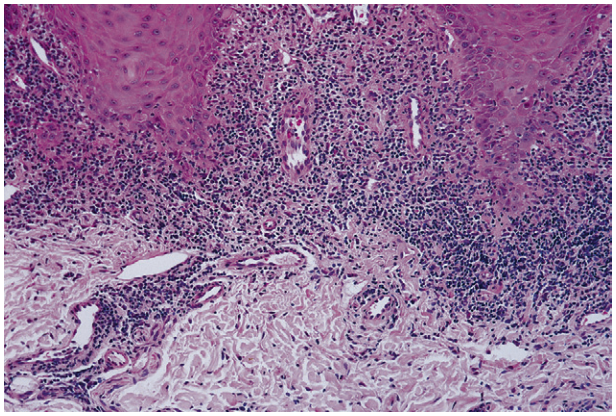

■ **FIGURE 3-56** Oral discoid lupus erythematosus showing interface and perivascular lymphocytic infiltrate.

disease. Kidney lesions (glomerulonephritis) showing a range of forms and severity are, however, the most important, because they are most commonly responsible for the morbidity and mortality of SLE-affected patients.

Serologic tests for autoantibodies yield positive results in patients with SLE. The ANA test is regarded as a reliable and relatively specific test for SLE. Among the antibodies that may cause a positive ANA test result are anti–single-stranded DNA, anti–double-stranded DNA, and antinuclear ribonuclear protein. Specific tests for these and other autoantibodies of SLE are available. Another serologic test for SLE is the LE cell test, although it is less sensitive and less specific than the ANA test. Antibodies to Ro (SS-A) and La (SS-B) cytoplasmic antigens may also be present in SLE.

Histopathology. In DLE, basal cell destruction, hyperkeratosis, epithelial atrophy, lymphocytic infiltration (subepithelial and perivascular distribution), and vascular dilation with edema of the submucosa are seen (Fig. 3-56). It appears that basal keratinocytes are a primary target in mucous membranes. Because this is also the case for lichen planus, the two diseases may be difficult, on occasion, to separate by routine microscopic studies.

In SLE, oral lesions are microscopically similar to lesions of DLE, although inflammatory cell infiltrates are less intense and more diffuse. The epithelial lesions are hyperproliferative in nature and are positive for cytokeratin markers CK 5/6 and CK 14. Other organs, when involved in SLE, show vasculitis, mononuclear infiltrates, and fibrinoid necrosis. Direct immunofluorescent testing of skin and mucosal lesions shows granular-linear deposits of immunoglobulins (IgG, IgM, IgA), complement (C3), and fibrinogen along the basement membrane zone in a majority of patients.

Differential Diagnosis. Clinically, lesions of oral LE most often resemble erosive lichen planus but tend to be less symmetrically distributed. The keratotic striae of LE are much more delicate and subtle than Wickham's striae of lichen planus and show characteristic radiation from a central focus. Erythematous gingival lupus may be confused with mucous membrane pemphigoid, erythematous lichen planus, erythematous candidiasis, and contact hypersensitivity.

Treatment. DLE is usually treated with topical corticosteroids. High-potency ointments can be used intraorally. In refractory cases, antimalarials or sulfones may be used.

Systemic steroids may be used in the treatment of SLE. The prednisone dose is generally dependent on the severity of the disease, and prednisone may be combined with immunosuppressive agents for their therapeutic and steroid-sparing effects. Antimalarials and nonsteroidal anti-inflammatory drugs may help control this disease.

BOX 3-13 CANDIDIASIS

SYNONYMS

Thrush, angular cheilitis, median rhomboid glossitis, denture sore mouth, yeast infection, candidal leukoplakia, antibiotic stomatitis, moniliasis

CAUSE

Candida albicans and other *Candida* species in oral flora
Predisposing factors required
Opportunistic overgrowth

TYPES

Acute, chronic, mucocutaneous

NONEPITHELIAL WHITE-YELLOW LESIONS

Candidiasis

Candidiasis is a common opportunistic oral mycotic infection that develops in the presence of one of several predisposing conditions. Clinical presentation is variable and is dependent on whether the condition is acute or chronic (Box 3-13).

Etiology and Pathogenesis. Candidiasis is caused by *C. albicans* and much less commonly by other species of *Candida: C. parapsilosis, C. tropicalis, C. glabrata, C. krusei, C. pseudotropicalis,* and *C. guilliermondii. C. albicans* is a commensal organism residing in the oral cavity in a majority of healthy persons. Transformation, or escape from a state of commensalism to that of a pathogen, relates to local and systemic factors. The organism is a unicellular yeast of the Cryptococcaceae family and may exist in three distinct biological and morphologic forms: (1) the vegetative or yeast form of oval cells (blastospores), measuring 1.5 to 5 µm in diameter; (2) the elongated cellular form (pseudohyphae); and (3) the chlamydospore form, which consists of cell bodies measuring 7 to 17 µm in diameter, with a thick, refractile enclosing wall. As evidenced by its frequency in the general population, *C. albicans* is of weak pathogenicity,

BOX 3-14 CANDIDIASIS: PREDISPOSING FACTORS

Immunodeficiency
Immunologic immaturity of infancy
Acquired immunosuppression
Endocrine disturbances
Diabetes mellitus
Hypoparathyroidism
Pregnancy
Hypoadrenalism
Corticosteroid therapy, topical or systemic
Systemic antibiotic therapy
Malignancies and their therapies
Xerostomia
Poor oral hygiene

BOX 3-15 CANDIDIASIS: CLASSIFICATION

ACUTE
Pseudomembranous (white colonies)
Erythematous (red mucosa)

CHRONIC
Erythematous (red mucosa)
Hyperplastic (white keratotic plaque)

MUCOCUTANEOUS
Localized (oral, face, scalp, nails)
Familial
Syndrome associated

thereby reflecting the necessity for local or systemic predisposing factors to produce a disease state (Box 3-14).

Infection with this organism is usually superficial, affecting the outer aspects of the involved oral mucosa or skin. In severely debilitated and immunocompromised patients, such as patients with AIDS, infection may extend into the alimentary tract (candidal esophagitis), the bronchopulmonary tract, or other organ systems. The opportunistic nature of this organism is observed in the frequency of mild forms of the disease resulting from short-term use of systemic antibiotic therapy for minor bacterial infections.

Clinical Features. The most common clinical type of candidiasis is the acute pseudomembranous form, also known as *thrush* (Box 3-15). Young infants and the elderly are commonly affected. Estimates of disease frequency range up to 5% of neonates; 5% of patients with cancer; and 10% of institutionalized, debilitated elderly patients. This infection is common in patients being treated with radiation or chemotherapy for leukemia and solid tumors, with up to half of those in the former group and 70% in the latter group affected. Recalcitrant candidiasis has been recognized in patients who have HIV infection and AIDS.

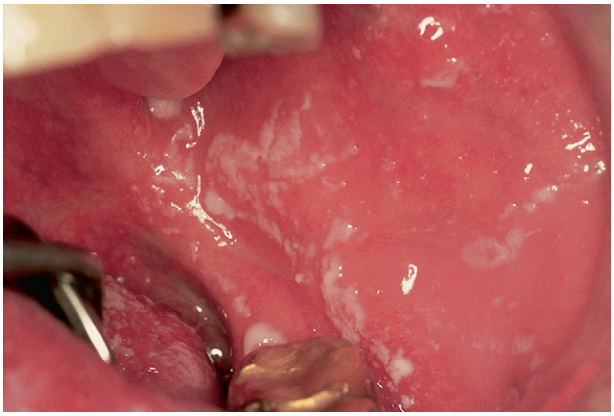

■ **FIGURE 3-57** Candidiasis, pseudomembranous type.

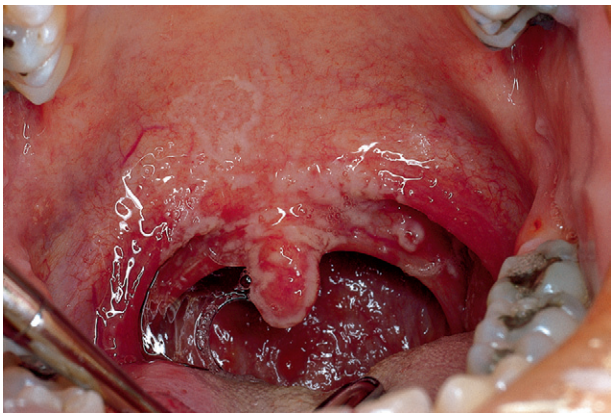

■ **FIGURE 3-58** Candidiasis, pseudomembranous type.

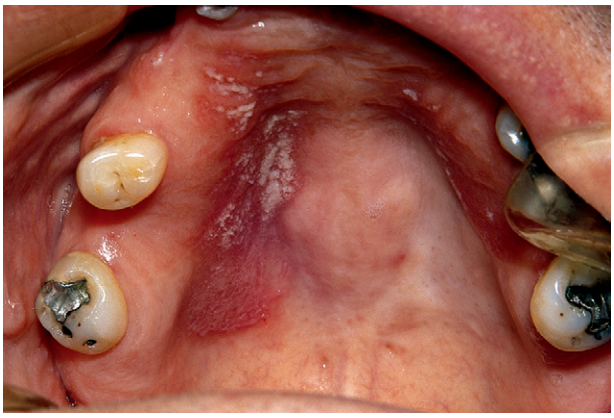

■ **FIGURE 3-59** Candidiasis, pseudomembranous type.

Oral lesions of *acute candidiasis (thrush)* are characteristically white, soft plaques that sometimes grow centrifugally and merge (Figs. 3-57 to 3-63). Plaques are composed of fungal organisms, keratotic debris, inflammatory cells, desquamated epithelial cells, bacteria, and fibrin. Wiping away the plaques or pseudomembranes with a gauze sponge leaves a painful erythematous, eroded, or ulcerated surface. Although lesions of thrush may develop at any location,

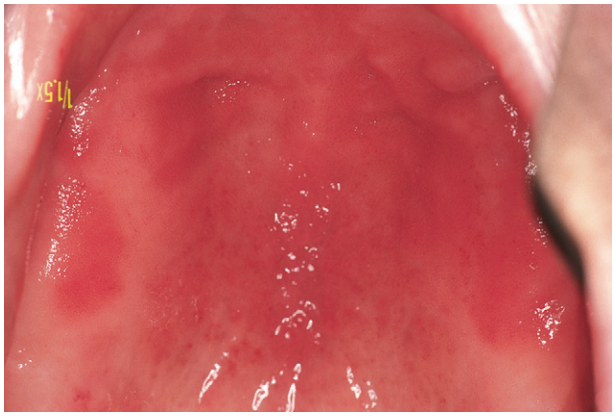

■ **FIGURE 3-60** Candidiasis, erythematous type.



■ **FIGURE 3-61** Candidiasis, angular cheilitis form.



■ **FIGURE 3-62** Candidiasis, hyperplastic type or median rhomboid glossitis.

favored sites include the buccal mucosa and mucobuccal folds, the oropharynx, and the lateral aspects of the tongue. In most instances in which the pseudomembrane has not been disturbed, associated symptoms are minimal. In severe cases, patients may complain of tenderness, burning, and dysphagia.

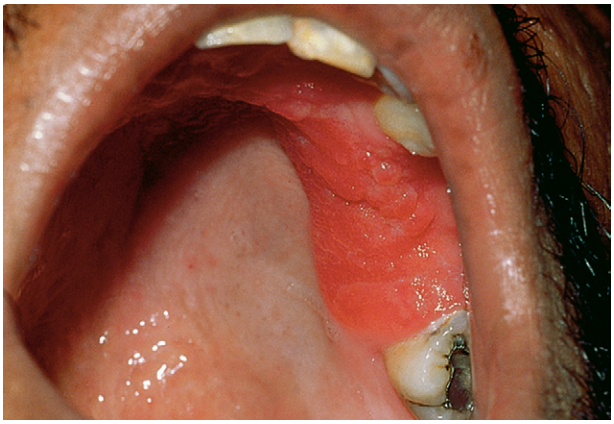

■ **FIGURE 3-63** Candidiasis, hyperplastic type.

Persistence of acute pseudomembranous candidiasis may eventually result in loss of the pseudomembrane, with presentation as a more generalized red lesion, known as *acute erythematous candidiasis.* Along the dorsum of the tongue, patches of depapillation and dekeratinization may be noted. In the past, this particular form of candidiasis was known as *antibiotic stomatitis* or *antibiotic glossitis* because of its common relationship to antibiotic treatment of acute infection. Broad-spectrum antibiotics or concurrent administration of multiple narrow-spectrum antibiotics may produce this secondary infection to a much greater degree than do single narrow-spectrum antibiotics. Withdrawal of the offending antibiotic, if possible, and institution of appropriate oral hygiene lead to improvement. In contrast to the acute pseudomembranous form, oral symptoms of the acute atrophic form are marked because of numerous erosions and intense inflammation.

Chronic erythematous candidiasis is a commonly seen form, occurring in as many as 65% of geriatric individuals who wear complete maxillary dentures (denture sore mouth). Expression of this form of candidiasis depends on conditioning of the oral mucosa by a covering prosthesis. A distinct predilection for the palatal mucosa as compared with the mandibular alveolar arch has been noted. Chronic low-grade trauma resulting from poor prosthesis fit, less than ideal occlusal relationships, and failure to remove the appliance at night all contribute to the development of this condition. The clinical appearance is that of a bright red, somewhat velvety to pebbly surface, with relatively little keratinization.

Also seen in individuals with denture-related chronic atrophic candidiasis is *angular cheilitis.* This condition is especially prevalent in individuals who have deep folds at the commissures as a result of mandibular overclosure. In such circumstances, small accumulations of saliva gather in the skin folds at the commissural angles and are subsequently colonized by yeast organisms (and often by *Staphylococcus aureus*). Clinically, the lesions are moderately painful, fissured, eroded, and encrusted. Angular cheilitis may also occur in individuals who habitually lick their lips

and deposit small amounts of saliva in the commissural angles.

A circumoral type of atrophic candidiasis may be noted in those with severe lip-licking habits with extension of the process onto surrounding skin. The skin is fissured and demonstrates a degree of brown discoloration on a slightly erythematous base. This condition is to be distinguished from *perioral dermatitis,* which characteristically shows less crusting and a circumferential zone of uninvolved skin immediately adjacent to the cutaneous-vermilion junction.

Chronic candidal infections are capable of producing a hyperplastic tissue response *(chronic hyperplastic candidiasis).* When occurring in the retrocommissural area, the lesion resembles speckled leukoplakia and, in some classifications, is known as *candidal leukoplakia.* It occurs in adults with no apparent predisposition to infection by *C. albicans,* and it is believed by some clinicians to represent a premalignant lesion.

Hyperplastic candidiasis may involve the dorsum of the tongue in a pattern referred to as *median rhomboid glossitis.* It is usually asymptomatic and is generally discovered on routine oral examination. The lesion is found anterior to the circumvallate papillae and has an oval or rhomboid outline with a paramedian distribution. It may have a smooth, nodular, or fissured surface and may range in color from white to a more characteristic red. A similar-appearing red lesion may also be present on the adjacent hard palate ("kissing lesion"). Whether on the tongue or on the palate, the condition may occasionally be mildly painful, although most cases are asymptomatic. In the past, this particular condition was believed to be a developmental anomaly, presumably resulting from persistence of the tuberculum impar of the developing tongue. Because it is never seen in children, it is more likely a hyperplastic form of candidiasis. Microscopically, epithelial hyperplasia is evident in the form of bulbous rete ridges. *C. albicans* hyphae usually can be found in the upper levels of the epithelium. A thick band of hyalinized connective tissue separates the epithelium from deeper structures.

Nodular papillary lesions of the hard palatal mucosa predominantly seen beneath maxillary complete dentures are thought to represent, at least in part, a response to chronic fungus infection. The *papillary hyperplasia* is composed of individual nodules that are ovoid to spherical and form excrescences measuring 2 to 3 mm in diameter on an erythematous background.

Mucocutaneous candidiasis is a diverse group of conditions. The localized form of mucocutaneous candidiasis is characterized by long-standing and persistent candidiasis of the oral mucosa, nails, skin, and vaginal mucosa. This form of candidiasis is often resistant to treatment, with only temporary remission following the use of standard antifungal therapy. This form begins early in life, usually within the first two decades. The disease begins as a pseudomembranous type of candidiasis and soon is followed by nail and cutaneous involvement.

A familial form of mucocutaneous candidiasis, believed to be transmitted in an autosomal-recessive fashion, occurs in nearly 50% of patients with an associated endocrinopathy. The endocrinopathy usually consists of hypoparathyroidism, Addison's disease, and occasionally hypothyroidism or diabetes mellitus. Other forms of familial mucocutaneous candidiasis have associated defects in iron metabolism and cell-mediated immunity.

A rare triad of chronic mucocutaneous candidiasis, myositis, and thymoma has been described. The role of the thymus relates to a deficiency in T cell–mediated immunologic function, hence providing an opportunity for the proliferation of *Candida.*

A final form of candidiasis, both acute and chronic, is becoming increasingly evident within the immunosuppressed population of patients, in particular those infected with HIV. This form of candidiasis was originally described in 1981 and is now well recognized as being one of the more important opportunistic infections that afflict this group of patients. The significantly depleted cell-mediated arm of the immune system is believed to be responsible for allowing the development of severe candidiasis in these patients.

So-called denture stomatitis, a chronic form of erythematous candidiasis, is in large measure associated with the prosthesis-related surface biofilm that becomes colonized with candidal organisms. The relationship between duration of denture use and development of this form of candidiasis has been established.

Histopathology. In acute candidiasis, fungal hyphae are seen penetrating the upper layers of the epithelium at acute angles (Fig. 3-64). Neutrophilic infiltration of the epithelium with superficial microabscess formation is typically seen. Fungal forms may be enhanced in tissue sections by staining with methenamine silver or periodic acid–Schiff (PAS) reagent. The predominant fungal forms growing in this particular form of the disease are pseudohyphae.

Epithelial hyperplasia is a rather characteristic feature of chronic candidiasis. However, organisms may be sparse, making histologic demonstration sometimes difficult. Although chronic candidiasis may give rise to oral leukoplakia, no clear evidence indicates that chronic candidiasis is in and of itself a precancerous state.

Clinical laboratory tests for this organism involve removal of a portion of the candidal plaque, which is smeared on a microscope slide and macerated with 20% potassium hydroxide or stained with PAS. The slide is subsequently examined for typical hyphae. Culture identification and quantification of organisms may be done on Sabouraud broth, blood agar, or cornmeal agar.

Differential Diagnosis. Candidal white lesions should be differentiated from slough associated with chemical burns, traumatic ulcerations, mucous patches of syphilis, and white keratotic lesions. Red lesions of candidiasis should be differentiated from drug reactions, erosive lichen planus, and DLE.

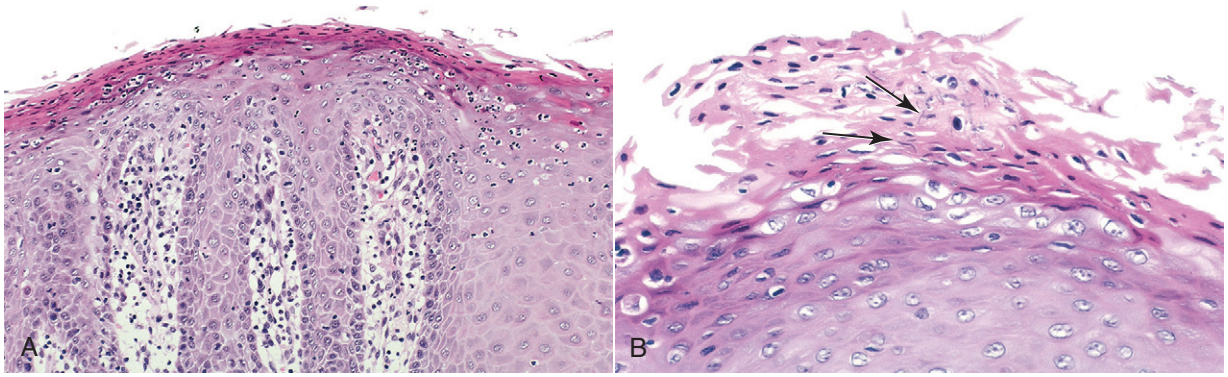

■ **FIGURE 3-64 Oral candidiasis. A,** Psoriasiform pattern. **B,** High magnification of fungal hyphae in keratin layer.

BOX 3-16 CANDIDIASIS: TREATMENT

TOPICAL

Nystatin—oral suspension* and pastille*; powder and ointment for denture; vaginal tablets (dissolved in mouth)

Clotrimazole—oral troches*

SYSTEMIC

Fluconazole, ketoconazole

*Contains sugar; do not use with dentate patients with xerostomia.

Treatment and Prognosis. Attending to predisposing factors is an important component of management of patients with candidiasis. The majority of infections may be treated simply with topical applications of nystatin suspension, although this may be prove to be ineffective because contact time with the lesion is short (Box 3-16). Nystatin powder, cream, or ointment is often effective when applied directly to the affected tissue on gauze pads and for denture-associated candidiasis when applied directly to the denture-bearing surface itself. In both circumstances, prolonged contact time with the lesion proves to be an effective delivery strategy. Clotrimazole can be conveniently administered in troche form. Topical applications of nystatin miconazole or clotrimazole should be continued for at least 1 week beyond the disappearance of clinical manifestations of the disease. It is important to note that antifungals designed specifically for oral use contain considerable amounts of sugar, making them undesirable for the treatment of candidiasis in dentulous patients with xerostomia. Sugar-free antifungal vaginal suppositories, dissolved in the mouth, are an excellent treatment alternative to avoid the complications of dental caries.

For hyperplastic candidiasis, topical and systemic antifungal therapy may be ineffective in completely removing the lesions, particularly those that occur on the buccal mucosa, near the commissures. In these circumstances, surgical management may be necessary to complement antifungal medications.

In cases of chronic mucocutaneous candidiasis or oral candidiasis associated with immunosuppression, topical agents may not be effective. In such instances, systemic administration of medications such as ketoconazole, fluconazole, itraconazole, or others may be necessary. All are available in oral form. Caution must be exercised, however, because these drugs may be hepatotoxic.

The prognosis for acute and most other forms of chronic candidiasis is excellent. The underlying defect in most types of persistent mucocutaneous candidiasis militates against cure, although intermittent improvement may be noted after the use of systemic antifungal agents.

Mucosal Burns

Etiology. The most common form of superficial burn of the oral mucosa is associated with topical applications of chemicals, such as aspirin or caustic agents. Topical abuse of drugs, accidental placement of phosphoric acid-etching solutions or gel by a dentist, or overly fastidious use of alcohol-containing mouth rinses may produce similar effects.

Clinical Features. In cases of short-term exposure to agents capable of inducing tissue necrosis, a localized mild erythema may occur (Fig. 3-65). As the concentration and contact time of the offending agent increase, surface coagulative necrosis is more likely to occur, resulting in the formation of a white slough, or membrane. With gentle traction, the surface slough peels from the denuded connective tissue, producing pain.

Thermal burns are commonly noted on the hard palatal mucosa and generally are associated with hot, sticky foods. Hot liquids are more likely to burn the tongue or the soft palate. Such lesions are generally erythematous rather than white (necrosis), as is seen with chemical burns.

Another form of burn that is potentially serious is the electrical burn. In particular, children who chew through electrical cords receive rather characteristic initial burns that are often symmetric. The result of these accidents is significant tissue damage, often followed by scarring. The surface



■ **FIGURE 3-65** Mucosal burn (necrosis) caused by prolonged aspirin contact.

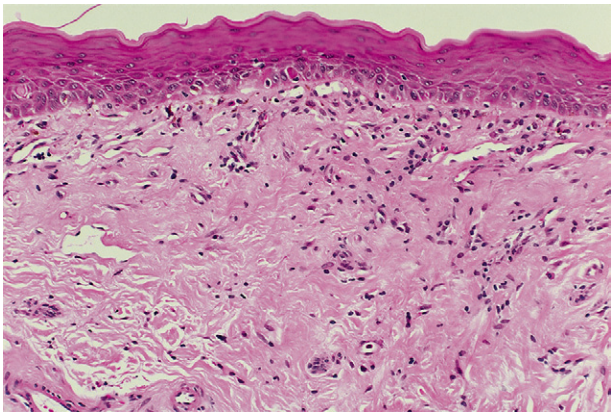

■ **FIGURE 3-66** Submucous fibrosis showing epithelial atrophy over fibrotic submucosa.

of these lesions tends to be characterized by a thickened slough that extends deep into the connective tissue.

Histopathology. In cases of chemical and thermal burns in which an obvious clinical slough has developed, the epithelial component shows coagulative necrosis through its entire thickness. A fibrinous exudate is also evident. The underlying connective tissue is intensely inflamed. Electrical burns are more destructive, showing deep extension of necrosis, often into muscle.

Treatment. Management of chemical, thermal, or electrical burns is varied. For patients with thermal or chemical burns, local symptomatic therapy aimed at keeping the mouth clean, such as sodium bicarbonate mouth rinses with or without the use of systemic analgesics, is appropriate. Alcohol-based commercial mouth rinses should be discouraged because of their drying effect on the oral mucosa. For patients with electrical burns, management may be much more difficult. The services of a pediatric dentist or an oral and maxillofacial surgeon may be necessary in more severe cases. Pressure stents over the damaged areas may be required to prevent early contracture of the wounds. After healing, further definitive surgical or reconstructive treatment may be necessary because of extensive scar formation.

Submucous Fibrosis

Etiology. Several factors contributing to submucous fibrosis include general nutritional or vitamin deficiencies and hypersensitivity to various dietary constituents. The primary factor appears to be chewing of the areca (betel) nut. It appears that this condition is due to impaired degradation of normal collagen by fibroblasts rather than excess production. Also, chronic consumption of chili peppers or chronic and prolonged deficiency of iron and B complex vitamins, especially folic acid, increases hypersensitivity to many potential irritants (areca nut, dietary spices, and tobacco), with an attendant inflammatory reaction and fibrosis. It has been reported that a polymorphism of the promoter region of the matrix metalloproteinase 3 (MMP 3) gene is common in oral submucous fibrosis and may contribute to development of the disease. Also postulated in terms of pathogenesis is an increased degree of collagen cross-linking through upregulation of lysyl oxidase activity stimulated by arecoline, an alkaloid contained in the areca nut component of paan and gutka.

Clinical Features. Once rarely seen in North America, submucous fibrosis is relatively common in Southeast Asia, India, and neighboring countries. Recent patterns of immigration to the Western hemisphere have led to an increase in the number of cases noted, however. The condition is seen typically between the ages of 20 and 40 and is often associated with the habitual use of compounds containing areca (betel) nut and tobacco in various forms, including a quid form (paan) and a powdered form (gutka), where these are placed in the oral cavity for extended periods of time and often are replaced up to several times per day. The addictive properties of this habit are well known, as are the mucosal alterations that accompany long-term use, in particular submucous fibrosis.

Oral submucous fibrosis presents as a whitish yellow change that has a chronic, insidious biological course. It is characteristically seen in the oral cavity, but on occasion it may extend into the pharynx and the esophagus. Submucous fibrosis occasionally may be preceded by or may be associated with vesicle formation. Over time, the affected mucosa, especially the soft palate and the buccal mucosa, loses its resilience and shows limited vascularity and elasticity. This process then progresses from the lamina propria to the underlying musculature. Fibrous bands are readily palpable in the soft palate and the buccal mucosa. The clinical result is significant trismus with considerable difficulty in eating.

Histopathology. Microscopically, the principal feature is atrophy of the epithelium and subjacent fibrosis (Fig. 3-66). Epithelial dysplasia occasionally may be evident. The lamina



■ **FIGURE 3-67** Fordyce's granules.

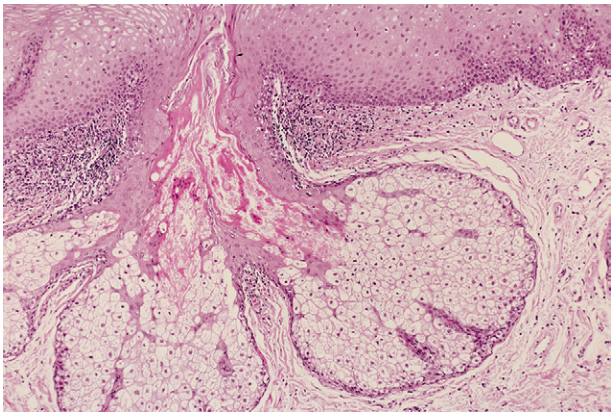

■ **FIGURE 3-68** Fordyce's granules showing sebaceous gland lobules.

propria is poorly vascularized and hyalinized; fibroblasts are few. A diffuse mild to moderate inflammatory infiltrate is present. Type I collagen predominates in the submucosa, whereas type III collagen tends to localize at the epithelium–connective tissue interface and around blood vessels, salivary glands, and muscle.

Treatment and Prognosis. Eliminating causative agents is part of the management of submucous fibrosis. Therapeutic measures include local injections of chymotrypsin, hyaluronidase, and dexamethasone, with surgical excision of fibrous bands and submucosal placement of vascularized free flap grafts. All methods of treatment, including surgical modalities, however, have proved to be of only modest help in this essentially irreversible condition.

The primary importance of submucous fibrosis relates to its premalignant nature. The development of squamous cell carcinoma has been noted in as many as one third of patients with submucous fibrosis.

Fordyce's Granules

Fordyce's granules represent ectopic sebaceous glands or sebaceous choristomas (normal tissue in an abnormal location). This condition is regarded as developmental and can be considered a variation of normal.

Fordyce's granules are multiple and often are seen in aggregates or in confluent arrangements (Figs. 3-67 and 3-68). Sites of predilection include the buccal mucosa and the vermilion of the upper lip. Lesions generally are symmetrically distributed and tend to become obvious after puberty, with maximal expression occurring between 20 and 30 years of age. Lesions are asymptomatic and often are discovered incidentally by the patient or by the practitioner during a routine oral examination. A large proportion of the population—more than 80% of individuals—is affected by this particular condition.

Microscopically, lobules of sebaceous glands are aggregated around or adjacent to excretory ducts. The heterotopic glands are well formed and appear functional.

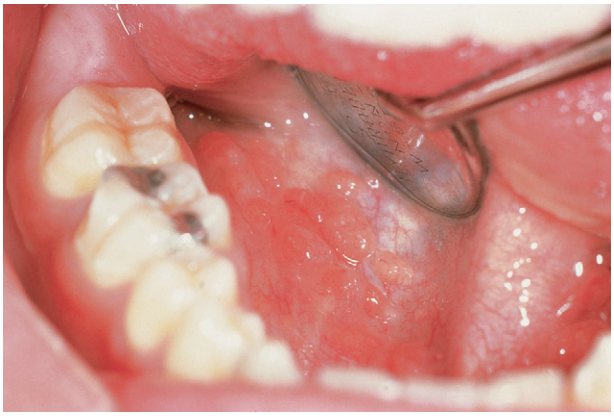

■ **FIGURE 3-69** Ectopic lymphoid tissue in the floor of the mouth.

No treatment is indicated for this particular condition because the glands are normal in character and do not cause any untoward effects.

Ectopic Lymphoid Tissue

Ectopic lymphoid tissue may be found in numerous oral locations. Found in the posterolateral aspect of the tongue, it is known as *lingual tonsil.* Aggregates of lymphoid tissue are commonly seen in the soft palate, floor of the mouth, and tonsillar pillars (Fig. 3-69).

Lymphoid tissue appears yellow or yellow-white clinically and typically produces small, dome-shaped elevations. The tissue appears uninflamed, and the patient is unaware of its presence. Crypts in the lymphoid tissue occasionally may become obstructed, causing "cystic" dilation of the area. These lesions may be called *lymphoepithelial cysts.* In a strict sense, however, lymphoepithelial cysts are believed to be derived from cystic changes of embryonically entrapped epithelium within lymphoid tissue.

Generally, lymphoid tissue can be diagnosed on the basis of clinical features alone. Because this is basically normal tissue, no biopsy is necessary.

Gingival Cysts

Gingival cysts of odontogenic origin occur in adults, as well as in infants *(Bohn's nodules)*. In infants, relative frequency is greatest in the neonatal phase. They occur along the alveolar ridges and involute spontaneously or rupture and exfoliate. Another eponym, *Epstein's pearls,* has been commonly used to designate nonodontogenic neonatal cysts that occur along the palatal midline (fusion of palatine shelves).

Etiology and Pathogenesis. Neonatal gingival cysts are thought to arise from dental lamina remnants. Fetal tissues between 10 and 12 weeks of age show small amounts of keratin within elements of the dental lamina. Toward the end of the 12th week of gestation, disruption of the dental lamina is evident, with many fragments exhibiting central cystification and keratin accumulation. Gingival cysts generally are numerous in the fetus and infant, increasing in number until the 22nd week of gestation.

Midline palatal cysts, or Epstein's pearls, are thought to result from epithelial entrapment within the midline of palatal fusion. Small epithelial inclusions within the line of fusion produce microcysts that contain keratin and rupture early in life.

The gingival cyst of the adult is probably formed from remnants of the dental lamina (rests of Serres) within the gingival submucosa. Cystic changes in these rests may occasionally result in a multilocular lesion. An alternative theory of pathogenesis relates to the traumatic implantation of surface epithelium into gingival connective tissue.

Clinical Features. Gingival cysts in a neonate appear as off-white nodules approximately 2 mm in diameter. Cysts ranging in number from one to many are evident along the alveolar crests. Midline palatal cysts, on the other hand, present along the midpalatal raphe toward the junction of the hard palate and the soft palate.

The gingival cyst of adults occurs chiefly during the fifth and sixth decades. It appears more commonly in the mandible than in the maxilla. A great deal of similarity has been noted between the gingival cyst in the adult and the lateral periodontal cyst, including the site of predilection, the age of occurrence, clinical behavior, and overall morphology. The gingival cyst presents as a painless growth in the attached gingiva, often within the interdental papilla. Only rarely are lesions found in the lingual gingiva. Premolar and bicuspid regions of the mandible are favored locations.

Histopathology. The neonatal gingival cyst is lined by bland stratified squamous epithelium and is filled with keratinaceous debris. The gingival cyst of adults is lined by a thin layer of cuboidal or flattened epithelium with focal thickenings that often show clear cell change.

Treatment. No treatment is indicated for gingival or palatal cysts of the newborn because they spontaneously rupture early in life. Treatment for gingival cyst of the adult is surgical excision.

Parulis

A parulis, or "gum boil," represents a focus of pus in the gingiva. It is derived from an acute infection at the base of an occluded periodontal pocket or at the apex of a nonvital tooth. The path of least resistance most often leads to gingival submucosa. The lesion appears as a yellow-white gingival tumescence with an associated erythema (Fig. 3-70). Pain is typical, but once the pus escapes to the surface, symptoms are temporarily relieved. Treatment of the underlying condition (periodontal pocket or nonvital tooth) is required to achieve resolution of the gingival abscess.

Lipoma

Lipoma appears as a yellow or yellow-white uninflamed submucosal mass of adipose tissue. It is included in this section for completeness. Discussion is found in Chapter 7.



■ **FIGURE 3-70** Parulis (gingival abscess) associated with periapical abscess.

BIBLIOGRAPHY

Hereditary Conditions

Allingham RR, Seo B, Rampersaud E et al: A duplication in chromosome 4q35 is associated with hereditary benign intraepithelial dyskeratosis. Am J Hum Genet 68:491–494, 2001.

Burge SM, Millard PR, Wojnarowska F et al: Darier's disease: a focal abnormality of cell adhesion. J Cutan Pathol 17:160–169, 1990.

Cardoso CL, Freitas P, Taviera LA et al: Darier disease: case report with oral manifestations. Med Oral Patol Cir Bucal 11:E404–E406, 2006.

Feinstein A, Friedman J, Schewach-Miller M: Pachyonychia congenita. J Am Acad Dermatol 19:705–711, 1988.

Lim J, Ng S: Oral tetracycline rinse improves symptoms of white sponge nevus. J Am Acad Dermatol 26:1003–1005, 1992.

Nichols GE, Cooper PH, Underwood PB et al: White sponge nevus. Obstet Gynecol 76:545–548, 1990.
Otobe IF, de Sousa SO, Matthews RW et al: White sponge naevus: improvement with tetracycline mouth rinse. Clin Exp Dermatol 32:749–751, 2007.
Richard G, De Laurenzi V, Didona B et al: Keratin 13 point mutation underlies the hereditary mucosal epithelial disorder white sponge nevus. Nat Genet 11:453–455, 1995.
Rugg E, McLean WH, Allison WE et al: A mutation in the mucosal keratin K4 is associated with oral white sponge nevus. Nat Genet 11:450–452, 1995.
Versteeg PA, Slot DE, van der Velden U et al: Effect of cannabis on the oral environment: a review. Int J Dent Hyg 6:315–320, 2008.
Zhang JM, Yang ZW, Chen RY et al: Two new mutations in the keratin 4 gene causing oral white sponge nevus in (a) Chinese family. Oral Dis 15:100–105, 2009.

Reactive Lesions

Cho H-H, Kim S-H, Seo S-H et al: Oral hairy leukoplakia which occurred as a presenting sign of acute myeloid leukemia in a child. Ann Dermatol 22:73–76, 2010.
Daniels TE, Hansen LS, Greenspan JS et al: Histopathology of smokeless tobacco lesions in professional baseball players. Oral Surg Oral Med Oral Pathol 73:720–725, 1992.
Fischman SL, Aguirre A, Charles CH: Use of essential oil-containing mouthrinses by xerostomic individuals: determination of potential for oral mucosal irritation. Am J Dent 17:23–26, 2004.
Grady P, Greene J, Daniels TE et al: Oral mucosal lesions found in smokeless tobacco users. J Am Dent Assoc 121:117–123, 1990.
Mitchell C, Joyce AR, Piper JT et al: Role of oxidative stress and MAPK signaling in reference moist smokeless tobacco-induced HOK-16B cell death. Toxicol Lett 195:23–30, 2010.
Piperi E, Omlie J, Koutlas IG et al: Oral hairy leukoplakia in HIV-negative patients: report of 10 cases. Int J Surg Pathol 18:177–183, 2010.
Podzamczer D, Bolao F, Gudiol F: Oral hairy leukoplakia and zidovudine therapy Arch Intern Med 150:689, 1990.
Robertson PB, Walsh M, Greene J et al: Periodontal effects associated with the use of smokeless tobacco J Periodontol 61:438–443, 1990.
Thompson DF, Kessler TL: Drug-induced black hairy tongue Pharmacotherapy 30:585–593, 2010.
Walsh PM, Epstein JB: The oral effects of smokeless tobacco J Can Dent Assoc 66:22–25, 2000.
Warnakulasuriya S, Dietrich T, Bornstein MM et al: Oral health risks for tobacco use and effects of cessation Int Dent J 60:7–30, 2010.
Yi L, Ping Z, Qui-bai L et al: Black hairy tongue associated with allo peripheral blood hematopoietic stem cell transplantation. Chinese Med J 123:1807–1808, 2010.

Preneoplastic and Neoplastic Lesions

Batsakis JG, Suarez P, el-Naggar AK: Proliferative verrucous leukoplakia and its related lesions. Oral Oncol 35:354–359, 1999.
Cabay TH, Morton TH, Epstein JB: Proliferative verrucous leukoplakia and its progression to oral carcinoma. J Oral Pathol Med 36:255–256, 2007.
Chi AC, Lambert PR 3rd, Pan Y et al: Is alveolar ridge keratosis a true leukoplakia? A clinicopathologic comparison of 2,153 lesions. J Am Dent Assoc 138:641–651, 2007.
Chung CH, Yang YH, Wang TV et al: Oral precancerous disorders associated with areca quid chewing, smoking, and alcohol drinking in southern Taiwan. J Oral Pathol Med 34:460–466, 2005.
Holmstrup P, Vedtofte P, Reibel J et al: Long-term treatment outcome of oral premalignant lesions. Oral Oncol 42:461–474, 2006.
Lodi G, Porter S: Management of potentially malignant disorders: evidence and critique. J Oral Pathol Med 37:63–69, 2008.
Lodi G, Sardella A, Bez C et al: Interventions for treating oral leukoplakia. Review. Cochrane Database Syst Rev 18;(4):CD001829, 2006.
Majorana A, Bardellini E, Flocchini P et al: Oral mucosal lesions in children from 0 to 12 years old: ten years' experience. Oral Surg Oral Med Oral Pathol Oral Radiol Endod 110:13–18, 2010.
Miloglu O, Gorgen M, Akgul HM et al: The prevalence and risk factors associated with benign migratory glossitis lesions in 7619 Turkish dental outpatients. Oral Surg Oral Med Oral Pathol Oral Radiol Endod 107:29–33, 2009.
Natarajan E, Woo SB: Benign alveolar ridge keratosis (oral simplex chronicus): a distinct clinicopathologic entity. J Am Acad Dermatol 58:151–157, 2008.
O'Shaughnessy JA, Kelloff GJ, Gordon GB et al: Treatment and prevention of intraepithelial neoplasia: an important target for accelerated new agent development. Clin Cancer Res 8:314–346, 2002.
Rojas AI, Ahmed AR: Adhesion receptors in health and disease. Crit Rev Oral Biol Med 10:337–358, 1999.
Savage NV, McKay C, Faulkner C: Actinic cheilitis in dental practice. Aust Dent J 55(Suppl 1):78–84, 2010.
Smith J, Rattay T, McConkey T et al: Biomarkers in dysplasia of the oral cavity: a systematic review. Oral Oncol 4:647–653, 2009.
Smith KJ, Germain M, Yeager J et al: Topical 5% imiquimod for the therapy of actinic cheilitis. J Am Acad Dermatol 47:497–501, 2002.
Thavarajiah R, Rao A, Raman U et al: Oral lesions of 500 habitual psychoactive substance users in Chennai, India. Arch Oral Biol 51:512–519, 2006.
van der Meij EH, Schepman KP, Smeele LE et al: A review of the recent literature regarding malignant transformation of oral lichen planus. Oral Surg Oral Med Oral Pathol Oral Radiol Endod 88:307–310, 1999.
van der Waal I: Potentially malignant disorders of the oral and oropharyngeal mucosa: terminology, classification and present concepts of management. Oral Oncol 45:317–323, 2009.
Zakrzewska JM, Lopes V, Speight P et al: Proliferative verrucous leukoplakia. Oral Surg Oral Med Oral Pathol Oral Radiol Endod 82:396–401, 1996.

Other White Lesions

Allen CL, Loudon J, Mascarenhas AK: Sanguinaria-related leukoplakia: epidemiologic and clinicopathologic features of a recently described entity. Gen Dent 49:608–614, 2001.
Barker J, Mitra R, Griffiths C et al: Keratinocytes as initiators of inflammation. Lancet 337:211–214, 1991.
Barnard NA, Scully C, Eveson JW et al: Oral cancer development in patients with oral lichen planus. J Oral Pathol Med 22:421–424, 1993.
Boehncke W, Kellner I, Konter U et al: Differential expression of adhesion molecules on infiltrating cells in inflammatory dermatoses. J Am Acad Dermatol 26:907–913, 1992.
Boisnic S, Francis C, Branchet MC et al: Immunohistochemical study of oral lesions of lichen planus: diagnostic and pathophysiologic aspects. Oral Surg Oral Med Oral Pathol 70:462–465, 1990.
Bolewska J, Holmstrup P, Moller-Madsen B et al: Amalgam-associated mercury accumulations in normal oral mucosa, oral mucosal lesions of lichen planus and contact lesions associated with amalgam. J Oral Pathol Med 19:39–42, 1990.
Carozzo M, Thorpe J: Oral lichen planus: a review. Minerva Stomatol 58:519–537, 2009.
Coogan MM, Greenspan J, Challacombe SJ: Oral lesions in infection with human immunodeficiency virus. Bull World Health Organ 83:700–706, 2005.

Dekker NP, Lozada-Nur F, Lagenauer LA et al: Apoptosis-associated markers in oral lichen planus. J Oral Pathol Med 26:170–175, 1997.
Ficarra G, Flaitz CM, Gaglioti D et al: White lichenoid lesions of the buccal mucosa in patients with HIV infection. Oral Surg Oral Med Oral Pathol 76:460–466, 1993.
Gandolfo S, Carbone M, Carrozzo M et al: Oral lichen planus and hepatitis C virus (HCV) infection: is there a relationship? A report of 10 cases. J Oral Pathol Med 23:119–122, 1994.
Gorouhi F, Sohlpour A, Beitollhi AM et al: Randomized trial of pimecrolimus cream versus triamcinolone acetonide paste in the treatment of oral lichen planus. J Am Acad Dermatol 57:806–813, 2007.
Greenspan JS, Greenspan D, Palefsky JM: Oral hairy leukoplakia after a decade, Epstein-Barr. Virus Report 2:123–128, 1995.
Holmstrup P, Scholtz AW, Westergaard J: Effect of dental plaque control on gingival lichen planus. Oral Surg Oral Med Oral Pathol 69:585–590, 1990.
Hong WK: Chemoprevention in oral premalignant lesions. Cancer Bull 1986;38:145–148.
Hong WK, Lippman SM, Itri LM et al: Prevention of second primary tumors with isotretinoin in squamous cell carcinoma of the head and neck. N Engl J Med 323:795–801, 1990.
Jarvinen J, Kullaa-Mikkonen A, Kotilainen R: Some local and systemic factors related to tongue inflammation. Proc Finn Dent Soc 85:197–209, 1990.
Kaliakatsou F, Hodgson TA, Lewsey JD et al: Management of recalcitrant ulcerative oral lichen planus with topical tacrolimus. J Am Acad Dermatol 46:35–41, 2002.
Lodi G, Scully C, Carozzo M et al: Current controversies in oral lichen planus: report of an international consensus meeting. Part 2. Clinical management and malignant transformation. Oral Surg Oral Med Oral Pathol Oral Radiol Endod 100:164–178, 2005.
Lourenco SV, Nacagami Sotto M, Constantino Vilela MA et al: Lupus erythematosus: clinical and histopathologic study of oral manifestations and immunohistochemical profile of epithelial maturation. J Cutan Path 33:657–662, 2006.
Lozada-Nur F, Robinson J, Regezi JA: Oral hairy leukoplakia in immunosuppressed patients. Oral Surg Oral Med Oral Pathol 78:599–602, 1994.
McCreary CE, McCartan BE: Clinical management of oral lichen planus. Br J Oral Maxillofac Surg 37:338–343, 1999.
Nakamura S, Hiroki A, Shinohara M et al: Oral involvement in chronic graft-versus-host disease after allogenic bone marrow transplantation. Oral Surg Oral Med Oral Pathol Oral Radiol Endod 82:556–563, 1996.
Patton DF, Shirley P, Raab-Traub N et al: Defective viral DNA in Epstein-Barr virus-associated oral hairy leukoplakia. J Virol 64:397–400, 1990.
Piperi E, Omlie J, Koutlas IG et al: Oral hairy leukoplakia in HIV-negative patients: report of 10 cases. Int J Surg Pathol 18:177–183, 2010.
Podzamczer D, Bolao F, Gudiol F: Oral hairy leukoplakia and zidovudine therapy. Arch Intern Med 150:689, 1990.
Porter SR, Kirby A, Olsen I et al: Immunologic aspects of dermal and oral lichen planus. Oral Surg Oral Med Oral Pathol Oral Radiol Endod 83:358–366, 1997.
Ramirez-Amador V, Dekker NP, Lozada-Nur F et al: Altered interface adhesion molecules in oral lichen planus. Oral Dis 2:188–192, 1996.
Ramirez-Amador V, Esquivel-Pedraza L, Sierra-Madero J et al: The changing clinical spectrum of human immunodeficiency virus (HIV) related oral lesions in 1,000 consecutive patients: a 12-year study in a referral center in Mexico. Medicine (Baltimore) 82:39–50, 2003.
Regezi JA, Daniels TE, Saeb F et al: Increased submucosal factor XIIIa-positive dendrocytes in oral lichen planus. J Oral Pathol Med 23:114–118, 1994.
Regezi JA, Dekker NP, MacPhail LA et al: Vascular adhesion molecules in oral lichen planus. Oral Surg Oral Med Oral Pathol Oral Radiol Endod 81:682–690, 1996.
Reznik DA: Oral manifestations of HIV disease, Topics. HIV Med 13:143–148, 2005.
Rozycki TW, Rogers RS, Pittelkow MR et al: Topical tacrolimus in the treatment of symptomatic oral lichen planus. J Am Acad Dermatol 46:27–34, 2002.
Salonen L, Axell T, Hellden L: Occurrence of oral mucosal lesions, the influence of tobacco habits and an estimate of treatment time in an adult Swedish population. J Oral Pathol Med 19:170–176, 1990.
Shiohara T, Moriya N, Nagashima M: Induction and control of lichenoid tissue reactions. Springer Semin Immunopathol 13:369–385, 1992.
Silverman S Jr, Gorsky M, Lozada F: Oral leukoplakia and malignant transformation. Cancer 53:563–568, 1984.
Sinor PN, Gupta PC, Murti PR et al: A case-control study of oral submucous fibrosis with special reference to the etiologic role of areca nut. J Oral Pathol Med 19:94–98, 1990.
Sniiders PJ, Schulten EA, Mullink H et al: Detection of human papillomavirus and Epstein-Barr virus DNA sequences in oral mucosa of HIV-infected patients by the polymerase chain reaction. Am J Pathol 137:659–666, 1990.
Sugerman PB, Savage NW, Seymour GJ et al: Is there a role for tumor necrosis factor-alpha in oral lichen planus? J Oral Pathol Med 25:21–24, 1996.
Van Wyk CW, Seedat HA, Phillips VM: Collagen in submucous fibrosis: an electron microscopic study. J Oral Pathol Med 19:182–187, 1990.
Vincent SD, Fotos PG, Baker KA et al: Oral lichen planus: the clinical, historical and therapeutic features of 100 cases. Oral Surg Oral Med Oral Pathol 70:165–171, 1990.
Walton LJ, Thornhill MH, Macey MG et al: Cutaneous lymphocyte-associated antigen (CLA) and alpha e beta 7 integrins are expressed by mononuclear cells in skin and oral lichen planus. J Oral Pathol Med 26:402–407, 1997.
Workshop on Oral Healthcare in HIV Disease: The provision of oral healthcare for patients with HIV disease: proceedings of workshop, London, Ontario, Canada, October 11–12, 1990. Oral Surg Oral Med Oral Pathol 73:137–247, 1992.

Nonepithelial White-Yellow Lesions

Auluck A, Rosin MP, Zhang L et al: Oral submucous fibrosis, a clinically benign but potentially malignant disease: report of 3 cases and review of the literature. J Can Dent Assoc 74:735–740, 2008.
Greenspan D: Treatment of oral candidiasis in HIV infection. Oral Surg Oral Med Oral Pathol 78:211–215, 1994.
Javed F, Chotai M, Mehmood A et al: Oral mucosal disorders associated with habitual gutka use. Oral Surg Oral Med Oral Pathol Oral Radiol Endod 109:857–864, 2010.
von Frauhofer JA, Loewy ZG: Factors involved in microbial colonization of oral prostheses. Gen Dent 57:136–143, 2009.
Zomorodian K, Haghighi NN, Rajaee N et al: Assessment of Candida species colonization and denture-related stomatitis in denture wearers. Med Mycol 49:208– 211, 2011.

CHAPTER 4

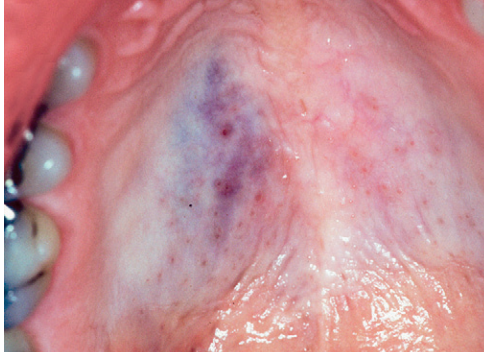

Red-Blue Lesions

INTRAVASCULAR LESIONS

CONGENITAL VASCULAR ANOMALIES
Congenital Hemangiomas and Congenital Vascular Malformations
Encephalotrigeminal Angiomatosis (Sturge-Weber Syndrome)
Hereditary Hemorrhagic Telangiectasia (Rendu-Osler-Weber Syndrome)
REACTIVE LESIONS
Varix and Other Acquired Vascular Malformations
Pyogenic Granuloma
Peripheral Giant Cell Granuloma
Scarlet Fever
NEOPLASMS
Erythroplakia
Kaposi's Sarcoma
METABOLIC-ENDOCRINE CONDITIONS
Vitamin B Deficiencies
Pernicious Anemia
Iron Deficiency Anemia
Burning Mouth Syndrome
Other Oral-Facial Pain Conditions
IMMUNOLOGIC ABNORMALITIES
Plasma Cell Gingivitis
Drug Reactions and Contact Allergies

EXTRAVASCULAR LESIONS

Petechiae and Ecchymoses

INTRAVASCULAR LESIONS

CONGENITAL VASCULAR ANOMALIES

Congenital Hemangiomas and Congenital Vascular Malformations

Etiology. The terms *congenital, hemangioma,* and *congenital vascular malformation* have been used as generic designations for many vascular proliferations, and they have been used interchangeably. Congenital hemangiomas and congenital vascular malformations appear at or around the time of birth and are more common in females. Because of the confusion surrounding the basic origin of many of these lesions, classification of clinical and microscopic varieties has been difficult. None of the numerous proposed classifications has had uniform acceptance, although there is merit in separating benign neoplasms from vascular malformations because of different clinical and behavioral characteristics (Table 4-1). The term *congenital hemangioma* is used to identify benign congenital neoplasms of proliferating endothelial cells. Congenital vascular malformations include lesions resulting from abnormal vessel morphogenesis. Separation of vascular lesions into these two groups can be of considerable significance relative to the treatment of patients. Unfortunately, in actual practice, some difficulty may be encountered in classifying lesions in this way because of overlapping clinical and histologic features.

In any event, congenital hemangiomas have traditionally been subdivided into two microscopic types—capillary and cavernous—essentially reflecting differences in vessel diameter. Vascular malformations may exhibit similar features but may also show vascular channels that represent arteries and veins.

Clinical Features. Congenital hemangioma, also known as strawberry nevus, usually appears around the time of birth but may not be apparent until early childhood (Fig. 4-1). This lesion may exhibit a rapid growth phase that is followed several years later by an involution phase. In contrast,

TABLE 4-1 CONGENITAL VASCULAR LESIONS

	Hemangioma	Vascular Malformation
Description	Abnormal endothelial cell proliferation	Abnormal blood vessel development
Elements	Results in increased number of capillaries	A mix of arteries, veins, and capillaries (includes AV shunt)
Growth	Rapid congenital growth	Grows with patient
Boundaries	Often circumscribed; rarely affects bone	Poorly circumscribed; may affect bone
Thrill and bruit	No associated thrill or bruit	May produce thrill and bruit
Involution	Usually undergoes spontaneous involution	Does not involute
Resection	Persistent lesions resectable	Difficult to resect; surgical hemorrhage
Recurrence	Recurrence uncommon	Recurrence common

AV, Arteriovenous.

congenital vascular malformations are generally persistent lesions that grow with the individual and do not involute (Figs. 4-2 to 4-6). They may represent arteriovenous shunts and exhibit a bruit or thrill on auscultation. Both types of lesions may range in color from red to blue, depending on the degree of congestion and their depth in tissue. When they are compressed, blanching occurs as blood is pressed peripherally from the central vascular spaces. This simple clinical test (diascopy) can be used to separate these lesions from hemorrhagic lesions in soft tissue (ecchymoses), where the blood is extravascular and cannot be displaced by pressure. Congenital hemangiomas and congenital vascular malformations may be flat, nodular, or bosselated. Other clinical signs include the presence of a bruit or thrill, features associated predominantly with congenital vascular malformations. Lesions are most commonly found on the lips, tongue, and buccal mucosa. Lesions that affect bone are probably congenital vascular malformations rather than congenital hemangiomas.

Vascular malformations are also a component of the rare condition termed *blue rubber bleb nevus syndrome (Bean's syndrome),* in which multiple small and large cavernous hemangiomas are present on the skin and throughout the gastrointestinal tract, including the mouth. The condition is usually diagnosed in childhood or young adulthood. Recognition of this syndrome is significant because many of those afflicted may suffer overt life-threatening gastrointestinal bleeding or occult blood loss with severe anemia and iron deficiency.



■ **FIGURE 4-1** Congenital hemangioma.

Histopathology. Congenital hemangiomas are composed of abundant capillary spaces lined by endothelium without muscular support. Congenital vascular malformations may consist not only of capillaries, but also of venous, arteriolar, and lymphatic channels. Direct arteriovenous communications are typical. Lesions may be of purely one type of vessel, or they may consist of two or more vessels. Vascular morphology accounts for lesions exhibiting rapid flow versus those exhibiting slow flow.

Diagnosis. As a generic group, the diagnosis of congenital vascular lesions is usually self-evident on clinical examination. When they affect the mandible or the maxilla, a radiolucent lesion with a honeycomb pattern and distinct margins is expected. Differentiation between congenital hemangiomas and congenital vascular malformations can be difficult and occasionally impossible. When affecting a segmental portion of the face or oral cavity, facial hemangiomas may be associated with several syndromes, which may include the eye, heart, and posterior cranial fossa (PHACE syndrome). A complete history, a clinical examination, and angiography or angiographic magnetic resonance imaging should be definitive in lesion identification and characterization.

Treatment. Spontaneous involution during early childhood is likely for congenital hemangiomas. If these lesions persist into the later years of childhood, involution is improbable and definitive treatment may be required. Congenital vascular malformations generally do not involute, and they require intervention if eradication is the goal. Excellent results may be achieved with propranolol, a nonselective beta-adrenergic blocking agent. Adjuncts include selective arterial embolization and sclerosant therapy. Laser therapy is another accepted form of primary treatment of selected vascular lesions. Because the margins of these lesions are often ill defined, total elimination may not be practical or possible.

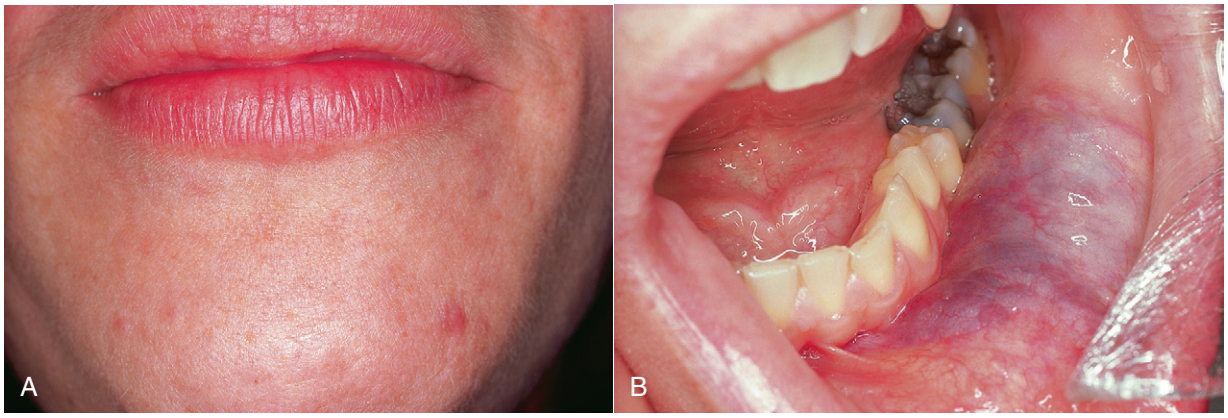

■ **FIGURE 4-2 A** and **B,** Oral vascular malformation causing slight facial asymmetry.



■ **FIGURE 4-3** Vascular malformation of the maxillary mucosa.

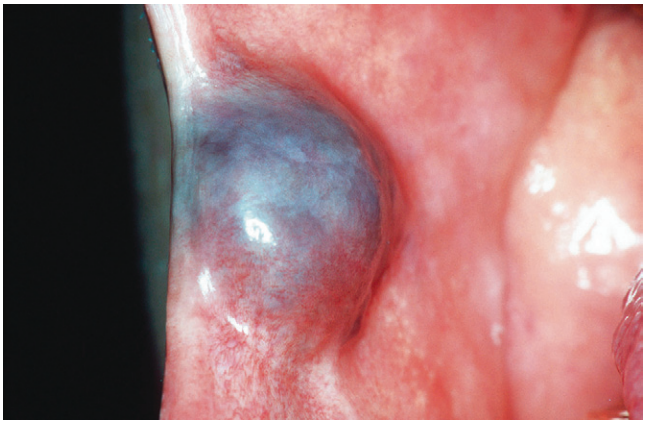

■ **FIGURE 4-5** Vascular malformation of the buccal mucosa.



■ **FIGURE 4-4** Vascular malformation of the palate.

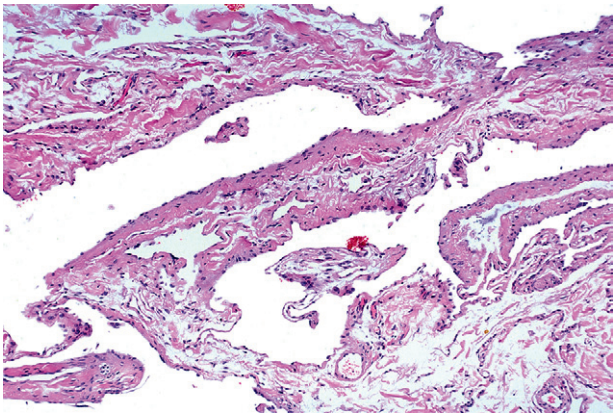

■ **FIGURE 4-6** Vascular malformation composed of large tortuous channels lined by endothelium.

Encephalotrigeminal Angiomatosis (Sturge-Weber Syndrome)

Encephalotrigeminal angiomatosis, or *Sturge-Weber syndrome,* is a neurocutaneous syndrome that includes vascular malformations with characteristic distribution. In this syndrome, venous malformations involve the leptomeninges of the cerebral cortex, usually with similar vascular malformations of the face (Fig. 4-7). The associated facial lesion, also known as *port-wine stain* or *nevus flammeus,* involves the skin innervated by one or more branches of the trigeminal nerve. Port-wine stains may also occur as isolated lesions of the skin without the other stigmata of encephalotrigeminal angiomatosis. The vascular defect of encephalotrigeminal

angiomatosis may extend intraorally to involve the buccal mucosa and the gingiva. Ocular lesions may appear.

Neurologic effects of encephalotrigeminal angiomatosis may include mental retardation, hemiparesis, and seizure disorders. Patients may be taking phenytoin (Dilantin) or similar drugs for control of the latter problem, with possible secondary development of drug-induced generalized gingival hyperplasia in relation to phenytoin. Calcification of the intracranial vascular lesion may provide radiologic evidence of the process in the leptomeninges.

A differential diagnosis would include Parkes-Weber syndrome and *angio-osteohypertrophy (Klippel-Trenaunay) syndrome,* the latter characterized by vascular malformations of the face (port-wine stains), varices, and hypertrophy of bone.

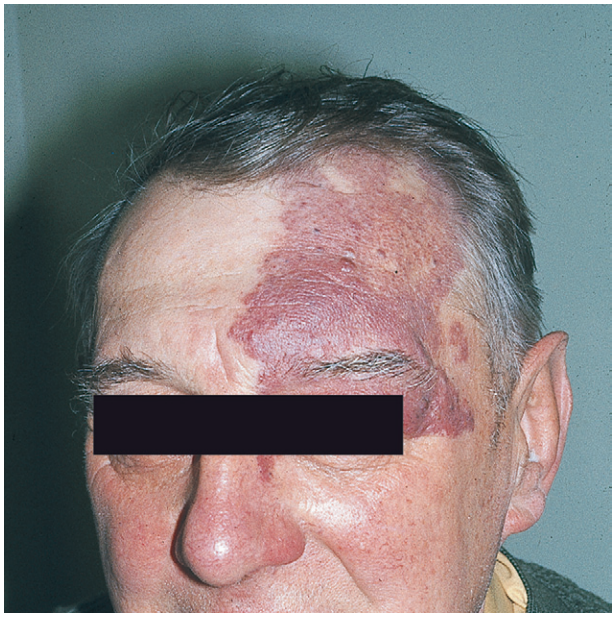

■ **FIGURE 4-7** Vascular malformation in Sturge-Weber syndrome. (Reproduced with permission from Regezi JA, Sciubba JJ, Pogrel MA: Atlas of Oral and Maxillofacial Pathology. Philadelphia, 2000, WB Saunders, Figure 3-12.)

The bony abnormality usually affects long bones but may also involve the mandible or maxilla, resulting in asymmetry, malocclusion, and an altered eruption pattern.

Hereditary Hemorrhagic Telangiectasia (Rendu-Osler-Weber Syndrome)

Hereditary hemorrhagic telangiectasia (HHT), or *Rendu-Osler-Weber syndrome,* is a rare condition, affecting 1 in 5000 to 8000 people, that is transmitted in an autosomal-dominant manner. Most cases are caused by mutations in two genes: endoglin on chromosome 9 (HHT type 1) and activin receptor–like kinase 1 (ALK 1) on chromosome 12 (HHT type 2). These genes are members of the transforming growth factor (TGF)-β signaling pathway and are implicated in vascular development and repair. HHT features abnormal and fragile vascular dilations of terminal vessels in skin and mucous membranes, as well as arteriovenous malformations of internal organs, particularly lungs, brain, and liver (Fig. 4-8). Telangiectatic vessels in this condition appear clinically as red macules or papules, typically on the face, chest, and oral mucosa. Lesions appear early in life, persist throughout adulthood, and often increase in number with aging.

Intranasal telangiectasias are responsible for epistaxis, the most common presenting sign of hereditary hemorrhagic telangiectasia. Bleeding from oral lesions is a common occurrence in affected patients. Occasionally, control of bleeding may be a difficult problem. Chronic low-level bleeding may also result in iron deficiency anemia.

Diagnosis of HHT is based on a history of spontaneous epistaxis, the presence of telangiectasias, arteriovenous malformations of internal organs, and family history. Another condition that might be considered in a differential diagnosis is *CREST syndrome.* This includes *c*alcinosis cutis, *R*aynaud's phenomenon, *e*sophageal dysfunction, *s*clerodactyly, and *t*elangiectasia.

Clinical management includes follow-up examination and the use of antifibrinolytic drugs for those with frequent epistaxis.



■ **FIGURE 4-8 A** and **B,** Rendu-Osler-Weber syndrome. Note numerous telangiectasias on the skin and tongue. The patient also has a secondary/recurrent herpetic lesion on her upper lip.



■ **FIGURE 4-9** Varix, ventral tongue.

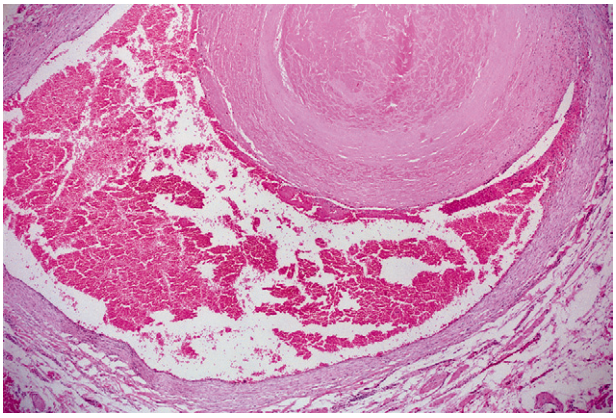

■ **FIGURE 4-11** Varix with thrombus.



■ **FIGURE 4-10** Thrombosed varix of the lower lip.

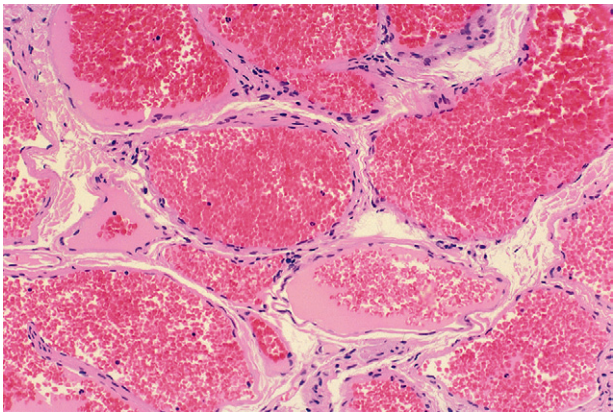

■ **FIGURE 4-12** Acquired vascular malformation.

REACTIVE LESIONS

Varix and Other Acquired Vascular Malformations

A *venous varix,* or varicosity, is a type of acquired vascular malformation that represents focal dilation of a single vein. It is a relatively trivial but common vascular malformation when it appears in the oral mucosa and lips (Figs. 4-9 to 4-11). Varices involving the ventral aspect of the tongue are common developmental abnormalities. Varices are also common on the lower lip in older adults, representing vessel wall weakness caused by chronic sun exposure with subsequent dilation. Varices typically are blue and blanch with compression. Thrombosis, which is insignificant in these lesions, occasionally occurs, giving them a firm texture. No treatment is required for a venous varix unless it is frequently traumatized or is cosmetically objectionable.

Other *acquired vascular malformations* represent a more complex network or proliferation of thin-walled vessels than simple varices. These are relatively common, are seen in adults, and are of undetermined cause (Fig. 4-12). Some may be related to vessel trauma and subsequent abnormal repair. These lesions present as red-blue discrete and asymptomatic tumescences that can be excised relatively easily.

Pyogenic Granuloma

Etiology. Pyogenic granuloma represents an exuberant connective tissue proliferation to a known stimulus or injury. It appears as a red mass because it is composed predominantly of hyperplastic granulation tissue in which capillaries are very prominent. The term *pyogenic granuloma* is a misnomer in that it is not pus producing, and it does not represent granulomatous inflammation (Table 4-2).

Clinical Features. Pyogenic granulomas occur mostly in the second decade of life and are most commonly seen on the attached gingiva (75%), where they presumably are caused by the presence of calculus or foreign material within the gingival crevice (Figs. 4-13 to 4-15). The tongue, lower lip, and buccal mucosa are the next most common sites. Hormonal changes of puberty and pregnancy may modify the gingival reparative response to injury, producing what was once called a *pregnancy tumor.* Under these circumstances, multiple gingival lesions or generalized gingival hyperplasia may be seen.

Pyogenic granulomas are typically red and smooth or lobulated with hemorrhagic and compressible features. They characteristically become ulcerated because of secondary

TABLE 4-2 GINGIVAL REACTIVE HYPERPLASIAS

	Pyogenic Granuloma	Peripheral Giant Cell Granuloma
Etiology	Initiated by trauma or irritation Modified by hormones, drugs	Probably trauma or irritation Not related to hormones or drugs
Location	Predominantly gingiva, but any traumatized soft tissue	Exclusively gingival Usually anterior to first molars
Histopathology	Hyperplastic granulation tissue Misnomer—neither pus producing nor granulomatous	Hyperplasia of fibroblasts with multinucleated giant cells Not granulomatous inflammation
Treatment	Excision to periosteum or periodontal membrane	Excision to periosteum or periodontal membrane
Recurrence	Some recurrence; no malignant potential	Some recurrence; no malignant potential



■ **FIGURE 4-13** Pyogenic granuloma.



■ **FIGURE 4-14** Pyogenic granuloma.

trauma. The ulcerated lesions may then become covered by a yellow, fibrinous membrane. They may be pedunculated or broad based and may range in size from a few millimeters to several centimeters. Older lesions become more pink and collagenized. These lesions may be seen at any age and tend to occur more commonly in females than in males; they are seen in up to 5% of pregnancies.

Histopathology. Microscopically, pyogenic granulomas are composed of lobular masses of hyperplastic granulation tissue (Fig. 4-16). Some scarring may be noted in some of these lesions, suggesting that occasionally maturation of the connective tissue repair process may occur. Variable numbers of chronic inflammatory cells may be seen. Neutrophils are present in the superficial zone of ulcerated pyogenic granulomas.

Differential Diagnosis. Clinically, this lesion is similar to peripheral giant cell granuloma, which also presents as a red gingival mass. A peripheral odontogenic or ossifying fibroma may be another consideration, although these tend to be much lighter in color. Less commonly, other conditions that may be considered include Kaposi's sarcoma, bacillary angiomatosis, and non-Hodgkin's lymphoma. Rarely, metastatic

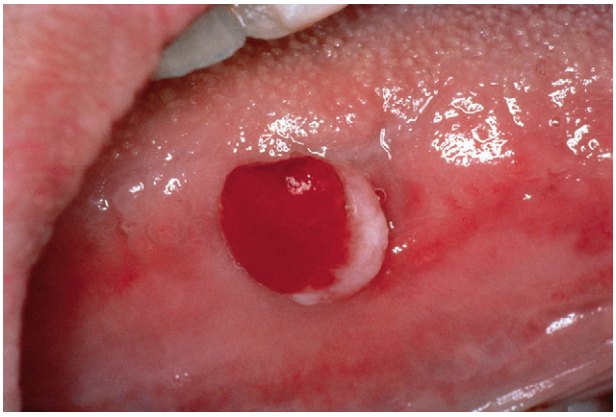

■ **FIGURE 4-15** Pyogenic granuloma of the lateral tongue.

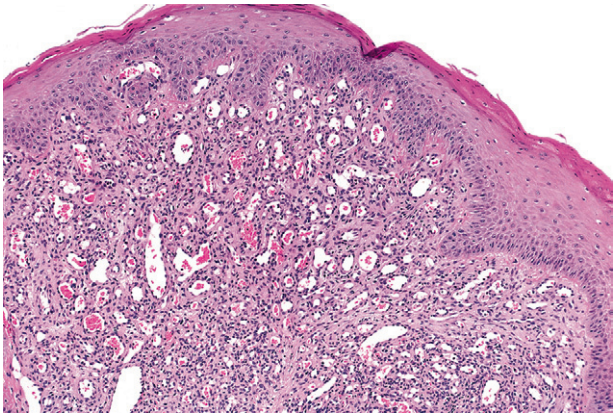

■ **FIGURE 4-16** Pyogenic granuloma showing abundant capillaries.



■ **FIGURE 4-17** Peripheral giant cell granuloma.

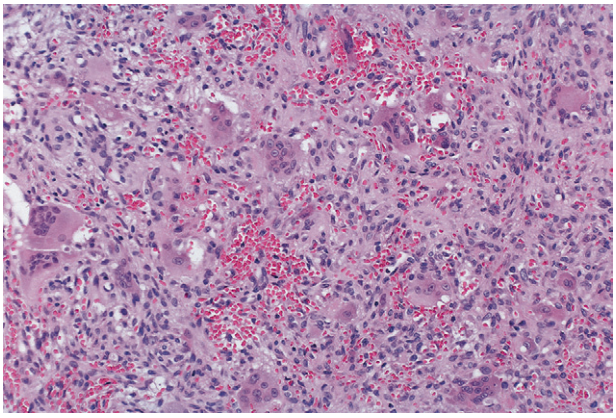

■ **FIGURE 4-18** Peripheral giant cell granuloma showing fibroblastic matrix and abundant multinucleated giant cells.

cancer may present as a red gingival mass. Biopsy findings are definitive in establishing the diagnosis.

Treatment. Pyogenic granulomas should be surgically excised; removal should include the connective tissue from which the lesion arises, as well as local etiologic factors (plaque, calculus, foreign material, source of trauma). Recurrence is occasional and is believed to result from incomplete excision, failure to remove etiologic factors, or reinjury of the area. The end of pregnancy often brings considerable shrinkage of pregnancy-associated pyogenic granulomas, but residual lesions may need to be excised.

Peripheral Giant Cell Granuloma

Etiology. Peripheral giant cell granuloma is a relatively uncommon and unusual hyperplastic connective tissue response to injury of gingival tissues. It is one of the "reactive hyperplasias" commonly seen in oral mucous membranes, representing an exuberant reparative process in association with local trauma or irritation. The feature that sets this lesion apart from the others is the appearance of multinucleated giant cells, but the reason for their presence remains unknown.

Clinical Features. Peripheral giant cell granulomas are seen exclusively in gingiva, usually between the first permanent molars and the incisors (Fig. 4-17). They presumably arise from periodontal ligament or periosteum, and they cause, on occasion, resorption of alveolar bone. When this process occurs on the edentulous ridge, a superficial, cup-shaped radiolucency may be seen. Peripheral giant cell granulomas typically appear as red to blue, broad-based masses. Secondary ulceration caused by trauma may result in the formation of a fibrin clot over the ulcer. These lesions, most of which are about 1 cm in diameter, may occur at any age and tend to be seen more commonly in females than in males.

Histopathology. Fibroblasts are the basic element of peripheral giant cell granulomas (Fig. 4-18). Scattered throughout the fibroblasts are abundant multinucleated giant cells believed to be related to osteoclasts. The giant cells appear to be nonfunctional in the usual sense of phagocytosis and bone resorption.

Islands of metaplastic bone occasionally may be seen in these lesions. This finding has no clinical significance. Chronic inflammatory cells are present, and neutrophils are found in ulcer bases.

Differential Diagnosis. Generally, this lesion is clinically indistinguishable from a pyogenic granuloma. Although a peripheral giant cell granuloma is more likely to cause bone resorption than is a pyogenic granuloma, the differences are otherwise minimal. A biopsy provides definitive diagnostic results. Microscopically, a peripheral giant cell granuloma is identical to its central or intraosseous counterpart, the central giant cell granuloma.

Treatment. Surgical excision is the preferred treatment for peripheral giant cell granulomas. Removal of local factors or irritants is also required. Recurrences, which are seen occasionally, are believed to be related to lack of inclusion of periosteum or periodontal ligament in the excised specimen.

Scarlet Fever

Scarlet fever is an acute exanthematous condition caused by any of three exotoxin-producing, antigenically dissimilar streptococcal strains (A, B, or C), most commonly seen between 1 and 10 years of age. The characteristic effects of scarlet fever, a systemic bacterial infection, are the result of an erythrogenic toxin that causes capillary damage and that is produced most commonly by some strains of group A streptococci. Other strains of group A streptococci that are unable to produce the toxin can cause pharyngitis and all the

attendant features of infection, but without the red skin rash and oral signs of scarlet fever. All group A streptococcal infections are generally spread through droplets from contact with an infected individual or, less likely, a carrier. Crowded living conditions promote the spread of streptococcal infections, with the upper respiratory tract representing the most common portal of entry.

Clinically, children are typically affected after an incubation period of several days. In addition to the usual symptoms of all group A streptococcal infections—pharyngitis, tonsillitis, fever, lymphadenopathy, malaise, and headache—the child exhibits a red skin rash that starts on the chest and spreads to other surfaces. The face is flushed except for a zone of circumoral pallor. The palate may show nonspecific inflammatory changes, and the tongue may become covered with a white coat in which fungiform papillae are enlarged and reddened (strawberry tongue). Later, the coat is lost, leaving a beefy red tongue (red strawberry tongue or raspberry tongue). In untreated and uncomplicated cases, the disease subsides in a matter of days.

Penicillin is the drug of choice for the treatment of group A streptococcal infections. Erythromycin should be used in patients allergic to penicillin. The rationale for antibiotic treatment of this short-lived, self-limited disease is the prevention of complications, particularly rheumatic fever and glomerulonephritis.

NEOPLASMS

Erythroplakia

Etiology. *Erythroplakia* is a clinical term that refers to a red patch on oral mucous membranes. It does not indicate a particular microscopic diagnosis, although after a biopsy most cases are found to be severe dysplasia or carcinoma. The causes of this lesion are believed to be similar to those responsible for oral cancer. Therefore tobacco use probably has a significant role in the induction of many of these lesions, as does heavy alcohol consumption. Nutritional deficits and other factors may have modifying roles.

Clinical Features. Erythroplakia is seen much less commonly than its white lesion counterpart, leukoplakia. A strong association with tobacco consumption and use of alcohol has been noted. In comparison with leukoplakia, it should, however, be viewed as a more serious lesion because of the significantly higher percentage of malignancies associated with it (Box 4-1). The lesion appears as a velvety red patch with well-defined margins (Figs. 4-19 and 4-20).

BOX 4-1 ERYTHROPLAKIA

IDIOPATHIC MUCOSAL RED PATCH

Cause unknown—some related to tobacco
Age—typically between 50 and 70 years
High-risk sites—floor of mouth, tongue, retromolar mucosa, soft palate

HISTOPATHOLOGY

Squamous cell carcinoma (50%)
Severe dysplasia or in situ carcinoma (40%)
Mild to moderate dysplasia (10%)
Biopsy must be performed.

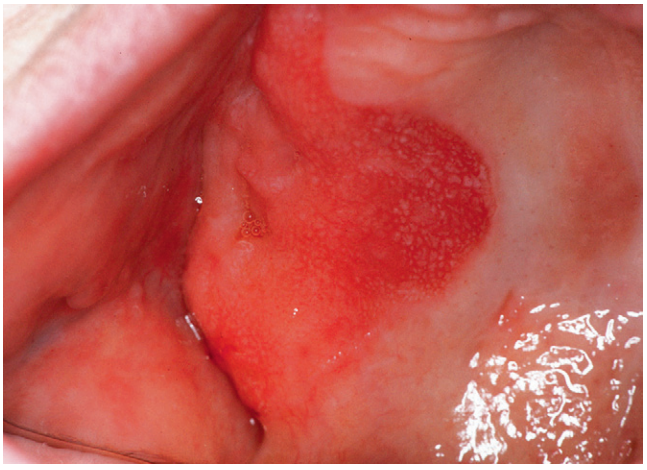

■ **FIGURE 4-19** Erythroplakia of the palate and alveolar ridge.

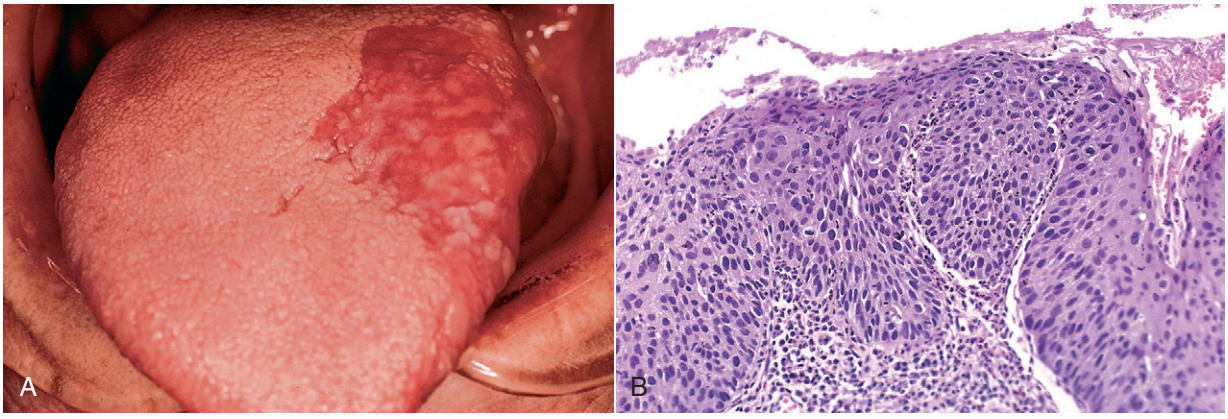

■ **FIGURE 4-20 A,** Erythroplakia of the tongue. **B,** Biopsy specimen showing carcinoma in situ.

Common sites of involvement include the floor of the mouth, the tongue, retromolar mucosa, and the soft palate. Individuals between 50 and 70 years of age are usually affected, and no gender predilection is apparent. Focal white areas representing keratosis may be seen in some lesions (erythroleukoplakia). Erythroplakia is usually supple to the touch unless the lesion is invasive, in which case induration may be noted.

Histopathology. Approximately 40% of erythroplakias show severe dysplastic change; about 50% are squamous cell carcinoma and 9% mild or moderate dysplasia. A relative reduction in keratin production and a relative increase in vascularity account for the clinical color of these lesions.

A histologic variant of carcinoma in situ exhibits changes analogous to the skin lesion called *Bowen's disease*. Microscopic features that separate this bowenoid change from the usual carcinoma in situ include marked disordered growth, multinucleated keratinocytes, large hyperchromatic keratinocyte nuclei, and atypical individual cell keratinization.

Differential Diagnosis. Differential diagnosis should include Kaposi's sarcoma, ecchymosis, contact allergic reaction, vascular malformation, and psoriasis. The clinical history and examination should distinguish most of these lesions. A biopsy provides a definitive answer.

Treatment. The treatment of choice for erythroplakia is surgical excision. Generally, it is more important to excise widely than to excise deeply in dysplastic and in situ lesions because of their superficial nature and the fact that dysplastic cells usually extend beyond the clinically evident lesion. However, because epithelial changes may extend along the salivary gland excretory ducts in the area, the deep surgical margin should not be too shallow (Fig. 4-21). Several histologic sections may be necessary to adequately assess the involvement of salivary ducts.

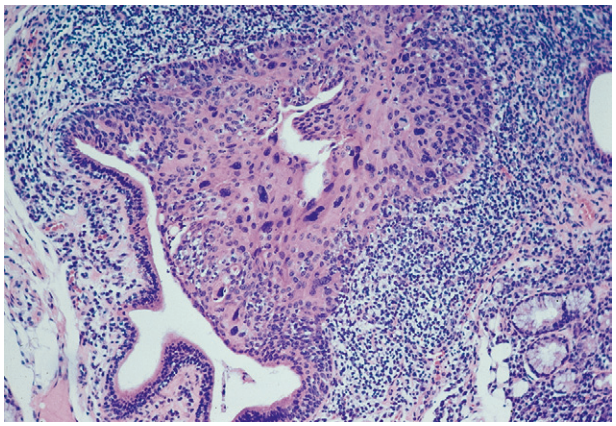

■ **FIGURE 4-21** In situ carcinoma extending into salivary duct. (Reproduced with permission from Regezi JA, Sciubba JJ, Pogrel MA: Atlas of Oral and Maxillofacial Pathology. Philadelphia, 2000, WB Saunders, Figure 3-19.)

It is generally accepted that severely dysplastic and in situ lesions eventually become invasive. The time required for this event can range from months to years. Follow-up examinations are critical for patients with these lesions because of the potential field effect and corresponding genetic and molecular alterations caused by etiologic agents.

Kaposi's Sarcoma

Etiology. Kaposi's sarcoma is a proliferation of endothelial cell origin, although dermal/submucosal dendrocytes, macrophages, lymphocytes, and probably mast cells may have a role in the genesis of these lesions. A relatively recently discovered herpesvirus known as human herpesvirus 8 (HHV8), or Kaposi's sarcoma herpesvirus (KSHV), has been identified in all forms of Kaposi's sarcoma lesions, as well as in acquired immunodeficiency syndrome (AIDS)-associated body cavity lymphomas and in multicentric Castleman's disease. This virus is believed to have a significant role in the induction and/or maintenance of Kaposi's sarcoma through perturbation of focally released cytokines and growth factors via virally encoded microRNAs.

Clinical Features. Three different clinical patterns of Kaposi's sarcoma have been described (Figs. 4-22 to 4-25).

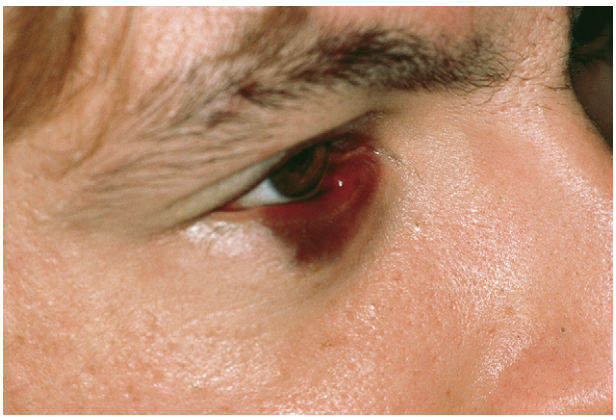

■ **FIGURE 4-22** Kaposi's sarcoma.



■ **FIGURE 4-23** Kaposi's sarcoma of the neck.

The condition was initially described by Kaposi in 1872 as a rare skin lesion, predominantly in older men living in the Mediterranean basin (Table 4-3). In this classic form, it appears as multifocal reddish-brown nodules primarily in the skin of the lower extremities, although any organ may be affected. Oral lesions are rare in this type. This classic form has a rather long indolent course and only a fair prognosis.

The second pattern of Kaposi's sarcoma was identified in Africa, where it is considered endemic. It is typically seen in the extremities of blacks. The most commonly affected organ is the skin. Oral lesions are rarely seen. The clinical course is prolonged, and the overall prognosis is only fair.

The third pattern of Kaposi's sarcoma has been seen in patients with immunodeficiency states, including patients with organ transplants and especially AIDS (Box 4-2). This type differs from the other two forms in several ways. Skin lesions are not limited to the extremities, and they may be multifocal. Oral mucosal and regional lymph node lesions are relatively common. Visceral organs may also be involved, and a younger age group is affected. The clinical course is relatively rapid and aggressive, and the prognosis is correspondingly poor.

Kaposi's sarcoma, once occurring in about one third of patients with AIDS, is now seen with considerably less frequency—a shift that appears to be related to suppression of human immunodeficiency virus (HIV) replication by antiretroviral drug therapy and concurrent improvement in CD4 lymphocyte levels, particularly with the use of highly active antiretroviral therapy (HAART). About half of AIDS-affected patients with cutaneous Kaposi's sarcoma develop oral lesions. Of significance is that oral lesions may be the initial site or the only site of involvement. Kaposi's sarcoma has been described in most oral regions, although the palate,

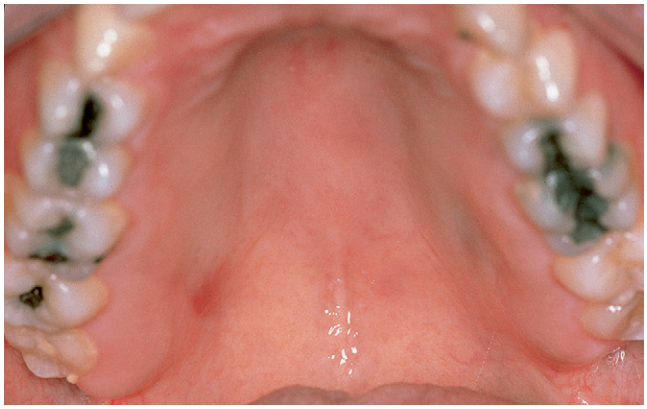

■ **FIGURE 4-24** Kaposi's sarcoma presenting as a dark macule in the right posterior palate.



■ **FIGURE 4-25** Advanced Kaposi's sarcoma of the gingiva.

BOX 4-2 KAPOSI'S SARCOMA: KEY FEATURES

Initiation by HHV8 control of endothelial cell proliferation
Perpetuation by cytokines and growth factors released by macrophages, lymphocytes, and other cells
Incidence—immunodeficiency type markedly reduced following use of new drugs to treat AIDS
High-risk oral sites—palate and gingiva
Early lesions—blue macule(s)
Differential—ecchymosis, vascular malformation, erythroplakia, melanoma, blue nevus, amalgam tattoo
Advanced lesions—nodular red-blue mass
Treatment—intralesional chemotherapy, radiation, and surgery (debulking) have produced modest results

AIDS, Acquired immunodeficiency syndrome; *HHV8*, human herpesvirus 8.

TABLE 4-3 KAPOSI'S SARCOMA

	Classic Type	Endemic Type	Immunodeficiency Type
Etiology	HHV8	HHV8	HHV8
Geography	Mediterranean basin	Africa	AIDS and transplant patients
Prevalence	Rare	Endemic	Uncommon
Age	Older men	Children and adults	Young adults
Sites	Skin, lower extremities	Skin, extremities	Skin, mucosa, internal organs
Course	Indolent but progressive	Prolonged	Aggressive
Prognosis	Fair prognosis	Fair prognosis	Poor prognosis

AIDS, Acquired immunodeficiency syndrome; *HHV8,* human herpesvirus 8.

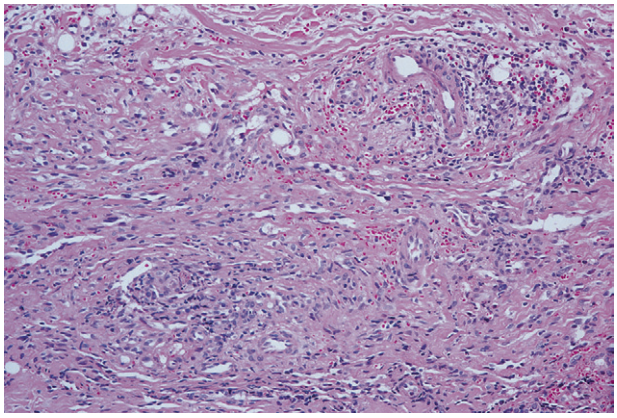

■ **FIGURE 4-26** Early Kaposi's sarcoma showing a subtle increase in the number of capillaries and extravasated red blood cells.

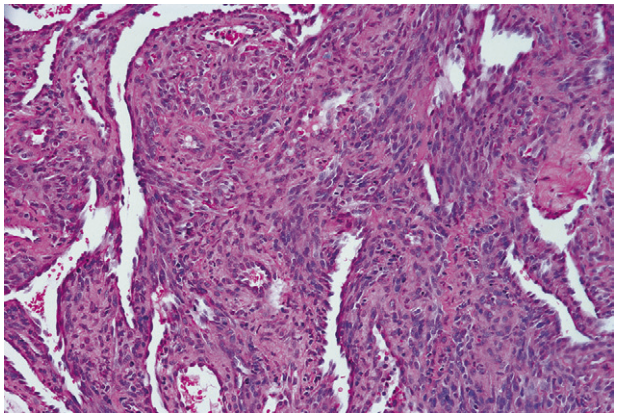

■ **FIGURE 4-27** Advanced Kaposi's sarcoma showing spindle cell proliferation and bizarre capillaries.

gingiva, and tongue seem to be the most commonly affected sites. Clinical presentation of oral Kaposi's sarcoma ranges from early, rather trivial-appearing, flat lesions to late, nodular, exophytic lesions. Lesions may be single or multifocal. The color is usually red to blue. AIDS-affected patients with oral Kaposi's sarcoma may have other oral problems concomitantly, such as candidiasis, hairy leukoplakia, advancing periodontal disease, and xerostomia.

Histopathology. Early lesions of Kaposi's sarcoma may be rather subtle, being composed of hypercellular foci containing bland-appearing spindle cells, ill-defined vascular channels, and extravasated red blood cells (RBCs) (Figs. 4-26 to 4-28). Later, they may superficially resemble pyogenic granulomas. Atypical vascular channels, extravasated RBCs, hemosiderin, and inflammatory cells are characteristic of advanced Kaposi's sarcoma. Macrophages, factor XIIIa–positive dendrocytes, lymphocytes, and mast cells are also seen in oral Kaposi's sarcoma (early and late stages).

In instances where Kaposi's sarcoma (or other vascular neoplasm) is being considered, immunohistochemical studies may be beneficial. Antibodies to CD31, CD34, and factor VIII–related antigen will identify endothelial cell–derived tumors. Anti-CD34 is also useful in confirming the diagnosis of solitary fibrous tumor. A commercial antibody to the causative virus HHV8-KSHSV is available and is useful in establishing the diagnosis of Kaposi's sarcoma using immunohistochemistry.

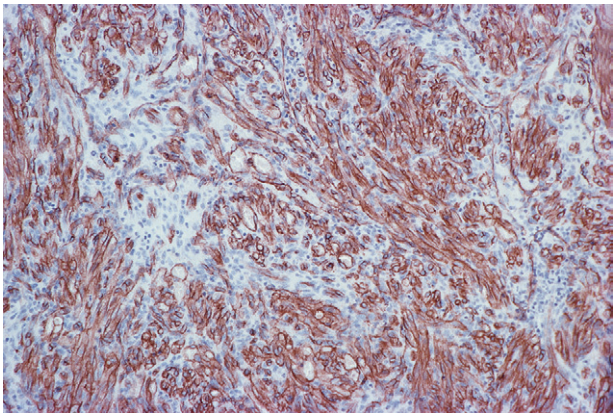

■ **FIGURE 4-28 Kaposi's sarcoma.** Positive immunohistochemical stain for CD34 of Kaposi's sarcoma, confirming spindle cells as endothelial cells.

Differential Diagnosis. Clinical considerations include hemangioma, erythroplakia, melanoma, and pyogenic granuloma. Another remarkable look-alike, known as *bacillary angiomatosis,* mimics Kaposi's sarcoma both clinically and microscopically. The causative organism is *Bartonella henselae* or *Bartonella quintana*. Cats are reservoirs for this organism, and fleas may be vectors. Microscopically, neutrophils and bacterial colonies are seen. This condition is cured with erythromycin or tetracycline therapy. Bacillary angiomatosis is uncommon in the skin and is very rare in oral mucous membranes.

Treatment. Various forms of treatment have been used for Kaposi's sarcoma, but none has been uniformly successful. Surgery has been useful on localized lesions, and low-dose radiation and intralesional chemotherapy have been used. For larger and multifocal lesions, systemic chemotherapeutic regimens are being used. Improvement in the underlying immunosuppression may help to reduce the size and number of the lesions. In cases of Kaposi's sarcoma associated with organ transplant–related immunosuppression and HIV disease, resolution has been achieved by alteration of the immunosuppression regimen and antiretroviral therapy.

METABOLIC-ENDOCRINE CONDITIONS

Vitamin B Deficiencies

Etiology. In various areas of the world, especially those with poor socioeconomic conditions, vitamin B deficiencies may be relatively common because of inadequate dietary

intake. In the United States, deficiencies of the B vitamins are relatively uncommon.

Vitamin B deficiencies may involve one or several of the water-soluble B complex vitamins. Decreased intake through malnutrition associated with alcoholism, starvation, or fad diets may lead to clinically apparent disease. Decreased absorption resulting from gastrointestinal disease (e.g., malabsorption syndromes) or increased use because of increased demand (e.g., hyperparathyroidism) may also account for deficiencies.

Most of the vitamins classified under the B complex (biotin, nicotinamide, pantothenic acid, and thiamine) are involved in intracellular metabolism of carbohydrates, fats, and proteins. Others (vitamin B_{12} and folic acid) are involved in erythrocyte development. Deficiencies of individual vitamins may produce distinctive clinical pictures. Significant oral changes have been well documented in deficiencies of riboflavin (ariboflavinosis), niacin (pellagra), folic acid (one of the megaloblastic anemias), and vitamin B_{12} (pernicious anemia) (see the following section).

Clinical Features. In general, oral changes associated with vitamin B deficiencies consist of cheilitis and glossitis. The lips may exhibit cracking and fissuring that are exaggerated at the corners of the mouth, in which case the condition is called *angular cheilitis.* The tongue becomes reddened, with atrophy of papillae, and patients complain of pain, tenderness, and burning (Fig. 4-29).

In addition to these oral changes, riboflavin deficiency results in keratitis of the eyes and a scaly dermatitis focused on the nasolabial area and genitalia. Niacin deficiency is associated with extraoral problems as well. The "four Ds" of niacin deficiency are dermatitis, diarrhea, dementia, and death. The most striking and consistent feature is a symmetrically distributed dermatitis that eventually shows marked thickening and pigmentary changes. Dementia is seen in the form of disorientation and forgetfulness. The glossitis in this deficiency may be severe and may extend to other mucosal surfaces.



■ **FIGURE 4-29** Atrophic glossitis. (Reproduced with permission from Regezi JA, Sciubba JJ, Pogrel MA: Atlas of Oral and Maxillofacial Pathology. Philadelphia, 2000, WB Saunders, Figure 3-20.)

Folic acid deficiency results in a megaloblastic (enlarged RBC precursors) bone marrow, a macrocytic (enlarged circulating erythrocytes) anemia, and gastrointestinal abnormalities, including diarrhea and the general oral lesions described previously. Vitamin B_{12} deficiency shares many of the signs and symptoms of folic acid deficiency. These are detailed in the following sections on anemia.

Diagnosis and Treatment. Diagnosis of B complex deficiencies is based on the history, clinical findings, and laboratory data. Replacement therapy should be curative.

Pernicious Anemia

Etiology. Pernicious anemia is essentially a deficiency of vitamin B_{12} (erythrocyte-maturing factor or extrinsic factor); vitamin B_{12} is necessary for DNA synthesis, especially in rapidly dividing cells, such as those found in bone marrow and the gastrointestinal tract. Pernicious anemia results from the inability to transport vitamin B_{12} across intestinal mucosa because of a relative lack of a gastric substance (intrinsic factor). This intrinsic factor is normally complexed to vitamin B_{12}, making the vitamin available to mucosal cells for absorption. An autoimmune response directed against the intrinsic factor producing parietal cells in the gastric mucosa is believed to be the probable mechanism responsible for pernicious anemia. The end result consists of atrophic gastritis, achlorhydria, neurologic changes, megaloblastic bone marrow, and macrocytic anemia. In addition, significant oral manifestations may be seen.

Clinical Features. Pernicious anemia affects adults of either gender. The clinical signs of anemia—weakness, pallor, shortness of breath, difficulty in breathing, and increased fatigue on exertion—may be present. In more severe cases, central nervous system manifestations (headache, dizziness, and tinnitus) and gastrointestinal manifestations (nausea, diarrhea, and stomatitis) may be noted.

Specific oral complaints center on the tongue. Pain and burning are typical symptoms. The tongue appears redder because of atrophy of the papillae. The resultant smooth, red appearance has been referred to as *Hunter's glossitis* or *Moeller's glossitis.* Angular cheilitis, oral candidiasis, recurrent oral ulcers, and a diffuse erythematous mucositis have been noted.

Diagnosis. The clinical picture of pernicious anemia can be only presumptive of this disease. Diagnosis is based on

laboratory demonstration of a megaloblastic, macrocytic anemia.

Treatment. Parenteral administration of vitamin B_{12} is curative for this condition. Increased risk of the development of gastric carcinoma is associated with the chronic atrophic gastritis that may occur in pernicious anemia.

Iron Deficiency Anemia

Etiology. Iron deficiency anemia is a rather common anemia caused by iron deficiency. This deficiency may be due to inadequate dietary intake; impaired absorption caused by a gastrointestinal malady; chronic blood loss caused by such problems as excessive menstrual flow, gastrointestinal bleeding, or aspirin ingestion; and increased demand as experienced during childhood and pregnancy.

Clinical Features. This relatively prevalent form of anemia predominantly affects women. In addition to the clinical signs and symptoms associated with anemias in general, iron deficiency anemia may result in brittle nails and hair and koilonychia (spoon-shaped nails). The tongue may become red, painful, and smooth. Angular cheilitis may also be seen.

In addition to iron deficiency, the Plummer-Vinson (Paterson-Kelly) syndrome includes dysphagia, atrophy of the upper alimentary tract, and a predisposition to the development of oral cancer.

Diagnosis. Laboratory blood studies show slightly to moderately reduced hematocrit and reduced hemoglobin level. The RBCs are microcytic and hypochromic. The serum iron level is also low, but the total iron-binding capacity (TIBC) is elevated.

Treatment. Recognition of the underlying cause of iron deficiency anemia is necessary to treat this condition effectively. Dietary iron supplements are required to elevate hemoglobin levels and replenish iron stores once an underlying cause has been defined and treated.

Burning Mouth Syndrome

This relatively common "nonlesion" clinical problem is included in this section because the symptoms associated with burning mouth also appear in patients with vitamin B deficiency, pernicious anemia, iron deficiency anemia, and chronic atrophic candidiasis. Patients with burning mouth, or burning tongue, syndrome usually exhibit no clinically detectable lesions, although symptoms of pain and burning can be intense. This is a particularly frustrating problem for both patient and clinician, because usually no clear-cut cause is evident once the previously stated conditions are ruled out, and no uniformly successful treatment is present.

TABLE 4-4 BURNING MOUTH (TONGUE) SYNDROME

Potential Causes	Potentially Helpful Regimens
Varied	Empathy
Candida albicans	Antifungals
Xerostomia—drugs, anxiety, Sjögren's syndrome	Oral lubricants—Moi-Stir, MouthKote, Salivart, Sialor
Nutritional deficiency—B vitamins, iron, zinc	Dietary supplement—vitamins, minerals
Abnormal tongue habit	Topical corticosteroids
Depression, anxiety	Tricyclic antidepressants, other
Pernicious anemia	Medical referral—internist, psychiatrist, gynecologist
Diabetes mellitus	
Hormone imbalance	

Etiology. The etiology of burning mouth syndrome is varied and often is difficult to decipher clinically. Symptoms of pain and burning appear to be the result of one of many possible causes (Table 4-4). The following factors have been cited as having possible etiologic significance:

- Microorganisms—especially fungi *(Candida albicans)* and possibly bacteria (staphylococci, streptococci, anaerobes)
- Xerostomia associated with Sjögren's syndrome, anxiety, or drugs (see Chapter 8)
- Nutritional deficiencies associated primarily with B vitamin complex or iron, and possibly zinc
- Anemias, namely, pernicious anemia and iron deficiency anemia
- Hormone imbalance, especially hypoestrogenemia associated with postmenopausal changes
- Neuropsychiatric abnormalities, such as depression, anxiety, cancer phobia, and other psychogenic problems
- Diabetes mellitus
- Mechanical trauma, such as an oral habit, chronic denture irritation, or sharp teeth
- Idiopathic causes, including idiopathic peripheral neuropathy

In some patients, more than one of these factors may be contributing to the problem of burning mouth syndrome. In many others, no specific cause can be identified. Other potential etiologic factors that might be explored are those related to dysgeusia (see Chapter 8), an occasional accompanying clinical feature of burning mouth syndrome.

The mechanism by which such a varied group of factors causes symptoms of burning mouth syndrome is completely enigmatic; more attention has recently been placed on a neuropathic alteration, although a psychological etiology or component cannot be ruled out in many cases. No common thread or underlying defect seems to tie these factors together. It is apparent that burning mouth syndrome occurs in a diverse group of patients, although many individuals will be suffering from depression or anxiety.

TABLE 4-5 ORAL-FACIAL PAIN CONDITIONS

Site	Cause	Character	Initiating Factors	Treatment
Burning Mouth Syndrome				
Mouth	Unknown, psychiatric factors, habits, fungi, blood dyscrasia, neuropathy	Burning: constant to increasing through the day	None	TCA, SSRI, local measures, psychotherapy
Trigeminal Neuralgia				
Face	Unknown, demyelination, aneurysm	Sharp, stabbing, shooting	Light touch	Carbamazepine, phenytoin, baclofen, surgery
Glossopharyngeal Neuralgia				
Throat, tonsil	Space-occupying lesion, unknown, demyelination, aneurysm	Sharp, stabbing, shooting	Swallowing, chewing	Surgery, carbamazepine, phenytoin, baclofen
Post-herpetic Neuralgia				
Face	Post varicella-zoster	Burning, constant dull pain	None	Gabapentin, TCA
Atypical Facial Pain				
Face	Unknown, psychiatric factors	Boring, constant ache	None	TCA, SSRI, psychotherapy
Atypical Odontalgia				
Tooth, alveolus	Unknown, psychiatric factors	Boring, constant ache	None	TCA, SSRI, psychotherapy

SSRI, Selective serotonin reuptake inhibitor; *TCA,* tricyclic antidepressant.

Clinical Features. This condition typically affects middle-aged women. Men are affected but generally at a later age than women. Burning mouth syndrome is rare in children and teenagers, very uncommon in young adults, and relatively common in adults older than 40 years of age.

Symptoms of pain and burning may be accompanied by altered taste and xerostomia. Occasionally a patient may attribute the start of the malady to recent dental work, such as placement of a new bridge or extraction of a tooth. Symptoms are often described as severe and ever present or, more typically, as worsening late in the day and evening. Any and all mucosal regions may be affected, although the tongue is by far the most commonly involved site (Table 4-5).

Highly characteristic of the complaint of an intensely burning mouth or tongue is a completely normal-appearing oral mucosa. Tissue is intact and has the same color as the surrounding tissue, with normal distribution of tongue papillae.

Some laboratory studies that may prove useful are cultures for *C. albicans,* serum tests for Sjögren's syndrome antibodies (SS-A, SS-B), a complete blood count, serum iron, total iron-binding capacity, and serum B_{12} and folic acid levels. Whether any or all of these tests should be performed is decided on an individual basis, depending on the clinical history and clinical suspicion.

Histopathology. Because no typical clinical lesion is associated with burning mouth syndrome, and because symptoms are more generalized than focal, a biopsy generally is not indicated. When an occasional arbitrary site in the area of the chief complaint is chosen for biopsy, tissue appears within normal limits in hematoxylin and eosin–stained sections. Special stains may reveal the presence of a few *C. albicans* hyphae.

Diagnosis. Diagnosis is based on a detailed history, a non-diagnostic clinical examination, laboratory studies, and exclusion of all other possible oral problems. Making the clinical diagnosis of burning mouth syndrome is generally not the difficult aspect of these cases. Rather, it is determining the subtle factor(s) that led to the symptoms that is the challenge.

Treatment. Treatment should initially involve patient reassurance of the common nature of burning mouth syndrome and the absence of any serious underlying problem, particularly oral cancer, because patients frequently have a significant level of phobia about cancer. The patient's history and examination should be reviewed along with results of hematologic and microbiological tests. If a nutritional deficit is the cause, replacement therapy is curative. If results of fungal cultures are positive, topical nystatin or clotrimazole therapy should produce satisfactory clinical results. If a patient wears a prosthetic device, its fit and tissue base should be carefully inspected. Relining or remaking the device may help eliminate chronic irritation or fungal overgrowth. If drug-induced xerostomia is involved, consultation with the patient's physician for an alternative drug may prove

beneficial. If occlusal problems are detected, an occlusal splint may be of some benefit.

Because most patients do not fall neatly into one of these categories in which an identified problem can be rectified, treatment becomes difficult. Hormonal changes, neurologic problems, and idiopathic disease are as difficult to identify as they are to treat. A sensitive, empathic approach should be used when treating patients with this problem. Clinicians should be supportive and offer an explanation of the various facets and frustrations of burning mouth syndrome. No great optimism or easy solution should be offered because patients ultimately may have to accept the disease and learn to live with the problem.

Other referrals may be useful, if only to exhaust all possibilities and reassure patients. The need for psychological counseling is often difficult to broach with these patients, but it may be necessary after all logical avenues of investigation have been explored.

Empirical treatment is often the approach most clinicians are forced to use for patients with burning mouth syndrome. Even though there may be no evidence of candidiasis, nystatin or clotrimazole may cause lessening of symptoms. Topical steroids, such as betamethasone (with or without antifungal agent), applied to the area of chief complaint may also be of some benefit. Generally, viscous lidocaine provides only temporary relief of pain, and saliva substitutes are of minimal value for patients suffering from associated (or stated) xerostomia.

Antidepressant therapy plays a major role in the management of burning mouth syndrome once other precipitating factors have been excluded. Some tricyclic antidepressants (TCAs) such as doxepin have anxiolytic, antidepressant, and muscle relaxant activity and have been found to be of great benefit for many patients with burning mouth syndrome. Unfortunately, xerostomia is a relatively frequent side effect of TCA therapy and may have to be discontinued. Alternatively, a selective serotonin reuptake inhibitor (SSRI), such as fluoxetine, fluvoxamine, or paroxetine, may be used. It has been suggested that SSRI preparations have fewer side effects than TCAs, in particular a less adverse effect on reaction time. Recent reports have suggested a role for daily low-dose benzodiazepines such as clonazepam. However, efficacy is uncertain because the drug has not been studied in these patients in double-blind clinical trials. The management of patients with burning mouth syndrome usually requires close coordination between the dental and the medical practitioners. For some patients, it may be necessary to seek care from a psychiatrist or a clinical psychologist.

Other Oral-Facial Pain Conditions

Trigeminal Neuralgia. Trigeminal neuralgia is a well-recognized condition characterized by sharp, stabbing pain along the distribution of the trigeminal nerve (fifth cranial nerve), with most cases demonstrating maxillary or second (V2) division distribution. The condition is precipitated by touching or surface stimulation over a small area of the skin or mucosa innervated by a branch of this cranial nerve (so-called trigger point), resulting in severe episodic or paroxysmal pain.

The cause of trigeminal neuralgia is not known, although several theories have been proposed but none entirely proven. One hypothesis proposes that the condition is due to demyelination of neurons along the distribution of the trigeminal nerve, particularly at the base of the skull. Other studies have implicated arteriovenous malformations in the cerebellopontine region or beneath the trigeminal ganglion. Rarely, an accompanying organic disease such as a neoplasm within the nasopharynx, maxillary antrum, middle ear, or base of skull in close relation to the trigeminal nerve may produce symptoms attributable to trigeminal neuralgia.

Trigeminal neuralgia primarily affects older individuals, typically in the sixth and seventh decades; women are slightly more often affected than men. The condition is rare in individuals younger than 40 years of age, and symptoms attributable to trigeminal neuralgia in this younger age group should raise suspicion of an underlying systemic disease, such as multiple sclerosis. The prevalence of trigeminal neuralgia in patients with multiple sclerosis is 1% to 4%.

The pain of trigeminal neuralgia is characteristically unilateral and limited to the anatomic pathway of one of the three main branches (V_1, ophthalmic; V_2, maxillary; or V_3, mandibular) of the trigeminal nerve. The right side of the face is more commonly affected than the left, with very few patients having a bilateral distribution. The pain is of short duration, lasting only a matter of seconds, and may be described by the patient as "lancinating," "shooting," "stabbing," or "electric shock–like." Sufferers may describe trigger spots on the skin or in the mouth, and others report that smiling, eating, or washing can bring on an attack. With untreated disease, the pain-free intervals between paroxysms diminish, and more frequent attacks occur. Clinical and radiographic examination fails to reveal any abnormality. Intraoral examination may be complicated or limited because of the patient's fear that movement or contact with facial tissues may precipitate an attack of pain. The presence of any other neurologic signs or symptoms, such as muscle weakness or altered nerve sensation, should lead to a full neurologic assessment.

The diagnosis of trigeminal neuralgia is based on clinical history and the nature of the symptoms. Although not practical in all clinical settings, computed tomography (CT) or magnetic resonance imaging (MRI) scans should be performed on any patient suspected of having trigeminal neuralgia to rule out organic disease, such as a space-occupying lesion at the base of the skull. Imaging or anatomic findings are absent in cases of trigeminal neuralgia.

Trigeminal neuralgia is initially managed using anticonvulsant drugs such as carbamazepine (Tegretol). The dose needs to be titrated and is usually effective in controlling the attacks. If this fails, other medicinal therapies include phenytoin, baclofen, sodium valproate, duloxetine, pregabalin,

or gabapentin. Sometimes combination therapy is needed. Pharmacologic therapy sometimes fails or loses its effectiveness; then surgical treatment may have to be considered. Peripheral techniques involving alcohol or glycerol rhizotomy at the level of the trigeminal ganglion are effective in some cases, although symptoms may return. Stereotactic gamma knife radiosurgery may also be a treatment consideration, although it is not as effective as microvascular decompression surgery (see later). Cryotherapy, surgical section, radiofrequency ablation, fractional rhizotomy, and thermocoagulation have also been prescribed with varying success. Unfortunately, surgical techniques produce permanent facial anesthesia and a risk of dysesthesia, which can be troublesome to the patient. Microvascular decompression (MVD) is a neurosurgical procedure involving displacement of aberrant blood vessels from immediate contact with the trigeminal nerve. MVD has achieved a high success rate, but the use of this technique should be considered on an individual basis based on significant risks of morbidity or mortality.

Glossopharyngeal Neuralgia. Classically, glossopharyngeal neuralgia produces a sharp lancinating pain along the distribution of the glossopharyngeal nerve. Symptoms are similar to those of trigeminal neuralgia, but in contrast, most cases of glossopharyngeal neuralgia are found to represent a neoplasm at the base of the tongue or in the oropharynx. Therefore a space-occupying lesion in these regions must be excluded by careful clinical examination and imaging studies.

Clinically, the pain of glossopharyngeal neuralgia is identical to that of trigeminal neuralgia, but in this condition, the severe shooting sensation is situated within the tonsillar region or oropharynx, often radiating to the ear. Symptoms are usually initiated by swallowing, chewing, or coughing. Diagnosis is based on clinical history and the nature of the symptoms. As with trigeminal neuralgia, the presence of organic disease—in particular, carcinoma of the oropharynx or nasopharynx or salivary gland neoplasm—should be excluded by appropriate examination of the area, supplemented with a CT scan or MRI. In addition to pain associated with glossopharyngeal neuralgia, this condition may be a cause of neurally mediated syncope, with a vasovagal reflex producing bradycardia, hypotension, and cardiac arrest.

If a space-occupying lesion has been excluded, medical management may be instituted. Carbamazepine is usually successful in controlling the pain, and additional pharmacologic agents are available. Resolution of symptoms following a trial course of carbamazepine in a suspected case can support the diagnosis. Surgical options may be considered in cases that are unresponsive to drug therapy.

Post-herpetic Neuralgia. Up to 10% of patients who have suffered recurrent varicella zoster infection of the trigeminal nerve (shingles, herpes zoster) subsequently develop a persistent neuralgia. Damage to neural tissue or persistence of virus within the trigeminal nerve ganglion has been implicated in this condition.

Symptoms occur along the dermatome previously affected by herpes zoster, with the ophthalmic division of the trigeminal nerve most commonly affected in the head and neck. The character of the pain can range from episodic severe shooting pain to a constant burning sensation. The affected area may show signs of postinflammatory pigmentation or scarring from the preceding herpes zoster infection. Pain may persist for many weeks to several months following clinical resolution of the infectious process. Diagnosis is made on the nature of the symptoms and a previous history of shingles.

Post-herpetic neuralgia is difficult to manage. Medications such as TCAs, desipramine, pregabalin, and gabapentin may be effective in controlling pain. Some reports have suggested treatment with topically applied capsaicin cream or lidocaine patch, opioids, and intrathecal methylprednisolone, but these therapies need to be validated. Surgical approaches produce no benefit. Transcutaneous electric nerve stimulation (TENS) has been found helpful in certain patients.

Giant Cell Arteritis (Temporal Arteritis). Giant cell arteritis is a multifocal granulomatous vasculitis that was previously called *temporal arteritis.* The latter term was replaced because the condition was found to affect vessels in the head or neck other than the temporal artery. If untreated, patients may develop retinal vasculitis with subsequent blindness.

Giant cell arteritis generally occurs in individuals over the age of 60 years and principally presents as unilateral headache-like pain in the temporal or occipital region; women are more frequently affected. It is one of the few causes of orofacial pain in which patients describe systemic upset, including weight loss, muscle weakness, and lethargy, although muscle biopsy, enzymology, and electromyography are normal. It may be associated with systemic muscular and joint pain termed *polymyalgia rheumatica.* The pain can be initiated by eating, and therefore the patient can eat for only short periods before resting to allow the pain to subside. This limitation of normal eating is thought to be ischemic in origin and has been misnamed *jaw claudication.*

Hematologic investigation shows a raised erythrocyte sedimentation rate (ESR) and often a raised unfractionated C-reactive protein. It has been proposed that temporal artery biopsy is of value in confirming the diagnosis, but granulomatous lesions occur sporadically along the vessel (skip lesions); therefore several biopsies or analysis of a length of artery may be required to detect them. More important, delay in obtaining the results of such a biopsy can be hazardous because of possible development of blindness.

Treatment consists of prednisone at a dose of 40 to 60 mg daily. After symptoms have been controlled, therapy can be reduced, although a low maintenance dose may be required for 3 to 6 months. The ESR is commonly used to monitor

disease activity and to guide therapy; this should fall to normal levels (generally <20 mm/h) following institution of steroid therapy.

Atypical Facial Pain. Atypical facial pain (AFP) is a chronic pain of unknown origin. Up to 50% of patients with AFP will be found to have an anxiety disorder or depression, although the nature of this relationship is unclear.

AFP predominantly affects women over the age of 30 years. This condition is a distinct clinical entity consisting of a constant unilateral boring or gnawing dull ache. The pain is chronic, being present every day from the time of waking until the patient goes to sleep. These symptoms do not awaken the patient from sleep, but because the condition is often associated with depression, a sleep disturbance such as early morning waking may be present. Although poorly localized, the pain most frequently affects one side of the maxilla. Crossing of anatomic boundaries is a frequent feature, for example, the pain may cross the midline of the maxilla or mandible. This finding may be helpful in achieving the diagnosis because most organic pain conditions do not cross anatomic boundaries. Clinical examination will fail to reveal any abnormality, but radiographs of the affected region must be taken to exclude dental or maxillary antral disease.

The diagnosis is made on the basis of clinical history and absence of any dental cause of the pain. A careful cranial nerve examination is required for all patients, supplemented with a CT scan or MRI to rule out organic disease or a space-occupying lesion in the base of the skull.

AFP responds well to low-dose antidepressive drug therapy such as a tricyclic antidepressant. Typically, a small dose is initiated and is gradually increased until the pain is controlled. In recent years, SSRIs have also been used in the management of this condition, but results have been mixed. Irrespective of which drug is chosen, carefully monitored therapy needs to be provided for at least 6 months.

Atypical Odontalgia. This condition is very closely related to AFP and is likely to have a similar psychological component. Many cases have a long and complicated history of failed dental treatment, although this relationship is poorly defined.

The complaint is of a constant dull ache, which is boring in nature. Symptoms are localized to one tooth or an edentulous area that is clinically and radiographically normal. Diagnosis is based on clinical history and absence of dental pathology. Similar to AFP, atypical odontalgia is managed with antidepressant therapy such as a TCA before sleep.

IMMUNOLOGIC ABNORMALITIES

Plasma Cell Gingivitis

Etiology. Plasma cell gingivitis was first given the name *plasma cell gingivostomatitis* because of the prominent plasma cell infiltrate in the tissues affected and because of its undetermined origin. This condition was subsequently named *allergic gingivostomatitis* because many cases were linked to chewing gum, which was believed to elicit an allergic reaction. When chewing gum was removed from the diet of affected patients, tissues reverted to normal in a matter of weeks. Although similar clinical lesions were noted in patients who did not chew gum, clinical and microscopic evidence still supports an allergic or hypersensitivity reaction. A possible explanation for the appearance of disease in non–gum chewers might be that the disease is a reaction to an ingredient in chewing gum such as mint or cinnamon flavoring that might also be found in other foods.

This peculiar condition is of historical interest because it was relatively prevalent at one time but is rarely encountered today. In the early 1970s, numerous cases, all nearly identical, were seen throughout the United States. Within a few years, the phenomenon all but disappeared. Clinicians speculated that chewing gum formulas or sources of offending ingredient(s) were changed, making the product nonallergenic.

Clinical Features. This condition affects adults and occasionally children of either gender. Burning mouth, tongue, or lips is the usual complaint of patients with plasma cell gingivitis. Onset is rather sudden, and discomfort may wax and wane. This condition should not be classified with burning mouth syndrome because distinctive clinical changes are present. The attached gingiva is fiery red and is often edematous-appearing but not ulcerated; the tongue mucosa is atrophic and red; and the commissures are reddened, cracked, and fissured (Figs. 4-30 and 4-31). Patients have no cervical lymphadenopathy and no systemic complaints.

Histopathology. The affected epithelium is spongiotic and is infiltrated by various types of inflammatory cells. Langerhans cells are also prominent, and apoptotic keratinocytes may occasionally be seen. The lamina propria displays



■ **FIGURE 4-30** Plasma cell gingivitis.



■ **FIGURE 4-31** A patient with plasma cell gingivitis showing angular cheilitis and fissured tongue.

prominent capillaries and is infiltrated by plasma cells of normal morphology.

Treatment. Most patients respond rather quickly to cessation of gum chewing or use of toothpastes containing cinnamic aldehyde–containing flavoring agents. Failing this, careful dietary history taking is indicated in an attempt to identify an allergic source.

Drug Reactions and Contact Allergies

Allergic reactions to drugs taken systemically or used topically often affect the skin but may also affect oral mucous membranes. A wide variety of agents are known to have this capacity, especially in patients who have a predisposition to the development of allergies.

The clinical appearance of allergic response in the skin ranges from red, erythematous lesions to an urticarial rash to a vesiculoulcerative eruption. The same types of changes may appear in the oral mucosa. In less intense and less destructive reactions, the mucosa exhibits a generalized and diffuse redness. When the tongue is the primary target, the pattern may be similar to the changes of vitamin B deficiency and anemia. (A detailed discussion on this subject can be found in Chapter 2.)

EXTRAVASCULAR LESIONS

Petechiae and Ecchymoses

Etiology. Soft tissue hemorrhages in the form of petechiae (pinpoint size) or ecchymoses (larger than pinpoint size) appear intraorally, generally as the result of trauma or blood disease (dyscrasia) (Box 4-3). Traumatic injury, if blood vessels are significantly damaged, can result in leakage of blood into surrounding connective tissue, producing red to purple lesions. The types of injury are many and, among other things, are related to cheek biting, persistent and forceful coughing, fellatio, trauma from prosthetic appliances, injudicious hygiene procedures, and iatrogenic dental injuries.

BOX 4-3 BLOOD DYSCRASIAS THAT MAY HAVE ORAL MANIFESTATIONS

Leukemia > monocytic > myelocytic > lymphocytic
Agranulocytosis
Cyclic neutropenia
Infectious mononucleosis
Thrombocytopenic purpura (ITP and TTP)
Hemophilia A and B
Macroglobulinemia
von Willebrand's disease
Multiple myeloma
Polycythemia vera
Sickle cell anemia
Thalassemia
Purpura*

*More commonly than ITP (idiopathic thrombocytopenic purpura) and TTP (thrombotic thrombocytopenic purpura).

BOX 4-4 BLOOD DYSCRASIAS: ORAL MANIFESTATIONS

Mucosal petechiae and ecchymoses—reduced platelets and/or clotting factors
Gingival enlargement
Leukemic infiltrates
Inflammation and hyperplasia (poor oral hygiene)
Excessive bleeding with minor trauma, gingivitis—reduced numbers of platelets and/or clotting factors
Refractory gingivitis
Leukemic infiltrates
Reduced numbers of platelets and/or clotting factors
Loose teeth—leukemic infiltrates in periodontal ligament
Mucosal ulcers—cyclic neutropenia; ulcer mechanism undetermined

In patients with blood dyscrasias, the presenting sign of minor trauma may also be oral red to purple petechiae or ecchymoses. Dental practitioners therefore can have a significant role in recognition of this abnormality. After ruling out a traumatic cause, clinicians should refer patients to an internist or hematologist.

All types of leukemia have the potential to produce one or more of the intraoral lesions listed in Box 4-4. In actual practice, monocytic leukemia is most often associated with oral manifestations, myelocytic leukemia (granulocyte series) is next, and lymphocytic leukemia (lymphocytes) is least likely to be associated with oral signs. Acute forms of the leukemias are more likely than chronic forms to be associated with oral lesions.

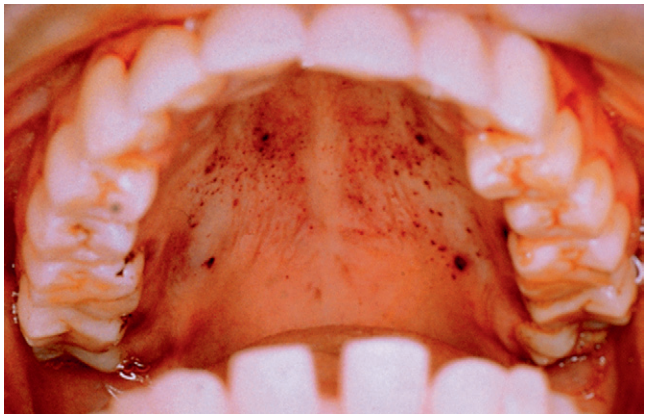

■ **FIGURE 4-32** Petechiae associated with idiopathic thrombocytopenic purpura.



■ **FIGURE 4-33** Ecchymosis at the junction of the hard and soft palate (trauma induced).

Platelet and coagulation defects make up another large group of blood dyscrasias that may be responsible for petechiae, ecchymoses, and other intraoral manifestations. Platelet problems may be qualitative or quantitative in nature. They may be of unknown origin (idiopathic thrombocytopenic purpura), or they may appear as a result of a wide variety of systemic factors, such as drug ingestion, infection, and immunologic disease. Hemophilia and related disorders in which clotting factors are deficient or defective are predominantly hereditary and are characteristically associated with prolonged bleeding and occasional ecchymoses.

Clinical Features. The color of these lesions varies from red to blue to purple, depending on the age of the lesion and the degree of degradation of the extravasated blood. Soft tissue hemorrhagic lesions usually appear in areas accessible to trauma, such as the buccal mucosa, lateral tongue surface, lips, and junction of the hard and soft palate (Figs. 4-32 and 4-33). In those injuries that are related to uncomplicated trauma, a cause-and-effect relationship can usually be established after a history has been taken.

Lesions that develop as a result of blood dyscrasias may follow trivial or otherwise insignificant trauma. In addition to petechiae and ecchymoses, other clinical oral signs of blood dyscrasias include gingival enlargement (especially with monocytic leukemia), gingivitis, "spontaneous" gingival hemorrhage, prolonged bleeding after oral surgery, loose teeth, and mucosal ulcers.

Diagnosis. Inability to otherwise explain the appearance of any of these clinical signs should cause clinicians to suspect one of the blood dyscrasias. Gingivitis that is refractory to standard therapy should be viewed as a potential dyscrasia. The concomitant presence of lymphadenopathy, weight loss, weakness, fever, joint pain, and headache should add to the suspicion of serious systemic disease. Clinicians in this situation should see that patients are evaluated by an internist or hematologist.

BIBLIOGRAPHY

Abetz LM, Savage NM: Burning mouth syndrome and psychological disorders. Aust Dent J 54:84–93, 2009.

Barozzi P, Bonini C, Potenza L et al: Changes in the immune responses against human herpesvirus-8 in the disease course of post-transplant Kaposi sarcoma. Transplantation 86:738–744, 2008.

Baselga E: Sturge-Weber syndrome. Semin Cutan Med Surg 23:87–98, 2004.

Bauland CG, van Steensel MA, Steijlen PM et al: The pathogenesis of hemangiomas: a review. Plast Reconstr Surg 117:29e–35e, 2006.

Bower M, Palmieri C, Dhillon T: AIDS-related malignancies: changing epidemiology and the impact of highly active antiretroviral therapy. Curr Opin Infect Dis 19:14–19, 2006.

Chang Y, Cesarman E, Pessin MS et al: Identification of herpesvirus-like DNA sequences in AIDS-associated Kaposi's sarcoma. Science 266:1865–1869, 1994.

Cohen MM: Vascular update: morphogenesis, tumors, malformations, and molecular dimensions. Am J Med Genet A 140(19): 2013–2038, 2006.

Comi AM: Pathophysiology of Sturge-Weber syndrome. J Child Neurol 18:509–516, 2003.

De Cillis E, Burdi N, Bortone AS et al: Endovascular treatment of pulmonary and cerebral arteriovenous malformations in patients affected by hereditary haemorrhagic telangiectasia. Curr Pharm Des 12:1243–1248, 2006.

Dictor M, Rambech E, Way D et al: Human herpesvirus 8 (Kaposi's sarcoma-associated herpesvirus) DNA in Kaposi's sarcoma lesions, AIDS Kaposi's sarcoma cell lines, endothelial Kaposi's sarcoma simulators, and the skin of immunosuppressed patients. Am J Pathol 148:2009–2016, 1996.

Dutree-Meulenberg R, Kozel M, van Jost T: Burning mouth syndrome: a possible role for local contact sensitivity. J Am Acad Dermatol 26:935–940, 1992.

Ensoli B, Gendelman R, Markham P et al: Synergy between basic fibroblast growth factor and HIV-1 tat protein in induction of Kaposi's sarcoma. Nature 371:674–680, 1994.

Epstein J, Scully C: HIV infection: clinical features and treatment of thirty-three homosexual men with Kaposi's sarcoma. Oral Surg Oral Med Oral Pathol 71:38–41, 1992.

Epstein JB, Cabay RJ, Glick M: Oral malignancies in HIV disease: changes in disease presentation, increasing understanding of molecular pathogenesis, and current management. Oral Surg Oral Med Oral Pathol Oral Radiol Endod 100:571–578, 2005.

Fernandez LA, Sanz-Rodriguez F, Blanco FJ et al: Hereditary hemorrhagic telangiectasia: a vascular dysplasia affecting the TGFβ signaling pathway. Clin Med Res 4:66–78, 2006.

Forbosco A, Criscuolo M, Coukos G: Efficacy of hormone replacement therapy in postmenopausal women with oral discomfort. Oral Surg Oral Med Oral Pathol 73:570–574, 1992.

Gallione CJ, Richards JA, Letteboer TG et al: SMAD4 mutations found in unselected HHT patients. J Med Genet 43:793–797, 2006.

Garzon MC, Huang JT, Enjolras O et al: Vascular malformations. Part II. Associated syndromes. J Am Acad Dermatol 56:541–564, 2007.

Gordon SC, Daley TD: Foreign body gingivitis: clinical and microscopic features of 61 cases. Oral Surg Oral Med Oral Pathol Oral Radiol Endod 83:562–570, 1997.

Gordon SC, Daley TD: Foreign body gingivitis: identification of foreign material by energy-dispersive x-ray microanalysis. Oral Surg Oral Med Oral Pathol Oral Radiol Endod 83:571–576, 1997.

Gorsky M, Silverman S, Chinn H: Clinical characteristics and management outcome in the burning mouth syndrome. Oral Surg Oral Med Oral Pathol 72:192–195, 1991.

Grand Maison A: Hereditary hemorrhagic telangiectasia. J Can Med Assoc 180:833–835, 2009.

Guttmacher AE, Marchuk DA, White RI: Hereditary hemorrhagic telangiectasia. N Engl J Med 333:918–924, 1995.

Horowitz M, Horowitz M, Ochs M et al: Trigeminal neuralgia and glossopharyngeal neuralgia: two orofacial pain syndromes encountered by dentists. J Am Dent Assoc 135:1427–1433, 2004.

Jafarzadeh H, Sanatkhani M, Mohtasham N: Oral pyogenic granuloma: a review. J Oral Sci 48:167–175, 2006.

Johari Y, Nicholson ML: Complete resolution of oral Kaposi's sarcoma achieved by changing immunosuppression: a case report. Ann R Coll Surg Engl 92:1–2, 2010.

Karlis V, Glickman RS, Stern R et al: Hereditary angioedema. Oral Surg Oral Med Oral Pathol Oral Radiol Endod 83:462–464, 1997.

Koehler JE, Glaser CA, Tappero JW: Rochalimaea henselae infection: a zoonosis with the domestic cat as reservoir. JAMA 271:531–535, 1994.

Koehler JE, Quinn FD, Berger TG et al: Isolation of Rochalimaea species from cutaneous and osseous lesions of bacillary angiomatosis. N Engl J Med 327:1625–1631, 1992.

Lamey PJ, Freeman R, Eddie SA et al: Vulnerability and presenting symptoms in burning mouth syndrome. Oral Surg Oral Med Oral Pathol Oral Radiol Endod 99:48–54, 2005.

Lamy S, Lachambre M-P, Lord-Dufour S et al: Propranolol suppresses angiogenesis in vitro: inhibition of proliferation, migration, and differentiation of endothelial cells. Vascul Pharmacol 53:200–208, 2010.

Lenato GM, Guanti G: Hereditary haemorrhagic telangiectasia (HUT): genetic and molecular aspects. Curr Pharm Des 12:1173–1193, 2006.

Maragon P, Ivanyi L: Serum zinc levels in patients with burning mouth syndrome. Oral Surg Oral Med Oral Pathol 71:447–450, 1991.

Martinez V, Caumes E, Gambotti L et al: Remission from Kaposi's sarcoma on HAART is associated with suppression of HIV replication and is independent of protease inhibitor therapy. Br J Cancer 94:1000–1006, 2006.

Miles SA: Pathogenesis of AIDS-related Kaposi's sarcoma: evidence of a viral etiology. Hematol Oncol Clin North Am 10:1011–1021, 1996.

Mock D, Chugh D: Burning mouth syndrome. Int J Oral Sci 2:1–4, 2010.

Morris CB, Gendelman R, Marrogi AJ et al: Immunohistochemical detection of Bcl-2 in AIDS-associated and classical Kaposi's sarcoma. Am J Pathol 148:1055–1063, 1996.

Nathan N, Thaller SR: Sturge-Weber syndrome and associated congenital vascular disorders. J Craniofac Surg 17:724–728, 2006.

Papagatsia Z, Jones J, Morgan P et al: Oral Kaposi sarcoma: a case of immune reconstitution inflammatory syndrome. Oral Surg Oral Med Oral Pathol Oral Radiol Endod 108:70–75, 2009.

Pontes HAR, Neto NC, Ferreira KB et al: Oral manifestations of vitamin B-12 deficiency: a case report. J Can Dent Assoc 75:533–537, 2009.

Porter SR, Di Alberti L, Kumar N: Human herpes virus 8 (Kaposi's sarcoma herpesvirus). Oral Oncol 34:5–14, 1998.

Qu Z, Liebler JM, Powers MR et al: Mast cells are a major source of basic fibroblast growth factor in chronic inflammation and cutaneous hemangioma. Am J Pathol 147:564–573, 1995.

Reichart PA, Philipsen HP: Oral erythroplakia—a review. Oral Oncol 41:551–561, 2005.

Schmid H, Zietz C: Human herpesvirus 8 and angiosarcoma: analysis of 40 cases and review of the literature. Pathology 37:284–287, 2005.

Shovlin CL: Molecular defects in rare bleeding disorders: hereditary hemorrhagic telangiectasia. Thromb Haemost 78:145–160, 1997.

Sidbury R: Update on vascular tumors of infancy. Curr Opin Pediatr 22:432–437, 2010.

Tourne LPM, Fricton JR: Burning mouth syndrome: critical review and proposed management. Oral Surg Oral Med Oral Pathol 74:158–167, 1992.

Tucci FM, De Vincentis GC, Sitzia E et al: Head and neck vascular anomalies in children. Int J Pediatr Otorhinolaryngol 73(Suppl 1):S71–S76, 2009.

van Doesburg MH, Breugem CC, Breur JM et al: Segmental facial hemangiomas and associated structural defects. J Craniofac Surg 29:1224–1227, 2009.

Viejo-Borbolla A, Ottinger M, Schulz IF: Human herpesvirus 8: biology and role in the pathogenesis of Kaposi's sarcoma and other AIDS-related malignancies. Curr HIV/AIDS Rep 1:5–11, 2004.

Zakrzewska JM: Medical management of trigeminal neuropathic pains. Expert Opin Pharmacother 11:1239–1254, 2010.

Zarrabeitia R, Albinana V, Salcedo M et al: A review on clinical management and pharmacologic therapy on hereditary hemorrhagic telangiectasia (HHT). Curr Vasc Pharmacol 8:473–481, 2010.

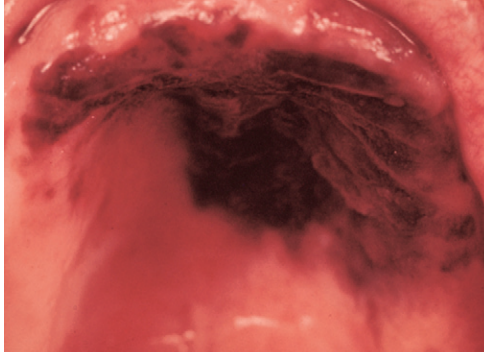

CHAPTER 5

Pigmented Lesions

MELANOCYTIC LESIONS

Physiologic (Ethnic) Pigmentation
Smoking-Associated Melanosis
Oral Melanotic Macule
Café-au-Lait Macules
Pigmented Neuroectodermal Tumor of Infancy
Melanocytic Nevus
Melanoacanthoma
Melanoma

NONMELANOCYTIC LESIONS

Amalgam Tattoo (Focal Argyrosis)
Drug-Induced Pigmentations
Heavy-Metal Pigmentations

Pigmented oral mucosal lesions can be divided into two fundamental groups: those containing melanin and those containing other pigments. The latter would include discolorations associated with drug ingestion, metal implantation, and heavy-metal ingestion/intoxication. Breakdown products from extravascular blood due to trauma or blood dyscrasias (see Chapter 4) can also discolor oral mucosa. Pigmented lesions, which range from trivial to serious (melanoma), can be confused with each other clinically, necessitating careful evaluation.

MELANOCYTIC LESIONS

Melanin-producing cells (melanocytes) have their embryologic origin in the neural crest. These cells migrate to epithelial surfaces and reside among basal cells. They have numerous dendritic processes that extend to adjacent keratinocytes. Organelles representing packaged granules of pigment known as *melanosomes* are produced by these melanocytes. These melanosomes are not ordinarily retained within the melanocyte itself but, rather, are delivered to surrounding keratinocytes and occasionally to subjacent macrophages. Light, hormones, and genetic constitution influence the amount of pigment produced.

Melanocytes are found throughout the oral mucosa but go unnoticed because of their relatively low level of pigment production (Fig. 5-1). They appear clear with nonstaining cytoplasm on routine histologic preparation. When focally or generally active in pigment production or proliferation, they may be responsible for several different entities in the oral mucous membranes, ranging from physiologic pigmentation to malignant neoplasia.

A relative of the melanocyte, the nevus cell, is responsible for pigmented nevi. Nevus cells, although morphologically different from melanocytes, possess the same enzyme, tyrosinase, which is responsible for conversion of tyrosine to melanin in the melanosome organelle.

Oral melanin-based pigmentations range from brown to black to blue, depending on the amount of melanin produced and the depth of the pigment relative to the surface.

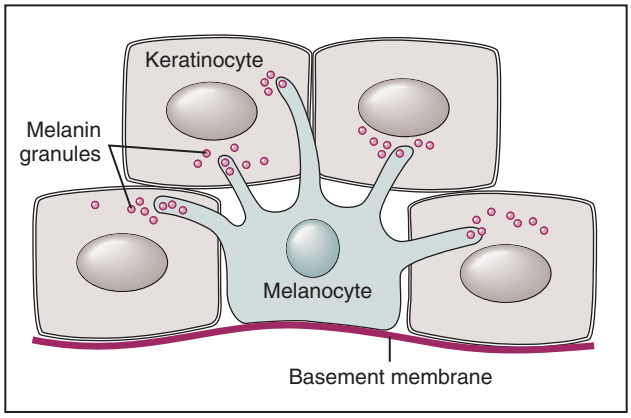

■ **FIGURE 5-1 Melanocyte-keratinocyte unit.** Note dendritic processes of melanocyte and melanin transfer to keratinocytes.

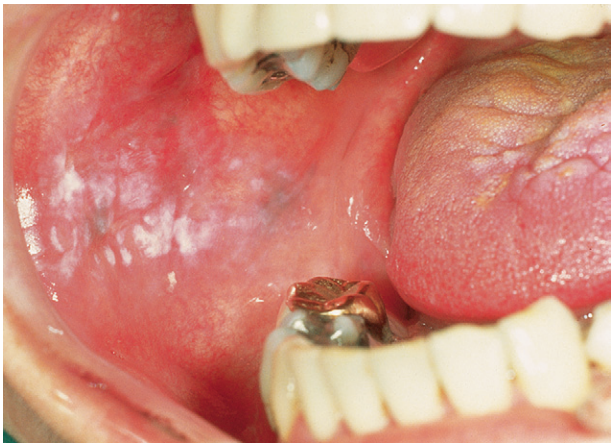

■ **FIGURE 5-3** Postinflammatory pigmentation.



■ **FIGURE 5-2** Physiologic (ethnic) pigmentation.

Generally, superficial pigmentation is brown, whereas more deeply located pigmentation is black to blue. Darkening of a preexisting lesion that has not been stimulated by known factors suggests that pigment cells are producing more melanin and/or invading deeper tissue.

Physiologic (Ethnic) Pigmentation

Clinical Features. Physiologic pigmentation is symmetric and persistent and does not alter normal architecture, such as gingival stippling (Fig. 5-2). This pigmentation may be seen in persons of any age and is without gender predilection. Often the degree of intraoral pigmentation may not correspond to the degree of cutaneous coloration. Physiologic pigmentation may be found in any location, although the gingiva is the most commonly affected intraoral tissue. A related type of pigmentation, called *postinflammatory pigmentation,* is occasionally seen after mucosal reaction to injury (Fig. 5-3). Occasionally in cases of lichen planus, areas surrounding active disease may eventually show mucosal or postinflammatory pigmentation.

Histopathology. Physiologic pigmentation is not due to increased numbers of melanocytes, but rather to increased melanin production. Melanin is found within surrounding basal keratinocytes and subjacent connective tissue macrophages (melanophages).

Differential Diagnosis. A clinical differential diagnosis would include smoking-associated melanosis, Peutz-Jeghers syndrome, Addison's disease, and melanoma. Although physiologic pigmentation is usually clinically diagnostic, a biopsy may be justified if clinical features are atypical.

Smoking-Associated Melanosis

Etiology and Pathogenesis. Abnormal melanin pigmentation of oral mucosa has been linked to cigarette smoking and has been designated *smoking-associated melanosis* or *smoker's melanosis.* The pathogenesis is believed to be related to a component in tobacco smoke that stimulates melanocytes. Female sex hormones are believed to be modifiers in this type of pigmentation because women (especially those taking birth control pills) are more commonly affected than men. Smoking up to nine cigarettes per day has been sufficient to produce gingival melanin deposition.

Clinical Features. The anterior labial gingiva is the region most typically affected, where brownish color can vary from subtle to obvious. Palate and buccal mucosal pigmentation has been associated with pipe smoking. In India, the use of smokeless tobacco forms has been linked to oral melanosis, particularly among alcoholics. In smoking-associated melanosis, the intensity of pigmentation is time and dose related (Fig. 5-4).

Histopathology. Melanocytes show increased melanin production, as evidenced by pigmentation of adjacent basal keratinocytes. The microscopic appearance is essentially



■ **FIGURE 5-4** Smoking-associated melanosis.



■ **FIGURE 5-5** Melanotic macule.



■ **FIGURE 5-6** Melanotic macules.

BOX 5-1 MELANOTIC MACULE

Common oral pigmentation
Idiopathic (ephelis)
Postinflammatory
Syndrome associated (Peutz-Jeghers, Addison's disease, Laugier-Hunziker, Bandler syndrome)
Early melanoma may have similar appearance.
Melanin seen in basal keratinocytes
Medication related (e.g., antimalarials [melanin complexed with ferric iron], others)

BOX 5-2 SYSTEMIC CONDITIONS ASSOCIATED WITH ORAL MELANOTIC MACULES

Peutz-Jeghers syndrome
  Intestinal polyposis (hamartomas)
  Autosomal-dominant inheritance
Addison's disease
  Macules and diffuse bronzing
  Adrenal cortical insufficiency—weakness, hypotension, nausea, weight loss
Laugier-Hunziker syndrome
  Oral, subungual, and skin macules
Bandler syndrome
  Small intestine hemangiomas and mucocutaneous macules

similar to that seen in physiologic pigmentation and melanotic macules.

Differential Diagnosis. Other entities to consider before a definitive diagnosis is established are physiologic pigmentation, diffuse melanoacanthoma, Peutz-Jeghers syndrome, Addison's disease, and other systemic drugs (Box 5-1) and melanoma.

Treatment. With cessation of smoking, improvement is expected over the course of months to a few years. Smoker's melanosis, per se, appears to be of little significance. However, it may potentially mask other lesions or may be cosmetically objectionable. In cases where surface irregularity or focally intense pigment deposits are noted, biopsy should be performed.

Oral Melanotic Macule

Clinical Features. Oral melanotic macule (or focal melanosis) is a focal pigmented lesion that may represent (1) an intraoral freckle; (2) postinflammatory pigmentation; or (3) macules associated with Peutz-Jeghers syndrome, Bandler syndrome, or Addison's disease (see Box 5-1).

Melanotic macules have been described as occurring predominantly on the vermilion of the lips and gingiva, although they may appear on any mucosal surface. They are asymptomatic and have no malignant potential.

When melanotic macules (freckles) are seen in excess in an oral and perioral distribution, *Peutz-Jeghers syndrome* and *Addison's disease* should be considered (Box 5-2; Figs. 5-5 to 5-8). Peutz-Jeghers syndrome is a condition that is inherited



■ **FIGURE 5-7** Perioral melanotic macules of Peutz-Jeghers syndrome.

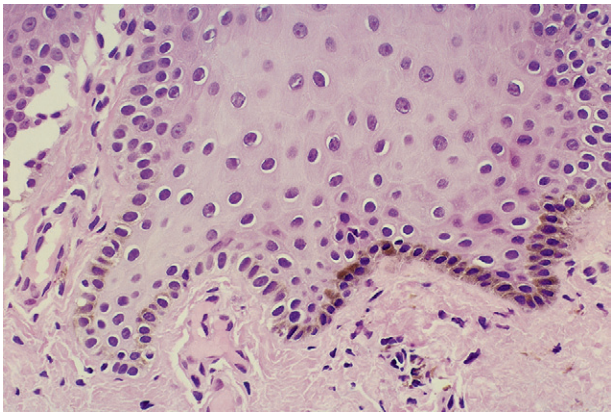

■ **FIGURE 5-9** Melanotic macule showing melanin in basal keratinocytes.



■ **FIGURE 5-8 Addison's disease. A** and **B,** Melanotic macules.

in an autosomal-dominant pattern. In addition to ephelides or melanotic macules, intestinal polyposis is present. These polyps are regarded as hamartomas without, or with very limited, neoplastic potential. They usually are found in the small intestine (jejunum) and may produce signs and symptoms of abdominal pain, rectal bleeding, and diarrhea.

Addison's disease, or primary adrenocortical insufficiency, may result from adrenal gland infection (tuberculosis), autoimmune disease, or idiopathic causes. With reduced cortisol production by the adrenals, pituitary adrenocorticotropic hormone (ACTH) and melanocyte-stimulating hormone (MSH) increase as part of a negative feedback mechanism. Overproduction of both ACTH and MSH results in stimulation of melanocytes, leading to diffuse pigmentation of the skin. Oral freckles and larger melanotic macules occur with generalized pigmentation. Other presenting signs and symptoms of this syndrome include weakness, weight loss, nausea, vomiting, and hypotension.

Pigmented macules have been described in association with two other rare syndromes. One includes soft tissue myxomas and endocrinopathies *(myxoma syndrome)*. Oral, cutaneous, and cardiac myxomas may be seen in this autosomal-dominant syndrome. The other, known as *Laugier-Hunziker syndrome* or *phenomenon,* is a rare acquired pigmentary disorder that presents as lip, oral, or finger macules and subungual melanocytic streaks. Pigmentation of the conjunctiva and penis has been described in patients with this syndrome.

A rare condition, *Bandler syndrome,* may feature melanotic macules of the oral mucosa and perioral region. This syndrome includes hemangiomas of the small intestine plus mucocutaneous pigmentation.

A melanotic macule that occurs exclusively on sun-damaged skin (especially the face and hands) is known as lentigo (plural, lentigines). These lesions are characteristically seen in older patients and appear as brown patches that are larger and darker than ephelides. The lesions are benign but may be cosmetically objectionable, in which case they may be treated with cryotherapy or laser vaporization.

Histopathology. Microscopically, melanotic macules are characterized by melanin accumulation in basal keratinocytes and normal numbers of melanocytes (Fig. 5-9). Melanophagocytosis is typically seen within the lamina propria.

Differential Diagnosis. These oral pigmentations must be differentiated from early superficial melanomas. They may be confused with blue nevi (palate) or amalgam tattoos.

BOX 5-3 DIFFERENTIAL DIAGNOSIS: PIGMENTED MACULE

Physiologic (ethnic) pigmentation
Melanotic macule
Smoking-associated melanosis
Syndrome-associated pigmentation
Peutz-Jeghers syndrome
Bandler syndrome
Addison's disease
Laugier-Hunziker phenomenon
Nevomelanocytic nevus
Melanoma
Amalgam tattoo
Drug-induced pigmentation

BOX 5-4 ORAL LESIONS ASSOCIATED WITH CUTANEOUS PIGMENTED MACULES

Neurofibromatosis
Neurofibromas of skin, oral mucosa, jaws
Café-au-lait macules of skin
McCune-Albright syndrome
Polyostotic fibrous dysplasia, including jaws
Endocrine abnormalities (e.g., precocious puberty)

If they are numerous, Peutz-Jeghers syndrome, Addison's disease, Bandler syndrome, and Laugier-Hunziker syndrome may be possible clinical considerations (Box 5-3).

Treatment. A biopsy may be required to establish a definitive diagnosis of this lesion. Otherwise, no treatment is indicated.

Café-au-Lait Macules

Café-au-lait macules are discrete melanin-pigmented patches of skin that have irregular margins and a uniform brown coloration. They are noted at birth or soon thereafter and may also be seen in normal children. No treatment is required, but they may be indicative of a syndrome of greater significance (Box 5-4).

Individuals with six or more large café-au-lait macules (>0.5 cm diameter prepubertal, >1.5 cm diameter postpubertal) should be suspected of having neurofibromatosis (NF) (Fig. 5-10). Two forms of this autosomal-dominant disorder affect 100,000 people in the United States: neurofibromatosis 1 (NF1; previously called *von Recklinghausen's disease*) and neurofibromatosis 2 (NF2; formerly known as *acoustic neurofibromatosis*). Although some overlapping features are known, the two conditions are distinct clinically and genetically. NF1 is a relatively common disorder affecting 1 in 3000 individuals. Approximately 50% of cases are inherited, and the remainder represent spontaneous new mutations. The condition is characterized by numerous neurofibromas of the skin, oral mucosa, nerves, and central nervous system, and occasionally the jaw. Axillary freckling (Crowe's sign) accompanied by the presence of six or more of these macules is regarded as pathognomonic for NF1. The genetic abnormality involves the neurofibromin gene located on chromosome 17q11.2. This tumor suppressor gene encodes for neurofibromin protein, which downregulates the function of the $p21^{ras}$ protein. NF2 is characterized by bilateral acoustic neuromas, one or more plexiform neurofibromas, and Lisch nodules. The condition is caused by a mutation in the *NF2* tumor suppressor gene located on chromosome 22q12 that encodes for the merlin protein, which, in turn, shows structural similarity to a series of cytoskeletal proteins. The normal function of merlin is not known.



■ **FIGURE 5-10** Café-au-lait macule *(top left)* and axillary freckling in patient with neurofibromatosis.

Café-au-lait macules may be associated with Albright's syndrome (polyostotic fibrous dysplasia, endocrine dysfunction, precocious puberty, café-au-lait macules), Noonan syndrome, Watson syndrome, Bloom syndrome, ring chromosome syndromes, and others. This sporadic disorder is considered to be strongly associated with mutation of the Gsα gene. Variants have been associated with primary biliary cirrhosis and alopecia. The café-au-lait macules of Albright's syndrome tend to be large and unilateral and have irregular borders.

Microscopically, café-au-lait macules are not particularly remarkable. They generally show excess amounts of melanin in basal keratinocytes and subjacent macrophages. Melanocytes are normal in appearance and may be slightly increased in number.

Pigmented Neuroectodermal Tumor of Infancy

Etiology. Pigmented neuroectodermal tumor of infancy is a rare, benign but fast-growing neoplasm that is composed of relatively primitive pigment-producing cells. Similar to

melanocytes and nevus cells, these cells have their origin in the neural crest.

Clinical Features. This lesion has been reported in infants usually younger than 6 months of age, and on occasion in older children. It occurs typically in the maxilla, although the mandible, epididymis, brain, and skull have been involved (Fig. 5-11). This lesion usually presents as a nonulcerated and occasionally darkly pigmented mass. The latter feature is due to melanin production by tumor cells. Radiographs show an ill-defined lucency that may contain developing teeth.



■ **FIGURE 5-11** Pigmented neuroectodermal tumor of infancy as a radiolucency in the anterior maxilla.

Histopathology. This neoplasm exhibits an alveolar pattern (i.e., nests of tumor cells with small amounts of intervening connective tissue) (Fig. 5-12). Variably sized nests of round to oval cells are found within a well-defined connective tissue margin. Cells located centrally within the neoplastic nests are dense and compact, resembling neuroendocrine cells; peripheral cells are larger and often contain melanin.

Differential Diagnosis. Few other lesions are reported in this age group and in this characteristic location. Malignancies of early childhood, such as neuroblastoma, rhabdomyosarcoma, and "histiocytic" tumors, might be considered. Odontogenic cysts and tumors would not be seriously considered in a differential diagnosis.

Treatment and Prognosis. This lesion has been treated with wide local surgical excision with good results. A few cases of local recurrence have been recorded; thus close clinical follow-up after excision is recommended. Recurrence may occur in between 10% and 20% of cases. Malignant transformation characterized by metastasis is very rare but has been documented following local excision.

Melanocytic Nevus

Etiology. *Nevus* is a general term that may refer to any congenital lesion of various cell types or tissue types. Generally, however, nevus (or mole) used without a modifier refers to a pigmented lesion composed of nevus or melanocytic cells. It is sometimes called, more specifically, *melanocytic nevus, nevocellular nevus, melanocytic nevus,* or *pigmented nevus.*

Melanocytic nevi are collections of nevus cells that are round or polygonal and are typically seen in a nested pattern (Fig. 5-13). They may be found in epithelium or supporting connective tissue, or both. Nevus cells have been postulated to originate from cells that migrate from the neural crest to the epithelium and dermis (submucosa), or to result from altered resident melanocytes.

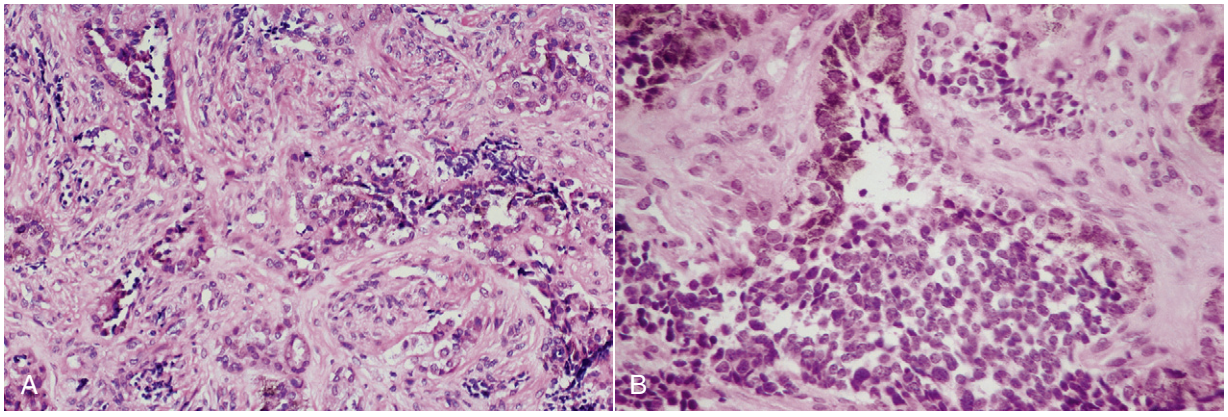

■ **FIGURE 5-12 Pigmented neuroectodermal tumor of infancy. A** and **B,** Nests of round cells with peripheral pigmented cells.

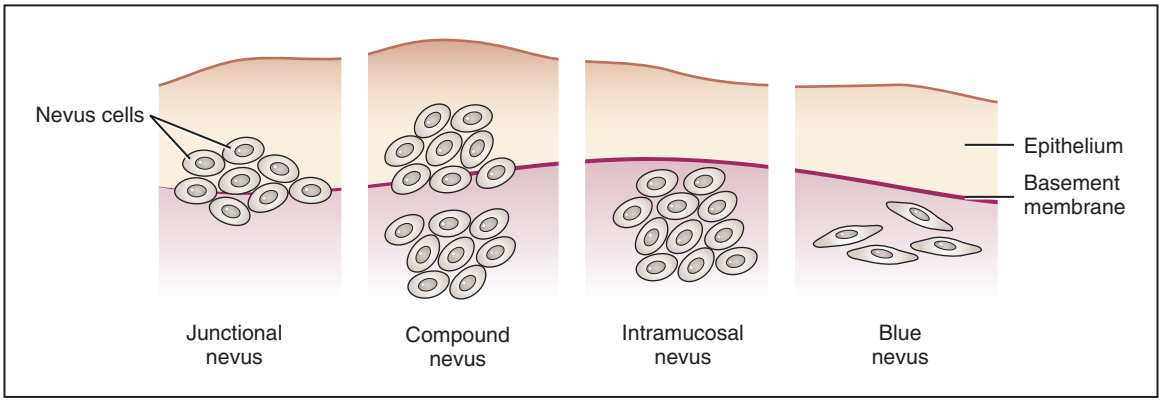

■ **FIGURE 5-13** Melanocytic nevus subtypes.

BOX 5-5 MUCOSAL MELANOCYTIC NEVUS

Palate is most common site.
Must differentiate from melanoma (biopsy)
Types (in order of frequency):
- Intramucosal nevus
- Blue nevus
- Compound nevus
- Junctional nevus

Probably has no malignant potential



■ **FIGURE 5-14** Intramucosal nevus.

Clinical Features. Melanocytic nevi of the skin are common acquired papular lesions that usually appear shortly after birth and throughout childhood. Intraoral melanocytic nevi are relatively rare lesions that may occur at any age. Most oral lesions present as small (<0.5 cm) elevated papules or nodules that are often nonpigmented (20%). The palate is the most commonly affected site. Less common sites are the buccal mucosa, labial mucosa, gingiva, alveolar ridge, and vermilion (Box 5-5; Figs. 5-14 and 5-15).

Histopathology. Microscopically, several subtypes are recognized (Figs. 5-16 and 5-17). Classification is dependent on the location of nevus cells. When cells are located in the epithelium–connective tissue junction, the lesion is called a *junctional nevus;* when cells are located in connective tissue, the lesion is called an *intradermal nevus* or *intramucosal nevus;* and when cells are located in a combination of these zones, the lesion is called a *compound nevus.* A fourth type of nevus, in which cells are spindle shaped and are found deep in the connective tissue, is known as *blue nevus.* Malignant transformation of an oral benign melanocytic nevus is highly improbable. Various observations support this statement, including (1) malignant features are never seen in oral nevi, (2) oral melanomas rarely, if ever, contain preexisting nevi histologically, and (3) almost no cases of the malignant counterpart of the relatively common oral blue nevus have

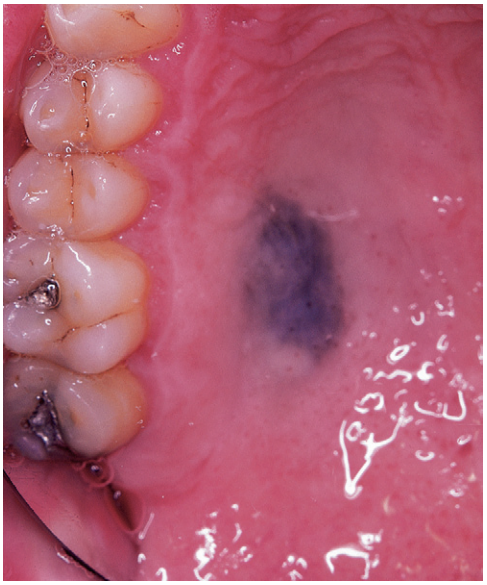

■ **FIGURE 5-15** Blue nevus.

been reported. Because oral melanocytic nevi can mimic melanoma clinically, all undiagnosed pigmented lesions should undergo a biopsy.

In the oral cavity, intramucosal nevi are the most commonly seen variety, and blue nevi are the second most common. Compound and junctional nevi occur relatively rarely in the oral mucosa. The so-called dysplastic nevus that is commonly seen in skin has not been observed in oral mucous membranes.

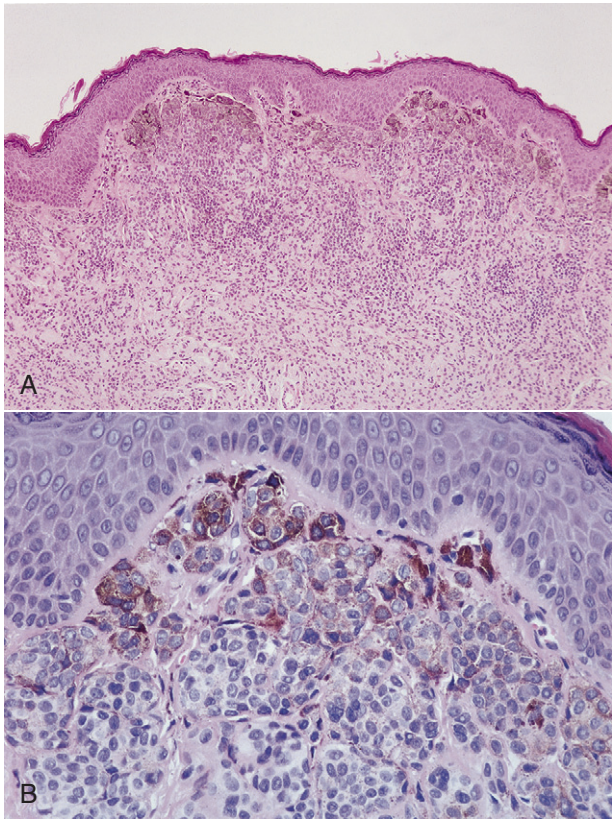

■ **FIGURE 5-16 Intramucosal nevus. A** and **B,** Confluent nests of pigmented nevus cells in submucosa.

Differential Diagnosis. Other clinical considerations that should be included with any type of oral melanocytic nevus are melanotic macule, amalgam tattoo, and melanoma. Palatal lesions may offer a challenge in terms of a clinical diagnosis, as both pigmented nevi and mucosal melanoma most commonly are noted at this site. Lesions of vascular origin might also be considered. These include hematoma, Kaposi's sarcoma, varix, and hemangioma. Diascopy (compression under glass) could be used to rule out the last two lesions, in which the blood is contained within a well-defined vascular system.

Treatment. Because of the infrequency with which oral nevi occur, and because of their ability to clinically mimic melanoma, all suspected oral nevi should be excised. Because they generally measure less than 1 cm, excisional biopsy is usually indicated.

Melanoacanthoma

Oral melanoacanthoma is an uncommon benign pigmented lesion with proliferation of dendritic melanocytes within an acanthotic epithelium with hyperkeratotic surface features. Typically, these hyperpigmented lesions are macular to minimally elevated with a tendency for rapid growth, thus raising concern over the possibility of a malignant process. Lesions are typically focal and are generally found in the buccal mucosa, where occlusal trauma may have an etiologic role. Lesions may disappear spontaneously or subsequent to incisional biopsy. Malignant transformation has not been reported.

Melanoma

Cutaneous Melanoma. Melanomas of the skin have been increasing in frequency during the past several years and now represent approximately 2% of all cancers (excluding carcinomas of the skin). Overall, the cancer-related death rate caused by melanoma of the skin is about 1% to 2%. Cutaneous melanoma is more common in locations closer

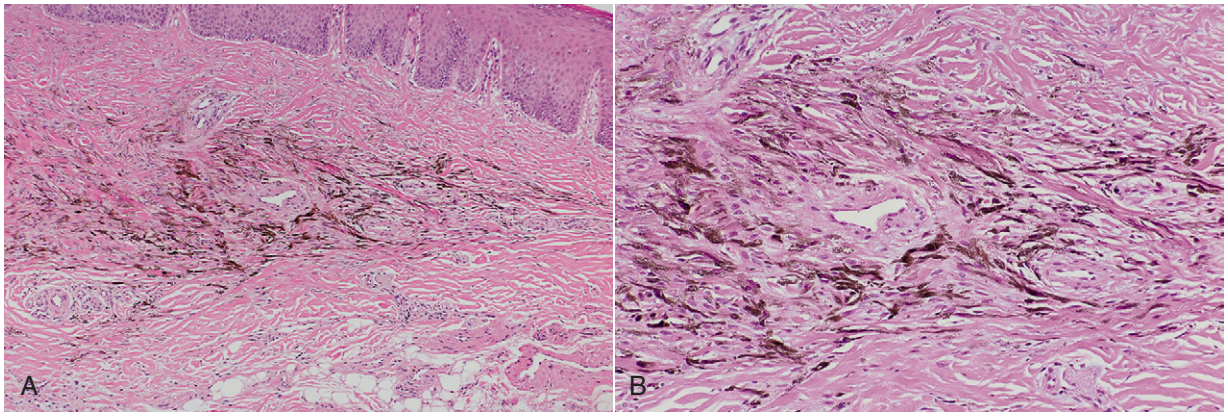

■ **FIGURE 5-17 Blue nevus. A** and **B,** Collection of pigmented spindled nevus cells in submucosa.

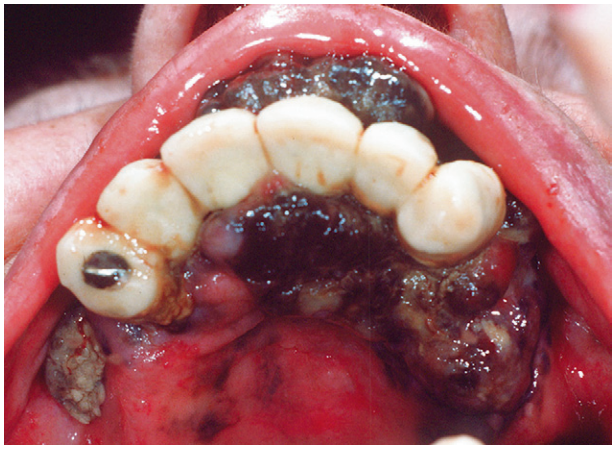

■ **FIGURE 5-18** Advanced invasive melanoma of the palate and gingiva.



■ **FIGURE 5-19** In situ melanoma of 8 years' duration.

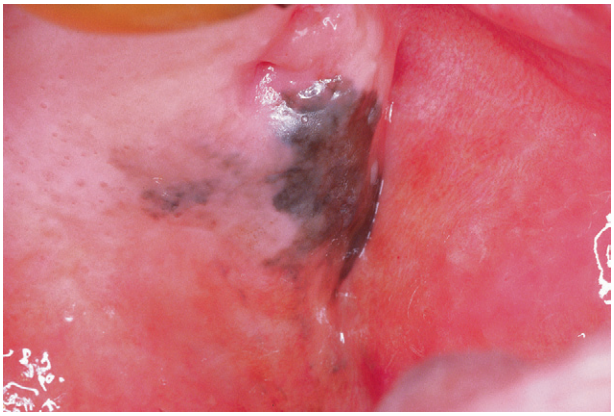

■ **FIGURE 5-20** In situ melanoma showing lateral spread.

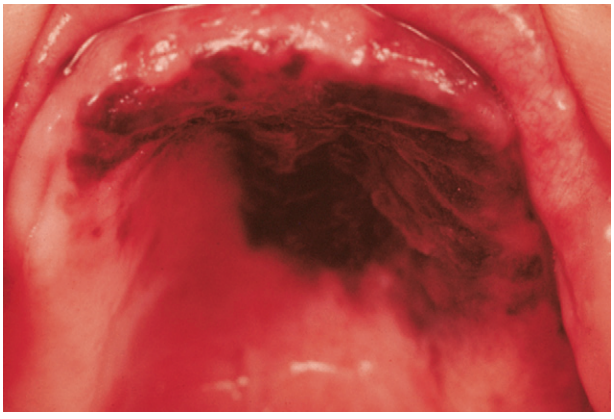

■ **FIGURE 5-21** Invasive melanoma with a several-year history of preceding lateral spread.

to the equator, where ultraviolet (UV) exposure is greater, and it is much more common in whites than in blacks and Asians. Predisposing factors for skin lesions include extensive sun exposure, particularly in childhood, fair natural pigmentation, and precursor lesions, such as congenital melanocytic nevi and dysplastic nevi.

On the skin are several melanoma subtypes, including nodular melanoma, superficial spreading melanoma, acral lentiginous melanoma, and lentigo maligna melanoma, each having distinctive microscopic, clinical, and behavioral features. Differences in clinical progression and histology are related, in large part, to recognition that all melanomas have two distinct phases of variable duration: (1) a radial or horizontal growth phase, during which malignant melanocytes spread laterally along the epidermal-dermal interface, and (2) a vertical growth phase, characterized by penetration of the dermis and subcutaneous tissues by malignant melanocytes. In nodular melanoma, the radial growth phase is generally very short compared with a longer radial growth phase in other forms of melanoma.

Oral Melanoma. Melanomas of oral mucosa are fortunately rare. No racial predilection has been noted. However, blacks and Asians compared with whites appear to be proportionately more commonly affected by this neoplasm in the oral mucosa.

Intraorally, preexisting melanosis was reported to appear before the development of some melanomas. This pigmentary defect, however, very likely represents an early radial growth phase of these lesions, and not benign melanosis. Two biological subtypes of oral melanoma have been identified: *invasive melanoma* and *in situ melanoma* (Figs. 5-18 to 5-24). The former type of oral melanoma shows an invasive or vertical growth pattern without significant lateral spread. The latter type features a junctional growth phase that may last months to years before entering a vertical growth phase. A third term, *atypical melanocytic proliferation,* has been used in relation to oral pigmentations that are microscopically difficult to categorize. This designation indicates the presence of unusual numbers of melanocytes with abnormal morphology at the epithelium–connective tissue interface. The changes are not severe enough to justify the diagnosis of melanoma. Lesions designated as *atypical melanocytic proliferation* should be regarded as high-risk lesions, followed carefully and rebiopsied as clinically indicated, or followed indefinitely.

Melanomas of oral mucosa are much less common than their cutaneous counterparts (Box 5-6). Of mucosal melanomas of the head and neck, oral melanoma accounts for approximately 40%. These lesions are found in adults; children are rarely affected. Oral melanomas tend to occur at a younger age than their more common sinonasal counterparts, with most cases noted in those younger than 40 years. They have a strong predilection for the palate and gingiva, where collectively, more than 70% of cases are found. Average time to arrival at a diagnosis is 9 months, in part because a third of oral melanomas are amelanotic in nature. Pigmentation patterns that suggest melanoma include different mixtures of color (such as brown, black, blue, and red), asymmetry, surface heterogeneity, and irregular margins.

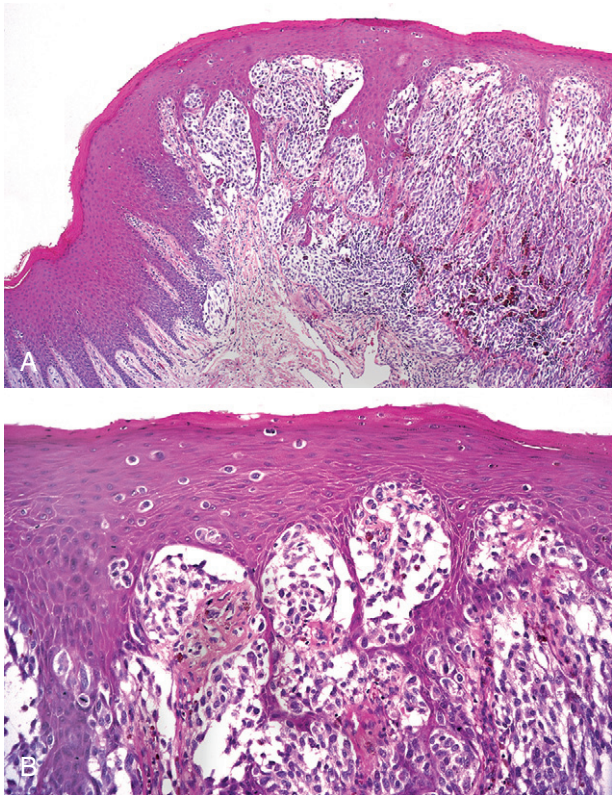

■ **FIGURE 5-22 Invasive melanoma. A** and **B,** Note that malignant cells are invading overlying epithelium **(B).**

Etiology. Recent molecular analyses have provided improved insights into the etiology, pathogenesis, and classification of distinct forms of melanoma. In familial melanoma syndromes, germline mutations are well defined in three highly penetrant gene products: p16, $p14^{ARF}$, and cyclin-dependent kinase 4 (CDK4). Variations in the melanocortin 1 receptor gene *(MC1R),* a low-penetrance gene, also increase melanoma risk and act as a genetic modifier when cosegregating with the mutant *p16* gene. In sporadic melanomas that occur on skin without chronic sun-induced damage, frequent mutations of the oncogene *BRAF* or *N-RAS* have been identified. By contrast, melanomas occurring on sun-exposed skin generally lack mutations of these genes. Melanomas with wild-type *BRAF* or *N-RAS* frequently have increases in copy numbers of genes for CDK4 and cyclin D1 (CCND1), which are downstream components of the *RAS-BRAF* pathway. With comparative genomic hybridization analysis, it has been shown that despite some overlapping histologic features, mucosal melanomas are genetically distinct from melanomas occurring on non–sun-exposed surfaces, such as acral lentiginous melanoma.

Immunohistochemistry. Melanoma, especially when amelanotic, can histologically mimic other malignancies and is often included in the histopathologic differential diagnosis of poorly differentiated neoplasms. Three reliable antibodies that react with proteins expressed by melanoma are HMB45, MART-1, and anti–S-100 protein. These reactions do not involve antigens directly linked to melanin formation, making such immunohistochemical analysis effective in distinguishing pigment-poor melanomas from other tumors with similar microscopic appearance. Staining with these antibodies may be useful in locating occult tumor cells in

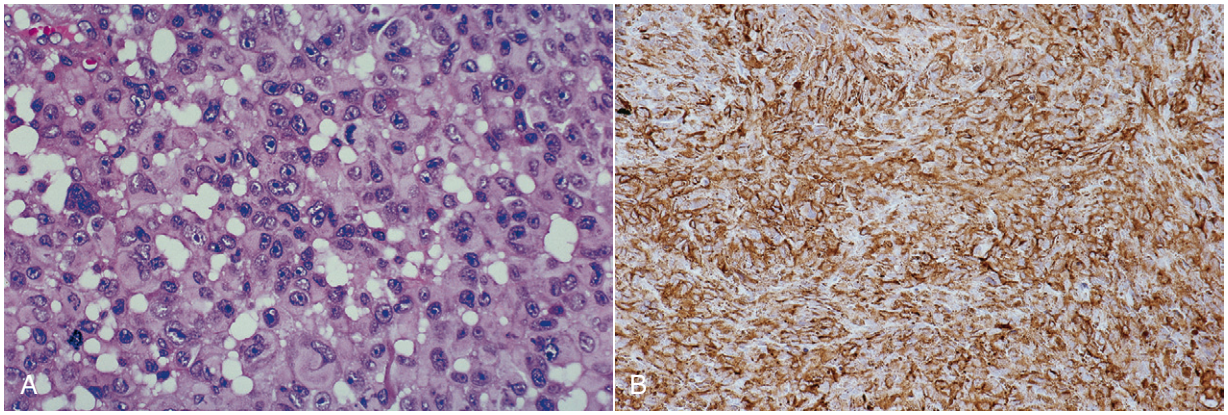

■ **FIGURE 5-23 A,** Amelanotic melanoma. **B,** Positive *(brown)* immunohistochemical stain (HMB-45), helping to confirm melanocytic origin.

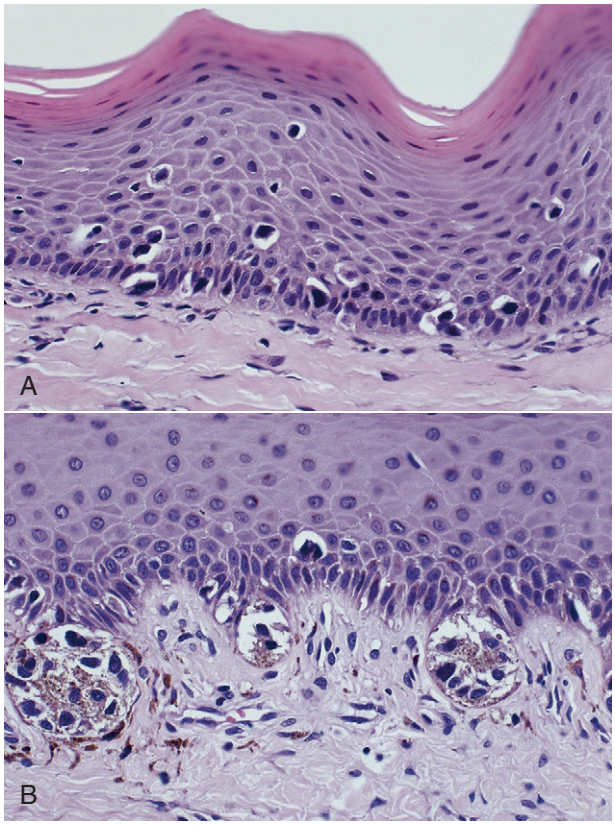

■ **FIGURE 5-24 In situ melanoma. A** and **B,** Lateral and intraepithelial spread of malignant cells. Small junctional tumor nests are evident in **B.**

BOX 5-6 ORAL MELANOMA

Palate and gingiva are high-risk sites.
Early lesion—pigmented macule
Advanced lesion (ABCS)—*a*symmetry, *b*orders irregular, *c*olor variable, *s*atellite lesions
No known risk factors

BIOLOGICAL SUBTYPES

In situ melanoma
- Prolonged preinvasive junctional phase
- Poor prognosis due to delayed diagnosis and undertreatment

Invasive melanoma
- Connective tissue invasion without junctional phase
- Poor prognosis

tissue sections, aiding in evaluation of the depth of invasion and in detection of metastasis.

HMB45 reacts with an intracellular antigen in a variable number of cells in approximately 90% of melanomas. Although highly specific for melanoma, some nevi may be reactive. Normal melanocytes are typically nonreactive. Some nonmelanoma tumors (lymphoma, adenocarcinoma, angiomyolipoma) have also been shown to react to HMB45.

An antibody to a transmembrane protein on melanoma cells recognized by T cells (anti–MART-1, or melanin-A) has been shown to be useful in the diagnosis of melanoma. Because this antigen (protein) is preserved in formalin-fixed tissue, it can be used when S-100 and HMB45 stains are equivocal, or in lieu of HMB45.

Differential Diagnosis. Intraorally, differential considerations include melanocytic nevus, amalgam tattoo, physiologic pigmentation, melanotic macule, and Kaposi's sarcoma. The history, symmetry, and uniformity of pigmentation are of significant value in differentiating these lesions. Because melanomas may initially have a relatively innocuous appearance, a biopsy should be done on any area of questionable pigmentation.

Treatment and Prognosis. Surgery remains the primary mode of treatment for melanomas. Chemotherapy is often used, and specific kinase inhibitors and immunotherapy are increasingly used as treatment adjuncts. Radiotherapy has not been fully explored as a primary treatment method, but it may have a supportive role in disease management. Treatment failures of mucosal melanomas are most commonly linked to incomplete excision, resulting in local recurrence and distant metastasis. Regional lymph node metastases are often detected by a sentinel node biopsy; this finding affects the choice and extent of therapy. The need for wide surgical excision of in situ melanomas with a radial growth pattern is apparent from the microscopic appearance of this phenomenon.

The prognosis is based on both the histologic subtype and the depth of tumor invasion. The latter feature is a well-established prognosticator for skin lesions that has been applied to oral melanomas. Oral lesions have been found to be of considerably greater thickness (and consequently to be more advanced) than skin lesions at the time of biopsy. After 5 years, the survival rate for patients with cutaneous melanomas is about 65%, whereas the survival rate for patients with oral lesions is about 20%. Unfortunately, the survival rate for patients with oral lesions continues to decline after the traditional measure of 5 years. The overall poor prognosis of oral lesions compared with skin lesions may therefore be related in part to late recognition of the oral lesions; this has led to tumor invasion beyond 4 mm in a majority of oral melanoma cases at the time of diagnosis, with direct prognostic relevance. Another factor is probably the more confining and difficult treatment area of the oral cavity, which often precludes the ability to achieve wide margins. Oral lesions may be inherently biologically more aggressive than skin lesions; support for this is seen in the finding of distinct genomic profiles compared with cutaneous melanomas. Until more lesions are subclassified and measured for depth of invasion, these questions will go unanswered.

NONMELANOCYTIC LESIONS

Amalgam Tattoo (Focal Argyrosis)

Etiology. Amalgam tattoo, or focal argyrosis, is an iatrogenic lesion that follows traumatic soft tissue implantation of amalgam particles or passive transfer by chronic friction of mucosa against an amalgam restoration. This usually follows tooth extraction, preparation of teeth having old amalgam fillings for gold-casting restorations, or polishing of old restorations (producing an aerosol of amalgam that becomes impregnated in the tissues). It has been suggested that the formation of soluble silver compounds may be involved in soft tissue deposits.

Clinical Features. This is the most common pigmentation of oral mucous membranes (Figs. 5-25 to 5-27). These lesions would be expected in the soft tissues contiguous with teeth restored with amalgam alloy. Therefore, the most commonly affected sites are the gingiva, buccal mucosa, palate, and tongue. Because amalgam is relatively well tolerated by soft tissues, clinical signs of inflammation are rarely seen. The lesions are macular and gray and do not change appreciably over time. If the amalgam particles are of sufficient size, they may be detected on soft tissue radiographs.

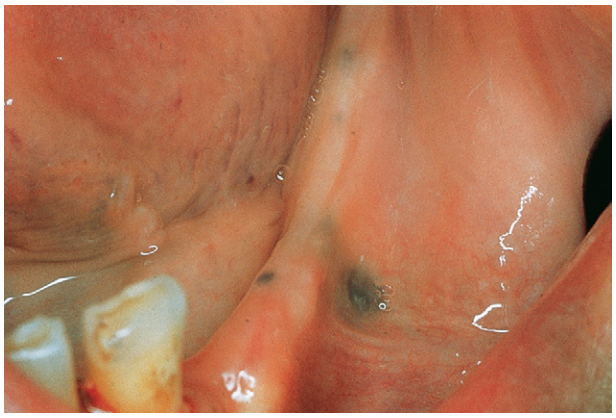

■ **FIGURE 5-25** Amalgam tattoo.



■ **FIGURE 5-26** Amalgam tattoo of the buccal mucosa.

Histopathology. Microscopically, amalgam particles have an affinity for collagen fibers and elastic fibers of blood vessels, typically staining them black or golden brown (Fig. 5-28). Few lymphocytes and macrophages are found, except in cases in which particles are relatively large. Multinucleated foreign body giant cells containing amalgam particles may be seen.

Differential Diagnosis. The significance of the amalgam tattoo lies in its clinical similarity to melanin-producing lesions. In a gingival or a palatal location, separation from nevi and, more important, early melanoma is mandatory, because these are the most common areas for the latter lesions as well. Radiographs, the history, and an even, persistent gray appearance would help to separate amalgam tattoo from melanoma. Any questionable lesions should undergo a biopsy.

Drug-Induced Pigmentations

Tetracycline-associated pigmentation may be found after the treatment of acne with prolonged high doses of *minocycline* (Fig. 5-29). Diffuse skin pigmentation may be seen in sun-exposed areas, apparently as a result of increased melanin

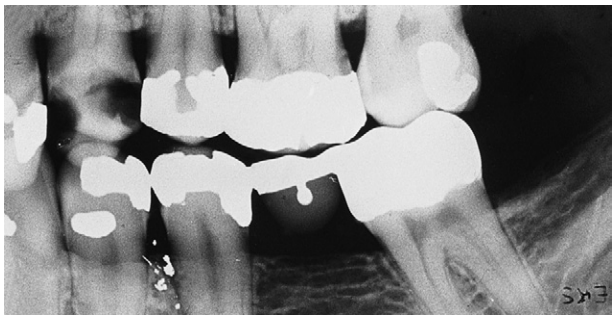

■ **FIGURE 5-27** Amalgam tattoo of the gingiva as detected in a bite-wing radiograph.

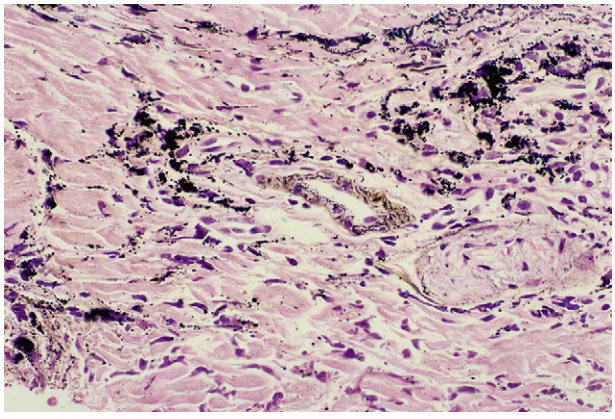

■ **FIGURE 5-28** Amalgam tattoo showing pigment along collagen bundles and around vessels.

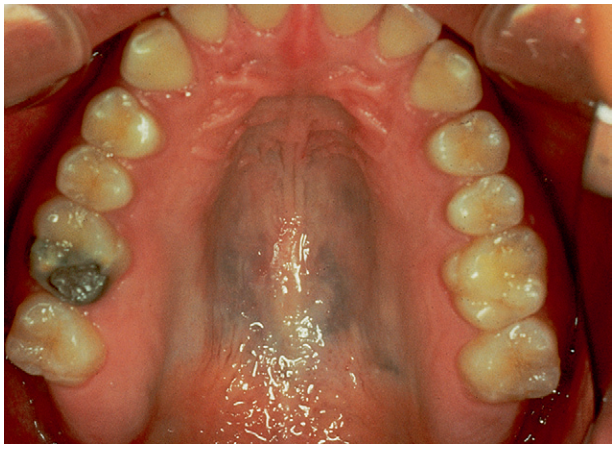

■ **FIGURE 5-29** Minocycline pigmentation of the palate.

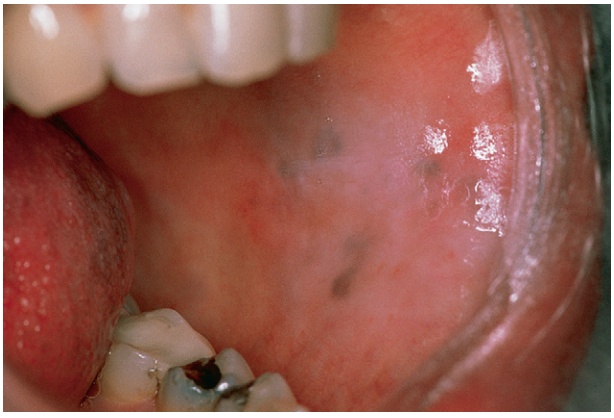

■ **FIGURE 5-30** Cyclophosphamide-induced pigmentation of the buccal mucosa.

BOX 5-7 DRUGS WITH ORAL PIGMENT–PRODUCING POTENTIAL

Amiodarone
Aminoquinolines
Clofazimine
Cyclophosphamide
Heavy metal–containing compounds
Quinacrine
Minocycline
Premarin
Zidovudine



■ **FIGURE 5-31** Clofazimine-related mucosal pigmentation.



■ **FIGURE 5-32** Lead pigmentation of the gingival margins.

production, or focal pigment deposits may be seen in the legs and periorbital skin, apparently as a result of drug complexes in melanocytes. Pigmentation of the gingiva and palate is due to increased amounts of melanin and probably deposits of drug (or drug bound to melanin) in bone and tooth roots.

Other exogenous drugs that may produce pigmentation of oral tissues (Box 5-7) include aminoquinolines (e.g., chloroquine), cyclophosphamide, amiodarone, zidovudine (azidothymidine [AZT]), quinacrine, clofazimine, and heavy metal–containing compounds (Figs. 5-30 and 5-31). Oral pigmentation has also been described in patients on hormone replacement therapy (conjugated estrogens [Premarin]). AZT, which is used in the treatment of acquired immunodeficiency syndrome (AIDS), may cause nail pigmentation, in addition to mucosal pigmentation.

Heavy-Metal Pigmentations

Etiology. Some heavy metals (arsenic, bismuth, platinum, lead, mercury) may be responsible for oral pigmentation. This phenomenon occurs predominantly after occupational exposure to vapors of these metals. Historically, arsenic and bismuth compounds were used to treat diseases such as syphilis, lichen planus, parasitic infections, and other dermatoses, providing another method for oral heavy-metal deposition. Cisplatinum, the salt of the heavy metal, has antineoplastic activity and is used to treat some malignancies. The side effect of a gingival platinum line has been described within this context.

Clinical Features. These heavy metals may be deposited in both skin and oral mucosa (especially in the gingiva). The characteristic color is gray to black, and the distribution is linear when found along the gingival margin (Fig. 5-32).

Bismuth and lead staining of gingival tissues is known as a *bismuth line* and a *lead line,* respectively. This staining is proportional to the amount of gingival inflammation and appears to be a result of the reaction of the heavy metal with bacterially produced hydrogen sulfide in inflammatory zones.

Significance. Metallic deposits in oral mucosa, per se, are relatively insignificant. The underlying cause must be investigated because of the detrimental effects of systemic toxicity. For dental personnel, chronic mercury vapor exposure is now recognized as a significant occupational hazard if dental amalgam is handled carelessly and without proper precautions. Dental patients, however, are apparently at no risk because of the relatively short exposure periods that they experience with routine office visits. Toxicity from the restorations themselves is apparently negligible.

If, in the dental office, the atmospheric air has elevated mercury vapor levels, dental personnel may show elevated body levels of mercury as measured in the hair, nails, saliva, and urine. *Chronic mercury intoxication* may produce symptoms of tremors, loss of appetite, nausea, depression, headache, fatigue, weakness, and insomnia. Hazards from mercury can be eliminated in the dental office if precautions are observed. The most common recommendations include (1) storage of mercury in sealed containers; (2) coverage of mercury spills with sulfur dust to prevent vaporization; (3) use of hard, seamless floor surfaces instead of carpeting; (4) working in well-ventilated spaces with frequent air filter changes; (5) storage of amalgam scraps under water in a sealed container; (6) use of well-sealed amalgam capsules; and (7) use of water spray and suction when grinding amalgam.

BIBLIOGRAPHY

Ayoub N, Barete S, Bouaziz JD et al: Additional conjunctival and penile pigmentation in Laugier-Hunziker syndrome: a report of two cases. Int J Dermatol 43:571–574, 2004.

Barker B, Carpenter WM, Daniels TE et al: Oral mucosal melanomas: the WESTOP Banff workshop proceedings. Oral Surg Oral Med Oral Pathol Oral Radiol Endod 83:672–679, 1997.

Batsakis JG, Suarez P, El-Naggar A: Mucosal melanomas of the head and neck. Ann Otol Rhinol Laryngol 107:626–629, 1998.

Bradley PJ: Primary malignant mucosal melanoma of the head and neck. Curr Opin Otolaryngol Head Neck Surg 14:100–104, 2006.

Buchner A, Merrell P, Hansen L et al: Melanocytic hyperplasia of the oral mucosa. Oral Surg Oral Med Oral Pathol 71:58–62, 1991.

Buchner A, Merrell PW, Carpenter WM: Relative frequency of solitary melanocytic lesions of the oral mucosa. J Oral Pathol Med 33:550–557, 2004.

Curtin JA, Fridlyand J, Kageshita T et al: Distinct sets of genetic alterations in melanoma. N Engl J Med 17:2135–2147, 2005.

Fitzpatrick J: New histopathologic findings in drug eruptions. Dermatol Clin 10:19–36, 1992.

Gerbig AW, Hunziker T: Idiopathic lenticular mucocutaneous pigmentation or Laugier-Hunziker syndrome with atypical features. Arch Dermatol 132:844–845, 1996.

Greenberg R, Berger T: Nail and mucocutaneous hyperpigmentation of azidothymidine therapy. J Am Acad Dermatol 22:327–330, 1990.

Gupta G, Williams RE, Mackie RM: The labial melanotic macule: a review of 9 cases. Br J Dermatol 136:772–775, 1997.

Hicks MJ, Flaitz CM: Oral mucosal melanoma: epidemiology and pathobiology. Oral Oncol 36:152–169, 2000.

Joska L, Venclikova Z, Podanna M et al: The mechanism of gingival metallic pigmentation formation. Clin Oral Invest 13: 1–7, 2009.

LaPorta VN, Nikitakis NG, Sindler AJ et al: Minocycline-associated intraoral soft tissue pigmentation: clinicopathologic correlations and review. J Clin Periodontol 32:119–122, 2005.

Lema B, Najarian DJ, Lee M et al: Numerous hyperpigmented macules of the oral mucosa. J Am Acad Dermatol 62:171–173, 2010.

Lerman MA, Karimbux N, Guze KA et al: Pigmentation of the hard palate. Oral Surg Oral Med Oral Pathol Oral Radiol Endod 107:8–12, 2009.

Marakoglu K, Gorsoy UK, Toker HC: Smoking status and smoke-related gingival melanin pigmentation in army recruits. Mil Med 172:100–113, 2007.

Marghoob AA, Koenig K, Bittencourt FV et al: Breslow thickness and Clark level in melanoma. Cancer 88:589–595, 2000.

Marocchio LS, Junior DSP, de Sousa SC et al: Multifocal diffuse oral melanoacanthoma: a case report. J Oral Sci 51:463–466, 2009.

McLean N, Tighiouart M, Muller S: Primary mucosal melanoma of the head and neck: comparison of clinical presentation and histopathologic features of oral and sinonasal melanoma. Oral Oncol 44:1039–1046, 2008.

Meleti M, Mooi WJ, Casparie MK et al: Melanocytic nevi of the oral mucosa: no evidence of increased risk of oral malignant melanoma: an analysis of 119 cases. Oral Oncol 43:976–981, 2007.

Meleti M, Vescovi P, Mooi WJ et al: Pigmented lesions of the oral mucosa and perioral tissues: a flow chart for the diagnosis and some recommendations for the management. Oral Surg Oral Surg Oral Pathol Oral Radiol Endod 105:606–616, 2008.

Mendenhall WM, Amdur RJ, Hinerman RW et al: Head and neck mucosal melanoma. Am J Clin Oncol 28:626–630, 2005.

Nunley KS, Gao F, Albers AC et al: Predictive value of café-au-lait macules at initial consultation in the diagnosis of neurofibromatosis type 1. Arch Dermatol 145: 883–887, 2009.

Odell EW, Hodgson RP, Haskell R: Oral presentation of minocycline-induced black bone disease. Oral Surg Oral Med Oral Pathol Oral Radiol Endod 79:459–461, 1995.

Patrick RJ, Fenske NA, Messina JL: Primary mucosal melanoma. J Am Acad Dermatol 56:828–834, 2007.

Patton LL, Brahim JS, Baker AR: Metastatic malignant melanoma of the oral cavity: a retrospective study. Oral Surg Oral Med Oral Pathol 78:51–56, 1994.

Piperi EP, Sake RA, Tosios KI et al: Mandibular melanotic neuroectodermal tumor of infancy treated conservatively with enucleation. J Craniofac Surg 21:685–688, 2010.

Rees T: Oral effects of drug abuse. Crit Rev Oral Biol Med 3:163–184, 1992.

Rustgi AK: Hereditary gastrointestinal polyposis and nonpolyposis syndromes. N Engl J Med 331:1694–1702, 1994.

Sanchez AR, Rogers RS, 3rd, Sheridan PJ: Tetracycline and other tetracycline-derivative staining of the teeth and oral cavity. Int J Dermatol 43:709–715, 2004.

Sarswathi TR, Kumar SN, Kavitha KM: Oral melanin pigmentation in smoked and smokeless tobacco users in India: clinicopathologic study. Indian J Dent Res 14:1010–1106, 2003.

Shah KN: The diagnostic and clinical significance of café-au-lait macules. Pediatr Clin North Am 57:1131–1153, 2010.

Slootweg P: Heterologous tissue elements in melanotic neuroectodermal tumor of infancy. J Oral Pathol Med 21:90–92, 1992.

Tadini G, D'Orso M, Cusini M et al: Oral mucosa pigmentation: a new side effect of azidothymidine therapy in patients with acquired immunodeficiency syndrome. Arch Dermatol 127: 267–268, 1991.

Tanaka N, Amagasa T, Iwaki H et al: Oral malignant melanoma in Japan. Oral Surg Oral Med Oral Pathol 78:81–90, 1994.

Tanaka N, Mimura M, Ogi K et al: Primary malignant melanoma of the oral cavity: assessment of outcome from the clinical records of 35 patients. J Oral Maxillofac Surg 33:761–765, 2004.

Veraldi S, Cavicchini S, Benelli C et al: Laugier-Hunziker syndrome: a clinical, histopathologic, and ultrastructural study of four cases and review of the literature. J Am Acad Dermatol 25:632–636, 1991.

Weyers W, Euler M, Diaz-Cascajo C et al: Classification of cutaneous malignant melanoma. Cancer 86:288–299, 1999.

Zala L, Hunziker T, Braathen LR: Pigmentation following long-term bismuth therapy for pneumatosis cystoides intestinalis. Dermatology 187:288–289, 1993.

CHAPTER 6



Verrucal-Papillary Lesions

REACTIVE/INFECTIOUS LESIONS

Squamous Papilloma/Oral Wart
Papillary Hyperplasia
Condyloma Latum
Condyloma Acuminatum
Focal Epithelial Hyperplasia

NEOPLASMS

Keratoacanthoma
Verrucous Carcinoma

IDIOPATHIC LESIONS

Pyostomatitis Vegetans
Verruciform Xanthoma

REACTIVE/INFECTIOUS LESIONS

Squamous Papilloma/Oral Wart

Oral squamous papilloma is a generic term that is used to include papillary and verrucous growths composed of benign epithelium and minor amounts of supporting connective tissue.

Oral squamous papilloma (including the vermilion portion of the lip) is the most common papillary lesion of the oral mucosa and accounts for approximately 2.5% of all oral lesions. Similar to verruca vulgaris (warts) on the skin, many oral squamous papillomas have been shown to be associated with the human papillomavirus (HPV). The type of HPV varies, with some cases having the same subtype as cutaneous warts and others having different HPV strains. Whether all oral papillomas are of viral origin is unresolved. It has been shown that the class of HPVs is very large (more than 100 subtypes), and that individually these viruses are associated with many conditions of squamous epithelium. For example, HPV subtypes 2 and 4 have been demonstrated within cutaneous warts; flat warts of the skin have been associated with HPV subtypes 3 and 10. HPV subtype 11 has been found within papillomas of the sinonasal tract and the oral cavity. HPV subtypes 16 and 18 have been related to neoplastic changes of cervical squamous epithelium and to oropharyngeal squamous cell carcinoma (Table 6-1).

Etiology. HPV, the putative etiologic agent of papillomas of the upper aerodigestive tract, is a member of the papovavirus group. It is a DNA virus containing a single molecule of double-stranded DNA comprising approximately 8000 nucleotide base pairs. The viruses themselves are nonenveloped icosahedral particles ranging from 45 to 55 nm in diameter with 72 capsomeres in a skewed arrangement. Various species are antigenically distinct, sharing some common antigenic determinants. HPV specifically infects basal epithelial cells and establishes productive infection only in the stratified squamous epithelium of the skin and mucosa. Replication of HPV occurs within the nuclei of

TABLE 6-1 LESIONS CAUSED BY HUMAN PAPILLOMAVIRUS SUBTYPES

Lesion	HPV Subtype
Oral papilloma/wart	2, 6, 11, 57
Focal epithelial hyperplasia	13, 32
Dysplastic wart (HIV)	16, 18, others
Verruca vulgaris, skin	2, 4, 40, others
Flat wart	3, 10
Condyloma acuminatum	6, 11, others
Laryngeal papilloma	11
Conjunctival papilloma	11

HIV, Human immunodeficiency virus; *HPV*, human papillomavirus.

BOX 6-1 PAPILLOMA

Common oral epithelial proliferation
Most caused by HPV
Nononcogenic subtypes (HPV subtypes 2, 6, 11, and 57)
"Oral wart" (verruca vulgaris)—synonym for papilloma
Very low level of infectivity
Little significance
Recurrence/multiple lesions in immunosuppressed patients (e.g., HIV-positive patients, transplant recipients)

HIV, Human immunodeficiency virus; *HPV*, human papillomavirus.

epithelial cells with the viral genome expressed in both early and late stages. In HPV-associated benign epithelial proliferations, the virus is episomal, but in HPV-associated cancers, the virus is integrated into the host cell DNA. If progeny production is blocked, persistent infection may result. However, if intact viruses are produced, new infective particles can be released with or without cell death.

Clinical Features. Oral squamous papillomas may be found on the vermilion portion of the lips and on any intraoral mucosal site, with predilection for the hard and soft palate and the uvula (Box 6-1; Figures 6-1 to 6-3). The latter three sites account for approximately one third of all lesions. The lesions generally measure less than 1 cm in greatest dimension and appear as pink to white exophytic granular or cauliflower-like surface alterations. They are generally asymptomatic and solitary in their presentation, although multiple lesions may occur.

The incidence of oral warts is increasing in patients with human immunodeficiency virus (HIV)/acquired immunodeficiency syndrome (AIDS) in contrast to other oral manifestations of the disease. This has been associated with the use of antiretroviral therapeutics, particularly highly active antiretroviral therapy (HAART). Lesions range from flat-topped plaques to verruciform or cauliflower-shaped exophytic masses. Lesions also tend to be multiple and recurrent.



■ **FIGURE 6-1 Papilloma,** lateral tongue.

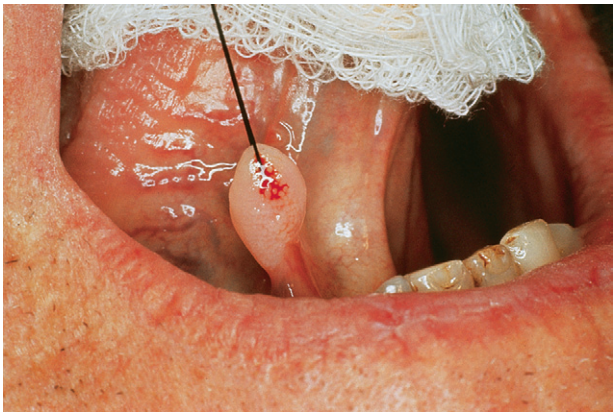

■ **FIGURE 6-2 Papilloma,** floor of mouth.

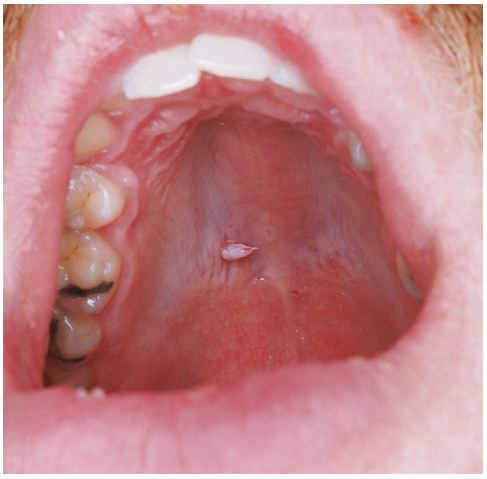

■ **FIGURE 6-3 Oral wart,** palate.

Histopathology. Oral squamous papillomas represent an exaggerated growth of normal squamous epithelium (Figures 6-4 to 6-6). The lesions are exophytic and are composed of finger-like extensions of epithelium, supported by



■ **FIGURE 6-4** Papilloma.

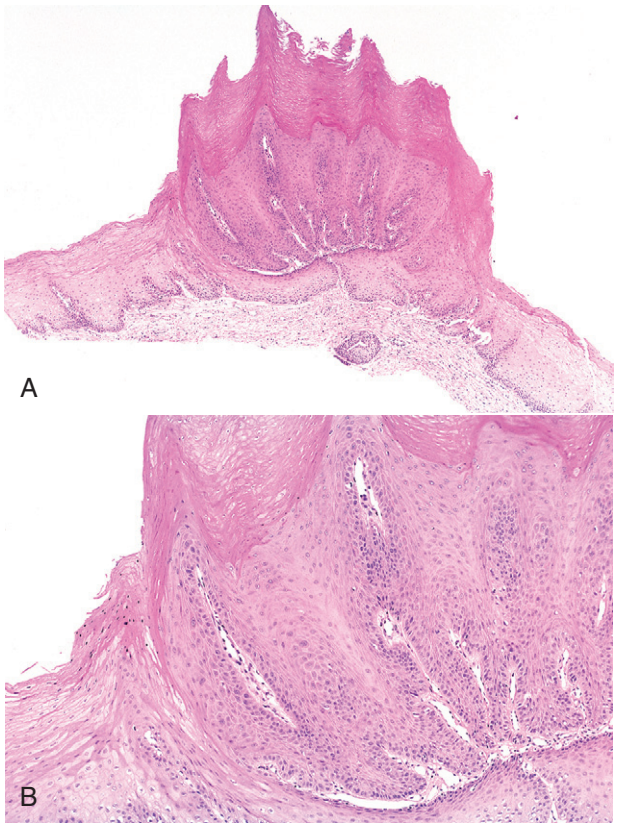

■ **FIGURE 6-5 A** and **B, Oral wart.**

a well-vascularized connective tissue core. The histologic architecture may mimic the pattern of the cutaneous wart. Upper level epithelial cells demonstrate nuclei that are pyknotic (condensed) and crenated, often surrounded by an edematous or optically clear zone, forming the so-called koilocytic cell. In the uterine cervix, this cytologic appearance represents HPV infection, which by extension is generally thought to present in the oral cavity.

Dysplastic Oral Warts. A small subset of HIV/AIDS patients develop oral warts that exhibit microscopic changes

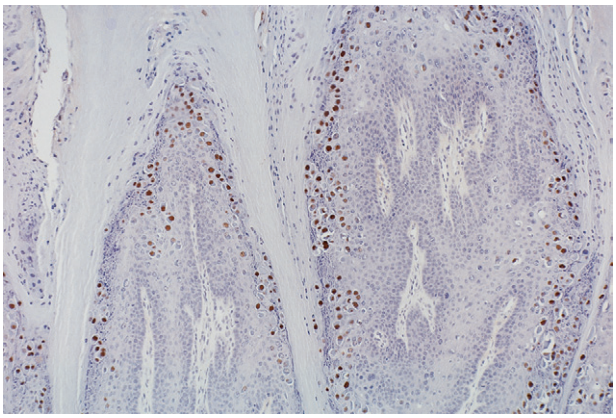

■ **FIGURE 6-6 Oral wart.** Immunohistochemical stain for common human papillomavirus in an oral wart. Positive, brown-staining nuclei are seen in upper level keratinocytes.

BOX 6-2 DYSPLASTIC ORAL WARTS

HIV-positive patients only
Multiple HPV subtypes, including 16, 18
Oral mucosa only
Histopathology—ranging from dysplasia to in situ carcinoma
Invasive/metastatic potential unknown

HIV, Human immunodeficiency virus; *HPV*, human papillomavirus.

that are dysplastic in appearance (Box 6-2; Figure 6-7). The degree of dysplasia ranges from mild to severe. The outcome, or natural history, of these dysplastic warts is unknown, although invasive carcinoma has yet to be reported despite several years of follow-up. A wide variety of HPV subtypes, including 16 and 18, can be demonstrated in these lesions.

Differential Diagnosis. The differential diagnosis of oral squamous papilloma, when solitary, includes verruciform xanthoma, papillary hyperplasia, and condyloma acuminatum. Verruciform xanthoma may resemble squamous papilloma, although this lesion has a distinct predilection for the gingiva and the alveolar ridge and contains xanthoma (foamy) cells in the connective tissue papillae. Inflammatory papillary hyperplasia usually occurs on the hard palate underneath a poorly fitting denture. A condyloma would be larger than the papilloma, would have a broader base, and would appear pink to red as a result of comparatively less keratinization.

Treatment and Prognosis. Although many oral squamous papillomas appear to be virally induced, the infectivity of the HPV is low. The route of transmission of the virus is unknown for oral lesions, although direct contact in an area of local trauma would be favored.

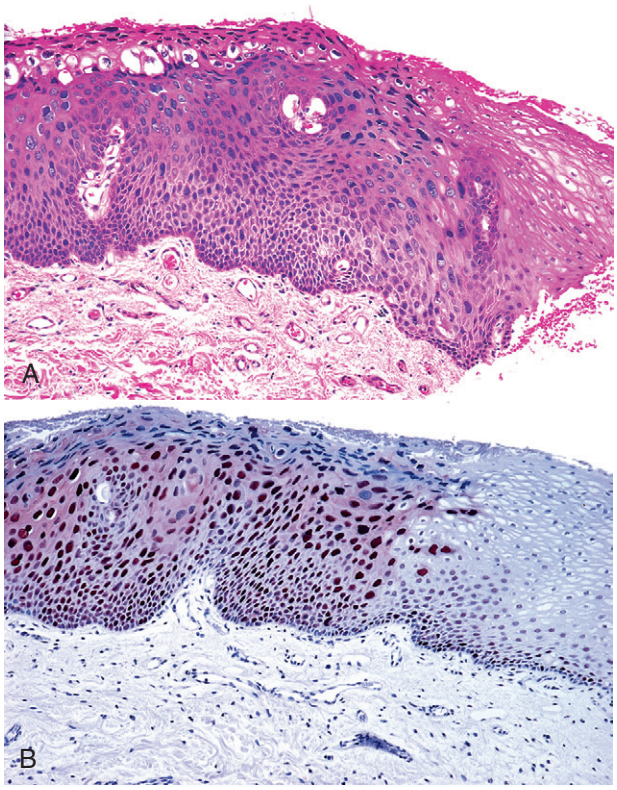

■ **FIGURE 6-7 Dysplastic oral wart. A,** Note normal epithelium at far right. **B,** Immunohistochemical stain for proliferation marker (proliferating cell nuclear antigen [PCNA]) showing positive nuclear staining *(red)* in most keratinocytes.



■ **FIGURE 6-8 Papillary hyperplasia.**

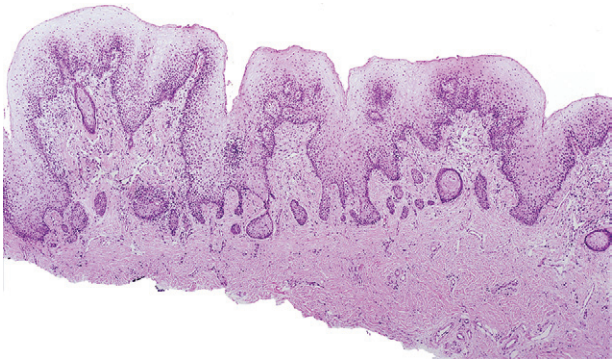

■ **FIGURE 6-9 Papillary hyperplasia.** Note pseudoepitheliomatous pattern.

Removal by surgical excision is the treatment of choice. Laser ablation is also effective but does not offer the opportunity for microscopic examination of the lesion to confirm the diagnosis. Recurrence is uncommon, except for lesions in patients infected with HIV.

Papillary Hyperplasia

Etiology. Papillary hyperplasia, or palatal papillomatosis, appears almost exclusively on the hard palate and almost always in association with a removable prosthesis. The precise cause of papillary hyperplasia is not well understood, although it appears to be associated with an ill-fitting or loose denture that creates a potential space between the denture base and tissue, predisposing to or potentiating growth of *Candida albicans* organisms. Tissue hyperplasia has been related to the presence of the fungal organism in the setting of low-grade chronic trauma.

Clinical Features. The area of mucosa over the palate that tends to be most commonly involved is the vault (Figure 6-8). Less commonly, the alveolar ridge or the palatal incline is affected.

Presentation is characterized by multiple erythematous and edematous papillary projections that are tightly aggregated, producing an overall verrucous, granular, or cobblestone appearance. The projections may be slender and almost villous, although in most cases, each projection tends to be rounded and blunted, with narrow spaces on either side. Ulceration is rare, although intense erythema may at times provide an overall appearance of erosion. Focal telangiectatic sites may also be noted on occasion.

Histopathology. On perpendicular cross-section, papillary hyperplasia appears as numerous small fronds or papillary projections covered with intact parakeratotic stratified squamous epithelium (Figure 6-9). The epithelium is supported by hyperplastic central cores of well-vascularized stromal tissue. The epithelium is hyperplastic and often demonstrates pseudoepitheliomatous features, occasionally severe enough to mimic squamous cell carcinoma. No evidence of dysplasia is found in association with this lesion and risk of malignant transformation is not increased.

Differential Diagnosis. The range of possibilities in the differential diagnosis of papillary hyperplasia of the palate is rather narrow because this particular entity is seldom

confused with other forms of pathology. The chief lesion to be separated from papillary hyperplasia is nicotine stomatitis involving the hard palate; however, nicotine stomatitis does not occur on the hard palate of those who wear complete maxillary removable appliances. Also, nicotine stomatitis tends to be more keratinized and usually demonstrates the presence of a small red dot or punctum in the center of each nodular excrescence, which represents the orifice of the subjacent minor salivary gland duct. Rarely, in Darier's disease, the mucosa of the palate may demonstrate numerous papules. Numerous squamous papillomas may occur on the palate; however, these lesions tend to be more keratinized with more delicate projections. In the so-called malignant form of acanthosis nigricans, oral lesions are papillary in nature and may regress relative to the treatment response of the underlying distant malignancy. Finally, in the multiple hamartoma syndrome (Cowden's syndrome), the oral mucosa may exhibit numerous papillary mucosal nodules. These nodules, composed of benign fibroepithelial proliferations, may impart a cobblestone appearance, usually to the tongue, buccal mucosa, and gingiva. Affected patients usually have other stigmata of the syndrome, including hamartomatous papules of the skin, benign breast lesions, and malignancies of the thyroid and kidney.

Treatment and Prognosis. Surgical removal is indicated before a denture is reconstructed for the patient. The actual surgical method is often a matter of individual preference and may include curettage, cryosurgery, electrosurgery, microabrasion, or laser ablation.

Removal of appliances at bedtime and soaking in a weak disinfecting or antifungal medium, as well as maintenance of good oral hygiene coupled with topical antifungal therapy, may significantly reduce the intensity of lesions. In mild cases, the use of soft tissue conditioning agents and liners, with frequent changes of the lining material, can produce sufficient resolution to preclude surgery. Topical antifungal ointment, alone or mixed with a corticosteroid ointment, may help reduce the size and intensity of the lesions, although it will not effect a complete cure when used alone.

Condyloma Latum

Condyloma latum is one of the many and variable expressions of secondary syphilis. As with all forms of syphilis, cutaneous, mucosal, and systemic lesions that mimic other conditions or diseases can be seen. Characteristic of condyloma latum is the presence of exophytic, sometimes friable, papillary to polypoid lesions within the oral cavity. Condyloma latum contains abundant microorganisms *(Treponema pallidum)*, making it potentially infectious.

Condyloma latum usually appears on the skin, especially in the perianal and genital areas. Lesions may also be noted within the oral cavity. Here the tissue is formed into a soft, red, often mushroom-like mass with a generally smooth, lobulated surface.

Microscopically, the overlying epithelium demonstrates significant acanthosis, along with intracellular and intercellular edema and transmigration of neutrophils. A perivascular plasma cell infiltrate is common within the lamina propria in the absence of a true vasculitis.

Patients require systemic administration of antibiotics to eliminate the underlying bacteremia. The oral lesions generally regress as the systemic disease is brought under control.

Condyloma Acuminatum

Condyloma acuminatum is an infectious lesion characteristically located in the anogenital region, but it may also involve the oral mucosa. Common to these sites is a warm, moist squamous epithelial surface. An increasing frequency of this lesion has been noted in HIV-infected patients, reflecting an aspect of opportunistic infection.

Etiology and Pathogenesis. Condyloma acuminatum is a verrucous or papillary growth of the skin or mucosa. More than 90% of cases are caused by HPV subtypes 6 and 11. The virus is spread through direct skin-to-skin or skin-to-mucosa contact during sex with an infected partner.

Clinical Features. Characteristic of early condyloma acuminatum formation is a group of numerous pink nodules that grow and ultimately coalesce (Figure 6-10). The result is a soft, broad-based, exophytic papillary growth that may be keratinized or nonkeratinized.

In 1 to 3 months after viral implantation, the disease becomes apparent. The lesions at times may be rather extensive, but they are generally self-limiting. Autoinoculation is a possible risk, thus offering a rationale for complete elimination of the lesions.

Histopathology. Papillary projections extending from the base of each lesion are covered by stratified squamous epithelium that is often parakeratotic but at times may be nonkeratinized. Koilocytosis of upper level epithelial cells is

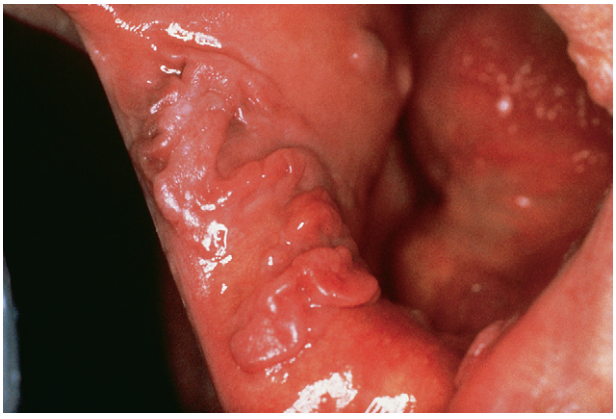

FIGURE 6-10 Condyloma acuminatum.

usually found. The epithelial layer itself is hyperplastic without evidence of dysplastic change. The underlying stroma is well vascularized and may contain a trace of chronic inflammatory cells.

Differential Diagnosis. Condyloma acuminatum may resemble focal epithelial hyperplasia in some cases. Multiple intraoral warts (verruca vulgaris) may be a consideration and indeed represent the same type of infection. Although condylomas tend to show more parakeratosis and acanthosis than verruca vulgaris, no universally accepted microscopic features can be used to reliably separate the two. DNA hybridization studies may be required to classify these lesions accurately.

Treatment and Prognosis. Treatment for these lesions is generally surgical excision, which may consist of cryosurgery, scalpel excision, electrodesiccation, or laser ablation. Recurrences are common and perhaps are related to surrounding normal-appearing tissue that may be harboring the infectious agent.

Focal Epithelial Hyperplasia

Focal epithelial hyperplasia (Heck's disease) was identified as a distinct entity in 1965. Early studies described lesions in Native Americans in both the United States and Brazil, and in the Inuits of Greenland. More recent studies have identified lesions in other populations and ethnic groups from South Africa, Mexico, and Central America, and clinical experience has demonstrated a wide ethnic incidence.

Etiology and Pathogenesis. Factors ranging from local low-grade irritation to vitamin deficiencies have been proposed as the cause of this condition. Convincing evidence, however, has been presented that HPV subtypes 13 and 32 have been consistently associated with focal epithelial hyperplasia. Suggestions that genetic factors are involved have been made but not substantiated.

Clinical Features. Focal epithelial hyperplasia is characterized by the presence of numerous nodular soft tissue masses distributed over the mucosal surfaces, especially the buccal mucosa, labial mucosa, tongue, and gingiva (Figures 6-11 and 6-12). Lesions may appear as discrete or clustered papules, often similar in color to the surrounding mucosa. If found in areas of occlusal trauma, they may appear whitish because of keratinization. The lesions are asymptomatic and often are discovered incidentally. Initially described in children, this condition is now known to affect patients in a wide age range. An equal gender distribution has been noted.

Histopathology. Acanthosis and parakeratosis are consistent findings. Prominent clubbing and fusion of epithelial ridges are also seen. Enlarged ballooning cells with abnormal nuclear chromatin patterns are often seen within the spinous layer. More superficial elements demonstrate cytoplasmic granular changes and nuclear fragmentation. Cells immediately beneath the surface often show pyknotic nuclei with a surrounding clear zone.

Ultrastructurally, crystalline arrangements of virus-like particles may be noted. Such particles, which are located within the superficial spinous cells, measure approximately 50 nm in diameter. Viruses may be found within the nucleus, as well as in the cytoplasm of spinous layer cells.



■ **FIGURE 6-11 Focal epithelial hyperplasia** of the lip.



■ **FIGURE 6-12 Focal epithelial hyperplasia** of the buccal mucosa.

Differential Diagnosis. A differential diagnosis would include verruca vulgaris and multiple squamous papillomas. The oral mucosal lesions of Cowden's (multiple hamartoma) syndrome may present similarly and should be ruled out. In addition, oral manifestations of Crohn's disease and pyostomatitis vegetans might be considered.

Treatment. No particular treatment is indicated, especially with widespread involvement. Surgical removal may be used if few lesions are present. Of significance is that

spontaneous regression has been noted in many cases, perhaps as an expression of viral recognition and cell-mediated immunity.

NEOPLASMS

Keratoacanthoma

Etiology. Keratoacanthoma is a squamoproliferative lesion of unknown cause that occurs chiefly on sun-exposed skin and, far less commonly, at the mucocutaneous junction. Lesions purported to represent keratoacanthoma have been described very rarely on mucous membranes. On the skin, keratoacanthomas originate within the pilosebaceous apparatus, which explains the predominance of this lesion there. It has been suggested that ectopic sebaceous glands may represent the site of origin intraorally. Virus-like intranuclear inclusions have been described in keratoacanthoma. Attempts to produce such lesions in experimental animals by inoculation of tumor tissue have been unsuccessful. However, a rabbit skin model of keratoacanthoma was developed using topical carcinogens. In addition to sunlight and viruses, suspected etiologic agents include chemical carcinogens, trauma, and disordered cellular immunity.

Clinical Features. Keratoacanthomas may be solitary or multiple (Figure 6-13). The lesion usually begins as a small red macule that soon becomes a firm papule with a fine scale over its highest point. Rapid enlargement of the papule occurs over approximately 4 to 8 weeks, resulting ultimately in a hemispheric, firm, elevated, asymptomatic nodule. When fully developed, a keratoacanthoma contains a core of keratin surrounded by a concentric collar of raised skin or mucosa. A peripheral rim of erythema at the base of the lesion may parallel the raised margin. Multiple keratoacanthomas are a feature of the Muir-Torre syndrome, an autosomal-dominant skin condition of genetic origin characterized by cutaneous tumors of the sebaceous gland and visceral malignant diseases.

If the lesion is not removed, spontaneous regression occurs. The central keratin mass is exfoliated, leaving a cup-shaped lesion that heals with superficial scar formation.

Histopathology. Keratoacanthoma is characterized by a central keratin plug with an overhanging lip or a marginal buttress of epithelium (Figure 6-14). Marked pseudoepitheliomatous hyperplasia is evident, along with an intense mixed inflammatory infiltrate.

The histologic similarity between a keratoacanthoma and a well-differentiated squamous cell carcinoma is of great importance. Numerous histologic criteria, such as a high level of differentiation, the formation of keratin masses, smooth symmetric infiltration, abrupt epithelial changes at lateral margins, and transepidermal elimination of sun-damaged elastic fibers, have been used to distinguish keratoacanthoma from carcinoma. Analysis of DNA indices and proliferative levels by flow cytometry of both well-differentiated squamous cell carcinomas and keratoacanthomas fails to separate the two lesions. Differences in various oncogene expression patterns and, more recently, in the expression of angiotensin type I receptors have supported or refuted the theory that keratoacanthomas are a well-differentiated type of carcinoma.

Differential Diagnosis. The primary entity to be distinguished from a solitary keratoacanthoma, from both a clinical and a microscopic perspective, is squamous cell carcinoma. Squamous cell carcinomas have a relatively slow growth rate, are of irregular shape, and generally begin later in life. For lesions on the lip, other conditions to be differentiated include molluscum contagiosum, solar keratosis, and verruca vulgaris. Most of these entities, however, can be easily excluded on the basis of histologic examination of the biopsy specimen.



■ **FIGURE 6-13 Keratoacanthoma** of the upper lip. (Reproduced with permission from Regezi JA, Sciubba JJ, Pogrel MA: Atlas of Oral and Maxillofacial Pathology. Philadelphia, 2000, WB Saunders, Figure 4-13.)

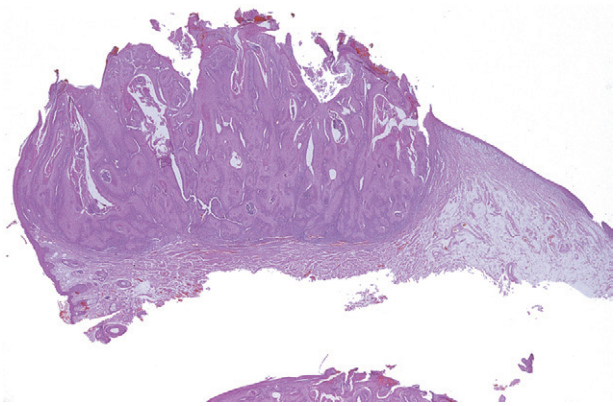

■ **FIGURE 6-14 Keratoacanthoma.** Note the "cup-shaped" symmetry and verruciform surface.

Treatment and Prognosis. At the least, a very careful follow-up is required in all cases because of difficulties in diagnosis and distinction from squamous cell carcinoma. Any dubious lesion should be treated because no absolutely reliable diagnostic, clinical, or histologic criteria are known to differentiate these two lesions. In addition, during the early phase of this lesion, prediction of its ultimate size may be impossible.

A solitary keratoacanthoma may be removed by surgical excision or by thorough curettage of the base; both methods are equally effective. No recurrence is expected. In cases in which no treatment is provided, spontaneous involution, often with scar formation, is seen.

Verrucous Carcinoma

Etiology. Verrucous carcinoma of oral mucous membranes (Box 6-3) is most closely associated with the use of tobacco in various forms, especially smokeless tobacco. Although oncogenic HPV has long been suspected to play a role in the development of verrucous carcinoma, studies using a variety of molecular methods have failed to establish a relationship.

Clinical Features. This form of cancer accounts for 5% of all intraoral squamous cell carcinomas (Figures 6-15 to 6-18). The buccal mucosa is the location for more than half of all cases, and the gingiva is the location for nearly one third of cases. The mandibular gingiva shows a slight predominance over the maxillary gingiva. A distinct male predominance has been noted, and most affected individuals are over 50 years of age.

Early lesions, which may initially be interpreted as verrucous hyperplasia, are relatively superficial and tend to appear white clinically. These lesions may arise in leukoplakia. In time, the lesion borders become irregular and indurated. As verrucous carcinoma develops, the lesion becomes exophytic with a whitish to gray shaggy surface. Although not highly infiltrative, the lesion pushes into surrounding tissues. When it involves the gingival tissues, it becomes fixed to the underlying periosteum. If it is untreated, gradual invasion of periosteum and destruction of bone occur.

Histopathology. At low magnification, surface papillary fronds are covered by a markedly acanthotic and highly

BOX 6-3 VERRUCOUS CARCINOMA

ETIOLOGY
Tobacco

CLINICAL FEATURES
Slow-growing verrucous patch
Locally destructive; rarely metastasizes
Buccal mucosa > gingiva > tongue > palate > other

MICROSCOPY
Well-differentiated carcinoma
Little or no dysplasia

TREATMENT
Excision; prognosis excellent

>, More frequently affected than.

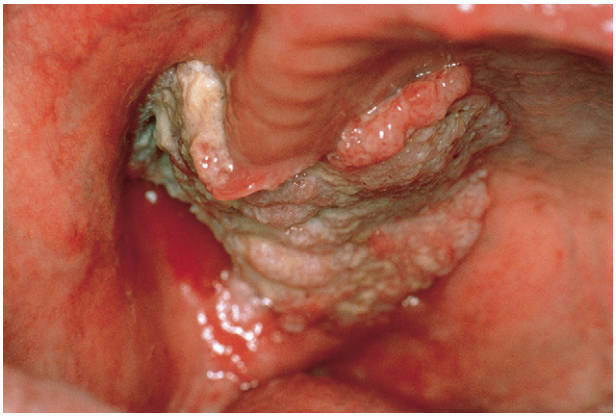

■ **FIGURE 6-15 Verrucous carcinoma** of the maxillary alveolar ridge.

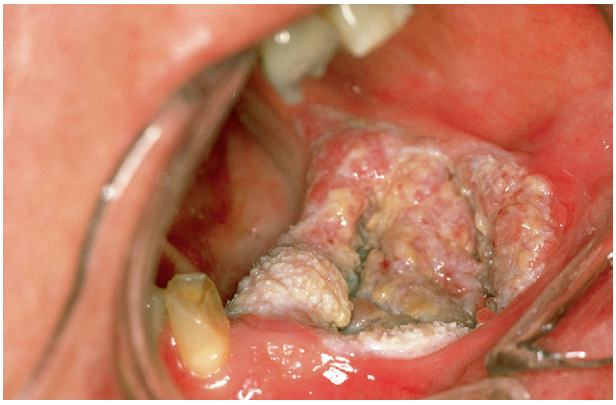

■ **FIGURE 6-16 Verrucous carcinoma** of the mandibular vestibule.



■ **FIGURE 6-17 Verrucous carcinoma** of the tongue.



■ **FIGURE 6-18 Verrucous carcinoma** of the lingual gingiva. (Reproduced with permission from Regezi JA, Sciubba JJ, Pogrel MA: Atlas of Oral and Maxillofacial Pathology. Philadelphia, 2000, WB Saunders, Figure 4-16.)

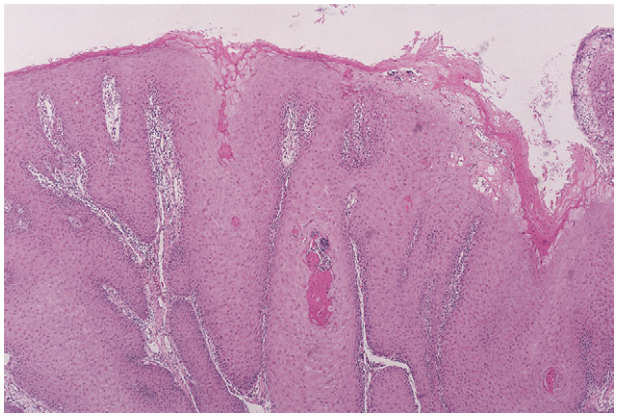

■ **FIGURE 6-19 Verrucous carcinoma** showing broad, "pushing," well-differentiated rete ridges.

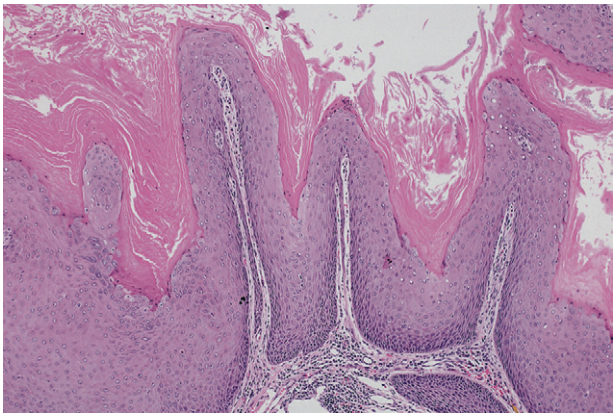

■ **FIGURE 6-20 Verrucous carcinoma** showing well-differentiated epithelium in a verruciform profile.



■ **FIGURE 6-21 Exophytic well-differentiated papillary squamous cell carcinoma** in the buccal sulcus in a 54-year-old woman.

keratinized epithelial surface. Bulbous, well-differentiated epithelial masses extend into the submucosa, with margins that are blunted and pushing (Figures 6-19 and 6-20). Adjacent to the pushing margins of the carcinoma is a lymphocytic infiltrate. Focal areas of acute inflammation surrounding foci of well-formed keratin are seen occasionally.

The deceptively benign microscopic pattern and the absence of significant cellular atypia are important. Diagnosis can be made only with a biopsy specimen of sufficient size to include the full thickness of the epithelial component, as well as the supporting connective tissue.

Papillary squamous cell carcinoma is a rarely seen malignancy of oral mucosa that has some resemblance to verrucous carcinoma (Figure 6-21). It exhibits a papillary profile and is moderately to well differentiated. Its prognosis is believed to be somewhat better than that for typical squamous cell carcinoma but worse than that for verrucous carcinoma.

Differential Diagnosis. In well-developed cases of verrucous carcinoma, the clinical pathologic diagnosis is relatively straightforward. However, in less than obvious situations, leukoplakia might be a clinical consideration. A differential diagnosis would also include papillary squamous carcinoma, which may be distinguished from verrucous carcinoma by its more infiltrative nature, its greater degree of cytologic atypia, and its more rapid growth. Verrucous carcinoma may develop from preexisting (and usually multiple) leukoplakia, representing part of the spectrum of *proliferative verrucous leukoplakia* (Box 6-4; Figures 6-22 to 6-27) (see also Chapter 3).

Treatment and Prognosis. Surgical methods are generally used as the primary form of therapy in most cases of verrucous carcinoma. This occurs primarily because of early reports of dedifferentiation seen in verrucous carcinoma after radiotherapy. The literature, however, now suggests that transformation to squamous cell carcinoma following radiotherapy occurs far less commonly than has been reported. Aggressive radiotherapy early or in combination with surgery may be a viable alternative treatment method.

Verrucous carcinoma rarely metastasizes, although it is locally destructive. In advanced cases in which the maxilla

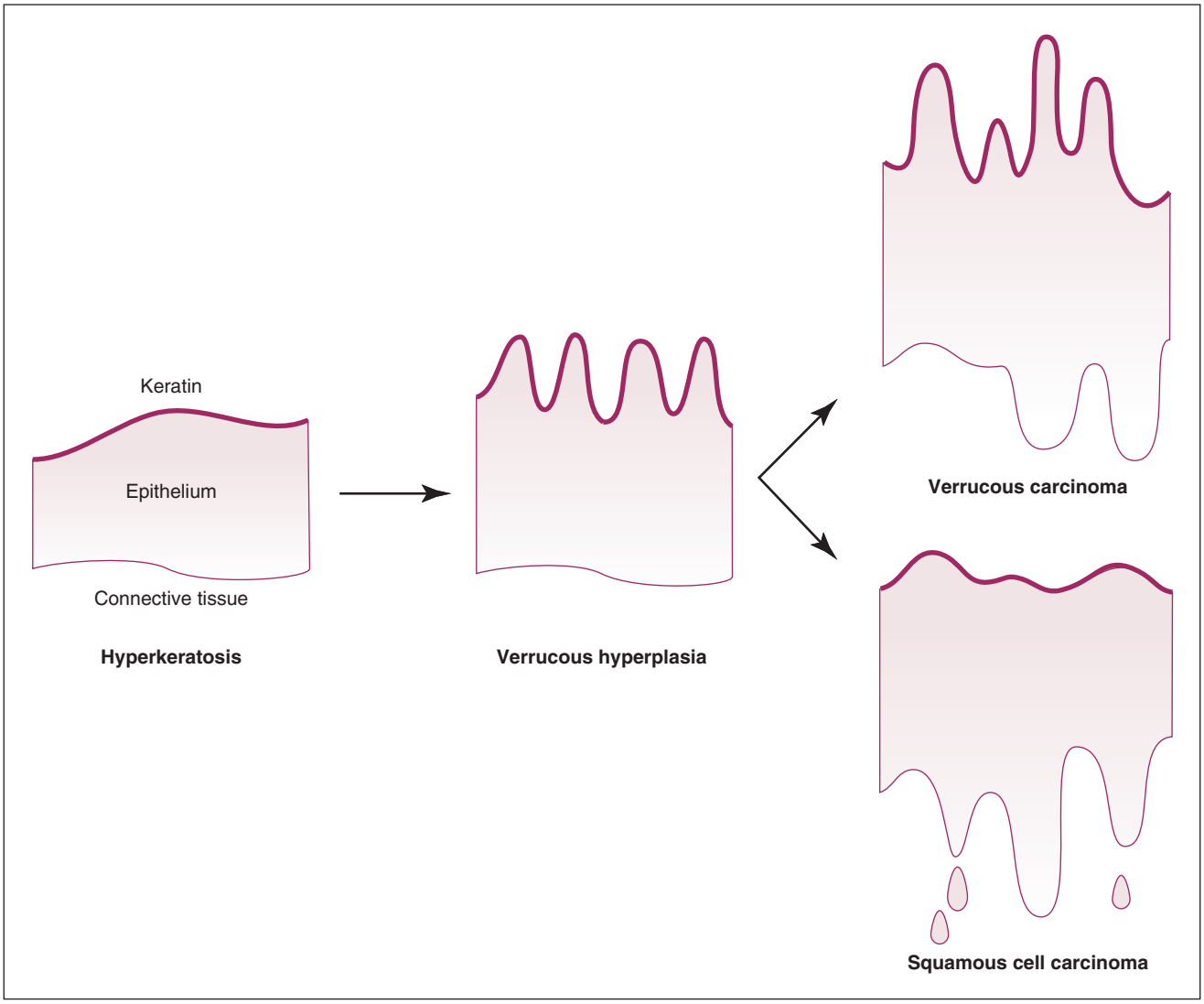

■ **FIGURE 6-22 Proliferative verrucous leukoplakia.**

BOX 6-4 PROLIFERATIVE VERRUCOUS LEUKOPLAKIA

ETIOLOGY

A subset of idiopathic leukoplakia
Unproven association with HPV subtypes 16 and 18
Tobacco not a strong etiologic factor, as with idiopathic leukoplakia

CLINICAL FEATURES

Females more often affected than males
Recurrent/persistent; multiple sites typical
Progression from simple keratosis to well-differentiated verruciform lesions
High risk of malignant transformation to verrucous carcinoma or squamous cell carcinoma

HPV, Human papillomavirus.

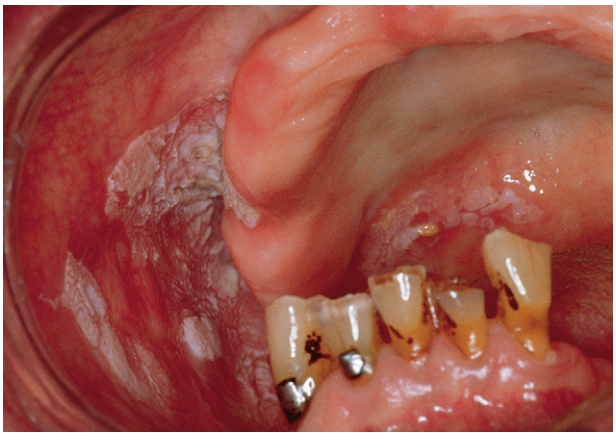

■ **FIGURE 6-23 Proliferative verrucous leukoplakia** of the buccal mucosa and soft palate.



■ **FIGURE 6-24 Proliferative verrucous leukoplakia** of the gingiva.



■ **FIGURE 6-25 Proliferative verrucous leukoplakia** of the gingiva. (Courtesy Dr. Sol Silverman, Jr.)

or the mandible exhibits significant destruction, resection may be necessary.

The prognosis for verrucous carcinoma is excellent, primarily because of its high level of differentiation and rarity of metastatic spread. Local recurrence, however, remains a distinct possibility if inadequate treatment is rendered.

IDIOPATHIC LESIONS

Pyostomatitis Vegetans

Originally described in 1949, pyostomatitis vegetans, a benign chronic and pustular form of mucocutaneous disease, is most often seen in association with inflammatory bowel disease. In two of the three original patients with oral disease, lesions were confined to the oral mucosa. The cause of pyostomatitis vegetans is unknown, although it may be seen in association with ulcerative colitis, spastic colitis, chronic diarrhea, and Crohn's disease. More than 25% of cases are not associated with gastrointestinal disturbances.

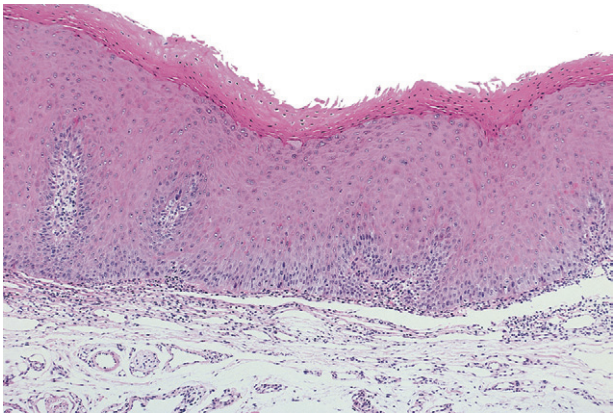

■ **FIGURE 6-26** Hyperkeratosis in an early phase of **proliferative verrucous leukoplakia.**

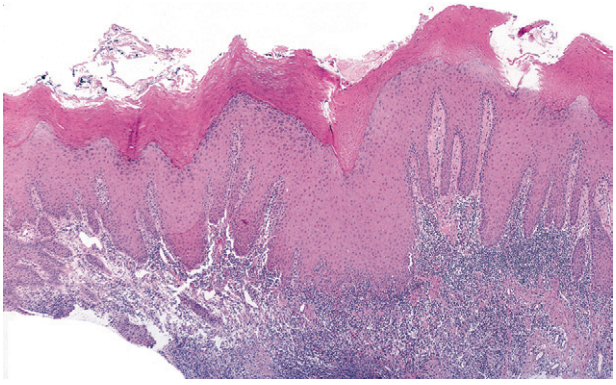

■ **FIGURE 6-27** Verrucous carcinoma developed from persistent **proliferative verrucous leukoplakia.**



■ **FIGURE 6-28 Pyostomatitis vegetans.**

Clinical Features. Early in the evolution of pyostomatitis vegetans, the oral mucosa (especially the buccal mucosa) appears erythematous, edematous, nodular, and occasionally fissured (Figure 6-28). Numerous tiny yellow pustules, ranging from 2 to 3 mm in diameter, and small vegetating papillary projections may be seen over the surface of friable mucosa. Oral mucosal involvement may include the gingiva,

hard and soft palate, buccal and labial mucosa, lateral and ventral aspects of the tongue, and floor of the mouth. Men are affected nearly twice as often as women, and the age range is generally between the third and sixth decades, with an average age of 34 years. Laboratory values may be within normal limits, but in most patients peripheral eosinophilia or anemia is noted.

Histopathology. The oral mucosa demonstrates hyperkeratosis and pronounced acanthosis, often with a papillary surface or with pseudoepitheliomatous hyperplasia (Figure 6-29). A pronounced inflammatory infiltrate composed of neutrophils and eosinophils is a constant finding. Superficial abscesses may be seen within the lamina propria, with extension into the parabasal regions of the overlying epithelium. Ulceration and superficial epithelial necrosis may be observed.

Treatment and Prognosis. Management of this entity relates to controlling the associated bowel disease. Topical agents, such as corticosteroids, may be used intraorally. In addition, antibiotics, multivitamins, and nutritional supplements may be given; however, all are associated with variable results. Remission of oral lesions occurs when underlying bowel disease is medically controlled.

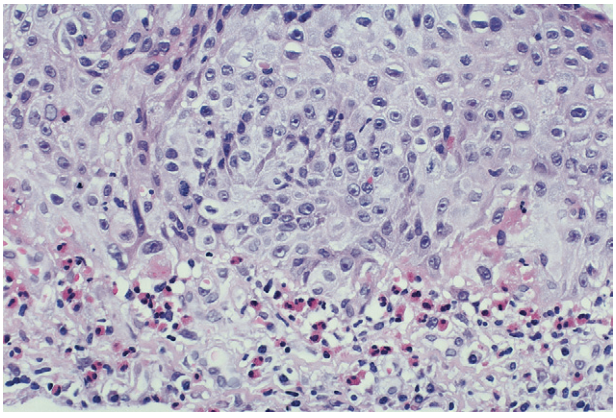

■ **FIGURE 6-29 Pyostomatitis vegetans** showing neutrophil and eosinophil infiltrates at the epithelium–connective tissue junction.

Verruciform Xanthoma

Verruciform xanthoma is an uncommon, benign oral mucosal lesion that occasionally may be found on the skin, typically on the genitalia. The cause is unknown, although missense mutations in exon 6 of the 3 beta-hydroxysteroid dehydrogenase *(NSDHL)* gene have been reported in solitary verruciform xanthoma. Mutations in this gene but within exons 4 and 6 have been reported in multiple syndromic verruciform xanthomas.

Clinical Features. Clinically, verruciform xanthoma is well circumscribed, with a granular to papillary surface. The size of this lesion ranges from 2 mm to more than 2 cm. An exophytic or depressed surface is present, and the lesion may occasionally be ulcerated. The level of keratinization of the surface influences the color, which ranges from white to red.

Most cases have been reported in whites, and no gender predilection has been noted. The average age of patients is 45 years, although a few cases have been reported within the first and second decades. The lesions are usually discovered incidentally.

Histopathology. The architecture of the lesion is flat or slightly raised, with a papillomatous or verrucous surface composed of parakeratinized epithelial cells (Figure 6-30). Uniformly invaginated crypts alternate with papillary extensions. Elongated epithelial ridges extend into the lamina propria at a uniform depth. The epithelial component is normal, with no evidence of dysplasia or atypia.

Numerous foam or xanthoma cells are found within the lamina propria or connective tissue papillae. Characteristic of the foam cells is a granular to flocculent cytoplasm that may contain periodic acid–Schiff (PAS)-positive, diastase-resistant granules or lipid droplets, or both. Ultrastructurally, the foam cells are best characterized as macrophages.

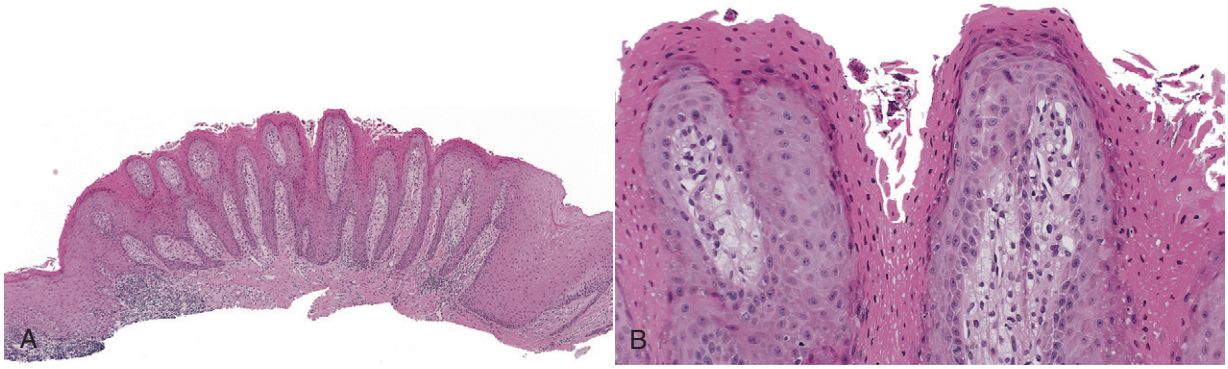

■ **FIGURE 6-30 Verruciform xanthoma. A** and **B,** Note xanthoma cells (foamy macrophages) in the lamina propria.

Differential Diagnosis. A differential diagnosis for this entity would include squamous papilloma, papillary squamous carcinoma, and condyloma acuminatum.

Treatment. Treatment consists of conservative excision. No recurrences have been reported.

BIBLIOGRAPHY

Squamous Papilloma/Oral Verruca Vulgaris

Broich G, Saskai I: Electron microscopic demonstration of HPV in oral warts. Microbiologica 13:27–34, 1990.

Cameron JE, Hagensee ME: Oral HPV complications in HIV-infected patients. Curr HIV/AIDS Rep 5:126–131, 2008.

Dos Santos Pinheiro R, Franca TT, Ribeiro CM et al: Oral manifestations in human immunodeficiency virus infected children in highly active antiretroviral therapy era. J Oral Pathol Med 38:613–622, 2009.

Kellokoski J, Syrjanen S, Syrjanen K et al: Oral mucosal changes in women with genital HPV infection. J Oral Pathol Med 19: 142–148, 1990.

Regezi JA, Greenspan D, Greenspan JS et al: HPV-associated epithelial atypia in oral warts in HIV patients. J Cutan Pathol 21:217–223, 1994.

Reznik DA: Oral manifestations of HIV disease. Topics HIV Med 13:143–148, 2005.

Zakrzewska JM, Atkin PA: Oral mucosal lesions in a UK HIV/AIDS oral medicine clinic: a nine-year, cross-sectional, prospective study. Oral Health Prev Dent 1:73–79, 2003.

Zeuss M, Miller C, White D: In situ hybridization analysis of human papilloma virus DNA in oral mucosal lesions. Oral Surg Oral Med Oral Pathol 71:714–720, 1991.

Papillary Hyperplasia

Chang F, Syrjanen S, Kellokoski J et al: Human papillomavirus (HPV) infections and their associations with oral disease. J Oral Pathol 20:305–307, 1991.

Kozlowski L, Nigra T: Esophageal acanthosis nigricans in association with adenocarcinoma from an unknown primary site. J Am Acad Dermatol 26:348–351, 1991.

Tyler MT, Ficarra G, Silverman S et al: Malignant acanthosis nigricans with florid papillary oral lesions. Oral Surg Oral Med Oral Pathol Oral Radiol Endod 81:445–449, 1996.

Young S, Min K: In situ DNA hybridization analysis of oral papillomas, leukoplakias, and carcinomas for human papillomavirus. Oral Surg Oral Med Oral Pathol 71:726–729, 1991.

Condyloma Acuminatum

Barone R, Ficarra G, Gaglioti D et al: Prevalence of oral lesions among HIV-infected intravenous drug abusers and other risk groups. Oral Surg Oral Med Oral Pathol 69:169–173, 1990.

Focal Epithelial Hyperplasia

Padayachee A, van Wyk C: Human papillomavirus (HPV) DNA in focal epithelial hyperplasia by in situ hybridization. J Oral Pathol Med 20:210–214, 1991.

Keratoacanthoma

Kaabipour E, Haupt HM, Stern JR et al: p16 expression in keratoacanthomas and squamous cell carcinomas of the skin: an immunohistochemical study. Arch Pathol Lab Med 130:69–73, 2006.

Lawrence N, Reed RJ: Actinic keratoacanthoma speculations on the nature of the lesion and the role of cellular immunity in its evolution. Am J Dermatopathol 12:517–533, 1990.

Mandrell JC, Santa Cruz D: Keratoacanthoma: hyperplasia, benign neoplasm, or a type of squamous cell carcinoma? Semin Diagn Pathol 26:150–163, 2009.

Randall MB, Geisinger RR, Kute TE et al: DNA content and proliferative index in cutaneous squamous cell carcinoma and keratoacanthoma. Am J Clin Pathol 93:159–262, 1990.

Slater M, Barden JA: Differentiating keratoacanthoma from squamous cell carcinoma by the use of apoptotic and cell adhesion markers. Histopathology 47:170–178, 2005.

Street ML, White JW, Gibson LE: Multiple keratoacanthomas treated with oral retinoids. J Am Acad Dermatol 23:862–866, 1990.

Tsuji T: Keratoacanthoma and squamous cell carcinoma: study of PCNA and Le(Y) expression. J Cutan Pathol 7:409–415, 1997.

Verrucous Carcinoma

Cabay RJ, Morton TH, Epstein JB: Proliferative verrucous leukoplakia and its progression to oral carcinoma: a review of the literature. J Oral Pathol Med 36:255–261, 2007.

Chang KC, Su IJ, Tsai ST et al: Pathological features of betel quid-related oral epithelial lesions in Taiwan with special emphasis on the tumor progression and human papillomavirus association. Oncology 63:362–369, 2002.

Gandolfo S, Castellani R, Pentenero M: Proliferative verrucous leukoplakia: a potentially malignant disorder involving periodontal sites. J Periodontol 80:274–281, 2009.

Ghazali N, Bakri MM, Zain RB: Aggressive, multifocal oral verrucous leukoplakia: proliferative verrucous leukoplakia or not? J Oral Pathol Med 32:383–392, 2003.

Impola U, Uitto VJ, Hietanen J et al: Differential expression of matrilysin-l (MMP-7), 92 kD gelatinase (MMP-9), and metalloelastase (MMP-12) in oral verrucous and squamous cell cancer. J Pathol 202:14–22, 2004.

Mork J, Lie AK, Glattre E et al: Human papillomavirus infection as a risk factor for squamous cell carcinoma of the head and neck. N Engl J Med 344:1125–1131, 2001.

Palefsky JM, Silverman S, Abdel-Salaam M et al: Association between proliferative verrucous leukoplakia and infection with human papillomavirus type 16. J Oral Pathol Med 24:193–197, 1995.

Spiro RH: Verrucous carcinoma, then and now. Am J Surg 176: 393–397, 1998.

Vidyasagar MS, Fernandes DJ, Kasturi P et al: Radiotherapy and verrucous carcinoma of the oral cavity. Acta Oncol 31:43–47, 1992.

Pyostomatitis Vegetans

Healy CM, Farthing PM, Williams DM et al: Pyostomatitis vegetans and associated systemic disease. Oral Surg Oral Med Oral Pathol 78:323–328, 1994.

Hegarty AM, Barrett AW, Scully C: Pyostomatitis vegetans. Clin Exp Dermatol 29:1–7, 2004.

Thornhill M, Zakrzawska J, Gilkes J: Pyostomatitis vegetans: report of 3 cases and review of the literature. J Oral Pathol Med 21: 128–133, 1992.

Verruciform Xanthoma

Olivera PT, Jaeger RG, Cabral LAG et al: Verruciform xanthoma of the oral mucosa: report of four cases and a review of the literature. Oral Oncol 37:326–331, 2001.

CHAPTER 7



Connective Tissue Lesions

FIBROUS LESIONS

REACTIVE HYPERPLASIAS
Peripheral Fibroma
Focal Fibrous Hyperplasia
Denture-Induced Fibrous Hyperplasia
Generalized Gingival Hyperplasia
NEOPLASMS
Solitary Fibrous Tumor
Giant Cell Angiofibroma
Myxoma
Nasopharyngeal Angiofibroma
Nodular Fasciitis
Myofibroblastic Tumors
Fibromatosis
Fibrosarcoma
Synovial Sarcoma
FIBROHISTIOCYTIC TUMORS
Benign Fibrous Histiocytoma
Malignant Fibrous Histiocytoma (Pleomorphic Sarcoma)

VASCULAR LESIONS

REACTIVE LESIONS AND CONGENITAL LESIONS
Lymphangioma
NEOPLASMS
Hemangiopericytoma
Angiosarcoma

NEURAL LESIONS

REACTIVE LESIONS
Traumatic Neuroma
NEOPLASMS
Granular Cell Tumors
Schwannoma
Neurofibroma
Mucosal Neuroma of Multiple Endocrine Neoplasia Syndrome Type III
Palisaded Encapsulated Neuroma (Solitary Circumscribed Neuroma)
Malignant Peripheral Nerve Sheath Tumor
Olfactory Neuroblastoma

MUSCLE LESIONS

REACTIVE LESIONS
Myositis Ossificans
NEOPLASMS
Leiomyoma and Leiomyosarcoma
Rhabdomyoma and Rhabdomyosarcoma

FAT LESIONS

Lipoma
Liposarcoma

Connective tissue lesions comprise a large and diverse number of entities ranging from reactive conditions to neoplasms. Reactive conditions are derived from mesenchymal cells and are represented by fibrous hyperplasias or exuberant proliferations of granulation tissue. Tumors of connective tissue elements are heterogeneous and form a complex collection of diseases. Prediction of biological behavior from histology alone is problematic and is reflected in the difficulties in grading individual tumors. Traditionally, tumors of connective tissues have been classified on a model of presumed histogenetic lineage. Hence neoplasms are subdivided into tumors of fibrous, fibrohistiocytic, myofibroblastic, vascular, neural, muscular, adipose, and other types of tissue. Increasingly, it is becoming evident that many tumors do not arise from their mature, differentiated counterparts, because soft tissue tumors can arise in sites that are devoid of their mature tissue counterpart. For example, liposarcomas often arise at sites where no adipose tissue is present, and rhabdomyosarcomas often arise at sites that contain no striated muscle. It is likely that soft tissue tumors arise from primitive progenitor cells that can develop along any differentiation pathway, which is dictated by the expression of specific differentiation genes. However, for the purposes of describing these entities, a histogenetic classification has been maintained here.

FIBROUS LESIONS

REACTIVE HYPERPLASIAS

Reactive hyperplasias comprise a group of fibrous connective tissue lesions that commonly occur in oral mucosa secondary to injury. They represent a chronic process in which exuberant repair (granulation tissue and scar) follows injury. As a group, these conditions present as submucosal masses that may become secondarily ulcerated when traumatized during mastication. Their color ranges from lighter than the surrounding tissue (because of a relative increase in collagen) to red (because of an abundance of well-vascularized granulation tissue). Because nerve tissue does not proliferate with reactive hyperplastic tissue, these lesions are painless. The reason for the exuberant repair is unknown. Treatment generally consists of surgical excision and removal of the irritating factor(s).

Although these lesions are all pathogenically related, different names or subdivisions have been devised because of variations in the anatomic site, clinical appearance, or microscopic picture. Those lesions that present as prominent red masses are discussed in Chapter 4.

Peripheral Fibroma

Clinical Features. By definition, peripheral fibroma is a reactive hyperplastic mass that occurs on the gingiva and is believed to be derived from connective tissue of the submucosa or periodontal ligament (Figure 7-1). It may occur at any age, although it does have a predilection for young adults. Females develop these lesions more commonly than do males, and the gingiva anterior to the permanent molars is most often affected.



■ **FIGURE 7-1 Peripheral fibroma** of maxillary attached gingiva. (From Regezi JA, Sciubba JJ, Pogrel MA: Atlas of Oral and Maxillofacial Pathology. Philadelphia, 2000, WB Saunders, Figure 4-31.)

Peripheral fibroma may present clinically as a stalked (pedunculated) or a broad-based (sessile) mass that is similar in color to surrounding connective tissue. Ulceration may be noted over the summit of the lesion. It rarely causes erosion of subjacent alveolar bone.

Histopathology. Peripheral fibroma is a form of fibrous hyperplasia that may also be called *hyperplastic scar.* It is highly collagenous and relatively avascular, and it may contain a mild to moderate chronic inflammatory cell infiltrate. This lesion is basically the gingival counterpart to traumatic fibroma occurring in other mucosal regions.

Microscopically, several subtypes of this lesion have been identified. These are essentially of academic interest because the biological behavior and treatment of these microscopic variants are the same.

Peripheral ossifying fibroma is a gingival mass in which islands of woven (immature) bone and osteoid are seen. The bone is found within a lobular proliferation of plump, benign fibroblasts. Chronic inflammatory cells tend to be seen around the periphery of the lesion (Figure 7-2). The surface is typically ulcerated.

Peripheral odontogenic fibroma is a gingival mass composed of well-vascularized, nonencapsulated fibrous connective tissue. The distinguishing feature of this variant is the presence of strands of odontogenic epithelium, often abundant, throughout the connective tissue. Amorphous hard tissue resembling tertiary (reactive) dentin, so-called dentinoid, may also be present. The lesion is usually nonulcerated.

Giant cell fibroma is a fibrous hyperplasia in which many of the mesenchymal cells are relatively larger than normal

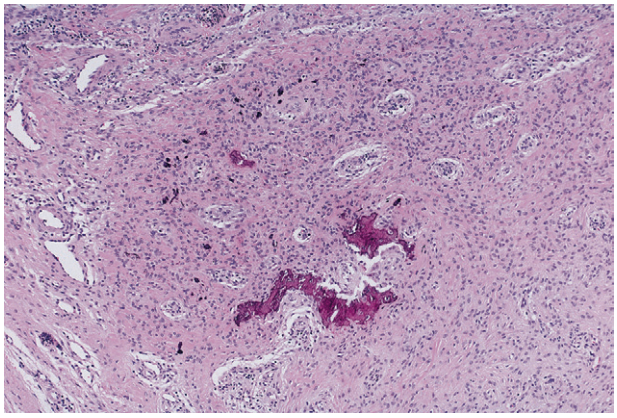

■ **FIGURE 7-2 Peripheral ossifying fibroma.** Note cellular fibroblastic proliferation with islands of new bone.

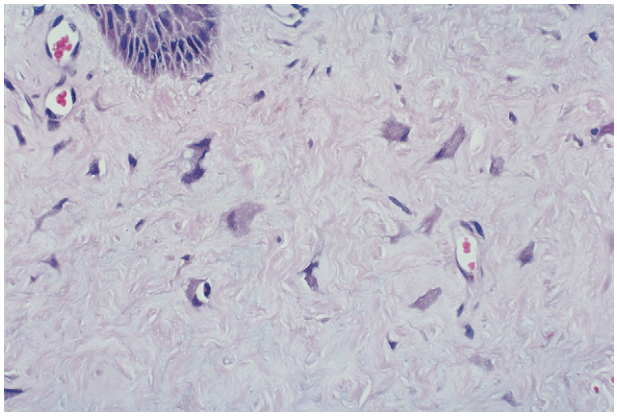

■ **FIGURE 7-3 Peripheral fibroma** with stellate-shaped fibroblasts.

fibroblasts (giant cells) and assume a stellate shape. Immunohistochemical studies have shown that most of these stellate cells are fibroblasts (a few factor XIIIa–positive dendritic cells are also typically present) (Figure 7-3). These same peculiar stellate cells can be found in focal fibrous hyperplastic lesions throughout the oral mucosa and occasionally on the skin (fibrous papule). One form of this lesion is known as *retrocuspid papilla* of the mandible.

Differential Diagnosis. Clinically, these lesions usually are not confused with anything else. However, some overlap may be noted with pyogenic granuloma and, rarely, peripheral giant cell granuloma, when these two lesions do not have a prominent vascular component.

Treatment. Peripheral fibroma should be treated by local excision, which should include the periodontal ligament, if involved. Also, any identifiable etiologic agent, such as calculus or other foreign material, should be removed. Recurrence may occasionally be associated with the microscopic subtype—peripheral ossifying fibroma. Re-excision to the periosteum or the periodontal ligament should prevent further recurrence.



■ **FIGURE 7-4 Focal fibrous hyperplasia,** buccal mucosa.

BOX 7-1 ORAL FIBROUS HYPERPLASIA: SYNONYMS

Traumatic fibroma
Irritation fibroma
Hyperplastic scar
Inflammatory fibrous hyperplasia
Peripheral fibroma of gingiva
Fibrous epulis of gingiva
Denture (-induced fibrous) hyperplasia
Epulis fissuratum (denture-induced)

Focal Fibrous Hyperplasia

Etiology. Focal fibrous hyperplasia is a reactive lesion usually caused by chronic trauma to oral mucous membranes. Overexuberant fibrous connective tissue repair results in a clinically evident submucosal mass. Although the terms *traumatic fibroma* and *oral fibroma* are often applied to these entities, they are misnomers because these lesions are not benign tumors of fibroblasts, as the term *fibroma* implies (Box 7-1).

Clinical Features. No gender or racial predilection for the development of this intraoral lesion has been noted. It is a very common reactive hyperplasia that is typically found in frequently traumatized areas, such as the buccal mucosa, the lateral border of the tongue, and the lower lip (Figure 7-4). It is a painless, broad-based swelling that is paler in color than the surrounding tissue because of its relative lack of vascular channels. The surface may occasionally be traumatically ulcerated, particularly in larger lesions. Lesions have limited growth potential and do not exceed 1 to 2 cm in diameter.

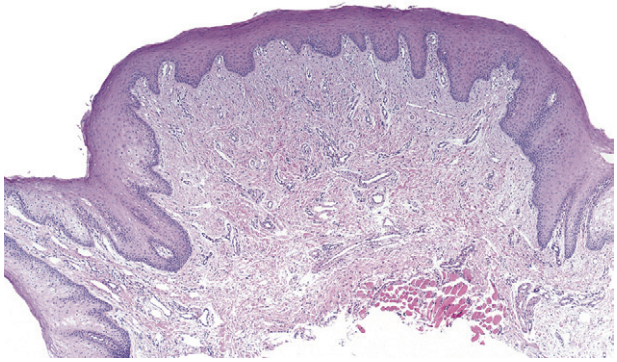

■ **FIGURE 7-5** Focal fibrous hyperplasia.

Multiple fibromas may be part of a rare autosomal-dominant syndrome known as *Cowden's syndrome* or *multiple hamartoma syndrome.* Many organ systems, such as the mucosa, skin, breast, thyroid, and colon, may be affected. Frequently encountered abnormalities include numerous oral fibromas and papillomas; cutaneous papules, keratoses, and trichilemmomas; benign and malignant neoplasms of the breast and thyroid; and colonic polyps. The underlying genetic problem appears to be related to germline mutations of the tumor suppressor gene *PTEN* found on chromosome 10q23.

Histopathology. Collagen overproduction is the basic process that dominates the microscopy of this lesion. Fibroblasts are mature and widely scattered in a dense collagen matrix. Sparse chronic inflammatory cells may be seen, usually in a perivascular distribution (Figure 7-5). Overlying epithelium is often hyperkeratotic because of chronic low-grade friction.

Differential Diagnosis. This is a relatively trivial lesion that should be removed to rule out other pathologic processes. Depending on its location, several other entities might be included in a clinical differential diagnosis. Neurofibroma, Schwannoma, and granular cell tumor would be possibilities for masses in the tongue. In the lower lip and buccal mucosa, lipoma, mucocele, and salivary gland tumors might be considered. Although rare, benign neoplasms of mesenchymal origin could present as submucosal masses not unlike focal fibrous hyperplasia.

Treatment. Simple surgical excision is usually effective. Infrequently, recurrence may be caused by continued trauma to the involved area. These lesions have no malignant potential.

Denture-Induced Fibrous Hyperplasia

Etiology. Denture-induced fibrous hyperplasia of oral mucosa is related to the chronic trauma produced by an ill-fitting denture. The process is essentially the same as the one that leads to traumatic fibroma, except that a denture is specifically identified as the causative agent. This lesion has also been referred to by several older synonyms including *inflammatory hyperplasia, denture hyperplasia,* and *epulis fissuratum.*

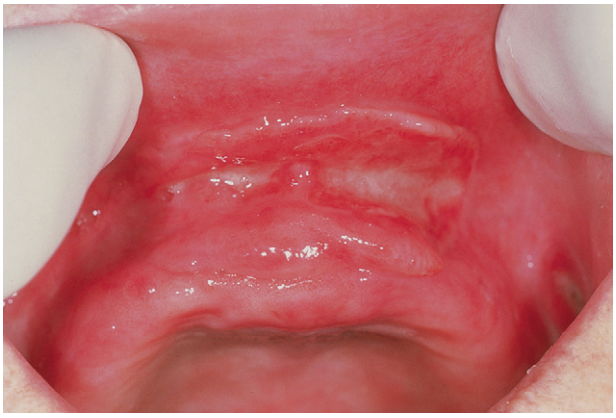

■ **FIGURE 7-6** Denture-induced fibrous hyperplasia.

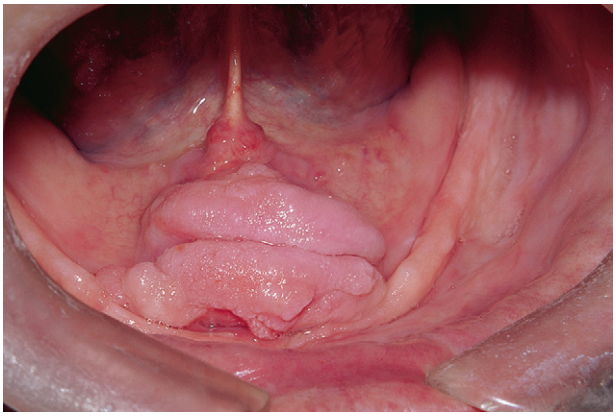

■ **FIGURE 7-7** Denture-induced fibrous hyperplasia.

Clinical Features. Denture-induced fibrous hyperplasia is a common lesion that occurs in the vestibular mucosa and less commonly along the mandibular lingual sulcus where the denture flange contacts tissue (Figures 7-6 and 7-7). As the bony ridges of the mandible and the maxilla resorb with long-term denture use, the flanges gradually extend farther into the vestibule. There, chronic irritation and trauma may incite an overexuberant fibrous connective tissue reparative response. The result is the appearance of painless folds of fibrous tissue surrounding the overextended denture flange.

Treatment. Some reduction in size of the lesion may follow prolonged removal of the denture. However, because the hyperplastic scar is relatively permanent, surgical excision is usually required. Construction of a new denture or relining of the old one is also required to prevent recurrence.

BOX 7-2 GINGIVAL HYPERPLASIA: CAUSES/MODIFIERS

Local factors: plaque, calculus, bacteria
Hormonal imbalance: estrogen, testosterone
Drugs: phenytoin (Dilantin); cyclosporine; nifedipine and other calcium channel blockers
Leukemia (due to leukemic infiltrates and/or local factors)
Genetic factors/syndromes

Generalized Gingival Hyperplasia

Etiology. In generalized gingival hyperplasia, overgrowth of the gingiva may vary from mild enlargement of the interdental papillae to such severe uniform enlargement that the crowns of the teeth may be covered by hyperplastic tissue (Box 7-2). Uniform or generalized gingival fibrous connective tissue hyperplasia may be due to one of several etiologic factors. Most cases are nonspecific and are the result of an unusual hyperplastic tissue response to chronic inflammation associated with local factors such as plaque, calculus, or bacteria. Why only some patients have a propensity for the development of connective tissue hyperplasia in response to local factors is unknown. Recent studies have reported a possible role for keratinocyte growth factor (a member of the fibroblast growth factor family) in this condition.

Other conditions such as hormonal changes and drugs can significantly potentiate or exaggerate the effects of local factors on gingival connective tissue. Hormonal changes that occur during pregnancy and puberty have long been known to be associated with generalized gingival hyperplasia. This hyperresponsiveness during pregnancy has led to the infrequently used and inappropriate term *pregnancy gingivitis.* Altered hormonal conditions act in concert with local irritants to produce the hyperplastic response. It is questionable whether significant gingival enlargement during periods of hormonal imbalance would occur in individuals with scrupulous oral hygiene.

Phenytoin (Dilantin), a drug used in the control of seizure disorders, is a well-known etiologic factor in generalized gingival enlargement. It is thought that phenytoin causes impaired collagen degradation through suppression of matrix metalloproteinases (MMPs)/tissue inhibitor of metalloproteinase-1 (TIMP-1) and $\alpha 2\beta 1$-integrin–mediated endocytosis. The extent or severity of so-called *Dilantin hyperplasia* is dependent on the presence of local factors such as plaque and calculus. The effects of time and dose of the drug on gingival tissue are not clear. Reported prevalence has ranged from 0% to 80%, depending on the investigator's clinical criteria and the number of patients observed. A value of 50% is generally accepted as the probable prevalence. In any event, the fact that not all patients taking phenytoin develop gingival hyperplasia indicates that some patients are predisposed to the development of this condition. It has only rarely been described in edentulous patients and in children before tooth eruption.

Cyclosporine, the immunosuppressant drug that is used to modulate T-lymphocyte function in transplant recipients and in patients with various autoimmune diseases, has also been linked to fibrous hyperplasia of the gingiva. The cause of this condition is not known, but edema secondary to increased sulfated-glycosaminoglycan synthesis by fibroblasts may play an important role. Not all patients are affected (10% to 70%), and local factors have a synergistic role. Unlike phenytoin-related hyperplasia, cyclosporine-induced hyperplasia has been reported to be a reversible process following cessation of drug use.

Nifedipine and other calcium channel blockers used in the treatment of cardiac angina, arrhythmias, and hypertension are known to contribute to gingival hyperplasia. The process mimics phenytoin-related hyperplasia but, similar to cyclosporine-induced gingival hyperplasia, appears to be reversible.

Gingival enlargement is also known to occur in patients with leukemia, especially those with the chronic monocytic form. This is believed to be a result of infiltration of the gingival soft tissues by malignant white blood cells. It may be modulated by local factors such as plaque and calculus; because of the bleeding tendency associated with leukemia, patients may be unable or reluctant to practice correct oral hygiene, resulting in the accumulation of plaque and debris. This accumulation may provide the inflammatory stimulus for connective tissue hyperplasia.

Some rare types of gingival hyperplasia that occur in early childhood have a hereditary basis. The best recognized is hereditary gingival fibromatosis, which clinically can resemble Dilantin-induced gingival hyperplasia. Patients with other rare syndromes such as Zimmerman-Laband, Cross', Rutherfurd's, Murray-Puretic-Drescher (juvenile hyaline fibromatosis), and Cowden's syndromes can develop varying degrees of fibrous gingival hyperplasia.

Clinical Features. The clinical feature common to the variously caused gingival hyperplasias is an increase in bulk of the free and attached gingiva, especially the interdental papillae (Figures 7-8 to 7-10). Stippling is lost, and gingival margins become rolled and blunted. The consistency of the gingiva ranges from soft and spongy to firm and dense, depending directly on the density and amount of fibrosis. A range of color from red-blue to lighter than surrounding tissue is also seen; this varies with the severity of the inflammatory response as well. Generally, hyperplasias associated with nonspecific local factors and hormonal changes appear more inflamed clinically than drug-induced and idiopathic forms. The idiopathic type is particularly dense and fibrous, with relatively little inflammatory change.

Histopathology. An abundance of collagen is noted. Fibroblasts are increased in number, and various degrees of chronic inflammation are seen. In some cases, especially



■ **FIGURE 7-8 Generalized gingival hyperplasia** associated with local factors and hormonal changes.



■ **FIGURE 7-9 Generalized gingival hyperplasia** associated with phenytoin therapy for seizures.



■ **FIGURE 7-10 Generalized gingival hyperplasia** associated with chronic monocytic leukemia.

those in which hormonal changes are important, capillaries may be increased and prominent. The overlying epithelium usually exhibits some hyperplasia. Occasionally, plasma cells dominate the histologic picture. In leukemic enlargements, atypical and immature white blood cells, representing a malignant infiltrate, may be found.

BOX 7-3 ORAL FIBROBLASTIC PROLIFERATIONS

Fibrous hyperplasia: very common oral lesion
Solitary fibrous tumor: uncommon to rare tumor
Nodular fasciitis: rare oral tumor
Myofibroma: uncommon to rare tumor
Fibromatosis: rare oral tumor
Fibrosarcoma: rare oral tumor
Fibrous histiocytoma
  Benign: uncommon to rare oral tumor
  Malignant: rare oral tumor

BOX 7-4 ORAL SOLITARY FIBROUS TUMOR

Oral counterpart of pleural solitary fibrous tumor
Benign spindle cell proliferation: fibroblastic origin
Buccal mucosa commonly affected
Immunochemistry: positive for CD34, CD99, and Bcl-2
Circumscribed
Treatment by excision; no recurrence

Treatment. In all forms of generalized gingival hyperplasia, attentive oral hygiene is necessary to minimize the effects of inflammation on fibrous proliferation and the effects of systemic factors. Gingivoplasty or gingivectomy may be required but should be done in combination with prophylaxis, oral hygiene instruction, and a comprehensive home care program.

NEOPLASMS

Solitary Fibrous Tumor

Solitary fibrous tumor is a benign proliferation of spindle cells of disputed but probable fibroblastic origin (Box 7-3). This lesion was first described as a tumor of the pleura and has subsequently been described at many other sites. Oral lesions are seen in adults and present as submucosal masses predominantly in the buccal mucosa (Box 7-4).

Microscopically, lesions are circumscribed and are composed of a "patternless" proliferation of spindle cells (Figure 7-11). Some areas may suggest neurofibroma or Schwannoma, whereas others may suggest hemangiopericytoma or leiomyoma. Tumor cells characteristically stain positive for CD34 (90% to 95% of cases), CD99 (70%), and Bcl-2 (20% to 35%) by immunohistochemistry. Many factor XIIIa–positive cells may be found. Immunohistochemistry has permitted a better understanding of this entity and more reliable identification; therefore many oral tumors previously diagnosed by light microscopy as other soft tissue neoplasms such as leiomyoma, hemangiopericytoma, and

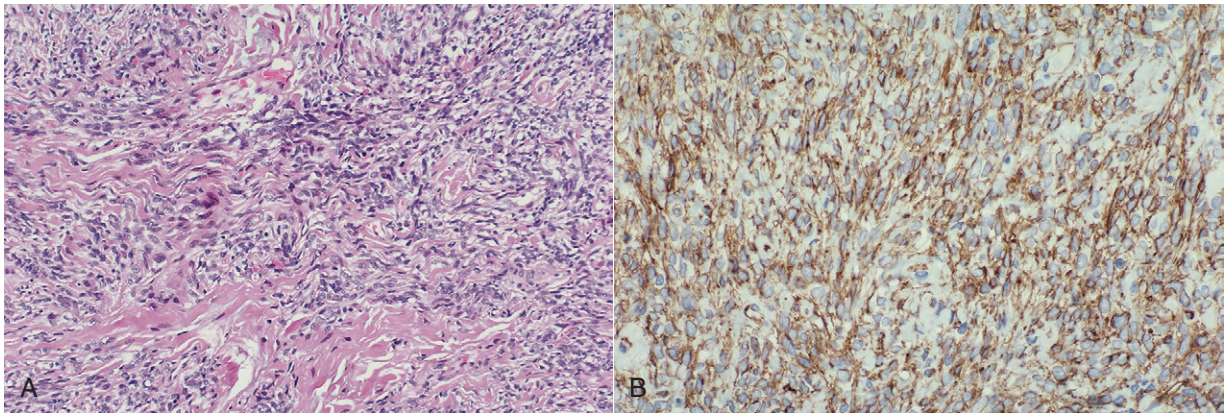

■ **FIGURE 7-11 Solitary fibrous tumor. A,** Haphazard spindle cell proliferation. **B,** Immunohistochemical stain for CD34 showing positive cytoplasmic staining *(brown)* of tumor cells.

TABLE 7-1 MUCOSAL MYXOID LESIONS: MICROSCOPIC DIFFERENTIATION

	Mast Cells	Reticulin	Pattern	Periphery
Soft tissue myxoma	No	Yes	Diffuse, uniform	Blending, infiltration
Nerve sheath myxoma	Yes	Yes	Lobular	Condensed fibrous tissue
Focal mucinosis	No	No	Uniform	Circumscribed

benign fibrous histiocytoma probably represent solitary fibrous tumor.

Treatment consists of surgical excision. Although most cases are benign, the behavior of solitary fibrous tumors is unpredictable. Approximately 10% to 15% behave aggressively, warranting long-term follow-up. It is important to note that correlation between histologic features and overall behavior is poor.

Giant Cell Angiofibroma

Clinical Features. Giant cell angiofibroma is a rare soft tissue tumor that was first described in the orbit. Since then, several case reports have described this tumor at various extraorbital sites, including the submandibular region, the parascapular area, and the posterior mediastinum. The condition is also reported to occur in the oral cavity. Currently, the giant cell angiofibroma is thought to be a variant of the solitary fibrous tumor. The condition presents as a slow-growing nodule or mass with normal overlying mucosa. It behaves in a benign fashion with only rare local recurrences and no tendency to metastasize.

Histopathology. Microscopically, giant cell angiofibroma shows noninfiltrative growth of patternless round to spindle cells in a stroma composed of collagen fibers or occasionally myxoid material with irregular pseudovascular spaces. The giant cells are interspersed among the spindle cells and partially line the walls of the pseudovascular spaces. These cells are multinucleated floret-type giant cells with nuclei located at the periphery of the cell. Immunohistochemically, the spindle and giant cells are positive for estrogen, progesterone, vimentin, and CD34, confirming the relationship to solitary fibrous tumor.

Treatment. This condition is benign, and local excision is curative.

Myxoma

Clinical Features. Myxoma is a soft tissue neoplasm composed of gelatinous material that has a myxoid histologic appearance. The oral form of soft tissue myxoma is a rare lesion that presents as a slow-growing, asymptomatic submucosal mass, usually in the palate. No gender predilection has been noted, and the lesion may occur at any age. Oral soft tissue myxomas have been reported in an autosomal-dominantly inherited syndrome consisting of myxomas (including cardiac myxomas), mucocutaneous pigmentation, and endocrine abnormalities.

Histopathology. Oral myxomas are not encapsulated and may exhibit infiltration into surrounding soft tissue. Dispersed stellate and spindle-shaped fibroblasts are found in a loose myxoid stroma. Soft tissue myxomas may be confused with other myxoid lesions, such as nerve sheath myxoma and oral focal mucinosis (Table 7-1).

Nerve sheath myxoma arises from the endoneurium of a peripheral nerve. This lesion typically exhibits lobulated mucoid tissue containing stellate and spindle-shaped cells.

Condensed connective tissue, representing perineurium, surrounds the lesion. With special stains, a fine reticulin network is seen throughout. Mast cells are characteristically present in this lesion and neural markers such as S-100 are expressed by the tumor.

Oral focal mucinosis represents the mucosal counterpart of cutaneous focal mucinosis. The lesion appears as a well-circumscribed area of myxomatous connective tissue in the submucosa. It contains no mast cells and no reticulin network, except that which surrounds supporting blood vessels. Unlike the nerve sheath myxoma, neural markers such as S-100 are negative.

Treatment. The treatment of choice for oral soft tissue myxoma, as well as other myxoid lesions, is surgical excision. Recurrence is not uncommon for myxomas but is unexpected for nerve sheath myxoma and focal mucinosis. All are benign processes and require conservative therapy only.

Nasopharyngeal Angiofibroma

Clinical Features. Nasopharyngeal angiofibroma is also known as *juvenile nasopharyngeal angiofibroma* because of its almost exclusive occurrence in the second decade of life. For this uncommon to rare neoplasm that nearly always affects boys, it is thought that sex hormones variably play a role in its pathogenesis, with expression of androgen, testosterone, and dihydrotestosterone receptors. This lesion characteristically produces a mass in the nasopharynx that arises along the posterolateral wall of the nasal roof and over time leads to obstruction or epistaxis that may, on occasion, be severe. Rarely, this lesion may present intraorally, causing palatal expansion or inferior displacement of the soft palate, which appears blue because of the intense vascularity of the lesion. It generally can be described as benign and slow-growing but unencapsulated and locally invasive. On occasion, it may exhibit aggressive clinical behavior, characterized by direct extension into the bones of the midface and the skull base. The symptom triad includes recurrent epistaxis, nasal obstruction, and mass effect within the nasopharynx.

Histopathology. Microscopically, nasopharyngeal angiofibroma has the appearance of a mature, well-collagenized lesion containing cleftlike vascular channels. The evenly spaced fibroblasts have a uniform, benign appearance with plump nuclei. The vascular channels vary in size and are lined by endothelium that may occasionally be rimmed by smooth muscle cells.

Treatment. Although numerous forms of treatment, such as radiation, exogenous hormone administration, sclerosant therapy, and embolization, have been used for nasopharyngeal angiofibroma, surgery remains the preferred form of therapy. Recurrences are common (up to 50% of cases) and are due to incomplete excision, the invasive nature of the lesion, and the surgically difficult anatomic location.

Nodular Fasciitis

Clinical Features. Nodular fasciitis, also known as *pseudosarcomatous fasciitis,* is a well-recognized entity representing a myofibroblastic proliferation. A closely related lesion known as *proliferative myositis* occurs in muscle. The cause of this proliferation is unknown. Although some patients with nodular fasciitis report a history of trauma at the site of the lesion, most patients do not. Traditionally considered a reactive condition, recent molecular evidence indicates that, at least in some cases, the cells in nodular fasciitis are clonal, suggesting a benign neoplasm. Expression analysis has shown that the proliferating cells in nodular fasciitis produce several molecules involved in inflammation and cytokine signaling. The condition typically presents as a firm mass in the dermis or the submucosa and exhibits such rapid growth clinically that malignancy may be suspected. Pain or tenderness often accompany the process. No gender predilection has been noted, and young adults and adults are usually affected. The trunk and the extremities are most commonly involved, with about 10% of cases reported to occur in the head and neck, usually in the skin of the face and the parotid sheath. Intraorally, the buccal mucosa is the most commonly affected site. All of these lesions are benign, and they often are managed by excision to remove the growing mass and to confirm the diagnosis. Ultimately if left untreated, regression will occur.

Histopathology. A nodular growth contains plump spindle cells with vesicular nuclei in a haphazard to storiform arrangement (Figure 7-12). Myxoid areas are usually found. Multinucleated giant cells are occasionally present and may originate from adjacent muscle or from fusion of macrophages. Mitotic figures may be frequent but are morphologically normal in appearance. Inflammatory cells and extravasated red blood cells are also microscopic features of nodular fasciitis. By immunohistochemistry, the cells in nodular fasciitis express smooth muscle and muscle-specific actins consistent with a myofibroblastic phenotype.

Proliferative myositis, an analogous lesion that occurs within muscle, is a reactive lesion that occurs usually in the trunk and rarely in the head and neck (sternomastoid muscle). It parallels the clinical course of nodular fasciitis, although it first appears in an older age group.

Differential Diagnosis. Diagnostic problems relative to nodular fasciitis occur because many of its microscopic features are shared by other fibrous proliferations, such as fibromatosis, benign fibrous histiocytoma, and fibrosarcoma (Table 7-2). Fibromatosis is more infiltrative than nodular fasciitis and may exhibit a fascicular growth pattern. It also produces more collagen, is generally less cellular, and has fewer mitotic figures. In addition, beta-catenin expression is seen in fibromatosis but not in nodular fasciitis. A benign fibrous histiocytoma is rare in the mouth and is histologically more cellular with a storiform pattern; it may not be as

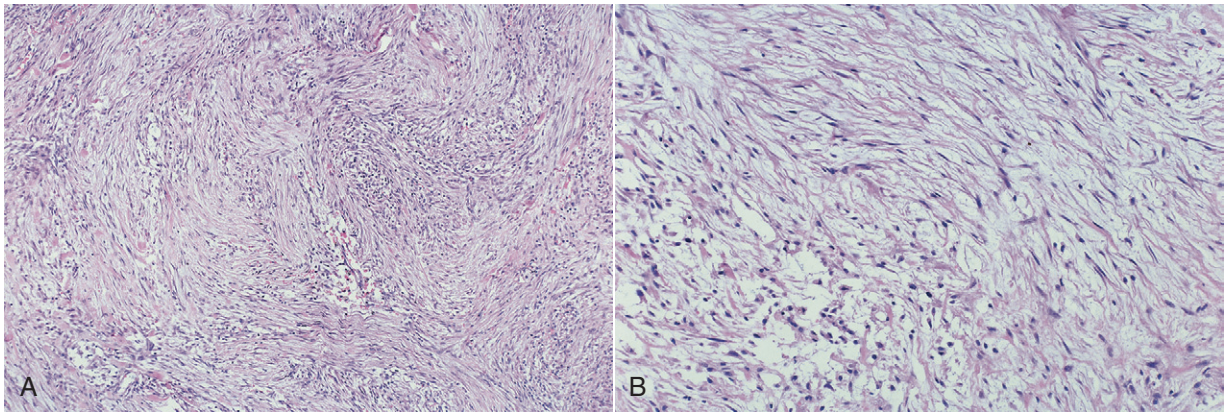

■ **FIGURE 7-12 Nodular fasciitis. A** and **B,** Lobular or nodular pattern with foci of lymphocytes.

TABLE 7-2 NODULAR FASCIITIS, FIBROUS HISTIOCYTOMA, FIBROMATOSIS

	Nodular Fasciitis	Fibrous Histiocytoma	Fibromatosis
Tumor type	Reactive	Benign	Benign, aggressive
Age	Young adults, adults	Adults	Children, young adults
Symptoms	Often	Infrequently	Infrequently
Sites	Trunk, extremities Head and neck 10%	Skin, mucosa	Shoulder, trunk Head and neck 10%
Growth rate	Rapid	Slow	Moderate
Periphery	Nodular	Circumscribed	Infiltrative
Recurrence	Rarely	Uncommon	Common
Treatment	Excision	Excision	Aggressive surgery

well circumscribed as nodular fasciitis. Fibrosarcoma is infiltrative and exhibits a herringbone pattern. Nuclei are pleomorphic and hyperchromatic, and mitoses are more abundant and atypical. By immunohistochemistry, the cells of nodular fasciitis express smooth muscle actin but not desmin. Some have described variable expression of CD68 antigen.

Treatment. Conservative surgical excision is the treatment of choice for nodular fasciitis. Local recurrence occurs in only 2% of cases, and in these instances, the diagnosis should be re-evaluated.

Myofibroblastic Tumors

Clinical Features. Myofibromatosis and myofibromas represent benign proliferations of myofibroblasts. Myofibromatosis is multifocal and occurs in infants; myofibroma is solitary and occurs over a wide age range. These lesions can appear at a variety of sites in the body but have a predilection for the head and neck, in particular, the oral cavity. They can occur in soft tissues or in bone and present as slow-growing, circumscribed masses.

Histopathology. Tumors show pushing, well-demarcated borders. Paucicellular lobules with hyalinized or collagenous stroma alternate with cellular zones, giving a hemangiopericytoma-like appearance. Tumor cells are generally uniform, showing tapered nuclei, and express smooth muscle actin. They are negative for desmin, CD34, and S-100 but positive for smooth muscle antigens, including actin and calponin (Figure 7-13). Lack of expression of desmin helps differentiate this tumor from leiomyoma and leiomyosarcoma, which are rare in the oral cavity.

Treatment. Myofibromas are benign, and local excision is generally curative. However, local recurrences are occasionally seen (<10%). Multiple lesions appearing in myofibromatosis likely do not represent recurrence or metastasis but multifocal disease.

Fibromatosis

Fibromatosis comprises a group of locally aggressive neoplasms that show infiltrative, destructive, and recurrent growth but no tendency to metastasize. They are classified as superficial (palmar, plantar) or deep (desmoid). Superficial fibromatoses do not occur in the oral cavity. Deep fibromatoses are clinically diverse, deep-seated, fibrous proliferations. Three types have been identified: sporadic, familial adenomatous polyposis (FAP) associated, and multicentric (familial). They can be further classified anatomically as extra-abdominal (60% of cases), abdominal wall (25% of cases), or intra-abdominal (15% of cases). Only

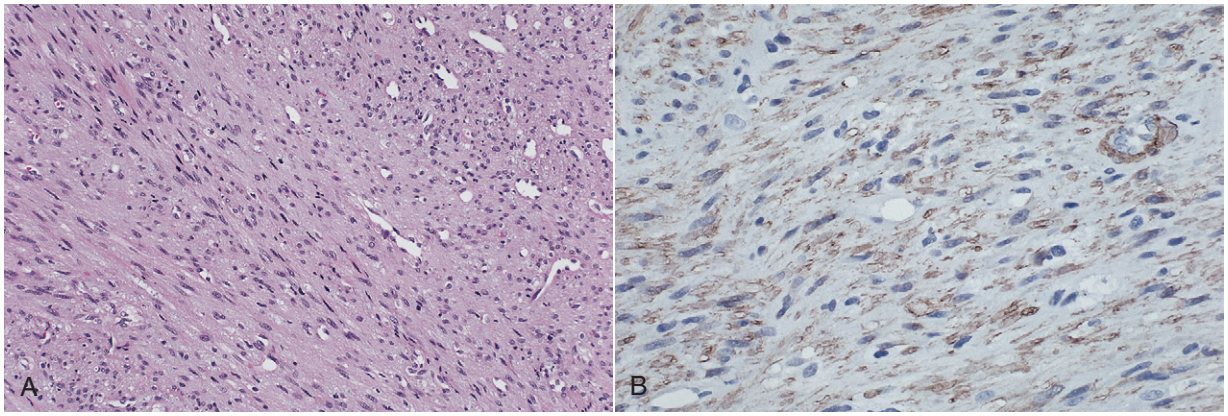

■ **FIGURE 7-13 A, Myofibroma** composed of fascicles of spindle cells. **B,** Positive *(brown)* immunohistochemical stain for smooth muscle actin; stain for desmin was negative.

extra-abdominal desmoid fibromatoses occur in the head and neck. Although traditionally thought to be reactive lesions, cytogenetic and X-inactivation studies have shown clonality; thus fibromatoses are thought to be benign neoplasms.

Clinical Features. All extra-abdominal desmoids are locally infiltrative lesions that have significant recurrence potential. Lesions typically present as firm asymptomatic masses. They are typically seen in children and young adults, with females affected twice as often as males. The most common site is the shoulder area and trunk, with about 10% of cases appearing in the soft tissues of the head and neck. The mandible and contiguous soft tissues are most often involved intraorally. Lesions are slower growing than those of nodular fasciitis and are less likely to be symptomatic.

Histopathology. Fibromatosis is a nonencapsulated infiltrative lesion with a fascicular growth pattern (Figure 7-14). The lesion is composed of highly differentiated connective tissue containing uniform, compact fibroblasts, often surrounded by abundant collagen. Nuclei are not atypical, and mitotic figures are infrequent. When muscle invasion occurs, giant cells representing degenerate muscle cells may be seen. Slitlike vascular spaces are usually seen as well. Overall, the bland microscopic appearance of this lesion belies its locally aggressive behavior. By immunohistochemistry, actin, desmin, and S-100 are negative, although some cases may show patchy expression. Expression of beta-catenin in the nuclei of tumor cells may be helpful in establishing the diagnosis of fibromatosis. In contrast to fibrosarcoma, fibromatoses lack alterations of *Bcl-2, RB1,* and *p53.*

Treatment. Recurrence rates in the range of 20% to 60% have been reported for fibromatosis. Because of this, and because of the locally destructive nature of fibromatosis, an aggressive surgical approach is recommended. No metastatic potential has been reported, although some cases, particularly in the head and neck, have proved fatal.

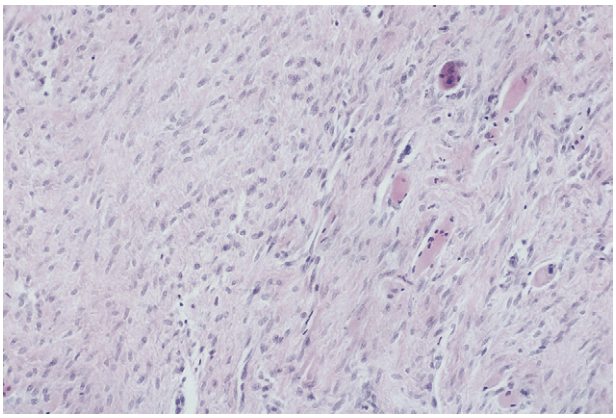

■ **FIGURE 7-14 Fibromatosis** appearing as deceptively bland fibroblastic proliferation. Note residual skeletal muscle *(right)* surrounded by invasive tumor.

Fibrosarcoma

At one time, fibrosarcoma was the most common soft tissue sarcoma. With the introduction of electron microscopy and immunohistochemistry, it became evident that many previously diagnosed fibrosarcomas represented a range of spindle cell malignancies. Today, *fibrosarcoma* is defined as a malignant spindle cell tumor showing a herringbone or interlacing fascicular pattern and no expression of other connective tissue cell markers. The cause of fibrosarcoma is not known. No specific predisposing factors are known, although some lesions arise in previously irradiated sites, and others are noted in preexisting connective tissue tumors such as solitary fibrous tumor, well-differentiated liposarcoma, and dermatofibrosarcoma. Although multiple chromosome abnormalities have been reported in fibrosarcoma,



■ **FIGURE 7-15 Fibrosarcoma** of the buccal mucosa.

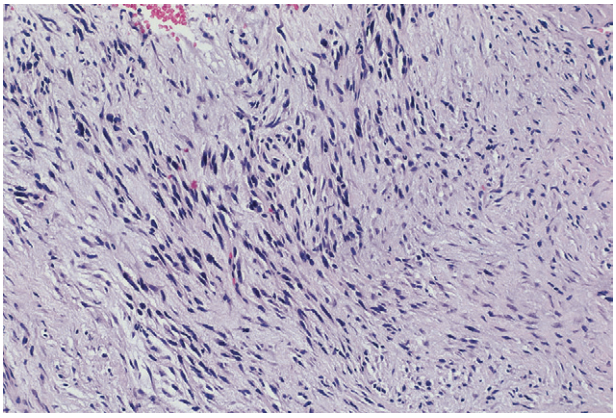

■ **FIGURE 7-16 Fibrosarcoma** composed of atypical spindle cells.

evidence suggests that alterations in one or more genes in the 2q14-22 region might contribute to the pathogenesis of this tumor.

Clinical Features. Fibrosarcoma is a rare soft tissue and bony malignancy of the head and neck (Figure 7-15). A tumor results from proliferation of malignant mesenchymal cells at the site of origin. Secondary ulceration may be seen as the lesion enlarges. Young adults are most commonly affected. This is an infiltrative neoplasm that is more of a locally destructive problem than a metastatic problem.

Histopathology. Microscopically, fibrosarcoma exhibits malignant-appearing fibroblasts, typically in a herringbone or interlacing fascicular pattern (Figure 7-16). Collagen may be sparse, and mitotic figures frequent. The degree of cell differentiation from one tumor to another may be quite variable. The periphery of this lesion is ill defined because the neoplasm freely invades surrounding tissue. Fibrosarcoma is essentially a diagnosis of exclusion, and by definition, there should be no expression of actin, S-100, epithelial membrane antigen, keratin, or desmin.

Treatment. Wide surgical excision is generally advocated for fibrosarcoma because of the difficulty involved in controlling local growth. Although recurrence is not uncommon, metastasis is infrequent. Bone lesions are more likely to metastasize via the bloodstream than are soft tissue lesions. The overall 5-year survival rate ranges between 30% and 50%. Generally, patients with soft tissue lesions fare better than those with primary lesions of bone. Also, well-differentiated lesions have a better prognosis than do those with poorly differentiated features.

Synovial Sarcoma

Synovial sarcoma (SS) accounts for about 10% of all soft tissue sarcomas. The peak incidence is seen in the third decade, with about one third of cases occurring in patients younger than 20 years. Despite its name, synovial sarcoma does not arise from synovial tissue, and the cause is generally not known. SS is a morphologically and genetically distinct sarcoma characterized by the specific chromosomal translocation t(X;18) (p11;q11). This translocation event produces a SYT-SSX fusion gene, which is the result of joining of the *SYT* gene on chromosome 18 with one of three SSX genes (*SSX1, SSX2,* and *SSX4*) on the X chromosome. Different forms are recognized histologically, depending on the presence and proportion of spindle and epithelial cells. When both patterns are present, the tumor is termed *biphasic,* but when only one is present, the tumor is termed *monophasic.* Clinically, SS presents as an expanding mass, and symptoms are related to this tumor mass effect on normal structures. Symptoms may be present for a long time before the diagnosis is made because the tumor generally grows slowly. The optimal treatment for SS has not been established, but current therapy is similar to that of several other sarcomas, combining surgery, radiation, and chemotherapy. Five-year survival rates depend on the stage of the tumor at presentation and on whether the tumor can be completely excised. For localized disease, 5-year survival rates may approach 80%, but for more extensive tumors, survival is significantly reduced.

FIBROHISTIOCYTIC TUMORS

The original concept that some tumors show fibrohistiocytic differentiation was based on the notion that there exists a dual population of fibroblasts and histiocytes (macrophages) that in tissue culture show ameboid growth and phagocytic properties. It is now accepted that this concept is incorrect, and that the tumors in this category show no histiocyte (macrophage) differentiation. Immunohistochemical evidence now favors a fibroblast cell of origin. However, the term *fibrous histiocytoma* has persisted to describe a group

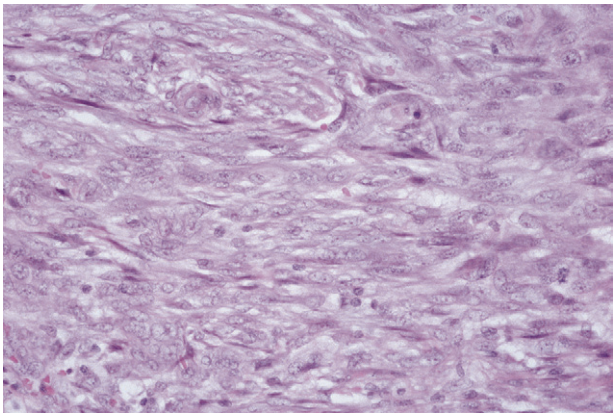

■ **FIGURE 7-17 Benign fibrous histiocytoma** composed of plump fibroblasts.

of likely unrelated benign and malignant tumors that share many histologic similarities.

Benign Fibrous Histiocytoma

Clinical Features. Benign fibrous histiocytomas are fibroblastic neoplasms that uncommonly or rarely occur in oral soft tissues, skin, or bone. They are lesions of adults, typically noted in the fifth decade, and present as painless masses that may be ulcerated. Intrabony lesions present as radiolucencies, often with ill-defined margins.

Histopathology. This tumor is fairly well demarcated and often is circumscribed at the periphery. A storiform (cartwheel or matlike) growth pattern of spindle cells (fibroblasts) is noted, with plump or vesicular nuclei admixed with some inflammatory cells (Figure 7-17). Tumor giant cells may be seen. No cellular atypia is present, and mitotic figures are infrequent and normal in appearance. Immunohistochemical stains are of little diagnostic value. Fibrous histiocytomas may show some positive staining for smooth muscle actin and or CD34, but a consistent pattern has not been demonstrated.

Treatment. Surgical excision is the treatment of choice for benign fibrous histiocytoma. Lesions usually do not recur.

Malignant Fibrous Histiocytoma (Pleomorphic Sarcoma)

Malignant fibrous histiocytoma (MFH) is a controversial soft tissue malignancy whose pathogenesis continues to be redefined. MFH was originally defined on the basis of morphologic and tissue culture analysis as a pleomorphic sarcoma that showed both fibroblastic and histiocytic differentiation. This concept is no longer accepted. *MFH,* at one time, was the most frequently used term for soft tissue sarcoma of late adult life. Five variants showing differing clinical and histologic features were described: prototypical pleomorphic-storiform, myxoid, giant cell, inflammatory, and angiomatoid. It has been proposed that the term *MFH* should be reserved for a small group of undifferentiated sarcomas lacking differentiation markers of other sarcomas; thus it is a diagnosis of exclusion. An interchangeable synonym is *pleomorphic sarcoma.* The angiomatoid type shows distinct clinical and histologic features and probably represents an entity that is distinct from other tumors in this category.

Clinical Features. MFH is an infrequently reported lesion in the head and neck. It may occur in bone, where it follows a more aggressive course than in soft tissue. Biologically, it has significant recurrence and metastatic potential that is dependent, in part, on clinical factors such as anatomic site, depth of location, and size.

Overall, MFH occurs in late adult life and is rare in children. Men are affected more often than women. The extremities and the retroperitoneum are favored sites. Intraoral soft tissue lesions appear to have no site predilection. Although only a small number have been reported, almost all regions have been affected. MFH has also been reported in the mandible and the maxilla, resulting in radiolucencies with poorly defined margins.

Histopathology. Basic to all MFH is the proliferation of pleomorphic spindle cells. Abnormal and frequent mitotic figures, necrosis, and extensive cellular atypia may be seen. In some lesions, a storiform pattern may dominate the microscopic picture; in others, myxoid zones, giant cells, acute inflammatory cells, xanthoma cells, or blood vessels may be prominent. Immunohistochemistry is helpful in excluding pleomorphic variants of other sarcomas such as leiomyosarcoma, liposarcoma, rhabdomyosarcoma, and myxofibrosarcoma. It is now accepted that histiocytic markers play no role in the diagnosis of pleomorphic sarcoma. These markers include alpha-1-antichymotrypsin, alpha-1-antitrypsin, CD68, and lysozyme.

Treatment. Wide surgical excision is the usual treatment. Radiation or chemotherapy offers limited additional benefit. The 5-year survival rate ranges from 20% to 60%. Patients with oral lesions generally fare somewhat worse than others. Recurrence and metastatic rates are about 40%.

VASCULAR LESIONS

REACTIVE LESIONS AND CONGENITAL LESIONS

Lymphangioma

Etiology. Regarded as a congenital lesion, lymphangioma usually appears within the first two decades of life. Involution over time, in contrast to the situation with congenital hemangiomas, does not usually occur.

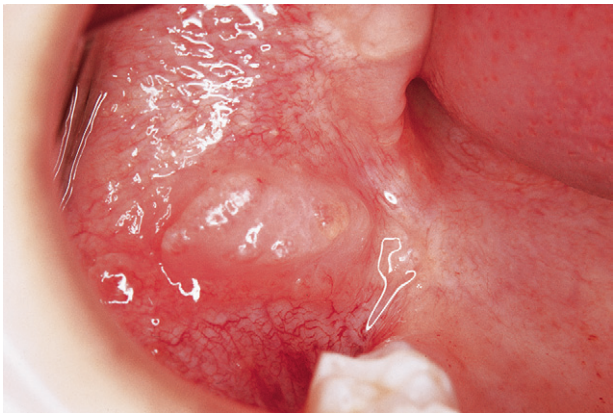

■ **FIGURE 7-18 Lymphangioma** of the buccal mucosa.



■ **FIGURE 7-19 Combined lymphangioma and hemangioma** of the tongue.

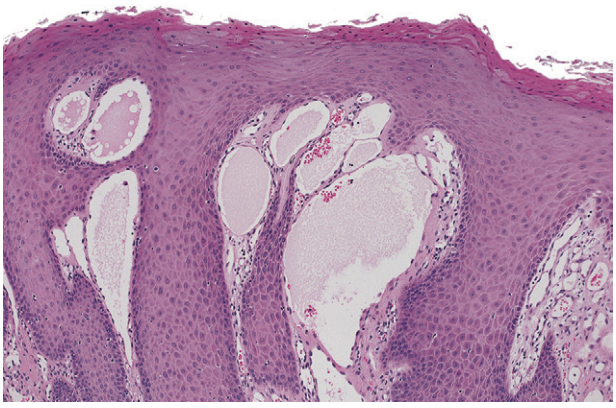

■ **FIGURE 7-20 Lymphangioma** composed of prominent lymphatic vessels. The vessels are characteristically apposed to the epithelium.

BOX 7-5 MACROGLOSSIA

Congenital hyperplasia/hypertrophy
Tumor: lymphangioma, vascular malformation, neurofibroma, granular cell tumor, salivary gland tumor
Endocrine abnormality: acromegaly, cretinism
Infections obstructing lymphatics
Beckwith-Wiedemann syndrome: macroglossia, exomphalos, gigantism
Amyloidosis
Angioedema

Clinical Features. Lymphangiomas present as painless, nodular, vesicle-like swellings when superficial, or as submucosal masses when located deeper. The color ranges from lighter than surrounding tissue to red-blue when capillaries are part of the congenital malformation (Figures 7-18 and 7-19). On palpation, the lesions may produce a crepitant sound as lymphatic fluid is pushed from one area to another.

The tongue is the most common intraoral site, and the lesions may be responsible for macroglossia when diffusely distributed throughout the submucosa (Box 7-5). Lymphangioma of the lip may cause a macrocheilia. Lymphangioma of the neck, known as *cystic hygroma, hygroma colli,* or *cavernous lymphangioma,* is a diffuse soft tissue swelling that may be life threatening because it involves vital structures of the neck. Respiratory distress, intralesional hemorrhage, and disfigurement are all potential sequelae to cystic hygroma.

Histopathology. Endothelium-lined lymphatic channels are diffusely distributed in the submucosa (Figure 7-20). The channels contain eosinophilic lymph that occasionally includes red blood cells, especially in mixed lymphatic and capillary proliferations. There is no capsule. A characteristic feature is the location of lymphatic channels directly adjacent to overlying epithelium, with no apparent intervening connective tissue.

Treatment. Lymphangiomas usually are surgically removed, but because of their lack of encapsulation, recurrences are common. Sclerotherapy has also been used successfully; in this procedure, sclerosing solutions are injected into cystic areas, with subsequent scarring of the aberrant vascular channels and generally acceptable results. Large lymphangiomas, such as cystic hygromas, may require staged surgical procedures to gain control of the lesion.

NEOPLASMS

Hemangiopericytoma

Hemangiopericytoma is a rare neoplasm that was originally described as a vascular tumor derived from the pericyte. This cell is believed to be a modified smooth muscle cell that is normally found surrounding capillaries and venules, between the basement membrane and the endothelium. The cell probably has a contractile property and serves as an

endothelial reserve cell. Immunohistochemical evidence indicates that conceptually this tumor is not derived from the pericyte because it does not express actin or myofibroblastic markers. It is likely that the neoplastic cell is an undifferentiated or fibroblastic cell. It has been suggested that many tumors previously diagnosed microscopically as hemangiopericytomas represent other soft tissue tumors that share similar features. For example, considerable histologic overlap has been noted between myofibroma, solitary fibrous tumor, synovial sarcoma, and mesenchymal chondrosarcoma, and it is conceivable that many hemangiopericytomas represent one of these entities. Increasingly, the diagnosis of hemangiopericytoma is a diagnosis of exclusion.

This neoplasm appears as a mass that may occur in any location of the body across a wide age spectrum. No distinguishing clinical signs would suggest a diagnosis of hemangiopericytoma.

Microscopically, the neoplasm is characterized by a proliferation of well-differentiated, oval to spindle-shaped mesenchymal cells separated by small, slitlike vascular channels. The vessels are thin walled and may exhibit "staghorn" profiles, although this pattern is also seen in several other soft tissue tumors.

The biological behavior of hemangiopericytoma is unpredictable. At least 70% of cases have a benign course, and the remainder are malignant. Unfortunately, no reliable histologic criteria can be used to predict the clinical course, although necrosis, numerous mitotic figures, a high proliferation marker (Ki67 or proliferating cell nuclear antigen [PCNA]), a labeling index, and hypercellularity may be suggestive of a more aggressive lesion. The treatment of choice is wide surgical excision. Recurrence and metastases are not uncommon.

Angiosarcoma

Angiosarcoma is a rare neoplasm of endothelial cell origin and unknown cause. Kaposi's sarcoma, also of endothelial origin but known to be caused by the human herpesvirus 8 (HHV8), is distinct from angiosarcoma.

The scalp is the usual location for angiosarcomas, although occasional lesions have been reported in the maxillary sinus and oral cavity. The lesion consists of an unencapsulated proliferation of anaplastic endothelial cells enclosing irregular luminal spaces. It has an aggressive clinical course and a poor prognosis.

NEURAL LESIONS

REACTIVE LESIONS

Traumatic Neuroma

Etiology. Traumatic neuromas are caused by injury to a peripheral nerve. In the oral cavity, the injury may occur with trauma from a surgical procedure such as a tooth extraction, from a local anesthetic injection, or from an accident. Transection of a sensory nerve can result in inflammation and scarring in the area of injury. As the proximal nerve segment proliferates in an attempt to regenerate into the distal segment, it becomes entangled and trapped in the developing scar, resulting in a disorganized composite mass of fibrous tissue, Schwann cells, and axons.



■ **FIGURE 7-21 Traumatic neuroma** presenting as a painful radiolucency at the mental foramen in an edentulous mandible *(ramus to the right).*

Clinical Features. About half of patients with oral traumatic neuromas have associated pain. Pain ranges from occasional tenderness to constant, severe pain. Radiating facial pain occasionally may be caused by a traumatic neuroma (Figure 7-21). Injection of local anesthesia into the area of tumescence relieves the pain.

Lesions occur over a wide age range, although most are seen in adults. The mental foramen is the most common location, followed by extraction sites in the anterior maxilla and the posterior mandible. The lower lip, tongue, buccal mucosa, and palate are also relatively common soft tissue locations.

Histopathology. Microscopically, bundles of nerves in a haphazard or tortuous arrangement are found admixed with dense collagenous fibrous tissue (Figure 7-22). A chronic inflammatory cell infiltrate may be seen in a minority of cases, particularly those that are symptomatic.

Treatment. Even though surgical transection of a peripheral nerve may have caused the lesion, surgical excision is the treatment of choice. Recurrence is infrequent.

NEOPLASMS

Granular Cell Tumors

Etiology. *Granular cell tumor,* formerly known as *granular cell myoblastoma,* is an uncommon benign tumor of unknown cause. The unique granular cells that make up the

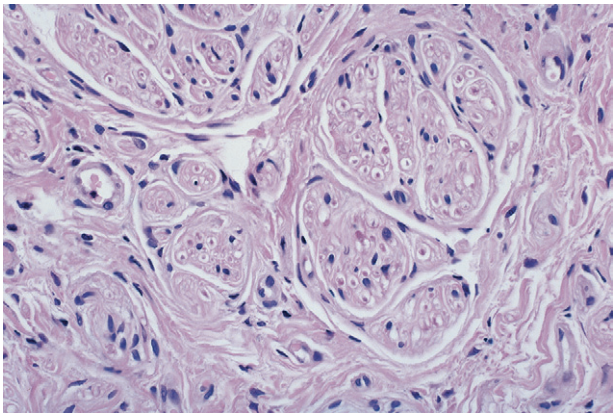

■ **FIGURE 7-22 Traumatic neuroma** composed of fibrous tissue and nerve bundles.



■ **FIGURE 7-23 Granular cell tumor** of the tongue.

BOX 7-6 ORAL GRANULAR CELL TUMOR

CLINICAL FEATURES
Benign tumor of neural sheath origin
Any age; females slightly more than males
Any site; usually tongue
Asymptomatic submucosal mass (1 to 2 cm)
  Same or lighter than mucosal color
  Intact overlying epithelium

HISTOPATHOLOGY
Large, uniform cells with granular cytoplasm
Overlying pseudoepitheliomatous hyperplasia
Cells positive for neural-associated proteins (e.g., S-100) and negative for muscle proteins (actin)

TREATMENT
Excision; no recurrence

BOX 7-7 CONGENITAL GRANULAR CELL TUMOR

CLINICAL FEATURES
Benign tumor of disputed origin
Infants only
Gingiva only
Usually pedunculated, nonulcerated mass

HISTOPATHOLOGY
Large, uniform cells with granular cytoplasm
No overlying pseudoepitheliomatous hyperplasia
Cells negative for S-100 and actin

TREATMENT
Excision; no recurrence

lesion are believed to be of neural (Schwann cell) origin, predominantly on the basis of immunohistochemical studies. Origins from skeletal muscle, macrophages, undifferentiated mesenchymal cells, and pericytes have been suggested but are unproven.

A related lesion known as *congenital gingival granular cell tumor* (congenital epulis) is composed of cells that are light microscopically identical to those of granular cell tumors. Slight differences have been noted by ultrastructural and immunohistochemical analysis, suggesting that congenital gingival tumors have a different histogenesis from granular cell tumors.

Clinical Features. Granular cell tumors appear in a range of patients from children to the elderly, with the mean appearance usually in middle adult life. Some studies have shown a predilection for females; others have shown nearly equal gender distribution (Box 7-6). In the head and neck, the tongue is by far the most common location for granular cell tumors (Figure 7-23). However, any oral location may be affected.

Presentation typically occurs as an uninflamed asymptomatic mass smaller than 2 cm in diameter. The tumor often has a yellowish surface coloration. The overlying epithelium is intact. Multiple lesions occasionally have been described.

Congenital gingival granular cell tumors appear on the gingiva (usually anterior) of newborns (Box 7-7). These lesions present as uninflamed, pedunculated, or broad-based masses (Figure 7-24). The maxillary gingiva is more often involved than the mandibular gingiva, and girls are affected more often than boys. The lesion does not recur, and spontaneous regression has been reported.

Histopathology. The clinical tumescence of granular cell tumors is due to the presence of unencapsulated sheets of large polygonal cells with pale granular or grainy cytoplasm (Figures 7-25 to 7-27). The nuclei are small, compact, and morphologically benign. Mitotic figures are rare. Pseudoepitheliomatous hyperplasia of the overlying oral epithelium is seen in about half of cases. This may be such a prominent feature that subjacent granular cells are overlooked, resulting



■ **FIGURE 7-24 Congenital gingival granular cell tumor.**

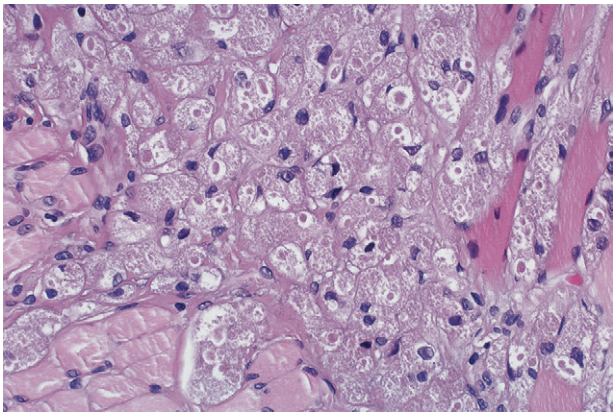

■ **FIGURE 7-25 Granular cell tumor.** Note uniform cells with granular cytoplasm found adjacent to skeletal muscle.

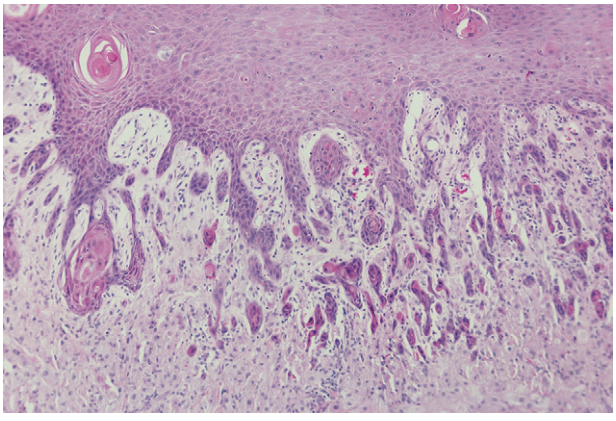

■ **FIGURE 7-26 Granular cell tumor** with overlying pseudoepitheliomatous hyperplasia.

in overdiagnosis of squamous cell carcinoma. The pseudoepitheliomatous hyperplasia overlying granular cell tumor is a completely benign process.

Ultrastructurally, granular cells of both the granular cell tumor and its congenital gingival counterpart contain autophagic vacuoles. One of the consistent differences noted has been the absence of angulate bodies in the gingival lesion. Also, in some gingival lesions, the presence of microfilaments with fusiform dense bodies, pinocytotic vesicles, and basement membrane has been noted.

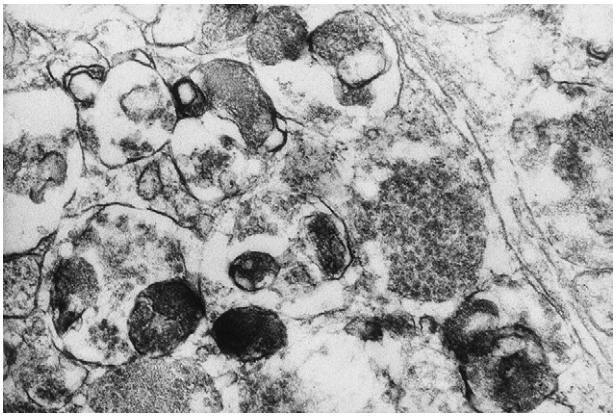

■ **FIGURE 7-27 Granular cell tumor.** Electron micrograph showing intracytoplasmic autophagic organelles.

Immunohistochemically, granular cell tumors express S-100 protein typical of neural tumors, CD57, and type IV collagen. Both lesions express carcinoembryonic antigens and human leukocyte antigens (HLA-DR) but are negative for alpha-1-antichymotrypsin and muscle actin.

Differential Diagnosis. Clinically, granular cell tumors might be confused with other connective tissue lesions. Neurofibroma, schwannoma, and palisaded encapsulated neuroma would be prime considerations for tongue lesions. Salivary gland tumors, lipoma, and other benign mesenchymal neoplasms may present intraorally as asymptomatic lumps similar to granular cell tumor. Focal fibrous hyperplasia (traumatic fibroma) is a common reactive lesion that should be included in a differential diagnosis. A biopsy with histopathologic analysis is the only way to achieve a definitive diagnosis.

Congenital gingival granular cell tumor is clinically distinct because of the age of the patient and the location in which the mass is seen. Other submucosal masses that occur in the gingiva of infants, such as gingival cyst and neuroectodermal tumor of infancy, are more deeply seated and broad based. Rhabdomyosarcoma tends to grow more rapidly and is darker in color.

Treatment. Granular cell tumors are surgically excised in a conservative fashion and generally do not recur.

Schwannoma

Etiology. Schwannoma, or *neurilemmoma,* is a benign neoplasm that is derived from a proliferation of Schwann cells of the neurilemma, or nerve sheath. As the lesion grows, the nerve is pushed aside and does not become enmeshed within the tumor.

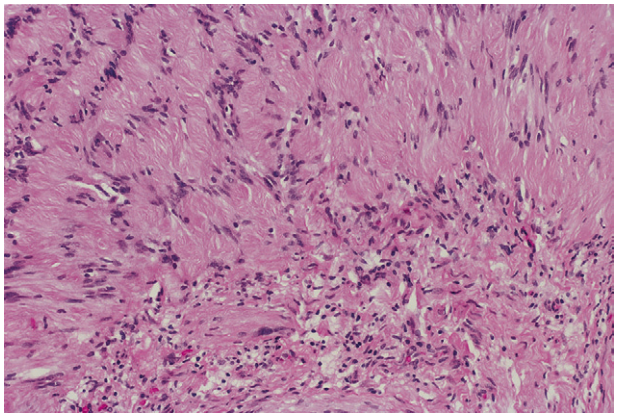

■ **FIGURE 7-28 Schwannoma** showing characteristic pattern of palisaded schwannoma cells around eosinophilic bodies.

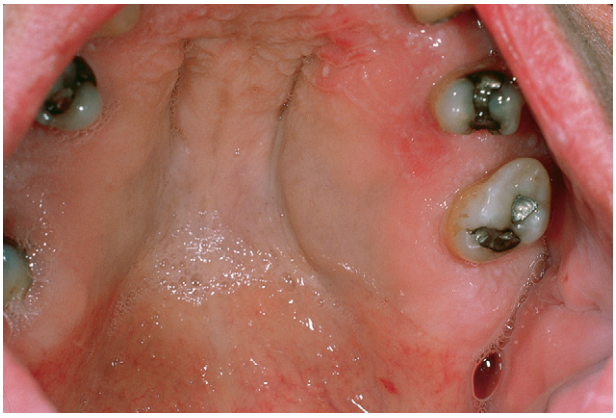

■ **FIGURE 7-29 Neurofibroma** of the left palate.

TABLE 7-3 NEURAL TUMORS: COMPARATIVE FEATURES

	Schwannoma	Neurofibroma	Mucosal Neuroma	PEN
Cell of origin	Schwann cell	Schwann cell and perineural fibroblast	Nerve tissue, hamartoma	Schwann cell
Age	Any	Any	Children, young adults	Adults
Site	Any, especially tongue	Any, especially tongue, buccal mucosa	Tongue, lip, buccal mucosa	Palate, lip
Number	Solitary	Solitary to multiple	Multiple	Solitary
Bone lesions	Occasionally	Frequently	No	No
Syndrome association	Neurofibromatosis	Neurofibromatosis	MEN III	None
Malignant potential	Rarely with syndrome	Infrequently with syndrome	No	No

MEN III, Multiple endocrine neoplasia syndrome type III; *PEN*, palisaded encapsulated neuroma.

Clinical Features. This lesion is an encapsulated submucosal mass that presents typically as an asymptomatic lump in patients of any age (Table 7-3). The tongue is the favored location, although lesions have been described throughout the mouth. Bony lesions produce a well-defined radiolucent pattern with a corticated periphery and may cause pain or paresthesia. The lesion is usually slow-growing but may undergo a sudden increase in size, which is thought in some cases to be due to intralesional hemorrhage. The fact that solitary schwannomas usually are not seen in neurofibromatosis is of clinical significance.

Histopathology. In this encapsulated tumor, spindle cells assume two different patterns. In one pattern, so-called Antoni A areas consist of spindle cells organized in palisaded whorls and waves. These cells often surround an acellular eosinophilic zone (Verocay body) representing reduplicated basement membrane and cytoplasmic cellular processes (Figure 7-28). The other pattern is the so-called Antoni B tissue, consisting of spindle cells haphazardly distributed in a delicate fibrillar microcystic matrix. By immunohistochemistry, this tumor strongly expresses S-100 protein. Stains for actin and desmin are negative.

A microscopic variant known as *ancient schwannoma* has been described to designate degenerative changes in a long-standing schwannoma. In this variant, fibrosis, inflammatory cells, and hemorrhage may be seen.

Treatment. Schwannomas are surgically excised, and recurrence is unlikely. The prognosis is excellent.

Neurofibroma

Etiology. Neurofibromas may appear as solitary lesions or as multiple lesions as part of the syndrome *neurofibromatosis (von Recklinghausen's disease of skin).* The cause of solitary neurofibroma is unknown. Neurofibromatosis, on the other hand, is inherited as an autosomal-dominant trait. It has variable expressivity and often (50% of cases) appears after spontaneous mutation. Two subsets have been defined: one associated with the *NF1* gene and the other with the *NF2* gene.

Clinical Features. Solitary neurofibroma presents at any age as an uninflamed asymptomatic, submucosal mass. The tongue, buccal mucosa, and vestibule are the oral regions most commonly affected (Figures 7-29 and 7-30).

Oral lesions are typically associated with neurofibromatosis 1. This condition includes multiple neurofibromas (Figures 7-31 and 7-32), cutaneous café-au-lait macules (Figure 7-33), bone abnormalities, central nervous system changes, and other stigmata. Neurofibromas range clinically from discrete, superficial nodules to deep, diffuse masses. Lesions may be so numerous and prominent that they become cosmetically significant. Intraoral neurofibromas

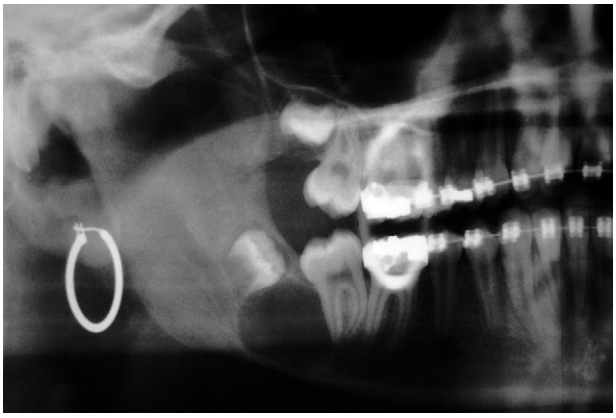

■ **FIGURE 7-30 Intramandibular neurofibroma.**



■ **FIGURE 7-33 Café-au-lait macule** in patient with neurofibromatosis.



■ **FIGURE 7-31 Neurofibromatosis,** cutaneous lesions.



■ **FIGURE 7-32 Neurofibromatosis,** oral lesions.

may be seen in as many as 25% of patients with neurofibromatosis. When other oral stigmata such as enlarged fungiform papillae and bone abnormalities are included, oral manifestations may be seen in as many as 70% of neurofibromatosis patients. Malignant transformation of neurofibroma into a malignant peripheral nerve sheath tumor (neurogenic sarcoma) can occur in 5% to 15% of patients with this syndrome.

The presence of six or more café-au-lait macules at any location greater than 1.5 cm in diameter is generally regarded as being suggestive of neurofibromatosis. Other important diagnostic signs of the syndrome are axillary freckling (Crowe's sign) and iris freckling (Lisch spots).

Bone changes may be seen in half or more of patients with neurofibromatosis. The changes may occur in the form of cortical erosion from adjacent soft tissue tumors or medullary resorption from intraosseous lesions. In the mandible, lesions most commonly arise from the mandibular nerve and may result in pain or paresthesia. In such cases of mandibular involvement, an accompanying radiographic sign may be the formation of a flaring of the inferior alveolar foramen, the so-called blunderbuss foramen.

Histopathology. Solitary and multiple neurofibromas have the same microscopic features (Figure 7-34). They contain spindle-shaped cells, with fusiform or wavy nuclei found in a delicate connective tissue matrix; this matrix may be notably myxoid in character. Lesions may be well circumscribed or may blend into surrounding connective tissue. Mast cells are characteristically scattered throughout the lesion. A histologic subtype known as *plexiform neurofibroma* is regarded as highly characteristic of neurofibromatosis. In this variety, a collagen matrix supports extensive interlacing masses of nerve tissue. Small axons may be seen among the proliferating Schwann cells and perineural cells.

Demonstration of S-100 protein and neurofilaments by immunohistochemistry may be useful in confirming the

diagnosis of neurofibroma, although cautious interpretation of S-100 staining is required. S-100 protein, once thought to be unique to the central nervous system, has been identified in numerous other cells outside the central nervous system, including Schwann cells, chondrocytes, Langerhans cells, and some nevus cells. Antibody to S-100 protein stains a wide array of unrelated neoplasms, including neural tumors, paraganglioma, some salivary gland tumors, granular cell tumor, Langerhans cell disease (LCD), chondrosarcoma, some muscle tumors, and approximately 95% of melanomas.

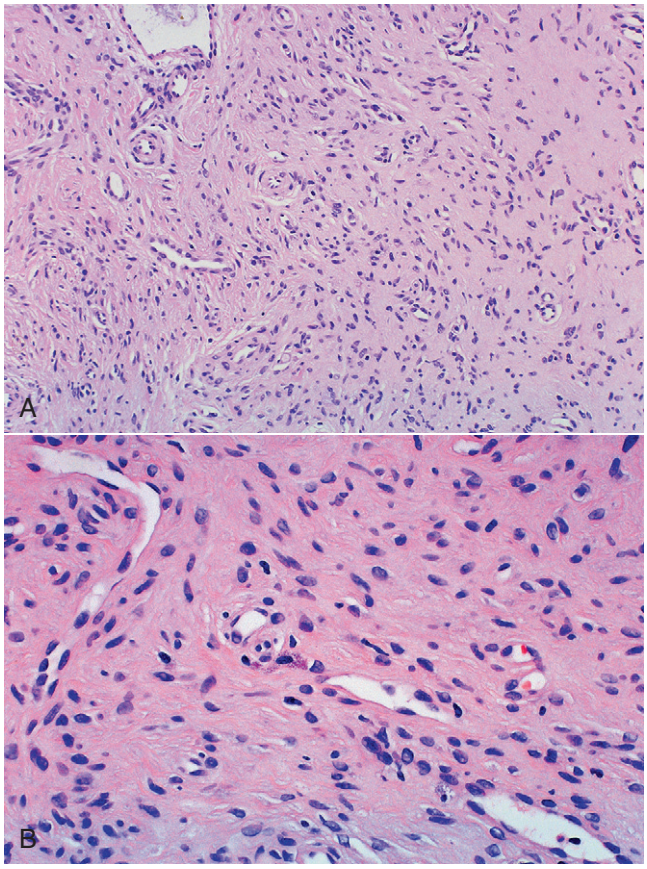

■ **FIGURE 7-34 Neurofibroma. A** and **B,** Haphazardly arranged spindle (Schwann) cells.

Differential Diagnosis. A solitary nodular neurofibroma should be considered in a clinical differential diagnosis with other submucosal masses of connective tissue origin, such as traumatic fibroma, granular cell tumor, and lipoma. A diffuse neurofibroma resulting in macroglossia may require differentiation from lymphangioma and possibly amyloidosis.

Treatment. Solitary neurofibromas are treated by surgical excision and have little chance of recurrence. Multiple lesions of neurofibromatosis may be treated in the same way but may be so numerous that excision becomes impractical. The prognosis for a patient who has had neurosarcomatous change in a preexisting lesion is poor.

Mucosal Neuroma of Multiple Endocrine Neoplasia Syndrome Type III

Etiology. The multiple endocrine neoplasia (MEN) syndromes comprise a group of conditions characterized by neoplasms arising in several endocrine organs. Only MEN type III (also known as MEN 2b), inherited as an autosomal-dominant trait, has oral manifestations (Table 7-4). MEN III is caused by a mutation in the *RET* oncogene resulting in a single amino acid substitution of a single methionine to threonine that affects a critical region of the tyrosine kinase catalytic core. Although a mutation of the *RET* gene is also responsible for the MEN II (also known as MEN 2a) syndrome, the mutations are different.

Clinical Features. MEN III consists of medullary carcinoma of the thyroid, pheochromocytoma of the adrenal, and mucosal neuromas (Figure 7-35). Café-au-lait macules and neurofibromas of the skin may also be seen in this condition. MEN I and MEN II are related to MEN III in that patients with types I and II syndromes have neoplasms of various endocrine organs, but they do not have the oral manifestations of mucosal neuromas.

The mucosal neuromas of MEN III usually appear early in life as small, discrete nodules on the conjunctiva, labia, or larynx, or in the oral cavity. The oral lesions are seen on the tongue, lips, and buccal mucosa.

TABLE 7-4 SOFT TISSUE TUMORS: CYTOGENETIC ABNORMALITIES

Tumor Type	Cytogenetic Change	Gene Abnormality
Alveolar rhabdomyosarcoma	t(2;13), t(1;13)	*PAX3-FKHR* *PAX7-FKHR*
Synovial sarcoma	t(X;18)(p11.2;q11.2)	*SYT* + one of *SSX1, SSX2, SSX4* *SSX2-SYT*
Lipoma	Rearranged 12q13-q15	*HMGA2/LPP, HMGA2/LHFP*
Myxoid liposarcoma	t(12;16)(q13;p11)	*DDIT3 (CHOP) + FUS (TLS)*
Mucosal neuroma (MEN III)	Chromosome 10 mutation	*RET*

MEN III, Multiple endocrine neoplasia syndrome type III.



■ **FIGURE 7-35 Mucosal neuromas of multiple endocrine neoplasia (MEN) III.**

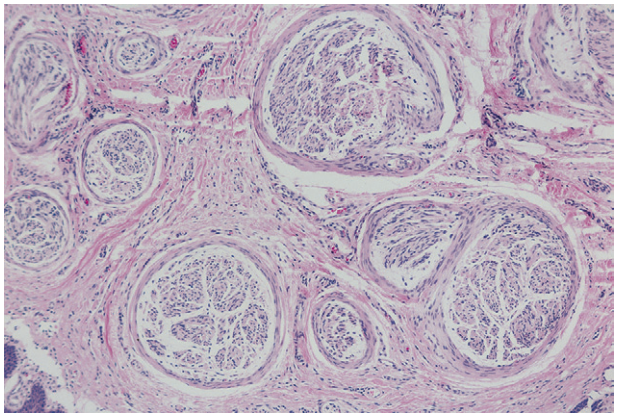

■ **FIGURE 7-36 Mucosal neuroma of multiple endocrine neoplasia (MEN) III.**

Histopathology. Mucosal neuromas are composed of serpiginous bands of nerve tissue surrounded by normal connective tissue (Figure 7-36). Axons have been found in the proliferating nerve tissue.

Treatment. Mucosal neuromas are surgically excised and are not expected to recur. The neuromas themselves are relatively trivial, but they are of considerable significance because they may be the first sign of this potentially fatal syndrome. The medullary carcinoma of the thyroid is a progressive malignancy that invades locally and has the ability to metastasize to local lymph nodes and distant organs. The 5-year survival rate of this malignancy is about 50%. Pheochromocytoma is a benign neoplasm that produces catecholamines that may cause significant hypertension and other cardiovascular abnormalities. Early detection of mucosal neuromas therefore is of utmost importance in establishing the diagnosis or calling attention to other components of the syndrome.

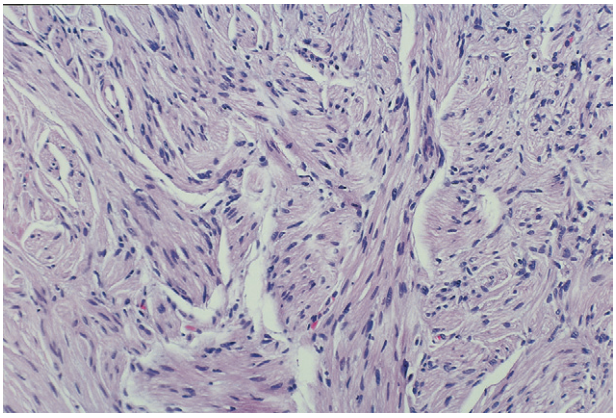

■ **FIGURE 7-37 Palisaded and encapsulated neuroma** showing a lobular pattern of spindle (Schwann) cells.

Palisaded Encapsulated Neuroma (Solitary Circumscribed Neuroma)

Palisaded encapsulated neuroma is another oral tumor of neural origin. It is not associated with neurofibromatosis or MEN III. It occurs typically in the palate and occasionally on the lips. This dome-shaped nodule is encapsulated and exhibits a fascicular microscopic pattern with some suggestion of nuclear palisading (Figure 7-37). The tumor is composed of cells positive for S-100 protein (Schwann cells) and some axons. After surgical removal, recurrence is unexpected.

Malignant Peripheral Nerve Sheath Tumor

Malignant peripheral nerve sheath tumor (MPNST) is a rare malignancy that may develop from a preexisting neurofibroma or de novo. It can complicate neurofibromatosis. The cell of origin is believed to be the Schwann cell and possibly other nerve sheath cells.

In soft tissues, MPNST appears as an expansile mass that is usually asymptomatic. In bone, where it is believed to arise most often from the inferior alveolar nerve, it presents as a dilation of the mandibular canal or as a diffuse radiolucency. Pain or paresthesia may accompany the lesion in bone; this is also the case for other malignancies within the mandible or the maxilla.

Microscopically, MPNST can be seen arising from a neurofibroma or from a nerve trunk. The lesion is composed of abundant spindle cells with variable numbers of abnormal mitotic figures. Streaming and palisading of nuclei are often seen, and nuclear pleomorphism may be prominent. Microscopic separation of this lesion from fibrosarcoma and leiomyosarcoma may be difficult, making immunohistochemistry an important diagnostic adjunct. Positive staining of tumor cells, at least focally, for S-100 protein and neurofilaments would be helpful in this regard.

The primary method of treatment is wide surgical excision. However, recurrence is common, and metastases are

frequently seen. The prognosis varies from fair to good, depending on clinical circumstances.

Olfactory Neuroblastoma

Olfactory neuroblastoma, also known as *esthesioneuroblastoma,* is a rare malignant lesion that arises from olfactory tissue in the superior portion of the nasal cavity. This lesion, which typically occurs in young adults, may result in epistaxis, rhinorrhea, or nasal obstruction, or it may present as polyps in the roof of the nasal cavity. It may also result in a nasopharyngeal mass or an invasive maxillary sinus lesion.

Microscopically, this lesion consists of small, undifferentiated, round cells with little visible cytoplasm (Figure 7-38). Compartmentalization and pseudorosette and rosette formations are often seen. Positive immunohistochemistry staining for chromogranin, synaptophysin, and neurofilaments can be used to confirm the light microscopic diagnosis. A microscopic differential diagnosis would include lymphoma, embryonal rhabdomyosarcoma, Ewing's sarcoma, and undifferentiated carcinoma.

Surgery or radiation is used to treat olfactory neuroblastoma. Recurrences are not uncommon, occurring in about half of patients. Metastasis, usually to local nodes or lung, occurs infrequently.

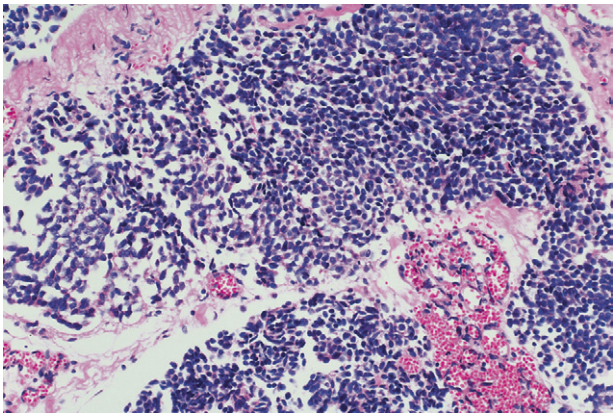

■ **FIGURE 7-38 Olfactory neuroblastoma;** "a round cell tumor."

MUSCLE LESIONS

REACTIVE LESIONS

Myositis Ossificans

Myositis ossificans is an uncommon reactive lesion of skeletal muscle. It may appear in the muscles of the head and neck. As the name implies, the condition is an intramuscular inflammatory process in which ossification occurs. The reason for the appearance of bone within the muscle during the reparative process has not been fully explained.

Muscle ossification may be seen in either of two forms: as a progressive systemic disease (myositis ossificans progressiva) of unknown cause, or as a focal single-muscle disorder (traumatic myositis ossificans). In the latter form, acute or chronic trauma may be responsible for the muscular change. The masseter and the sternocleidomastoid muscles are most commonly affected within the head and neck region. As the lesion matures, soft tissue radiographs show a delicate feathery opacification. Proliferating osteoblasts have occasionally been confused microscopically with malignant cells of osteosarcoma. Maturation and organization of the osseous tissue peripheral to the central cellular zone are believed to be important diagnostic features of myositis ossificans. The lesion is treated with surgical excision and has little tendency to recur.

NEOPLASMS

Leiomyoma and Leiomyosarcoma

Smooth muscle neoplasms, in general, are relatively common and may arise anywhere in the body (Table 7-5). Leiomyomas most commonly arise in the muscularis layer of the gut and in the body of the uterus (Figure 7-39). Leiomyosarcomas most commonly arise in the retroperitoneum, mesentery, omentum, or subcutaneous and in deep tissues of the limbs (Figure 7-40).

Both leiomyoma and leiomyosarcoma are rare in the oral cavity. Oral *leiomyomas* present as slow-growing, asymptomatic submucosal masses, usually in the tongue, hard palate,

TABLE 7-5 ORAL SPINDLE CELL NEOPLASMS: DIFFERENTIAL IMMUNOPROFILE

	S-100	Neurofilament	Muscle Actin	Desmin	CD34	CD99	CD31
Nerve sheath tumors (benign and malignant)	+	+	–	–	–	–	–
Myofibroma	–	–	+	–	–	–	–
Leiomyoma/sarcoma	–	–	+	+	–	–	–
Rhabdomyoma/sarcoma	–	–	+	+	–	–	–
Fibrous histiocytoma and MFH*	–	–	–	–	–	–	–
Solitary fibrous tumor	–	–	–	–	+	+	–
Kaposi's sarcoma	–	–	–	–	–	–	+

MFH, Malignant fibrous histiocytoma.
*Inconsistent staining. Angiomatoid MFH is positive for desmin and muscle actin.

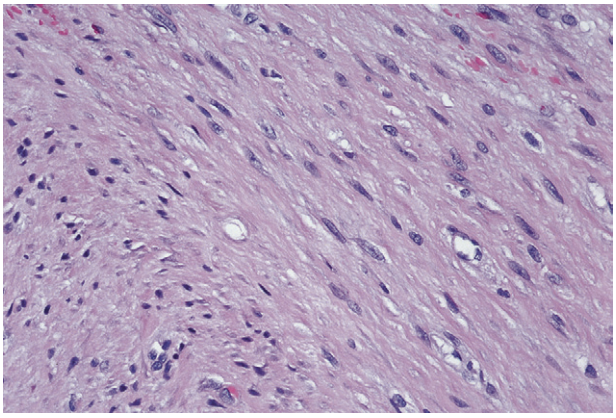

■ **FIGURE 7-39 Leiomyoma** composed of bland spindle cells.

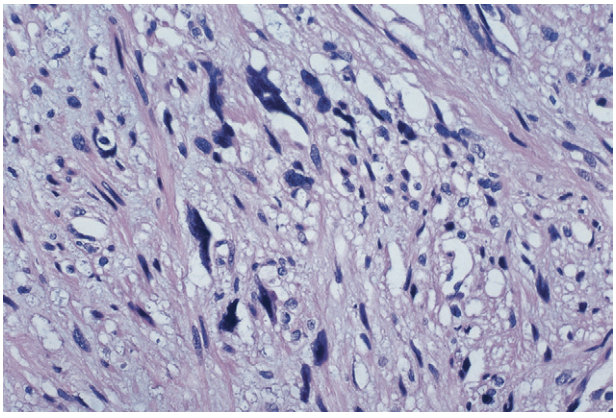

■ **FIGURE 7-40 Leiomyosarcoma** composed of spindle cells with atypical nuclei.

or buccal mucosa. They may be seen at any age and usually are discovered when they are 1 to 2 cm in diameter.

Microscopic diagnosis may occasionally be difficult because the spindle cell proliferation shares many similarities with neurofibroma, schwannoma, fibromatosis, and myofibroma. Special stains that identify collagen may be helpful in distinguishing these lesions. Immunohistochemical demonstration of actins can confirm the diagnosis. A microscopic subtype known as *vascular leiomyoma* (angioleiomyoma) has numerous thick-walled vessels associated with well-differentiated smooth muscle cells. Leiomyomas are surgically excised, and recurrence is unexpected.

Oral *leiomyosarcomas* have been reported in all age groups and in most intraoral regions. Microscopic diagnosis is a considerable challenge because of similarities to other spindle cell sarcomas. As with benign neoplasms, immunohistochemistry can be a valuable diagnostic tool to demonstrate the expression of actin proteins. Actin is a small cytoplasmic filament, approximately 5 nm in diameter, that has contractile properties. Six actin isotypes differentiate smooth muscle, striated muscle, and nonmuscle cells. Anti–muscle-specific actin and anti–smooth muscle actin generally provide good sensitivity and intensity for the detection

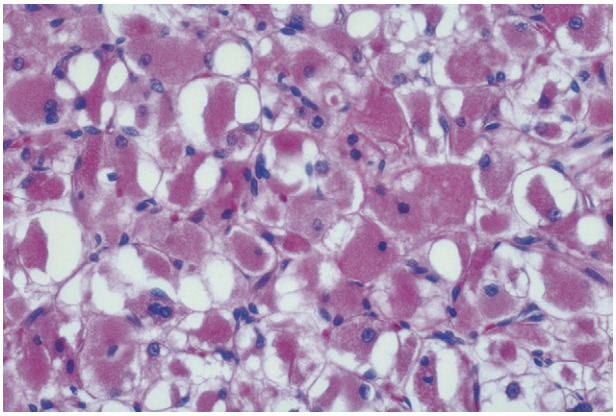

■ **FIGURE 7-41 Rhabdomyoma** mimicking adult skeletal muscle cells.

of leiomyosarcoma. Staining for desmin is less reliable, as it is positive in about two thirds of cases.

Leiomyosarcomas are usually treated with wide surgical excision. Metastasis to lymph nodes or lung is not uncommon.

Rhabdomyoma and Rhabdomyosarcoma

Rhabdomyomas are rare lesions, but they have a predilection for the soft tissues of the head and neck. The oral sites most frequently reported are floor of the mouth, soft palate, tongue, and buccal mucosa. The mean age of patients is about 50 years, and the age range extends from children to older adults. Presentation occurs as an asymptomatic, well-defined submucosal mass.

Two microscopic variants are recognized. In the adult type, neoplastic cells closely mimic their normal counterparts (Figure 7-41); in the fetal type, neoplastic cells are elongated and less differentiated and exhibit fewer cross-striations. The latter type may be confused with rhabdomyosarcoma. Treatment consists of excision, and recurrence is unlikely.

Rhabdomyosarcomas are subdivided into three principal microscopic forms: embryonal, alveolar, and pleomorphic. The first two types occur in children, and the latter type occurs principally in adults. The embryonal type consists of primitive round cells in which striations are rarely found (Figure 7-42). Two subtypes are recognized: spindle cell and botryoid types. Both confer an excellent prognosis. The alveolar variant is composed of round cells but in a compartmentalized pattern. The pleomorphic type, the best differentiated, contains strap or spindle cells that often exhibit cross-striations (Figure 7-43).

When it occurs in the head and neck, rhabdomyosarcoma is found primarily in children. When it occurs outside the head and neck, it is seen typically in adults. Rhabdomyosarcoma presents as a rapidly growing mass that may cause pain or paresthesia if jaw involvement occurs. The most commonly affected oral sites are the tongue and soft palate. The

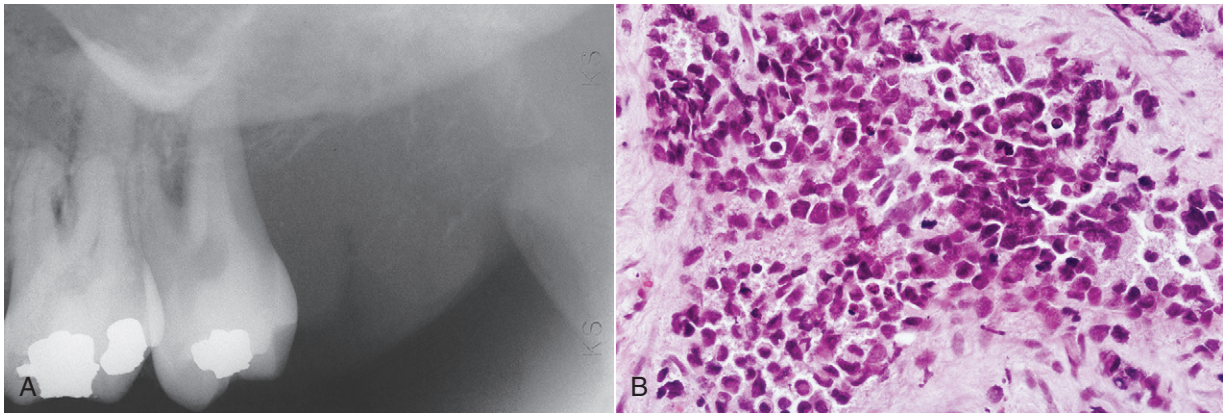

■ **FIGURE 7-42 Rhabdomyosarcoma** of the palate. **A,** Radiograph showing tumor destruction of tuberosity and alveolar bone around roots of second molar tooth. **B,** Biopsy specimen showing malignant round rhabdomyoblasts.

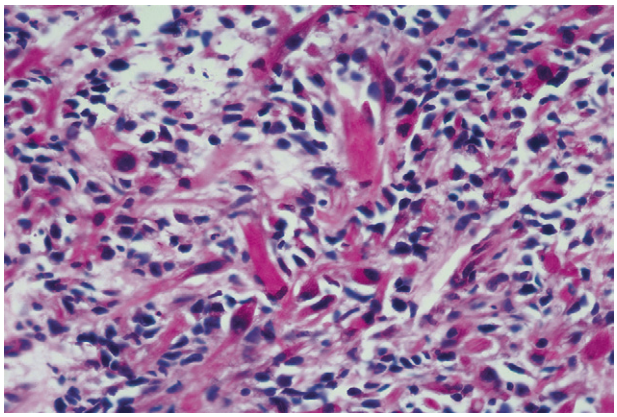

■ **FIGURE 7-43 Rhabdomyosarcoma,** pleomorphic type. Note straplike malignant cells.



■ **FIGURE 7-44 Lipoma,** posterior floor of mouth.

embryonal type of rhabdomyosarcoma is the variety most commonly seen in the head and neck. Because of the relatively undifferentiated nature of this microscopic subtype, immunohistochemistry to demonstrate muscle-associated proteins (desmin, actin, myogenin, myoD1) is typically used to support light microscopic interpretations. Two consistent and reproducible chromosome translocations are associated with alveolar rhabdomyosarcoma. The most common is t(12;13)(q35;q14), and t(1;13)(p36q14) is less common. These translocations juxtapose the *PAX3* or *PAX7* gene on chromosomes 2 and 1, respectively, with the *FKHR* gene on chromosome 13, resulting in chimeric fusion proteins that act as potent transcription factors. This process differs from the deletions on 11p15 that are seen in the embryonal forms of rhabdomyosarcoma.

The combination of surgery, radiation, and chemotherapy has been shown to produce far better clinical results than any one of these treatment methods alone. Survival rates have increased from less than 10% to better than 70% with this more aggressive treatment approach.

FAT LESIONS

Lipoma

Lipomas are uncommon neoplasms that may occur in any region of the oral cavity. The buccal mucosa, tongue, and floor of the mouth are among the more common locations (Figure 7-44). Lesions typically present clinically as asymptomatic, yellowish submucosal masses. The overlying epithelium is intact, and superficial blood vessels are usually evident over the tumor. Other benign connective tissue lesions such as granular cell tumors, neurofibromas, traumatic fibromas, and salivary gland lesions (mucocele and mixed tumor) might be included in a differential diagnosis.

Numerous microscopic subtypes have been described, but they are primarily of academic interest. All types have adipocytes of various degrees of maturity. The usual simple lipoma consists of a well-circumscribed, lobulated mass of mature fat cells. The lesions are excised and are not expected to recur.

Liposarcoma

Liposarcoma is rarely encountered in soft tissues of the head and neck. It is a lesion of adulthood and may potentially occur at any site. It is generally slow-growing and thus may be mistaken for a benign process. Considerable microscopic variation in these malignancies has led to subclassification into at least four types: well differentiated, myxoid, round cell, and pleomorphic. Apart from the expression of CD34, immunohistochemistry plays little role in the diagnosis of liposarcoma. The degree of tumor cell differentiation coupled with identification of the microscopic subtype is an important factor in predicting clinical behavior (Figure 7-45). These neoplasms may be treated with surgery or radiation, and the prognosis is fair to good.

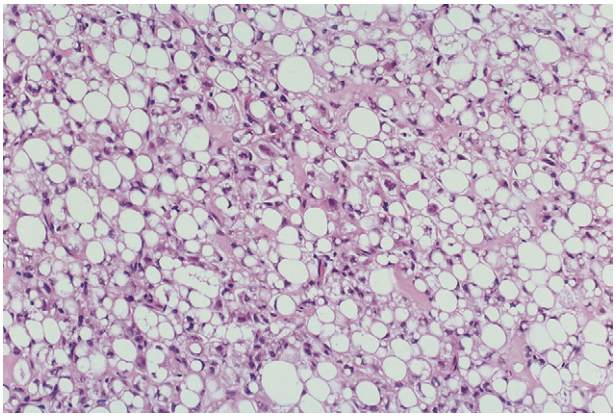

■ **FIGURE 7-45 Liposarcoma** showing irregular fat cells with atypical nuclei.

BIBLIOGRAPHY

Fibrous Connective Tissue Lesions

Alawi F, Stratton D, Freedman PD: Solitary fibrous tumor of the oral soft tissues: a clinicopathologic and immunohistochemical study of 16 cases. Am J Surg Pathol 25:900–910, 2001.

Brown R, Sein P, Corio R et al: Nifedipine-induced gingival hyperplasia. Oral Surg Oral Med Oral Pathol 70:593–596, 1990.

Das SJ, Olsen I: Keratinocyte growth factor is upregulated by the hyperplasia-inducing drug nifedipine. Cytokine 12:1566–1569, 2000.

Dayan D, Nasrallah V, Vered M: Clinico-pathologic correlations of myofibroblastic tumors of the oral cavity: 1. Nodular fasciitis. J Oral Pathol Med 34:426–435, 2005.

de Villiers-Slabbert H, Altini M: Peripheral odontogenic fibroma: a clinicopathologic study. Oral Surg Oral Med Oral Pathol 71:86–90, 1991.

Dent CD, DeBoom GW, Hamlin ML: Proliferative myositis of the head and neck. Oral Surg Oral Med Oral Pathol 78:354–358, 1994.

Foss RD, Ellis G: Myxofibromas and myofibromatosis of the oral region: a clinicopathologic analysis of 79 cases. Oral Surg Oral Med Oral Pathol Oral Radiol Endod 89:57–65, 2000.

Fowler CB, Hartman KS, Brannon RB: Fibromatosis of the oral and paraoral region. Oral Surg Oral Med Oral Pathol 77:373–386, 1994.

Hajdu S: Fibrosarcoma: a historic commentary. Cancer 82:2081–2089, 1998.

Harel-Raviv M, Eckler M, Lalani K et al: Nifedipine-induced gingival hyperplasia. Oral Surg Oral Med Oral Pathol Oral Radiol Endod 79:715–722, 1995.

Ishiki H, Miyajima C, Nakao K et al. Synovial sarcoma of the head and neck: rare case of cervical metastasis. Head Neck 31:131–135, 2009.

Montgomery E, Speight PM, Fisher C: Myofibromas presenting in the oral cavity: a series of 9 cases. Oral Surg Oral Med Oral Pathol Oral Radiol Endod 89:343–348, 2000.

Perez-Ordonez B, Koutlas IG, Strich E et al: Solitary fibrous tumor of the oral cavity. Oral Surg Oral Med Oral Pathol Oral Radiol Endod 87:589–593, 1999.

Piperi E, Rohrer MD, Pambuccian SE, Koutlas IG: Vascular solitary fibrous tumor with "floret" cells or giant cell angiofibroma? A lingual example highlighting the overlapping characteristics of these entities and positive immunoreaction for estrogen and progesterone receptors. Oral Surg Oral Med Oral Pathol Oral Radiol Endod 107:685–690, 2009.

Rousseau A, Perez-Ordonez B, Jordan RCK: Giant cell angiofibroma of the oral cavity: report of a new location for a rare tumour. Oral Surg Oral Med Oral Pathol Oral Radiol Endod 88:581–585, 1999.

Vally I, Altini M: Fibromatosis of the oral and paraoral soft tissues and jaws. Oral Surg Oral Med Oral Pathol 69:191–198, 1990.

Vigneswaran N, Boyd D, Waldron C: Solitary infantile myofibromatosis of the mandible. Oral Surg Oral Med Oral Pathol 73:84–88, 1992.

Wiegand S, Eizavi B, Zimmerman AP et al: Sclerotherapy of lymphangiomas of the head and neck. Head Neck Aug 24, 2010. [Epub ahead of print]

Yamaguchi S, Nagasawa H, Suzuki T et al: Sarcomas of the oral and maxillofacial region: a review of 32 eases in 2S years. Clin Oral Investig 8:52–55, 2004.

Neural Lesions

Chauvin P, Wysocki G, Daley T et al: Palisaded encapsulated neuroma of oral mucosa. Oral Surg Oral Med Oral Pathol 73:71–74, 1992.

Chrysomali E, Papanicolaou S, Dekker NP et al: Benign neural tumors of the oral cavity: a comparative immunohistochemical study. Oral Surg Oral Med Oral Pathol Oral Radiol Endod 84:381–390, 1997.

Gutmann DH, Aylsworth A, Carey JC et al: The diagnostic evaluation and multidisciplinary management of neurofibromatosis 1 and neurofibromatosis 2. JAMA 278:51–57, 1997.

Muscle and Fat Lesions

Cessna MH, Zhou H, Perkins SL et al: Are myogenin and MyoD1 expression specific for rhabdomyosarcoma? Am J Surg Pathol 25:1150–1157, 2001.

Parham DM: Pathologic classification of rhabdomyosarcomas and correlations with molecular studies. Mod Pathol 14:506–514, 2001.

CHAPTER 8



Salivary Gland Diseases

REACTIVE LESIONS

Mucus Extravasation Phenomenon
Mucus Retention Cyst (Obstructive Sialadenitis)
Maxillary Sinus Retention Cyst/Pseudocyst
Necrotizing Sialometaplasia
Adenomatoid Hyperplasia

INFECTIOUS SIALADENITIS

Mumps
Cytomegaloviral Sialadenitis
Bacterial Sialadenitis
Sarcoidosis
Metabolic Conditions
Sjögren's Syndrome
Salivary Lymphoepithelial Lesion
Scleroderma
Xerostomia
Taste Disturbances
Halitosis

BENIGN NEOPLASMS

Mixed Tumor (Pleomorphic Adenoma)
Basal Cell Adenoma
Canalicular Adenoma
Myoepithelioma
Oncocytic Tumors
Sebaceous Adenoma
Ductal Papilloma

MALIGNANT NEOPLASMS

Mucoepidermoid Carcinoma
Polymorphous Low-Grade Adenocarcinoma
Adenoid Cystic Carcinoma
Clear Cell Carcinoma
Acinic Cell Carcinoma
Adenocarcinoma Not Otherwise Specified

RARE TUMORS

Carcinoma Ex-Mixed Tumor/Malignant Mixed Tumor/
Metastasizing Mixed Tumor
Epimyoepithelial Carcinoma
Salivary Duct Carcinoma
Basal Cell Adenocarcinoma
Squamous Cell Carcinoma

REACTIVE LESIONS

Mucocele is a clinical term that includes mucus extravasation phenomenon and mucus retention cyst. Because each has a distinctive pathogenesis and microscopy, they are considered separately.

Ranula is a clinical term that includes mucus extravasation phenomenon and mucus retention cyst, but it occurs specifically in the floor of the mouth. Ranula is associated with the sublingual or submandibular glands and presents as a fluctuant, unilateral, soft tissue mass. It often exhibits a bluish color that has been compared with a frog's belly, hence the term *ranula.* When it is significantly large, it can produce medial and superior deviation of the tongue. It may also cross the midline if the retained mucin dissects through the submucosa. A deep, plunging ranula develops if mucus herniates inferiorly through the mylohyoid muscle and along the fascial planes of the neck. On rare occasions, it may progress into the mediastinum.

Mucus Extravasation Phenomenon

Etiology and Pathogenesis. The cause of mucus extravasation phenomenon is traumatic severance of a salivary gland excretory duct, resulting in escape of mucus, or extravasation, into the surrounding connective tissue (Figure 8-1). An inflammatory reaction of neutrophils followed by macrophages ensues. Granulation tissue forms a wall around the mucin pool, and the contributing salivary gland undergoes inflammatory change. Ultimately, scarring occurs in and around the gland.

Clinical Features. The lower lip is the most common site of mucus extravasation phenomenon, but the buccal mucosa, anterior-ventral surface of the tongue (location of Blandin-Nuhn glands), floor of the mouth, and retromolar region are often affected (Figures 8-2 and 8-3). Lesions are uncommonly found in other intraoral regions where salivary glands are located, probably because of lower susceptibility to trauma.

Mucus extravasation phenomenon presents as a relatively painless mass of smooth surface ranging in size from a few millimeters to 2 cm in diameter. It has a bluish color when mucin is superficially located. Adolescents and children are more commonly affected than adults. Lesions may fluctuate in size because of mucosal rupture over the pooled mucin. Continued production of mucin leads to recurrence. The maximum size is usually reached within several days after injury, and a viscous material is found if aspiration is attempted.

Superficial mucocele is a variant of the extravasation-type mucocele. Rather than arising from traumatic duct rupture, this form of mucocele is believed to arise as a result of increased pressure in the outermost part of the excretory duct. These lesions are asymptomatic and numerous, occurring most commonly in the retromolar area, soft palate, and posterior buccal mucosa. Their clinical appearance suggests a vesiculobullous disease, but the lesions persist for an extended time. Other than being a diagnostic challenge, they are of little significance.

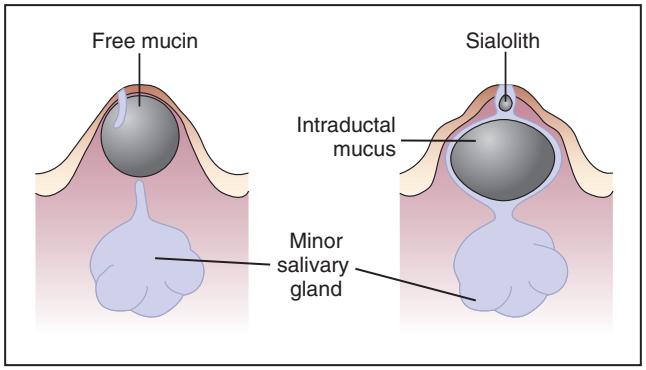

■ **FIGURE 8-1 Mucus extravasation phenomenon** *(left)* showing free mucin in the submucosa and a **mucus retention cyst** *(right)* showing mucin retained in the salivary excretory duct because of blockage by a sialolith.



■ **FIGURE 8-2 Mucus extravasation phenomenon** of the lower lip.

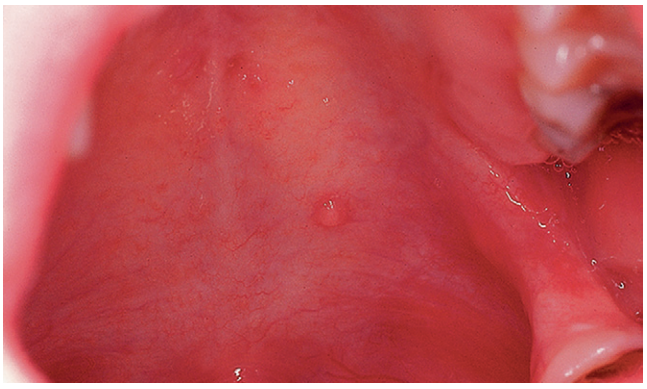

■ **FIGURE 8-3 Superficial mucocele** of the palate.

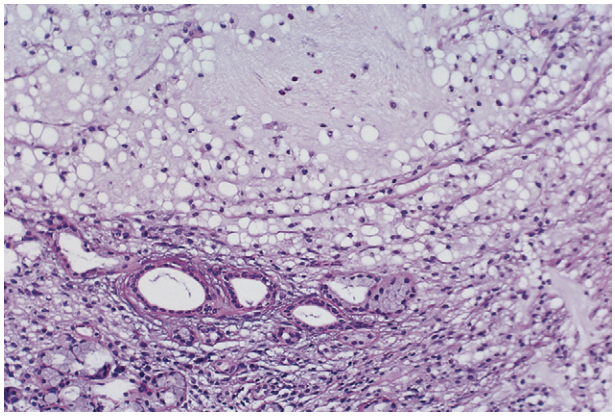

■ **FIGURE 8-4 Mucus extravasation phenomenon** showing free mucin *(top)* surrounded by inflamed granulation and connective tissue and salivary gland tissue.

Histopathology. Extravasation of free mucin incites an inflammatory response that is followed by connective tissue repair. Neutrophils and macrophages are seen, and granulation tissue forms around the mucin pool (Figure 8-4). The adjacent salivary gland whose duct was transected shows ductal dilation, chronic inflammation, acinar degeneration, and interstitial fibrosis.

Differential Diagnosis. Although a history of a traumatic event followed by development of a bluish translucency of the lower lip is characteristic of the mucus extravasation phenomenon, other lesions might be considered when a typical history is absent. These include salivary gland neoplasm (especially mucoepidermoid carcinoma), vascular malformation, venous varix, and soft tissue neoplasm such as neurofibroma or lipoma. Rarely, a mucocele may appear in the alveolar gingival mucosa. When this occurs, an eruption cyst or gingival cyst should be included in the differential diagnosis.

Treatment and Prognosis. Treatment for the mucus extravasation phenomenon consists of surgical excision. Aspiration of the fluid content provides no lasting clinical benefit. Removal of associated minor salivary glands along with the pooled mucus is necessary to prevent recurrence.

No treatment is required for superficial mucoceles because they rupture spontaneously and are short-lived.

Mucus Retention Cyst (Obstructive Sialadenitis)

Etiology and Pathogenesis. Mucus retention cysts usually result from obstruction of salivary flow caused by a sialolith (Box 8-1). The sialolith(s) may be found anywhere in the ductal system, from the gland parenchyma to the excretory duct orifice. A sialolith represents the precipitation of calcium salts (predominantly calcium carbonate and calcium phosphate) around a central nidus of cellular debris, inspissated mucin, and/or bacteria. Predisposition includes salivary stasis, chronic sialadenitis, and gout (uric acid calculi). Occasionally, periductal scar or an impinging tumor may cause the obstructive sialadenitis.

BOX 8-1 MUCOUS RETENTION CYST (OBSTRUCTIVE SIALADENITIS)

ETIOLOGY

Most are caused by obstruction by a salivary stone (sialolith).
Stones form by accumulation of calcium salts around a nidus within salivary duct.
Nidus consists of desquamated cells, inspissated mucin, and/or bacteria.

CLINICAL FEATURES

Obstruction causes sialadenitis, but not xerostomia.
Adults, male/female = 2:1, unilateral.
Submandibular gland up to 80%, parotid 20%, sublingual and minor glands 1% to 15%
Produce intermittent pain and swelling
Sialoliths in minor glands most commonly found in upper lip
Typically asymptomatic
Stones may be detected by x-ray in major glands.

TREATMENT

Minor glands—remove retention cyst and associated salivary gland.
Major glands—remove retention cyst and associated salivary gland,
or
Remove stone through duct incision, or by massaging stone through duct orifice.

Clinical Features. Obstructive sialadenitis due to stones is most commonly seen in submandibular glands (up to 80%) (Figures 8-5 and 8-6). About 20% are seen in the parotids, and a very small percentage is seen in sublingual and minor glands (especially upper lip). Adults are most commonly affected.

Recurrent swelling and pain are the primary presenting signs and symptoms, respectively, with worsening of either or both at mealtime. Infection may or may not be present. A purulent, cloudy-to-flocculent discharge at the duct orifice with massage, as well as limited flow from the gland at rest, is a common finding. Mucin in the floor-of-mouth lesions may penetrate the musculature and escape into the soft tissues of the neck, causing a *plunging ranula.*

Minor salivary gland lesions typically present as asymptomatic swellings without antecedent trauma. They vary in size from 3 to 10 mm and are mobile and nontender on palpation. The overlying mucosa is intact and has normal color.

Radiographically, nearly 90% of submandibular sialoliths are radiopaque, whereas most parotid calculi (90%) are radiolucent. The diagnosis may be suggested or confirmed by routine retrograde sialography or by cross-sectional imaging with intravenous contrast administration (computed tomographic [CT] sialogram).

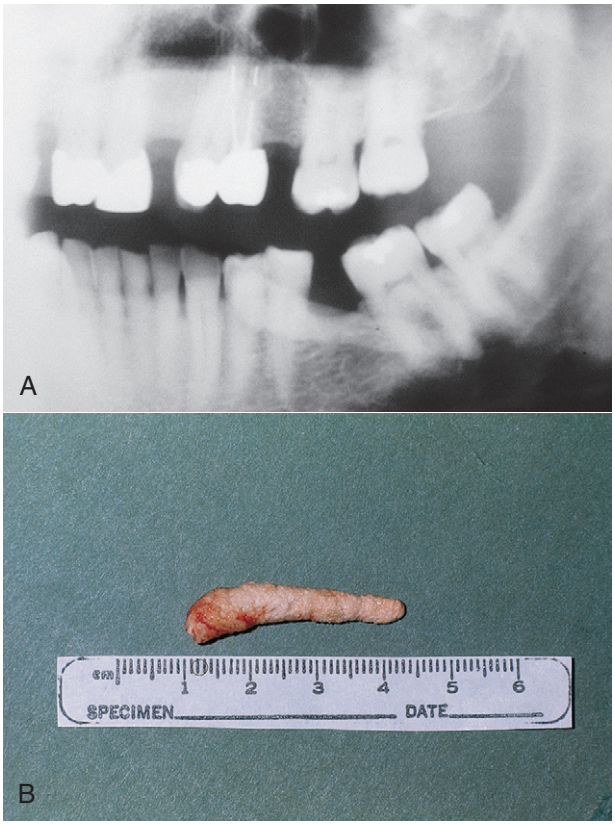

■ **FIGURE 8-5 A, Sialolithiasis** of the submandibular duct. **B,** Sialolith removed.

Histopathology. The cystlike cavity of a mucus retention cyst is lined by normal but compressed ductal epithelium (Figure 8-7). The type of lining formed by the epithelial cells ranges from pseudostratified to stratified squamous. The cystlike lumen contains mucin obstructed by a sialolith. The connective tissue around the lesion is minimally inflamed, although the associated gland shows inflammatory-obstructive change.

Differential Diagnosis. Salivary gland neoplasms, the mucus extravasation phenomenon, and benign connective tissue neoplasms should be included in a clinical differential diagnosis. Dermoid cyst might also be included for lesions in the floor of the mouth. Differentiation from a calcified phlebolith may be necessary, depending on the clinical presentation. Phleboliths show a circular morphology, with multiple calcifications often present beyond the glandular drainage system.

Treatment and Prognosis. For minor salivary glands, treatment consists of removal of both the mucus retention cyst and the associated gland to avoid postoperative mucus extravasation phenomenon, which may occur if only the cystic component is removed or decompressed. Lesions of the major salivary glands are treated in a similar way if the stone(s) resides in the hilum of the ductal system. If the stone is in the distal part of the ductal system, the sialolith may be surgically removed or may be milked through the duct orifice. If a duct is surgically entered, special precautions (marsupialization/cannula) are used to aid the healing process, so that duct scarring is minimized. Constriction of the duct through excessive scar formation could result in recurrence. Recurrence is noted in up to 20% of cases following routine treatment.

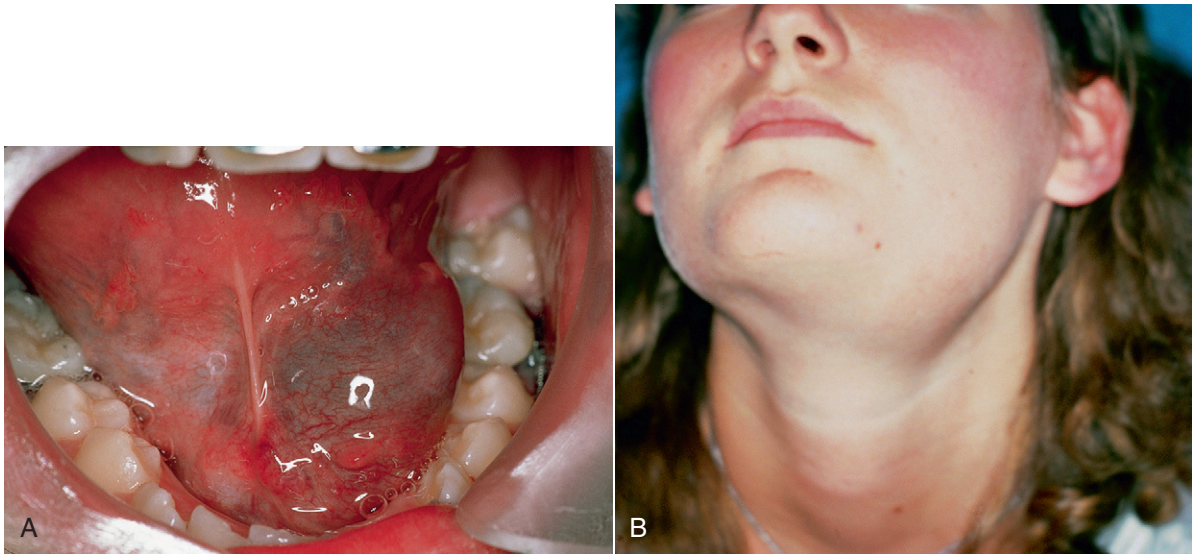

■ **FIGURE 8-6 A, Ranula** on the floor of the mouth. **B, Plunging ranula.**

Maxillary Sinus Retention Cyst/Pseudocyst

Retention cysts and pseudocysts involving the lining of the maxillary antrum are common findings on panoramic radiographs. These lesions are discovered incidentally and are of little clinical significance.

Etiology and Pathogenesis. Retention cysts are thought to arise from blockage of an antral seromucous gland, resulting in a ductal epithelium-lined cystic structure filled with mucin. Pseudocysts are inflammatory in origin and result from fluid accumulation within the sinus membrane. They may be related to infection or allergy. Bacterial toxins, anoxia, and other factors presumably cause leakage of protein into surrounding soft tissue, thus raising the extravascular osmotic pressure with a subsequent fluid increase.

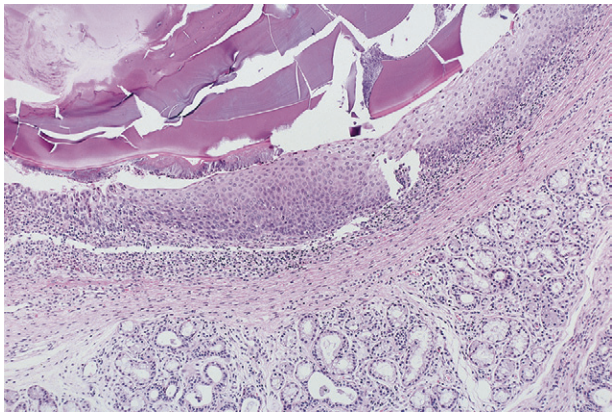

■ **FIGURE 8-7 Sialolith** *(top)* in a minor salivary gland *(bottom)* excretory duct of the upper lip.

Clinical Features. A great majority of these lesions are asymptomatic, although some slight tenderness may be noted in the mucobuccal fold or, more rarely, palpable buccal expansion in this region. On panoramic and periapical radiographs, retention cysts and pseudocysts of the maxillary sinus are hemispheric, homogeneously opaque, and well delineated (Figure 8-8). They usually demonstrate an attachment to the floor of the antrum, with size—rather than duration—being a function of the anatomic space. Uncommonly, these lesions may appear bilaterally.

Histopathology. The pathogenesis of the two forms of antral cysts is reflected in the histologic appearance. The retention cyst is lined by pseudostratified columnar epithelium with occasional interspersed mucous cells. The supportive elements are minimally inflamed. The pseudocyst shows no evidence of an epithelial lining but, rather, pools of mucoid material surrounded by slightly compressed connective tissue. A mixed inflammatory infiltrate is present within the granulation tissue wall, and numerous mucus-containing macrophages are present within the mucin pool.

Differential Diagnosis. A clinical differential diagnosis of cysts and pseudocysts arising within the mucosa of the maxillary sinus would include inflammatory polyps, hyperplasia of the sinus lining as a result of odontogenic infection, maxillary sinusitis, and neoplasms arising within the soft tissues of the antral lining.

Treatment. Antral retention cysts and pseudocysts generally are left untreated because they are limited in growth and are not destructive, and most spontaneously rupture or slowly resolve. Therefore only periodic observation is required.

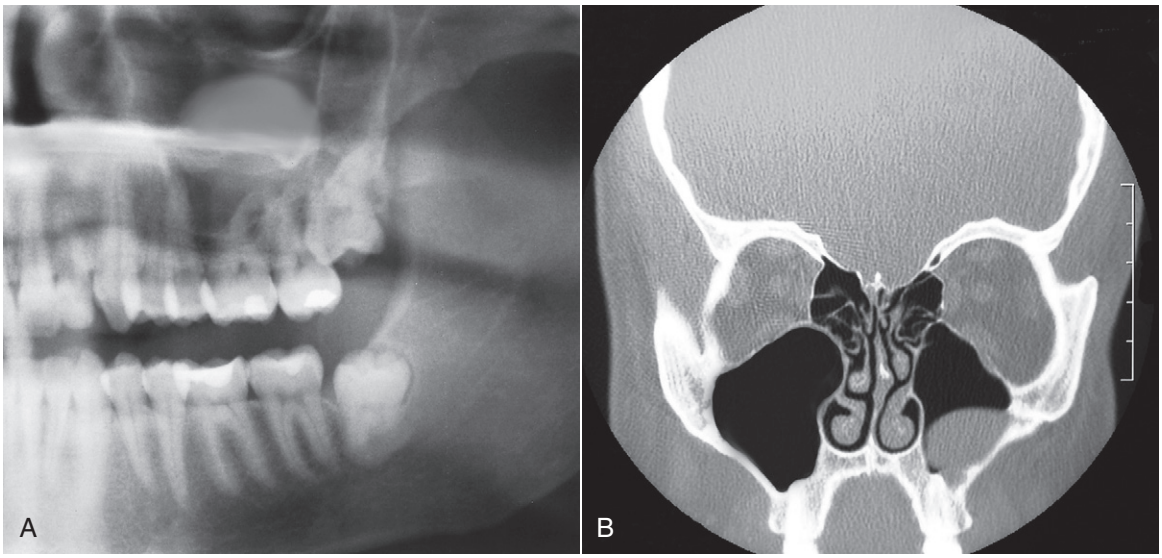

■ **FIGURE 8-8 A** and **B,** Maxillary sinus retention cyst.

Necrotizing Sialometaplasia

Necrotizing sialometaplasia is a benign condition that typically affects the palate and rarely other sites containing salivary glands (Box 8-2). Recognition of this entity is important because it mimics malignancy both clinically and microscopically. Unnecessary surgery has been performed because of an erroneous preoperative diagnosis of squamous cell carcinoma or mucoepidermoid carcinoma.

Etiology and Pathogenesis. The initiating event of necrotizing sialometaplasia is believed to be salivary gland ischemia precipitated by local trauma, surgical manipulation, or local anesthesia. Infarction of the gland follows, and squamous metaplasia of ductal remnants eventually appears.

This condition is believed to be due to local trauma or focal vascular compromise leading to discrete tissue necrosis in the area. Patients often have no history of a prior traumatic event, although some cases may be caused by local anesthetic placement in relation to a dental procedure with associated vascular compromise or direct vessel damage.

Clinical Features. Intraorally, necrotizing sialometaplasia is characterized by a seemingly spontaneous appearance, most commonly at the junction of the hard and soft palates (Figure 8-9). Early in its evolution, the lesion may be noted as a tender swelling, often with a dusky erythema of the overlying mucosa. Subsequently the mucosa breaks down, and a sharply demarcated deep ulcer with a yellowish gray lobular base is formed. In the palate, the lesion may be unilateral or bilateral, with individual lesions ranging from 1 to 3 cm in diameter. Pain is generally disproportionately slight compared with the size of the lesion. Healing is generally protracted, taking from 6 to 10 weeks.

Histopathology. Submucosa adjacent to an ulcer shows necrosis of salivary glands and squamous metaplasia of salivary duct epithelium (Figure 8-10). Preservation of the lobular architecture of salivary glands serves to distinguish this process from neoplasia. The characteristic ductal squamous metaplasia shows no cytologic atypia, but the pattern may be misinterpreted as squamous cell carcinoma. When this metaplasia is seen in the presence of residual viable

BOX 8-2 NECROTIZING SIALOMETAPLASIA

ETIOLOGY
Ischemia of minor salivary glands? Trauma? Other?

CLINICAL APPEARANCE
Junction of hard and soft palates
Unilateral or bilateral
Swelling, erythema, tenderness, followed by ulceration

CLINICAL DIFFERENTIAL DIAGNOSIS
Squamous cell carcinoma, salivary gland tumor, chronic infection, traumatic ulcer

TREATMENT
Incisional biopsy to establish diagnosis
Observation, because lesion is self-limiting and heals spontaneously in 6 to 10 weeks

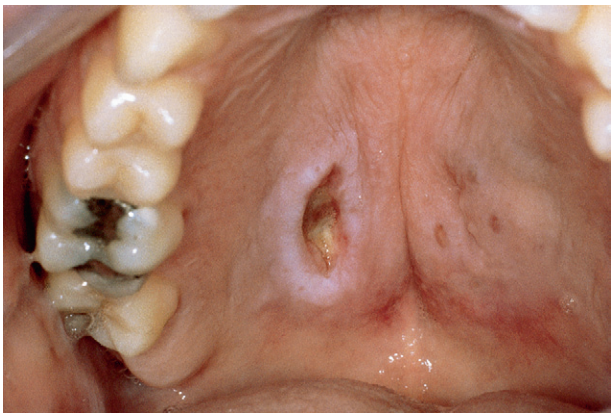

■ **FIGURE 8-9 Necrotizing sialometaplasia** of the hard palate.

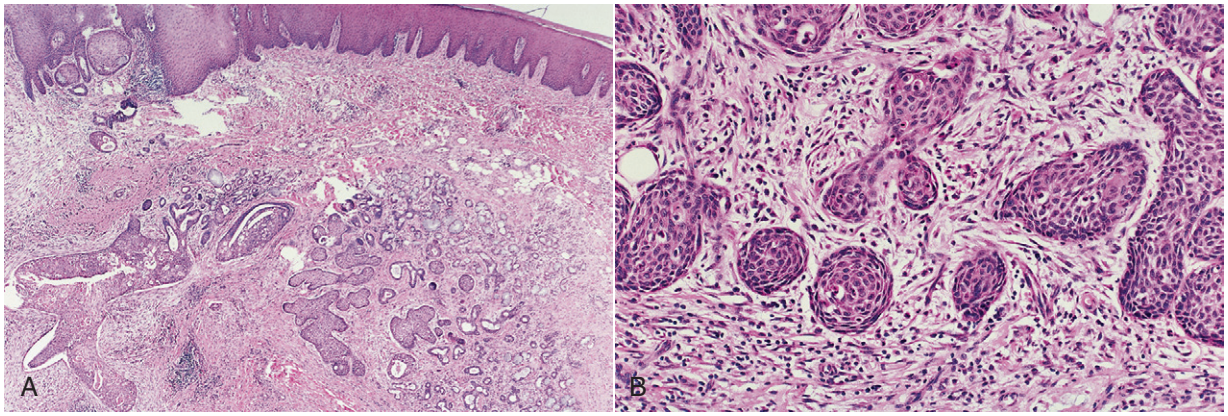

■ **FIGURE 8-10 Necrotizing sialometaplasia. A** and **B,** Squamous metaplasia of salivary ducts.

salivary gland, the lesion may be mistaken for mucoepidermoid carcinoma.

Differential Diagnosis. Clinically, squamous cell carcinoma and malignant minor salivary gland neoplasms must be ruled out, usually by a biopsy. Syphilitic gummas and deep fungal infections likewise must be ruled out because they may present as punched-out lesions of the palate. Findings from serology, biopsy, and/or culture are usually needed to exclude these entities. In medically compromised patients, such as those with poorly controlled diabetes, opportunistic fungal infections such as mucormycosis may cause a similar clinical picture.

The entity *subacute necrotizing sialadenitis* has been described as a nonspecific, inflammatory condition of minor salivary glands of unknown origin. It is characterized by abrupt onset of pain and localized swelling, usually of the hard or soft palate, but, unlike necrotizing sialometaplasia, it is self-limiting and has no ulcerative or metaplastic components.

Treatment and Prognosis. This condition is a benign, self-limiting process that does not require surgical intervention. However, an incisional biopsy should be performed to establish a definitive diagnosis. Healing takes place over several weeks by secondary intention. Patient reassurance, wound irrigation using a bland baking soda-and-water mouth rinse, and occasional use of analgesics are the only necessary management steps.

Adenomatoid Hyperplasia

Adenomatoid hyperplasia is a non-neoplastic enlargement of the minor salivary glands of the hard palate. The cause is unknown, although evidence suggests that trauma may play a role.

Clinical Features. The palate is the chief site of involvement of this salivary gland hyperplasia. A male predominance has been noted, and age ranges from 24 to 63 years. The clinical presentation is seen as a unilateral swelling of the hard and/or soft palate. This lesion is asymptomatic, broad-based, and covered with intact mucosa of normal color and quality.

Histopathology. Lobules of hyperplastic mucous glands extend beyond the submucosa and into the lamina propria. Individual acinar clusters are more numerous and larger than normal. Ducts exhibit a slight increase in relative prominence. The cytologic and morphologic features of acinar and ductal elements are within normal limits. Generally, no significant inflammatory cell infiltrate is found.

Differential Diagnosis. A clinical differential diagnosis would include salivary neoplasm, lymphoma, and extension of nasopharyngeal or sinonasal disease into the oral cavity. Periapical inflammatory disease should be excluded.

Treatment and Prognosis. Subsequent to identification by means of an incisional biopsy, no treatment is necessary, given the purely benign nature of this process. There is no neoplastic potential.

INFECTIOUS SIALADENITIS

Mumps

Mumps is an infectious, acute viral sialadenitis primarily affecting the parotid glands. Considered the most common of all salivary gland diseases before the advent of routine immunization, it has a year-round endemic pattern, although seasonal peaks are noted in the late winter and spring months. A rare noninfectious form of mumps or parotid enlargement is *iodide mumps*. This is seen most commonly in association with administration of iodine-containing radiographic contrast material. The condition is self-limiting and benign in nature with recurrence likely with repeat exposure to iodinated contrast material.

Etiology and Pathogenesis. The causative agent of infectious mumps is a paramyxovirus. A 2- to 3-week incubation period precedes clinical symptoms. Transmission occurs by direct contact with salivary droplets.

Clinical Features. Patients develop fever, malaise, headache, and chills, in addition to preauricular pain. Salivary glands, usually the parotid, demonstrate a 70% incidence of bilateral infection. Parotid swelling tends to be asymmetric at the outset, reaching maximum proportions within 2 to 3 days. Severe local pain is often noted, especially on movement of the jaws in talking and chewing. Stensen's duct may become partially occluded as the gland swells, with sharp pain resulting from stimulation of the secretory mechanism by food or drink. Perceptible diminution of swelling is noted approximately 10 days after the onset of symptoms. The disease affects males and females equally, especially young adults and children. Potentially serious complications (orchitis or oophoritis) can occur in adults. Mumps is a systemic infection, as evidenced by the widespread involvement of glandular and other tissues in the body, including the liver, pancreas, kidney, and nervous system.

Treatment and Prognosis. Treatment is symptomatic and includes bed rest. Analgesics are prescribed, and corticosteroids may be used in severe cases. Complete recovery is generally the rule, although fatalities have been associated with viral encephalitis, myocarditis, and nephritis. Nerve deafness and bilateral testicular atrophy have been noted but are uncommon.

Prevention of the disease is possible using a live attenuated vaccine that induces a noncommunicable, subclinical infection. Antibody conversion occurs in approximately 90% of susceptible individuals, and immunity is lifelong.

Although mumps is the most common form of viral sialadenitis, parotitis may be caused by other viral agents, including Coxsackie A virus, echovirus, choriomeningitis virus, cytomegalovirus, and parainfluenza virus types 1 and 2.

Cytomegaloviral Sialadenitis

Cytomegaloviral infection of the salivary glands, or cytomegalic inclusion disease, is a rare condition that affects neonates as a result of transplacental infection. Systemic disease may cause debilitation, developmental retardation, and premature birth.

When encountered in adults who are immunosuppressed (e.g., human immunodeficiency virus [HIV] infection, organ transplants), infection may cause fever, salivary gland enlargement, hepatosplenomegaly, pneumonitis, and lymphocytosis. Retinitis can be a serious complication of this infection. Cytomegalovirus can be demonstrated in biopsy material; with the use of in situ hybridization methods, its presence can be easily confirmed in tissue sections. Oral aphthous-like ulcers, particularly those arising in immunocompromised patients, may contain the virus, but its importance is undetermined. In severely infected immunocompromised patients, ganciclovir may be used to control cytomegaloviral infection.

Adults who are not immunosuppressed may also be infected with cytomegalovirus, as evidenced by demonstration of antibodies in serum. Symptoms may be nonexistent, or slight to debilitating fever and malaise may occur. The significance of cytomegaloviral infection in this population is poorly understood.

Bacterial Sialadenitis

Etiology and Pathogenesis. Bacterial infections of salivary glands generally are due to microbial overgrowth in association with a reduction in salivary flow. Such reduction in flow may be noted subsequent to dehydration, postoperative states, and debilitation. Traditionally, bacterial sialadenitis has been a common postoperative complication of surgery related to inadequate hydration. Numerous drugs associated with a decreased salivary flow rate likewise contribute to infections of the major salivary glands, especially the parotid. Submandibular gland sialadenitis is far less common than its parotid counterpart, in part because of the stated higher degree of bactericidal quality and the greater viscosity of submandibular saliva versus the serous and lower viscosity quality of parotid fluid. Other possible causes include trauma to the duct system and hematogenous spread of infection from other areas. The most commonly isolated organisms in parotitis are penicillin-resistant *Staphylococcus aureus, Streptococcus viridans, Streptococcus pneumoniae, Escherichia coli,* and *Haemophilus influenzae.* Anaerobic organisms may be cultured from acute cases and include *Porphyromonans gingivalis.* It is of interest to note the marked reduction in the overall incidence of acute parotitis after antibiotic preparations are introduced. As resistant strains of bacteria have appeared, the prevalence of acute parotitis has increased.

Clinical Features. Clinical features of acute parotitis include the sudden onset of painful lateral facial swelling, low-grade fever, malaise, and headache. Laboratory studies disclose an elevated erythrocyte sedimentation rate (ESR) and leukocytosis, often with a characteristic shift to the left, where neutrophil counts are elevated, indicating acute infection. The involved gland is extremely tender, and the patient often demonstrates guarding during examination. Trismus is often noted, and purulence at the duct orifice may be produced by gentle pressure on the involved gland or duct.

If the infection is not eliminated early, suppuration may extend beyond the limiting capsule of the parotid gland. Extension into surrounding tissues along fascial planes in the neck or extension posteriorly into the external auditory canal may follow.

Treatment and Prognosis. Management of bacterial sialadenitis is directed at elimination of the causative organism combined with rehydration of the patient and drainage of purulence, if present. Culture and sensitivity testing of the exudate at the orifice of the duct is the first step in antibiotic management. After a culture is obtained, all patients should empirically be placed on a regimen of a penicillinase-resistant antibiotic such as semisynthetic penicillin. Along with rehydration and attempts at establishing and encouraging salivary flow, moist warm compresses, analgesics, and rest are in order. Medications containing parasympathomimetic agents, which reduce salivary flow, should be reduced or eliminated.

Biopsy and retrograde sialography should be avoided, particularly in cases of acute and subacute infection. The former may cause sinus tract formation, and the latter may allow infection to proceed beyond the boundaries of the gland into surrounding soft tissues. With prompt and effective treatment of acute infection, recurrence is generally avoided. In cases of chronic recurrent parotitis with considerable destructive glandular changes, painful recurrent enlargement, and xerostomia, sialadenectomy—particularly in cases of submandibular gland involvement—may be considered, although duct ligation and parotidectomy remain treatment options.

In the *juvenile variant of parotitis,* intermittent unilateral or bilateral painful swelling is accompanied by fever and malaise. The initial attack usually occurs in individuals between ages 2 and 6 years, with numerous recurrences thereafter. A neonatal form of suppurative parotitis develops

rarely, with *S. aureus* being the most common causative pathogen. Gross destruction of parenchymal and ductal elements may be noted on sialographic examination. Absence of secretory acinar components and a damaged ductal system with numerous punctate globular spaces may be noted. Spontaneous regeneration of parotid salivary tissue has been reported in this condition. Finally, the rare example of childhood- to adolescent-onset Sjögren's syndrome may be heralded by recurrent bilateral parotitis.

Sarcoidosis

Etiology. Sarcoidosis is a granulomatous multisystemic disease of undetermined origin (Box 8-3). Although no specific cause has been identified, it has been suggested that this disease represents an infection or a hypersensitivity response to atypical mycobacteria. As many as 90% of sarcoidosis patients demonstrate significant titers of serum antibodies to these organisms. In some patients with sarcoidosis, a transmissible agent from human sarcoid tissue has been identified. With the use of molecular biological techniques, mycobacterial DNA and RNA have been identified in sarcoid tissues, raising the possibility of *Mycobacterium tuberculosis* or a related mycobacterial organism as a causative agent. Alternate microbial causes include Propionibacteria and Epstein-Barr and human herpesvirus 8 (HHV8) viruses.

Susceptibility related to human leukocyte antigens (HLAs) has been studied. Patients with some histocompatibility antigens (HLA-A1, HLA-B8, HLA-DR3, HLA-DRB1) may have a greater incidence of sarcoidosis than others. It has also been found that most patients with sarcoidosis are anergic, demonstrating decreased levels of cutaneous sensitization to dinitrochlorobenzene, as well as to tuberculin, mumps virus, *Candida* antigen, and pertussis antigen.

BOX 8-3 SARCOIDOSIS

ETIOLOGY

Unknown, atypical mycobacteria

CLINICAL FEATURES

Primary lesion in perihilar lymph nodes; also liver, skin, bone

Oral lesions in mucosa (nodules) or salivary glands (swelling)

Ocular and parotid disease known as Heerfordt's syndrome

May lead to xerostomia

DIAGNOSIS

Biopsy (shows noncaseating granulomas), chest x-ray, serum angiotensin-converting enzyme (ACE) level

TREATMENT

No specific treatment

Corticosteroids often prescribed, or occasionally other immunomodulating agents

Clinical Features. The protean manifestations of this disease are well known, and pulmonary symptoms are prime factors for evaluation, although the diagnosis generally is one of exclusion. Clinical courses range from spontaneous resolution to chronic progression. The disease may affect individuals at any age, although most are affected in the second through fourth decades. Females show a higher incidence than males, and blacks are more commonly affected than whites.

Sarcoidosis is usually a self-limiting, benign disease with an insidious onset and a protracted course. Patients may complain of lethargy, chronic fatigue, and anorexia, with specific signs and symptoms related to the organ involved.

Pulmonary manifestations are most characteristic of this disease. They are typified by bilateral, hilar, and, less commonly, paratracheal lymphadenopathy. The disease may stabilize at this point, or it may advance to pulmonary fibrosis and a more ominous prognosis. The most serious complications of sarcoidosis are pulmonary hypertension, respiratory failure, and cor pulmonale.

The skin may be involved in approximately 25% of cases; most commonly, an erythema nodosum of acute onset and short duration is seen. Skin plaques characterized by nontender, dark purple, elevated areas on the limbs, abdomen, and buttocks may appear. Another form of cutaneous pathology includes lesions known as *lupus pernio,* a term used to describe symmetric, infiltrative, violaceous plaques on the nose, cheeks, ears, forehead, and hands.

Ocular involvement is variable, with inflammation of the anterior uveal tract most commonly seen. This may be associated with parotid gland swelling and fever, referred to as *uveoparotid fever* or *Heerfordt's syndrome.*

Hepatic involvement is common, with approximately 60% of patients showing granulomatous lesions on liver biopsy specimens. However, clinical evidence of hepatic involvement appears in less than 50% of patients, as demonstrated in abnormal liver function test results.

Osseous lesions are uncommonly noted, with a 5% occurrence rate in most studies. When present, punched-out lesions involving the distal phalanges with erosions of cancellous bone and an intact cortex are seen. Destruction of alveolar bone with tooth mobility may be evident within the maxilla and the mandible.

Oral soft tissue lesions of sarcoidosis are nodular and generally are indistinguishable from those seen in Crohn's disease. Parotid swelling may occur unilaterally or bilaterally with about equal frequency (Box 8-4). This is often associated with lassitude, fever, gastrointestinal upset, joint pain, and night sweats, which may precede glandular involvement by several days to weeks. Other salivary glands may also be involved in the granulomatous inflammatory process, leading to xerostomia.

The upper aerodigestive tract may be involved, with lesions developing in the nasal mucosa, especially in the inferior turbinate and septal regions. Granulomas may occur in the nasal sinuses, pharynx, epiglottis, and larynx.

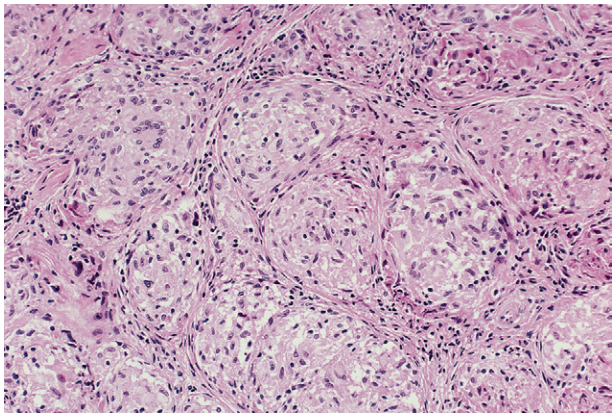

■ **FIGURE 8-11 Sarcoidosis** showing multiple granulomas.

BOX 8-4 CAUSES OF PAROTID GLAND ENLARGEMENT

Sjögren's syndrome
Neoplasms
Adenomas and carcinomas
Lymphoma
Bacterial infections
Mumps
Human immunodeficiency virus (HIV) disease
Tuberculosis
Sarcoidosis
Other bacterial infections
Metabolic conditions
Malnutrition, including anorexia and bulimia
Diabetes mellitus
Chronic alcoholism

Serum chemistry, radiographic studies, and biopsy are useful laboratory tests. Serum chemistry studies should include calcium (for evidence of hypercalcemia) and angiotensin 1–converting enzyme, lysozyme, and adenosine deaminase levels (for evidence of macrophage activity within granulomas). Gallium scintiscanning and routine chest radiographs and intraoral films may be used to demonstrate bone involvement.

Histopathology. Consistent microscopic findings of sarcoidosis are seen as noncaseating granulomas (Figure 8-11). The granulomas may be well demarcated and discrete or confluent. Within the granulomas are epithelioid macrophages and multinucleated giant cells, which may contain stellate inclusions (asteroid bodies) and concentrically laminar calcifications (Schaumann bodies). A diffuse lymphocytic infiltrate may be seen around the periphery of the granulomas. The caseation-type necrosis that is typical of tuberculosis is absent. Microorganisms are also absent.

A lip biopsy may occasionally provide evidence of sarcoid involvement of minor salivary glands in support of a clinical impression of pulmonary disease.

Diagnosis. The Kveim test was traditionally used to establish the diagnosis of sarcoidosis; however, this test is no longer used. Of considerable value is a laboratory assay for angiotensin 1–converting enzyme. Elevation of this enzyme in conjunction with a positive chest radiograph has a high diagnostic reliability.

The histologic differential diagnosis includes tuberculosis, Crohn's disease, leprosy, cat-scratch disease, fungal infection (blastomycosis, coccidioidomycosis, and histoplasmosis), and parasitic diseases such as toxoplasmosis. Granulomas seen in association with beryllium and talc exposure must also be considered.

Treatment and Prognosis. Spontaneous resolution occurs in a significant number of patients (65% to 70%) with few to no signs of residua or chronic sequelae. Corticosteroids are generally considered beneficial in the acute phase and remain the drugs of choice in treating symptomatic pulmonary sarcoidosis. Other agents may be used in addition to or instead of corticosteroids. Chloroquine, given alone or in combination with corticosteroids, has been found useful in the management of this disease. Immunosuppressive drugs have been used with good results in individuals not responding to corticosteroid management. A management role for thalidomide and infliximab has been identified as well. Immunomodulators such as levamisole may be useful in the management of arthritic symptoms caused by sarcoidosis.

In general, the prognosis for sarcoidosis is good, but patients must be monitored periodically with chest radiographs and serum angiotensin 1–converting enzyme determinations. Clinical relapses are unusual in cases in which spontaneous resolution has occurred.

Metabolic Conditions

A generic term for a group of metabolic disorders that may cause salivary gland enlargement is *sialadenosis,* or *sialosis.* These conditions usually affect the parotid glands bilaterally, typically in the absence of inflammatory symptoms. Chronic alcoholism, dietary deficiency, obesity, diabetes mellitus, hypertension, bulimia, anorexia nervosa, and hyperlipidemia have been linked to this clinical salivary gland abnormality. Alterations in aquaporin water channel function have been implicated in the development of sialadenosis in recent years.

Asymptomatic enlargement of the parotid glands occur in 30% to 80% of patients with alcoholic cirrhosis or chronic alcoholism. Salivary gland enlargement has been attributed to chronic protein deficiency. Comparable parotid gland enlargement in individuals with liver cirrhosis resulting from other causes apparently does not occur. Nutritional or

protein deprivation may lead to a similar salivary gland enlargement.

In diabetes mellitus, reduced flow rates have been reported in addition to bilateral parotid gland enlargement. The mechanism of acinar hypertrophy in this condition is unknown. Reduced flow rates from the parotid and other major salivary glands may lead to increased risk of bacterial sialadenitis.

In cases of type I hyperlipoproteinemia, a sicca-like syndrome has been described. This is characterized primarily by parotid enlargement with mild oral or ocular sicca symptoms; it is generally attributed to the presence of fatty replacement of functional salivary gland parenchyma.

Another endocrine-related salivary gland enlargement may be noted in acromegaly. This may merely be a reflection of a generalized organomegaly encountered in this endocrine-mediated disturbance. Apparent parotid enlargement (acinar hypertrophy) and increased levels of parotid flow have been noted in patients with chronic relapsing pancreatitis.

Sjögren's Syndrome

Sjögren's syndrome is the expression of an autoimmune process that results principally in dry eyes (keratoconjunctivitis sicca) and dry mouth (xerostomia) owing to lymphocyte-mediated destruction of lacrimal and salivary gland parenchyma (Box 8-5). Other autoimmune conditions, particularly rheumatoid arthritis, lupus erythematosus, and scleroderma, may also be seen as a component of this syndrome. Lacrimal and salivary gland involvement is often one expression of this generalized exocrinopathy that is lymphocyte mediated.

BOX 8-5 SJÖGREN'S SYNDROME

ETIOLOGY

Systemic autoimmune disease

Lymphocyte-mediated destruction of salivary parenchyma

CLASSIFICATION

Primary Sjögren's syndrome or sicca complex

- Dry eyes and mouth

Secondary Sjögren's syndrome

- Dry eyes and mouth plus collagen vascular disease (e.g., rheumatoid arthritis, lupus erythematosus, scleroderma)

DIAGNOSIS

Lip biopsy for salivary component

Schirmer test and wafer test for lacrimal component

Serologic tests for rheumatoid factor, ANA, SS-A, SS-B

TREATMENT AND PROGNOSIS

Symptomatic treatment

Artificial saliva and tears

Scrupulous oral hygiene necessary to prevent xerostomia-associated dental caries

Chronic disease with risk of lymphoma development (10%)

ANA, Antinuclear antibodies; *SS-A,* Sjögren's syndrome-A; *SS-B,* Sjögren's syndrome-B.

Etiology. Although the specific cause of this syndrome is unknown, it is considered a multifactorial process. Numerous immunologic alterations indicating a disease of great complexity characterized in part by environmental factors and a susceptible host results in a generalized immune dysregulation as noted by polyclonal B-cell hyperactivity reflecting lack of regulation by T-cell subpopulations. Specific immune system abnormalities include enhanced activity of the type 1 interferon system with subsequent upregulation of B-cell–activating factor. Other possible etiologic factors include altered autonomic activity of the affected glands and antimuscarinic receptor autoantibody production with resultant type 3 receptor dysfunction. As with the benign (salivary) lymphoepithelial lesion, the specific causes of this immunologic defect remain speculative.

This syndrome appears to be of autoimmune origin that may be limited to exocrine glands, or it may extend to include systemic connective tissue disorders. In instances of only exocrine glandular involvement, the syndrome is known as *primary Sjögren's syndrome.* If an associated connective tissue disorder is present, in addition to the xerostomia and keratoconjunctivitis sicca, regardless of the specific type, it is known as *secondary Sjögren's syndrome*; when associated with rheumatoid arthritis, it occurs on a different genetic background (HLA-DR4) and may represent a different pathogenetic process. Similarities and differences between primary and secondary forms of this condition have been noted, including a higher frequency of parotid gland enlargement and oral symptoms in the primary form with a more pronounced degree of B-cell activity. In both forms, extraglandular manifestations, with the exception of Raynaud's phenomenon, and prevalence of local infiltration are similar. A third and distinct pattern of autoantibodies, genetic predisposition, clinical manifestations, and therapy is noted in the association of secondary Sjögren's syndrome with progressive systemic sclerosis.

Viruses, particularly retroviruses and Epstein-Barr virus, have been implicated in the development of Sjögren's syndrome, but none are proven causes. Evidence suggesting a role for retroviruses has come from the demonstration of antibodies against HIV-associated proteins in a subset of patients with Sjögren's syndrome and from the clinical similarity of HIV-associated salivary gland disease to Sjögren's syndrome. The significance of anti-HIV antibodies in some patients with Sjögren's syndrome has not been determined. It has been suggested that these antibodies may be stimulated by another retrovirus that is related to HIV, or that they may represent cross-reacting autoantibodies.

Epstein-Barr virus has been demonstrated in the salivary gland tissue of patients with Sjögren's syndrome. However, this virus has also been found in the salivary glands of normal individuals, thus weakening the contention that Epstein-Barr virus has a primary role in causing this condition. If Epstein-Barr virus is involved, its role is likely secondary in nature.

Initial steps in the development of disease involve parenchymal vascular endothelium, acinar cells, and mesenchymal elements, including dendritic cells, by way of type 1 interferon production, allowing homing and long-term retention and localization of organ-specific lymphocytes in the area. Alterations of *out-in messaging* between stroma and epithelial elements by way of stromal metalloproteinase activity are also believed to play an important role in the early phases of pathogenesis, as well as in apoptosis of acinar cells via FAS-FAS ligand interaction, granzyme A formation, elaboration of perforin, and engagement of Toll receptors and interferon production. The net result of cell surface and acinar cell perturbation may relate to membrane dysfunction by way of aquaporin transport alteration, whereby water channel transport may be permanently altered.

Clinical Features. Sjögren's syndrome occurs in all ethnic and racial groups. The peak age of onset is 50 years, and 90% of cases occur in women. Children and teenagers are rarely affected. Distinguishing between primary and secondary forms of the syndrome, especially those associated with rheumatoid arthritis, usually is not difficult. This may be important because of increased risk that lymphoreticular malignancy (low-grade CD20+ extranodal marginal zone B-cell non-Hodgkin's lymphoma in 70% of cases, and other lymphoma variants in the remaining 30%) may develop in the primary form in approximately 5% of patients. The *MALT1* gene demonstrates the specific translocations t(11;18)(q21;q21) and (t14;18)(q32;q21) in up to 26% of cases. Lymphoma is considered a late development during the course of the syndrome, occurring from 7.5 to 14 years after disease onset. Often presaging or predicting the development of malignancy are parotid enlargement, lymphadenopathy, inflammatory neuropathy, and vasculitis. Subsequent lymphoma is further characterized by the presence of cryoglobulinemia and serum or urinary monoclonal proteins.

The chief oral complaint in Sjögren's syndrome is xerostomia, which may be the source of eating and speaking difficulties. These patients are also at greater risk for dental caries, periodontal disease, and oral candidiasis caused by dry mouth. Parotid gland enlargement, which is often recurrent and symmetric, occurs in approximately 50% of patients (Figure 8-12). A significant percentage of these patients also present with complaints of arthralgia, myalgia, and fatigue.

The salivary component of Sjögren's syndrome may be assessed by sialochemical studies, nuclear imaging of the glands (scintigraphy), contrast sialography, flow rate analysis, and a minor salivary gland biopsy. The most commonly used and most reliable method of assessing salivary alteration in this syndrome is a labial salivary gland biopsy.

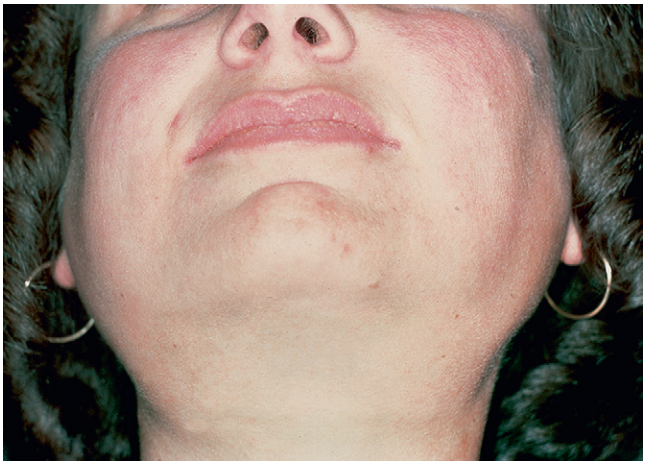

■ **FIGURE 8-12 Sjögren's syndrome** patient with bilateral parotid swelling.

Nuclear medicine techniques using a technetium pertechnetate isotope and subsequent scintiscanning can yield functional information relative to uptake of the isotope by salivary gland tissue. Contrast sialography aids in detecting filling defects within the gland being examined. A punctate sialectasia is characteristic in individuals with Sjögren's syndrome. This latter finding reflects significant ductal and acinar damage, with only the interlobular ducts remaining in cases of moderate to advanced disease. Over time, with further parenchymal and ductal damage, focal areas of narrowing or stenosis of larger ducts takes place and may be seen on a sialogram. Other forms of sialectasia, including globular and cavitary types, may be noted.

Other laboratory findings commonly found in primary and secondary Sjögren's syndrome include mild anemia, leukopenia, eosinophilia, an elevated ESR, and diffuse elevation of serum immunoglobulin levels. In addition, numerous autoantibodies may be found, including rheumatoid factor, antinuclear antibodies, and precipitating antinuclear antibodies such as anti–Sjögren's syndrome-A (SS-A) and anti–Sjögren's syndrome-B (SS-B). Antibodies SS-A and SS-B may be seen in association with both primary and secondary Sjögren's syndrome. Patients who have SS-B antibodies are more likely to develop extraglandular disease.

In the secondary form of Sjögren's syndrome, rheumatoid arthritis is the most common systemic autoimmune disease, although systemic lupus erythematosus is not infrequently encountered (Box 8-6). Less commonly, diseases such as scleroderma, primary biliary cirrhosis, polymyositis, vasculitis, parotitis, and chronic active hepatitis may be associated with secondary Sjögren's syndrome.

Immunogenetic typing studies have indicated statistically significant expression of various histocompatibility antigens in patients with primary and secondary forms of the syndrome. HLA-DR4 antigen is often identified in patients with

BOX 8-6 SJÖGREN'S SYNDROME: POTENTIAL ORGANOPATHY

SKIN
Dryness (reduced sweat production)
Scleroderma
Lupus erythematosus

SALIVARY AND LACRIMAL GLANDS
Enlargement
Xerostomia, dental caries, candidiasis
Keratoconjunctivitis sicca

GASTROINTESTINAL TRACT
Biliary cirrhosis
Hepatitis

RESPIRATORY TRACT
Rhinitis, pharyngitis
Obstructive pulmonary disease

CARDIOVASCULAR SYSTEM
Vasculitis

MUSCULOSKELETAL SYSTEM
Rheumatoid arthritis
Myositis

HEMATOPOIETIC SYSTEM
Lymphoma
Anemia, leukopenia

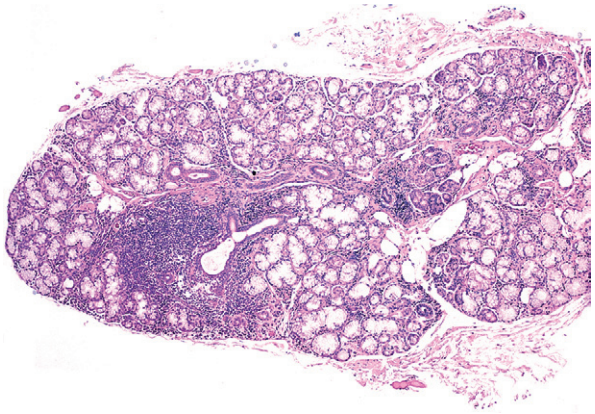

■ **FIGURE 8-13 Sjögren's syndrome,** minor salivary gland expression. Note lymphocytic focus adjacent to intact acini.

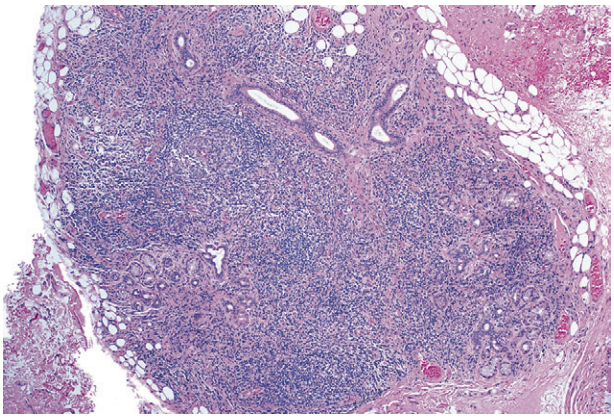

■ **FIGURE 8-14 Sjögren's syndrome,** minor salivary gland expression. Note confluent lymphocytic foci without evidence of scarring.

secondary Sjögren's syndrome; antigens found in patients with the primary form include HLA-B8 and HLA-DR3 types.

Histopathology. In individuals with Sjögren's syndrome, a benign lymphocytic infiltrate replaces major salivary gland parenchyma. The initial lesion is focal periductal aggregation of lymphocytes and occasionally plasma cells. As inflammatory foci enlarge, a corresponding level of acinar degeneration is seen (Figures 8-13 and 8-14). With increasing lymphocytic infiltration, confluence of inflammatory foci occurs. Epimyoepithelial islands are present in major glands in approximately 40% of cases and are only rarely seen in minor glands. A positive correlation in the pattern and extent of infiltration between labial salivary glands and submandibular and parotid glands is noted in patients with Sjögren's syndrome.

An objective grading system has been developed for assessing the salivary component (lymphocytic sialadenitis) of Sjögren's syndrome in labial salivary gland biopsy specimens. A glandular area that contains 50 or more lymphocytes is designated as a *focus*. More than one focus in 4 mm^2 is regarded as consistent with the salivary component of Sjögren's syndrome. Interpretation of labial gland biopsy specimens should be done with the knowledge that infiltrates may be seen both in normal glands and in glands that are inflamed for other reasons, including myasthenia gravis, bone marrow transplantation, other connective tissue diseases, and obstructive phenomena.

Diagnosis. Diagnosis depends on the correlation between patient history and laboratory data, clinical examination, and assessment of salivary function. An important consideration concerns the clinical manifestation of xerostomia. Although this is the main oral symptom and clinical sign in Sjögren's syndrome, other considerations of dry mouth must be evaluated. In addition, major salivary gland enlargement is a feature of Sjögren's syndrome, but it may be episodic in nature and may not be present at all in some patients. Sialographic and salivary scintigraphic findings generally are not specific and should be incorporated into other clinical and laboratory studies, including a minor salivary gland biopsy, as one considers the diagnosis of Sjögren's syndrome.

Treatment. Sjögren's syndrome and the complication of the sicca component are best managed symptomatically. Artificial saliva and oral lubricants as well as artificial tears are available for this purpose. Preventive oral measures are extremely important relative to xerostomia. Scrupulous oral hygiene, dietary modification, topical fluoride therapy, and remineralizing solutions are important in maintaining oral and dental tissues. Use of sialagogues, such as pilocarpine and cevimeline, remains of limited value, especially in long-standing Sjögren's syndrome. Dietary considerations also are important, whereby the patient must avoid intake of caffeine-containing drinks and foods and limit consumption of cariogenic foods and drinks.

The prognosis of Sjögren's syndrome is complicated by an association with malignant transformation to lymphoma. This may occur in approximately 5% of cases, but it is more common in those with only the sicca component of the syndrome (primary Sjögren's syndrome).

Generally, the course for Sjögren's syndrome is one of chronicity, requiring long-term symptomatic management. Careful follow-up and management by a dentist, ophthalmologist, and rheumatologist, among others, are critical. In cases of severe primary Sjögren's syndrome with systemic complications, a promising treatment option is the use of anti-CD20 monoclonal antibody (rituximab), although this remains an open issue in the absence of randomized controlled trials.

Salivary Lymphoepithelial Lesion

An uncommon cause of major salivary gland enlargement is the *benign (salivary) lymphoepithelial lesion (BLEL).* The condition presents as a persistent, nonpainful, firm, unilateral or bilateral mass in a major salivary gland. Although this lesion most commonly occurs in the setting of Sjögren's syndrome, it has been reported in the absence of the disease. Histopathology classically shows effacement of salivary tissue by a dense infiltrate of lymphocytes and plasma cells. This is associated with proliferation of the ductal components to produce irregular islands of epithelium that are called *epimyoepithelial islands*.

Although the term *benign lymphoepithelial lesion* has enjoyed common usage, other terms, including *myoepithelial sialadenitis* and *immunosialadenitis,* have been suggested. Unfortunately, none of these appropriately reflect the biology of this lesion, because studies of the natural history, histopathology, immunology, and molecular biology now support the concept that many are not "benign" but, rather, represent occult lymphoma of the marginal zone type. Differentiation of benign lymphoid infiltrate from low-grade malignant lymphoma is difficult in this setting and rests on the identification of lymphocyte monotypia by molecular or immunohistochemical methods. The term *salivary lymphoepithelial lesion* has been proposed as a more accurate descriptor of the basic pathologic lesion and its anatomic location without implicit reference to the underlying or potential biology of the disease.

Scleroderma

Scleroderma is a chronic disease of unknown cause, although it is generally regarded as an immune dysfunction condition. Two basic forms are recognized: a relatively inconsequential but disfiguring localized cutaneous form known as *morphea,* and a potentially life-threatening form known as *systemic scleroderma.* The remainder of this discussion focuses on the systemic type. It often occurs in conjunction with other autoimmune conditions such as rheumatoid arthritis, lupus erythematosus, dermatomyositis, and Sjögren's syndrome. Rheumatoid factor and antinuclear antibodies are typically demonstrable in patients with scleroderma. Hypergammaglobulinemia and an elevated erythrocyte sedimentation rate are also noted. Along with an increased rate of collagen synthesis is the appearance of vascular changes. Inflammatory and obstructive changes are seen microscopically in arterioles and capillaries, supporting the notion that vessel changes are important in the pathogenesis of scleroderma. Also, Raynaud's phenomenon, a peripheral vascular condition, often precedes the other manifestations of the disease. Systemic scleroderma appears usually during middle age (30 to 50 years) and predominantly in women (4:1). No racial predilection has been noted.

Clinical Features. The disease can affect any organ and may progress to affect many organ systems (Figures 8-15 to 8-17). The skin is typically affected first, although joint involvement may provide the initial sign. In time, as fibrosis of organs progresses, signs of organ failure begin to appear.

Cutaneous manifestations are typified by pitting edema early in the disease process, followed by tightness and rigidity of the skin. The skin eventually becomes indurated, smooth, and atrophic, with telangiectasias. The face becomes expressionless and seems masklike. Fibrosis of the fingers leads to stiffness and atrophy of the skin over the digits. Vascular compromise may result in ischemia and ulceration



■ **FIGURE 8-15 Scleroderma;** perioral fibrosis limiting the oral opening.



■ **FIGURE 8-16 Scleroderma** resulting in thickened and shortened fingertips.

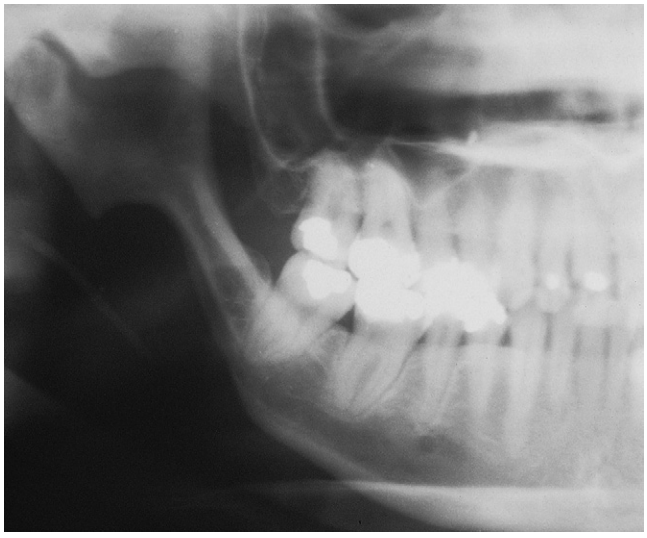

■ **FIGURE 8-17 Scleroderma** resulting in resorption of the posterior ramus.

of the fingertips—a phenomenon seen in both scleroderma and Raynaud's phenomenon.

The rigidity of the perioral skin causes restriction of the oral orifice. Oral hygiene and routine dental care become difficult. Fibrosis of the salivary glands gives rise to xerostomia and potentially to cervical caries. Mandibular bone resorption and uniformly widened periodontal membranes (as seen in periapical films) are also characteristic oral manifestations of this disease.

Histopathology. The primary histologic feature of scleroderma is the deposition of vast amounts of relatively acellular collagen. Perivascular lymphocytic infiltrates are also typical. Minor salivary gland changes include pronounced interstitial fibrosis and acinar atrophy.

Treatment. Systemic disease stabilizes in most patients after a time. Patients with progressive disease are likely to succumb to renal, cardiac, or pulmonary failure. Other than supportive therapy, no satisfactory treatment is available for scleroderma. Corticosteroids may provide some benefit early but are not likely to give lasting control in progressive cases. Immunosuppressive drugs such as azathioprine have shown some promise.

BOX 8-7 CAUSES OF XEROSTOMIA

MEDICATIONS
Analgesics
Opioids
Anticholinergic drugs
Antihistamines
Antidepressants
Selective serotonin reuptake inhibitors (SSRIs)
Tricyclic and heterocyclic antidepressants
Atypical antidepressants
Antihypertensive agents
Diuretics
Muscle relaxants
Sedatives/anxiolytics

AUTOIMMUNE OR SYSTEMIC DISEASES
Sjögren's syndrome
  Primary
  Secondary
Primary biliary cirrhosis
Wegener's granulomatosis
Sarcoidosis
Scleroderma

OTHER CONDITIONS
Local radiation therapy
Type 1 or 2 diabetes
Radioactive iodine treatment
Human immunodeficiency virus (HIV)/acquired immunodeficiency syndrome (AIDS)
Anxiety/depression

Xerostomia

Etiology. Dry mouth or xerostomia is defined as an overall reduction in salivary output. This condition affects up to 30% of sampled populations by self-reporting and by salivary output testing. Many causes for xerostomia are known (Box 8-7), including anxiety, autoimmune disease (Sjögren's syndrome), diabetes mellitus, chemotherapy, external beam radiotherapy to the oral and head and neck regions, radioactive iodine treatment for thyroid malignancy, and many commonly used medications. (See following section on taste disturbances.) The role of aging and of associated salivary dysfunction remains controversial; however, recent studies

have postulated that, although a demonstrable secretory reserve is present to preserve function, an overall loss of acinar cells occurs with aging. Moreover, it has also been shown that xerogenic drugs more adversely impact healthy older adults compared with younger adults, for whom secretory reserve is higher. From a dietary perspective, caffeine remains the most important and the most commonly identified agent that contributes to xerostomia. In addition, the role of alcohol consumption must be recognized as a modifying factor in xerostomia. Transient dry mouth often may be a more subjective symptom, in particular in relation to various psychosocial factors and anxiety.

Clinical Features. The clinical presentation of xerostomia is the same regardless of the cause. Patients complain of various symptoms, in particular difficulty in talking or swallowing, altered taste, generalized oral discomfort, and, if worn, poor retention of dentures. Usually, a reduction in salivary flow of more than 50% is required before clinical symptoms develop. Examination will reveal lack of saliva in the floor of mouth, and attempts to express saliva from the major salivary duct openings by external pressure on the gland may fail. In addition to being reduced in amount, any saliva that is present may be frothy. Lack of saliva will produce generalized erythema of the oral mucosa and a lobulated appearance on the dorsum of the tongue. There is also likely to be evidence of candidiasis and angular cheilitis. The teeth are prone to cervical caries, and existing restorations may fail because of recurrent caries. Patients with xerostomia are predisposed to recurrent episodes of suppurative sialadenitis, particularly of the parotid gland.

The impact of chronic xerostomia is clinically significant because of associated difficulty in eating, speaking, and swallowing, and because of alterations in taste. Xerostomia-associated dental caries is a serious complication of reduced salivary flow. The net result often consists of diminished nutritional status, malnutrition, and decreased social interaction. Also seen in association with dry mouth are oral burning and mucosal soreness.

Treatment. Management of the patient with xerostomia is generally directed toward palliation and requires a careful multifactorial approach, wherein local and systemic factors are considered, along with analysis of all prescription and over-the-counter medications and diet. Direct interventional strategies include the use of topical agents such as oral polymer-based sprays, so-called saliva substitutes, sipping of small amounts of water during the day, drug modification when possible, elimination of caffeine-containing products, chewing of sugar-free gum, and elimination of alcohol-containing mouth rinses (Box 8-8). Obviously, excellent oral hygiene, topical fluoride application, and careful dental follow-up are required to help prevent or control dental caries. In some cases, cholinergic agonists including pilocarpine and cevimeline may be helpful, as may the use of acupuncture.

BOX 8-8 MANAGEMENT OF XEROSTOMIA

PALLIATION

Elimination of alcohol and caffeine consumption
Elimination of alcohol-containing mouth rinses
Gustatory salivary stimulation
Sugarless candies, gum
Moist sugar-free or complex carbohydrate foods
Oral lubricants
Carboxymethylcellulose- or hydroxymethylcellulose-based products
Other polymer-based rinses
Scrupulous oral hygiene

PRESCRIPTION STRATEGIES

Cholinergic agonists
Pilocarpine
Cevimeline
Acupuncture

Taste Disturbances

Taste or gustation relates to the perception of four basic elements and their relationship to each other. These four elements include the modalities of sweet, salty, sour, and bitter. In concert and in combination they form a *flavor,* derived from the collective sense of smell and trigeminal inputs of texture, temperature, and pungency over surfaces of the tongue, oral cavity, and nasal cavity. The complex relationships between these components often become distorted, leading to disturbances in taste, including hypogeusia (blunted taste), ageusia (absence of taste), cacogeusia (unpleasant or obnoxious taste associated with familiar previously acceptable foods), and dysgeusia (altered or incongruous taste perception or a persistent misinterpretation of normal taste sensation). Alterations in taste can be minimal and only slightly bothersome to incapacitating, with possible resultant depression and anorexia as secondary clinical events.

Although dental practitioners do not routinely perform qualitative testing of the basic taste modalities, thorough review of a patient's medical and surgical history and careful oral examination may provide clues or direction concerning possible cause(s). Oral mucosal diseases, including candidiasis, must be addressed as important potential etiologic factors. Upper airway surgery (paranasal sinus procedures), viral infection, or neoplasia may alter olfactory function, thus secondarily affecting taste perception. Tonsillectomy and orofacial-orthognathic surgical procedures may produce chorda tympani injury, thus affecting at least one-sided taste function. Many diseases are capable of inducing taste aberrations (Box 8-9), as are representatives of several drug classes (Box 8-10). Habits, in particular moderate to heavy smoking and use of smokeless tobacco, have been associated with hypogeusia. Xerostomia, as a complication

BOX 8-9 DISEASES ASSOCIATED WITH TASTE DISTURBANCES

Bell's palsy
Cancer/oral—head and neck irradiation
Candidiasis (thrush)—oral
Diabetes mellitus with associated peripheral neuropathy
Gingivitis, periodontitis
Hypothyroidism
Multiple sclerosis
Parkinsonism
Pernicious anemia (vitamin B_{12} related)
Renal failure/hemodialysis
Sjögren's syndrome
Upper respiratory disturbances and infection/influenza
Zinc deficiency

BOX 8-10 DRUG CLASSES AND AGENTS ASSOCIATED WITH TASTE DISTURBANCES

Angiotensin-converting enzyme (ACE) inhibitors
Calcium antagonists
Diuretics
Antiarrhythmics
Antithyroid agents
Antidiabetics
Antihistamines
Antiasthmatics
Antidepressants
Antipsychotics
Antineoplastics
Chelating agents
Neuromuscular/antiseizure drugs
Nitroglycerin
Opioids

of anticholinergic drug use or as a component of Sjögren's syndrome, may commonly produce an associated decrease in taste, possibly secondary to incomplete food solubilization, and by diminished transport of tastant molecules to taste buds. This problem is often underreported within the elderly population as a result of polypharmacy on one hand and direct effects of some drugs on taste sensation and xerogenic effects of drugs on the other, mimicking a Sjögren's syndrome effect. Individuals who have undergone radiation therapy to the oral and head and neck regions for malignant tumors often experience taste disturbances as a result of both direct damage to taste buds and salivary dysfunction. Finally, those complaining of idiopathic burning mouth syndrome commonly state a concomitant taste alteration, usually dysgeusia of the metallic to salty type.

Management of this problem remains difficult and limited. Resumption of normal taste function may be realized by management of any metabolic or endocrine abnormality. Relative to drug-induced taste dysfunction, the use of vitamin and mineral replacement has been advocated, although with unpredictable and transient benefits. Consideration of switching of drugs known to interfere with taste alteration to an alternate class may be helpful. Evaluation of diagnosed olfactory alterations, including anosmia or hyposmia, and management of such are important considerations in the treatment of any taste disturbance. For patients with demonstrable xerostomia, salivary stimulation with sialogogues may be useful. Studies on idiopathic dysgeusia have demonstrated improvement with alpha lipoic acid therapy, suggesting a possible neuropathic axis, similar to that proposed in burning mouth syndrome, which occurs with accompanying dysgeusia.

In addition, patients must be counseled concerning their role in management. This includes several aspects of food intake such as increasing texture, maximizing smell, and avoiding food spoilage.

Halitosis

A common complaint in adults, halitosis (bad breath; fetor ex oris) is characterized by a wide variety of causes, with the possible inclusion of altered taste as a complaint as well. Although the precise incidence is not known, a preliminary report noted that up to 40% of adults do complain about this issue in the morning hours. It is more common in those with nasal obstruction or those who sleep in a hot, dry environment. Up to 17% of adults state that halitosis is a concern at one time or another, and 1% or less indicate that their lives are disrupted as a result.

Halitosis originates chiefly from the mouth and less so from the nose, tonsils (tonsillitis, tonsilliths), and a wide variety of other sites (Box 8-11). Within the mouth, gingival and periodontal diseases are the most important drivers of malodor, where a specific periodontal pathogen, *Porphyromonas gingivalis,* is a known producer of methyl mercaptan. A broad range of medical conditions and factors can be related to the development or promotion of xerostomia, including oral, oropharyngeal, and upper airway diseases; metabolic diseases; dietary constituents including alcohol, tobacco, and sulfur-containing foods; onion and garlic in particular. In cases of a negative evaluation and failure to confirm the presence of halitosis by others in the patient's family or friends, consideration must be given to the possibility of a hypochondria, or delusional halitosis.

An objective assessment on the part of the patient is difficult; a third party is often needed to confirm the presence of malodor, its intensity at the time of evaluation, and comparison of the stated odor at other times. Variations in breath quality fluctuate with time of day and generally are related inversely to salivary flow rates. The concept of delusional halitosis is well known and likely accounts for a significant

BOX 8-11 ANATOMIC ORIGINS OF HALITOSIS

- Oral cavity
  - Poor oral hygiene/prosthesis hygiene
  - Posterior dorsal surface of tongue
- Periodontal pathogens
  - *Porphyromonas gingivalis*
  - *Prevotella intermedia*
  - *Fusobacterium nucleatum*
  - *Bacteroides forsythensis*
  - *Treponema denticola*
- Oral infection (primary and secondary)
  - Candidiasis
  - Pericoronitis
  - Postextraction alveolitis
- Oral ulcerative and erosive diseases
- Dietary considerations
  - Volatile sulfur-containing foods (onions, garlic, others)
  - Hydrogen sulfide
  - Dimethyl disulfide
  - Methyl mercaptan
- Xerostomia
- Nasal cavity
  - Nasal infection
  - Sinusitis
  - Nasal polyps and nasal foreign bodies
- Other airflow obstruction
  - Tonsils
  - Infection
  - Tonsilliths
  - Neoplasia
- Other sites
  - Bronchial and pulmonary infection
  - Renal failure

portion of those who complain of oral malodor. When objectively assessed, these individuals are found not to have halitosis but remain unconvinced. Ultimately, no organic oral disease will be found to account for their complaint.

Specific methods of breath analysis include the organoleptic approach, coming from the mouth and nose, and comparing the two. Monitoring devices capable of detecting levels of sulfide and mercaptan compounds are available at specialty sites, as is the capability for microbiological assessment with darkfield techniques and testing for benzoyl-arginine-naphthylamide (BANA). Gas chromatographic analysis is considered the gold standard but is impractical within the routine patient care setting.

Management of this problem subsequent to establishment of an oral cause includes routine dental treatment and proper oral hygiene measures, maintenance of removable prostheses, gentle surface cleaning of the posterior dorsum of the tongue, remaining hydrated, and avoiding consumption of foods containing sulfide compounds (Box 8-12). Mouth rinses containing chlorhexidine, chlorine dioxide, benzalkonium chloride, or zinc salts may have a role in management, but this is unproven. Commercial mouthwashes contain high concentrations of alcohol and flavoring agents and likely work only to temporarily camouflage malodor caused by organic oral disease. Finally, after a thorough evaluation or treatment course without detectable halitosis on examination in the face of continued complaints, referral for a psychiatric evaluation should be considered for hypochondria or delusion.

BOX 8-12 MANAGEMENT OF HALITOSIS OF ORAL ORIGIN

- Proper oral and prosthesis hygiene
- Treatment of existing dental and periodontal disease
- Daily gentle scraping of the posterior dorsum of the tongue
- Avoidance of foods containing sulfide compounds
- Daily use of mouth rinses with antimicrobial properties

BENIGN NEOPLASMS

At approximately 5 months of embryonic development, a characteristic lobular architecture of salivary glands becomes established. As branching morphogenesis continues, terminal tubular elements give rise to striated intralobular ducts, intercalated ducts, acini, and myoepithelial cells. Intralobular and interlobular ducts of the excretory system arise from the remaining progenitor stalk cells. A stem cell or a reserve cell within the salivary duct system is believed by many to be the cell of origin of salivary gland neoplasms (Box 8-13). Because of their relatively undifferentiated ultrastructural appearance, intercalated duct cells are thought to be capable of giving rise to these neoplasms. The importance of the myoepithelial cell in the composition and growth of numerous epithelial salivary tumors is considerable. Cells with a myoepithelial phenotype can be seen in all salivary gland tumors and are particularly abundant in mixed tumors, myoepitheliomas, adenoid cystic carcinomas, and epimyoepithelial carcinomas of intercalated duct origin.

The three major paired salivary glands—parotid, submandibular, and sublingual—plus the hundreds of small minor salivary glands located within the submucosa of the oral cavity and oropharynx are capable of giving rise to a wide range of neoplasms. A vast majority of salivary neoplasms are epithelial in origin; rarely, the interstitial connective tissue components of the major salivary glands give rise to primary neoplasms whose behavior is similar to that of their extraglandular counterparts. The ratio of benign to malignant salivary gland tumors is gland dependent (Table 8-1).

BOX 8-13 BENIGN SALIVARY GLAND TUMORS

Mixed tumor (pleomorphic adenoma)
Monomorphic adenomas
- Basal cell adenomas—solid, tubular, trabecular, membranous
- Canalicular adenoma
- Myoepithelioma
- Oncocytoma
- Warthin's tumor and papillary cystadenoma

Sebaceous adenoma
Ductal papilloma
Inverted ductal papilloma
Sialadenoma papilliferum
Intraductal papilloma

TABLE 8-1 SALIVARY GLAND TUMORS

	Frequency, %	% Malignant
Parotid glands	65	25
Submandibular glands	10	40
Sublingual glands	<1	90
Minor salivary glands	25	50

Mixed Tumor (Pleomorphic Adenoma)

The histogenesis of mixed tumor, or pleomorphic adenoma, relates to dual proliferation and co-mingling of cells with ductal or myoepithelial features in a stroma of mucoid, myxoid, and, less commonly, chondroid quality. This separates it from monomorphic adenomas composed of only one cell type and a more homogeneous or less varied stroma. The myoepithelial-differentiated cell assumes an important role in determining the overall composition and appearance of mixed tumors. A range of cell types and microscopic patterns are seen in mixed tumors—those composed almost completely of epithelial cells at one end of a spectrum and those composed almost completely of myoepithelial cells at the other end. Between these two extremes, less well developed cells with features of both myoepithelial and ductal elements may be seen. Alternatively, it has been theorized that rather than simultaneous proliferation of neoplastic epithelial and myoepithelial cells, a single cell with the potential to differentiate toward either epithelial or myoepithelial cells may be responsible for these tumors. This latter concept is supported by molecular evidence using the human androgen receptor gene assay (HUMARA).

Clinical Features. The mixed tumor is the most common tumor of the major and minor salivary glands (Box 8-14). The parotid gland accounts for approximately 85% of these tumors, whereas the submandibular gland and the intraoral minor salivary glands account for 8% and 7%, respectively. Mixed tumors occur at any age, favor males slightly more than females, and are most prevalent in the fourth through sixth decades of life. They constitute approximately 50% of all intraoral minor salivary gland tumors. Generally, they are mobile, except when they occur in the hard palate. They appear as firm, painless swellings and, in the vast majority of cases, do not cause ulceration of the overlying mucosa (Figure 8-18). The palate is the most common intraoral site, followed by the upper lip and buccal mucosa.

When they arise within the parotid gland, mixed tumors are generally painless and slow-growing. They are usually located below the ear and posterior to the mandible. They are smooth, firm, and mobile unless they achieve large size, when they may become multinodular or bosselated. Some tumors may be grooved by the posterior extent of the mandibular ramus, with long-standing lesions capable of producing pressure atrophy on this bone. When they are situated within the inferior pole or tail of the parotid, the tumors may present below the angle of the mandible and anterior to the sternocleidomastoid muscle. When arising within the deep lobe of the parotid gland, they are nonpalpable and usually present as a mass within the lateral pharyngeal region.



■ **FIGURE 8-18 Mixed tumor** of the palate.

BOX 8-14 MIXED TUMOR

CLINICAL FEATURES
Adults; men and women affected equally
Asymptomatic submucosal mass
Sites—palate > upper lip > buccal mucosa > other sites

HISTOPATHOLOGY
Encapsulated; variable glandular patterns; epithelial and myoepithelial differentiation; no mitoses

TREATMENT
Excision; occasional recurrence in major glands

>, More frequently affected than.

Mixed tumors range from a few millimeters to several centimeters in diameter and are capable of reaching giant proportions in the major salivary glands, especially the parotid. The tumor is typically lobulated and enclosed within a connective tissue pseudocapsule that varies in thickness within the major salivary glands, whereas in minor glands, the capsule is poorly defined to absent in areas. Where the capsule is deficient, neoplastic tissue may lie in direct contact with, or may extend into, adjacent salivary tissue and may contribute to recurrences if treatment is excessively conservative (see following text).

Histopathology. Microscopically, mixed tumors demonstrate a wide spectrum of histologic features (Figures 8-19 to 8-22). The pleomorphic patterns and the variable ratios of ductal to myoepithelial cells are responsible for the synonym *pleomorphic adenoma.* A capsule of varying thickness surrounds mesenchymal and stromal components. Approximately one third of mixed tumors show an almost equal ratio of epithelial and mesenchymal elements (believed to be derived from myoepithelial-differentiated cells). The epithelial component may appear as ducts, tubules, ribbons, and solid sheets, and the mesenchymal component may appear as myxoid, hyalinized connective tissue. Infrequently, fat, cartilage, and/or bone may be seen. Myoepithelial cells may appear as plasmacytoid cells or spindled cells with an immunoprofile showing coexpression of cytokeratin markers, vimentin, variable positivity for S-100 protein, calponin, alpha-smooth muscle actin, and muscle-specific actin. The plasmacytoid cells, when seen, are highly characteristic of mixed tumors and are almost never found in other salivary gland tumors. The ductal cell components are positive for several cytokeratins, including 3, 6, 10, 11, 13, and 16.

The pseudocapsule surrounding mixed tumors may demonstrate islands of tissue within it or extending through it. These islands represent outgrowths or pseudopods continuous with the main tumor mass, and likely contribute to recurrences, particularly in the parotid gland.

Treatment and Prognosis. The treatment of choice is surgical excision. Enucleation of mixed tumors within the parotid gland is not recommended because of the risk of

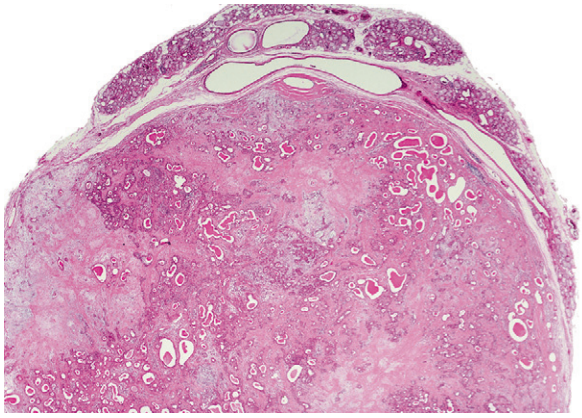

■ **FIGURE 8-19 Mixed tumor** showing encapsulation and heterogeneous pattern.

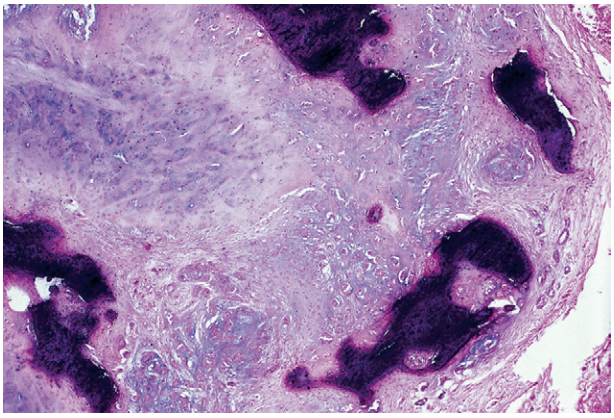

■ **FIGURE 8-21 Mixed tumor** with cartilage *(upper left)* and bone *(dark blue)* differentiation.

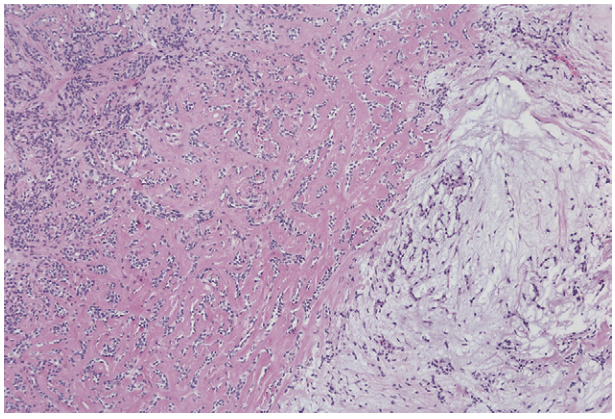

■ **FIGURE 8-20 Mixed tumor** with myxoid component *(right)* and fibrous/epithelial component *(left).*

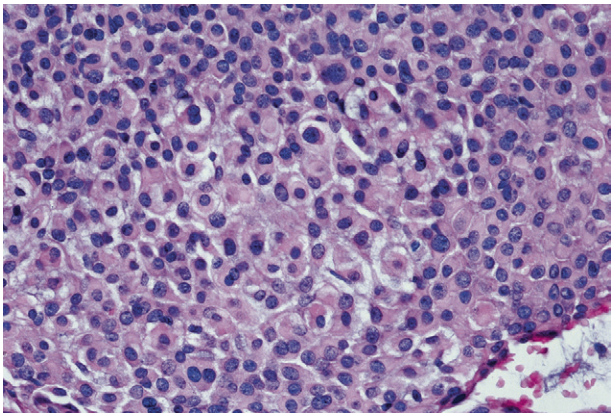

■ **FIGURE 8-22 Mixed tumor** showing plasmacytoid myoepithelial cells.

recurrence due to extension of tumor through capsular defects. Removal of mixed tumors arising within the parotid gland is complicated by the presence of the facial nerve. Any surgical approach, therefore, must include preservation of the uninvolved facial nerve. In most cases, superficial parotidectomy (lateral lobectomy) with preservation of the facial nerve is the most appropriate management for those tumors arising within the parotid. Resection of the submandibular gland is the preferred treatment for mixed tumors in this location. Lesions of the palate or gingiva often involve or abut periosteum or bone, making complete removal difficult, unless some bone is removed. Other oral benign mixed tumors can be more easily excised, preferably including tissue beyond the pseudocapsule.

Inadequate initial removal of mixed tumors in major glands may result in recurrence, often with multiple, discrete tumor foci. Rates of recurrence within the parotid gland are 3.4% at 5 years and 6.8% after 10 years, with a wide range reported. These recurrent lesions may be distributed widely within the area of previous surgery and may occur in association with the surgical scar. In most instances, the recurrent tumor maintains the original pathology; however, with each recurrence, the possibility of malignant transformation (carcinoma ex-mixed tumor) is increased. The proportion of mixed tumors undergoing malignant transformation is not known with certainty, because almost all tumors are treated fairly early in their clinical course. However, if lesions are untreated for an extended length of time, typically years to decades, up to 25% may undergo malignant transformation. The probability of malignant change also increases if the area has been treated previously with surgery or radiotherapy.

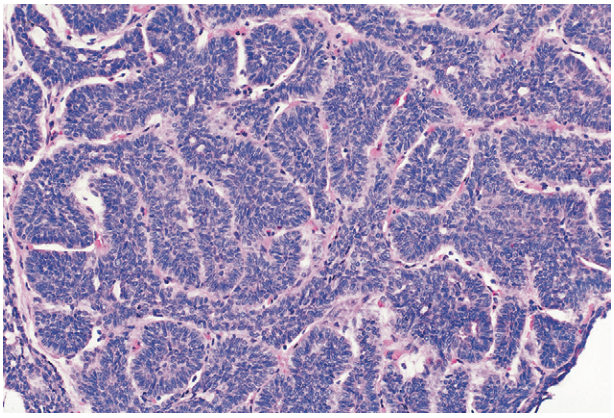

■ **FIGURE 8-23 Basal cell adenoma,** solid pattern.

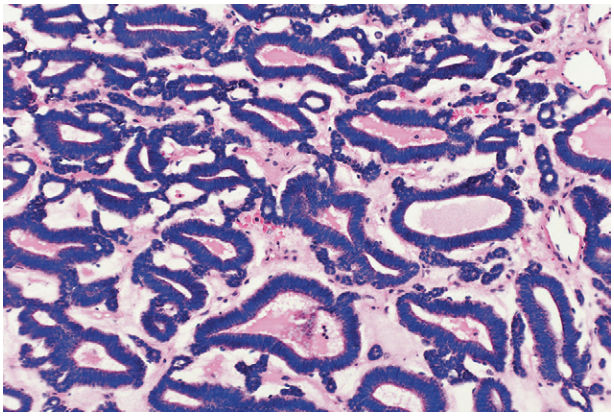

■ **FIGURE 8-24 Basal cell adenoma,** tubular pattern.

Basal Cell Adenoma

Basal cell adenoma, as originally defined, represents a group of benign salivary neoplasms of histologic uniformity, particularly in relation to the benign mixed tumor. Use of this term as a specific diagnostic entity has given way to subdivisions of individual benign salivary gland neoplasms that are composed of isomorphic epithelial cell populations that lack the histologic diversity that characterize mixed tumors. The classification scheme is based on the histologic pattern (see Box 8-13).

Basal cell adenomas constitute approximately 1% to 2% of all salivary gland adenomas. About 70% are found within the parotid followed by the submandibular gland. In minor salivary glands, most occur in the upper lip, followed in frequency by adenomas in the palate, buccal mucosa, and lower lip.

Clinical Features. Basal cell adenomas are generally slow-growing, solitary, and painless. Lesions tend to be clinically distinct and firm on palpation, but they can be multifocal and multinodular. The age range of patients is between 35 and 80 years, with a mean age of approximately 60 years. A distinct male predilection has been noted.

Histopathology. Based on overall architectural features, basal cell adenomas may be separated into four subsets: solid, trabecular, tubular, and membranous forms. In the *solid* variety of basal cell adenoma, islands or sheets of isomorphic basaloid cells often show peripheral palisading, with individual cells at the periphery appearing cuboidal to low columnar in profile (Figure 8-23). The *trabecular* form of basal cell adenoma exhibits thin trabeculae and cords of epithelial cells separated by a delicately vascularized stroma. The *tubular* form shows ductal structures as the dominant feature with lining cells of cuboidal type surrounded by single or multiple layers of basaloid cells (Figures 8-24 and 8-25). *Membranous adenoma* grows in a nodular fashion with variably sized islands of tumor tissue surrounded by a thick periodic acid–Schiff (PAS)-positive hyaline membrane. Similar, if not identical, eosinophilic hyaline material is noted in droplet form within the intercellular areas of the tumor islands, similar to those noted in collagenous spherulosis of the breast and polycystic adenosis of salivary glands. Membranous adenomas may also contain foci of normal salivary gland, giving the erroneous impression of invasiveness and necessitating separation from adenoid cystic carcinoma.

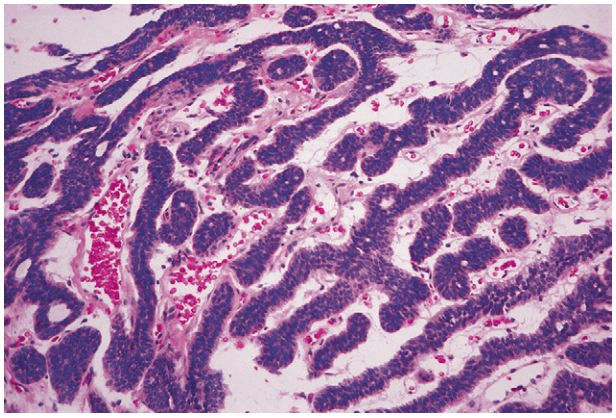

■ **FIGURE 8-25 Basal cell adenoma,** trabecular pattern.

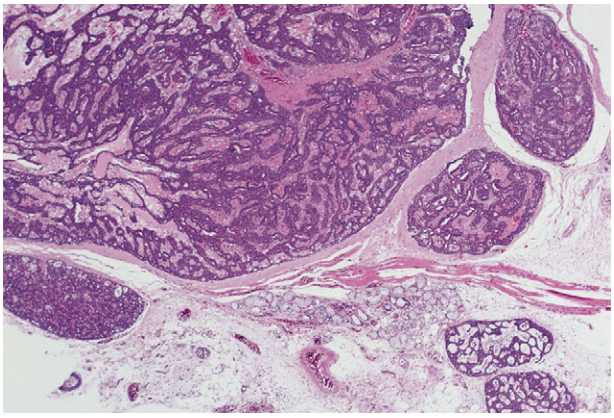

■ **FIGURE 8-26 Canalicular adenoma** with multiple foci.

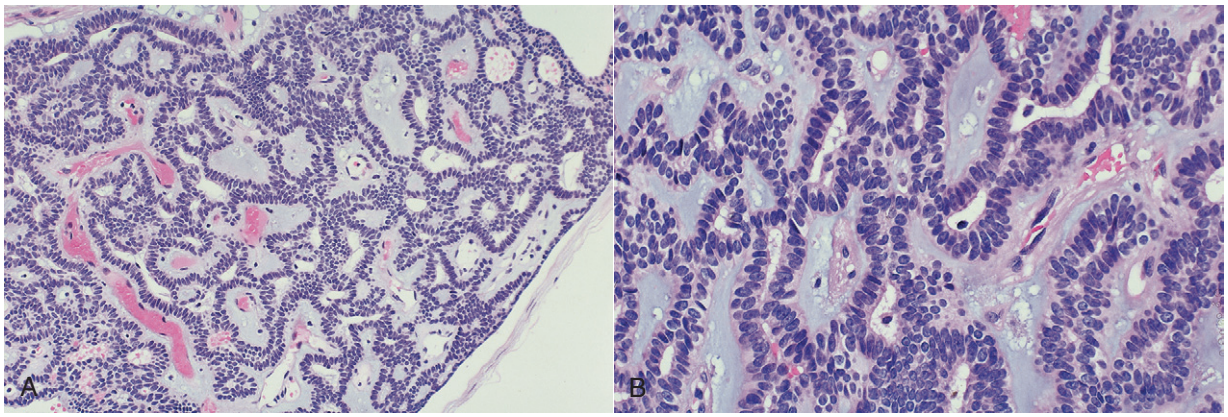

■ **FIGURE 8-27 A** and **B, Canalicular adenoma.** Note vascular stroma.

The *membranous (basal cell) adenoma (dermal analog tumor)* variant occurs predominantly in the parotid gland (>90% of cases), with few cases occurring in the other major glands. These lesions range from 1 to 5 cm in greatest dimension and generally present as an asymptomatic swelling. Several patients with this particular finding in the parotid gland have presented with synchronous or metachronous adnexal cutaneous tumors, including dermal cylindroma, trichoepithelioma, and eccrine spiradenoma.

Treatment and Prognosis. Except for membranous adenoma, basal cell adenomas are benign and rarely recur. The membranous form of basal cell adenoma has a significant rate of recurrence because of its growth pattern and multifocal nature. Preferred management consists of conservative surgical excision, including a margin of normal uninvolved tissue.

Canalicular Adenoma

Canalicular adenoma is generally separated from other basal cell adenomas because it occurs almost exclusively within the oral cavity, where it accounts for up to 6% of all minor salivary gland neoplasms. This benign neoplasm occurs most commonly in the upper lip and has distinctive histologic features. Its biological behavior is, however, similar to that of the general group of basal cell adenomas.

Clinical Features. A narrow age range is noted in patients with canalicular adenomas. Most patients tend to be older than 50 years of age, and most patients are women. The upper lip is by far the most common site for canalicular adenomas, with one series reporting 81% of lesions located in this region. Lesions tend to be freely movable and asymptomatic and range in size from a few millimeters to 2 to 3 cm.

Histopathology. Characteristically, canalicular adenomas show bilayered strands of basaloid cells that branch and anastomose within a delicate stroma that is highly vascular and contains few fibroblasts and little collagen (Figures 8-26 and 8-27). Individual cells are characteristically cuboidal to columnar, with moderate to abundant amounts of eosinophilic cytoplasm. Canalicular adenomas occasionally may not be totally encapsulated, and more than 20% of cases are multifocal.

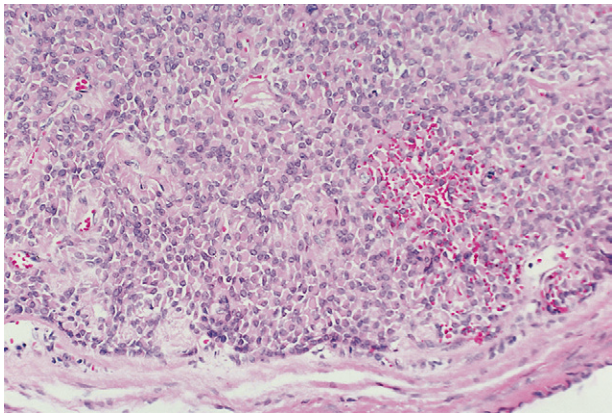

■ **FIGURE 8-28 Myoepithelioma** composed of plasmacytoid myoepithelial cells.

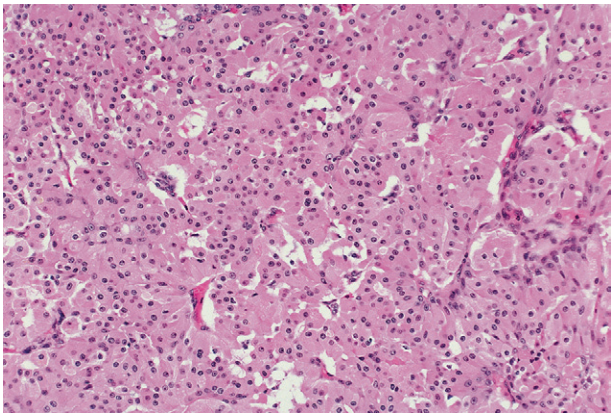

■ **FIGURE 8-29 Oncocytoma** composed of uniform cells with pink cytoplasm and centrally placed nuclei.

Treatment and Prognosis. The treatment of choice for canalicular adenoma is surgical excision with the inclusion of a cuff of clinically normal tissue. The fact that more than 20% of lesions are multifocal may account for some recurrences.

Myoepithelioma

Benign salivary gland tumors composed entirely of myoepithelial cells are called *myoepitheliomas* (Figure 8-28). Although these tumors are of epithelial origin, the phenotypic expression of the tumor cells is more closely related to that of smooth muscle. Reflective of this is the immunohistochemical staining of myoepithelioma cells with antibodies to actins, cytokeratin, and S-100 protein.

Most myoepitheliomas arise within the parotid gland, followed by the intraoral minor salivary glands and, less commonly, the submandibular gland. Clinically, myoepitheliomas present as circumscribed painless masses. Lesions appear from the third through ninth decades (median age, 53 years) and in both genders equally.

Microscopically, sheets of plasmacytoid or spindle cells make up these lesions. Approximately 70% of cases contain spindle cells, and approximately 20% are composed of plasmacytoid cells. Occasionally, both cell forms may be seen in approximately equal quantity. Myoepithelial differentiation of tumor cells has been confirmed with immunohistochemical and electron microscopic studies. Rarely, clear cells may dominate the histologic presentation, leading to the designation of a *clear cell variant* of this entity.

Treatment of this benign lesion is identical to that of the benign mixed tumor. Conservative excision of lesions arising in minor salivary glands is advised, including a thin rim of surrounding normal tissue. When lesions are noted within the parotid gland, superficial parotidectomy is indicated. The overall prognosis is excellent, and recurrences are not expected.

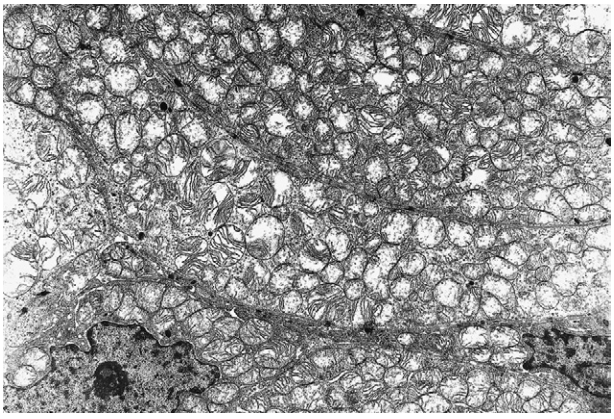

■ **FIGURE 8-30 Oncocytoma,** electron micrograph. Oncocytes filled with mitochondria; nuclei in lower left and right.

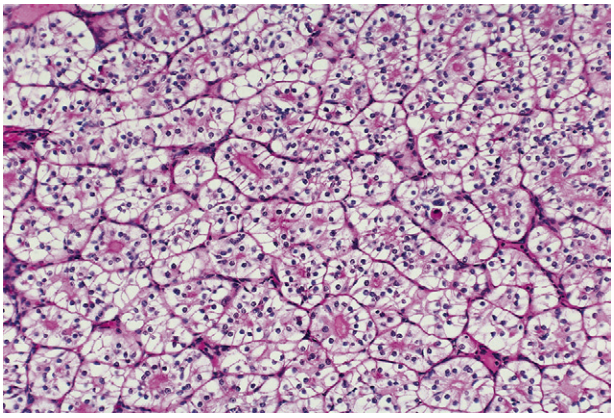

■ **FIGURE 8-31 Oncocytoma** with clear cell change.

Oncocytic Tumors

Oncocytoma. Oncocytoma, or oxyphilic adenoma, is a rare lesion seen predominantly in the parotid gland (Figures 8-29 to 8-31). This lesion is composed of oncocytes, which are large granular acidophilic cells filled with mitochondria. Such cells are normally found in salivary glands in the

intralobular ducts, and they usually increase in number with age. The histogenetic source of this lesion is believed to be the salivary duct epithelium, in particular the striated duct.

Clinically, oncocytomas are solid, ovoid encapsulated lesions, usually smaller than 5 cm in diameter when they are noted within the major salivary glands. In some instances, bilateral occurrence may be noted. These lesions are rarely seen intraorally.

Within individual glands (most often the parotid), a nonneoplastic and multicentric cellular change known as *oncocytosis* may be seen. This metaplasia of salivary duct and acinar cells is seen in the context of an otherwise normal gland. As oncocytic foci enlarge, confusion with oncocytoma may occur.

Microscopically, oncocytoma cells are polyhedral with granular eosinophilic cytoplasm. Nuclei are centrally placed and are typically vesicular. The histologic pattern usually consists of sheets of cells, although microcystic spaces and clear cell changes may be seen. The histochemical stain phosphotungstic acid hematoxylin (PTAH), highlighting the intracytoplasmic mitochondria, is useful to confirm the diagnosis of oncocytoma. Antimitochondrial antibodies may also be used in an immunohistochemical approach to confirm the diagnosis.

The growth rate is slow, and the course is benign. Treatment is conservative, with superficial parotidectomy as the treatment of choice for parotid lesions. In minor salivary glands, removal of the tumor with a margin of normal tissue is deemed adequate. Recurrence is rarely noted.

The malignant oncocytic tumor, or *malignant oncocytoma,* is rare. The diagnosis is based on atypical nuclear changes in oncocytes in conjunction with an invasive pattern. Malignant change may arise de novo, or it may occur in a preexisting benign oncocytoma.

Papillary Cystadenoma Lymphomatosum (Warthin's Tumor). Papillary cystadenoma lymphomatosum, also known as Warthin's tumor, accounts for approximately 7% of epithelial neoplasms of salivary glands, with the vast majority occurring within the parotid gland (Figures 8-32 to 8-34). Intraorally, this lesion is rare. It is seen predominantly in men, typically between the fifth and eighth decades of life. Studies have shown a strong positive correlation between the development of Warthin's tumor and cigarette smoking.

Warthin's tumor is thought to arise within lymph nodes as a result of entrapment of salivary gland elements early in development. This theory is supported by the occasional case of multicentricity, as well as by normal lymph node architecture surrounding many early or developing tumors. This is the most common salivary gland to occur bilaterally, and it is the most common salivary tumor to be synchronously associated with other salivary tumors. It is believed that some intraoral lesions may arise in an area of reactive lymphoid hyperplasia as a result of chronic inflammation.

When it occurs in the parotid, this tumor presents typically as a doughy to cystic mass in the inferior pole of the

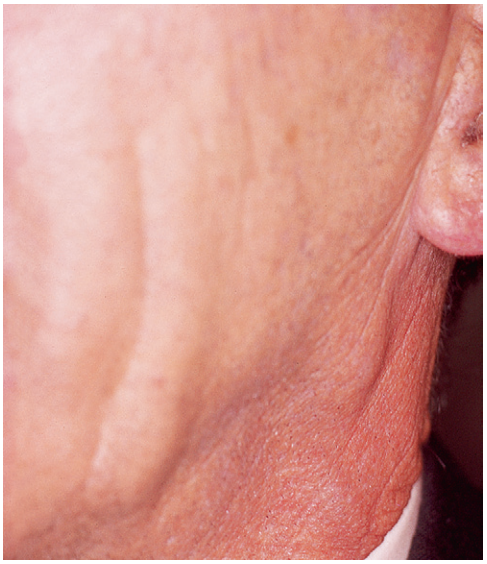

■ **FIGURE 8-32 Papillary cystadenoma lymphomatosum (Warthin's tumor)** in the tail of the parotid gland.

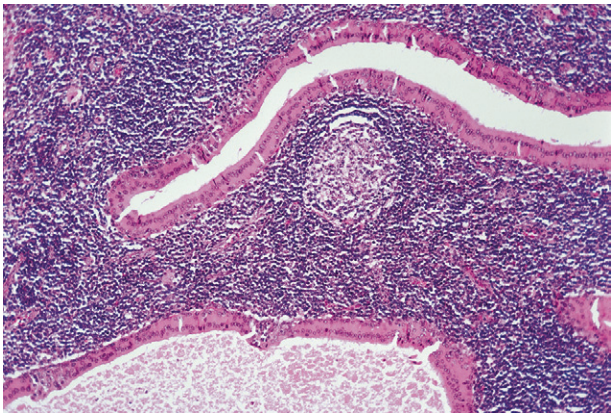

■ **FIGURE 8-33 Warthin's tumor** composed of pink oncocytes and lymphoid tissue.

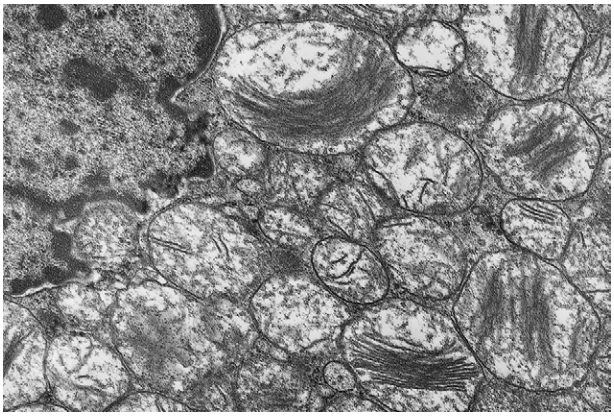

■ **FIGURE 8-34 Warthin's tumor.** Electron micrograph showing oncocytes in tumor cells. Note abundant mitochondria and nucleus *(upper left).*

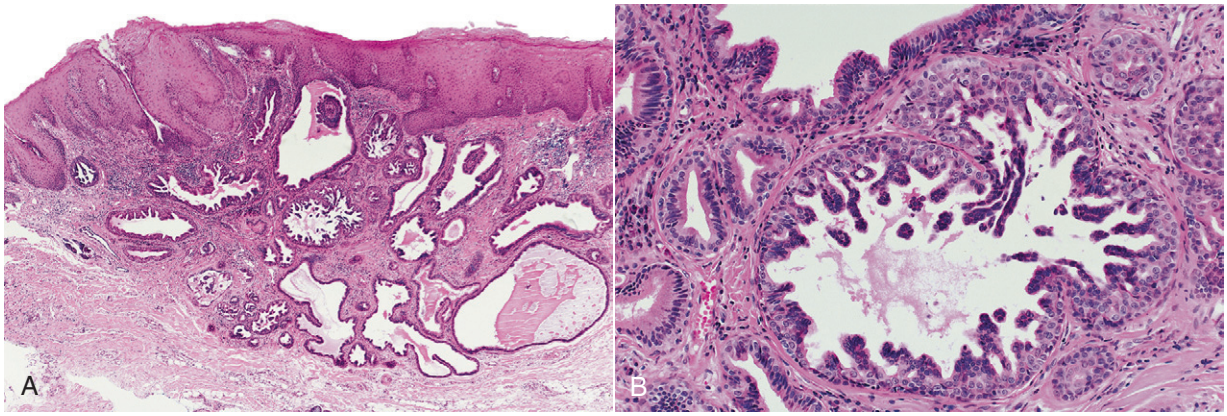

■ **FIGURE 8-35 Sialadenoma papilliferum. A** and **B,** Papillary structures within cystlike spaces.

gland, adjacent and posterior to the angle of the mandible. In this situation, the proximity of the submandibular gland may give the impression that the lesion has developed within this gland, rather than within the parotid.

The tumor is encapsulated and has a smooth to lobulated surface and a round outline. Microscopically, numerous cystic spaces of irregular outline contain papillary projections lined by columnar eosinophilic cells (oncocytes). The lining cells are supported by cuboidal cells that overlie lymphoid tissue with germinal centers.

Recurrences have been reported and documented but are believed to represent second primary lesions. Malignant transformation to carcinoma, especially as a complication of radiotherapy to the region, is rare.

Sebaceous Adenoma

The presence of sebaceous glands or evidence of sebaceous differentiation has been noted in submandibular and parotid salivary glands. This particular tissue, thought to originate in intralobular ducts, gives rise to sebaceous adenoma and to other sebaceous neoplasms designated as sebaceous lymphadenoma, sebaceous carcinoma, and sebaceous lymphadenocarcinoma. These rare lesions (<0.5% of all salivary gland adenomas) are composed predominantly of sebaceous gland–derived cells; they are well differentiated when benign, and moderately to poorly differentiated when malignant. In sebaceous lymphadenoma, a benign lymphoid component is seen. The parotid gland is the site of chief involvement; lesions occur at this location 50% of the time, although intraoral lesions have been reported, chiefly in the buccal mucosa and retromolar region. Parotidectomy is the treatment of choice when lesions arise in this gland. Surgical excision is used in cases of intraoral neoplasms.

Ductal Papilloma

Ductal papillomas comprise sialadenoma papilliferum, inverted ductal papilloma, and intraductal papilloma. These rare tumors are thought to arise within the interlobular and excretory duct portions of the salivary gland unit.

Sialadenoma papilliferum is an unusual benign salivary gland neoplasm that was first reported in 1969 as a distinct entity of minor and major salivary gland origin. Most cases reported subsequently have been found intraorally; the buccal mucosa and the palate are the most common sites.

Sialadenoma papilliferum usually presents as a painless exophytic papillary lesion of the surface mucosa and salivary duct epithelium. Most cases have been reported in men between the fifth and eighth decades of life. The clinical impression before removal is that of a simple papilloma, owing to its frequent keratotic appearance and papillary surface configuration.

This tumor appears to originate from the superficial portion of the salivary gland excretory duct (Figure 8-35). Papillary processes develop, forming convoluted clefts and spaces. Each papillary projection is lined by a layer of epithelium approximately two to three cells thick, and is supported by a core of fibrovascular connective tissue. The more superficial portions of the lesion demonstrate a squamous epithelial lining; deeper portions show more cuboidal to columnar cells, often oncocytic in appearance. As growth continues, the overlying mucous membrane becomes papillary to verrucous in nature, much like a squamous papilloma. This lesion generally resembles syringocystadenoma papilliferum of the scalp, a lesion of eccrine sweat gland origin.

The behavior of this lesion is benign. Management consists of conservative surgery; there is little chance of recurrence.

A related papillary lesion of minor salivary gland duct origin is the *inverted ductal papilloma.* This rare entity presents as a nodular submucosal mass resembling a fibroma or lipoma. It is seen in adults and has an equal gender distribution.

Microscopically, marked proliferation of ductal epithelium is seen subjacent to intact mucosa (Figure 8-36). Crypts and cyst-like spaces lined by columnar cells with polarized nuclei are interspersed with goblet cells and transitional forms of cuboidal to squamous cells as an intraluminal proliferative process with an endophytic growth pattern.

The third form of ductal papilloma is *intraductal papilloma.* This rare lesion arises from a greater depth within the

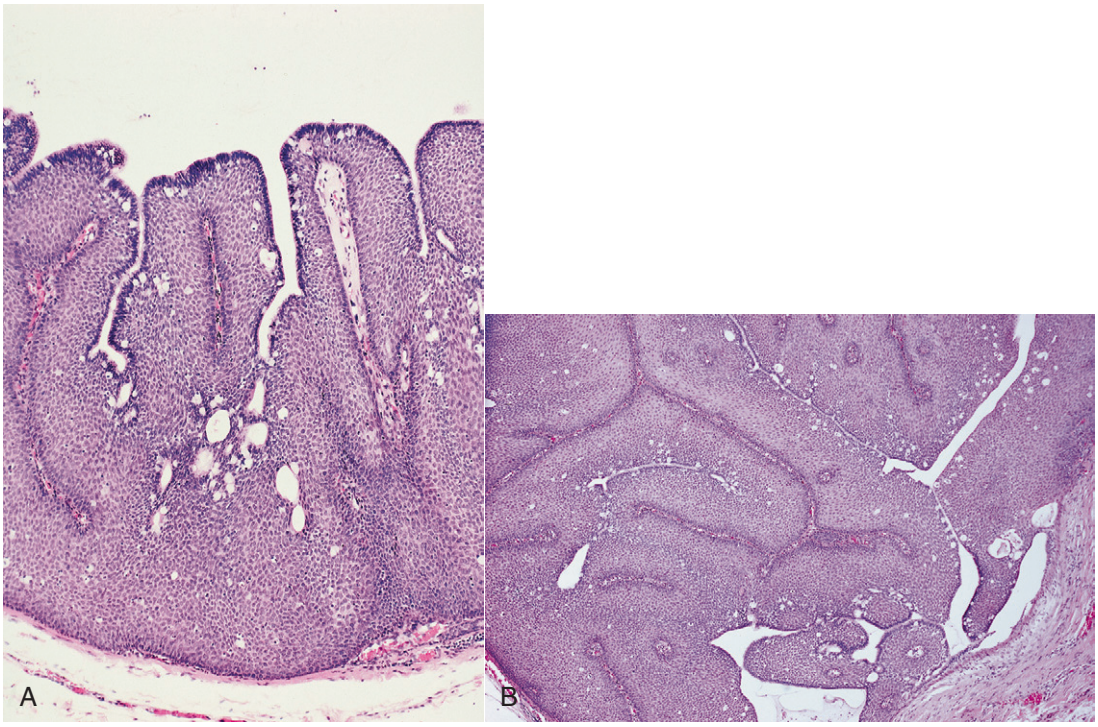

■ **FIGURE 8-36 Inverted ductal papilloma. A** and **B,** Circumscribed folds of bland ductal epithelial cells and occasional mucous cells.

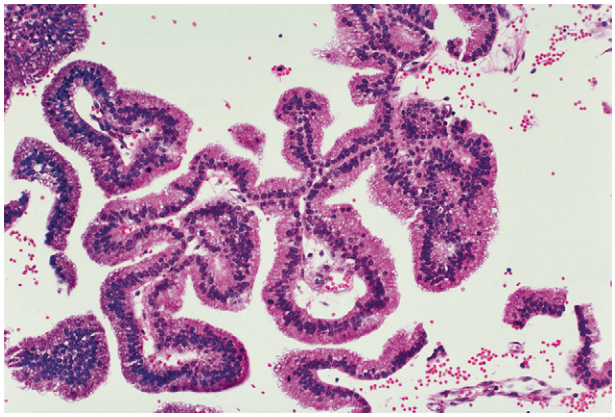

■ **FIGURE 8-37 Intraductal papilloma** composed of fronds of ductal cells. The duct from which this lesion is derived is not included in the photomicrograph.

ductal system, often presenting as a salivary obstruction caused by intraluminal exophytic growth. Histologically, a single or double layer of cuboidal to columnar epithelium covers several papillary fronds that project into a duct, with no evidence of proliferation into the wall of the cyst (Figure 8-37). Treatment for this lesion, as well as for inverted ductal papilloma, is simple excision. There is little risk of recurrence.

MALIGNANT NEOPLASMS

Salivary gland malignancies can be classified in several ways. Box 8-15 lists them according to relative frequency, and Box 8-16 lists them according to biological behavior.

BOX 8-15 MALIGNANT SALIVARY GLAND TUMORS

Mucoepidermoid carcinoma
Polymorphous low-grade adenocarcinoma
Adenoid cystic carcinoma
Clear cell carcinoma
Acinic cell carcinoma
Adenocarcinoma NOS
Rare, predominantly parotid tumors
Carcinoma ex-mixed tumor/malignant mixed tumor
Epimyoepithelial carcinoma
Salivary duct carcinoma
Basal cell adenocarcinoma
Oncocytic adenocarcinoma
Sebaceous adenocarcinoma
Squamous cell carcinoma

NOS, Not otherwise specified.

Box 8-17 provides a summary of the general features that characterize malignancies of minor salivary glands. Table 8-2 compares features of benign and malignant salivary gland tumors.

Mucoepidermoid Carcinoma

Mucoepidermoid carcinomas exhibit biological behaviors that range from low to high grade. All are capable of metastasis, but low-grade mucoepidermoid carcinomas typically

BOX 8-16 MALIGNANT SALIVARY GLAND TUMORS: BIOLOGICAL CLASSIFICATION

LOW-GRADE MALIGNANCIES
Mucoepidermoid carcinoma (low grade)
Polymorphous low-grade adenocarcinoma
Acinic cell carcinoma (low to intermediate grade)
Clear cell carcinoma
Basal cell adenocarcinoma

INTERMEDIATE-GRADE MALIGNANCIES
Mucoepidermoid carcinoma (intermediate grade)
Epimyoepithelial carcinoma
Sebaceous adenocarcinoma

HIGH-GRADE MALIGNANCIES
Mucoepidermoid carcinoma (high grade)
Adenoid cystic carcinoma
Carcinoma ex-mixed tumor
Salivary duct carcinoma
Squamous cell carcinoma
Oncocytic adenocarcinoma

BOX 8-17 MALIGNANT MINOR SALIVARY GLAND TUMORS

CLINICAL FEATURES
Adults; men and women affected equally
Mass or ulcerated mass
Asymptomatic in early stages
Sites—palate > buccal mucosa > retromolar pad > upper lip > tongue
Low-grade mucoepidermoid carcinoma > polymorphous low-grade adenocarcinoma > adenoid cystic carcinoma

HISTOPATHOLOGY
Highly variable but characteristic patterns; infiltrative margins; rare mitoses; little pleomorphism

TREATMENT AND PROGNOSIS
Wide excision; radiation added for problematic cases
Ranges from low- to high-grade behavior (adenoid cystic carcinoma has worst long-term prognosis)

>, More frequently affected than.

pursue a locally invasive, relatively nonaggressive course. As the name implies, mucoepidermoid carcinomas are epithelial mucin-producing tumors. They are believed to arise from reserve cells in the interlobular and intralobular segments of the salivary duct system. Neoplastic mucous cells contain neutral glycoproteins, acidic mucins, and sulfomucins; epidermoid cells contain keratin intermediate filaments.

TABLE 8-2 COMPARISON OF SALIVARY GLAND TUMORS

	Benign	Malignant
Growth rate	Slow	Varied, usually rapid
Ulceration	No	Yes
Fixation	No	Yes
Facial nerve palsy	No	Yes
Encapsulated	Yes	No
Natural history	Slow growth	Slow to rapid growth
Metastasis	No	Yes
Treatment	Local excision	Surgery with or without radiation

BOX 8-18 MUCOEPIDERMOID CARCINOMA

Most common malignancy of salivary glands
Most common salivary malignancy in children
Palate, most common intraoral site; rare primary intrabony (jaws) tumors
Low-, intermediate-, and high-grade lesions
More ducts and mucous cells in low-grade lesions
Most oral lesions of low grade
Low-grade lesions—excellent prognosis (~95%)
High-grade lesions—fair prognosis (~40%)

Clinical Features. The most common site of mucoepidermoid carcinomas is the parotid gland, where 60% to 90% of such lesions are encountered (Box 8-18). This lesion represents the most common malignant tumor of salivary glands and is the most common salivary gland malignancy of childhood. Mucoepidermoid carcinomas account for approximately 34% of parotid malignancies, 20% of submandibular gland malignancies, and 30% of minor salivary gland malignancies. This lesion may arise centrally within the mandible, presumably from embryonically entrapped salivary elements or from neoplastic transformation of mucous cells in odontogenic cysts.

The prevalence of mucoepidermoid carcinoma is noted to be highest in the third through fifth decades of life, and an equal gender representation has been noted. The annual incidence is 0.44 cases per 100,000 persons. Clinical manifestations of this lesion depend greatly on the grade of malignancy (Figure 8-38). Tumors of low-grade malignancy present with a prolonged period of painless enlargement. Within the oral cavity, mucoepidermoid carcinoma often resembles an extravasation or retention-type mucocele that at times may be fluctuant as a result of mucous cyst formation. Tumors of high-grade malignancy, on the other hand, grow rapidly and are often accompanied by pain and mucosal ulceration. Within the major salivary glands, high-grade tumors may present with evidence of facial nerve involvement

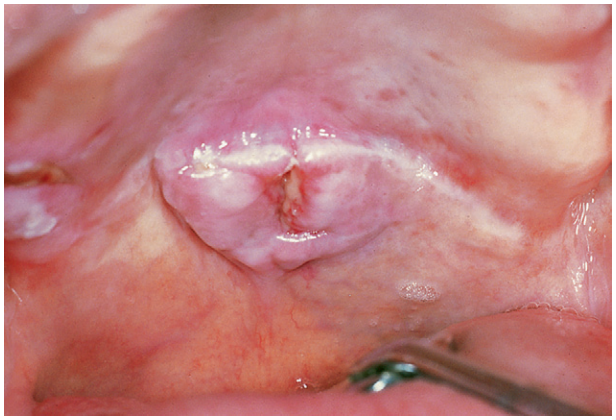

■ **FIGURE 8-38 Mucoepidermoid carcinoma** of the palate.

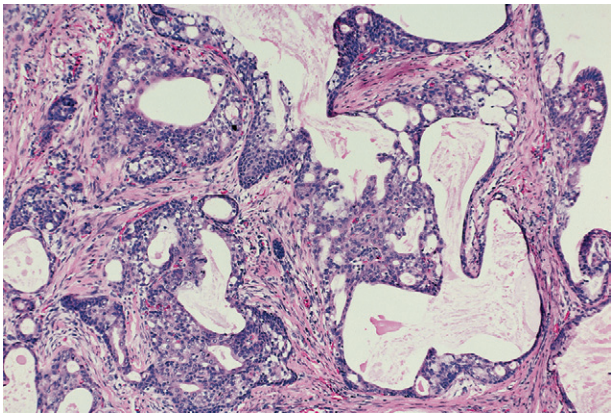

■ **FIGURE 8-39 Mucoepidermoid carcinoma,** low grade. Note cystic spaces and mucous tumor cells.

TABLE 8-3 MUCOEPIDERMOID CARCINOMA: HISTOLOGIC

	Low Grade (Good Prognosis)	High Grade (Fair Prognosis)
Cell type	Numerous mucous cells and intermediate cells; few epidermoid cells	Mainly epidermoid cells and few mucous cells; looks like squamous cell carcinoma
Microcystic spaces	Large and numerous cysts	Few cysts; mainly solid tumor
Cytologic atypia	None to little	Abundant

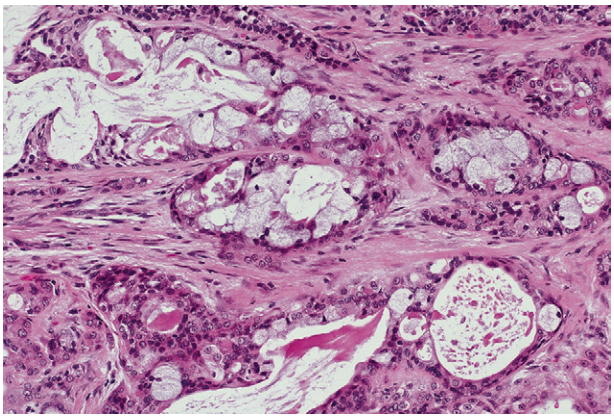

■ **FIGURE 8-40 Mucoepidermoid carcinoma,** low grade. Note cystic spaces and mucous tumor cells.

or obstructive signs. Mucoepidermoid carcinomas in the mandible or maxilla appear as radiolucent lesions within the molar and premolar areas.

Histopathology. Mucoepidermoid carcinomas typically appear as a lobular infiltration of adjacent tissue, although they are often well circumscribed. A wide range of cell type predominance, differentiation, and composition characterizes this neoplasm. Lesions generally are divided into low-, intermediate-, and high-grade types (Table 8-3). Low-grade mucoepidermoid carcinomas are composed of cuboidal to columnar mucus-secreting cells arranged around microcystic structures, with an intermingling of epithelial, or "intermediate," cells with a few epidermoid cells (Figures 8-39 and 8-40). The mucin-containing cells are PAS and mucicarmine positive. Coalescence of small cysts into large cystic spaces is typical of low-grade malignancy. These cysts may distend the surrounding supportive tissue and rupture, allowing escape of mucus into surrounding tissues, with a concomitant reactive inflammatory response. At the margin of low-grade tumors, the pattern is often one of broad "pushing" fronts.

High-grade malignancies are characterized by neoplastic cell clusters composed chiefly of epidermoid cells that are more solid, with fewer mucin-containing cystic spaces and scattered mucous cells (Figures 8-41 and 8-42). Larger numbers of non–mucin-producing epithelial cells are seen at the expense of better-differentiated mucous cells. Cellular pleomorphism, nuclear hyperchromatism, and mitotic figures are noted within these higher-grade tumors. In many high-grade mucoepidermoid carcinomas, much of the lesion may resemble squamous cell carcinoma, with only small numbers of mucous cells evident. In high-grade lesions, infiltration in the form of cords and strands of cells may be noted well beyond the obvious clinical focus of the tumor.

Intermediate-grade lesions lie histologically and biologically between low- and high-grade lesions. Mucous cells and microcystic spaces are apparent but are not as numerous as in low-grade lesions. Cellular atypia is minimal.

Prognosis and Treatment. Prognostic significance may be generally correlated to histologic grades of malignancy. Low-grade mucoepidermoid carcinomas characteristically follow a benign clinical course; however, in some instances, low-grade lesions have metastasized widely. Clinical confirmation of the aggressiveness of high-grade carcinomas is generally evident within the first 5 years after the initial

treatment; local and distant metastases are evident in as many as 60% of cases. The incidence of metastasis to cervical lymph nodes from mucoepidermoid carcinomas of the parotid gland (excluding low-grade lesions) has reached 44%. A 5-year survival rate of 95% or greater is associated with low-grade lesions. For high-grade lesions, however, survival rates are approximately 40%. In follow-up periods extending to 15 years, the cure rate for high-grade carcinoma drops to 25% or less.

The prognosis of intraoral minor salivary gland mucoepidermoid carcinomas has been shown to be related to the immunohistochemical demonstration of a universal cyclin-dependent kinase inhibitor, where low expression was related to overall poorer prognosis, whereas expression of the proliferative marker Ki-67 was correlated with those histologic factors that indicated a generally poorer prognosis, as does beta-catenin expression.

Treatment of low-grade mucoepidermoid carcinomas is typically surgical. High-grade malignancies are usually managed with surgery plus postoperative radiotherapy to the primary site. Neck dissection is rarely performed in small lesions of low-grade malignancy; high-grade tumors usually require this form of management.

Central (intrabony) mucoepidermoid carcinomas are usually of low-grade histology and behavior. Most deaths occur because of uncontrolled local recurrence. When arising centrally in bone, these lesions have been associated with a 40% recurrence rate after simple curettage.

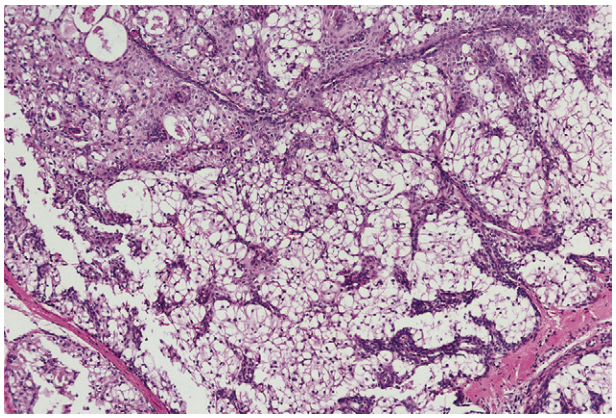

■ **FIGURE 8-41 Mucoepidermoid carcinoma** (intermediate grade) with a focus of clear cell change.

Polymorphous Low-Grade Adenocarcinoma

Polymorphous low-grade adenocarcinoma was first reported in 1983 by two different groups under the terms *lobular carcinoma of salivary glands* and *terminal duct carcinoma*. Today the term *polymorphous low-grade adenocarcinoma* is the accepted term for this entity. It has been segregated from other salivary tumors because of its distinct clinical, histomorphologic, and behavioral aspects. This tumor is generally considered to be a low-grade malignancy with a relatively indolent course and low risk of recurrence and metastasis. The putative source of the polymorphous low-grade adenocarcinoma is believed to be reserve cells in the most proximal portion of the salivary duct. Myoepithelial-differentiated cells appear in this neoplasm, but only in low to moderate numbers.

Clinical Features. This neoplasm occurs in the fifth through eighth decades of life with no gender predilection. It accounts for 26% of all salivary carcinomas; more than 70% occur in patients between the ages of 50 and 70 with a mean age of 59 years, and it appears almost exclusively in minor salivary glands, the palate being the most frequently reported site (Boxes 8-19 and 8-20). Polymorphous low-grade adenocarcinomas typically present as firm, elevated, nonulcerated nodular swellings that are usually nontender. A wide range in size has been noted, but most are between 1 and 4 cm in diameter. The slow growth rate is evidenced by the long duration—many months to years—before diagnosis and treatment. Neurologic symptoms usually are not reported in association with this tumor. Metastasis to local

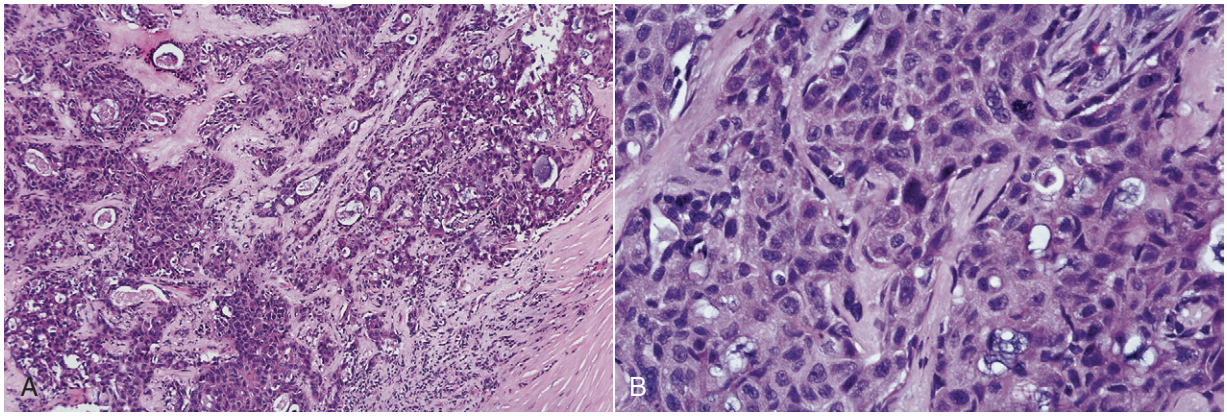

■ **FIGURE 8-42 A** and **B, Mucoepidermoid carcinoma,** high grade. Note that there are few tumor ducts and mucous cells.

BOX 8-19 POLYMORPHOUS LOW-GRADE ADENOCARCINOMA

Malignancy of minor salivary gland; second in frequency to mucoepidermoid carcinoma
Presents as asymptomatic submucosal mass
Polymorphous microscopic pattern (most cases show small nerve invasion but no effect on prognosis)
Low-grade malignancy; good prognosis
Treatment by wide excision; recurrence rate ~10%
Occasional metastasis
Regional nodes ~10%
Rare to lungs

BOX 8-20 POLYMORPHOUS LOW-GRADE ADENOCARCINOMA: LOCATION

MINOR SALIVARY GLANDS
45% palate
20% lips
23% buccal mucosa
10% retromolar mucosa
1% floor of mouth
1% tongue

PAROTID GLAND
Few cases reported

SUBMANDIBULAR GLAND
Rare

NASAL/NASOPHARYNX
Few cases reported

nodes is present at the time of diagnosis in approximately 10% of patients. Rare instances of lung metastasis have been reported.

Histopathology. Absence of encapsulation together with infiltrating streams of cells and a general lobular morphology characterize this group of low-grade adenocarcinomas. Infiltration into the surrounding salivary gland and connective tissue is evident at low-power examination. In cases involving the hard palate or jaw bone, extension into surrounding or adjacent bone may be noted. A wide range of histomorphologic patterns between and within individual tumors is characteristic. In most areas, the tumor is composed of a homogeneous population of cells with prominent, bland, uniform, and often vesicular nuclei surrounded by minimal cytoplasm (Figures 8-43 to 8-48). These cells are arranged in lobules, as well as in solid nests. Tubules lined by a single layer of cells are typical of this tumor. Cribriform structures bearing a resemblance to adenoid cystic carcinoma may also be seen. Tumor cells, often spindled, are also arranged in trabeculae and narrow cords. Striking patterns in which

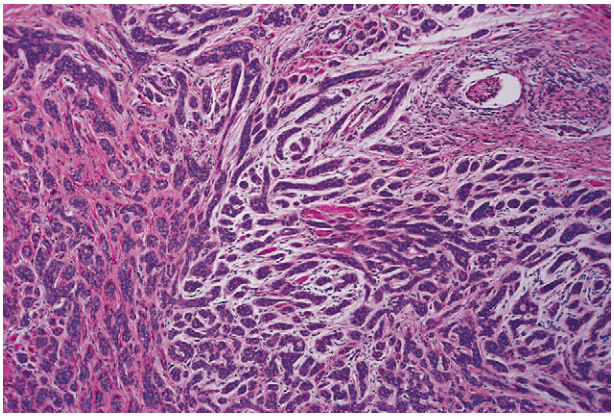

■ **FIGURE 8-43 Polymorphous low-grade adenocarcinoma** showing streaming pattern.

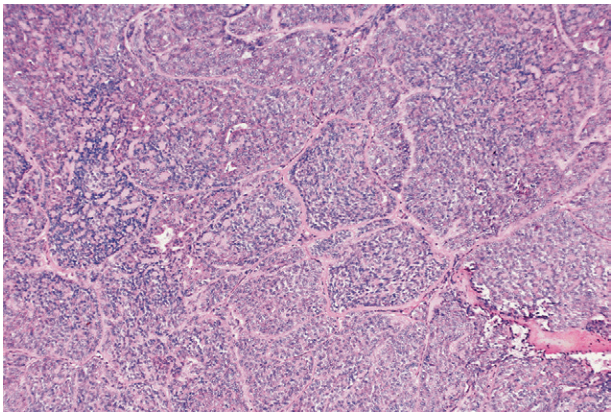

■ **FIGURE 8-44 Polymorphous low-grade adenocarcinoma** showing solid jigsaw pattern.

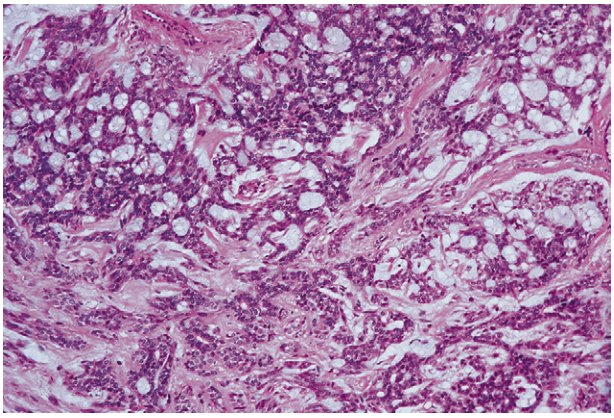

■ **FIGURE 8-45 Polymorphous low-grade adenocarcinoma** with a pseudocribriform pattern.

concentric arrangements of individual cells appear around blood vessels and nerves may be observed. Perineural growth around small nerve twigs is evident in most cases but appears to have no clinical relevance. Nuclear atypia, necrosis, and mitotic figures are absent. The stroma may contain areas of mucoid quality and hyalinization.

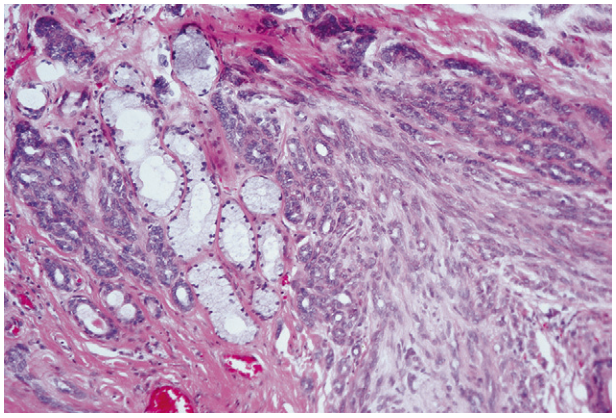

■ **FIGURE 8-46 Polymorphous low-grade adenocarcinoma** showing infiltrating tumor composed of single-layered ducts.

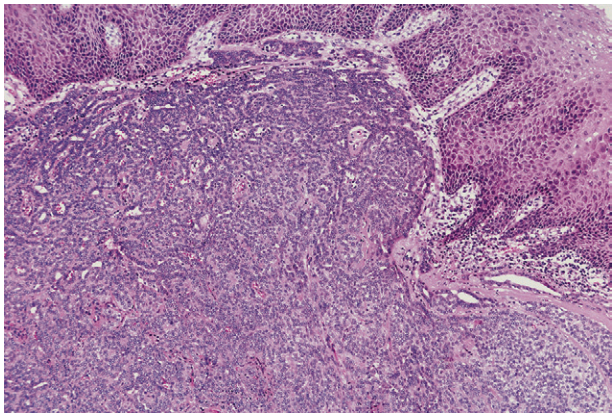

■ **FIGURE 8-47 Polymorphous low-grade adenocarcinoma** showing characteristic epithelial encroachment pattern.

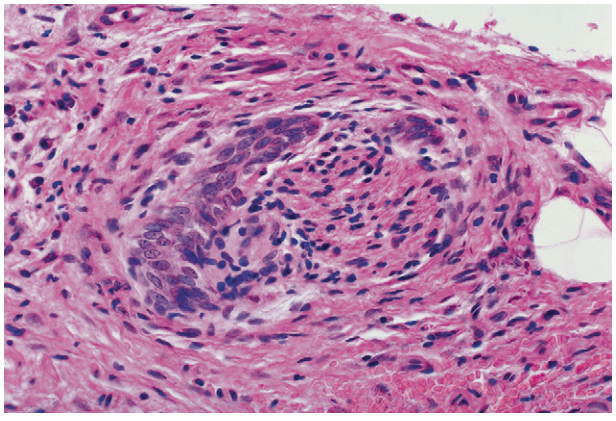

■ **FIGURE 8-48 Polymorphous low-grade adenocarcinoma** in perineural spaces.

Treatment and Prognosis. The indolent nature of this tumor mandates conservative surgical excision. With wide surgical excision, the recurrence rate is approximately 10%, and the overall survival rate is excellent. In patients who present with concurrent regional lymph node enlargement, neck dissection should be performed. The role of radiation therapy in the primary treatment of polymorphous low-grade adenocarcinoma has yet to be fully assessed in the absence of regional nodal spread.

BOX 8-21 ADENOID CYSTIC CARCINOMA

High-grade salivary gland malignancy
Adults; palatal mass/ulceration
Cribriform microscopic pattern
Spread through perineural spaces
Local recurrence and metastasis; lung > nodes
5-year survival 70%; 15-year survival 10%

>, More frequently than.

Adenoid Cystic Carcinoma

Adenoid cystic carcinoma is a high-grade malignancy that has a fair 5-year survival rate but a dismal 15-year survival rate. It is composed of duct-type epithelial cells and myoepithelial cells in variable patterns. Typically showing little cellular atypia and only rare mitotic figures, it pursues an unrelenting course that defies most therapeutic measures.

Clinical Features. This lesion accounts for approximately 23% of all salivary gland carcinomas (Box 8-21). Approximately 50% to 70% of all reported cases of adenoid cystic carcinoma occur in minor salivary glands of the head and neck, chiefly of the palate. In the major salivary glands, the parotid gland is most often affected. Most patients with adenoid cystic carcinoma are in the fifth through seventh decades of life, and no gender predilection has been noted.

In the major salivary glands, the clinical appearance of a typically behaving adenoid cystic carcinoma is usually that of an infiltrative, slow-growing unilobular mass that is firm on palpation, although with occasional pain or tenderness. These lesions are generally characterized by a slow growth rate; they are often present for several years before the patient seeks treatment. Pain, facial nerve weakness, or paralysis may occasionally be the initial presenting symptom, especially in late-stage lesions.

Bone invasion occurs often, initially without radiographic changes, because of infiltration through marrow spaces. Distant spread to the lungs is more common than metastasis to regional lymph nodes. The lesion typically invades perineural spaces, leading to extension of neoplasm well beyond the primary mass. A common feature of intraoral lesions, particularly those arising on the palate, is ulceration of the overlying mucosa—a point often used to help distinguish this lesion clinically from the more common benign mixed tumor (Figure 8-49).

Histopathology. Three basic histomorphologic patterns have been identified: tubular, cribriform, and solid (Figures 8-50 to 8-56). The cribriform pattern is the best-recognized

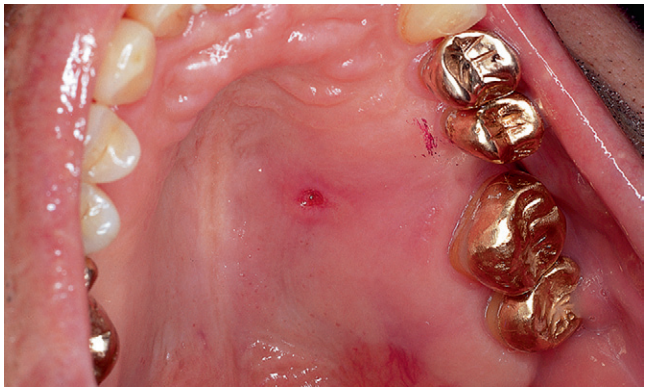

■ **FIGURE 8-49 Adenoid cystic carcinoma** of the palate.

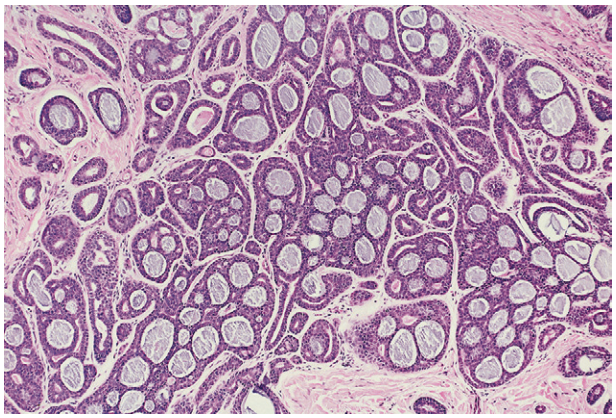

■ **FIGURE 8-50 Adenoid cystic carcinoma,** cribriform pattern.

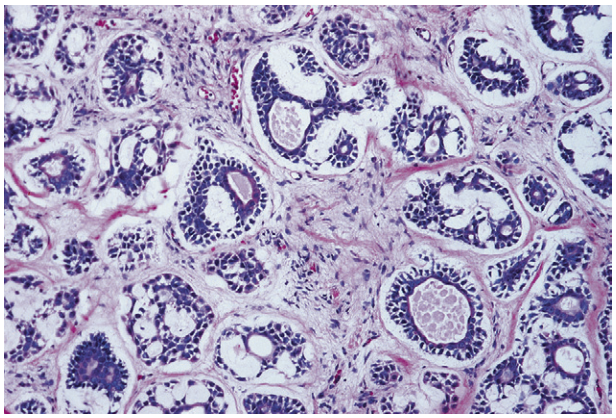

■ **FIGURE 8-51 Adenoid cystic carcinoma,** nests with retraction spaces.

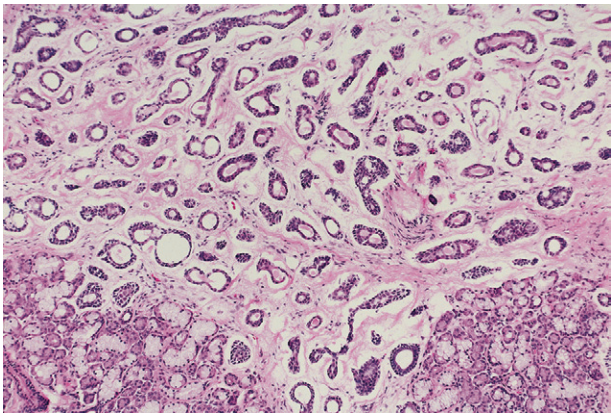

■ **FIGURE 8-52 Adenoid cystic carcinoma,** microinvasive pattern.

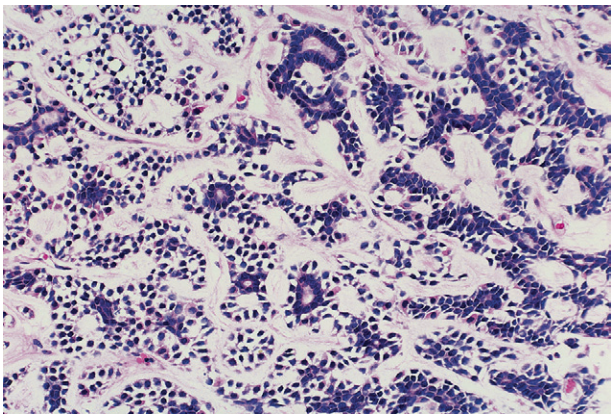

■ **FIGURE 8-53 Adenoid cystic carcinoma** with prominent clear cell layer surrounding inner ductal cells.

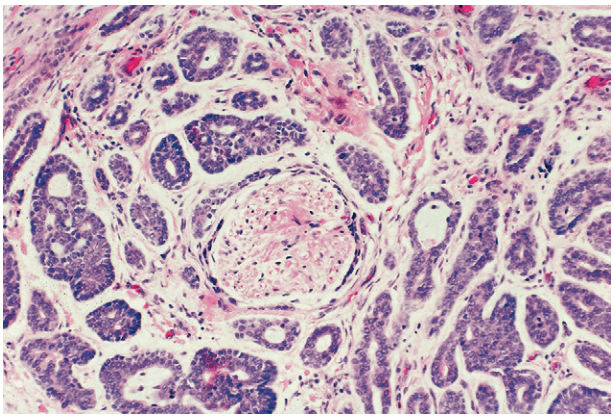

■ **FIGURE 8-54 Adenoid cystic carcinoma** showing perineural invasion.

pattern and the prototypical one that typifies the tumor. The pseudocystic spaces contain sulfated mucopolysaccharides that are ultrastructurally characterized by multilayered or replicated basal lamina material. The tubular form is composed of smaller islands of cells with distinct ductlike structures centrally. The solid basaloid pattern shows little duct formation and is composed of larger islands of small to medium-sized cells with small, dark nuclei. This type may show more pleomorphism than the others and is associated with a poorer outcome. Areas of central necrosis within solid clusters of cells may indicate a more aggressive form of disease. Factors regarding prediction of behavior include the size of the histologic type, whether it is a primary lesion, the anatomic location, the presence or absence of metastatic disease at the time of diagnosis, and facial nerve involvement. An aggressive variant, the *de-differentiated* form of adenoid cystic carcinoma, arises within a preexisting or

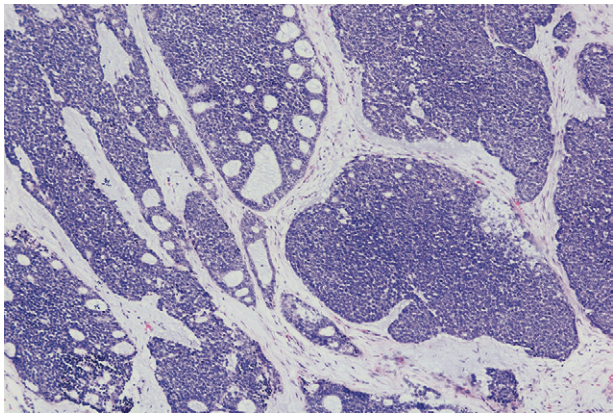

■ **FIGURE 8-55 Adenoid cystic carcinoma,** solid pattern.

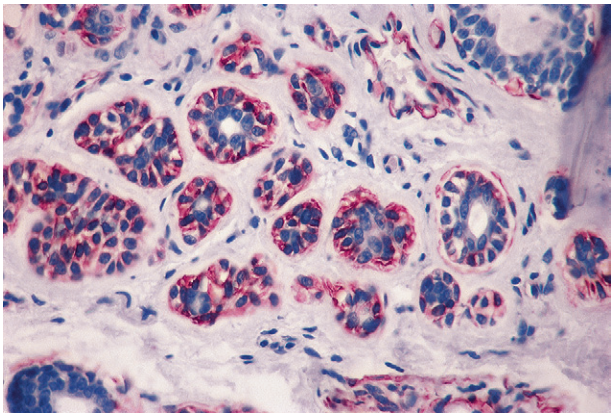

■ **FIGURE 8-56 Adenoid cystic carcinoma** stained for muscle-specific actin. Positive staining *(red)* is seen in the outer layer of cells.

typical adenoid cystic carcinoma, most likely in recurrent or metastatic disease. In this variant, the growth rate or progression is rapid.

Ductal structures are lined by cuboidal cells with uniform nuclei with condensed chromatin. An outer layer of cells with clear cytoplasm and angular nuclei characteristically surrounds the inner layer of cuboidal cells. The outer layer of cells exhibits myoepithelial differentiation and stains positive for actins. Nuclear atypia is absent or minimal, and mitotic figures are rare.

Treatment and Prognosis. Regardless of the site of the primary lesion, surgery is regarded as the treatment of choice for adenoid cystic carcinomas. When the parotid glands are involved, wide resection in the form of a superficial parotidectomy or superficial and deep lobectomy is recommended, depending on size and tumor location. In the parotid region, the debate is whether or not the facial nerve should be spared; most investigators recommend resection if the tumor surrounds or invades this nerve.

Intraorally, wide excision, often with removal of underlying bone, is the treatment of choice. Radical surgical excision may be justified to obtain surgical margins that are free of tumor.

Radiation therapy has a role in the management of primary disease, as a postoperative modality, and in locally recurrent disease, but to be effective, the radiation fields must be wide, reflecting the disseminated nature of the disease. Chemotherapy is generally regarded as ineffective, although multiple-agent chemotherapy has shown some promise in the management of widely metastatic disease. Immunohistochemical demonstration of *c*-kit protein expression by this tumor may provide a basis for molecular therapeutic intervention.

The prognosis for patients with adenoid cystic carcinoma must be judged not in terms of 5-year survival rates, but rather, in terms of 15- to 20-year survival rates. Survival rates at 5 years approximate 70%; at 15 years, the rate is only 10%. Factors that negatively influence the prognosis include the presence of tumor at the line of surgical excision, tumor size greater than 4 cm, the presence of more than 30% of a solid pattern within the tumor, and the presence of facial nerve paralysis at initial presentation. A long survival time has been positively correlated with a greater number of glandlike spaces per square millimeter (tubular and cribriform patterns within the tumor). Between 80% and 90% of patients die of disease by the 15th year, with local recurrence rates ranging widely from 16% to 85%, as stated in several series. The lung is the most common site of distant metastasis, followed by bone, brain, and liver.

Clear Cell Carcinoma

Four salivary gland tumors, when poorly fixed, may have areas in which tumor cells exhibit clear cytoplasm, apparently as a result of autolysis of cytoplasmic organelles (Box 8-22). Thus this categorization is descriptive of more than a single entity. Also, two clear cell tumors—clear cell carcinoma and epimyoepithelial carcinoma (discussed later)—exhibit clear cell changes that are the result of cytoplasmic accumulation of glycogen and myofilaments, respectively. Clear cell carcinoma, formerly called *hyalinizing clear cell carcinoma,* is a low-grade tumor that occurs predominantly in the minor salivary glands (80% of cases). Most present as submucosal masses in the palate, although other sites may be affected (Figure 8-57). Microscopically, the neoplasm is composed of uniform bland cells, predominantly with clear cytoplasm (Figures 8-58 and 8-59). The pattern is typically trabecular, although nests and sheets of cells may be seen. The tumor cells stain positive for glycogen, but negative for mucin, S-100 protein, and muscle-specific actin. Treatment is by excision, and recurrence is very uncommon.

Acinic Cell Carcinoma

Acinic cell carcinoma occurs predominantly in the major salivary glands, especially the parotid. The putative source of acinic cell carcinoma is the intercalated duct reserve cell,

although there is reason to believe that the acinic cell itself retains the potential for neoplastic transformation.

Clinical Features. Acinic cell carcinoma is found in all age groups, including children, with the peak incidence noted within the fifth and sixth decades of life. No gender predilection has been noted.

This lesion accounts for 14% of all parotid gland tumors and 9% of the total of salivary gland carcinomas of all sites. An unusual feature is the frequency of bilateral parotid gland involvement in approximately 3% of cases. Most cases (approximately 80%) develop within the superficial lobe and the inferior pole of the parotid gland. Fewer cases have been reported within the submandibular gland (4%) and the intraoral minor salivary glands (17%). Within the oral cavity, most cases occur in the palate and the buccal mucosa. Acinic cell carcinoma usually presents as a slow-growing lesion smaller than 3 cm in diameter. Although it is not indicative of the prognosis, pain is a common presenting symptom. Rarely, acinic cell carcinoma, as with other

BOX 8-22 SALIVARY GLAND CLEAR CELL TUMORS

CLEAR CELL TUMORS
Clear cell carcinoma
Epimyoepithelial carcinoma

CLEAR CELL CHANGE/ARTIFACT IN OTHER TUMORS
Adenoid cystic carcinoma
Oncocytoma
Acinic cell carcinoma
Mucoepidermoid carcinoma

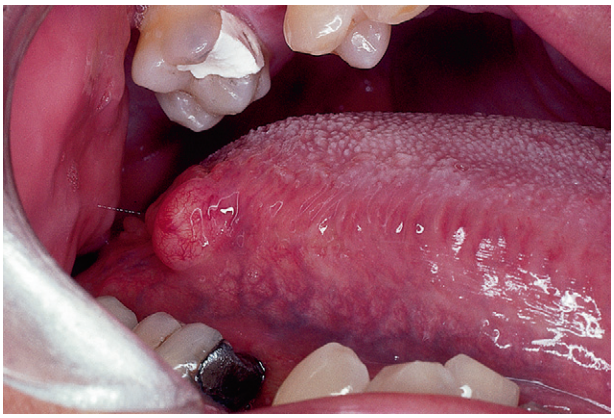

■ **FIGURE 8-57 Clear cell carcinoma** of the lateral tongue. (Courtesy Dr. Francina Lozada-Nur.)

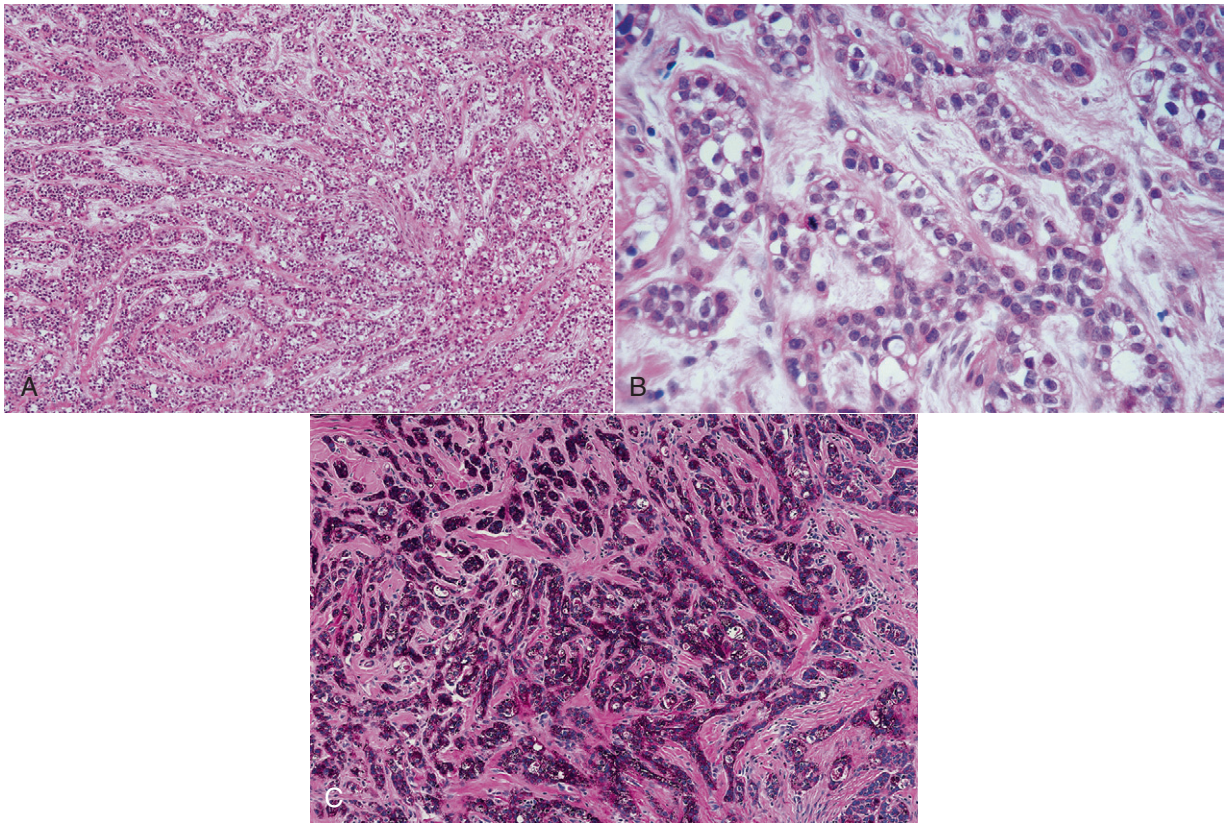

■ **FIGURE 8-58 A** and **B, Clear cell carcinoma,** trabecular arrangement of clear cells. **C,** Positive *(red)* periodic acid–Schiff (PAS) staining (glycogen) of tumor cells.

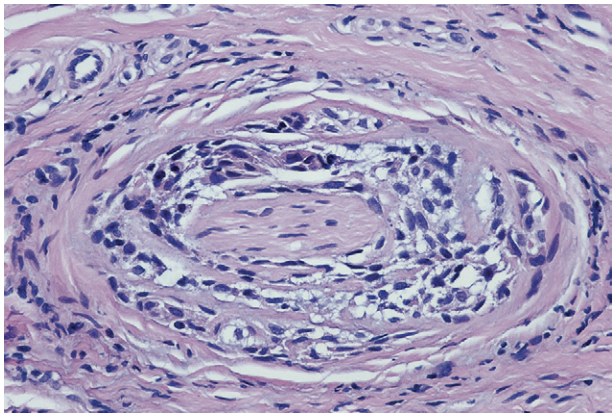

■ **FIGURE 8-59 Clear cell carcinoma** showing perineural invasion.

malignant salivary gland tumors including, adenoid cystic carcinoma, may assume a dedifferentiated phenotype (Figure 8-60), with corresponding levels of clinical aggressiveness, rapid growth, lymphovascular invasion, and regional lymph node metastasis.

Histopathology. Acinic cell carcinoma typically grows as an intraglandular mass that is generally well circumscribed. The neoplasm usually exhibits a solid microscopic pattern, although one third of lesions have a microcystic pattern (Figures 8-61 to 8-64). Papillary and follicular patterns may be seen within the solid component, or may represent the majority of the lesion. Hemosiderin is often found, and there is little stromal tissue. Tumor cells are uniform and well differentiated toward serous acinar cells, containing cytoplasmic PAS-positive, diastase digestion–resistant granules similar to those found in normal acinic cells. Many acinic cell carcinomas demonstrate clear cell element zones, probably as a result of inadequate fixation.

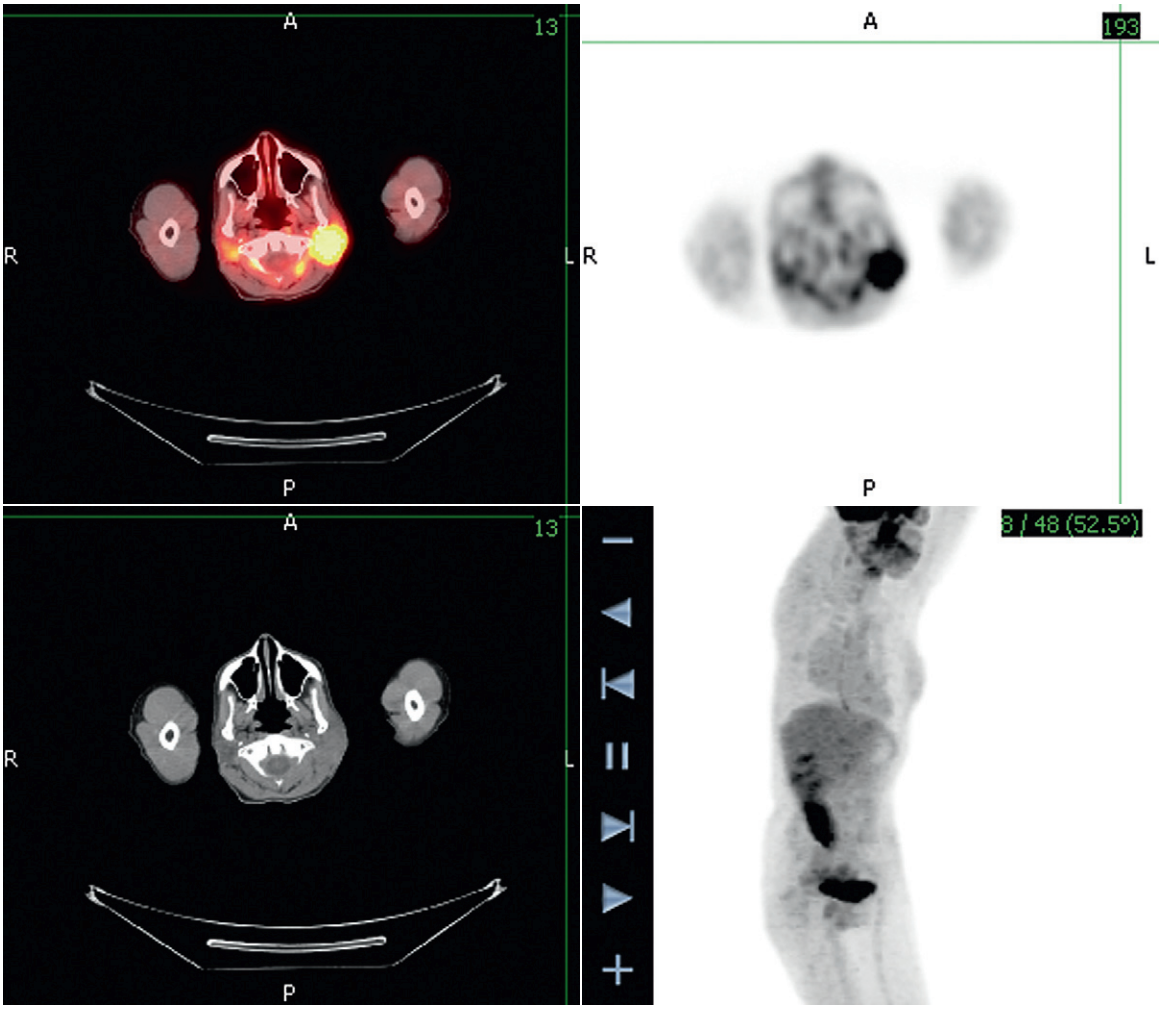

■ **FIGURE 8-60** Acinic cell carcinoma—dedifferentiated type. Computed tomography (CT) scan and positron emission tomography (PET) scan *(black area)* images with fusion of each technique *(orange-red area)*.

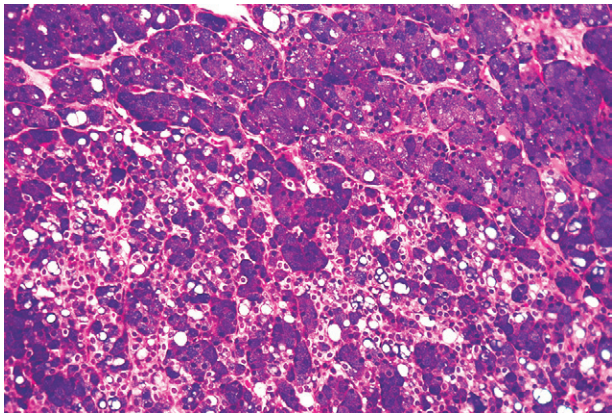

■ **FIGURE 8-61 Acinic cell carcinoma** with cells containing darkly staining zymogen granules.

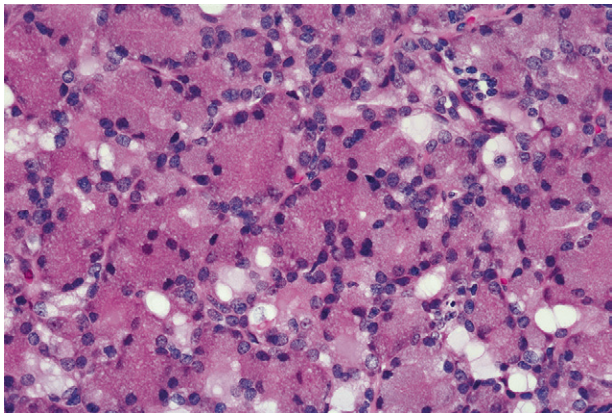

■ **FIGURE 8-62** Acinic cell carcinoma.

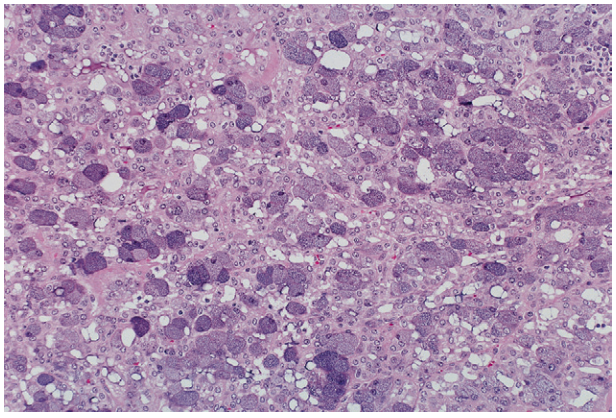

■ **FIGURE 8-63** Acinic cell carcinoma.

Treatment and Prognosis. Surgery is the preferred treatment. In general, acinic cell carcinomas seldom metastasize, yet they have a tendency to recur. Determinant survival rates are 89% at 5 years and 56% at 20 years, indicating the overall malignant nature of these tumors. Metastases to regional lymph nodes occur in approximately 10% of cases, whereas distant metastases occur in approximately 15% of cases. It has been found that neither the morphologic pattern nor the cell composition is a predictable prognostic feature. Unfavorable prognostic features include pain or fixation to surrounding tissue; gross tumor invasion into adjacent tissue; and microscopic features of desmoplasia, cellular atypia, and increased mitotic activity.

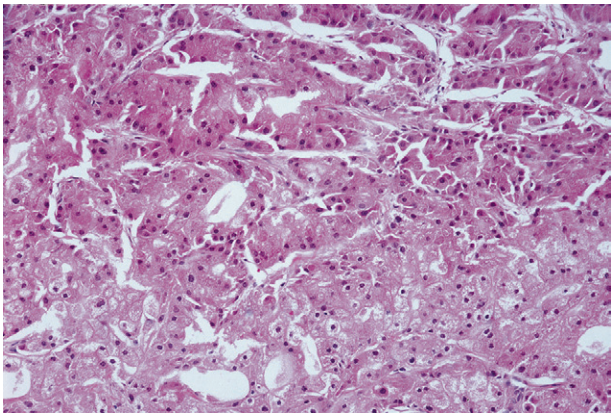

■ **FIGURE 8-64 Acinic cell carcinoma** with clear cell area *(bottom)*.

Adenocarcinoma Not Otherwise Specified

By definition, any malignancy arising from salivary duct epithelium or within salivary glands of epithelial origin is an adenocarcinoma. The term *adenocarcinoma not otherwise specified* is used as a diagnosis when lesions cannot be classified into existing categories. The "not otherwise specified (NOS)" label indicates that the microscopic appearance is nonspecific. Whether the lesion can be considered of high grade depends on the presence of cellular atypia and an invasive growth pattern.

RARE TUMORS

Carcinoma Ex-Mixed Tumor/Malignant Mixed Tumor/Metastasizing Mixed Tumor

Carcinoma ex-mixed tumor represents an epithelial malignancy arising in a preexisting mixed tumor in which such remnants may be identified. When metastatic disease occurs, only the malignant component metastasizes. This is more common than the *malignant mixed tumor,* which has also been recognized. One type of the latter lesion is a malignancy in which both epithelial and mesenchymal components are malignant, hence a carcinosarcoma designation could be used. In metastatic sites, both elements are present. *Metastasizing mixed tumor* is characterized by a histologically benign mixed tumor that for some reason metastasizes while still retaining its bland, benign histologic appearance.

Carcinoma ex-mixed tumor usually arises from an untreated benign mixed tumor known to be present for several years, or from a benign mixed tumor that has had

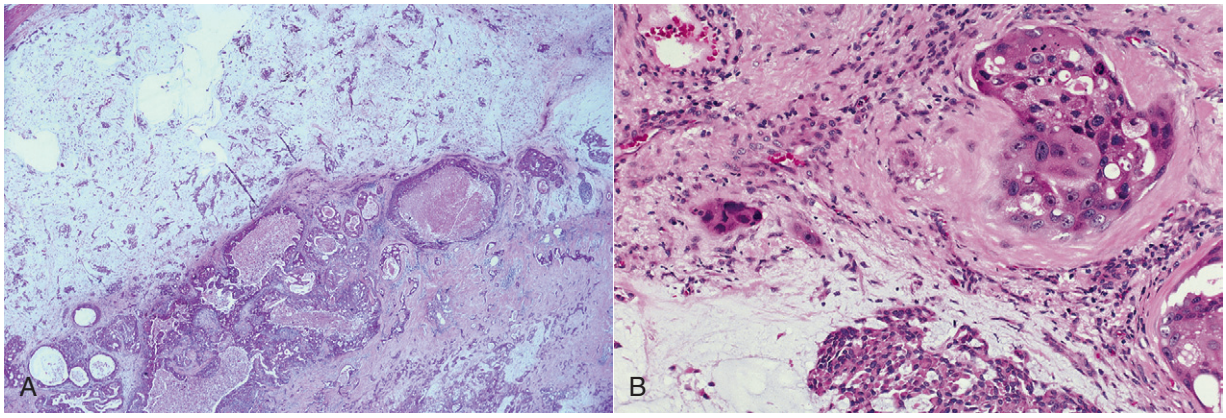

■ **FIGURE 8-65 Carcinoma ex-mixed tumor. A** and **B,** Note cellular atypia.

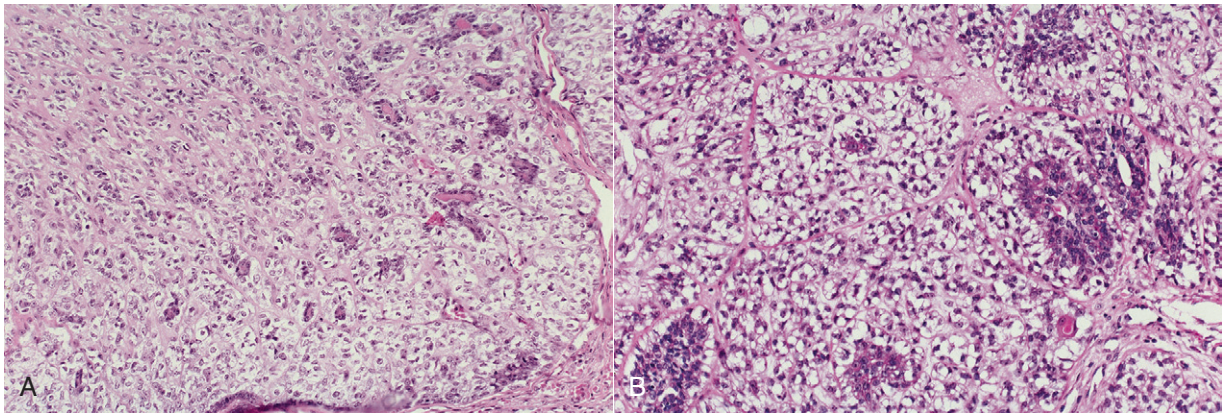

■ **FIGURE 8-66 Epimyoepithelial carcinoma. A** and **B,** Note clear cells surrounding darker-staining tumor ductal cells.

many recurrences over many years (Figure 8-65). Malignancy occurring within a previously benign tumor is heralded by rapid growth after an extremely long period of minimally perceptible increase.

Approximately 68% of carcinoma ex-mixed tumors and malignant mixed tumors are found in the parotid gland, and 18% are found in the intraoral minor salivary glands. The average age when malignancy becomes evident is 60 years—approximately 20 years beyond the age noted for benign mixed tumors. Suspicious signs of malignancy include fixation of the mass to surrounding tissues, ulceration, and regional lymphadenopathy. Treatment is almost exclusively surgical, and radical neck dissection is part of the initial treatment in patients with evidence of cervical lymph node involvement.

Local recurrence is a problem in nearly half of patients with primary parotid neoplasms and in nearly three fourths of patients with submandibular and minor salivary gland tumors. Approximately 10% of cases present with uncontrollable lymphatic disease, and nearly one third of these show metastasis to distant sites, usually lung and bone. Determinant cure rates at 5, 10, and 15 years after treatment in one study were 40%, 24%, and 19%, respectively; in another study, 30% of those monitored for 10 years were free of disease.

Epimyoepithelial Carcinoma

Epimyoepithelial carcinoma is a clear cell–containing malignancy of salivary gland (predominantly the major glands) origin characterized by a biphasic morphology. It is seen in the seventh and eighth decades of life, and a 2:1 female predilection has been reported.

A lobular growth pattern is generally present that is composed of two cell types: abundant intercalated duct–like elements forming ducts surrounded by clear myoepithelial cells. Glycogen, actins, and S-100 protein are present in the bordering clear cells, supporting their myoepithelial origin (Figure 8-66). More specific myoepithelial cell markers may be used, including p63 and smooth muscle actin.

Recurrences have most often been associated with lesions larger than 3 cm. Overall recurrence and metastasis rates suggest that this is a malignancy of intermediate grade.

Salivary Duct Carcinoma

Salivary duct carcinoma is a high-grade malignancy of the major salivary glands. It is characterized clinically by a distinct predominance in the parotid gland (more than 80% of cases); the submandibular gland accounts for the remainder of cases. Nearly 80% of cases have been recorded in men, and

the overall peak incidence is in the seventh decade. The lesion arises as a firm, painless mass. A striking microscopic resemblance to ductal carcinoma originating in the breast is noted, with architectural features that include papillary cribriform and solid growth patterns, along with a desmoplastic stroma and central or comedo-type necrosis. Expression of androgen receptor is also a defining characteristic of salivary duct carcinoma. Nuclear atypia is noted, but few mitoses are seen. Most tumors have infiltrative margins, and neural invasion is evident in approximately 50% of cases.

Surgical excision is the treatment of choice. Large series indicate that more than 50% of patients die of their disease within 5 months to 6 years after treatment. Pulmonary and osseous metastases are often noted.

Basal Cell Adenocarcinoma

Basal cell adenocarcinoma, a rare tumor of the major salivary glands, is considered to be the malignant counterpart of basal cell adenoma, with a histologic resemblance to ductal carcinoma of the breast. It appears microscopically similar to basal cell adenoma, except that it exhibits an infiltrative growth pattern and has the ability to metastasize. These tumors are composed of nests, cords, and solid zones of basaloid cells (Figure 8-67). Two cytologic types of cells are often seen: small, compact cells and larger, polygonal cells. The former may often be seen surrounding the latter, frequently in a palisade fashion. The feature that separates this tumor from basal cell adenoma is the finding of small nests of neoplasm in adjacent normal structures. Infiltration of nerves is also seen. Local recurrence and distant metastasis seem to be distinct potentials for basal cell adenocarcinoma. Nonetheless, this tumor is generally regarded as a low-grade, minimally invasive malignancy. With adequate surgical treatment, patients should have a favorable outcome.

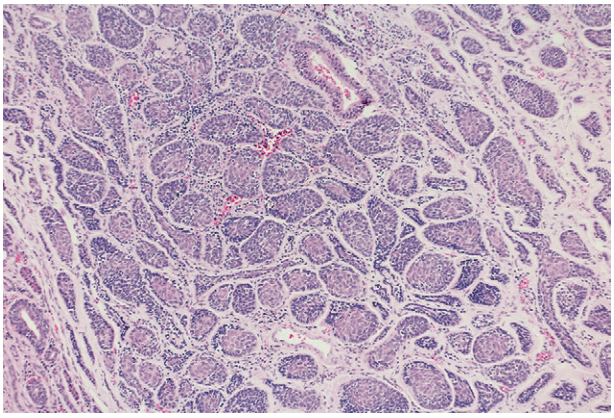

■ **FIGURE 8-67 Basal cell adenocarcinoma** in nested pattern.

Squamous Cell Carcinoma

Squamous cell carcinoma arising within the salivary glands is a relatively rare event and seems to be limited to the major salivary glands. The submandibular gland is most commonly involved, followed by the parotid. Obstructive sialadenitis (more common in the submandibular gland) has been thought to be a predisposing condition. Most patients are in the seventh decade of life or beyond.

Squamous cell carcinomas of the parotid and submandibular glands are generally well to moderately well differentiated with no evidence of mucin production. Metastatic squamous cell carcinoma and high-grade mucoepidermoid carcinoma are usually alternative diagnoses.

Local recurrence and regional lymph node metastasis are common events, and distant metastasis is unusual. Surgery is the treatment of choice. As with most other salivary gland malignancies, ultimate survival relates more to clinical stage than to histologic differentiation.

BIBLIOGRAPHY

Reactive Lesions (Noninfectious)

Bohora S, Harikrishnan S, Tharakan J: Iodide mumps. Int J Cardiol 130:82–83, 2008.

Brannon R, Fowler C, Hartman K: Necrotizing sialometaplasia: a clinico-pathologic study of sixty-nine cases and review of the literature. Oral Surg Oral Med Oral Pathol 72:317–325, 1991.

Bryant C, Manisali M, Barrett AW: Adenomatoid hyperplasia of palatal minor salivary glands. J Laryngol Otol 110:167–169, 1996.

Buchner A, Merrel PW, Carpenter WM et al: Adenomatoid hyperplasia of minor salivary glands. Oral Surg Oral Med Oral Pathol 71:583–587, 1991.

Fowler CB, Brannon RB: Subacute necrotizing sialadenitis: report of 7 cases and a review of the literature. Oral Surg Oral Med Oral Pathol Oral Radiol Endod 89:600–609, 2000.

Jensen JL: Superficial mucoceles of the oral mucosa. Am J Dermatopathol 12:88–92, 1990.

Keogh PV, O'Regan E, Toner M, Flint S: Necrotizing sialometaplasia: an unusual bacterial presentation associated with antecedent anaesthesia and lack of response to intralesional steroids: case report and review of literature. Br Dent J 196:79–81, 2004.

McClatchey KD, Appelblatt NH, Zarbo RJ: Plunging ranula. Oral Surg Oral Med Oral Pathol 57:408–412, 1984.

Stephens LC, Schultheiss TE, Price RE et al: Radiation apoptosis of serous acinar cells of salivary and lacrimal glands. Cancer 67:1539–1543, 1991.

Wolff A, Fox PC, Ship JA et al: Oral mucosal status and major salivary gland function. Oral Surg Oral Med Oral Pathol 70:49–54, 1990.

Infectious Conditions

Balada E, Ordi-Ros J, Vilardell-Tarres M: Molecular mechanisms mediated by human endogenous retroviruses (HERVs) in autoimmunity. Rev Med Virol 19:173–286, 2009.

Coleman H, Altini M, Nayler S, Richards A: Sialadenosis: a presenting sign in bulimia. Head Neck 20:758–762, 1998.

Doumas S, Vladikas A, Papagianni M, Kolokotronis A: Human cytomegalovirus-associated oral and maxillofacial disease. Clin Microbiol Infect 13:557–559, 2007.

Flaitz C: Parotitis as the initial sign of juvenile Sjögren's syndrome. Pediatr Dent 23:140–142, 2001.

Mitchell I, Turk J, Mitchell D: Detection of mycobacterial rRNA in sarcoidosis with liquid-phase hybridization. Lancet 339:1015–1017, 1992.
Nikolay NP, Illei GG: Pathogenesis of Sjögren's syndrome. Curr Opin Rheumatol 21:465–470, 2009.
Sabatino G, Verrotti A, de Martino M et al: Neonatal suppurative parotitis: a study of five cases. Eur J Pediatr 158:312–314, 1999.
Saboor S, Johnson N, McFadden J: Detection of mycobacterial DNA in sarcoidosis and tuberculosis with polymerase chain reaction. Lancet 339:1012–1015, 1992.
Suresh I, Radfar L: Oral sarcoidosis: a review of literature. Oral Dis 11:138–145, 2005.

Conditions Associated With Immune Defects

Atkinson JC, Travis WD, Pillemer SR et al: Major salivary function in primary Sjögren's syndrome and its relationship to clinical features. J Rheumatol 17:318–322, 1990.
Caselitz J, Osborn M, Wustrow J et al: Immunohistochemical investigations on the epimyoepithelial islands in lymphoepithelial lesions. Lab Invest 55:427–432, 1986.
Daniels TE, Fox PC: Salivary and oral components of Sjögren's syndrome. Rheum Dis Clin North Am 18:571–589, 1992.
Daniels TE, Whitcher JP: Association of patterns of labial salivary gland inflammation with keratoconjunctivitis sicca. Arthritis Rheum 37:869–877, 1994.
Falzon M, Isaacson PG: The natural history of benign lymphoepithelial lesion of the salivary gland in which there is a monoclonal population of B-cells. Am J Surg Pathol 15:59–65, 1991.
Fox RI: Sjögren's syndrome. Lancet 366:321–331, 2005.
Fox RI, Luppi M, Kang HI et al: Reactivation of Epstein-Barr virus in Sjögren's syndrome. Springer Semin Immunopathol 13:217–231, 1991.
Garry RF, Fermin CD, Darrenn JH et al: Detection of a human intracisternal A-type retroviral particle antigenically related to HIV. Science 250:1127–1129, 1990.
Guggenheimer J, Moore PA: Xerostomia: etiology, recognition and treatment. J Am Dent Assoc 134:61–69, 2003.
Hernandez-Molina G, Avila Cosado C, Cardenas-Velazquez F et al: Similarities and differences between primary and secondary Sjögren's syndrome. J Rheumatol 37:800–808, 2010.
Jonsson R, Gordon TP, Konttinen YT: Recent advances in understanding molecular mechanisms in the pathogenesis and antibody profile of Sjögren's syndrome. Curr Rheum Rep 5:311–316, 2003.
Jordan R, Diss TC, Lench NJ et al: Immunoglobulin gene rearrangements in lymphoplasmacytic infiltrates of labial salivary glands in Sjögren's syndrome. Oral Surg Oral Med Oral Pathol Oral Radiol Endod 79:723–729, 1995.
Kovacs L, Szodoray P, Kiss E: Secondary tumors in Sjögren's syndrome. Autoimmun Rev 9:203–206, 2010.
Lazarus MN, Robinson D, Mak V et al: Incidence of cancer in a cohort of patients with primary Sjögren's syndrome. Rheumatology (Oxford) 45:1012–1015, 2006.
Mandic R, Teymoortash A, Kann PH, Werner JA: Sialadenosis of the major salivary glands in a patient with central diabetes insipidus-implications of aquaporin water channels in the pathomechanism of sialadenosis. Exp Clin Endocrinol Diabetes 113:205–207, 2005.
Manthorpe R, Bredberg A, Henriksson G, Larsson A: Progress and regression within primary Sjögren's syndrome. Scand J Rheumatol 35:1–6, 2006.
Ramon-Casals M, Tzioufas AG, Stone JH et al: Treatment of primary Sjögren's syndrome: a systematic review. JAMA 304: 452–460, 2010.
Sanchez-Guerrero J, Perez-Dosal MR, Celis-Aguilar E et al: Validity of screening tests for Sjögren's syndrome in ambulatory patients with chronic diseases. J Rheumatol 33:907–911, 2006.
Schiodt M: HIV-associated salivary gland disease: a review. Oral Surg Oral Med Oral Pathol 73:164–167, 1992.
Smedby KE, Hjalgrim H, Aslding J et al: Autoimmune and chronic inflammatory disorders and risk of non-Hodgkin lymphoma by subtype. J Natl Cancer Inst 98:51–60, 2006.
Talal N: Immunologic and viral factors in Sjögren's syndrome. Clin Exp Rheumatol 8(suppl 5):23–26, 1990.
Talal N, Dauphinee MJ, Dang H et al: Detection of serum antibodies to retroviral proteins in patients with primary Sjögren's syndrome (autoimmune exocrinopathy). Arthritis Rheum 33: 774–781, 1990.
Vougarelis M, Dafni UG, Isenberg DA, Moutsopoulos H: Malignant lymphoma in primary Sjögren's syndrome: a multi-center, retrospective clinical study in the European Concerted Action of Sjögren's syndrome. Arthritis Rheum 42:1765–1772, 1999.

Xerostomia

Cassolato SF, Turnbull SF: Xerostomia: clinical aspects and treatment. Gerodontology 20:64–77, 2003.
Ghezzi EM, Ship JA: Aging and secretory reserve capacity of major salivary glands. J Dent Res 82:844–848, 2003.
Guggenheimer J, Moore P: Xerostomia: etiology, recognition and treatment. J Am Dent Assoc 134:61–69, 2003.
Kassimos DG, Shirlaw PJ, Choy EHS et al: Chronic sialadenitis in patients with nodal osteoarthritis. Br J Rheumatol 36:1312–1317, 1997.
Moore PA, Guggenheimer J, Etzel KR et al: Type 1 diabetes mellitus, xerostomia, and salivary flow rates. Oral Surg Oral Med Oral Pathol Oral Radiol Endod 92:281–291, 2001.
Porter SJ, Scully C, Hegarty AM: An update on the etiology and management of xerostomia. Oral Surg Oral Med Oral Pathol Oral Radiol Endod 97:28–46, 2004.

Taste Disturbances

Ackerman BH, Kasbekar N: Disturbances of taste and smell induced by drugs. Pharmacotherapy 17:482–496, 1997.
Cullen MM, Leopold DA: Disorders of smell and taste. Med Clin North Am 83:57–74, 1999.
Femiano G, Scully C, Gombos F: Idiopathic dysgeusia; an open trial of alpha lipoic acid (ALA) therapy. Int J Oral Maxillofac Surg 31:625–628, 2002.
Schiffman S: Taste and smell losses in normal aging and disease. JAMA 278:1357–1362, 1997.

Halitosis

Ilana E, Bhat R, Koriat H, Rosenberg M: Self-perception of breath odor. J Am Dent Assoc 132:621–626, 2001.
Iwu CO, Akpata O: Delusional halitosis: review of the literature and analysis of 32 cases. Br Dent J 168:294–296, 1990.
Morita M, Wand HL: Relationship between oral malodor and adult periodontitis: a review. J Clin Periodontol 28:813–819, 2001.
Ratcliff PA, Johnson PW: The relationship between oral malodor, gingivitis and periodontitis. J Periodontol 70:485–489, 1999.
Scully C, Felix DH: Oral medicine—update for the dental practitioner: oral malodour. Br Dent J 199:498–500, 2005.

Benign Neoplasms

Batsakis JG, Luna MA, El-Naggar AK: Basaloid monomorphic adenomas. Ann Otol Rhinol Laryngol 100:687–690, 1991.
Brannon RB, Sciubba JJ, Giuliani M: Benign papillary intraoral minor salivary gland tumors: a report of 19 cases and a review of the literature. Oral Surg Oral Med Oral Pathol Oral Radiol Endod 92:68–77, 2001.
Chung YF, Khoo ML, Heng MK et al: Epidemiology of Warthin's tumor of the parotid gland in an Asian population. Br J Surg 85:661–664, 1994.

Ethunandan M, Witton R, Hoffman G et al: Atypical features in pleomorphic adenoma—a clinicopathologic study and implications for management. Int J Oral Maxillofac Surg 35:608–612, 2006.
Hickman RE, Cawson RA, Duffy RA: The prognosis of specific types of salivary gland tumors. Cancer 54:1620–1624, 1984.
Maiorano E, LoMuzio L, Favia G et al: Warthin's tumor: a study of 78 cases with emphasis on bilaterality, multifocality and association with other malignancies. Oral Oncol 38:35–40, 2002.
Noguchi S, Aihara T, Yoshino K et al: Demonstration of monoclonal origin of human parotid gland pleomorphic adenoma. Cancer 77:431–435, 1996.
Rousseau A, Mock D, Dover DG et al: Multiple canalicular adenomas: a case report and review of the literature. Oral Surg Oral Med Oral Pathol Oral Radiol Endod 87:346–350, 1999.
Smith BC, Ellis GL, Slater L et al: Sclerosing polycystic adenosis of major salivary glands: a clinicopathologic analysis of nine cases. Am J Surg Pathol 20:161–170, 1996.
Webb AJ, Eveson JW: Pleomorphic adenomas of the major salivary glands: a study of the capsular form in relation to surgical management. Clin Otolaryngol 26:134–142, 2001.

Malignant Neoplasms

Auclair PL, Goode RK, Ellis GL: Mucoepidermoid carcinoma of minor salivary glands. Cancer 69:2021–2030, 1992.
Batsakis JG, El-Naggar AK: Terminal duct adenocarcinomas of salivary tissues. Ann Otol Rhinol Laryngol 100:251–253, 1991.
Beltran D, Faquin WE, Gallagher M, August M: Selective immunohistochemical comparison of polymorphous low-grade adenocarcinoma and adenoid cystic carcinoma. J Oral Maxillofac Surg 64:415–423, 2006.
Brandwein MS, Jagirdar J, Patil J et al: Salivary duct carcinoma (cribriform salivary carcinoma of excretory ducts). Cancer 65:2307–2314, 1990.
Brookstone MS, Huvos AS: Central salivary gland tumors of the maxilla and mandible: a clinicopathologic study of 11 cases with an analysis of the literature. J Oral Maxillofac Surg 50:229–236, 1992.
Callendar DL, Frankenthaler RA, Luna MA et al: Salivary gland neoplasms in children. Arch Otolaryngol Head Neck Surg 118:472–476, 1992.
Castle JT, Thompson LDR, Frommelt RA et al: Polymorphous low grade adenocarcinoma: a clinicopathologic study of 164 cases. Cancer 86:207–219, 1999.
Dardick I, Gliniecki GR, Heathcote J et al: Comparative histogenesis and morphogenesis of mucoepidermoid carcinoma and pleomorphic adenoma. Virchows Arch A Pathol Anat Histopathol 417:405–417, 1990.
Dickson PV, Davidoff AM: Malignant neoplasms of the head and neck. Semin Pediatr Surg 15:92–98, 2006.
Evans HL, Luna MA: Polymorphous low grade adenocarcinoma: a study of 40 cases with long term followup and an evaluation of the importance of papillary areas. Am J Surg Pathol 24: 1319–1328, 2000.
Fowler MH, Fowler J, Ducatman B et al: Malignant mixed tumors of the salivary gland: a study of loss of heterozygosity in tumor suppressor genes. Mod Pathol 19:350–355, 2006.
Goode RK, Auclair PL, Ellis GL: Mucoepidermoid carcinoma of the major salivary glands. Cancer 82:1217–1224, 1998.
Hamper K, Lazar F, Dietel M et al: Prognostic factors for adenoid cystic carcinoma of the head and neck. J Oral Pathol Med 19:101–107, 1990.
Holst VA, Marshall CE, Moskaluk CA et al: KIT protein expression and analysis of c-kit gene mutation in adenoid cystic carcinoma. Mod Pathol 12:956–960, 1999.
Hosai AS, Fan C, Barnes L et al: Salivary duct carcinoma. Otolaryngol Head Neck Surg 129:720–725, 2003.
Jeng YM, Lin CY, Hsu HC: Expression of the c-kit protein is associated with certain subtypes of salivary gland carcinomas. Cancer Lett 154:107–111, 2000.
Khafif A, Anavi Y, Haviv J et al: Adenoid cystic carcinoma of the salivary glands: a 20-year review with long-term follow-up. Ear Nose Throat J 84:664–667, 2005.
Lee PS, Sabbath-Solitare M, Redondo TC et al: Molecular evidence that the stromal and epithelial cells in pleomorphic adenomas of salivary gland arise from the same origin: clonal analysis using human androgen receptor gene. Hum Pathol 31:498–503, 2000.
Lewis JE, Olsen KD, Sebo TJ: Carcinoma ex pleomorphic adenoma: pathologic analysis of 73 cases. Hum Pathol 32:596–604, 2001.
Lewis JE, Olsen KD, Weiland LH: Acinic cell carcinoma: clinicopathologic review. Cancer 67:172–179, 1991.
Milchgrub S, Gnepp DR, Vuitch F et al: Hyalinizing clear cell carcinoma of salivary gland. Am J Surg Pathol 18:74–82, 1994.
Nagao T, Gaffney TA, Serizawa H et al: Dedifferentiated adenoid cystic carcinoma: a clinicopathologic study of 6 cases. Mod Pathol 16:1265–1272, 2003.
Norberg LE, Burford-Mason AP, Dardick I: Cellular differentiation and morphologic heterogeneity in polymorphous low-grade adenocarcinoma. J Oral Pathol Med 20:373–379, 1991.
Ogawa Y, Hong SS, Toyosawa S et al: Expression of major histocompatibility complex class II antigens and interleukin-1 by epithelial cells of Warthin's tumor. Cancer 66:2111–2117, 1990.
Okabe M, Inagaki H, Murase T et al: Prognostic significance of p27 and Ki-67 expression of mucoepidermoid carcinoma of intraoral minor salivary gland. Mod Pathol 14:1008–1014, 2001.
Pinkston JA, Cole JA: Incidence rates of salivary gland tumors: results from a population-based study. Otolaryngol Head Neck Surg 120:834–840, 1999.
Seifert G, Brocheriou C, Cardesa A et al: WHO International Classification of Tumors: tentative histological classification of salivary gland tumors. Pathol Res Pract 186:555–581, 1990.
Shapiro NL, Bhattacharyya N: Clinical characteristics and survival for major salivary gland malignancies in children. Otolaryngol Head Neck Surg 134:631–634, 2006.
Shieh Y-S, Chang L-C, Chiu KC et al: Cadherin and catenin expression in mucoepidermoid carcinoma: correlation with histopathologic grade, clinical stage and patient outcome. J Oral Pathol Med 32:397–402, 2003.
Simpson R, Sarsfield P, Clarke T et al: Clear cell carcinoma of minor salivary glands. Histopathology 17:433–438, 1990.
Simpson RHW, Clarke TJ, Sarsfield PTL et al: Epithelial-myoepithelial carcinoma of salivary glands. J Clin Pathol 44: 419–423, 1991.
van der Waal JE, Snow GB, van der Waal I: Intraoral adenoid cystic carcinoma: the presence of perineural spread in relation to site, size, local extension and metastatic spread in 22 cases. Cancer 66:2031–2033, 1990.
Vincent SD, Hammond HL, Finkelstein MW: Clinical and therapeutic features of polymorphous low-grade adenocarcinoma. Oral Surg Oral Med Oral Pathol 77:41–47, 1994.
Waldron CA, el-Mofty SK, Gnepp DR: Tumors of the intraoral salivary glands: a demographic and histologic study of 426 cases. Oral Surg Oral Med Oral Pathol 66:323–333, 1988.
Waldron CA, Koh ML: Central mucoepidermoid carcinoma of the jaws: report of four cases with analysis of the literature and discussion of the relationship to mucoepidermoid, sialodontogenic and glandular odontogenic cysts. J Oral Maxillofac Surg 48:871–877, 1990.
Yoo J, Robinson RA: H-ras gene mutations in salivary gland mucoepidermoid carcinomas. Cancer 88:518–523, 2000.

CHAPTER 9

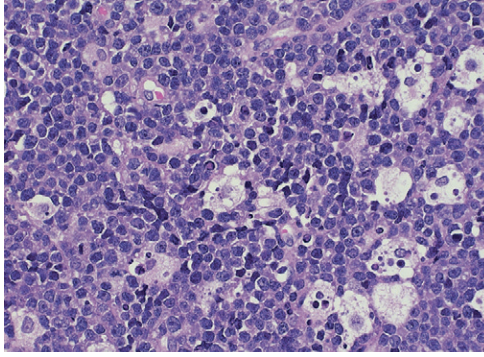

Lymphoid Lesions

REACTIVE LESIONS

Lymphoid Hyperplasia
Epithelioid Hemangioma (Angiolymphoid Hyperplasia With Eosinophilia)

DEVELOPMENTAL LESIONS

Lymphoepithelial Cyst

NEOPLASMS

Lymphoma
Non-Hodgkin's Lymphoma
Hodgkin's Lymphoma
Multiple Myeloma/Plasmacytoma
Leukemias
Granulocytic Sarcoma

REACTIVE LESIONS

In this chapter, three primary groupings of lesions—reactive, developmental, and neoplastic—are considered. An important point in the discussion of lymphoid lesions involving the oral cavity and adjacent areas is that many lesions, especially those arising in lymph nodes, are capable of simulating malignancy.

Lymphoid Hyperplasia

It is sometimes difficult to distinguish reactive from neoplastic lymphoid proliferations, especially when they occur in unusual sites such as the peritonsillar area, palate, buccal mucosa, lymph nodes, and salivary glands. The incidence of benign cystic lymphoepithelial lesions within the parotid and submandibular glands is increasing in patients with acquired immunodeficiency syndrome (AIDS).

One of the normal sites of lymphoid tissue is the posterolateral portion of the tongue. Aggregations of lymphoid tissue within this area are part of the *foliate papillae,* or lingual tonsil. They may be distinguished from other lymphoid tissues by deep crypts lined by stratified squamous epithelium. These papillae occasionally become inflamed or irritated, with associated enlargement and tenderness. In such instances, patients may become symptomatic. On examination, these areas are enlarged and somewhat lobular in outline, with an intact overlying mucosa and prominent superficial vessels. In instances in which such lesions are removed for diagnostic purposes, the chief finding is reactive lymphoid hyperplasia. Within the enlarged germinal centers, mitoses and macrophages containing cellular debris may be seen. In addition to the foliate papillae, other zones where lymphoid tissue is found include the anterior floor of the mouth on either side of the lingual frenum, the anterior tonsillar pillar, and the posterior portion of the soft palate (Figures 9-1 and 9-2). Because lymphoid tissues are not always found in these areas, they are usually regarded as ectopic. The term *oral tonsil* also refers to this tissue.



■ **FIGURE 9-1 Hyperplastic lymphoid tissue** in uvula and tonsillar areas.

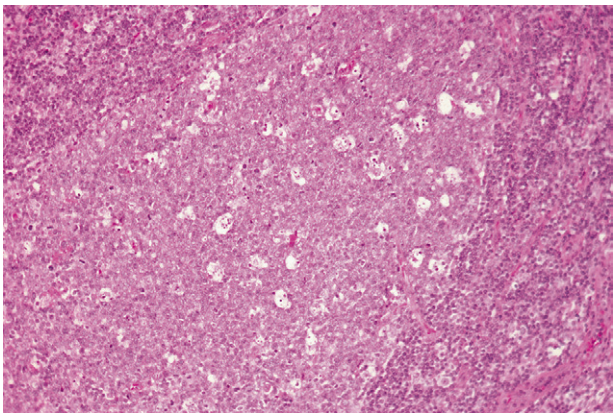

■ **FIGURE 9-2 Hyperplastic lymphoid follicle** with prominent macrophages (light-staining cells).

Reactive lymphoid hyperplasia (oral tonsil) has male predominance and is noted within the second and third decades of life. In one study, a mean age of 23 years was found. Lesions range from 1 to 15 mm in diameter and may persist for years.

The *buccal* or *facial lymph node* is often the site of a reactive hyperplastic process. This is characterized as a freely movable submucosal nodule in the buccal mucosa that is usually adjacent to the second premolar and first molar teeth and can often be palpated extraorally. The cause of the process is unknown, but it may be a reaction to irritation or localized trauma. Gingivitis or periapical pathology may occasionally stimulate or initiate enlargement of this particular lymph node.

Management should be directed toward elimination of the cause of the problem if it can be identified, followed by simple observation.

Follicular lymphoid hyperplasia may be seen in the palate. This reactive polyclonal proliferation of lymphocytes is often difficult to separate from *lymphoproliferative disease of the palate,* a condition that may signify lymphoma. Histologically, follicular lymphoid hyperplasia of the palate is characterized by irregularly sized, well-demarcated germinal centers with a crisply defined rim or mantle of small, mature lymphocytes. Within the germinal centers, macrophages contain phagocytosed nuclear debris. Using immunohistochemical techniques, a mixture of kappa and lambda light chains (B lymphocytes) is seen, indicating a polyclonal population of cells. In addition, the mantle zones are composed of both mature and immature B cells, whereas the extramantle zones contain both B and T lymphocytes, plasma cells, macrophages, and eosinophils. Indefinite follow-up is prudent because of possible progression to lymphoma.

Epithelioid Hemangioma (Angiolymphoid Hyperplasia With Eosinophilia)

Epithelioid hemangioma, also known as angiolymphoid hyperplasia with eosinophilia (ALHE), was first described in 1948 as a nodular subcutaneous benign disease in young men. Later, however, cases with the same clinical and histologic features were reported in the oral cavity. In addition to nodular aggregates of lymphocytes and eosinophils, regional lymphadenopathy and blood (peripheral) eosinophilia were noted. Similar findings were noted under the headings of *Kimura's disease,* eosinophilic granuloma of soft tissue, and eosinophilic lymphofolliculosis. Because Kimura's disease was originally described as having a distinct male predilection without associated regional lymphadenopathy, some clinicians believe that the two conditions represent different entities. Histologically, some differences have been described, adding to the tendency to split ALHE and Kimura's disease into two separate but related entities.

Etiology. Because of vascular proliferation and an intensive inflammatory infiltrate, a reactive etiology has been suggested. Increased serum immunoglobulin (Ig)E levels and deposition of IgE within the lymphoid follicles further suggest a reactive immune cause. Also demonstrated has been the presence of anti–*Candida albicans* antibody within the lesions and improvement after hyposensitization to this allergen.

Clinical Features. ALHE is found predominantly in the head and neck area, accounting for approximately 85% of all cases. However, oral mucous membrane involvement is rare. The labial mucosa is the oral site most commonly affected. A wide age range from 7 to 79 years has been noted, with a mean age of 35 years. Lesions generally are solitary, with a mean size of 1.7 cm. Peripheral eosinophilia greater than 4% has been noted in 60% of cases in which peripheral blood counts have been studied. The clinical course is characterized by the presence of a painless, mobile, submucosal nodule that enlarges gradually. Multiple lesions have been reported in more than 40% of cases.

Histopathology. Lesions are circumscribed and usually are grossly separable from surrounding tissue. A nodular mass of hyperplastic lymphoid tissue with well-developed

lymphoid follicles containing germinal centers may be seen. Proliferating capillaries with plump endothelial cells are found in a dense, patchy infiltrate of lymphocytes, with eosinophils and fewer numbers of macrophages noted. Toward the periphery, this infiltrate may extend into surrounding soft tissue. Arterial intimal proliferation and disruption of the internal elastic lamina may be seen. Early lesions or those in an active growth phase may be dominated by a vascular element; older or quiescent lesions may contain a larger percentage of inflammatory cells.

Differential Diagnosis. When it involves the labial mucosa, the characteristic nodule of ALHE may be indistinguishable from a minor salivary gland neoplasm or a mucus retention cyst or mucocele. Other benign soft tissue neoplasms, such as lipoma and schwannoma, might be included in the differential diagnosis.

Because of the presence of eosinophils within tissue, a microscopic differential diagnosis should include Langerhans cell disease (eosinophilic granuloma), traumatic (eosinophilic) granuloma, and possibly a drug reaction (hypersensitivity) or parasitic infection.

Treatment. Excision is the treatment of choice. Intralesional steroid injections have been used with variable results. Recurrences are occasionally noted. The presence of blood or peripheral eosinophilia has generally been reported with numerous or recurrent lesions.

DEVELOPMENTAL LESIONS

Lymphoepithelial Cyst

Lymphoepithelial cyst is an uncommon lesion of the mouth, major salivary glands, or neck that is thought to arise from an entrapment of epithelium within lymph nodes or lymphoid tissue during development. Subsequent epithelial proliferation results in a clinically evident mass.

Oral lymphoepithelial cysts (see also the discussion on ectopic lymphoid tissue in Chapter 3) present as asymptomatic mucosal elevations that are well defined and yellowish pink (Figure 9-3). The site most commonly affected is the floor of the mouth, where approximately 50% of cases are found. Ventral and posterolateral portions of the tongue constitute an additional 40% of cases; the balance is shared among the soft palate, the mucobuccal fold, and anterior facial pillars. A wide age range is noted, from adolescence to the seventh decade of life. The gender distribution is essentially equal. Except for the small central cystic space, these lesions are identical to ectopic lymphoid aggregates.

A marked increase in the incidence of lymphoepithelial cysts of the major salivary glands has been noted recently, particularly in those testing positive for the human immunodeficiency virus (HIV). The mechanism of cyst formation is unclear.



■ **FIGURE 9-3 Lymphoepithelial cyst** in lingual frenum.

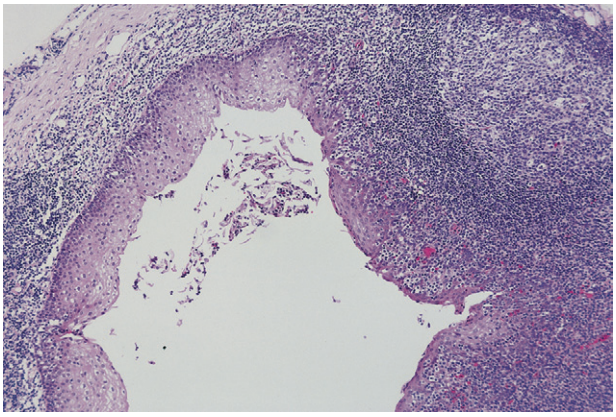

■ **FIGURE 9-4 Lymphoepithelial cyst.** Squamous epithelial lining and lymphoid tissue in surrounding tissue.

Histopathology. The lymphoepithelial cyst is lined by stratified squamous epithelium that often is parakeratotic. Focal areas of pseudostratified columnar cells or mucous cells may be present. The epithelial lining is surrounded by a discrete, well-circumscribed lymphoid component, often with germinal center formation and a sharply defined zone of mantle lymphocytes. In addition, the cyst wall may contain variable proportions of lymphocytes, macrophages, and plasma cells, with occasional multinucleated giant T cells (Figure 9-4). Continuity of the cyst lining with the surface oral epithelium may be noted occasionally.

Differential Diagnosis. In the anterior floor of the mouth, a sialolith may have a similar clinical appearance. However, a history of pain and swelling of the associated salivary gland would be expected with a salivary duct stone. Developmental anomalies such as teratomas or dermoid cysts, benign mesenchymal neoplasms, and salivary gland tumors might also be considered in a differential diagnosis for a floor-of-mouth soft tissue mass. When it involves the parotid gland, a lymphoepithelial cyst must be distinguished from salivary lymphoma, Warthin's tumor, and cystic neoplasm of salivary origin.

Treatment. Conservative excisional biopsy is generally used for definitive diagnosis, as well as for treatment. Recurrence is not expected.

NEOPLASMS

Lymphoma

Lymphomas are malignant neoplasms of component cells of lymphoid tissues. Broad division of the group into Hodgkin's and non-Hodgkin's lymphomas is widely accepted. Hodgkin's lymphoma is primarily a disease of lymph nodes characterized by the presence of large binucleated cells called Reed-Sternberg cells and a lymphoid stroma composed of large numbers of non-neoplastic cells. Hodgkin's lymphoma is very rare in the oral cavity.

Non-Hodgkin's Lymphoma

Non-Hodgkin's lymphomas (NHLs) are a relatively common group of neoplasms (more than 50,000 cases per year) that often occur in extranodal head and neck sites, especially in HIV-infected (AIDS) patients. NHLs are heterogeneous with a spectrum of behaviors. Some cases are indolent but ultimately fatal; others are aggressive and if left untreated kill the patient rapidly. NHL can arise in lymph nodes (nodal) and extranodal sites. Up to 40% of all NHLs arise at extranodal sites, with the most common site being the gastrointestinal tract. In the West, they most commonly occur in the stomach, but in the Middle East, the intestine is the most common location. The head and neck is the second most common site for extranodal NHL; most cases arise in Waldeyer's ring.

Similar to lymphomas arising in lymph nodes, B-cell lymphomas are the most common phenotype in extranodal sites. A wide histologic and biological spectrum of B-cell lymphomas occur in the head and neck. Although most are diffuse large B-cell lymphomas, other types are seen in specific sites and populations of patients. These include Burkitt's lymphoma occurring in the facial bones of young patients and T-cell and natural killer cell lymphomas in the nasofacial region, producing the clinical condition termed *midline granuloma.* A large proportion of lymphomas arise within lymph nodes embedded in the salivary tissues. Lymphomas may also arise within salivary gland parenchyma; they resemble those arising in mucosa-associated lymphoid tissue (MALT). This group of tumors, now known as *extranodal marginal zone lymphomas,* is genotypically and phenotypically unique and is characterized by a relatively long and indolent natural history.

Classification. The microscopic classification of NHL continues to evolve. At least eight classifications have been proposed over the past 30 years, but none have gained universal acceptance. The current and most widely adopted system is that from the World Health Organization (WHO) (Table 9-1), which is based on a prior system known as the *Revised European American Lymphoma (REAL)* scheme. This scheme divides lymphomas into T- and B-cell groups and includes a number of entities that arise at extranodal sites. This system focuses on distinct biological entities defined by a combination of clinical, morphologic, immunophenotypic, and genotypic features. It has been shown to be highly reproducible and clinically relevant. Moreover, because it is a list of entities, new lymphomas can be added when they are identified and characterized. Both the WHO and REAL classification systems have been criticized for their heavy reliance on immunohistochemical phenotyping and their problematic application when clinical information is missing or limited. Moreover, because both systems provide a list of entities without biological groupings, learning the systems can be difficult.

TABLE 9-1 MODIFIED WHO CLASSIFICATION OF LYMPHOMAS

	B-Cell Neoplasms	T-Cell and Postulated NK-Cell Neoplasms
Precursor cell neoplasms	Precursor B-lymphoblastic lymphoma/leukemia	Precursor T-lymphoblastic lymphoma/leukemia
Peripheral (mature) cell neoplasms	B-cell chronic lymphocytic leukemia/small lymphocytic lymphoma (B-CLL/SLL)	T-cell chronic lymphocytic leukemia
	Lymphoplasmacytoid lymphoma	Large granular lymphocytic leukemia (T-cell or NK-cell type)
	Mantle cell lymphoma	Mycosis fungoides
	Marginal zone B-cell lymphoma (extranodal or nodal)	Peripheral T-cell lymphoma, unspecified
	Splenic marginal zone B-cell lymphoma	Angioimmunoblastic lymphoma
	Hairy cell leukemia	Intestinal T-cell lymphoma
	Plasmacytoma	Adult T-cell lymphoma/leukemia
	Diffuse large B-cell lymphoma	Anaplastic large cell lymphoma
	Burkitt's lymphoma	

NK, Natural killer.

TABLE 9-2 CHARACTERISTIC CYTOGENETIC FINDINGS IN SELECTED, SPECIFIC LYMPHOMAS

Lymphoma Type	Translocation	Oncogene or Tumor Suppressor Genes	Mechanism
Follicular lymphoma	t(14;18)	*Bcl-2*	Juxtaposition of *Bcl-2* with IgH promoter results in overexpressed antiapoptotic protein *Bcl-2*
Extranodal marginal zone	t(11;18) t(1;14)	*AP12, MLT* *Bcl-10*	Chimeric protein that inhibits apoptosis Juxtaposition of lymphoma *Bcl-10* with IgH promoter results in overexpressed *Bcl-10* protein
Mantle cell lymphoma	t(11;14)	*Bcl-1* (cyclin D1)	Juxtaposition of *Bcl-1* with IgH promoter results in overexpressed cyclin D1 protein
Burkitt's lymphoma	t(8;14) t(8;22) t(2;8)	*c-Myc*	Overexpression of *Myc* is due to juxtaposition of the *c-Myc* gene with IgH, Igκ, or Igλ
Anaplastic large cell lymphoma	t(2;5)	*NPM, ALK*	Production of chimeric *NPM, ALK* protein, which has lymphoma tyrosine kinase activity

Ig, Immunoglobulin.

Etiology. Little is known about the origin of NHL. Variations in incidence in different ethnic groups suggest a strong genetic predisposition. Immunodeficiency, whether acquired or congenital, is an important risk factor for the development of some lymphomas and may be related to a defective immune response to the Epstein-Barr virus (EBV), permitting clonal expansion of infected cells. Some lymphomas are clearly associated with specific chromosome translocations such as t(8;14), t(8;22), and t(2;8) in Burkitt's lymphoma and t(11;14) in mantle cell lymphoma (Table 9-2). These specific chromosome translocations result in the dysregulation of oncogenes or tumor suppressor genes, producing unregulated cell proliferation. Why specific translocations occur is not known.

Staging. The importance of proper staging (determining the clinical extent of disease) for patients with lymphoma in the oral region cannot be overemphasized. Staging serves a number of important purposes, including determination of the type and intensity of therapy, the overall prognosis for the patient, and potential complications associated with the disease. The Ann Arbor method, although initially designed to stage Hodgkin's lymphoma, is now widely used for NHL (Box 9-1). Generally, patients are assigned a stage between I and IV depending on the site and extent of their tumor. In addition, patients are classified as "A" (no symptoms) or "B" (constitutional symptoms).

The staging procedure often differs according to the type and site of lymphoma. Gastrointestinal assessment is performed for lymphomas of Waldeyer's ring because these tumors are often accompanied by gastrointestinal involvement. Extranodal marginal zone lymphoma tends to remain localized for prolonged periods and has a relatively indolent clinical course, hence less extensive investigation is often required. Assessment of the central nervous system (CNS) is performed for lymphomas of the nose and paranasal sinuses, and for lymphoblastic lymphoma and undifferentiated types. Bone marrow biopsy is generally performed for all extranodal lymphomas of the head and neck, but staging laparotomy is rarely done because visceral organ involvement is unlikely.

BOX 9-1 ANN ARBOR STAGING SYSTEM FOR NON-HODGKIN'S LYMPHOMA

STAGE	DEFINITION
I	Involvement of a single lymph node region or of a single extranodal organ or site (I_E)
II	Involvement of two or more lymph node regions on the same side of the diaphragm, or localized involvement of an extranodal site or organ (II_E) and one or more lymph node regions on the same side of the diaphragm
III	Involvement of lymph node regions on both sides of the diaphragm, which may also be accompanied by localized involvement of an extranodal organ or site (III_E) or spleen (III_S), or both (III_{SE})
IV	Diffuse or disseminated involvement of one or more distant extranodal organs with or without associated lymph node involvement

SUBCLASSIFICATION

A. Without systemic symptoms
B. Systemic symptoms: unexplained fever >38° C; unexplained weight loss >10% of body weight in past 6 months; night sweats

Clinical Features. Clinically, three broad groups of NHLs can be discerned on the basis of biological behavior (Table 9-3). These lymphomas may be indolent, aggressive, or highly aggressive. Indolent lymphomas are characterized by slow growth, wide dissemination at presentation, a long

TABLE 9-3 COMPARISON OF FEATURES OF INDOLENT, AGGRESSIVE, AND HIGHLY AGGRESSIVE LYMPHOMAS

	Indolent	Aggressive	Highly Aggressive
Examples of types	Follicular lymphoma B-CLL/SLL Mantle cell lymphoma	Diffuse B-cell lymphoma Peripheral T-cell lymphoma	Burkitt's lymphoma
Age	Adults	Any	Children, young adults
Stage at presentation	High (>80% stages III and IV)	Any	High
Tumor growth rate	Slow; proliferative fraction is low	Fast	Very fast; proliferative fraction >95%
Bone marrow involvement	Yes	Uncommon	Common
Natural history if untreated	Indolent, usually takes years to kill patient	Patient death in 1 to 2 years	Patient death in weeks to months
Response to treatment	Poor	Responsive	Very responsive

Modified from Chan JKC: Chapter 21. In Fletcher CDM: Diagnostic histopathology of tumors, ed 2, London, 2000, Churchill Livingstone.
B-CLL/SLL, B-Cell chronic lymphocytic leukemia/small lymphocytic lymphoma.

natural history, and relative incurability. By contrast, aggressive and highly aggressive groups are characterized by rapid growth, frequent localized presentation, a short natural history, and frequent responsiveness to chemotherapeutic agents. Paradoxically, the most aggressive lymphomas are the ones most likely to be cured. Most lymphomas in adults are diffuse B-cell lymphoma or follicular lymphomas, which together make up more than 50% of all types. Follicular lymphoma is predominantly a tumor of lymph nodes and rarely occurs in the oral cavity. By contrast, T-cell lymphomas are considerably less common at all sites, including the oral cavity. In children, aggressive and highly aggressive lymphomas are the most common, with Burkitt's lymphoma accounting for more than 40% of types.

The clinical presentation of lymphomas of the oral region varies with their site of origin and tumor type, but most present as a mass or an ulcerated mass and resemble squamous cell carcinoma or salivary neoplasm. Other lymphoid malignancies, such as plasmacytoma and Burkitt's lymphoma, show a striking predilection for primary involvement of bone. The microscopic characterization of specific lymphoma types is important because staging procedures and therapy may differ for each type. The only reliable method of distinguishing and characterizing these lesions is by immunophenotyping with the use of tissue-based immunologic studies or by flow cytometry of material obtained by fine-needle aspiration. Lymphomas arising within the oral cavity account for less than 5% of oral malignancies. In the head and neck, lymphomas may be seen within regional lymph nodes and within extranodal lymphoid sites in areas known as gut associated or MALT (extending from the oral cavity to the anal region) (Figure 9-5). Within the oral cavity, lymphoid tissue is chiefly represented in Waldeyer's ring; elsewhere within the oral cavity, it appears as unencapsulated lymphoid tissue within the base of the tongue and soft palate, as well as within the major and minor salivary glands. The tonsils are the most common oropharyngeal site, followed by the palate (Figures 9-6 to 9-8). If bone is the primary site, alveolar bone loss and tooth mobility are often presenting signs (Figure 9-9). Swelling, pain, numbness of the lip, and pathologic fracture may be associated with bone lesions.

Treatment and Prognosis. The treatment of NHL depends on various factors, including the histologic type and grade of the tumor; the stage of the disease; the patient's age, health, and immune status; and the patient's wishes. Two modes of treatment are available: radiation therapy and chemotherapy. Radiation therapy is used if the tumor is found in a specific localized field, and chemotherapy is used for nonlocalized disease. Radiation is typically delivered at the level of 40 to 50 Gy. Chemotherapy is given as a single- or multiple-drug regimen. The goal of chemotherapy is to maximize tumor toxicity while minimizing damage to normal tissues, particularly the hematopoietic tissues. A monoclonal antibody to CD20 antigen (Rituximab) is a newer adjuvant treatment used for many B-cell lymphomas and leukemias, and some autoimmune diseases. Disease relapse during the course of treatment is a poor prognostic sign and is likely related to the evolution of drug-resistant clones. If relapse occurs years after discontinuation of therapy, the tumor likely is still susceptible to the original chemotherapeutic agent. For some patients with indolent lymphomas, no treatment may be given initially. Later, both radiation and chemotherapy can be used if necessary. In general, the prognosis of indolent lymphoma is poor. Although survival is long, with a mean time of 8 years, this group is considered incurable. For aggressive lymphomas, more than 90% of patients receive chemotherapy. Multiple-agent chemotherapy will induce remission in about 40% of patients. The goal of treatment is to extend the dose to the limits of tolerance by the patient. For patients who respond, the outlook is good, with cures expected. For patients who do not respond, the outlook is poor. Similarly, highly aggressive lymphomas respond well to chemotherapy, with many patients having resolution of the disease after only one course of treatment. For nonresponders, however, the disease is usually fatal within weeks.

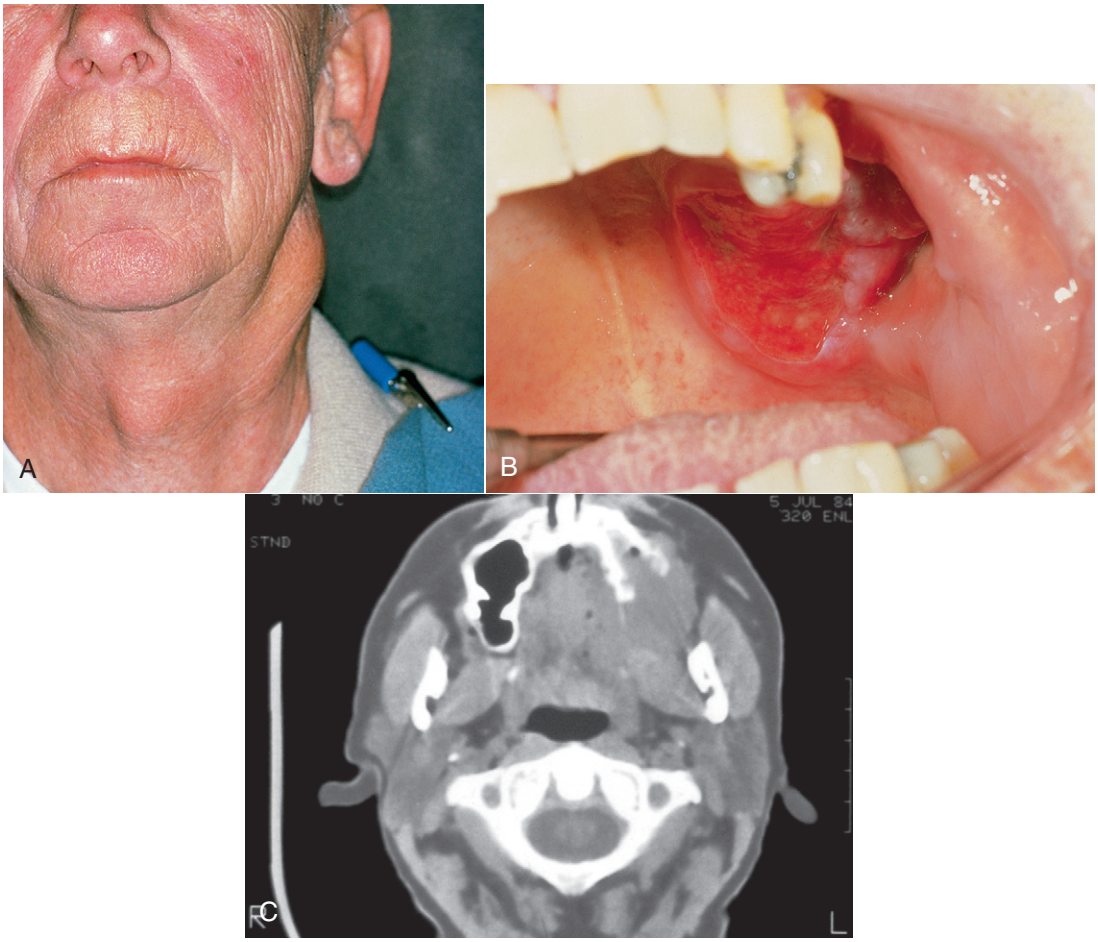

■ **FIGURE 9-5 A, Lymphoma,** left side of neck. **B,** Lesion also in the maxillary alveolar ridge. **C,** Computed tomography (CT) scan showing mass in left maxilla.

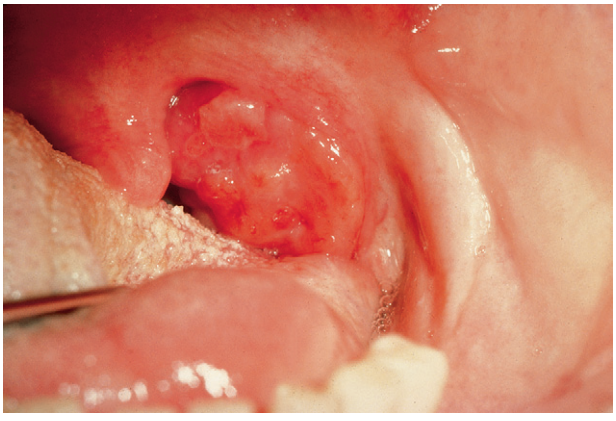

■ **FIGURE 9-6 Lymphoma** of the left tonsil.



■ **FIGURE 9-7 Lymphoma** of the palate.

Specific Lymphomas. In general, two basic histomorphologic groups of lymphomas are recognized: follicular (nodular) and diffuse forms; the former group shows a more favorable prognosis. Follicular lymphomas show malignant cells arranged in uniformly sized nodules distributed throughout a lymph node or extranodal site. In lymphomas showing a diffuse pattern, abnormal cells are distributed uniformly throughout the involved tissue. In either case, the normal architecture of the lymphoid tissue is destroyed. Cytology, or the predominant cell type within the lesion, is of great significance. Not all classified forms of lymphoma are discussed here—only entities of relevance to the head



■ **FIGURE 9-8 Lymphoma** of the palate.



■ **FIGURE 9-9 Lymphoma** presenting as lucencies around apices of anterior maxillary teeth.

and neck. Specific antibodies used in the diagnosis of each type of lymphoma are detailed in Table 9-4. The cytogenetics and immunophenotyping of specific lymphomas are shown in Table 9-2 and Table 9-5, respectively.

Diffuse B-Cell Lymphoma. Diffuse B-cell lymphoma is an aggressive, rapidly growing neoplasm of large lymphoid cells. Diffuse B-cell lymphomas usually arise de novo but may represent transformation of a lower-grade lymphoma. They occur over a wide age range with a slight male predilection. Diffuse B-cell lymphomas may present as lymphadenopathy or in extranodal sites (Figure 9-10). Within bone, the tumor produces extensive destruction. Approximately 50% of all tumors present in stage I or II, and with treatment, 50% to 60% of patients can achieve prolonged disease-free survival.

Microscopically, the tumor is composed of sheets of large lymphoid cells showing abundant cytoplasm and nuclei, comparable in size or larger than reactive histiocytes. Within

TABLE 9-4 ANTIBODIES TO CD MARKERS USEFUL IN THE DIAGNOSIS OF LYMPHOMA

CD Marker	Expression in Normal Tissues	Expression in Malignancy
CD1a	Langerhans cells	Langerhans cell disease
CD3	T cells NK cells	T-cell neoplasms NK neoplasms
CD4	Helper/inducer T cells Monocytes Histiocytes Langerhans cells	Some T-cell neoplasms Langerhans cell disease
CD8	Suppressor/ cytotoxic T cells NK cells	Some T-cell neoplasms Some NK-cell neoplasms
CD10(CALLA)	Follicular center B cells Granulocytes	Follicular center cell lymphomas Burkitt's lymphoma
CD15(LeuM1)	Granulocytes Monocytes	Classic Hodgkin's disease
CD20	B cells but not pre-B cells or plasma cells	B-cell neoplasms Weak in B-CLL/SLL Nodular lymphocyte–predominant Hodgkin's disease
CD22	B cells but not plasma cells	B-cell neoplasm
CD23	B cells Follicular dendritic cells	B-CLL/SLL Some follicular center cell lymphomas
CD30	Activated T and B cells	Classic Hodgkin's disease ALCL
CD43	T cells Histiocytes	T-cell neoplasms Some B-cell neoplasms
CD45RB	All leukocytes Not plasma cells	Lymphomas and leukemias
CD45RO (UCHL-1)	T cells Histiocytes Myeloid cells	T-cell neoplasms
CD56	NK cells	NK-cell neoplasms Some peripheral T-cell lymphomas
CD79a	B cells, including plasma cells	B-cell neoplasms including plasma cell tumors Nodular lymphocyte–predominant Hodgkin's disease
CD138	Plasma cells and precursors	Plasma cell tumors
Pax5	All B cells but not plasma cells	B-cell neoplasms
Oct2	Immunoglobulin producing B cells	B-cell neoplasms

ALCL, Anaplastic large cell lymphoma; *B-CLL/SLL,* B-cell chronic lymphocytic leukemia/small lymphocytic lymphoma; *NK,* natural killer.

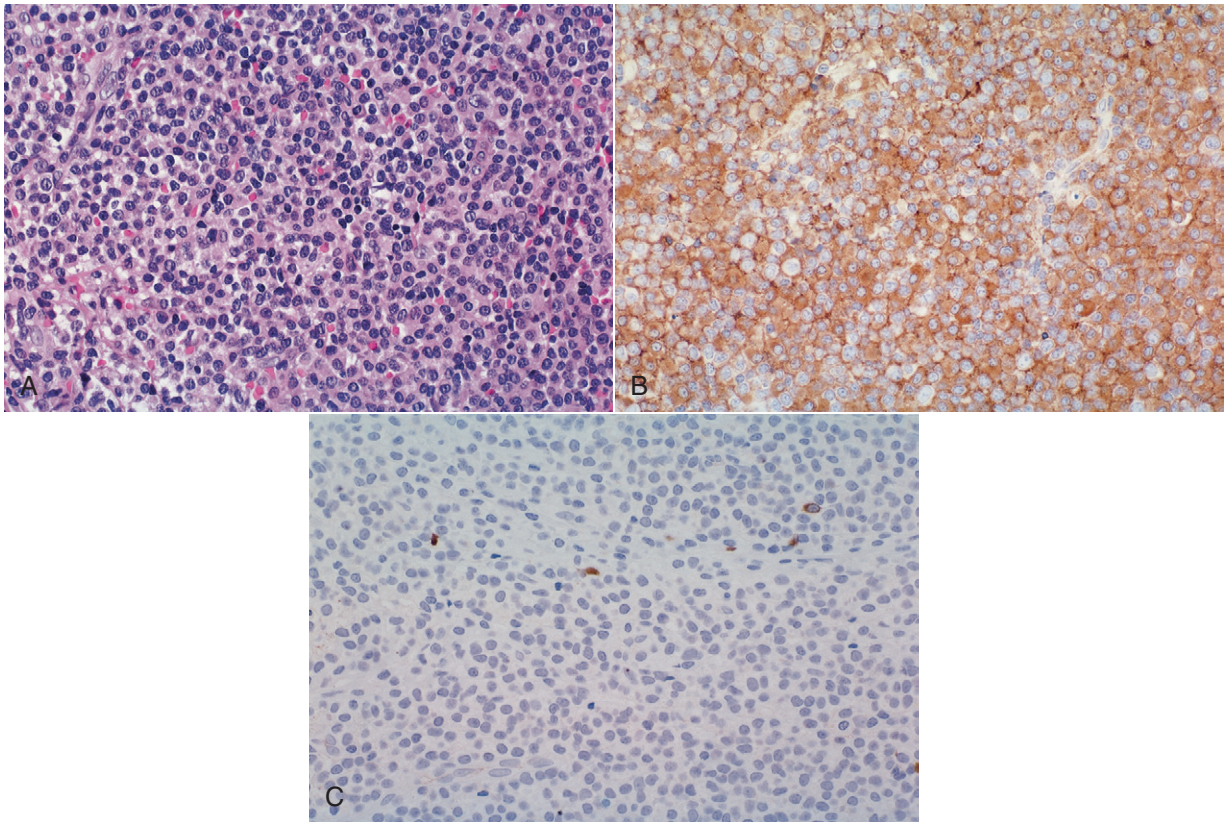

■ **FIGURE 9-10 A, Diffuse B-cell lymphoma. B** and **C,** Immunohistochemical stains for kappa (B) and lambda **(C)** light chains demonstrating monoclonality of infiltrate.

TABLE 9-5 ANTIBODY PANEL FOR IMMUNOPHENOTYPING OF LYMPHOMAS

Lymphoma Type	CD5	CD20	CD23	CD10	CD30	Cyclin D1	Bcl-2	CD3
B-CLL/SLL	+	–	+	–	–	–	–	–
Mantle cell	+	+	–	–	–	+	–	–
Marginal zone	–	+	–	–	–	–	–	–
Diffuse B-cell	–	+	–	–	–	–	±	–
Follicular	–	+	–	+	–	–	+	–
ALCL	–	–	–	–	+	–	±	+*

ALCL, Anaplastic large cell lymphoma; *B-CLL/SLL,* B-cell chronic lymphocytic leukemia/small lymphocytic lymphoma; *NK,* natural killer. *Positive in only about 25% of ALCL and negative in NK-cell type. Other positive T-cell markers, such as CD4 and CD2, are usually needed to confirm ALCL.

lymph nodes, normal lymphoid architecture is effaced and necrosis is common.

Follicular B-Cell Lymphoma. Follicular B-cell lymphomas are tumors composed of follicular center B lymphocytes arranged in nodules. This category of tumor accounts for 22% to 40% of all NHLs in whites, but only 5% to 10% of NHLs in Asians. It is typically a disease of older adults, presenting as a slowly growing, painless enlargement of one or several lymph nodes. It is rare in the oral cavity. The tumor is characterized by a protracted clinical course highlighted by numerous recurrences over several years. This tumor is essentially incurable, with a median survival of 5 to 10 years. Microscopically, there is effacement of normal lymph node architecture by neoplastic follicles composed of a range of follicular center–like cells, including small and large cleaved cells and, occasionally, large noncleaved cells.

Extranodal Marginal Zone Lymphoma. Extranodal marginal zone lymphoma was previously known as lymphoma of MALT (mucosa-associated lymphoid tissue). This indolent lymphoma occurs in mucosal sites and in extranodal tissues, including the gastrointestinal tract, salivary glands, lung, thyroid gland, and skin (Figure 9-11). Any age

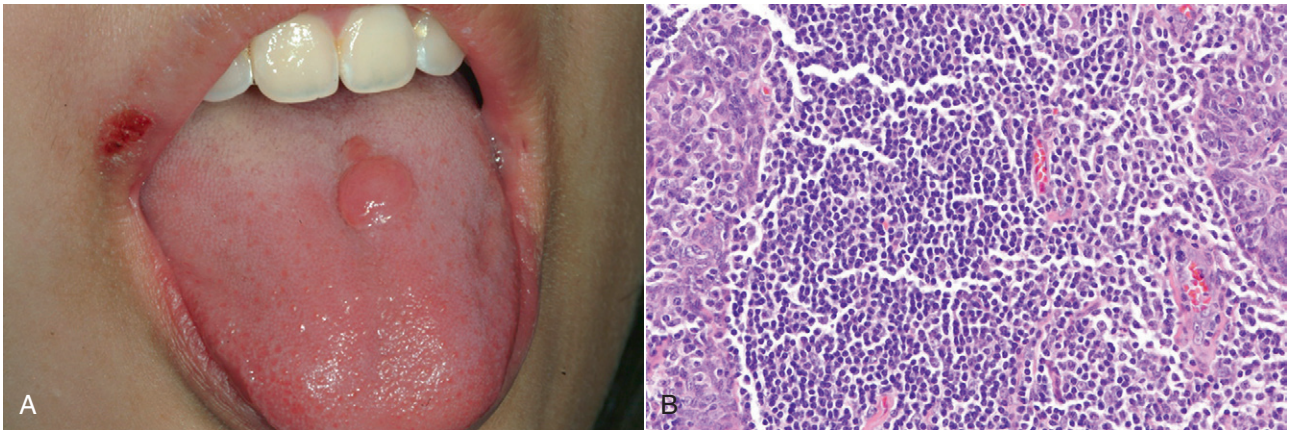

■ **FIGURE 9-11 A, Marginal zone lymphoma (mucosa-associated lymphoid tissue [MALT] lymphoma)** of the dorsum of the tongue presenting as a nodule. **B,** Microscopy shows sheets of small lymphoid cells and infiltration of epithelial islands.

group or gender can be affected, although in some settings, such as those associated with Sjögren's syndrome, a striking female predominance is evident. Predisposing factors for extranodal marginal zone lymphoma include Hashimoto's thyroiditis, Sjögren's syndrome, *Helicobacter pylori* gastritis, and *Borrelia burgdorferi* skin infection (Lyme disease). These lymphomas tend to localize to an involved organ for a protracted time before dissemination. Most cases are treated with local-regional therapy, and the prognosis is excellent, with 5-year survival on the order of 75%.

Microscopically, unifocal or multifocal involvement of extranodal tissues can be seen. All extranodal marginal zone lymphomas share several histopathologic features regardless of site. The tumor is composed predominantly of centrocyte-like (CCL) cells morphologically resembling a range from lymphocytes to monocytoid cells. In some tumors, the proportion of CCL cells showing plasmacytoid differentiation can be so extensive as to resemble a plasmacytoma. Clusters of CCL cells typically invade and destroy the epithelium to form lymphoepithelial lesions, which can be few or extensive (see Figure 9-11). The tumor cells begin proliferation in the marginal zone and gradually expand around reactive lymphoid follicles. Over time, the neoplastic CCL cells infiltrate the reactive follicles in one of three patterns termed *follicular colonization.* Occasionally, this can give the tumors a vague nodularity, which can lead to the misdiagnosis of a follicular lymphoma.

Mantle Cell Lymphoma. This B-cell lymphoma is derived from mantle zone cells of primary lymphoid follicles. The hallmark of this disease is the inappropriate overexpression of cyclin D1 protein. Mantle zone lymphoma occurs in middle-aged or older adults and has a striking male predominance. The condition typically presents as lymphadenopathy, but extranodal disease, including that in the spleen and gastrointestinal tract, is common. The clinical course is progressive, with an almost uniformly poor outcome. Most patients relapse within 24 months, with a 5-year survival rate of 30%. Histology shows a diffuse, vaguely nodular or nodular pattern of lymphocytes around residual reactive germinal centers. Cells are monotonous and small with indented or angulate nuclei but a spherical shape. Pleomorphic or *blastoid* variants are recognized and pursue an even more aggressive clinical course.

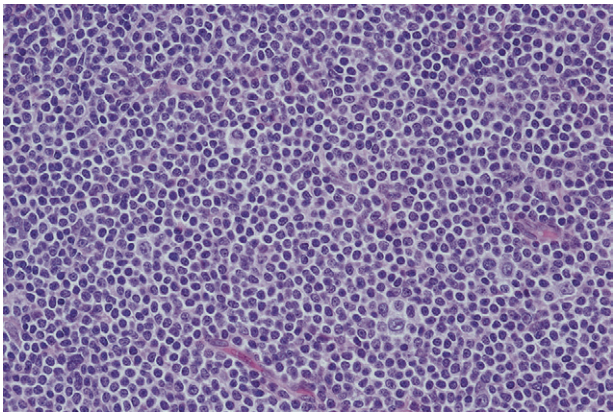

■ **FIGURE 9-12 Small lymphocytic lymphoma.**

B-Cell Chronic Lymphocytic Leukemia/Small Lymphocytic Lymphoma. B-cell chronic lymphocytic leukemia/small lymphocytic lymphoma (B-CLL/SLL) is an indolent lymphoma composed of a neoplastic proliferation of small, well-differentiated lymphocytes (Figure 9-12). Most cases have a leukemic presentation, and the lesions are rarely localized. The condition affects older patients and is typically an incidental finding in the peripheral blood. Bone marrow involvement at presentation is common, and about 40% of patients have B-type symptoms. Many have infectious complications, and some develop autoimmune hemolytic anemia. Because the condition is indolent and slowly progressive, many asymptomatic patients are not treated. B-CLL/SLL responds to single-agent chemotherapy, but cures are almost never achieved. The course of the disease is characterized by

frequent relapses and death after many years. The median survival is 5 to 8 years. Histologically, the following are evident: effacement of lymph nodes by small lymphocytes with small, rounded nuclei; condensed chromatin; inconspicuous nucleoli; and little cytoplasm.

Burkitt's Lymphoma. Burkitt's lymphoma (BL) is a highly aggressive B-cell lymphoma that primarily afflicts children and adolescents. Three forms of the disease are recognized: an endemic type in Africa, a sporadic form occurring in North America and Europe, and a form associated with immunodeficiency.

Endemic BL is a disease of children that occurs in equatorial Africa, where endemic malaria may serve as a pathogenetic cofactor. Approximately 95% of this form is associated with EBV infection. Jaw involvement is characteristic of endemic BL; up to 50% of those afflicted have lesions of the maxilla or mandible. Other organs are commonly involved, including the kidneys, liver, retroperitoneum, and gonads. Sporadic BL occurs in non-African countries and primarily affects young adults. This variety of BL often presents as an abdominal mass, and bone marrow involvement is more common than in the endemic form. Jaw lesions in sporadic BL are considerably less common than in endemic BL, occurring in approximately 10% of cases. BL can complicate HIV infection. Most patients are adults with marked immunosuppression. Tumor presentation is noted both in lymph nodes and at extranodal sites, particularly the central nervous system (CNS), bone marrow, and gastrointestinal tract. Although EBV has been identified in a large proportion of endemic BL, only 10% of cases of sporadic BL are associated with EBV infection. The outcome for endemic and sporadic BL depends on the stage at presentation. With aggressive chemotherapy protocols, the 5-year survival rate is greater than 75% for stages I to III, but only 25% for stage IV disease. For AIDS-associated BL, the prognosis is poor.

Microscopically, all forms of BL show similar findings consisting of monotonous sheets of densely packed, medium-sized neoplastic lymphocytes. The cytoplasm of the cells is deeply basophilic and often forms acute angles with neighboring cells in well-fixed sections. The tumor has a very high mitotic rate, with more than 10 mitoses per high-power field, and staining for the proliferation marker Ki-67 demonstrates that almost 100% of the tumor cells are dividing. Numerous macrophages containing cellular debris give the classic starry sky appearance to the tumor (Figure 9-13). Characteristic cytogenetic findings that involve translocation of the *c-Myc* gene on chromosome 8 with one of the immunoglobulin genes (heavy or light chain) on chromosome 2, 14, or 22 define the disease.

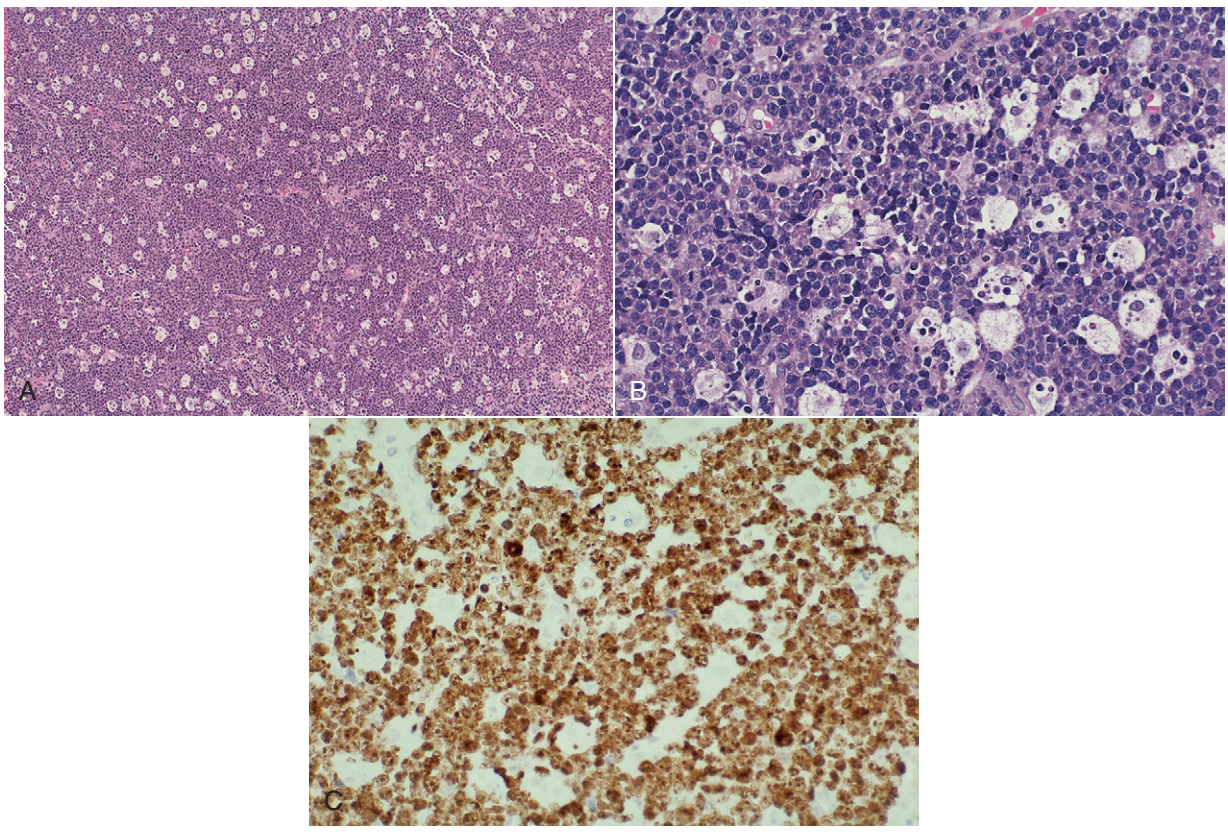

■ **FIGURE 9-13 A** and **B, Burkitt's lymphoma.** Note the starry sky effect due to scattered light-staining tingible body macrophages. **C,** Immunohistochemical stain for Ki-67 proliferation marker showing positive reaction in nearly all tumor cells.

Lymphomas Associated With Human Immunodeficiency Virus Infection. The development of NHL has long been recognized as a rare complication of many congenital immunodeficiency states. The increase in organ transplantation coupled with immunosuppression techniques has witnessed a marked increase in the development of many lymphoproliferative disorders. The development of lymphoma in the setting of HIV infection is recognized as an important complication of AIDS (Figure 9-14). It is a relatively late complication of HIV infection, with some lymphomas, particularly immunoblastic lymphoproliferations and plasmablastic lymphoma, occurring primarily when marked depression of CD4 T cells is seen.

In contrast to lymphomas complicating other immunodeficiency states, up to 75% of those arising in HIV infection occur at extranodal sites, and almost one fifth occur in the CNS. Sites of involvement are relatively distinct in AIDS-related lymphomas and include the CNS, anorectal region, and oral cavity. NHLs account for 3% of all malignant tumors within the oral cavity in patients with HIV infection. The most commonly affected sites include the gingiva, palate, and fauces, which typically exhibit a rapidly growing mass and/or tooth mobility. Characteristically, these lymphomas present as widespread disease with systemic symptoms. Also, a large proportion of patients will develop spread to the CNS and bone marrow during the course of their disease. In AIDS, B-cell lymphomas predominate, although T-cell lymphomas are also seen. Most B-cell lymphomas are plasmablastic, immunoblastic, or Burkitt's-like lymphoma. Plasmablastic lymphoma is a recently recognized aggressive B-cell lymphoma that occurs in the setting of HIV infection. It has a predilection for the oral cavity but can occur in other sites such as the GI tract and lymph nodes. Both EBV and human herpesvirus 8 (HHV8) have been implicated in the development of plasmablastic lymphoma, but the link with EBV is stronger. The prognosis for plasmablastic lymphoma is poor; reported average survival time is less than a year.

Anaplastic Large Cell Lymphoma. Anaplastic large cell lymphoma (ALCL) is an aggressive lymphoma of T-cell or natural killer (NK)-cell lineage that characteristically expresses the CD30 (Ki-1 or Ber-H2) antigen (Figure 9-15). Although expression of this antigen was thought to be specific for ALCL, it is now recognized that CD30 is an

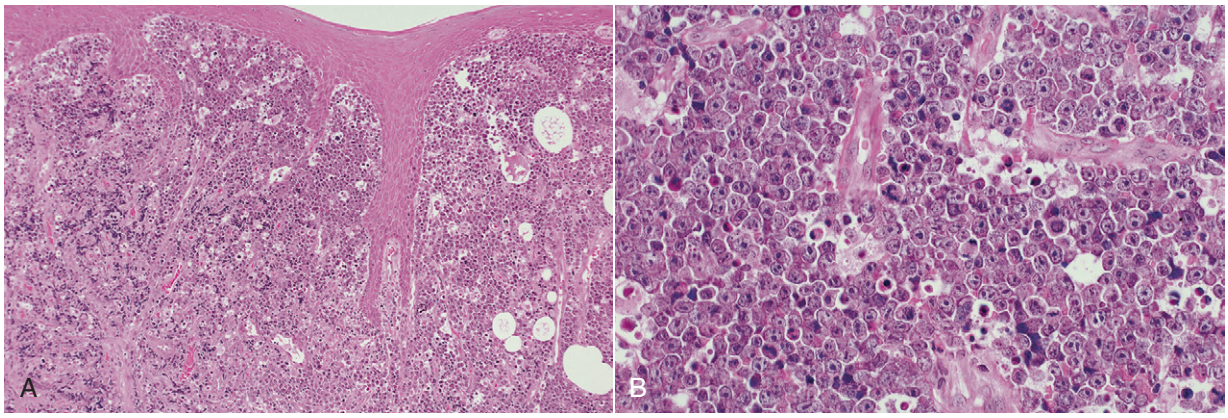

■ **FIGURE 9-14 A** and **B, High-grade lymphoma** from a palatal mass in a patient with acquired immunodeficiency syndrome (AIDS).

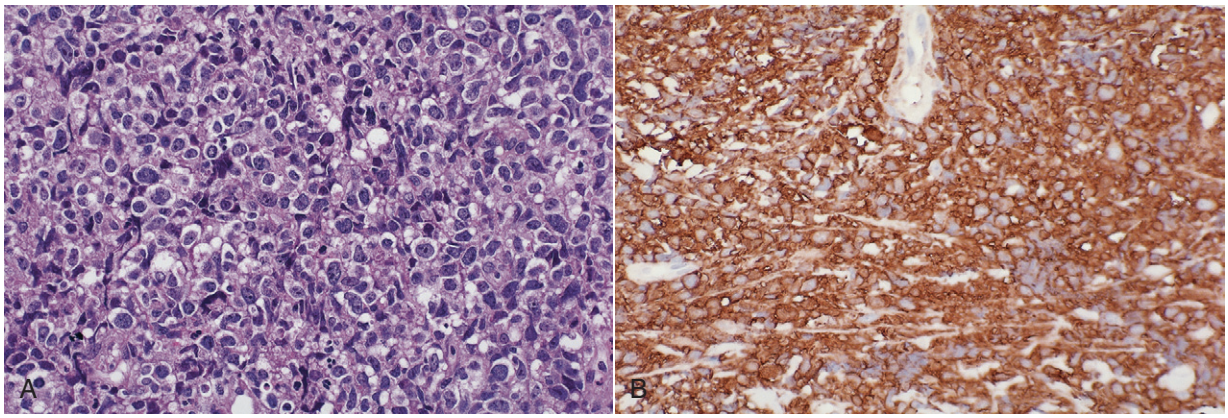

■ **FIGURE 9-15 A, Anaplastic large cell lymphoma. B,** Immunohistochemical stain for CD20 confirming B-cell lineage of tumor.

activation marker that can be expressed by other B-cell and T-cell lymphomas. It has been determined that the cytogenetic abnormality t(2;5) involving the *NPM* and *ALK* genes is an important characteristic of ALCL. The fact that up to 80% of ALCLs express the ALK protein in nuclei and cytoplasm of tumor cells makes this an important diagnostic feature.

ALCL has a characteristic bimodal age distribution, affecting both adolescents and older adults. Males are affected more often than females. The lymphoma has a variable clinical presentation with both lymph node and extranodal presentations, including skin, the gastrointestinal tract, and bone. Bone marrow involvement at presentation is variable, ranging from 10% to 40%, depending on whether morphologic or immunohistochemical methods are used for detection. Bone marrow involvement at presentation is a poor prognostic sign. Although the tumor is aggressive, it responds well to single- or multiple-agent chemotherapy, with a 5-year median survival rate of 77%. Histologically, many different patterns are noted. The prototypic form consists of large or very large cells with rounded or horseshoe-shaped single or multiple nuclei. Occasionally, the nuclei are arranged in a wreathlike pattern. The cytoplasm is amphophilic and abundant. ALCL may be difficult to differentiate from other large cell neoplasms such as undifferentiated carcinoma and malignant melanoma, hence the need for immunophenotyping to diagnose the condition.

Nasofacial Natural Killer/T-Cell Lymphoma. Progressive, ulcerative destruction of the palate, nose, and paranasal structures has long been recognized as a striking and potentially fatal condition. The term *midline lethal granuloma* was originally used to describe this condition, but various other terms have been suggested, including *polymorphous reticulosis, lymphomatoid granulomatosis, idiopathic destructive disease,* and *midline malignant reticulosis.* Evidence now shows that a variety of diseases, including Wegener's granulomatosis, infectious agents, and lymphoma, were diagnosed as midline (lethal) granuloma. After exclusion of Wegener's granulomatosis and infection, remaining cases appear to be T-cell or NK-cell (NK/T-cell) lymphomas. At this site, it is often difficult to histologically separate T-cell lymphoma from NK-cell lymphoma, hence the term *nasofacial NK/T-cell lymphoma* is preferred.

Nasofacial NK/T-cell lymphoma is an aggressive lymphoma of adults, with a median age at presentation of 53 years. Men are affected more often than women. Nasal symptoms are often the most common presenting feature, with epistaxis occasionally present. Some patients may present early on with swelling of the soft or hard palate. Over time, this evolves to frank ulceration and destruction of the palatal and nasal tissues, often leading to an oronasal fistula. Without treatment, the relentless destruction of midface structures by the lymphomatous infiltrate can lead to death from hemorrhage or secondary infection. Typically, the condition is treated with chemotherapy, radiation therapy, or a combination of both. Reports of long-term survival vary, in part because of confusion regarding diagnosis of the condition. Overall survival from the time of diagnosis has been reported as ranging from 3 months to 14 years. More aggressive management has improved the prognosis to a 5-year disease-free survival of 78% for patients with early-stage lesions and 19% for those with more widely disseminated disease.

The microscopic appearance of nasofacial NK/T-cell lymphoma is characterized by the presence of varying amounts of granulation tissue and necrosis. An inflammatory infiltrate consists of a mixture of acute and chronic inflammatory cells intermingled with atypical lymphocytes that can range from a few in number to a predominant proportion of the infiltrate. These cells are medium-sized or large with a clear cytoplasm and an irregular nuclear outline. Some have prominent nucleoli and may resemble immunoblasts. Angiocentricity and epitheliotropism are common histopathologic features of nasofacial NK/T-cell lymphoma. A minority of cases of midface destructive disease are caused by other types of lymphoma, including various B-cell lymphomas.

Eosinophil-Rich CD30-Positive Lymphoproliferative Disorder. This unusual lymphoma has been reported in the oral cavity and resembles primary cutaneous T-cell lymphoma. Clinically, the condition presents as a solitary ulcer, often of the tongue. Microscopically, the stromal cellular infiltrate is composed of small round lymphocytes and abundant eosinophils intermixed with an atypical population of small and medium-sized and sparse large cells with atypical nuclei and prominent nucleoli. The large cells express CD3 and CD30 antigens. By molecular analysis, the T-cell receptor is clonal, consistent with a neoplasm. The microscopy of eosinophil-rich CD30-positive lymphoproliferative disorders resembles *traumatic ulcerative granuloma* (TEG) of the oral mucosa, a chronic but self-limiting reactive lesion, which has been known by several terms, including *traumatic granuloma of the tongue, traumatic ulcerative granuloma with stromal eosinophilia, eosinophilic ulcer of the oral mucosa, oral traumatic granuloma,* and *eosinophilic granuloma of soft tissue.* Despite its name, the relationship between TEG and trauma is unclear. The clinical course of eosinophil-rich CD30-positive lymphoproliferative disorder is not well understood because published cases are few, but it appears to follow an indolent course and some cases are cured with simple excision.

Hodgkin's Lymphoma

Hodgkin's lymphoma rarely involves the oral cavity, although there are cases in which this disease has appeared in the soft tissues, as well as in the mandible and maxilla. On occasion, the oral manifestations may represent the primary site of involvement; in other cases, associated cervical lymphadenopathy or more widespread disease may be noted concurrently.

Clinical Features. Generally, Hodgkin's lymphoma occurs over a wide age spectrum, with clustering of patients between 15 and 35 years of age and beyond 55 years of age. A slight male predilection has been noted. Clinically, Hodgkin's lymphoma is characterized by painless enlargement of lymph nodes or extranodal lymphoid tissue. Within the oral cavity, tonsillar enlargement, usually unilateral, may be seen in the early phases. When extranodal sites are involved, submucosal swellings may be seen, sometimes with mucosal ulceration or erosion of underlying bone. Subsequent to microscopic diagnosis, clinical staging must be undertaken. This may consist of physical examination, radiographic imaging, lymphangiography, and laparotomy. After the staging procedure, a definitive treatment plan is established. Box 9-1 provides details of the Ann Arbor system of clinical staging.

Histopathology. Of greatest significance is identification of the Reed-Sternberg cell, which must be present for the diagnosis of Hodgkin's lymphoma to be established. This cell of lymphocytic origin is characterized by its large size and bilobed nucleus; each lobe contains a large amphophilic or eosinophilic nucleolus. The nuclear chromatin pattern is vesicular and condensed at the periphery. Other Reed-Sternberg cells may be characterized by two nuclei with a prominent nucleolus or by multiple nuclei. Cells similar to Reed-Sternberg cells may be seen in certain viral diseases, such as infectious mononucleosis and BL, as well as in patients with treated lymphocytic lymphoma, chronic lymphocytic leukemia, or some benign immunoblastic proliferations.

The REAL/WHO system for classifying Hodgkin's lymphoma is the most current and most widely used system; it is based on two earlier systems: the Lukes-Butler and Rye schemes. Classic Hodgkin's lymphoma comprises four entities: (1) lymphocyte-rich, classic; (2) nodular sclerosis; (3) mixed cellularity; and (4) lymphocyte depletion types. The REAL/WHO system has added lymphocyte predominant, nodular, which is not a classic type. The lymphocyte-rich, classic type has the most favorable prognosis, and the lymphocyte depletion type has the least favorable prognosis. In the lymphocyte-rich, classic form, a small, mature lymphocyte is the most prevalent cell, but it is mixed with scattered macrophages. Few Reed-Sternberg cells are seen in this form of the disease.

The most common form of Hodgkin's lymphoma is the nodular-sclerosing type, which accounts for more than 50% of cases. It is characterized by bands of collagen that originate from the periphery and penetrate into the lymph node, subdividing it into islands of tumor that contain Reed-Sternberg cells.

The mixed cellularity type of Hodgkin's lymphoma contains a combination of lymphocytes, eosinophils, neutrophils, plasma cells, and macrophages, and many Reed-Sternberg cells. The mixed cellularity type of Hodgkin's lymphoma carries a prognosis that is intermediate between the nodular sclerosing type and the lymphocyte depletion form.

In the lymphocyte depletion form of Hodgkin's disease, the chief microscopic characteristic is abundant pleomorphic Reed-Sternberg cells and relatively few lymphocytes.

Differential Diagnosis. Cervical lymphadenopathy would suggest conditions ranging from inflammatory to neoplastic. Specified entities that can produce lymph node enlargement include chronic lymphadenitis, infectious disease, and lymphoma. In young patients, infectious mononucleosis should be considered. Nonlymphoid lateral neck lesions that could be included in a clinical differential diagnosis encompass salivary gland tumors, cervical lymphoepithelial cyst, carotid body tumor, and metastatic cancer.

Treatment and Prognosis. Clinical staging and histologic classification of Hodgkin's disease are critical in determining management and prognosis. The lymphocyte-rich, classic form of disease carries with it the most favorable prognosis, and the lymphocyte depletion form has the worst prognosis. Stage I disease has the best prognosis, and stage IV (disseminated disease) the worst. Generally, the clinical stage has a greater influence on the overall prognosis than does the histologic subtype. Management of Hodgkin's disease consists of external radiation therapy and multiple-agent chemotherapy. What was once a fatal illness with poor survival statistics has become a curable disease. Most patients with Hodgkin's disease are cured because of treatment with intensive radiotherapy and/or chemotherapy.

Multiple Myeloma/Plasmacytoma

Plasma cell neoplasms include multiple myeloma, solitary plasmacytoma of bone, and extramedullary plasmacytoma and are characterized by expansion of a clone of immunoglobulin-secreting cells (Figure 9-16) (see also Chapter 14). The biological behavior of these conditions varies, although histologically, all contain monotonous sheets of neoplastic cells resembling plasma cells. The cell population may vary from small, well-differentiated cells with an eccentric nucleus and basophilic cytoplasm to less well differentiated, atypical cells resembling immunoblasts.

The most common and important plasma cell neoplasm is multiple myeloma characterized by multiple osteolytic bone lesions, serum or urinary M proteins, and bone marrow biopsy findings showing greater than 10% plasma cell composition (Figure 9-17). Symptoms are related to infiltration of organs by neoplastic plasma cells and by excessive production of immunoglobulins having abnormal biochemical properties. Pathologic fractures occur in 20% of patients. Advanced disease is associated with hypercalcemia and renal failure. Bone marrow infiltration leads to anemia, thrombocytopenia, and leukocytopenia, with the latter resulting in increased susceptibility to infection. Jaw lesions can be identified in 30% of cases of multiple myeloma and

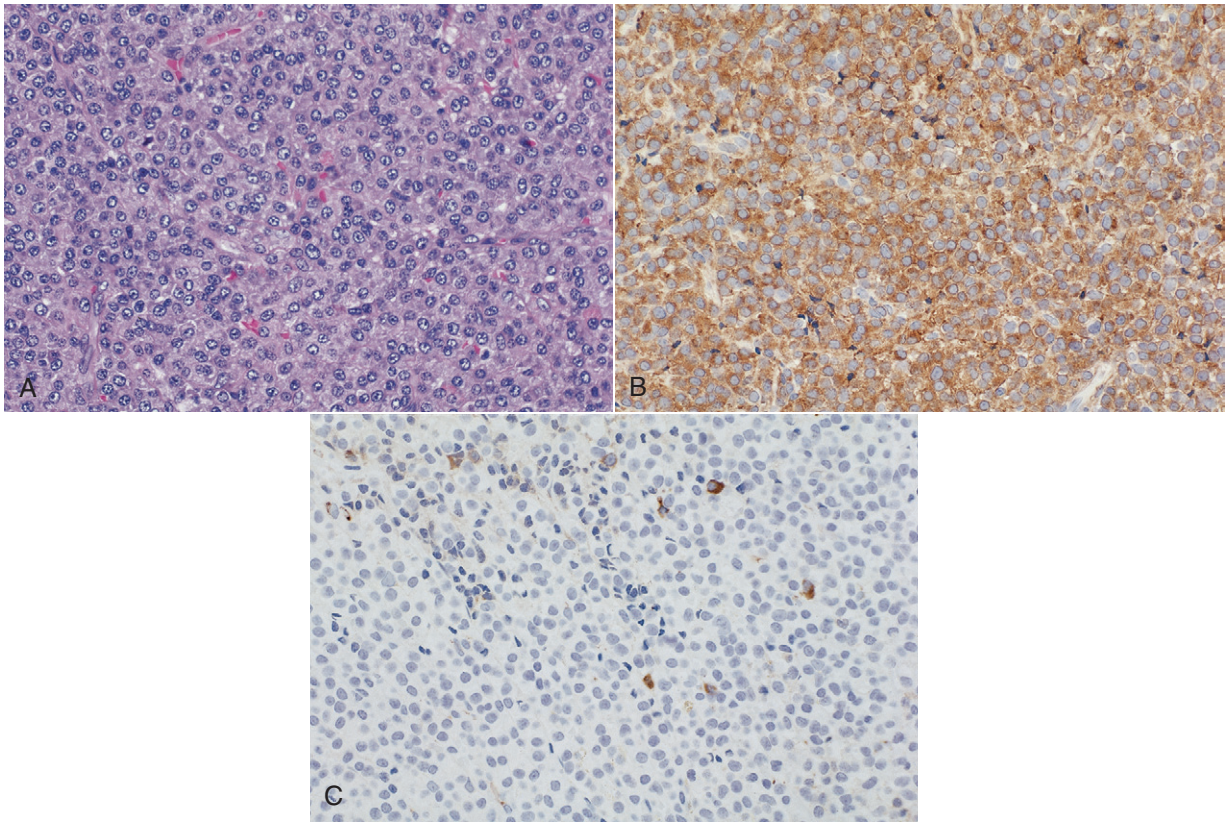

■ **FIGURE 9-16 A, Multiple myeloma** composed of neoplastic plasma cells. **B** and **C,** Immunohistochemical stains for kappa **(B)** and lambda **(C)** light chains demonstrating monoclonality of the plasma cells.

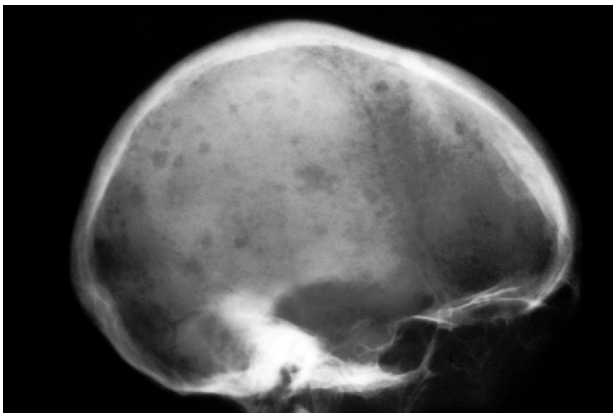

■ **FIGURE 9-17 Multiple myeloma** showing multiple punched-out lesions of the skull.

radiographically appear as noncorticated, well-defined radiolucencies that are more common in the mandible than in the maxilla (Figures 9-18 to 9-20). The posterior portions of the jaw are more commonly affected because the marrow spaces are larger. The formation of amyloid from the aggregation of immunoglobulin light-chain proteins is a common sequela of multiple myeloma and when deposited in the tongue can produce macroglossia. Treatment of multiple myeloma is directed at reducing the tumor burden and reversing complications of the disease, such as those related to renal failure or osteolytic tumor foci. Single-agent or multiagent alkylating chemotherapy is the treatment of choice for multiple myeloma. New agents such as the proteasome inhibitor bortezomib and the antiangiogenic immunomodulator thalidomide and its analogs have been studied alone and in combination with other antineoplastic therapies; as induction therapy prior to stem cell transplantation or in patients with relapsed disease, they may offer promise for future therapies.

A solitary focus of lytic bone destruction showing a plasma cell tumor without bone marrow involvement is termed *solitary plasmacytoma of bone.* This lesion constitutes 3% of all plasma cell neoplasms and is believed to represent a localized myeloma. Involvement of the facial bones is rare and, when present, typically represents disseminated disease. Progression to myeloma occurs in 30% to 75% of cases, although long-term survival is common. Solitary lesions are typically treated with radiation therapy supplemented by chemotherapy. When the disease is disseminated, it is treated as myeloma.

Isolated plasma cell tumors within soft tissues are termed *extramedullary plasmacytoma.* This definition excludes tumors that have arisen in bone, involving soft tissues secondarily, following perforation of the bone cortex. More than 80% of all extramedullary plasmacytomas arise in the

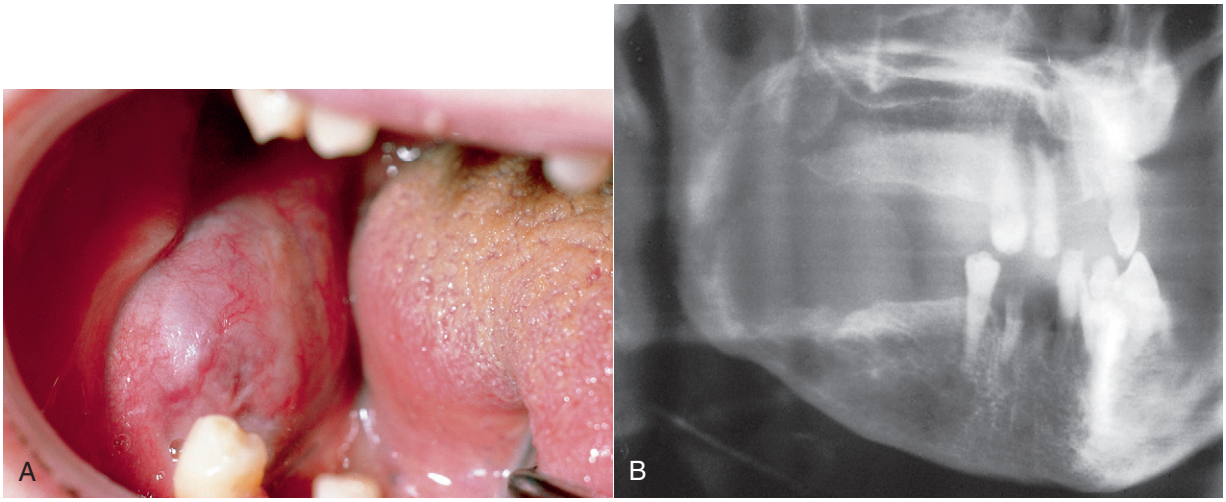

■ **FIGURE 9-18 Multiple myeloma. A** and **B,** Right mandibular mass.

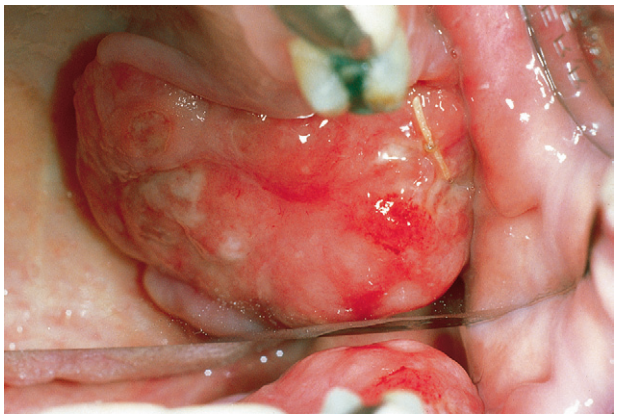

■ **FIGURE 9-19 Multiple myeloma** involving the left maxillary tuberosity.



■ **FIGURE 9-20 Multiple myeloma** presenting orally as an ulcerated gingival mass.

upper respiratory tract and oral cavity, accounting for 4% of all nonepithelial neoplasms of the nose, nasopharynx, and paranasal sinuses. The clinical appearance is of a dark red, fleshy mass that rarely ulcerates. Multiple lesions at other sites in the head and neck are seen in 20% of patients, and up to 40% may have involvement of regional lymph nodes. Unlike with multiple myeloma and solitary plasmacytoma of bone, wide dissemination is rare and typically shows no preference for active hematopoietic sites. In contrast to the behavior of solitary plasmacytoma of bone, many reports have shown that the progression of extramedullary plasmacytoma to myeloma is distinctly uncommon. Extramedullary plasmacytomas are radiosensitive, and regional control rates of 80% can be achieved.

A complication not infrequently associated with multiple myeloma is *amyloidosis* (Figures 9-21 and 9-22). Amyloid is the deposition of complex proteins in tissues that, when



■ **FIGURE 9-21 Amyloidosis** of the tongue resulting in macroglossia.

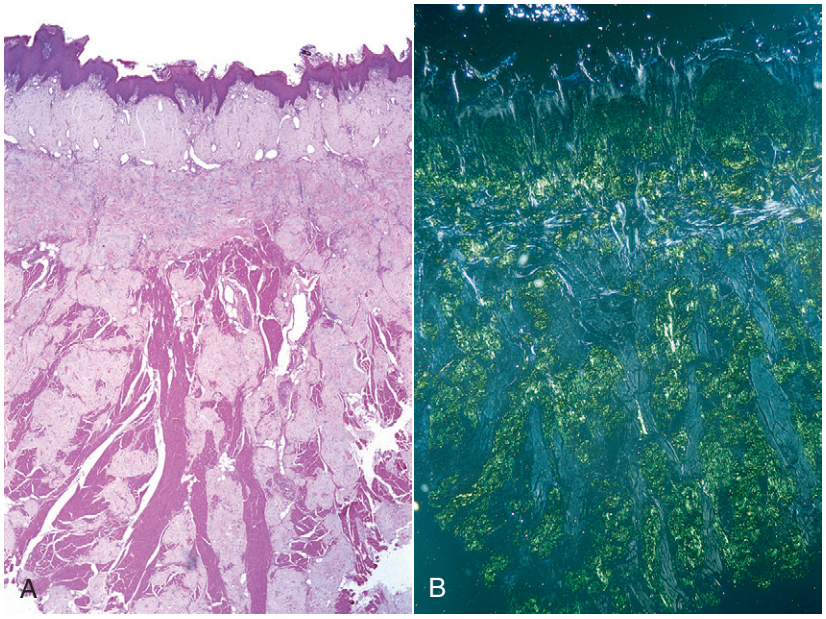

■ **FIGURE 9-22 A, Amyloidosis** of the tongue exhibiting pale eosinophilic deposits between skeletal muscle bundles *(right)*. **B,** Congo red stain in polarized light showing characteristic apple green birefringence of amyloid deposits. (*Note:* Mucosa is to the left in **A** and **B.**)

TABLE 9-6 AMYLOIDOSIS CLASSIFICATION ACCORDING TO FIBRIL-FORMING PROTEINS

Disease	Amyloid Subtype and Protein	Precursor Protein
Primary amyloidosis (myeloma associated)	AL	Igκ, Igλ
Secondary amyloidosis (chronic inflammatory disease associated)	AA	Serum amyloid A (apoSAA)
Chronic renal failure	$A\beta_2M$	β_2-Microglobulin
Alzheimer's disease	Aβ	Amyloid β-precursor protein
Medullary carcinoma of thyroid	ACa	Calcitonin

Ig, Immunoglobulin.

stained with the dye Congo red, shows apple green birefringence under polarized light. Several forms of amyloid may occur in various clinical conditions, including multiple myeloma, some chronic inflammatory diseases, and several hereditary conditions. The constituent proteins of each condition differ, but common to all is a unique protein folding pattern known as a *beta-pleated sheet.* By electron microscopy, all amyloid has a fibrillar appearance. The most common proteins making up amyloid are immunoglobulin light chains (Table 9-6). Other proteins that can aggregate into amyloid include liver-derived amyloid-associated nonimmunoglobulin protein, transthyretin, beta 2-microglobulin, and some keratins. In multiple myeloma, excess immunoglobulin light chains are produced and combine to form amyloid. These are deposited in organs such as the kidney, replacing normal tissues and resulting in organ dysfunction. Also in multiple myeloma, nodular or diffuse deposits of amyloid may be seen on the tongue, producing macroglossia.

Leukemias

Leukemias encompass a group of disorders characterized by neoplastic proliferation of bone marrow lymphocyte or myeloid precursors that replace the marrow and can be identified in the peripheral blood. Neoplastic cells can also infiltrate other organs such as the liver, spleen, and lymph nodes, and other tissues. Various causes have been attributed to the development of specific forms of leukemia, including genetic factors such as specific chromosome translocations (t[9;22] in chronic myeloid leukemia), environmental agents such as benzene, ionizing radiation, and viruses such as human T-cell lymphotrophic virus type 1 (HTLV-1) in adult T-cell leukemia.

Leukemias are classified on the basis of the type of progenitor cell (myeloid or lymphoid lineage) and the clinical presentation (acute or chronic). Acute leukemias are characterized by the presence of immature cells and a fulminant clinical course. Chronic leukemias are characterized by the presence of better-differentiated, mature cells and a more indolent clinical course.

Acute Leukemias. Acute myeloid leukemia (AML) is a disease of adults, and acute lymphocytic leukemia (ALL) is predominantly a disease of children. Patients with AML or ALL present with bleeding (due to thrombocytopenia), fatigue (due to anemia), and infection (due to agranulocytosis). Diagnosis is established by examination of the peripheral blood differential and count and is confirmed by bone marrow biopsy findings showing greater than 5% blast cells. Treatment of ALL in children has been one of medicine's great success stories; between 50% and 80% of patients with AML achieve complete remission with aggressive chemotherapy. Several decades ago, ALL was almost uniformly fatal. For those who relapse, cure is rare without bone marrow transplantation. Between 60% and 90% of patients with ALL achieve remission.

Chronic Leukemias. Both chronic myeloid leukemia (CML) and chronic lymphocytic leukemia (CLL) are diseases of adults. The incidence of CML is highest in the fourth and fifth decades of life and rare in children. CLL occurs more commonly than other types of leukemia and has a median age at diagnosis in the seventh decade of life. Most patients with CML are asymptomatic. Some may have fatigue, weight loss, fever, and night sweats. Symptoms related to splenomegaly may also occur. CLL is also most commonly asymptomatic at diagnosis, although as the disease progresses, lymphadenopathy, splenomegaly, and hepatomegaly may occur. The diagnosis of chronic leukemia is made by examination of the peripheral blood and by bone marrow biopsy. A common complication of CML, particularly the myelomonocytic and monocytic forms, is generalized gingival hypertrophy (Figure 9-23). The gingiva is red, boggy, and edematous, and it bleeds easily. Sometimes this may be the initial presenting feature of CML. The gingival appearance is due to infiltration by neoplastic myeloid cells. Both CML and CLL are difficult to cure. CML is managed by chemotherapy, typically with hydroxyurea or busulfan. More recently, interferon-alpha and a tyrosine kinase inhibitor have been used with clinical efficacy. CLL often is not treated if the patient is elderly or asymptomatic. Symptomatic CLL patients and those with extensive disease will receive alkylating chemotherapy, although cure is unlikely.

Granulocytic Sarcoma

Granulocytic sarcoma, also known as extramedullary myeloid tumor, is a localized infiltrate of immature granulocytes in an extramedullary site that superficially resembles sarcoma clinically. Oral granulocytic sarcoma presents as a localized soft tissue mass, although less frequently intraosseous presentation has been reported. Clinically, granulocytic sarcoma may occur in three settings: in a patient previously known to have AML; as a sign of blast transformation in a patient with CML or another chronic myeloproliferative disorder; or in a patient who was previously well.

Granulocytic sarcoma may be difficult to differentiate histologically from other malignancies such as large cell lymphoma, poorly differentiated carcinoma, or even plasmacytoma (Figure 9-24). Crystalline, rodlike, intracytoplasmic acidophilic bodies (Auer rods) can establish the diagnosis of both granulocytic sarcoma and AML; however, they may be present in less than 10% of cases. Diagnostic confirmation usually requires histochemical staining to demonstrate the presence of myeloperoxidase. Naphthol AS-D chloroacetate esterase and α-naphthol acetate esterase demonstrate the presence of granulocytic esterases. Specific markers of cluster differentiation (CD) typical of myeloid (granulocytic) lineage, including CD15, can also be demonstrated using immunohistochemistry.

The prognosis for granulocytic sarcoma is poor. In patients with no history of leukemia, the frequent association with AML has prompted some clinicians to recommend chemotherapy regimens for patients with granulocytic sarcoma that are typical for the management of acute leukemia. Although few long-term survivors have been described, these individuals generally received chemotherapy shortly after diagnosis.



■ **FIGURE 9-23 Chronic monocytic leukemia** of the gingiva.

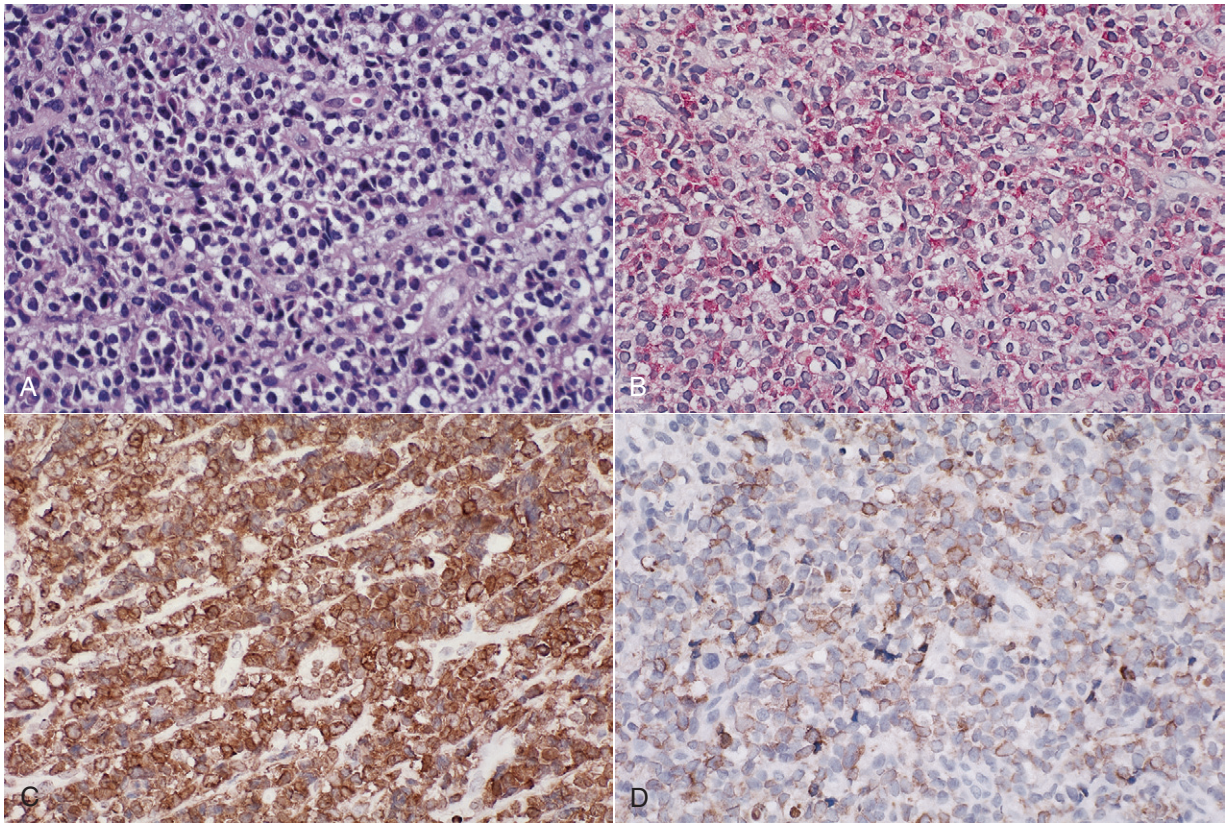

■ **FIGURE 9-24 A, Granulocytic sarcoma. B,** Positive *(red)* chloroacetate esterase stain of tumor cells. **C** and **D,** Positive *(brown)* immunohistochemical stains for CD43 and myeloperoxidase. Stains shown confirm the granulocyte lineage of the tumor infiltrate.

BIBLIOGRAPHY

Reactive Lesions

d'Agay MF, de Roquancourt A, Peuchamaur M et al: Cystic benign lymphoepithelial lesion of the salivary glands in HIV-positive patients. Virchows Arch A Pathol Anat Histopathol 417:353–356, 1990.

Finfer MD, Gallo L, Perchick A et al: Fine needle aspiration of cystic benign lymphoepithelial lesion of the parotid gland in patients at risk for the acquired immune deficiency syndrome. Acta Cytol 34:821–826, 1990.

Napier SS, Newlands C: Benign lymphoid hyperplasia of the palate: report of two cases and immunohistochemical profile. J Oral Pathol Med 19:221–225, 1990.

Developmental Lesions

Elliott JN, Oertel YC: Lymphoepithelial cysts of the salivary glands: histologic and cytologic features. Am J Clin Pathol 93:39–43, 1990.

Hong SS, Ogawa Y, Yagi T et al: Benign lymphoepithelial lesion with large cysts. Oral Surg Oral Med Oral Pathol 19:266–270, 1990.

Neoplasms

Alobeid B, Pan LX, Milligan L et al: Eosinophil-rich CD30+ lymphoproliferative disorder of the oral mucosa: a form of "traumatic eosinophilic granuloma." Am J Clin Pathol 121:43–50, 2004.

Carbone A, Vaccher E, Barzan L et al: Head and neck lymphomas associated with human immunodeficiency virus infection. Arch Otolaryngol Head Neck Surg 121:210–218, 1995.

Chan JKC: Advances in immunohistochemical techniques: toward making things simpler, cheaper, more sensitive, and more reproducible. Adv Anat Pathol 5:314–325, 1998.

Chan JKC: Tumors of the lymphoreticular system, including spleen and thymus. In Fletcher CDM, editor: Diagnostic Histopathology of Tumors, ed 2, London, 2001, Churchill Livingstone.

Chu PG, Chang KL, Arber DA et al: Practical applications of immunohistochemistry in hematolymphoid neoplasms. Ann Diagn Pathol 3:104–133, 1999.

Dardick I, Moher D, Cavell S et al: An ultrastructural morphometric study of follicular center lymphocytes. III. The control of lymphocyte nuclear size in reactive hyperplasia and non-Hodgkin's lymphoma. Mod Pathol 3:176–185, 1990.

Druker BJ, Talpaz M, Resta DJ et al: Efficacy and safety of a specific inhibitor of the BCR-ABL tyrosine kinase in chronic myeloid leukemia. N Engl J Med 344:1031–1037, 2001.

Economopoulos T, Asprou N, Stathakis N et al: Primary extranodal non-Hodgkin's lymphoma in adults: clinicopathological and survival characteristics. Leuk Lymphoma 21:131–136, 1996.

Green JD, Neel HB, Witzig TE: Lymphoproliferative disorders of the head and neck. Am J Otolaryngol 12:26–32, 1991.

Grogan TM, Miller TP, Fisher RI: A southwest oncology group perspective on the revised European-American Lymphoma Classification. Hematol/Oncol Clin North Am 11:819–842, 1997.

Guggisberg K, Jordan RC: Mantle cell lymphoma of the oral cavity: case series and comprehensive review of the literature. Oral Surg Oral Med Oral Pathol Oral Radiol Endod 109:98–104, 2010.

Hamilton-Dutoit SJ, Pallesen G, Franzmann MB et al: AIDS-related lymphoma. Am J Pathol 138:149–163, 1991.

Harris NL, Jaffe ES, Stein H et al: A revised European-American classification of lymphoid neoplasms: a proposal from the International Lymphoma Study Group. Blood 84:1361–1392, 1994.

Ioachim HL, Dorsett B, Cronin W et al: Acquired immunodeficiency syndrome-associated lymphomas: clinical, pathologic, immunologic, and viral characteristics of 111 cases. Hum Pathol 22:659–673, 1991.

Jaffe ES, Chan JK, Su IJ et al: Report of the workshop on nasal and related extranodal angiocentric T/natural killer cell lymphomas: definitions, differential diagnosis, and epidemiology. Am J Surg Pathol 20:103–111, 1996.

Jordan RCK, Chong L, Dipierdomenico S et al: Oral lymphoma in human immunodeficiency virus infection: a report of six cases and review of the literature. Otolaryngol Head Neck Surg 119:672–677, 1998.

Jordan RCK, Speight PM: Extranodal non-Hodgkin's lymphomas of the oral cavity, Curr Top Pathol 90:125–146, 1996.

Kantarjian HM, Smith TL, O'Brien S et al: Prolonged survival in chronic myelogenous leukemia after cytogenetic response to interferon-alpha therapy: the leukemia service, Ann Intern Med 122:254–261, 1995.

Leong IT, Fernandes BJ, Mock D: Epstein-Barr virus detection in non-Hodgkin's lymphoma of the oral cavity: an immunocytochemical and in situ hybridization study, Oral Surg Oral Med Oral Pathol Oral Radiol Endod 92:184–193, 2001.

Morra E: The biological markers of non-Hodgkin's lymphomas: their role in diagnosis, prognostic assessment and therapeutic strategy, Int J Biol Markers 14:149–153, 1999.

Parker SL, Tong T, Bolden S et al: Cancer statistics, 1997. CA Cancer J Clin 47:5–27, 1997.

Regezi JA, Zarbo RJ, Stewart JCB: Extranodal oral lymphomas: histologic subtypes and immunophenotypes (in routinely processed tissue). Oral Surg Oral Med Oral Pathol 72:702–708, 1991.

Sarode SC, Sarode GS, Patil A: Plasmablastic lymphoma of the oral cavity: a review. Oral Oncol 46:146–153, 2010.

Serraino D, Pezzotti P, Dorrucci M et al: Cancer incidence in a cohort of human immunodeficiency virus seroconverters. Cancer 79:1004–1008, 1997.



CHAPTER 10

Cysts of the Jaws and Neck

ODONTOGENIC CYSTS

Periapical (Radicular) Cyst
Lateral Periodontal Cyst
Gingival Cyst of the Newborn
Dentigerous Cyst
Eruption Cyst
Glandular Odontogenic Cyst
Odontogenic Keratocyst/Keratocystic Odontogenic Tumor
Calcifying Odontogenic Cyst

NONODONTOGENIC CYSTS

Globulomaxillary Cyst/Lesion
Nasolabial Cyst
Median Mandibular Cyst
Nasopalatine Canal Cyst

PSEUDOCYSTS

Aneurysmal Bone Cyst
Traumatic (Simple) Bone Cyst
Static Bone Cyst (Stafne's Bone Defect)
Focal Osteoporotic Bone Marrow Defect

SOFT TISSUE CYSTS OF THE NECK

Branchial Cyst/Cervical Lymphoepithelial Cyst
Dermoid Cyst
Thyroglossal Tract Cyst

A *cyst* is defined as an epithelial-lined pathologic cavity. Cysts of the maxilla, mandible, and perioral regions vary markedly in histogenesis, incidence, behavior, and treatment. Cysts are divided into odontogenic cysts, nonodontogenic cysts, pseudocysts, and neck cysts. In contrast to true cysts, pseudocysts lack an epithelial lining.

ODONTOGENIC CYSTS

Periapical (Radicular) Cyst

Periapical (radicular or apical periodontal) cysts are by far the most common cysts of the jaws. These inflammatory cysts derive their epithelial lining from the proliferation of small odontogenic epithelial residues (rests of Malassez) within the periodontal ligament.

Etiology and Pathogenesis. A periapical cyst develops from a preexisting *periapical granuloma,* which is a focus of chronically inflamed granulation tissue located at the apex of a nonvital tooth (Figures 10-1 and 10-2). Periapical granulomas are initiated and maintained by the degradation products of necrotic pulp tissue. Stimulation of the resident epithelial rests of Malassez occurs in response to the products of inflammation (Table 10-1). Cyst formation occurs as a result of epithelial proliferation, which helps to separate the inflammatory stimulus (necrotic pulp) from the surrounding bone (Figure 10-3).

Breakdown of cellular debris within the cyst lumen raises the protein concentration, increasing osmotic pressure and resulting in fluid transport across the epithelial lining into the lumen from the connective tissue side. Fluid ingress assists in outward growth of the cyst. With osteoclastic bone resorption, the cyst expands. Other bone-resorbing factors, such as prostaglandins, interleukins, and proteinases, from inflammatory cells and cells in the peripheral portion of the lesion permit additional cyst enlargement.



■ **FIGURE 10-1 Periapical granulomas** associated with nonvital teeth.

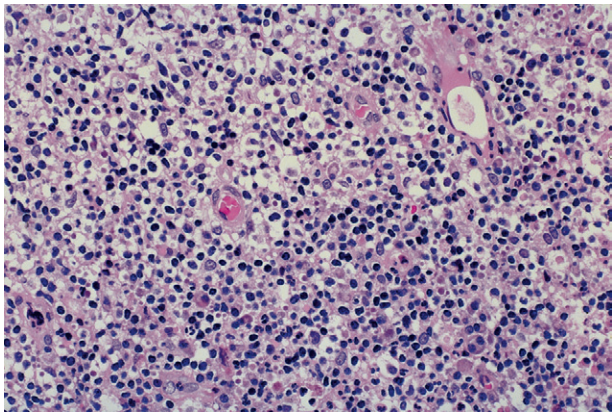

■ **FIGURE 10-2 Periapical granuloma** composed of a mixed inflammatory cell infiltrate in a connective tissue stroma.

Clinical Features. Periapical cysts constitute approximately one half to three fourths of all cysts in the jaws (Box 10-1). The age distribution peaks in the third through sixth decades. Of note is the relative rarity of periapical cysts in the first decade, even though caries and nonvital teeth are rather common in this age group. Most cysts are located in the maxilla, especially the anterior region, followed by the maxillary posterior region, the mandibular posterior region, and finally the mandibular anterior region.

Periapical cysts usually are asymptomatic and often are discovered incidentally during routine dental radiographic examination (Figures 10-4 and 10-5). They cause bone

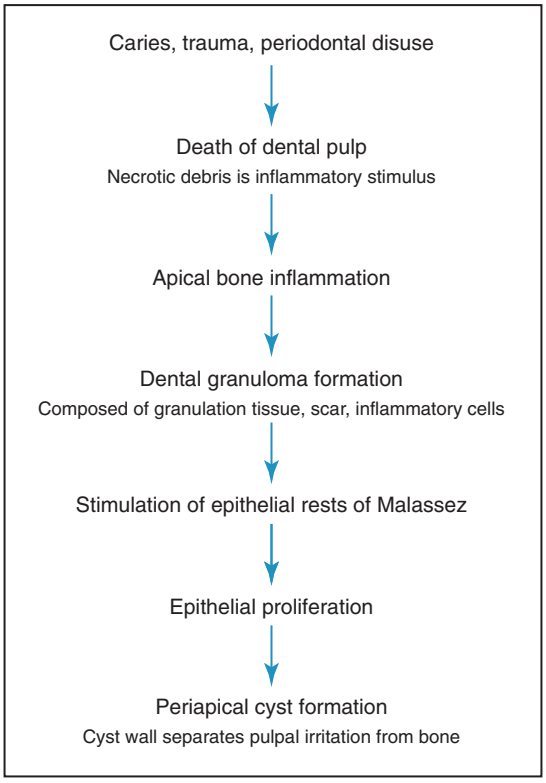

■ **FIGURE 10-3 Periapical (radicular) cyst** developmental sequence.

TABLE 10-1 CYSTS OF THE JAWS: EPITHELIAL ORIGIN

Type	Source	Origin of Rests	Cyst Examples
Odontogenic rests	Rests of Malassez Reduced enamel epithelium Rests of dental lamina (rests of Serres)	Epithelial root sheath Enamel organ Epithelial connection between mucosa and enamel organ	Periapical (radicular) cyst Dentigerous cyst Odontogenic keratocyst Lateral periodontal cyst Gingival cyst of adult Gingival cyst of newborn Glandular odontogenic cyst
Nonodontogenic rests	Remnants of nasopalatine duct	Paired nasopalatine ducts (vestigial)	Nasopalatine canal cyst



■ **FIGURE 10-4 Periapical cyst** associated with a nonvital lateral incisor.

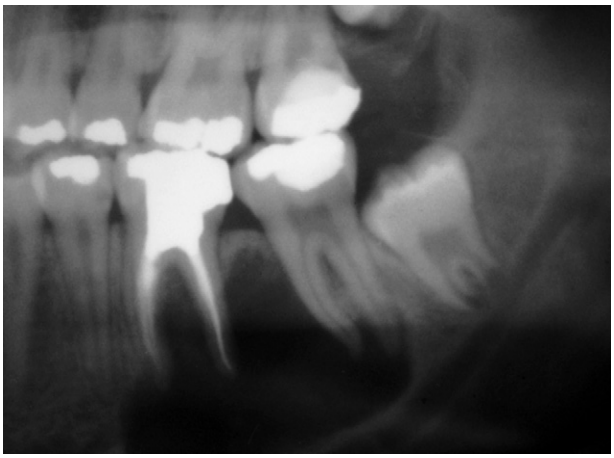

■ **FIGURE 10-5 Periapical cyst** associated with a mandibular first molar.

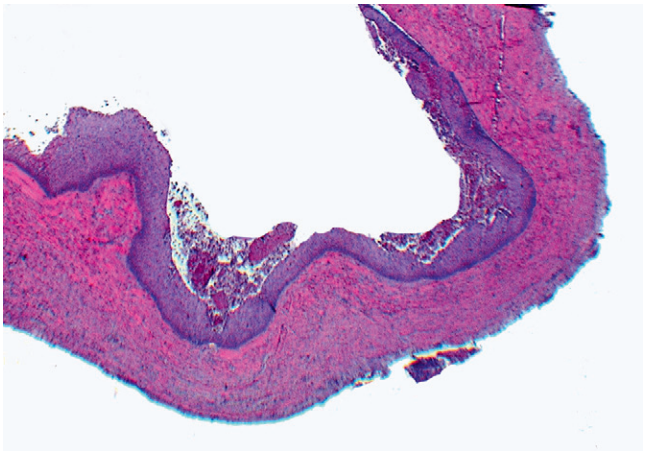

■ **FIGURE 10-6 Periapical cyst** with a chronic inflammatory cell infiltrate and nonkeratinized epithelial lining.

BOX 10-1 PERIAPICAL (RADICULAR) CYST

PATHOGENESIS

Preceded by periapical granuloma (chronic inflammation) associated with nonvital tooth
Rests of Malassez stimulated by chronic inflammation
Products of cyst epithelium and inflammation: cause bone resorption
Cyst expands because of increasing osmotic pressure in lumen.

CLINICAL FEATURES

Most common type of jaw cyst
Radiographically, cannot distinguish cyst from preexisting granuloma
Persists if treated by root canal filling only
Treated by cystectomy (apicoectomy) and retrograde root filling
Incompletely removed cyst lining results in a residual cyst.

resorption but generally do not produce bone expansion. By definition, a nonvital tooth is necessary for the diagnosis of a periapical cyst.

Radiographically, a periapical cyst cannot be differentiated from a periapical granuloma. Studies have shown that a provisional radiographic diagnosis was correct in 48% of cases for periapical granuloma and 36% for radicular cyst, with an incidence of cystic change in inflammatory periapical lesions of pulpal origin of approximately 30%. Use of more advanced radiographic techniques such as cone beam computed tomography (CBCT) has not been shown to increase the level of accuracy in distinguishing periapical granulomas from radicular cysts. The radiolucency associated with a periapical cyst is generally round to ovoid, with a narrow, opaque margin that is contiguous with the lamina dura of the involved tooth. This peripheral radiopaque component may not be apparent if the cyst is rapidly enlarging. Cysts range from a few millimeters to several centimeters in diameter, although most measure less than 1.5 cm. In long-standing cysts, root resorption of the offending tooth and occasionally of adjacent teeth may be seen.

Histopathology. The periapical cyst is lined by nonkeratinized stratified squamous epithelium of variable thickness (Figure 10-6). Transmigration of inflammatory cells through the epithelium is common, with large numbers of neutrophils (polymorphonuclear leukocytes [PMNs]) and fewer numbers of lymphocytes involved. The underlying supportive connective tissue may be focally or diffusely infiltrated

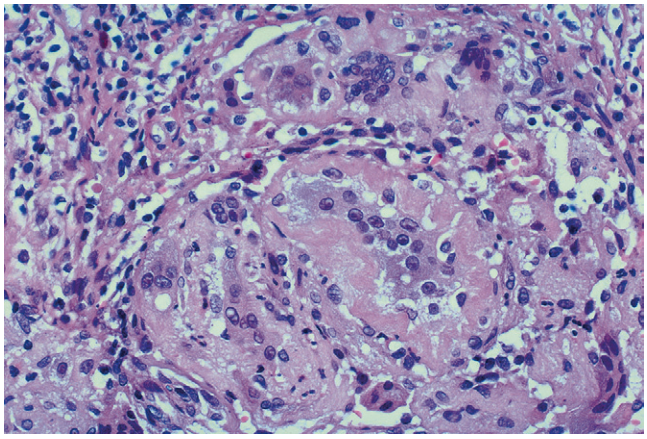

■ **FIGURE 10-7 Pulse (seed) granuloma** in the wall of a periapical cyst.



■ **FIGURE 10-8** Residual cyst.

with a mixed inflammatory cell population. The molecular signature of a periapical granuloma differs from that of the radicular cyst, with a high level of matrix metalloproteinase (MMP) activity compared with that within a radicular cyst. Plasma cell infiltrates and associated refractile and spherical intracellular *Russell bodies,* representing accumulated gamma globulin, are often found and sometimes dominate the microscopic picture. Foci of dystrophic calcification, cholesterol clefts, and multinucleated foreign body–type giant cells may be seen subsequent to hemorrhage in the cyst wall. A foreign body reaction to vegetable matter (Figure 10-7) (pulse or seed granuloma) is occasionally found in periapical cyst walls, indicating apical communication with the oral cavity through the root canal and carious lesion.

In a small percentage of periapical cysts (and dentigerous cysts), hyaline bodies, or *Rushton bodies,* may be found. Such bodies within the epithelial lining are characterized by a hairpin or slightly curved shape, concentric lamination, and occasional basophilic mineralization. Previous hemorrhage is believed to be related to the origin of these bodies, but their presence is of no clinical significance.

Differential Diagnosis. Radiographically, a differential diagnosis for periapical cyst must include periapical granuloma. In areas of previously treated apical pathology, a surgical defect or a periapical scar might also be considered. In the anterior mandible, periapical radiolucency should be distinguished from the earliest developmental phase of periapical cemento-osseous dysplasia. In the posterior quadrants, apical radiolucencies must be distinguished from a traumatic bone cyst. Occasionally, developmental odontogenic cysts, odontogenic tumors, giant cell lesions, metastatic disease, and primary osseous tumors may mimic a periapical cyst radiographically. In all of these considerations, associated teeth are vital.

Treatment and Prognosis. A periapical lesion (cyst/granuloma) may be successfully managed by extraction of the associated nonvital tooth and curettage of the apical zone. Alternatively, a root canal filling may be performed in association with an apicoectomy and direct curettage of the lesion. The third, and most often used, option involves performing a root canal filling only, because most periapical lesions are granulomas and resolve after removal of the inflammatory stimulus (necrotic pulp). Surgery (apicoectomy and curettage) is performed for lesions that are persistent, indicating the presence of a cyst or inadequate root canal treatment. The presence of endodontic filling material within a significant proportion of persistent apical radiolucencies following endodontic treatment suggests a possible causal relationship, with emphasis directed toward proper treatment to restrict extrusion of filling material beyond the periapex.

When the necrotic tooth is extracted but the cyst lining is incompletely removed, a *residual cyst* may develop months to years after the initial extirpation (Figure 10-8). If a residual cyst or the original periapical cyst remains untreated, continued growth can cause significant bone resorption and weakening of the mandible or maxilla. Complete bone repair is usually seen in adequately treated periapical and residual cysts.

Lateral Periodontal Cyst

A lateral periodontal cyst is a nonkeratinized developmental cyst occurring adjacent or lateral to the root of a tooth. *Gingival cysts of the adult* are histogenetically and pathologically similar and are also discussed here.

Etiology and Pathogenesis. The origin of this cyst is believed to be related to proliferation of rests of dental lamina. The lateral periodontal cyst has been pathogenetically linked to the gingival cyst of the adult; the former is believed to arise from dental lamina remnants within bone, and the latter from dental lamina remnants in soft tissue between the oral epithelium and the periosteum (rests of Serres). The close relationship between the two entities is further supported by their similar distribution in sites



■ **FIGURE 10-9 Lateral periodontal cyst.**



■ **FIGURE 10-10 Gingival cyst** located between canine and premolar.

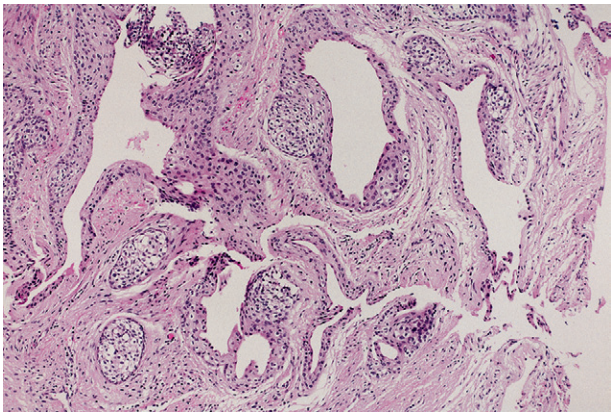

■ **FIGURE 10-11 Lateral periodontal cyst.** Note loculations lined by thick and thin epithelium.

BOX 10-2 LATERAL PERIODONTAL CYST

Origin from rests of the dental lamina in bone
Occurs along lateral surface of tooth root
Associated with a vital tooth
Most found in mandibular canine-premolar area
Males affected more than females
Treated by cystectomy; multilocular variant has recurrence potential
Dental lamina rests in soft tissue give rise to gingival cysts of adult.

containing a higher concentration of dental lamina rests, and their identical histology.

Clinical Features. Most lateral periodontal cysts and gingival cysts of the adult occur in the mandibular premolar and cuspid regions and occasionally in the incisor area (Figure 10-9; Box 10-2). In the maxilla, lesions are noted primarily in the lateral incisor region. A distinct male predilection has been noted for lateral periodontal cysts, with a greater than 2:1 distribution. Gingival cysts show a nearly equal gender predilection. The median age for both types of cysts is between the fifth and sixth decades of life, with a range of 20 to 85 years for lateral periodontal cysts, and 40 to 75 years for gingival cysts of the adult.

Clinically, a gingival cyst appears as a small soft tissue swelling within or slightly inferior to the interdental papilla (Figure 10-10). It may assume a slightly bluish discoloration when it is relatively large. Most cysts are less than 1 cm in diameter. Radiography reveals no findings.

A lateral periodontal cyst presents as an asymptomatic, well-delineated, round or teardrop-shaped unilocular (and occasionally multilocular) radiolucency with an opaque margin along the lateral surface of a vital tooth root. Root divergence is rarely seen. The term *botryoid odontogenic cyst* is sometimes used when the lesion is multilocular.

Histopathology. Both the lateral periodontal cyst (Figure 10-11) and the gingival cyst of the adult (Figure 10-12) are lined by a thin, nonkeratinized epithelium. Clusters of glycogen-rich, clear epithelial cells may be noted in nodular thickenings of the cyst lining.

Differential Diagnosis. The lateral periodontal cyst must be distinguished from a cyst resulting from an inflammatory stimulus through lateral root canal of a nonvital tooth (a lateral radicular cyst), an odontogenic keratocyst along the lateral root surface, and radiolucent odontogenic tumors. A differential diagnosis for the gingival cyst would include gingival mucocele, Fordyce's granules, parulis, and possibly a peripheral odontogenic tumor.

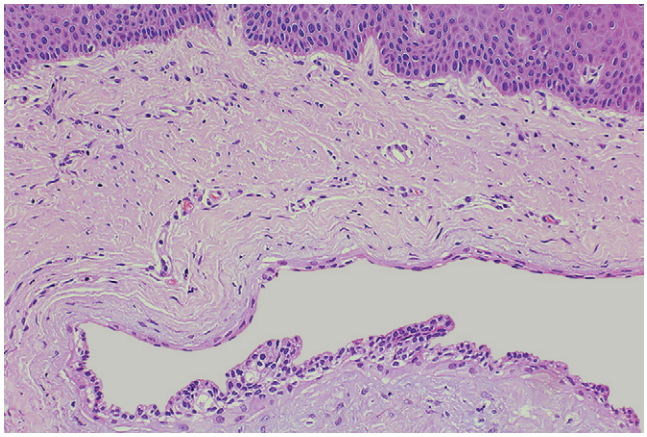

■ **FIGURE 10-12 Gingival cyst** of the adult lined by thin, nonkeratinized epithelium.

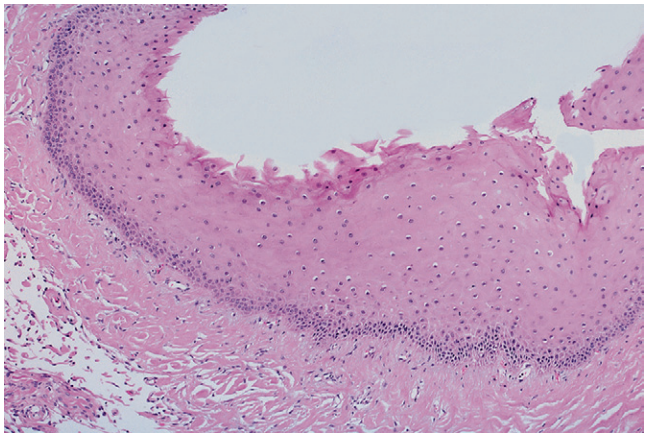

■ **FIGURE 10-13 Gingival cyst** of the newborn lined by stratified squamous epithelium.

Treatment and Prognosis. Local excision of both gingival and lateral periodontal cysts is generally curative. The multilocular variant, botryoid odontogenic cyst, seems to have increased recurrence potential. Follow-up, therefore, is suggested for treated multilocular odontogenic cysts.

Gingival Cyst of the Newborn

Gingival cysts of the newborn are also known as *dental lamina cysts of the newborn,* or *Bohn's nodules.* These cysts typically appear as multiple nodules along the alveolar ridge in neonates. It is believed that fragments of the dental lamina that remain within the alveolar ridge mucosa after tooth formation proliferate to form these small, keratinized cysts. In the vast majority of cases, these cysts are self-limiting and degenerate, and they involute or rupture into the oral cavity within a few weeks to a few months.

Histologically, this cyst is lined by a bland stratified squamous epithelium (Figure 10-13). Treatment is not necessary because nearly all involute spontaneously or rupture before the patient is 3 months of age.

BOX 10-3 DENTIGEROUS CYST

CLINICAL

Second most common odontogenic cyst after periapical cyst
Third molars and canine teeth most commonly affected
Stimulus unknown

RADIOGRAPHIC FEATURES

Lucency associated with crown of impacted tooth

HISTOPATHOLOGY

Lined by nonkeratinized stratified squamous epithelium
Proliferation of reduced enamel epithelium

POSSIBLE COMPLICATIONS

Extensive bone destruction with growth
Resorption of adjacent tooth roots
Displacement of teeth
Neoplastic transformation of lining (rare)—ameloblastoma formation; carcinoma very rarely

Similar epithelial inclusion cysts may occur along the midline of the palate *(palatine cysts of the newborn,* or *Epstein's pearls).* These cysts are of developmental origin and are derived from epithelium that is included in the fusion line between the palatal shelves and the nasal processes. No treatment is necessary because they fuse with the overlying oral epithelium, discharge their contents, and resolve spontaneously.

Dentigerous Cyst

Dentigerous or follicular cysts are the second most common type of odontogenic cyst, and the most common developmental cyst of the jaws. In children from 2 to 14 years of age, dentigerous cysts account for 49% of intraosseous cystic lesions, with eruption cysts, odontogenic keratocysts, and radicular cysts accounting for more than 10% each. By definition, a dentigerous cyst is attached to the tooth cervix at the enamel-cementum junction, and it encloses the crown of the unerupted tooth.

Etiology and Pathogenesis. A dentigerous cyst develops from proliferation of the enamel organ remnant or reduced enamel epithelium.

As with other cysts, expansion of the dentigerous cyst is related to an increase in cyst fluid osmolality and the release of bone-resorbing factors.

Clinical Features. Dentigerous cysts are most commonly seen in association with third molars and maxillary canines, which are the most commonly impacted teeth (Box 10-3; Figure 10-14). The highest incidence of dentigerous cysts occurs during the second and third decades. A greater incidence in males has been noted, with a ratio of 1.6:1 reported.

Symptoms generally are absent, and delayed eruption is the most common indication of dentigerous cyst formation. This cyst is capable of achieving significant size, occasionally with associated cortical bone expansion, but rarely does it reach a size that predisposes the patient to a pathologic fracture.



■ **FIGURE 10-14 Dentigerous cyst** surrounding the crown of an impacted molar.

Radiographically, a dentigerous cyst presents as a well-defined, unilocular radiolucency with corticated margins in association with the crown of an unerupted tooth. The unerupted tooth is often displaced (Figure 10-15). These cysts range in size from several millimeters to several centimeters, where they may compromise jawbone integrity and produce facial asymmetry. In the mandible, associated radiolucency may extend superiorly from the third molar site into the ramus or anteriorly and inferiorly along the body of the mandible. In maxillary dentigerous cysts involving the canine region, extension into the maxillary sinus or to the orbital floor may be noted. Resorption of roots of adjacent erupted teeth may occasionally be seen.

A variant of the dentigerous cyst arising at the bifurcation of molar teeth is the *paradental cyst* or *buccal bifurcation cyst* (Figure 10-16). Originally, this cyst was described along the buccal root surface of partially erupted mandibular third molar teeth, but later, involvement of other mandibular molar teeth was recognized. Often in these latter circumstances, the molar teeth are fully erupted. Radiographically, paradental cysts are characterized as well-circumscribed radiolucencies in the buccal bifurcation region. Often buccal

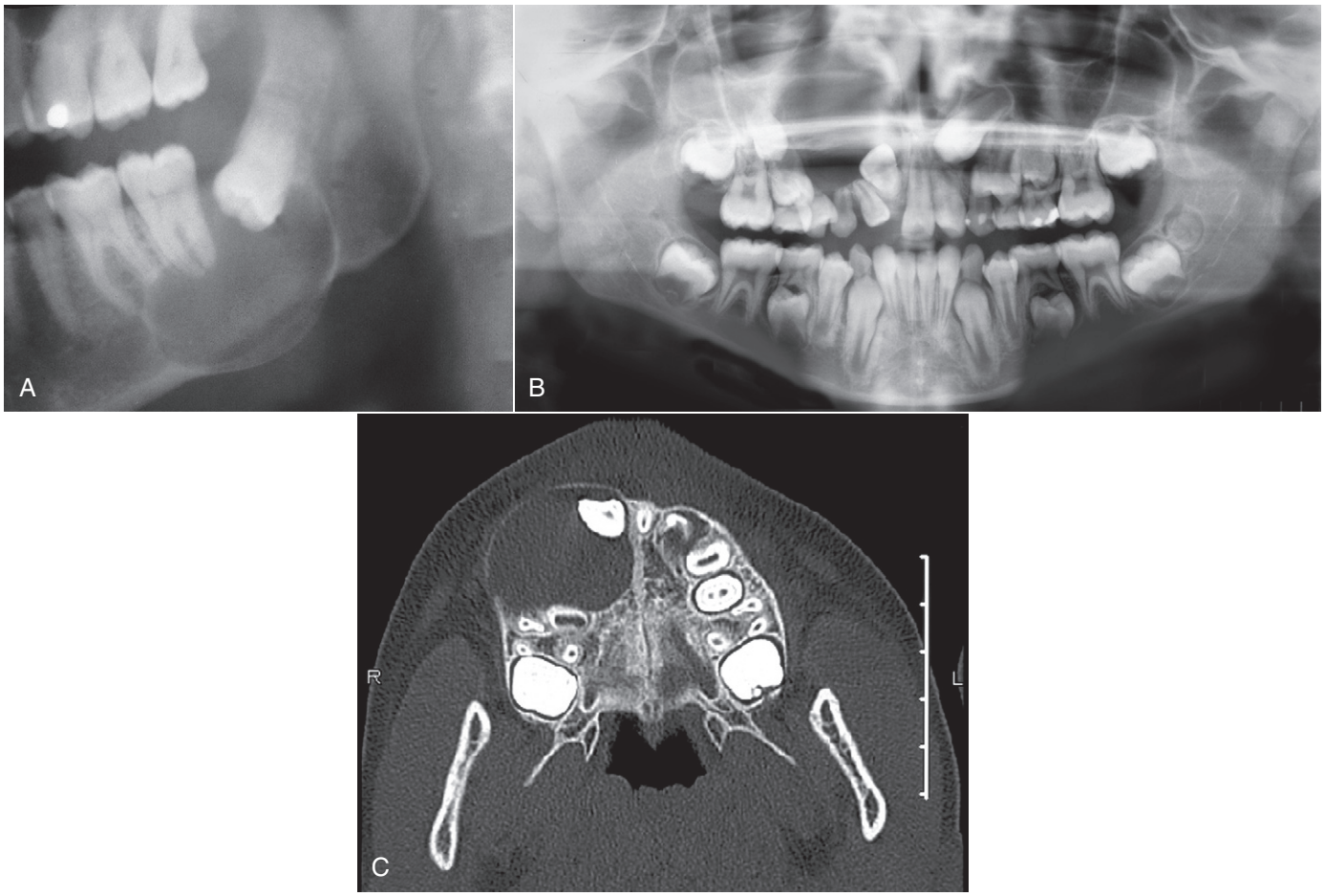

■ **FIGURE 10-15 A, Dentigerous cyst** exhibiting cortical expansion. **B,** A large dentigerous cyst of the right maxilla. **C,** An axial computed tomography (CT) scan of an expansile maxillary dentigerous cyst and associated impacted tooth.



■ **FIGURE 10-16 Paradental cyst** associated with a mandibular molar, gross specimen.

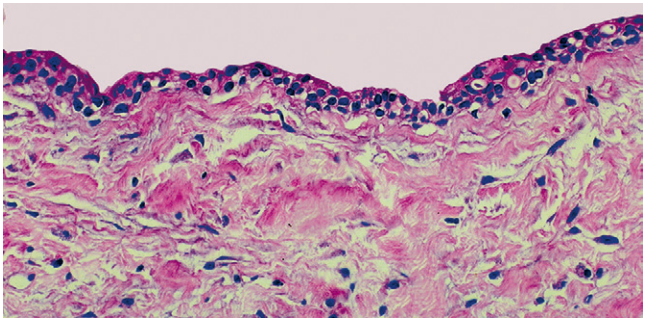

■ **FIGURE 10-17 Dentigerous cyst** lined by thin, nonkeratinized epithelium.

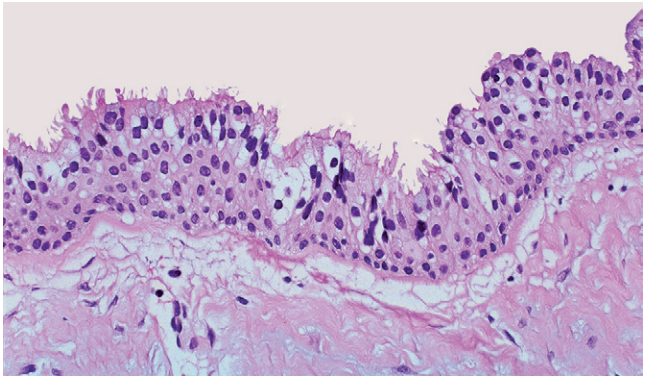

■ **FIGURE 10-18 Dentigerous cyst** lined by ciliated stratified squamous epithelium.

tipping of the crown can be demonstrated by occlusal radiography.

Histopathology. Microscopically, the dentigerous cyst is formed by a fibrous connective tissue wall and is lined by stratified squamous epithelium (Figures 10-17 to 10-19). In an uninflamed dentigerous cyst, the epithelial lining is nonkeratinized and tends to be approximately four to six cell layers thick. On occasion, numerous mucous cells, ciliated cells, and, rarely, sebaceous cells may be found in the lining

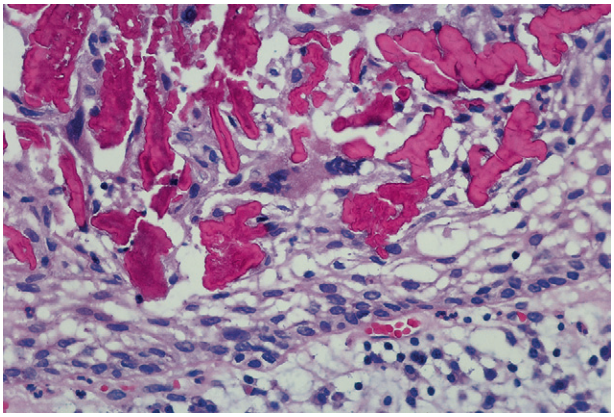

■ **FIGURE 10-19 Dentigerous cyst,** epithelial lining containing Rushton bodies; an incidental finding of no significance.

of the epithelium. The epithelium–connective tissue junction is generally flat, although in cases of secondary inflammation, epithelial hyperplasia may be noted.

Differential Diagnosis. A differential diagnosis of pericoronal radiolucency should include odontogenic keratocyst, ameloblastoma, and other odontogenic tumors. Ameloblastic transformation of a dentigerous cyst lining should be part of the differential diagnosis. Adenomatoid odontogenic tumor would be a further consideration with anterior pericoronal radiolucencies, and ameloblastic fibroma would be a possibility for lesions occurring in the posterior jaws of young patients.

Treatment. Removal of the associated tooth and enucleation of the pericoronal soft tissue component constitute definitive therapy in most instances. In cases in which cysts affect significant portions of the mandible, an acceptable early treatment approach involves exteriorization or marsupialization of the cyst to allow for decompression and subsequent shrinkage of the lesion, thereby reducing the extent of surgery to be done at a later date.

Potential complications of untreated dentigerous cysts include transformation of the epithelial lining into an ameloblastoma and, rarely, carcinomatous transformation of the epithelial lining. It has been suggested that the presence of mucous cells may indicate the potential for development of the rare intraosseous mucoepidermoid carcinoma. This is speculative because the evidence is anecdotal; the presence of mucous cells may indicate mucus metaplasia or a glandular odontogenic cyst.

Eruption Cyst

An eruption cyst results from fluid accumulation within the follicular space of an erupting tooth (Figure 10-20). The epithelium lining this space is simply reduced enamel epithelium. With trauma, blood may appear within the tissue space, forming an *eruption hematoma.* No treatment is

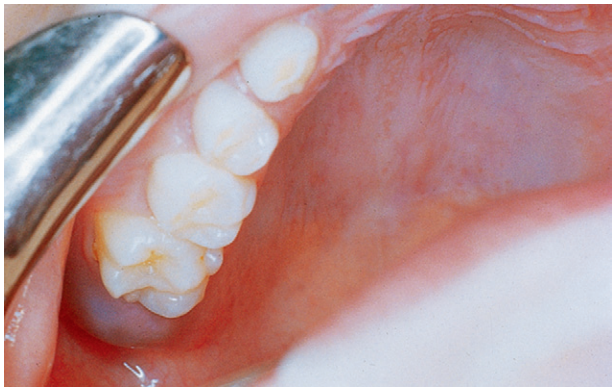

■ **FIGURE 10-20 Eruption cyst** overlying an erupting maxillary molar.

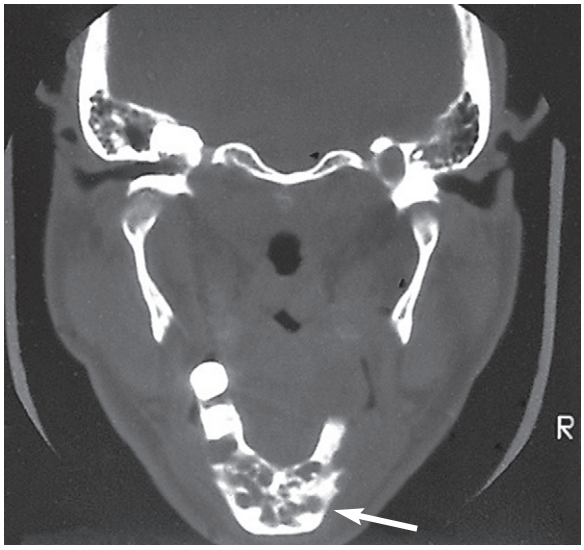

■ **FIGURE 10-21** Glandular odontogenic cyst.

needed because the tooth erupts through the lesion. Subsequent to eruption, the cyst disappears spontaneously without complication.

Glandular Odontogenic Cyst

The rare glandular odontogenic cyst, or *sialo-odontogenic cyst,* was first described in 1987 and has some histologic features that suggest a mucus-producing salivary gland tumor (low-grade mucoepidermoid carcinoma).

Clinical Features. A strong predilection is seen for the mandible (80%), especially the anterior mandible (Box 10-4; Figure 10-21). Maxillary lesions tend to be localized to the anterior segment. A slow growth rate is characteristic and symptoms are absent. Jaw expansion is not uncommon, particularly in association with mandibular lesions. The gender ratio is approximately 1:1. The mean age is 50 years, with a wide age range from the second through ninth decades.

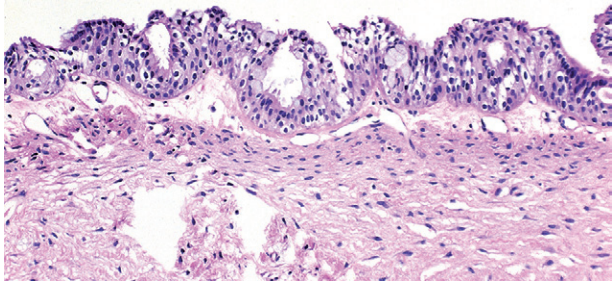

■ **FIGURE 10-22 Glandular odontogenic cyst** lined by epithelium showing ductlike features and mucous cells.

BOX 10-4 GLANDULAR ODONTOGENIC CYST (SIALO-ODONTOGENIC CYST)

Rare developmental cyst

CLINICAL FEATURES
Adults
Either jaw (anterior > posterior)

HISTOPATHOLOGY
Focal mucous cells, pseudoducts
Resembles low-grade mucoepidermoid carcinoma

BEHAVIOR
Locally aggressive; recurrence potential

>, More frequently affected than.

Radiographic Features. Most cases are radiographically multiloculated. In cases in which a unilocular radiolucency has been noted initially, recurrent lesions have tended to be multiloculated. Lesions that have been reported have exhibited a wide variation in size, from smaller than 1 cm to involving most of the mandible bilaterally. Radiographic margins are well defined and sclerotic and scalloped. Teeth may be displaced, and root resorption is noted in some cases. More aggressive lesions have shown an ill-defined peripheral border.

Histopathology. Histologically, this multilocular cyst is lined by nonkeratinized epithelium with focal thickenings in which the epithelial cells assume a swirled appearance. The epithelial lining consists of cuboidal cells, often with cilia at the luminal surface. Mucous cells are clustered in the cyst lining along with mucin pools. The overall histomorphology is reminiscent of a cystic low-grade mucoepidermoid carcinoma (Figures 10-22 and 10-23).

Treatment and Prognosis. This lesion can be considered locally aggressive; therefore, surgical management should be dictated by the clinical and radiographic extent of the disease. Where adequate healthy bone remains beyond the extent of the cystic lesion, peripheral curettage or marginal excision is

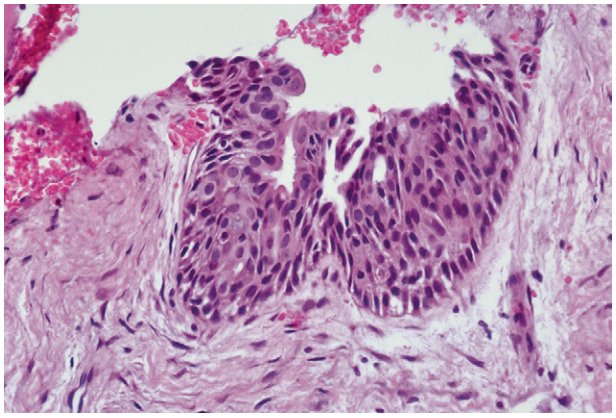

■ **FIGURE 10-23 Glandular odontogenic cyst** lined by epithelium showing a few ductlike changes.

appropriate. Long-term follow-up is essential given the local aggressiveness and recurrence rate (approximately 25%) of this lesion.

Odontogenic Keratocyst/Keratocystic Odontogenic Tumor

Odontogenic keratocysts (OKCs) or keratocystic odontogenic tumors (KCOTs) may exhibit aggressive clinical behavior, a significant recurrence rate, and an association with *nevoid basal cell carcinoma syndrome (NBCCS).* They are found anywhere in the jaws and can radiographically mimic other types of cysts. Microscopically, however, they have a consistent and unique appearance.

Etiology and Pathogenesis. It is generally agreed that OKCs/KCOTs develop from dental lamina remnants in the mandible and maxilla. However, origin of this cyst from extension of basal cells of the overlying oral epithelium has also been suggested. Factors that may contribute to the pathogenesis of the OKC/KCOT include a high proliferation rate, overexpression of the antiapoptotic protein *Bcl-2* and several growth factors, and expression of MMPs 2 and 9 (Box 10-5). Studies on NBCCS and sporadic OKCs/KCOTs have provided evidence of a two-hit genetic mechanism at two or more chromosome loci on chromosome 9q22.3, leading to overexpression of several proteins, including cyclin D1 and p53. Central to the development of OKCs/KCOTs are mutations of the *PTCH* gene mapped to chromosome 9p22.3-q31. The defective gene associated with NBCCS was found to be homologous to the *Drosophila* (fruit fly) patched *(PTCH)* gene. The protein product of the *PTCH* gene (a tumor-suppressor gene) is a component of the hedgehog-signaling pathway and is essential for development during embryogenesis and cell signaling in the adult. The *PTCH* gene product normally represses the activity of the so-called sonic hedgehog protein and other signaling proteins, such as smoothened (SMO) protein. If the *PTCH* gene is nonfunctional, overexpression of sonic hedgehog and/or smoothened proteins occurs, leading to increased cell proliferation. Mutations of the *PTCH* gene are involved in the development of human syndromic basal cell carcinoma and are present in a proportion of sporadic basal cell carcinomas (as well as medulloblastomas), providing further evidence of the crucial role of *PTCH* as a tumor suppressor in human keratinocytes. *PTCH* mutations are also found in OKCs/KCOTs in NBCCS patients and probably in many OKCs/KCOTs that occur sporadically. Thus, the currently proposed change in terminology from OKC to KCOT reflects the concept that these are cystic tumors and not developmental cysts.

BOX 10-5 ODONTOGENIC KERATOCYST/ KERTAOCYSTIC ODONTOGENIC TUMOR: PATHOGENETIC MECHANISMS

- High proliferation rate—Ki-67 staining
- Overexpression of antiapoptotic protein—*Bcl-2* staining
- Overexpression of interface protein—MMPs 2 and 9, TGF, IL-1α, and IL-6
- Mutations in *PTCH* tumor suppressor gene (protein receptor in hedgehog signaling pathway)
- Found in basal cell carcinomas and medulloblastomas of nevoid basal cell carcinoma syndrome
- *PTCH* mutations noted in syndromic and nonsyndromic odontogenic keratocysts/keratocystic odontogenic tumors

IL, Interleukin; *MMP,* matrix metalloproteinase; *TGF,* transforming growth factor.

BOX 10-6 ODONTOGENIC KERATOCYST: CLINICAL FEATURES

- Aggressive; recurrence risk; association with nevoid basal cell carcinoma syndrome
- Solitary cysts—common (5% to 15% of odontogenic cysts); recurrence rate 10% to 30%
- Multiple cysts—5% of OKC patients; recurrence greater than with solitary cysts
- Syndrome-associated, multiple cysts—5% of OKC patients; recurrence greater than with multiple cysts

OKC, Odontogenic keratocyst.

Clinical Features. OKCs/KCOTs are relatively common jaw cysts (Box 10-6; Figures 10-24 and 10-25). They occur at any age and have a peak incidence within the second and third decades. Lesions found in children are often reflective of multiple cysts as a component of NBCCS. OKCs/KCOTs represent 5% to 15% of all odontogenic cysts. Approximately 5% of patients with OKCs/KCOTs have multiple cysts (Figure 10-26), and another 5% have NBCCS.



■ **FIGURE 10-24 Odontogenic keratocyst.**



■ **FIGURE 10-25 Odontogenic keratocyst** in a lateral root position.

OKCs /KCOTs are found in the mandible in approximately a 2:1 ratio. In the mandible, the posterior portion of the body and the ramus region are most commonly affected, and in the maxilla, the third molar area is most commonly affected.

Radiographically, an OKC/KCOT characteristically presents as a well-circumscribed radiolucency with smooth radiopaque margins (Figures 10-27 and 10-28). Multilocularity is often present and tends to be seen more commonly in larger lesions. Most lesions, however, are unilocular, with as many as 40% noted adjacent to the crown of an unerupted tooth (dentigerous cyst presentation). Approximately 30% of maxillary and 50% of mandibular lesions produce buccal expansion. Mandibular lingual enlargement is occasionally seen.

Histopathology. The epithelial lining is uniformly thin, generally ranging from 6 to 10 cell layers thick. The basal layer exhibits a characteristic palisaded pattern with



■ **FIGURE 10-26 Multiple odontogenic keratocysts** in a patient with nevoid basal cell carcinoma syndrome.



■ **FIGURE 10-27 Odontogenic keratocyst** of the mandible.

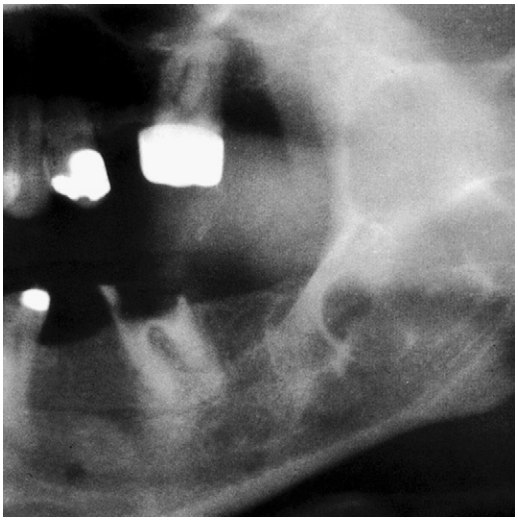

■ **FIGURE 10-28** Multiloculated **odontogenic keratocyst** of the mandibular ramus.

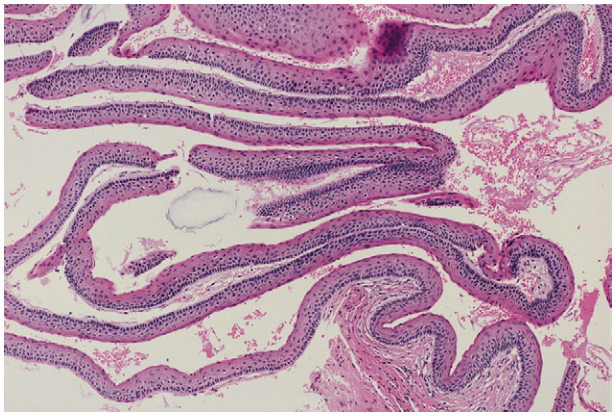

■ **FIGURE 10-29 Odontogenic keratocyst** epithelium exhibiting characteristic loss of adhesion to underlying connective tissue.

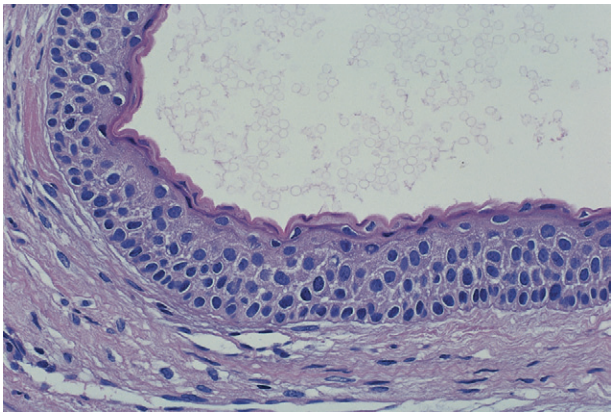

■ **FIGURE 10-30 Odontogenic keratocyst** showing characteristic parakeratinized lining with basal cell polarization.

BOX 10-7 ODONTOGENIC KERATOCYST: DIAGNOSIS

Thin epithelium (6 to 10 cell layers)
Refractile, *parakeratotic* lining
Epithelial budding and "daughter cysts"
Characteristic microscopic features lost when inflamed
Orthokeratinized odontogenic cyst
- Lined by thin orthokeratinized epithelium
- Less common
- Not syndrome associated
- Lower recurrence rate

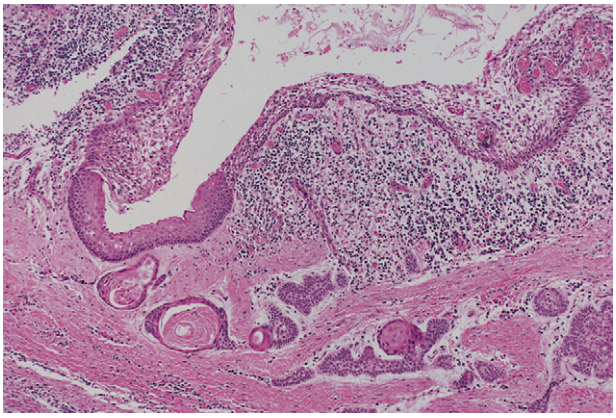

■ **FIGURE 10-31 Odontogenic keratocyst** showing loss of characteristic features in areas of inflammation, as well as mural daughter cysts/rests.

polarized and intensely stained nuclei of uniform diameter. The luminal epithelial cells are parakeratinized and produce an uneven or corrugated profile. Focal zones of orthokeratin are occasionally seen. Additional histologic features that may occasionally be encountered include budding of the basal cells into the connective tissue wall and microcyst formation. The fibrous connective tissue component of the cyst wall is often free of an inflammatory cell infiltrate and is relatively thin. The epithelium–connective tissue interface is characteristically flat with no epithelial ridge formation. All so-called primordial cysts (cyst in place of a tooth), when examined microscopically, are OKCs/KCOTs (Box 10-7; Figures 10-29 to 10-33).

An *orthokeratinized odontogenic cyst* has been described and is about one twentieth as common as the OKC/KCOT (Figure 10-34). Histologic distinction between parakeratinized and orthokeratinized cysts is made because the latter type of cyst is less clinically aggressive, has a lower rate of recurrence, and generally is not syndrome associated. In the orthokeratotic odontogenic cyst, a prominent granular layer is found immediately below a flat, noncorrugated surface. The basal cell layer is less prominent and has a more flattened or squamoid appearance in comparison with the parakeratotic type.

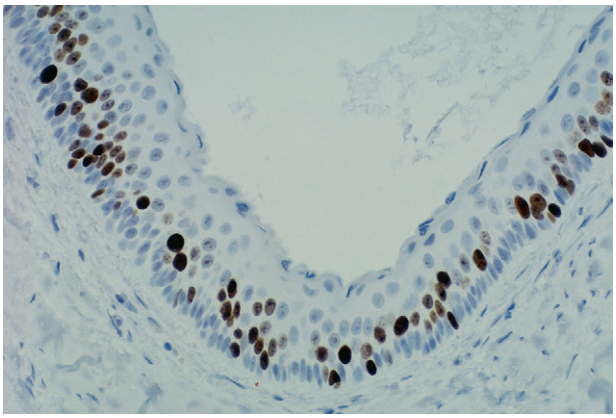

■ **FIGURE 10-32 Odontogenic keratocyst.** Note numerous positive staining nuclei *(brown)* in immunohistochemical stain for proliferation protein Ki-67.

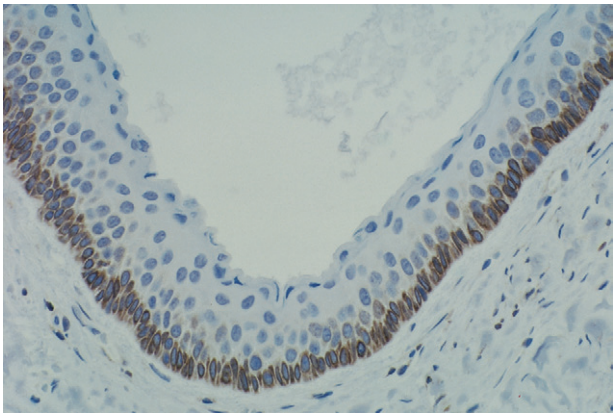

■ **FIGURE 10-33 Odontogenic keratocyst.** Note numerous positive staining cells *(brown)* in immunohistochemical stain for antiapoptosis protein *Bcl-2*.

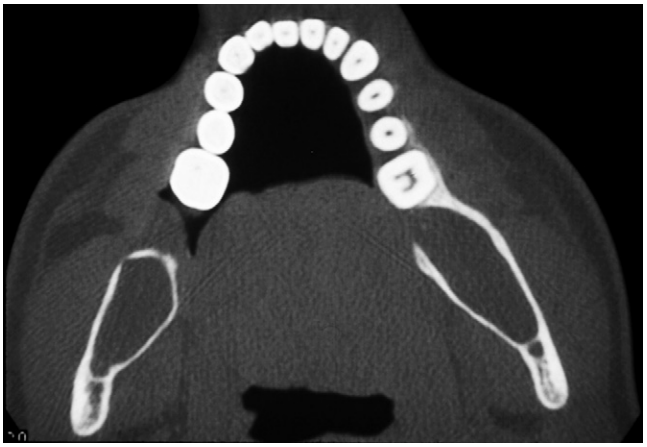

■ **FIGURE 10-35** Computed tomography (CT) scan of multiple **odontogenic keratocysts** in a patient with nevoid basal cell carcinoma syndrome.

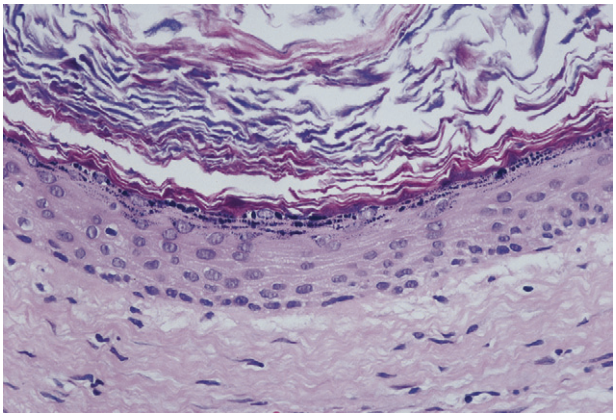

■ **FIGURE 10-34 Orthokeratinized odontogenic cyst.** Note granular layer subjacent to keratin and lack of basal cell organization.

BOX 10-8 NEVOID BASAL CELL CARCINOMA SYNDROME

ETIOLOGY

Autosomal-dominant inheritance pattern

Mutations found in the *PTCH* gene (hedgehog signaling)

CLINICAL FEATURES

Multiple odontogenic keratocysts/keratocystic odontogenic tumors

Multiple basal cell carcinomas

Skeletal anomalies (e.g., bifid rib, kyphoscoliosis)

Calcified falx cerebri

Facial defects

Differential Diagnosis. When cysts are associated with teeth, several entities might be considered, such as dentigerous cyst, ameloblastoma, odontogenic myxoma, adenomatoid odontogenic tumor, and ameloblastic fibroma. Radiolucent, nonodontogenic tumors, such as central giant cell granuloma, traumatic bone cyst, and aneurysmal bone cyst, might be included in a differential diagnosis of this entity in young patients.

Treatment and Prognosis. Surgical excision with peripheral osseous curettage or ostectomy is the preferred method of management. This more aggressive approach for a cystic lesion is justified by the high recurrence rate associated with OKCs/KCOTs. Some have advocated marsupialization to permit cyst shrinkage, followed by enucleation as an alternative.

The recurrence rate of 10% to 30% appears to be associated with several physical factors. The friable, thin connective tissue wall of the cyst may lead to incomplete removal. Small dental lamina remnants or satellite cysts in the bone adjacent to the primary lesion may contribute to recurrence. Also, cystic proliferation of the overlying oral epithelial basal cell layer, if not eliminated during cyst removal, is considered significant by some. Actual biological qualities of the cyst epithelium, such as an increased mitotic index and production of bone-resorbing factors, may be associated with recurrence.

Follow-up examinations are important for patients with this lesion. Patients should be evaluated for completeness of excision, new keratocysts, and NBCCS. Most recurrences become clinically evident within 5 years of treatment. Aside from the recurrence potential, ameloblastic transformation is a rare complication. Patients with multiple keratocysts have a significantly higher rate of recurrence than those with single keratocysts (30% and 10%, respectively).

Clinical manifestations of NBCCS include multiple OKCs/KCOTs, bone defects, and multiple basal cell carcinomas (Figure 10-35; Box-10-8). The other cutaneous abnormalities include palmar and plantar keratotic pitting, multiple milia, and dermal calcinosis. Common bone defects include

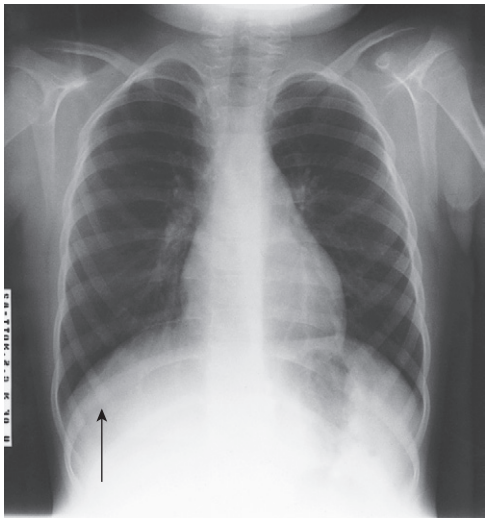

■ **FIGURE 10-36 Nevoid basal cell carcinoma** syndrome patient. Note bifid rib *(arrow)*.

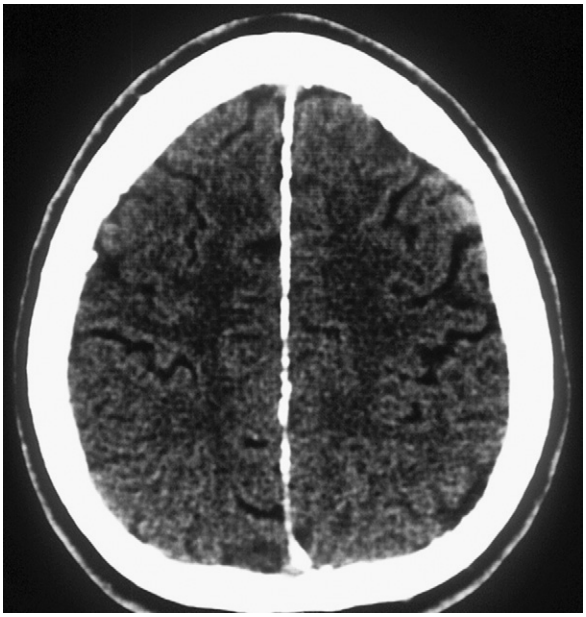

■ **FIGURE 10-37** Computed tomography (CT) scan of calcified falx cerebri in a patient with **nevoid basal cell carcinoma syndrome.**

bifid ribs (Figure 10-36), kyphoscoliosis, and vertebral and metacarpal abnormalities. Mild mandibular prognathism has been recorded in a small percentage of cases. Facial dysmorphogenesis, including a broad nasal bridge with corresponding ocular hypertelorism and laterally displaced inner ocular canthi (dystopia canthorum), may be seen. Neurologic abnormalities—including medulloblastoma, dysgenesis or agenesis of the corpus callosum, calcification of the falx cerebri (Figure 10-37), and (less often) calcification of the falx cerebelli—have been documented.

BOX 10-9 CALCIFYING ODONTOGENIC CYST

CLINICAL FEATURES
No distinctive age, gender, or location
Lucent to mixed radiographic patterns

HISTOPATHOLOGY
Basal palisading
Ghost cells and dystrophic calcification
Similar to pilomatrixoma of skin

BEHAVIOR
Unpredictable

VARIANTS
Odontogenic ghost cell tumor—solid
Odontogenic ghost cell carcinoma—cytologic atypia

Calcifying Odontogenic Cyst

Calcifying odontogenic cysts (COCs) are developmental odontogenic lesions that occasionally exhibit recurrence (Box 10-9). A solid variant known as *odontogenic ghost cell tumor* is believed to potentially exhibit more aggressive clinical behavior.

Etiology and Pathogenesis. COCs are believed to be derived from odontogenic epithelial remnants within the gingiva or within the mandible or maxilla. *Ghost cell keratinization,* the characteristic microscopic feature of this cyst, is also a defining feature of the cutaneous lesion known as *calcifying epithelioma of Malherbe,* or *pilomatrixoma.* In the jaws, ghost cells may be seen in other odontogenic tumors, including odontomas, ameloblastomas, adenomatoid odontogenic tumors, ameloblastic fibro-odontomas, and ameloblastic fibromas. Mutations of genes in the WNT signaling pathway, including the beta-catenin gene, have been reported in COCs.

Clinical Features. A wide age range has been reported for this cyst, with a peak incidence in the second decade. It usually appears in individuals younger than 40 years of age and has a decided predilection for females. More than 70% of COCs are seen in the maxilla. Rarely, COCs may present as localized extraosseous masses involving the gingiva. Those presenting in an extraosseous or peripheral location are usually noted in individuals older than 50 years of age and are found anterior to the first molar region.

Radiographically, COCs may present as unilocular or multilocular radiolucencies with discrete, well-demarcated margins (Figures 10-38 and 10-39). Within the radiolucency may be scattered, irregularly sized calcifications. Such opacities may produce a salt-and-pepper type of pattern, with an equal and diffuse distribution. In some cases, mineralization

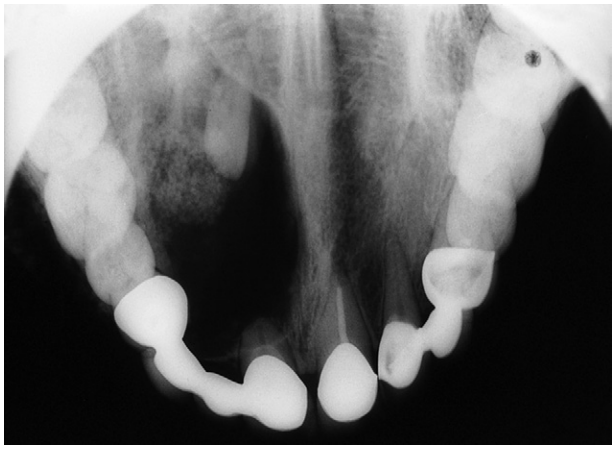

■ **FIGURE 10-38 Calcifying odontogenic cyst** of the maxilla seen in association with an impacted tooth.



■ **FIGURE 10-39 Calcifying odontogenic cyst.**

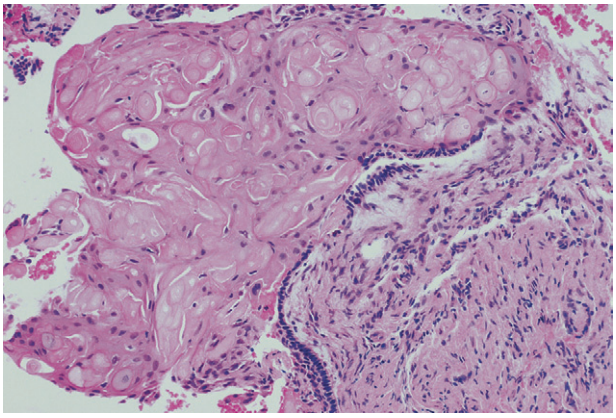

■ **FIGURE 10-40 Calcifying odontogenic cyst** showing keratinized epithelial cells (ghost cells) filling the lumen *(left)*.

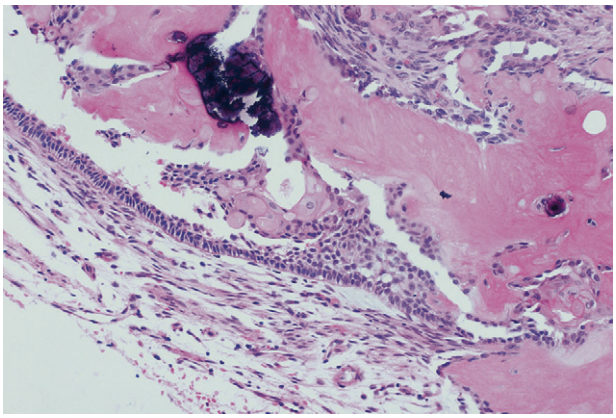

■ **FIGURE 10-41 Calcifying odontogenic cyst** showing calcification of ghost cells *(upper left)*.

may develop to such an extent that the radiographic margins of the lesion are difficult to determine.

Histopathology. Most COCs present as well-delineated cystic proliferations with a fibrous connective tissue wall lined by odontogenic epithelium. Intraluminal epithelial proliferation occasionally obscures the cyst lumen, thereby producing the impression of a solid tumor. The epithelial lining is of variable thickness. The basal epithelium may be prominent focally, with hyperchromatic nuclei and a cuboidal to columnar pattern. Above the basal layer are more loosely arranged epithelial cells, sometimes resembling the stellate reticulum of the enamel organ. The most prominent and unique microscopic feature is the presence of so-called ghost cell keratinization. Ghost cells are anucleate and retain the outline of the cell membrane. These cells undergo dystrophic mineralization characterized by fine basophilic granularity, which may eventually result in large sheets of calcified material (Figures 10-40 and 10-41). On occasion, ghost cells may become displaced in the connective tissue wall, eliciting a foreign body giant cell response.

Differential Diagnosis. In the early stages of formation, COCs may have little or no mineralization and therefore may present as radiolucencies. The differential diagnosis in these instances includes dentigerous cyst, OKC/KCOT, and ameloblastoma. In later stages, when a mixed radiolucent-radiopaque appearance is present, a differential diagnosis would include adenomatoid odontogenic tumor, a partially mineralized odontoma, calcifying epithelial odontogenic tumor, and ameloblastic fibro-odontoma.

Treatment and Prognosis. Because of the unpredictable biological behavior of this lesion, treatment is usually more aggressive than simple curettage. Patients should be monitored following treatment because recurrences are

not uncommon. Management of the extraosseous or peripheral variant is conservative because recurrence is not characteristic.

NONODONTOGENIC CYSTS

Globulomaxillary Cyst/Lesion

Globulomaxillary cysts were once considered fissural cysts, located between the globular and maxillary processes. The former theory of origin involved epithelial entrapment within a line of embryologic closure with subsequent cystic change. Embryologic evidence now shows that the premaxilla and the maxillary processes do not fuse in this manner; thus there can be no fusion-related mechanism to account for a distinct globulomaxillary cyst in this location. Radiolucencies in this location, when reviewed microscopically, have been shown to represent radicular cysts, periapical granulomas, lateral periodontal cysts, OKCs, central giant cell granulomas, calcifying odontogenic cysts, and odontogenic myxomas. Thus, today the term *globulomaxillary* can be justified only in an anatomic sense, with definitive diagnosis of lesions located in this area made by combined clinical and microscopic examination (Box 10-10).

Radiologically, a globulomaxillary lesion appears as a well-defined radiolucency, often producing divergence of the roots of the maxillary lateral incisor and canine teeth. Radicular cyst and periapical granuloma can be ruled out with pulp vitality testing.

Because of the array of potential diagnoses, the histology varies considerably from case to case. Specific histologic features of the entities included in the differential diagnosis are found in the discussions of those entities.

Treatment and prognosis are determined by the definitive microscopic diagnosis.

Nasolabial Cyst

Nasolabial cysts are soft tissue cysts of the upper lip. The pathogenesis of the nasolabial cyst is unclear, although it has been suggested that this lesion represents cystic change in the solid cord remnants of cells that form the nasolacrimal duct.

BOX 10-10 GLOBULOMAXILLARY LESIONS

- Nonspecific designation for any lesion in the globulomaxillary area (between maxillary lateral incisor and canine)
- Inverted pear-shaped radiolucency
- Asymptomatic; teeth vital; divergence of roots
- May represent odontogenic cyst or neoplasm, or nonodontogenic tumor
- Biopsy necessary to establish definitive diagnosis

The nasolabial cyst is a rare lesion with a peak incidence noted in the fourth and fifth decades. A distinct female predilection of nearly 4:1 has been noted. The chief clinical sign is a soft tissue swelling that may present in the soft tissue over the canine region or the mucobuccal fold.

The epithelial lining of this cyst is characteristically a pseudostratified columnar type with numerous goblet cells. Stratified squamous epithelium may be present in addition to cuboidal epithelium in some cases. The cyst is treated by curettage with few recurrences expected.

Median Mandibular Cyst

Median mandibular cysts, similar to globulomaxillary cysts, were once considered fissural cysts. Justification for a fissural origin was based on the no-longer-tenable theory of epithelial entrapment in the midline of the mandible during "fusion" of each half of the mandibular arch. Embryologic evidence suggests an isthmus of mesenchyme between the mandibular processes that is gradually eliminated as growth continues, and therefore no evidence of epithelial fusion. Cases diagnosed clinically as median mandibular cysts represent a microscopic spectrum of odontogenic cysts and tumors.

Nasopalatine Canal Cyst

Nasopalatine canal cysts, also known as *incisive canal cysts,* are located within the nasopalatine canal or within the palatal soft tissues at the point of opening of the canal, where the lesions are called *cysts of the palatine papilla.* The so-called *median palatine cyst* is believed to represent a more posterior presentation of a nasopalatine canal cyst, rather than cystic degeneration of epithelial rests in the line of fusion of the palatine shelves.

Etiology and Pathogenesis. A nasopalatine canal cyst develops from the proliferation of epithelial remnants of paired embryonic nasopalatine ducts within the incisive canal. The canal itself is formed as a result of fusion of the premaxilla with the right and left palatal processes. The anatomic exit of the canal is slightly posterior to the incisive papilla.

The stimulus for cyst formation from the epithelial remnants of the nasopalatine canals is uncertain, although bacterial infection and/or trauma is thought to have a role. Alternatively, it has been suggested that mucous glands within the lining may cause cyst formation as a result of mucin secretion.

Clinical Features. This relatively common cyst may present as a symmetric swelling in the anterior region of the palatal midline or as a midline radiolucency (Figures 10-42 and 10-43; Box 10-11). Most cases occur between the fourth and sixth decades of life. Men are affected more often than women, with differences as great as 3:1.



■ **FIGURE 10-42 Nasopalatine canal cyst** in the midline of the maxilla.

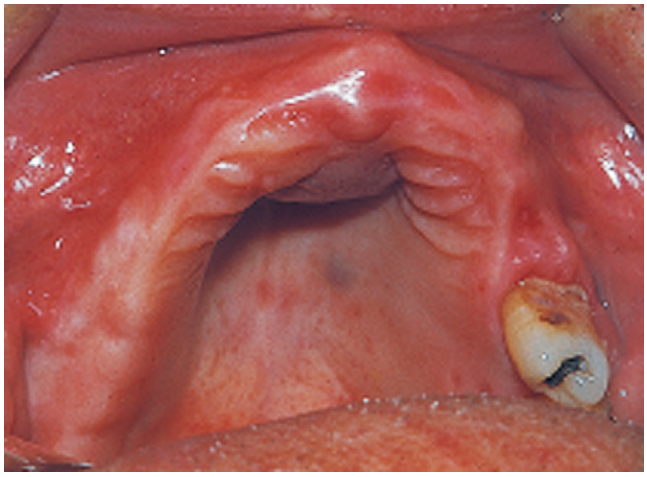

■ **FIGURE 10-43** Oral expression of a **nasopalatine canal cyst.** (Reproduced with permission from Regezi JA, Sciubba JJ, Pogrel MA: Atlas of Oral and Maxillofacial Pathology. Philadelphia, Pa: WB Saunders, 2000: Figure 6-50.)

BOX 10-11 NASOPALATINE CANAL (DUCT) CYST

Most common nonodontogenic oral cyst
Arises from remnants of the vestigial paired palatine ducts
Stimulus for cyst development undetermined
Most occur in bone, soft tissue lesion in incisive papilla
Asymptomatic unless secondarily inflamed
Adults, males more commonly affected

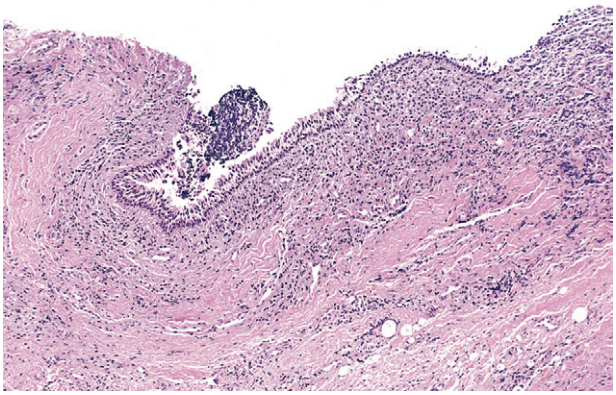

■ **FIGURE 10-44 Nasopalatine canal cyst** exhibiting respiratory-type epithelium and mural inflammation.

Most cases are asymptomatic, with the clinical sign of swelling usually calling attention to the lesion. Symptoms may follow secondary infection. Sinus formation and drainage occur occasionally at the most prominent portion of the palatine papilla.

Radiographically, a nasopalatine canal cyst is purely radiolucent, with sharply defined margins. The lesion may produce divergence of the roots of the maxillary incisor teeth and, less commonly, may induce external root resorption. The anterior nasal spine often is centrally superimposed on the lucent defect, producing a heart shape. The radiolucency may occasionally be unilateral, with the midline forming the most medial aspect of the radiolucency.

Histopathology. The epithelial lining of this cyst ranges from stratified squamous to pseudostratified columnar (when located near the nasal cavity). In many instances, a mixture of two or more types of lining cells is seen. The connective tissue wall contains small arteries and nerves, representing the nasopalatine neurovascular bundle (Figure 10-44).

Differential Diagnosis. The entities periapical granuloma and periapical (radicular) cyst must be separated from the nasopalatine canal cyst. This can be done simply by determining tooth vitality. A normal but widened canal might also be considered.

Treatment and Prognosis. This cyst requires surgical enucleation. In cases of large cysts, marsupialization may be considered before definitive enucleation. The recurrence rate is very low.

PSEUDOCYSTS

Aneurysmal Bone Cyst

Aneurysmal bone cysts are pseudocysts because they appear radiographically as cystlike lesions but microscopically exhibit no epithelial lining (Box 10-12). This lesion

BOX 10-12 ANEURYSMAL BONE CYST

ETIOLOGY
Unknown; may be related to altered hemodynamics or abnormal healing of bone hemorrhage

CLINICAL FEATURES
Teenagers and young adults affected
Multilocular lucency
No associated thrill or bruit on auscultation

HISTOPATHOLOGY
Blood-filled spaces lined by connective tissue and multinucleated giant cells
Differential diagnosis includes central giant cell granuloma, hyperparathyroidism, cherubism.

TREATMENT
Excision: no bleeding hazard

represents a benign lesion of bone that may arise in the mandible, the maxilla, or other bones. Within the craniofacial complex, approximately 40% of lesions are located in the mandible and 25% are located in the maxilla.

Etiology and Pathogenesis. The pathogenesis of the aneurysmal bone cyst is not well understood. Some evidence suggests a reactive process, and other evidence suggests a tumor. Supporting the tumor concept is the identification of translocation of the TRE17/USP6 locus, resulting in TRE17 overexpression in more than 60% of ABC cases in long bones. An unrelated antecedent primary lesion of bone, such as fibrous dysplasia, central giant cell granuloma, nonossifying fibroma, chondroblastoma, and other primary bone lesions, is believed to initiate a vascular malformation, resulting in a secondary lesion or aneurysmal bone cyst.

Clinical Features. Aneurysmal bone cysts typically occur in persons younger than 30 years. The peak incidence occurs within the second decade of life. A slight female predilection has been noted.

When the mandible and the maxilla are involved, the more posterior regions are affected, chiefly the molar areas (Figure 10-45). Pain is described in approximately half of cases, and a firm, nonpulsatile swelling is a common clinical sign. On auscultation, a bruit is not heard, indicating that blood is not located within an arterial space; on firm palpation, crepitus may be noted.

Radiographic features include the presence of a destructive or osteolytic process with slightly irregular margins. A multilocular pattern is noted in some instances. When the alveolar segment of the mandible and the maxilla is involved, teeth may be displaced with or without concomitant external root resorption.

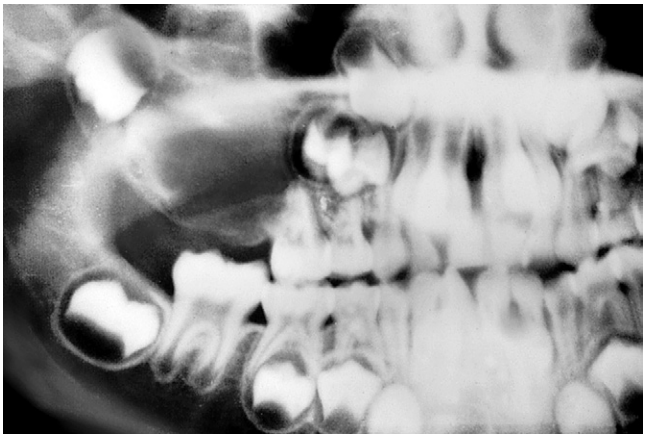

■ **FIGURE 10-45 Aneurysmal bone cyst** of the right maxilla.

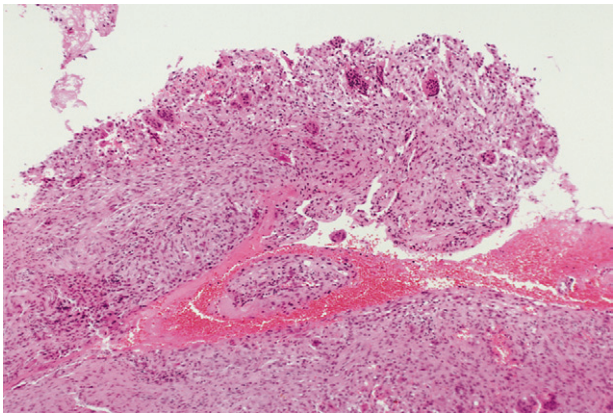

■ **FIGURE 10-46 Aneurysmal bone cyst** lining composed of connective tissue and scattered multinucleated giant cells.

Histopathology. A fibrous connective tissue stroma contains variable numbers of multinucleated giant cells (Figure 10-46). Sinusoidal blood spaces are lined by fibroblasts and macrophages. With the exception of the sinusoids, the aneurysmal bone cyst is similar to central giant cell granuloma. Reactive new bone formation is commonly noted.

Differential Diagnosis. OKC/KCOT, central giant cell granuloma, and ameloblastic fibroma should be included in the differential diagnosis. Ameloblastoma and odontogenic myxoma could be included, although these lesions more typically appear in older patients.

Treatment and Prognosis. A relatively high recurrence rate has been associated with simple curettage. Excision or curettage with supplemental cryotherapy is the treatment of choice.

Traumatic (Simple) Bone Cyst

A traumatic bone cyst is an empty intrabony cavity that lacks an epithelial lining. The designation of pseudocyst relates to the cystic radiographic appearance and gross

surgical presentation of this lesion (Box 10-13). It is seen most often in the mandible.

Pathogenesis. The pathogenesis is not known, although some cases seem to be associated with antecedent trauma. Assuming this to be the case, a traumatically-induced hematoma has been hypothesized as forming within the intramedullary portion of bone. Rather than organizing, the clot breaks down, leaving an empty bony cavity. Alternative developmental pathways include cystic degeneration of primary tumors of bone, such as central giant cell granuloma, disorders of calcium metabolism, and ischemic necrosis of bone marrow.

Clinical Features. Teenagers are most commonly affected, although traumatic bone cysts have been reported over a wide age range. An equal gender distribution has been noted.

By far, the most common site of occurrence is the mandible (Figure 10-47). The lesion may be seen in anterior or posterior regions. Rare bilateral cases have been described. Swelling is occasionally seen, and pain is infrequently noted.

BOX 10-13 TRAUMATIC BONE CYST

ETIOLOGY
Unknown; trauma sometimes suggested
May be related to bleeding in the jaw with clot resorption

CLINICAL FEATURES
Lucency discovered on routine examination
Empty "dead" space in medullary bone, especially mandible
Teenagers most commonly affected

TREATMENT
Surgical entry to initiate bleeding and stimulate healing
Some may heal spontaneously.

Radiographically, a well-delineated area of radiolucency with an irregular but defined edge is noted. Inter-radicular scalloping of varying degrees is characteristic, and occasionally slight root resorption may be observed.

Traumatic bone cysts have often been seen in association with florid osseous dysplasia. The relationship between these two entities is not understood.

Histopathology. Grossly, only minimal amounts of fibrous tissue from the bony wall are seen. The lesion may occasionally contain blood or serosanguineous fluid. Microscopically, delicate, well-vascularized, fibrous connective tissue without evidence of an epithelial component is identified (Figure 10-48).

Treatment and Prognosis. Once entry into the cavity is accomplished, the clinician need merely establish bleeding into the lesion before closure. Organization of the bony clot results in complete bony repair without recurrence.

Static Bone Cyst (Stafne's Bone Defect)

A static bone cyst is an anatomic indentation of the posterior lingual mandible that appears to resemble a cyst on radiographic examination (Box 10-14; Figure 10-49). This depression of the mandible is believed to be developmental, although almost all cases appear in adults, particularly men.

BOX 10-14 STATIC (STAFNE'S) BONE CYST

Developmental defect
Located below mandibular canal in molar region
Salivary gland or adipose tissue in defect
Discrete corticated margin
Diagnostic on panoramic film
No symptoms
No biopsy or treatment—radiographic diagnosis

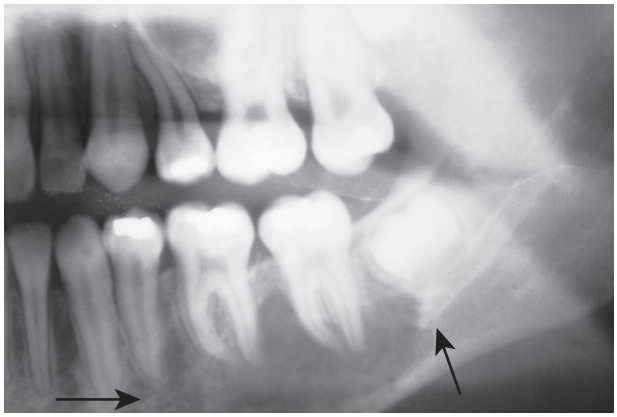

■ **FIGURE 10-47 Traumatic bone cyst** of the body of the mandible.

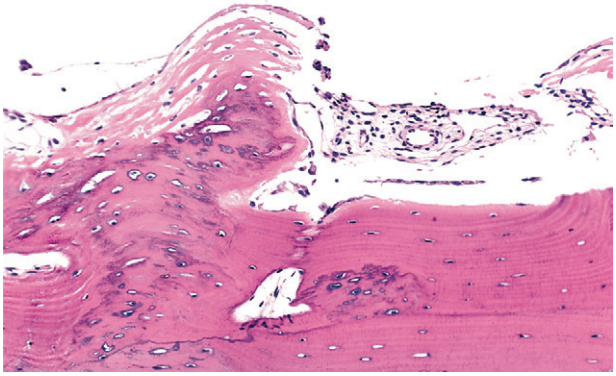

■ **FIGURE 10-48 Traumatic bone cyst** consisting of connective tissue fragments lining surrounding bone *(bottom)*.

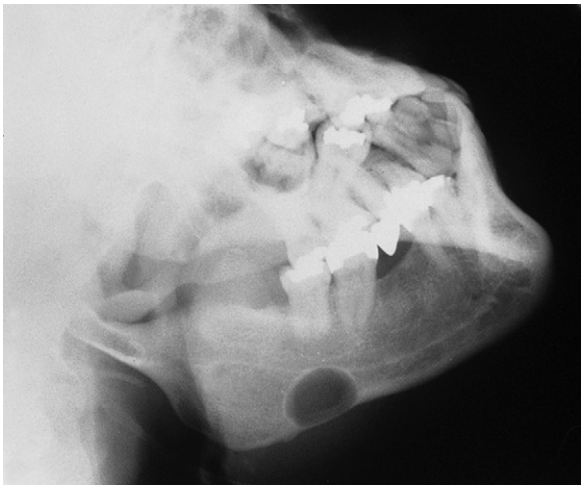

■ **FIGURE 10-49** Static bone cyst.

The cause is unknown, but some have suggested that the lesion is due to entrapment of the salivary gland or other soft tissue during development of the mandible. Others have suggested that the cause is lingual mandibular cortical erosion from hyperplastic salivary gland tissue. Both demographic and anatomic findings are more consistent with the latter hypothesis. These defects occasionally may be noted bilaterally and, rarely, anterior to the first molar region of the mandible.

This lesion is entirely asymptomatic and is often observed as an incidental finding on panoramic radiographic films. It appears as a sharply circumscribed oval radiolucency beneath the level of the inferior alveolar canal, with encroachment on the inferior border of the mandible. The presence of salivary tissue within the defect may be confirmed by sialography. The appearance of a static bone cyst is usually pathognomonic, and no treatment is required. Other depressions of the cortical surface of the mandible have been reported, albeit rarely, within the parotid gland along the lateral or facial aspect of the mandibular ramus.

Focal Osteoporotic Bone Marrow Defect

Focal osteoporotic bone marrow defects *(hematopoietic bone marrow defects)* are uncommon lesions that typically present as asymptomatic, focal radiolucencies in areas where hematopoiesis is normally seen (angle of the mandible and maxillary tuberosity). Approximately 70% of these lesions occur in the posterior mandible; 70% occur in females.

The pathogenesis of the osteoporotic marrow defect is unknown, although three theories have been proposed. One theory states that abnormal healing following tooth extraction may be responsible (Figure 10-50). Another theory proposes that residual remnants of fetal marrow may persist into adulthood, thus presenting as a focal lucency. Finally, this tissue may merely represent a focus of extramedullary hematopoiesis that becomes hyperplastic in adult life.



■ **FIGURE 10-50 Focal osteoporotic bone marrow defect** in a maxillary molar extraction site.

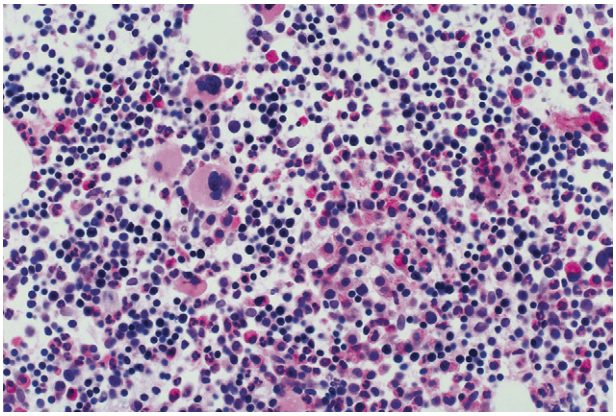

■ **FIGURE 10-51 Focal osteoporotic bone marrow defect** composed of maturing blood cells and megakaryocytes.

Microscopic findings show a predominance of hematopoietic cells with relatively fewer fat cells. Within the cellular marrow, small lymphoid aggregates may be found, as well as megakaryocytes (Figure 10-51).

Because of nonspecific radiographic findings, diagnosis by an incisional biopsy is generally desirable. Subsequent to the establishment of this diagnosis, no further treatment is necessary.

SOFT TISSUE CYSTS OF THE NECK

Branchial Cyst/Cervical Lymphoepithelial Cyst

Branchial (cleft) cysts, or cervical lymphoepithelial cysts, are located in the lateral portion of the neck, usually anterior to the sternomastoid muscle (Figure 10-52). These lesions may also appear in the submandibular area, adjacent to the parotid gland, or around the sternomastoid muscle. There is an intraoral *lymphoepithelial cyst* counterpart (Figure 10-53).



■ **FIGURE 10-52 Cervical lymphoepithelial cyst.**



■ **FIGURE 10-53 Lymphoepithelial cyst** (yellowish nodule) located at the left submandibular caruncle.

BOX 10-15 BRANCHIAL CYST

Developmental cyst—arises from epithelium entrapped in lymph node
Lateral neck mass—along anterior border of sternocleidomastoid muscle
Fluctuant texture
Young adults
Lymphoid tissue surrounds a squamous or pseudostratified epithelial lining.

The floor of the mouth is the most common site for these lesions, followed by the posterior lateral tongue.

At one time, the branchial cyst was thought to occur because of incomplete obliteration of the branchial clefts, with epithelial remnants ultimately undergoing cystic change. The current theory of origin proposes that epithelium is entrapped in cervical lymph nodes during embryogenesis (Box 10-15). This epithelium, thought to be of salivary origin, would undergo cystic change at a later date.

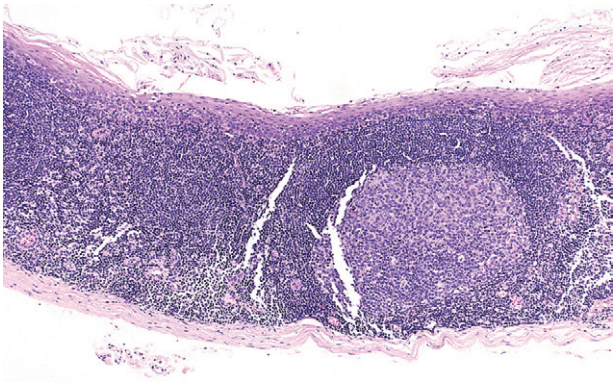

■ **FIGURE 10-54 Lymphoepithelial cyst** lined by squamous epithelium *(top)* and supported by lymphoid tissue.

Clinical Features. These asymptomatic cysts usually become clinically apparent in late childhood or young adulthood as a result of enlargement. Drainage may occur along the anterior margin of the sternomastoid muscle.

Histopathology. The branchial cyst is lined with stratified squamous epithelium, pseudostratified columnar epithelium, or both (Figure 10-54). The epithelium is supported by connective tissue containing lymphoid aggregates.

Differential Diagnosis. Preoperative diagnoses may include cervical lymphadenitis, skin inclusion cyst, lymphangioma, and tumor of the tail of the parotid. Laterally displaced thyroglossal tract cyst and dermoid cyst might also be considered. In adults, metastatic oropharyngeal squamous cell carcinoma, particularly cases associated with human papillomavirus (HPV) infection, may present as a lateral neck mass. Fine-needle aspiration biopsy of the neck mass and advanced imaging are helpful in excluding this possibility.

Treatment. Treatment is surgical excision.

Dermoid Cyst

Dermoid cysts are developmental lesions that may occur in many areas of the body (Box 10-16). When found in the oral cavity, the lesion is usually in the anterior portion of the floor of the mouth in the midline. The cause of the lesion in this area is believed to be developmental entrapment of multipotential cells or possibly implantation of epithelium.

Clinical Features. Clinically, these cysts, when located above the mylohyoid muscle, displace the tongue superiorly and posteriorly (Figure 10-55). When they are located below the mylohyoid muscle, midline swelling of the neck occurs (Figure 10-56). These cysts are painless and slow-growing; no gender predilection has been noted. Lesions are generally smaller than 2 cm in diameter; however, extreme examples may range up to 8 to 12 cm. On palpation, the

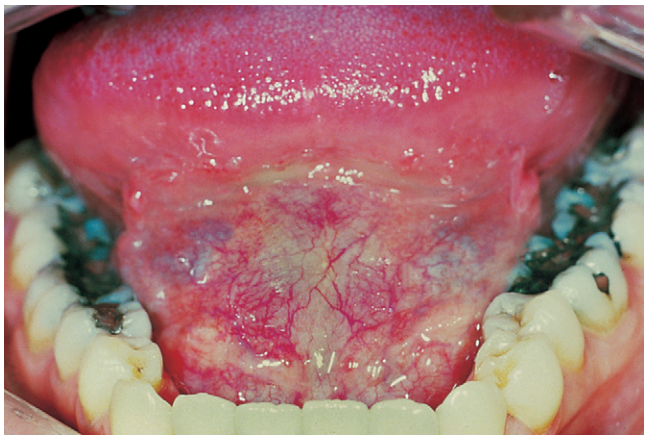

■ **FIGURE 10-55 Dermoid cyst** presenting intraorally as a midline swelling in the floor of the mouth.



■ **FIGURE 10-56 Dermoid cyst** presenting as a midline swelling in the neck.

BOX 10-16 DERMOID CYST

- Mass in midline of neck or floor of mouth (location depends on relationship to mylohyoid and geniohyoid muscles)
- Young adults
- Doughy by palpation because of sebum in lumen
- Lined by epithelium and secondary skin structures (sebaceous glands, hair)
- Designated as teratoma if all three germ layers are represented

cysts are soft and doughy because of keratin and sebum in the lumen.

Histopathology. Microscopically, the dermoid cyst is lined by stratified squamous epithelium supported by a fibrous connective tissue wall (Figure 10-57). Numerous

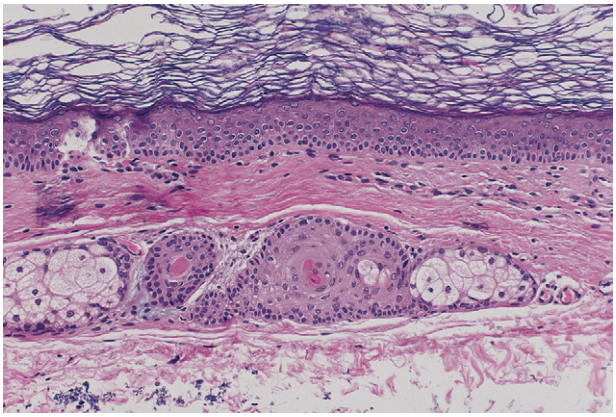

■ **FIGURE 10-57 Dermoid cyst** lined by keratinized epithelium with sebaceous glands and rudimentary hair in the supporting connective tissue.

BOX 10-17 THYROGLOSSAL TRACT CYST

- Arises from epithelial remnants of thyroid gland development
- Occurs in midline of neck—anywhere between thyroid embryonic origin (foramen caecum of tongue) and thyroid gland
- Lingual thyroid
- Mass in tongue base caused by failed descent of thyroid tissue
- May be only functional thyroid tissue in patient
- Treatment by excision; may recur because of tortuous configuration
- Rare cases of thyroid cancer develop along the cyst tract.

secondary skin structures, including hair follicles, sebaceous glands, and sweat glands (and occasionally teeth), may be found.

Treatment. Treatment is surgical excision. Most lesions can be removed through the mouth with little risk of recurrence.

Thyroglossal Tract Cyst

Thyroglossal tract cysts are the most common developmental cysts of the neck, accounting for nearly three fourths of such lesions (Box 10-17). The basis of this cystic pathology relates to thyroid gland development. Thyroid tissue becomes evident in the fourth week of gestation, when derivatives of first and second branchial arches form the posterior portion of the tongue in the region of the foramen caecum. The thyroid anlage grows downward from the foramen caecum area to its permanent location in the neck. Residual epithelial elements along this pathway that do not completely atrophy may give rise to cysts in later life from the posterior portion

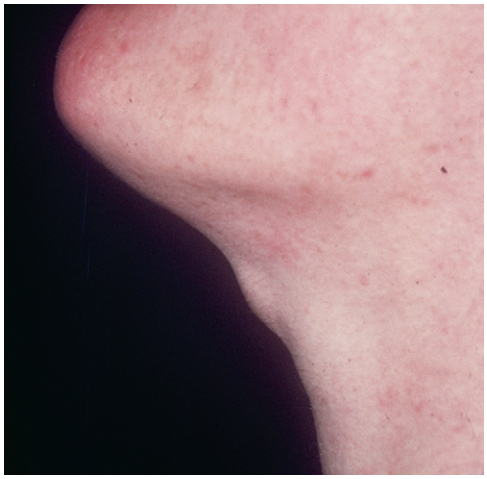

■ **FIGURE 10-58 Thyroglossal tract cyst** in the midline of the neck.



■ **FIGURE 10-59 Lingual thyroid** posterior to circumvallate papillae in the midline of the tongue.

of the tongue *(lingual thyroid)* to the midline of the neck (Figures 10-58 and 10-59).

Clinical Features. Approximately 30% of cases are found in patients older than 30 years, with a similar percentage in patients younger than 10 years. Most cysts occur at the midline, with 60% occurring in the thyrohyoid membrane and only 2% within the tongue itself. An over-riding majority (70% to 80%) occur below the level of the hyoid bone.

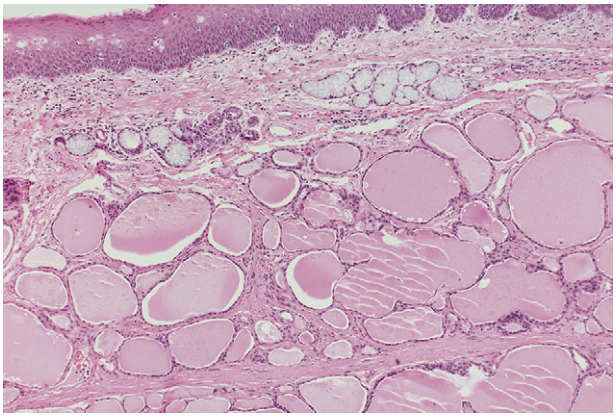

■ **FIGURE 10-60 Lingual thyroid** showing thyroid acini in the submucosa.

These cysts are generally asymptomatic. When attached to the hyoid bone and tongue, they may retract on swallowing or on extension of the tongue. If infected, drainage through a sinus tract may occur. Rarely, malignant transformation has been described in these lesions.

Histopathology. Microscopic findings vary depending on the location of the cyst (Figure 10-60). Lesions that occur above the level of the hyoid bone demonstrate a lining chiefly of stratified squamous epithelium. A ciliated or columnar type of epithelium is usually found in cysts that occur below the hyoid bone. However, wide variation may be seen within a single cyst. Thyroid tissue may be present within the connective tissue wall. Rare malignancies arising within the thyroglossal tract are usually papillary thyroid adenocarcinomas.

Differential Diagnosis. Differential diagnosis of the thyroglossal tract cyst should include dermoid cyst, thyroid neoplasm, branchial cyst, and sebaceous cyst.

Treatment. Treatment is surgical excision. It is important to establish before surgery whether the thyroglossal duct cyst represents the only functioning thyroid tissue in the patient. Because the lesion may be rather tortuous in configuration, recurrence may be seen. It is often recommended that the central portion of the hyoid bone be removed in an effort to eliminate any residual thyroglossal tract epithelium from this site.

BIBLIOGRAPHY

Odontogenic Cysts

Androulakis M, Johnson JT, Wagner RL: Thyroglossal duct and second branchial cleft anomalies in adults. Ear Nose Throat J 69:318–322, 1990.

Aszterbaum M, Rothman A, Johnson RL et al: Identification of mutations in the human PATCHED gene in sporadic basal cell carcinomas and in patients with basal cell nevus syndrome. J Invest Dermatol 110:885–888, 1998.

Barnes L, Eveson JW, Reichart P, Sidransky D, editors: Pathology and Genetics of Head and Neck Tumours. WHO Classification Series, Lyon, 2005, IARC Press, pp 306–307.

Barretto DC, Gomez RS, Bale AE et al: PTCH gene mutations in odontogenic keratocysts. J Dent Res 79:1418–1422, 2000.

Becconsall-Ryan R, Tong D, Love RM: Radiolucent inflammatory jaw lesions: a twenty year analysis. Int Endod J 43:859–865, 2010.

Buchner A: The central (intraosseous) calcifying odontogenic cyst: an analysis of 215 cases. J Oral Maxillofac Surg 49:330–339, 1991.
Crowley TE, Kaugars GE, Gunsolley JC: Odontogenic keratocysts: a clinical and histologic comparison of the parakeratin and ortho-keratin variants. J Oral Maxillofac Surg 50:22–26, 1992.
Fantasia JE: Lateral periodontal cysts, botryoid odontogenic cysts and glandular odontogenic cysts. Oral Maxillofac Surg Clin North Am 3:127–136, 1991.
Garcia de Paula e Silva FW, D'Silva MJ, da Silva LB, Kapila YL: High matrix metalloproteinase activity is a hallmark of periapical granulomas. J Endod 35:1234–1242, 2009.
Henley J, Summerlin DJ, Tomich C et al: Molecular evidence supporting the neoplastic nature of odontogenic keratocyst: a laser capture microdissection study of 15 cases. Histopathology 47:582–586, 2005.
Iatrou I, Theologie N, Leventis M: Intraosseous cystic lesions of the jaws in children: a retrospective analysis of 47 consecutive cases. Oral Surg Oral Med Oral Pathol Oral Radiol Endod 107:485–492, 2009.
Kenealy JF, Torsiglieri AJ, Jr, Tom LW: Branchial cleft anomalies: a five year retrospective review. Trans Pa Acad Ophthalmol Otolaryngol 42:1022–1025, 1990.
Kolar Z, Geierova M, Bouchal J et al: Immunohistochemical analysis of the biological potential of odontogenic keratocyst. J Oral Pathol Med 35:75–80, 2006.
Krishnamurthy A, Sherlin HJ, Ramalingam K et al: Glandular odontogenic cyst: report of two cases and review of literature. Head Neck Pathol 3:153–158, 2009.
Lench NJ, High AS, Markham AF et al: Investigation of chromosome 9q22.3-q31 DNA marker loss in odontogenic keratocysts. Oral Oncol 32B:202–206, 1996.
Lo Muzio L, Staibano S, Pannone G et al: Expression of cell cycle and apoptosis-related proteins in sporadic odontogenic keratocysts and odontogenic keratocysts associated with the nevoid basal cell carcinoma syndrome. J Dent Res 78:1345–1353, 1999.
Love RM, Firth N: Histopathological profile of surgically removed persistent periapical radiolucent lesions of endodontic origin. Int Endod J 42:198–202, 2009.
Madras J, Lapointe H: Keratocystic odontogenic tumor: reclassification of the odontogenic keratocyst from cyst to tumor. J Can Dent Assoc 74:165–165h, 2008.
Maurette PE, Jorge J, de Moraes M: Conservative treatment protocol of odontogenic keratocyst: a preliminary study. J Oral Maxillofac Surg 64:379–383, 2006.
Morgan TA, Burton CC, Qian F: A retrospective review of treatment of the odontogenic keratocyst. J Oral Maxillofac Surg 63:635–639, 2005.
Nawshad AI, Savage NW, Young WG et al: Allelic losses in chromosome 9q22.3-31q in odontogenic keratocysts. J Oral Pathol Med 29:353, 2000.
Pavelic B, Levanat S, Crnic I et al: *PTCH* gene altered in dentigerous cysts. J Oral Pathol Med 30:569–576, 2001.
Pogrel MA: Treatment of keratocysts: the case for decompression and marsupialization. J Oral Maxillofac Surg 63:1667–1673, 2005.
Ramer M, Montazem A, Lane SL et al: Glandular odontogenic cyst. Oral Surg Oral Med Oral Pathol Oral Radiol Endod 84:54–57, 1997.
Redman RS, Whitestone BW, Winne CE et al: Botryoid odontogenic cyst: report of a case with histologic evidence of multicentric origin. Int J Oral Maxillofac Surg 19:144–146, 1990.
Renard TH, Choucair RJ, Stevenson WD et al: Carcinoma of the thyroglossal duct. Surg Gynecol Obstet 171:305–308, 1990.
Rosenberg PA, Frisbie J, Lee J et al: Evaluation of pathologists (histopathology) and radiologists (cone beam computed tomography) differentiating radicular cysts from granulomas. J Endod 36:423–428, 2010.
Sadeghi EM, Weldon LL, Kwon PH et al: Mucoepidermoid odontogenic cyst. Int J Oral Maxillofac Surg 29:142–143, 1991.
Sciubba JJ, Fantasia JE, Kahn LB: Tumors and Cysts of the Jaws. Washington, DC, 2001, Armed Forces Institute of Pathology.
Shen J, Fan M, Chen X et al: Glandular odontogenic cyst in China: report of 12 cases and immunohistochemical study. J Oral Pathol Med 35:175–182, 2006.
Spatafore CM, Griffin JA, Jr, Keyes GG et al: Periapical biopsy report: an analysis over a ten year period. J Endod 16:239–241, 1990.
Taylor MD, Liu L, Raffel C et al: Mutations in SUFU predispose to medulloblastoma. Nat Genet 31:306–310, 2002.
Teronen O, Konttinen YT, Rifkin B et al: Identification and characterization of gelatinase/type IV collagenases in jaw cysts. J Oral Pathol Med 24:78–84, 1995.
van Heerden WFP, Raubenheimer EJ, Turner M: Glandular odontogenic cyst. Head Neck 14:316–320, 1992.
Waldron CA, Koh ML: Central mucoepidermoid carcinoma of the jaws: report of four cases with analysis of the literature and discussion of the relationship to mucoepidermoid, sialoodontogenic and glandular odontogenic cysts. J Oral Maxillofac Surg 48:871–877, 1990.
Wolf J, Hietanen J: The mandibular infected buccal cyst (paradental cyst): a radiographic and histologic study. Br J Oral Maxillofac Surg 28:322–325, 1990.
Yaskima M, Ogura M, Abiko Y: Studies on cholesterol accumulation in radicular cyst fluid-origin of heat-stable cholesterol-binding protein. Int J Biochem 22:165–169, 1990.
Zedan W, Robinson PA, Markham AF et al: Expression of the Sonic Hedgehog receptor "PATCHED" in basal cell carcinomas and odontogenic keratocysts. J Pathol 194:473–477, 2001.

Nonodontogenic Cysts

Revel MP, Vanel D, Sigal R et al: Aneurysmal bone cysts of the jaws: CT and MR findings. J Comput Assist Tomogr 16:84–86, 1992.

Cysts of the Neck

Fernandez JF, Ordonez NG, Schultz PN et al: Thyroglossal duct carcinoma. Surgery 6:928–934, 1991.

CHAPTER 11

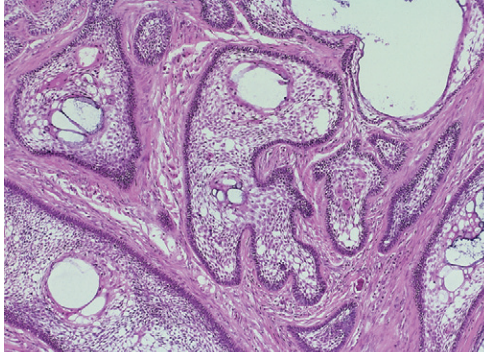

Odontogenic Tumors

EPITHELIAL TUMORS

Ameloblastoma
Calcifying Epithelial Odontogenic Tumor (Pindborg Tumor)
Adenomatoid Odontogenic Tumor
Squamous Odontogenic Tumor
Clear Cell Odontogenic Tumor (Carcinoma)

MESENCHYMAL TUMORS

Odontogenic Myxoma
Central Odontogenic Fibroma
Cementifying Fibroma
Cementoblastoma
Periapical Cemento-osseous Dysplasia

MIXED (EPITHELIAL AND MESENCHYMAL) TUMORS

Ameloblastic Fibroma and Ameloblastic Fibro-odontoma
Odontoma

Odontogenic tumors are derived from the epithelial and/or mesenchymal remnants of the tooth-forming apparatus. Therefore, they are found exclusively in the mandible and maxilla (and occasionally in the gingiva). The origin and pathogenesis of this group of lesions are unknown. Clinically, odontogenic tumors are typically asymptomatic, although they may cause jaw expansion, movement of teeth, root resorption, and bone loss. Knowledge of typical basic features such as age, location, and radiographic appearance of the various odontogenic tumors can be extremely valuable in developing a clinical differential diagnosis.

Similar to neoplasms elsewhere in the body, odontogenic tumors tend to mimic microscopically the cell or tissue of origin. Histologically, they may resemble soft tissue components of the enamel organ or dental pulp, or they may contain hard tissue elements of enamel, dentin, and/or cementum.

Biologically, lesions in this group range from hamartomatous proliferations to malignant neoplasms with metastatic capabilities. They may be found within the maxillofacial skeleton (central) or may be located in the soft tissue overlying the tooth-bearing regions and in the alveolar mucosa of edentulous segments of the jaws (peripheral). An understanding of the biological behavior of the various odontogenic tumors is fundamentally important to the overall treatment of patients.

Several classification schemes based on histologic patterns have been devised for this complex group of lesions. Common to all is the division of tumors into those composed of odontogenic epithelial elements, those composed of odontogenic mesenchyme, and those that are proliferations of both epithelium and mesenchyme (ectomesenchyme). As classified on the basis of biological behavior, they range from clinically trivial (i.e., benign, no recurrence potential) to malignant (Box 11-1).

EPITHELIAL TUMORS

Ameloblastoma

Historically, ameloblastoma has been recognized for over a century and a half. Its frequency, persistent local growth, and ability to produce marked deformity before leading to serious

BOX 11-1 BIOLOGICAL CLASSIFICATION OF ODONTOGENIC TUMORS

BENIGN, NO RECURRENCE POTENTIAL
Adenomatoid odontogenic tumor
Squamous odontogenic tumor
Cementoblastoma
Periapical cemento-osseous dysplasia
Odontoma

BENIGN, SOME RECURRENCE POTENTIAL
Cystic ameloblastoma
Calcifying epithelial odontogenic tumor
Central odontogenic fibroma
Florid cemento-osseous dysplasia
Ameloblastic fibroma and fibro-odontoma

BENIGN AGGRESSIVE
Ameloblastoma
Clear cell odontogenic tumor
Odontogenic ghost cell tumor
Odontogenic myxoma
Odontoameloblastoma

MALIGNANT
Malignant ameloblastoma
Ameloblastic carcinoma
Primary intraosseous carcinoma
Odontogenic ghost cell carcinoma
Ameloblastic fibrosarcoma

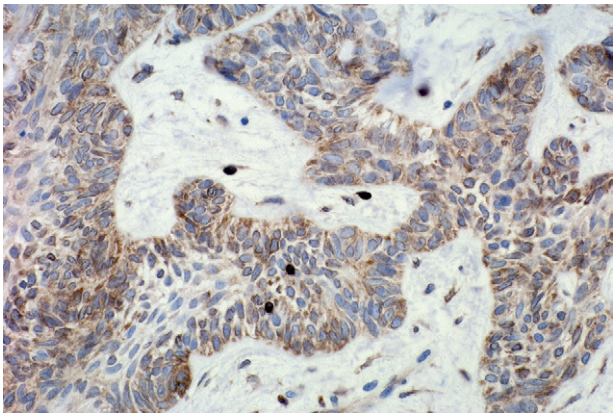

■ **FIGURE 11-1 Ameloblastoma** exhibiting overexpression (brown cytoplasmic stain) of antiapoptotic protein Bcl-2.

BOX 11-2 AMELOBLASTOMA: PATHOGENETIC MECHANISMS

CELL CYCLE–RELATED FACTORS
Low proliferation rate; few cells in cell cycle based on low Ki-67 expression
Antiapoptotic proteins expressed; overexpression of Bcl-2 and Bcl-x_L
Some positive p53 staining; probably wild-type protein inactivated by MDM2 binding
TNF-α expression

INTERFACE FACTORS
Invasive properties enhanced
Altered laminin 5 at interface
Expression of FGF and interleukins (1 and 6)
Overexpression of proteinases (MMPs 9 and 20; EMSP1)

EMSP1, Enamel matrix serine proteinase; *FGF,* fibroblast growth factor; *MDM2,* murine double minute 2; *MMPs,* matrix metalloproteinases.

debilitation probably account for its early recognition. Recurrence, especially after conservative treatment, has also contributed to awareness of this lesion.

Pathogenesis. This neoplasm originates within the mandible or maxilla from epithelium involved in the formation of teeth. Less commonly, the ameloblastoma may arise at a soft tissue location within the gingiva of tooth-bearing areas. Potential epithelial sources include the enamel organ, odontogenic rests (rests of Malassez, rests of Serres), reduced enamel epithelium, and the epithelial lining of odontogenic cysts, especially dentigerous cysts. The trigger or stimulus for neoplastic transformation of these epithelial residues is unknown.

Mechanisms by which ameloblastomas gain a growth and invasion advantage include those associated with tumorigenesis and differentiation as well as other molecules related to tumor progression. These include but are not limited to overexpression of tumor necrosis factor (TNF)-α, antiapoptotic proteins (Bcl-2, Bcl-x_L), and interface proteins (fibroblast growth factor [FGF], matrix metalloproteinases [MMPs]) (Figure 11-1 and Box 11-2). Ameloblastomas, however, have a low proliferation rate, as shown by staining for the cell cycle–related protein, Ki-67. Suggestions that dysregulation of the sonic hedgehog (SHH) pathway may play a role in the development of ameloblastoma have been put forth, although it must be emphasized that the overall significance of this is unclear. Mutations of the *p53* gene do not appear to play a role in the development and growth of ameloblastoma; a role for ameloblastin protein has been identified, although it is not specific to ameloblastoma.

Clinical Features. Ameloblastoma is chiefly a lesion of adults. It occurs predominantly in the fourth and fifth decades of life, and the age range is very broad, extending from childhood to late adulthood (mean age, approximately 40 years) (Box 11-3). The rare lesions occurring in children are usually cystic and appear clinically as odontogenic cysts. There appears to be no gender predilection for this tumor.

BOX 11-3 AMELOBLASTOMA: CLINICAL FEATURES

Benign, aggressive tumor that is invasive and persistent
Sometimes called solid or multicystic ameloblastoma
Adults most commonly affected
Broad age range; mean age, 40 years
Mandibular molar-ramus most commonly affected site
Always radiolucent
Unilocular or multilocular
Slow-growing and typically well defined radiographically
Treated by surgical excision to resection
Recurrence rate higher with conservative treatment



■ **FIGURE 11-2 Ameloblastoma** of the mandible producing marked cortical expansion.

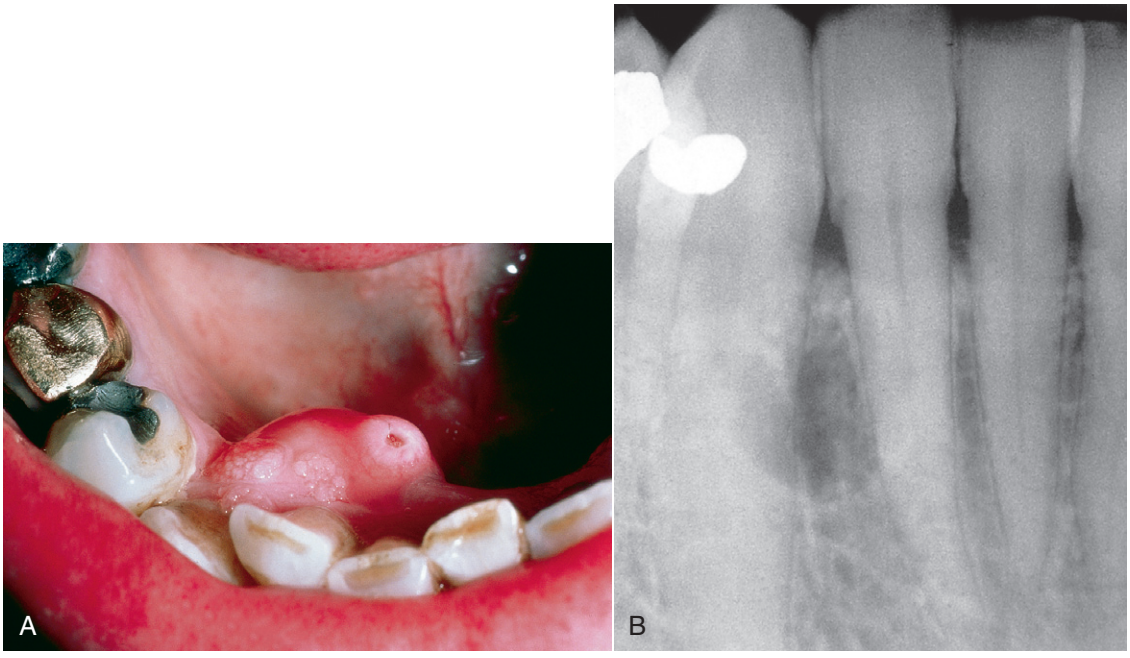

■ **FIGURE 11-3 A** and **B, Ameloblastoma** of the mandible with oral presentation.

Ameloblastomas may occur anywhere in the mandible or maxilla, although the mandibular molar-ramus area is the most common site. In the maxilla, the molar area is more commonly affected than the premolar and anterior regions. Lesions usually are asymptomatic and are discovered during routine radiographic examination or because of asymptomatic jaw expansion (Figures 11-2 and 11-3). Occasionally, tooth movement or malocclusion may be the initial presenting sign.

Radiographically, ameloblastomas are osteolytic, typically found in the tooth-bearing areas of the jaws, and they may be unicystic or multicystic (Figures 11-4 to 11-7). Because ameloblastomas are slow-growing, the radiographic margins usually are well defined and sclerotic. In cases in which connective tissue desmoplasia occurs in conjunction with tumor proliferation, ill-defined radiographic margins are typically seen. This variety, known as *desmoplastic ameloblastoma,* also has a predilection for the anterior jaws and radiographically may resemble a fibro-osseous lesion. The generally slow tumor growth rate may be responsible for the movement of tooth roots. Root resorption occasionally occurs in association with ameloblastoma growth.

Biological Subtypes. *Peripheral* or *extraosseous ameloblastomas* may occur in the gingiva and very rarely in the buccal mucosa (Boxes 11-4 and 11-5; Figure 11-8). These lesions are seen in older adults, usually between 40 and 60 years of age. They may arise from overlying epithelium or

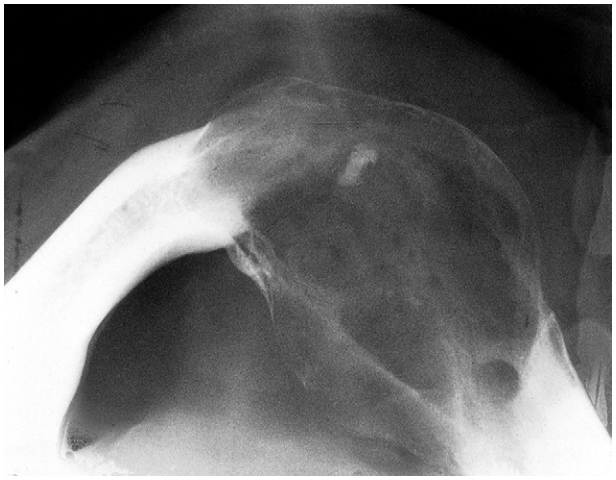

■ **FIGURE 11-4 Ameloblastoma** in an edentulous anterior mandible. Occlusal view shows a destructive multilocular lesion.

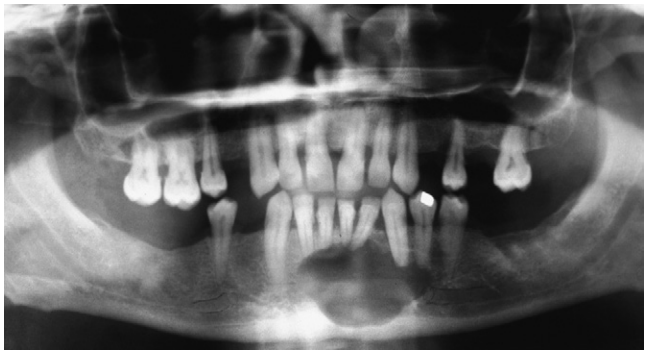

■ **FIGURE 11-5 Unilocular ameloblastoma** of the anterior mandible.

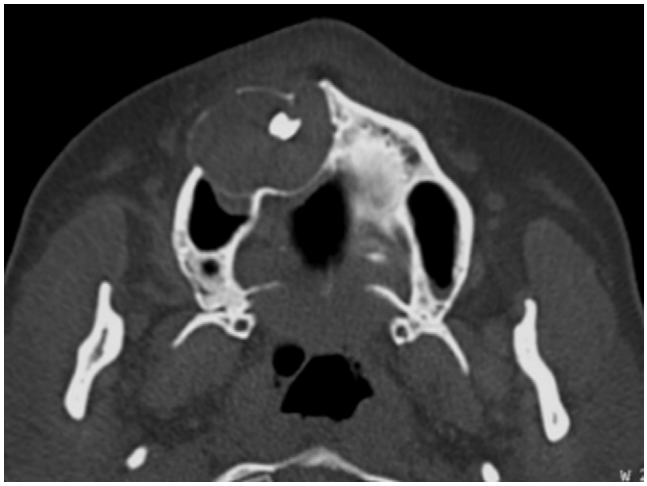

■ **FIGURE 11-6 Ameloblastoma** of the maxilla with an impacted premolar tooth and a uniform thin cortical margin of bone of the expanded buccal and palatal regions on this axial CT scan.

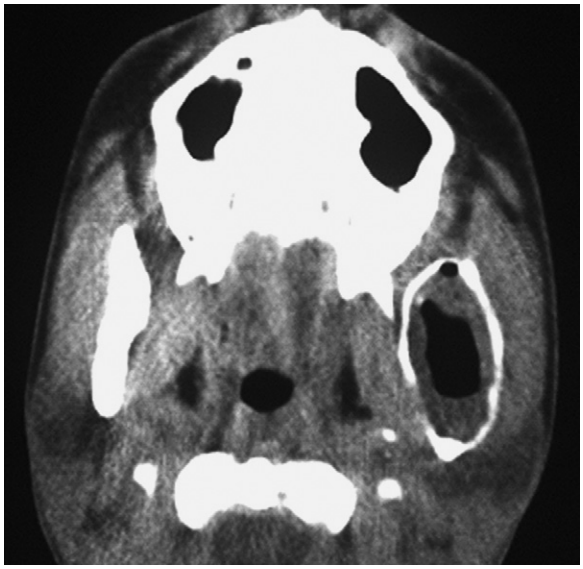

■ **FIGURE 11-7 Ameloblastoma** of the mandibular ramus on CT scan.

BOX 11-4 AMELOBLASTOMA: BIOLOGICAL SUBTYPES

(Solid) ameloblastoma
Cystic (unicystic) ameloblastoma
Peripheral ameloblastoma
Malignant ameloblastoma
Ameloblastic carcinoma

BOX 11-5 PERIPHERAL AMELOBLASTOMA

Ameloblastoma developing in gingival soft tissue
May originate from gingival epithelium
Typically does not invade underlying bone
Older adults most commonly affected
Presents as a painless gingival mass
Mandibular gingiva > maxillary gingival
Treated with local excision; rarely recurs

>, More frequently affected than.

rests of Serres. They exhibit a benign, nonaggressive course and generally do not invade underlying bone. Following local excision, recurrence is rare.

Cystic ameloblastoma (also referred to as *unicystic ameloblastoma)* accounts for approximately 6% of ameloblastomas. We prefer the term *cystic ameloblastoma* because these entities are often multilocular, show cortical perforation in 25% of cases, and have a recurrence rate as high as 40% when treated by curettage (as late as 9 years following surgery) (Box 11-6; Figures 11-9 and 11-10). They are seen in a younger age group (mean age, ≈35 years) than solid tumors.

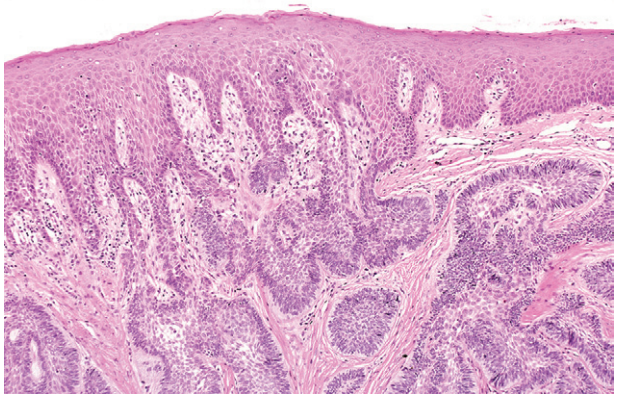

■ **FIGURE 11-8 Peripheral ameloblastoma** showing communication with overlying epithelium.

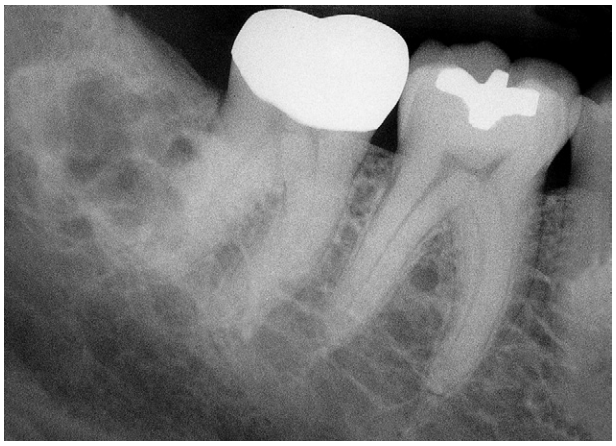

■ **FIGURE 11-9 Cystic ameloblastoma** with a loculated appearance in retromolar mandibular bone.

BOX 11-6 CYSTIC (UNICYSTIC) AMELOBLASTOMA

CLINICAL FEATURES

Multilocularity and cortical perforation (25% of cases)

HISTOPATHOLOGY

Thin, nonkeratinized epithelium
Basal palisading
Spongiosis
Epithelial invaginations
Subepithelial hyalinization

MICROSCOPIC PATTERNS

Simple cystic intraluminal growth
Simple cystic with mural invasion

TREATMENT

Excision
Curettage; recurrence rate as high as 40% (seen as late as 9 years after surgery)



■ **FIGURE 11-10 Cystic ameloblastoma** occupying the body of the mandible. The lesion recurred twice following curettage.

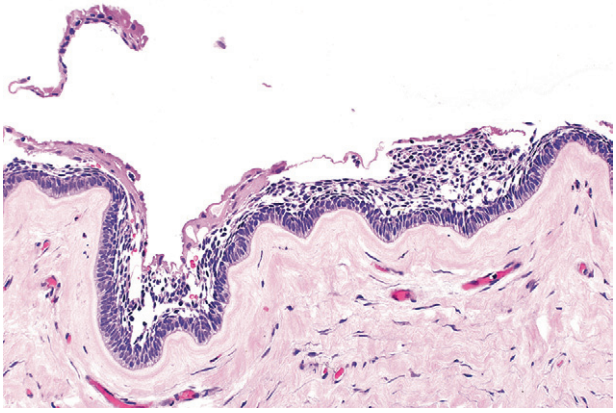

■ **FIGURE 11-11 Cystic ameloblastoma** showing spongiotic epithelium and basal palisading.

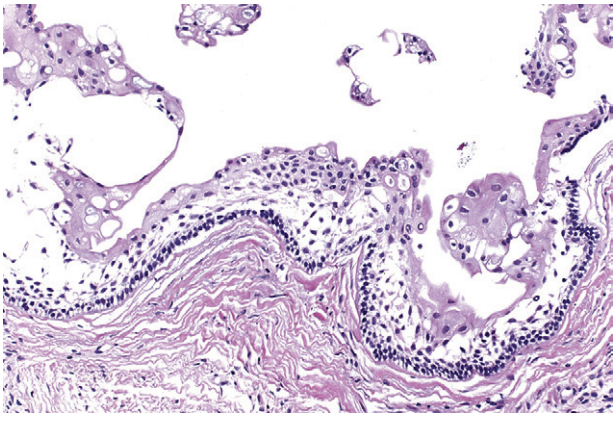

■ **FIGURE 11-12 Cystic ameloblastoma** with a spongiotic epithelial lining.

The microscopy is deceptive because the lesions are nearly completely cystic and can be confused with a simple odontogenic cyst (Figures 11-11 and 11-12).

Malignant variants of ameloblastomas may rarely be encountered. These lesions occur in a relatively young age group (thirties) and appear in the mandible more commonly than in the maxilla. By definition, these are lesions that metastasize to local lymph nodes or distant organs. Direct

extension into contiguous areas does not qualify for a malignant designation. Malignant lesions have been divided into two subtypes: *malignant ameloblastoma* (Figure 11-13), in which primary and metastatic lesions are microscopically well differentiated with the characteristic histologic features of ameloblastoma, and *ameloblastic carcinoma* (Figure 11-14), in which the lesions (primary and/or metastatic) exhibit less microscopic differentiation, showing cytologic atypia and mitotic figures. Malignant variants of ameloblastomas are difficult to control locally. Metastases may appear, usually in the lung, as a result of aspiration of tumor cells or by hematogenous spread after multiple unsuccessful attempts at primary tumor control. Regional lymph nodes are the second most common metastatic site, followed by the skull, liver, spleen, kidney, and skin.

The *primary intraosseous carcinoma* is an epithelial odontogenic malignancy of the mandible and maxilla that is believed to arise from odontogenic rests. This lesion does not have histologic features of ameloblastoma and is regarded as a primary jaw carcinoma. It does not arise from a preexisting odontogenic cyst. This rare lesion of adults affects men more than women, and it is seen in the mandible more than the maxilla. Microscopically, about half of these lesions exhibit keratin formation, and about half show peripheral palisading of epithelial cell nests. This lesion must be differentiated microscopically from acanthomatous ameloblastoma and squamous odontogenic tumor. The prognosis is poor, with a 2-year survival rate reported at 40%.

Another ameloblastoma that might be considered a subtype has been designated as *sinonasal ameloblastoma.* Mean age of 61 years and male dominance have been noted. Signs of nasal obstruction, epistaxis, and opacification are seen. The "totipotential" sinonasal lining cells are the putative cells of origin. A plexiform microscopic pattern is most commonly seen.

Histopathology. The numerous histologic patterns described for ameloblastoma are of no clinical relevance (Box 11-7). Some may exhibit a single histologic subtype, and others may display several histologic patterns within the same lesion. Common to all subtypes is the palisading of columnar cells around epithelial nests in a pattern similar to that of ameloblasts of the enamel organ. Central to these cells are loosely arranged cells that mimic the stellate reticulum of the enamel organ (Figure 11-15). Another typical feature is the budding of tumor cells from neoplastic foci in a pattern reminiscent of tooth development.

The microscopic subtype most commonly seen in solid ameloblastoma is the *follicular* type (Figure 11-16). It is

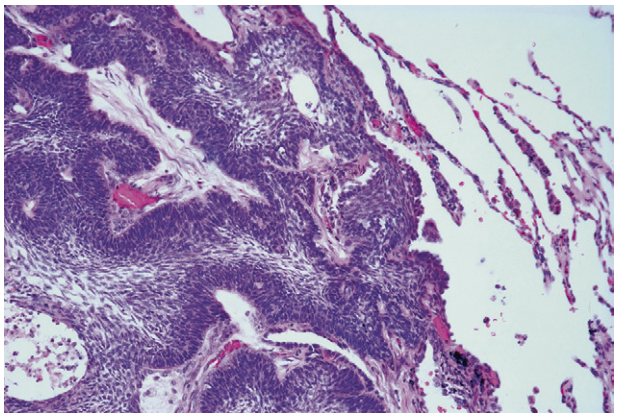

■ **FIGURE 11-13 Malignant ameloblastoma** in the lung (lung septa at *right*).

BOX 11-7 AMELOBLASTOMA: HISTOLOGIC SUBTYPES/PATTERNS

All subtypes mimic enamel organ
Peripheral palisades and budding
No hard tissue formation
No clinical significance to subtypes
Microscopic—desmoplastic, follicular, plexiform, granular cell, basaloid

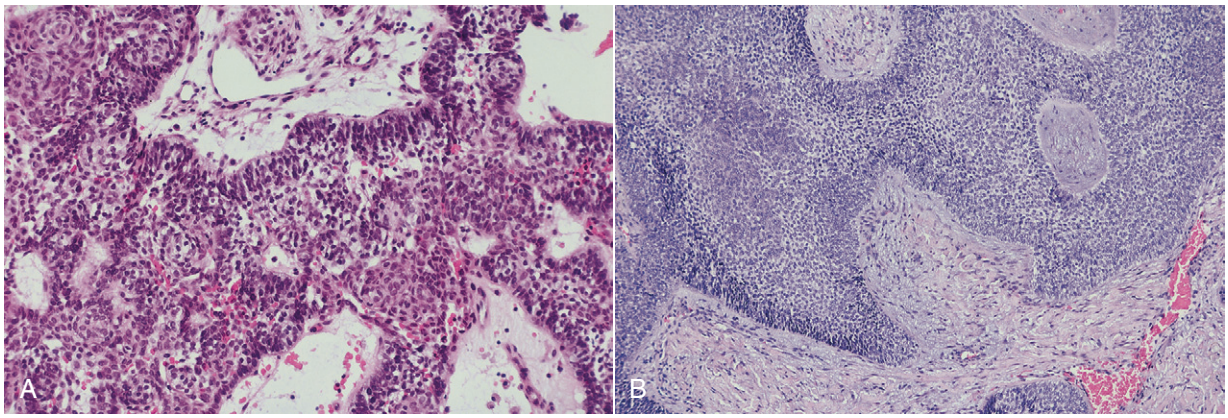

■ **FIGURE 11-14 A, Ameloblastic carcinoma** exhibiting cellular atypia and mitotic figures. **B,** Second recurrence of the lesion in **A.**

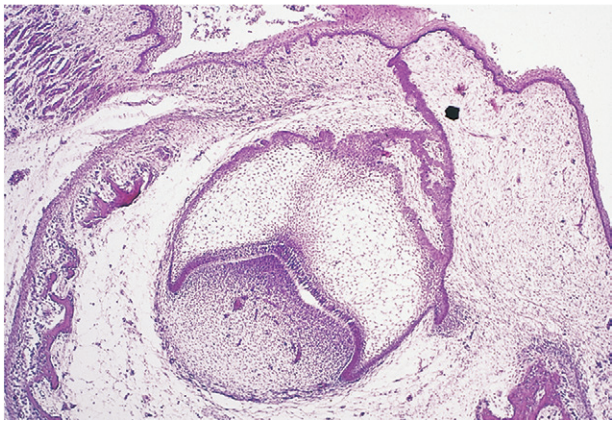

■ **FIGURE 11-15 Enamel organ** from mandible of a 22-week fetus. (Reproduced with permission from Regezi JA, Sciubba JJ, Pogrel MA: Atlas of Oral and Maxillofacial Pathology. Philadelphia, 2000, WB Saunders, Figure 7-5.)

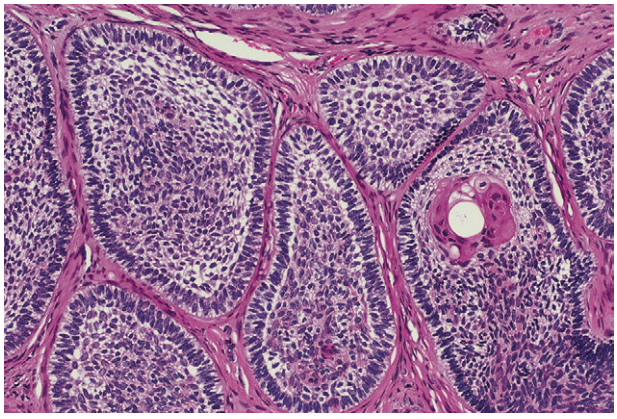

■ **FIGURE 11-16 Ameloblastoma,** follicular pattern.

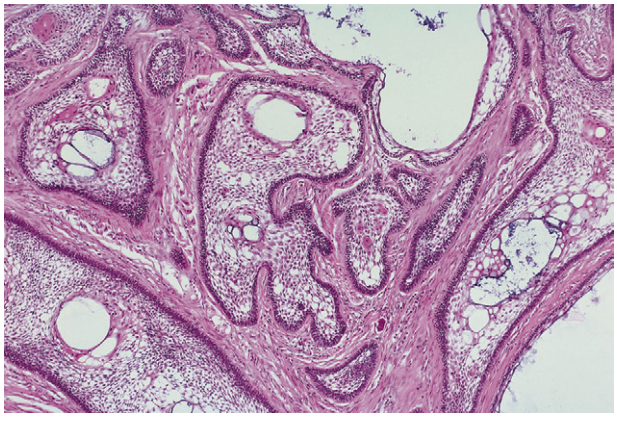

■ **FIGURE 11-17 Ameloblastoma,** follicular pattern with microcystic change.

composed of islands of tumor cells that mimic the normal dental follicle. Central cystic degeneration of follicular islands leads to a microcystic pattern (Figure 11-17). Neoplastic cells occasionally develop into a network of epithelium, prompting the term *plexiform ameloblastoma* (Figure 11-18). When the stroma is desmoplastic and the tumor

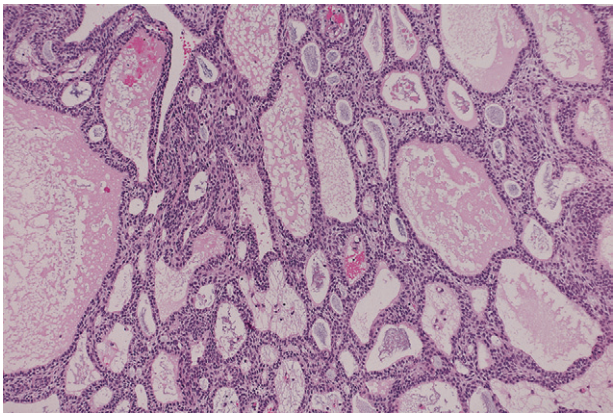

■ **FIGURE 11-18 Ameloblastoma,** plexiform pattern.

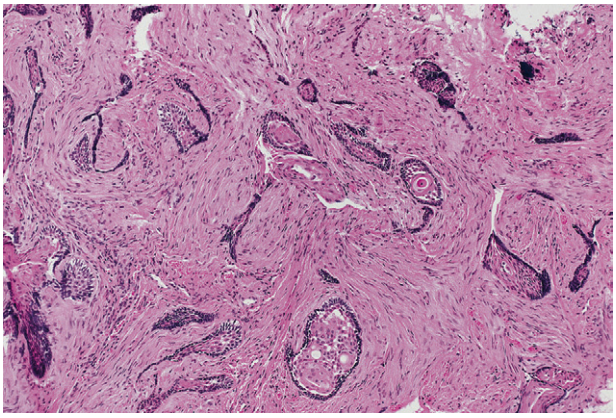

■ **FIGURE 11-19 Ameloblastoma,** desmoplastic type.

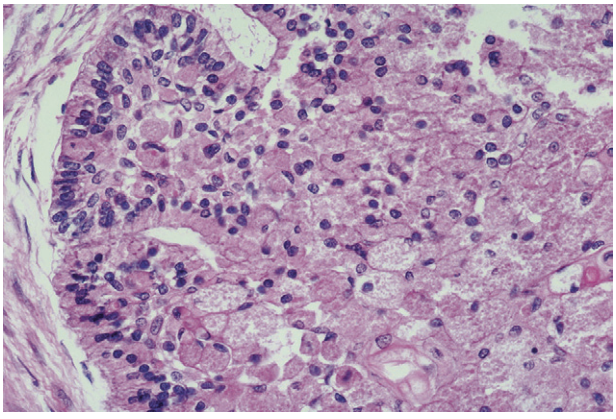

■ **FIGURE 11-20 Ameloblastoma** with granular cell change.

islands become squamous appearing (squamoid) or elongated, the term *desmoplastic ameloblastoma* is used (Figure 11-19). Some tumors are microscopically similar to basal cell carcinoma and are called *basal cell* or *basaloid ameloblastomas*. A type of solid ameloblastoma in which the central neoplastic cells exhibit prominent cytoplasmic granularity (and swelling) is known as *granular cell ameloblastoma* (Figure 11-20). Clear tumor cells and cells expressing ghost cell–type keratinization have also been seen in

ameloblastomas. Separation of ameloblastomas into the various microscopic groups described is essentially an academic exercise, because there appears to be no correlation between clinical behavior and these microscopic patterns.

Cystic ameloblastoma is a type of ameloblastoma that is primarily cystic in appearance; it is formed by a thin epithelial layer containing columnar basal cells with palisaded nuclei showing hyperchromasia and vacuolar change. Epithelial invagination into supporting connective tissue often occurs, and occasionally, mural islands may be seen. A characteristic spongiotic change is seen in the epithelial lining, and often subepithelial hyalinization represents odontogenic ectomesenchyme induction. Some lesions have an intraluminal component, usually in a plexiform pattern. Diagnosis is often retrospective after enucleation for what was thought to be an odontogenic cyst.

Differential Diagnosis. When age, location, and radiographic features are considered together, the clinical differential diagnosis generally can be limited to several entities in the three categories of jaw disease: odontogenic tumors, cysts, and benign nonodontogenic lesions. Among odontogenic tumors, the radiolucent form of the calcifying epithelial odontogenic tumor and odontogenic myxomas are prime considerations. The dentigerous cyst and the odontogenic keratocyst can also be included. In relatively young individuals, lesions that are radiographically similar to ameloblastoma include nonodontogenic lesions such as central giant cell granuloma, ossifying fibroma, central hemangioma, and possibly idiopathic histiocytosis.

Treatment and Prognosis. No single standard type of therapy can be advocated for patients with ameloblastoma. Rather, each case should be judged on its own merits. Prime considerations are whether the lesion is solid, cystic, extraosseous, or malignant, and its location. Solid ameloblastoma requires at least surgical excision, because recurrence follows curettage in 50% to 90% of cases. Block excision or resection followed by immediate surgical reconstruction generally is reserved for larger lesions. Cystic ameloblastomas may be treated less aggressively, but with the knowledge that recurrences are often associated with simple curettage. For cystic ameloblastoma, treatment options can range from enucleation to resection, although recurrences are more likely if enucleated. Peripheral ameloblastomas should be treated in a more conservative fashion. Malignant lesions should be managed as carcinomas. Patients with all forms of central ameloblastoma should be followed indefinitely because recurrences may be seen as long as 10 to 20 years after primary therapy. Ameloblastomas of the maxilla generally are more difficult to manage than those of the mandible because of anatomic relationships, as well as the comparatively higher content of cancellous bone compared with the mandible. Thus, intraosseous maxillary ameloblastomas are often excised with a wider normal margin than mandibular tumors.

BOX 11-8 CALCIFYING EPITHELIAL ODONTOGENIC TUMOR (PINDBORG TUMOR)

HISTOGENESIS
Unknown; may be dental lamina or stratum intermedium

CLINICAL FEATURES
Adults 30 to 50 years old
Posterior mandible favored

HISTOPATHOLOGY
Epithelioid strands/nests/sheets
Amyloid and calcification
Rare clear cell variant

BEHAVIOR
Benign; recurrence potential (<20%)

Radiotherapy has rarely been used in the treatment of ameloblastomas because it is generally believed that these tumors are radioresistant. Until more is known about tumor responsiveness, radiation should be reserved for exceptional cases that are difficult or impossible to control surgically.

Calcifying Epithelial Odontogenic Tumor (Pindborg Tumor)

Calcifying epithelial odontogenic tumor (CEOT), also known as *Pindborg tumor* after the oral pathologist who first described the entity, is a benign tumor of odontogenic origin that shares many clinical features with ameloblastoma (Box 11-8). Microscopically, however, there is no resemblance to ameloblastoma, and radiographically distinct differences will often be noted. The cells from which these tumors are derived are unknown, although dental lamina remnants and the stratum intermedium of the enamel organ have been suggested.

Clinical Features. CEOTs are seen in patients ranging in age from the second to the tenth decade, with a mean age of about 40 years. There is no gender predilection. The mandible is affected twice as often as the maxilla, and a predilection for the molar-ramus region has been noted, although any site may be affected (Figure 11-21). Peripheral lesions, usually in the anterior gingiva, account for less than 5% of cases.

Jaw expansion or incidental observation on a routine radiographic survey is the usual way in which these lesions are discovered. Radiographically, the lesions are often associated with impacted teeth. The lesions may be unilocular or multilocular. Small loculations in some lesions have prompted use of the term *honeycomb* to describe this lucent pattern. A CEOT may be completely radiolucent, or it may contain opaque foci—a reflection of the calcified amyloid

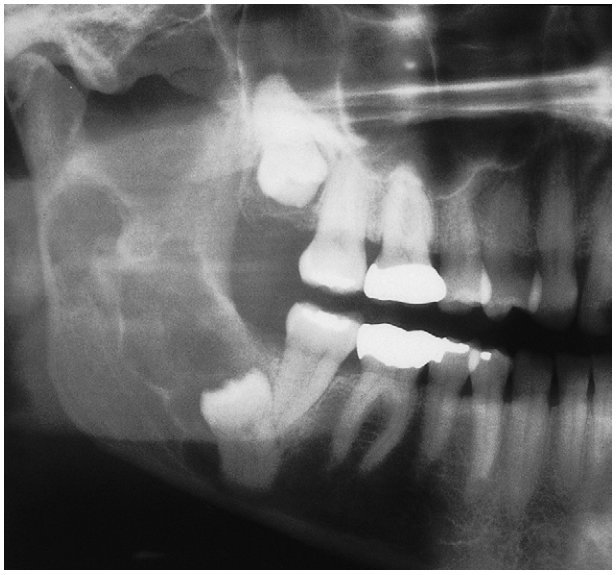

■ **FIGURE 11-21 Calcifying epithelial odontogenic tumor.** The multiloculated lesion extends from the third molar to the condyle. (Courtesy Dr. Bruce A. Shapton.)

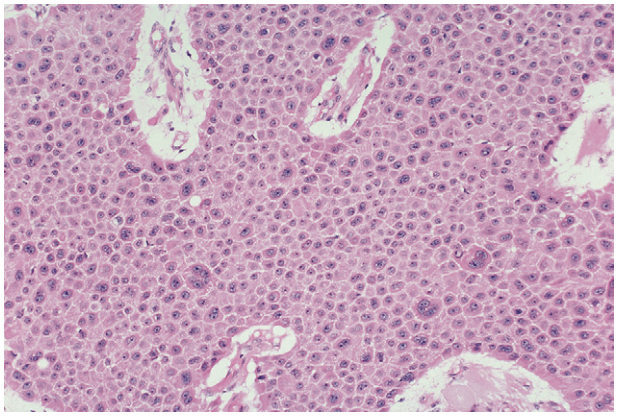

■ **FIGURE 11-22 Calcifying epithelial odontogenic tumor** composed of a sheet of atypical and multinucleated tumor epithelial cells.

seen microscopically. The lesions are usually well circumscribed radiographically, although sclerotic margins may not always be evident.

Histopathology. The CEOT has a unique and sometimes bizarre microscopic pattern. Large polygonal epithelial cells, arranged in sheets or islands, contain nuclei that show considerable variation in size and shape (Figure 11-22). Mitotic figures are rare. The cytoplasm is abundant and eosinophilic. Focal zones of clear cells occasionally can be seen in a so-called clear cell variant. Extracellular amyloid of epithelial origin is also typical of these tumors (Figures 11-23 and 11-24). This homogeneous, pale-staining eosinophilic material can be stained with Congo red or thioflavine T (Figure 11-25). Immunohistochemical staining for cytokeratins is also positive, suggesting that keratin proteins form an important component of the amyloid in this tumor. Unique to the CEOT, this type of amyloid has been found to contain a 153-residue protein encoded by a specific gene *(FLJ20513)* of the odontogenic ameloblast–associated protein locus. Concentric calcific deposits with a characteristic annular staining pattern (Liesegang rings), seen in the amyloid material, are responsible for radiopacities when sufficiently dense.

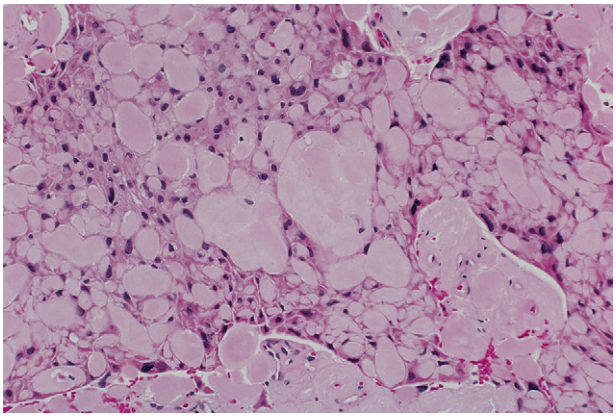

■ **FIGURE 11-23 Calcifying epithelial odontogenic tumor** showing amyloid deposits.

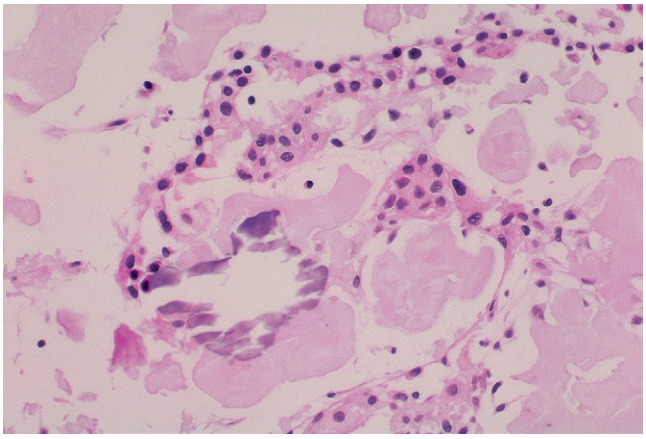

■ **FIGURE 11-24 Calcifying epithelial odontogenic tumor** showing nuclear atypia, amyloid, and calcification.

Differential Diagnosis. When this lesion is radiolucent, it must be separated clinically from dentigerous cyst, odontogenic keratocyst, ameloblastoma, and odontogenic myxoma. Some benign nonodontogenic jaw tumors might also be considered, but these would be less likely, on the basis of age and location.

When a mixed radiolucent-radiopaque pattern is encountered, calcified odontogenic cyst should be considered in a clinical differential diagnosis. Other, less likely possibilities include adenomatoid odontogenic tumor, ameloblastic fibro-odontoma, ossifying fibroma, and osteoblastoma.

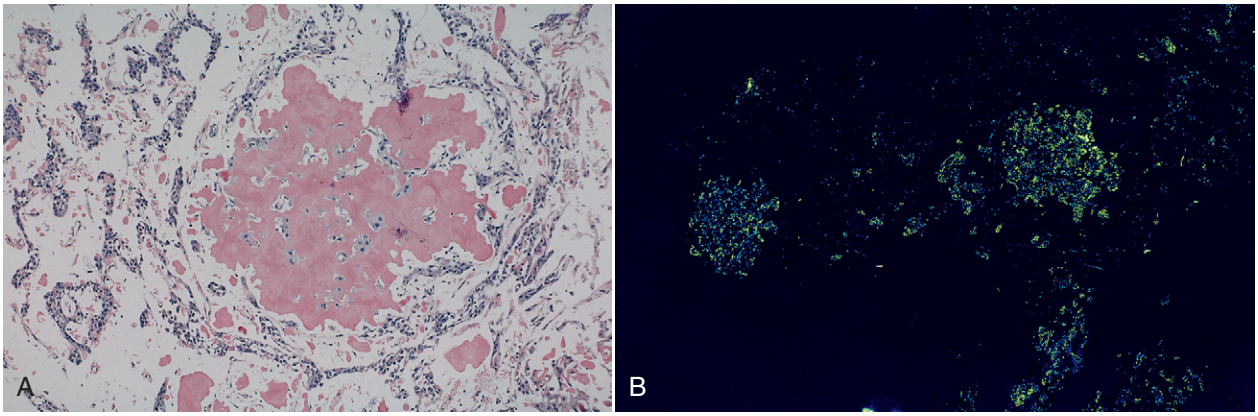

■ **FIGURE 11-25 Calcifying epithelial odontogenic tumor. A,** Congo red stain. **B,** Congo red stain viewed through polarized light. Amyloid is apple green.

BOX 11-9 ADENOMATOID ODONTOGENIC TUMOR

- Epithelial odontogenic hamartoma containing pseudoducts and enameloid
- Tumor of "two-thirds" maxilla, females, anterior jaws, crown of impacted tooth
- Teenagers most commonly affected; rarely seen over the age of 30 years
- Lucent and lucent-opaque patterns
- Treatment by enucleation; no recurrences

Treatment. This tumor has a locally infiltrative potential but apparently not to the same extent as ameloblastoma. It is slow-growing and causes morbidity through direct tumor extension. Various forms of surgery, ranging from enucleation to resection, have been used to treat CEOTs. The overall recurrence rate has been less than 20%, indicating that aggressive surgery is not indicated for the management of most of these benign neoplasms. Very rare examples of malignant transformation of this tumor have been reported and are associated with loss of *p53* transcriptional activity. Metastases have not been reported.

Adenomatoid Odontogenic Tumor

Adenomatoid odontogenic tumor (AOT) was formerly termed *adenoameloblastoma* because it was believed to be a subtype of ameloblastoma that contains ductlike or glandlike structures. Clinically, microscopically, and behaviorally, it is clearly different from ameloblastoma, and the term *adenoameloblastoma* is not used (Box 11-9).

Clinical Features. AOTs are seen in a rather narrow age range—between 5 and 30 years—with most cases appearing in the second decade. Females are more commonly affected than males. Lesions often appear in the anterior portion of the jaws, more often in the anterior maxilla, generally in association with the crowns of impacted teeth (Figure 11-26). Three variants of this tumor have been identified: follicular (73% of cases), extrafollicular (24%), and peripheral (3%).

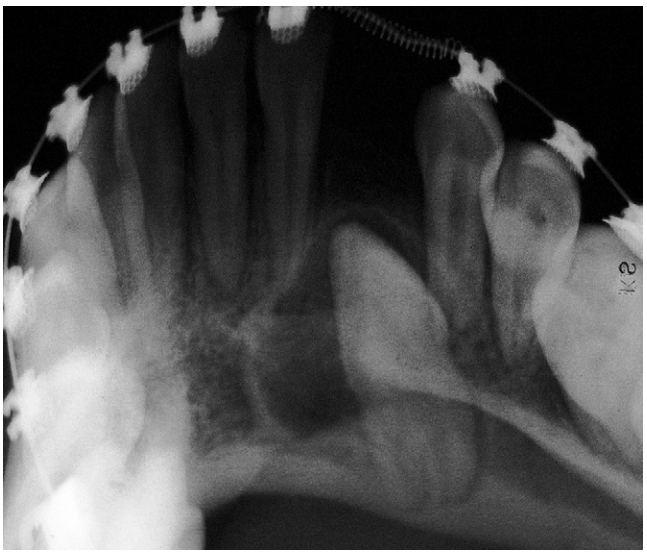

■ **FIGURE 11-26 Adenomatoid odontogenic tumor** surrounding the crown of an impacted tooth.

Radiographically, the follicular AOT is a well-circumscribed unilocular lesion that usually appears around the crown of an impacted tooth; the extrafollicular type usually presents as a well-defined unilocular radiolucency above, between, or superimposed over the roots of an unerupted tooth. Lesions typically are radiolucent but may have small opaque foci distributed throughout, reflecting the presence of calcifications in the tumor tissue (Figure 11-27). When they are located between anterior teeth, divergence of roots may be seen. The peripheral type is characterized by a painless, nontender gingival swelling.

Histopathology. An intracystic epithelial proliferation is composed of polyhedral to spindle cells. The pattern typically is lobular, although some areas may show a syncytial arrangement of cells. Rosettes and ductlike structures of columnar epithelial cells give the lesion its characteristic microscopic features (Figures 11-28 and 11-29). Foci of periodic acid–Schiff (PAS)-positive material are scattered throughout the lesion. The number, size, and degree of calcification of these foci determine how the lesion presents radiographically.

Differential Diagnosis. Other lesions that might be included in a differential diagnosis of AOT are dentigerous cyst (because of frequent association with impacted teeth) and lateral periodontal cyst (because of its occasional location adjacent to roots of anterior teeth). If opacities are evident, calcifying odontogenic cyst and CEOT should receive consideration.

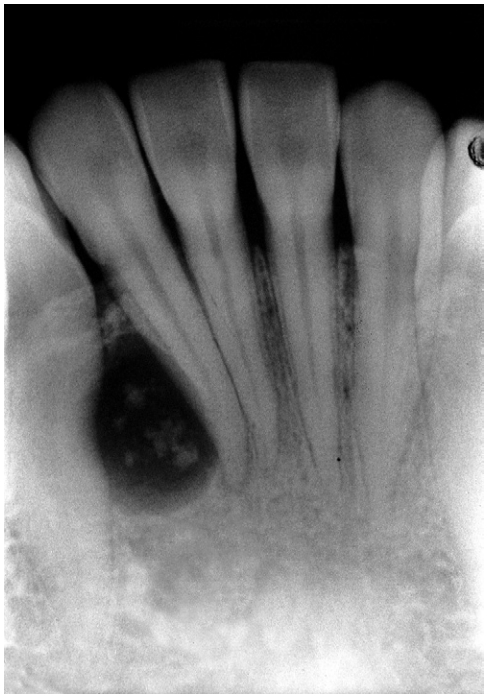

■ **FIGURE 11-27 Adenomatoid odontogenic tumor** with opaque foci.

Treatment. Conservative treatment (enucleation) is all that is required. AOTs are benign, encapsulated lesions that do not recur.

Squamous Odontogenic Tumor

Because squamous odontogenic tumor involves the alveolar process, the lesion is believed to be derived from neoplastic transformation of the rests of Malassez. It occurs in the mandible and the maxilla with equal frequency, favoring the anterior region of the maxilla and the posterior region of the mandible. Multiple lesions have been described in about 20% of affected patients, as have familial multicentric lesions.

The age range for this tumor extends from the second through seventh decades, with a mean age of 40 years. There is no gender predilection. Patients usually experience no symptoms, although tenderness and tooth mobility have been reported. Radiographically, this lesion typically is a well-circumscribed, often semilunar lesion associated with the cervical region of roots of teeth. Microscopically, it has some similarity to ameloblastoma, although it lacks the columnar peripherally palisaded layer of epithelial cells (Figure 11-30). Although proliferation is robust, some similarity to proliferating odontogenic rests has been noted.

Squamous odontogenic tumors have some invasive capacity and infrequently recur after conservative therapy. Curettage or excision is the treatment of choice.

Clear Cell Odontogenic Tumor (Carcinoma)

Clear cell odontogenic tumor (carcinoma) is a rare neoplasm of the mandible and maxilla (Box 11-10). The origin is unknown, but the location and histologic appearance of

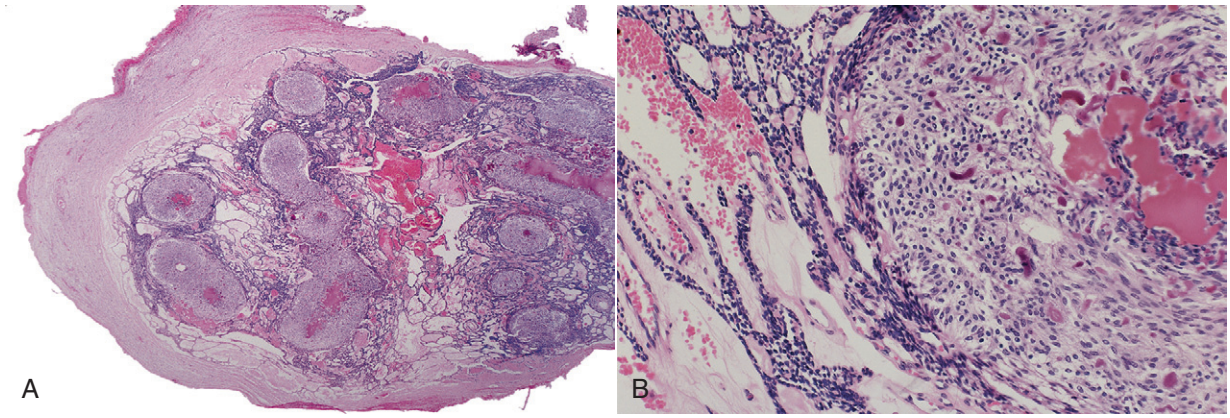

■ **FIGURE 11-28 Adenomatoid odontogenic tumor. A** and **B,** Characteristic thick capsule and intraluminal nodular proliferation. Note calcified material in **B** *(right)*.

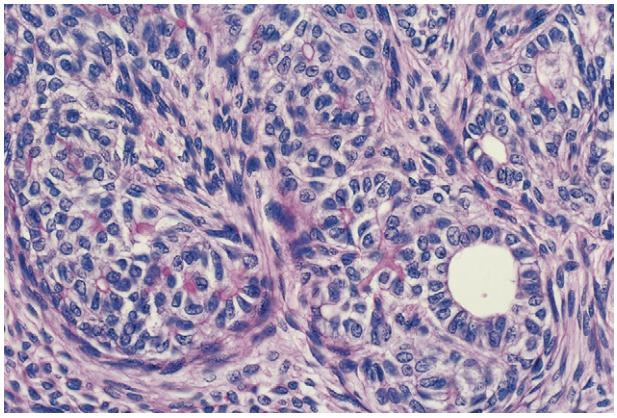

■ **FIGURE 11-29 Adenomatoid odontogenic tumor** exhibiting pseudoducts and rosettes.

BOX 11-10 CLEAR CELL ODONTOGENIC TUMOR

HISTOGENESIS
Unknown; probably odontogenic

CLINICAL FEATURES
Age over 60 years; women affected more often than men
Either jaw
Occasionally painful

HISTOPATHOLOGY
Nests/cords of clear cells, some palisades
Some glycogen; mucin negative

MICROSCOPIC DIFFERENTIAL DIAGNOSIS
Calcifying epithelial odontogenic tumor
Mucoepidermoid carcinoma
Renal cell carcinoma

BEHAVIOR
Recurrence and metastasis (neck nodes/lung)

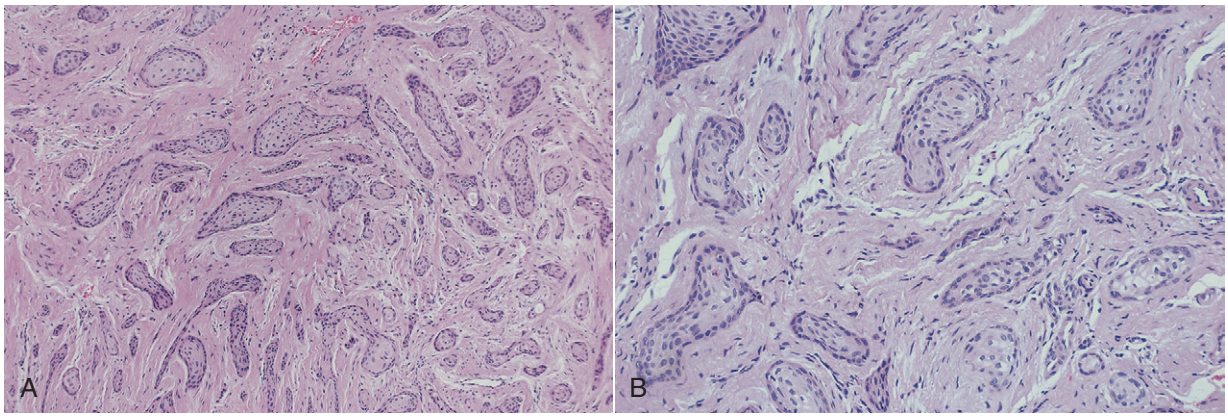

■ **FIGURE 11-30 Squamous odontogenic tumor. A** and **B,** Bland proliferation of squamous islands.

this lesion suggest an odontogenic source. Usually found in women older than 60 years, it is a locally aggressive, poorly circumscribed neoplasm composed of sheets of cells with relatively clear cytoplasm (Figure 11-31). The rate of recurrence may be as high as 50%. Metastases to lung and to regional lymph nodes have been reported. The microscopic differential diagnosis includes other jaw tumors that may have a clear cell component, such as CEOT, central mucoepidermoid carcinoma, metastatic acinic cell carcinoma, metastatic renal cell carcinoma, hyalinizing clear cell carcinoma, and ameloblastoma. Stains often need to be performed to rule out other local clear cell carcinomas that produce mucin or glycogen, and a metastatic survey needs to be done to exclude clear cell malignancies from other sites in the body.

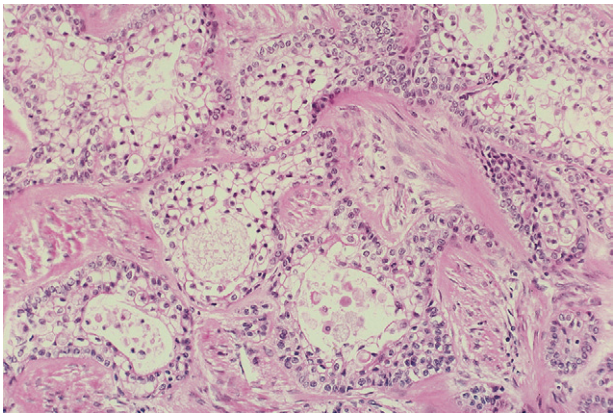

■ **FIGURE 11-31 Clear cell odontogenic tumor** as nests of odontogenic epithelium with relatively clear cytoplasm.

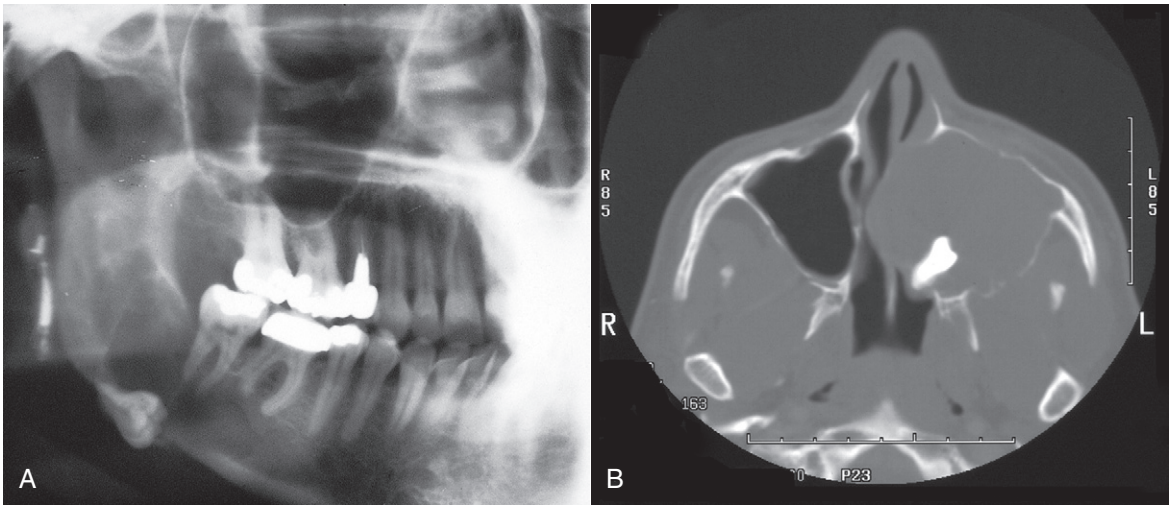

■ **FIGURE 11-32 A, Odontogenic myxoma** of the right mandible. Note malpositioned third molar. **B,** Odontogenic myxoma of the maxilla with a widely expansile quality containing an impacted tooth.

BOX 11-11 ODONTOGENIC MYXOMA (FIBROMYXOMA)

HISTOGENESIS
Periodontal ligament or dental pulp

CLINICAL FEATURES
Adults (median age, about 30 years)
Either jaw

HISTOPATHOLOGY
Bland myxoid
Rare epithelial rests
Variable amounts of collagen

MICROSCOPIC DIFFERENTIAL DIAGNOSIS
Hyperplastic follicular sac and dental pulp
Odontogenic fibroma
Desmoplastic fibroma

BEHAVIOR
Recurrences
No capsule and loose tumor consistency

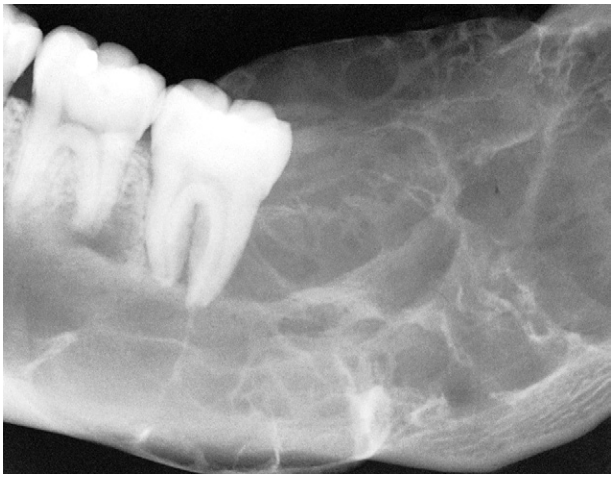

■ **FIGURE 11-33 Odontogenic myxoma** showing characteristic multilocularity.

MESENCHYMAL TUMORS

Odontogenic Myxoma

Odontogenic myxoma is a benign mesenchymal lesion that mimics microscopically the dental pulp or follicular connective tissue. It is a relatively common odontogenic tumor, representing 1% to 17% of all tumor types. Although myxomas are noted at various sites of the body, including the dermis, heart (left atrium), and other head and neck sites, only odontogenic myxoma of the jaws is derived from odontogenic ectomesenchyme. This benign neoplasm is infiltrative and may recur after inadequate treatment (Box 11-11).

Clinical Features. The age range in which this lesion appears extends from 10 to 50 years, with a mean of about 30 years. There is no gender predilection, and the lesions are seen anywhere in the mandible and maxilla with about equal frequency (Figure 11-32).

Radiographically, this lesion is always lucent, although the pattern may be quite variable. It may appear as a well-circumscribed or diffuse lesion. It often is multilocular with a honeycomb pattern (Figure 11-33). Other radiographic

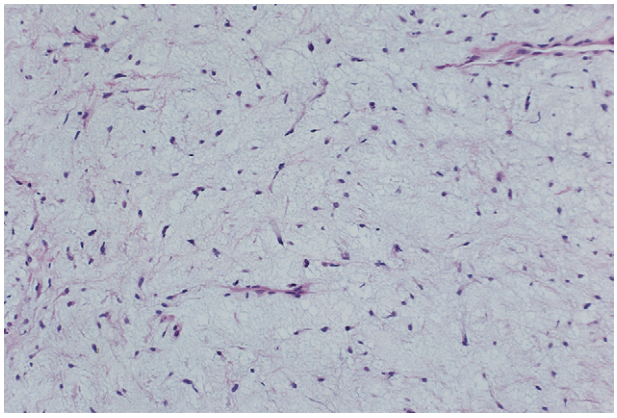

■ **FIGURE 11-34 Odontogenic myxoma** exhibiting typical bland myxoid appearance.

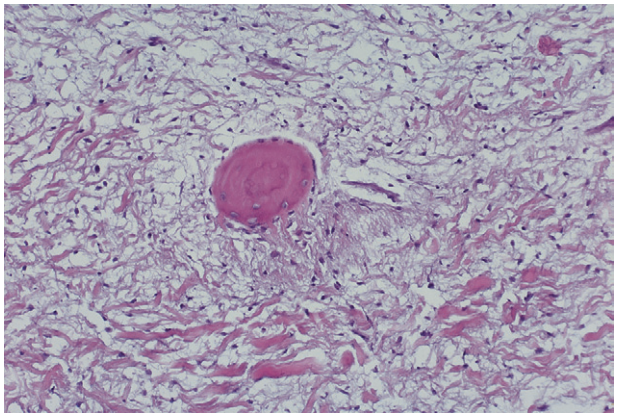

■ **FIGURE 11-35 Odontogenic fibromyxoma** with collagen bundles and residual bony trabecula *(center)* evident.

patterns and descriptors include "honeycomb," "soap bubble," or "tennis racket." Cortical expansion or perforation and root displacement or resorption may be seen.

Histopathology. This tumor is composed of bland, relatively acellular myxomatous connective tissue (Figure 11-34). Benign fibroblasts and myofibroblasts with variable amounts of collagen are found in a mucopolysaccharide matrix. Bony islands, representing residual trabeculae, and capillaries are found scattered throughout the lesion (Figure 11-35). Odontogenic rests typically are absent in these tumors and are not required for the diagnosis. Odontogenic myxomas have a very low proliferation rate. However, they express some antiapoptotic proteins, which, in part, may explain their persistence. Myxomatous follicular sacs with odontogenic rests should not be confused with this neoplasm (Figure 11-36). When relatively large amounts of collagen are evident, the term *odontogenic fibromyxoma* may be used.

Differential Diagnosis. The clinical differential diagnosis is essentially the same as that described for ameloblastoma. In addition, central hemangioma is a serious consideration

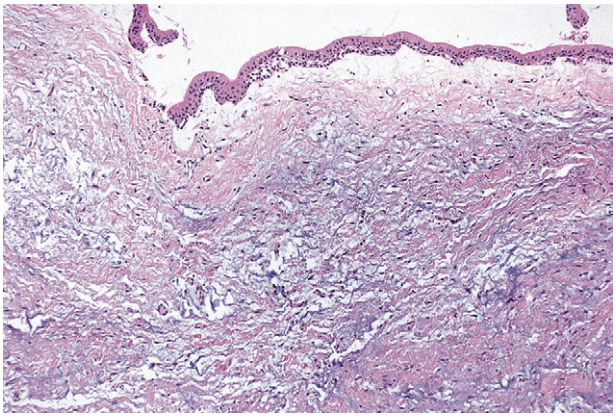

■ **FIGURE 11-36 Follicular sac** with myxomatous change. Note residual reduced enamel epithelium at top.

for a lesion with a honeycomb radiographic appearance. An important note is that the microscopic differential diagnosis should include developing dental pulp and hyperplastic follicular connective tissue surrounding a developing or mature impacted tooth. Nerve sheath myxoma might be considered, although this entity is rare in the jaws. Odontogenic myxoma do not express neural proteins. Clinical pathologic correlation is important in the definitive diagnosis of odontogenic myxoma.

Treatment. Surgical excision is the treatment of choice. Because of its classical loose, gelatinous consistency, curettage usually results in incomplete removal of the neoplasm. Absence of encapsulation may contribute to recurrence if the lesion is treated too conservatively. Although these lesions exhibit some aggressiveness and have a moderate recurrence rate, the prognosis is very good. Repeated surgical procedures do not appear to stimulate growth or metastasis. Follow-up examinations should be performed for a minimum of 5 years.

Central Odontogenic Fibroma

Central odontogenic fibroma is a rare ectomesenchymal tumor that is regarded as the central counterpart to peripheral odontogenic fibroma (Box 11-12). It has been seen in all age groups and is found in both the mandible and the maxilla, with a 2:1 female predilection (Figure 11-37). It results in a radiolucent lesion that usually is multilocular, often causing cortical expansion. Approximately 45% of cases occur anterior to the first molar region of the maxilla, often with a cortical bony depression of the palatal contour. The clinical differential diagnosis is similar to that described for ameloblastoma.

Microscopically, two patterns generally are ascribed to central odontogenic fibroma (Figure 11-38). In the simple or epithelium-poor type, the lesion is composed of a mass of mature fibrous tissues containing few epithelial rests. In the complex (World Health Organization [WHO]) type, mature

BOX 11-12 CENTRAL ODONTOGENIC FIBROMA

HISTOGENESIS
Origin unknown; may be from periodontal ligament or dental pulp

CLINICAL FEATURES
Adults
Well-defined lucency

HISTOPATHOLOGY
Collagenous with epithelial strands

MICROSCOPIC DIFFERENTIAL DIAGNOSIS
Desmoplastic fibroma
Fibromyxoma
Hyperplastic follicular sac

BEHAVIOR
Few recurrences



■ **FIGURE 11-37 Central odontogenic fibroma** of the right maxilla.

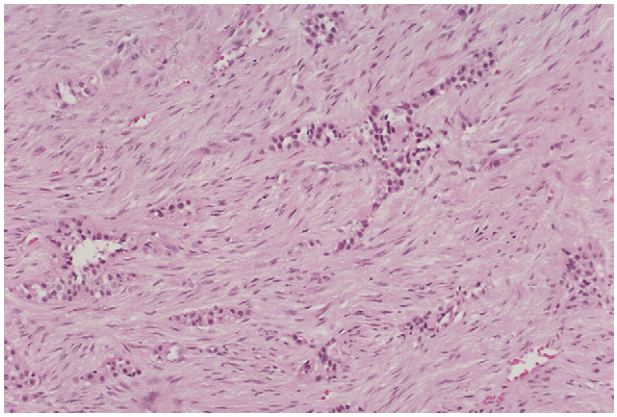

■ **FIGURE 11-38 Central odontogenic fibroma** containing strands of odontogenic epithelium.

BOX 11-13 CEMENTOBLASTOMA

Benign fibro-osseous/cementum jaw lesion
Young adults, mandible > maxilla
Attached to and replaces tooth root
Periodontal ligament space surrounds lesion
Opaque mass; may rarely cause cortical expansion
Histologic features of osteoblastoma
Attached to tooth; tooth removed with lesion
No recurrence

>, More frequently affected than.

connective tissue contains an abundant odontogenic epithelial component in the form of rests, along with calcified deposits of what is regarded as dentin or cementum. This microscopic differentiation may be academic, in that there appears to be no difference in clinical behavior between the two subtypes. A microscopic differential diagnosis would include *desmoplastic fibroma* (the bony counterpart of fibromatosis). This purely fibrous connective tissue lesion may be difficult to separate from central odontogenic fibroma because of overlapping microscopy. Clinical correlation should help because desmoplastic fibroma would exhibit a more aggressive and recurrent behavior. The tumor has been reported to be associated with giant cell granuloma–like lesions. Treatment of odontogenic fibroma is enucleation or excision, and recurrence is very uncommon. An exception in terms of recurrence potential is the odontogenic fibroma with a central giant cell lesion component, in which a 23% rate of recurrence has been reported.

Cementifying Fibroma

See discussion of ossifying fibroma in Chapter 12.

Cementoblastoma

Clinical Features. Cementoblastoma, also known as true cementoma, is a rare benign neoplasm of cementoblasts that microscopically resembles an osteoblastoma but is connected or fused to the root of a tooth (Box 11-13). It occurs predominantly in the second and third decades of life, typically before 25 years of age. There is no gender predilection. It is seen more often in the mandible than in the maxilla and more often in posterior than in anterior regions. It is intimately associated with the root of a tooth, and the tooth remains vital. Cementoblastoma may cause cortical expansion and, occasionally, low-grade intermittent pain.

Radiographically, this neoplasm is an opaque lesion that replaces the root of the tooth (Figure 11-39). It usually is surrounded by a thick and uniform radiolucent ring that is contiguous with the periodontal ligament space and the advancing front of the tumor.

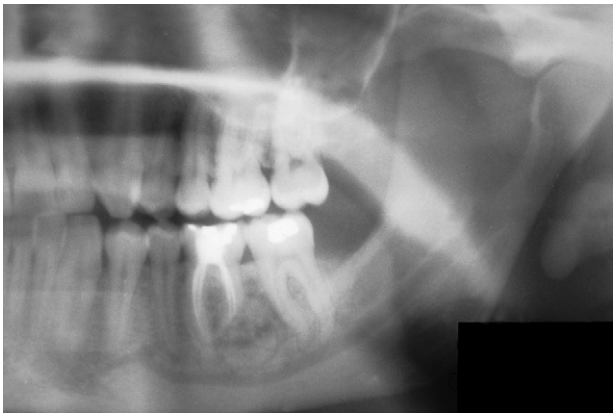

■ **FIGURE 11-39 Cementoblastoma** around the roots of a mandibular first molar.

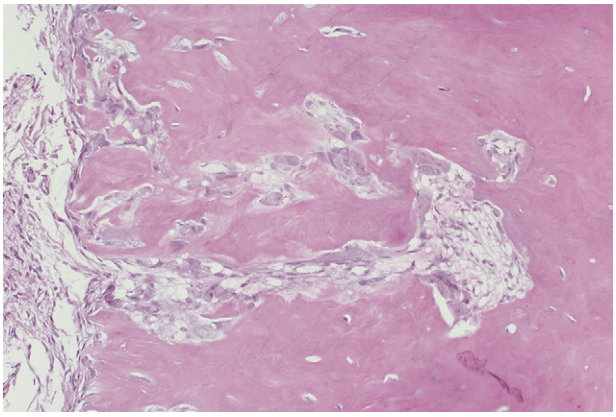

■ **FIGURE 11-40 Cementoblastoma** with a periphery showing numerous pale cementoblasts *(left)* against a dense network of cementum.

Histopathology. This lesion appears microscopically as a dense mass of mineralized cementum-like material with numerous reversal lines (Figure 11-40). Intervening well-vascularized soft tissue contains cementoblasts—often numerous, large, and hyperchromatic. The histologic features are similar if not identical to those of an osteoblastoma but with attachment to a tooth root.

Differential Diagnosis. The characteristic radiographic appearance of this lesion is usually diagnostic. Other opaque lesions that share some features include odontoma, osteoblastoma, focal sclerosing osteomyelitis, and hypercementosis.

Treatment. Because of the intimate association of this neoplasm with the tooth root, it cannot be removed without sacrificing the tooth by way of a surgical extraction procedure. Bone relief typically is required to remove this well-circumscribed mass. Recurrence is not seen.

BOX 11-14 PERIAPICAL CEMENTO-OSSEOUS DYSPLASIA

CLINICAL FEATURES
Reactive, unknown stimulus, teeth vital
Common in anterior mandible of adults
No symptoms
Progresses from lucent to opaque lesion
Exuberant variant—florid cemento-osseous dysplasia

HISTOPATHOLOGY
Fibro-osseous lesion
Mature and immature bone
Heterogeneous pattern
Few inflammatory cells

OTHER
No treatment
Clinical radiographic correlation is diagnostic

Periapical Cemento-osseous Dysplasia

As the name implies, periapical cemento-osseous dysplasia represents a reactive or dysplastic process, rather than a neoplastic one. This lesion appears to be an unusual response of periapical bone and cementum to some undetermined local factor (Box 11-14). Populations most at risk include East Asians and those of African origin. When not associated with a tooth apex, the term *focal cemento-osseous dysplasia* is used.

Clinical Features. This relatively common phenomenon occurs at the apex of vital teeth. A biopsy is unnecessary because the condition is usually diagnostic by clinical and radiographic features. Women, especially black women, are affected more than men. Periapical cemento-osseous dysplasia appears in middle age (~40 years) and rarely before the age of 20. The mandible, especially the anterior periapical region, is far more commonly affected than other areas. Often, the apices of two or more teeth are affected.

This condition typically is discovered on routine radiographic examination because patients are asymptomatic. It appears first as a periapical lucency that is continuous with the periodontal ligament space. Although this initial pattern simulates radiographically a periapical granuloma or cyst, the teeth are always vital. As the condition progresses or matures, the lucent lesion develops into a mixed or mottled pattern because of bone repair. In its final stage, the tumor appears as a solid, opaque mass that often is surrounded by a thin, lucent ring. This process takes months to years to reach the final stages of development and, obviously, may be discovered at any stage (Figures 11-41 to 11-43).

A related but less common condition is known as *florid cemento-osseous dysplasia (FCOD)* (Box 11-15; Figures 11-44 and 11-45). No cause is apparent and patients are



■ **FIGURE 11-41 Periapical cemento-osseous dysplasia,** radiolucent phase.

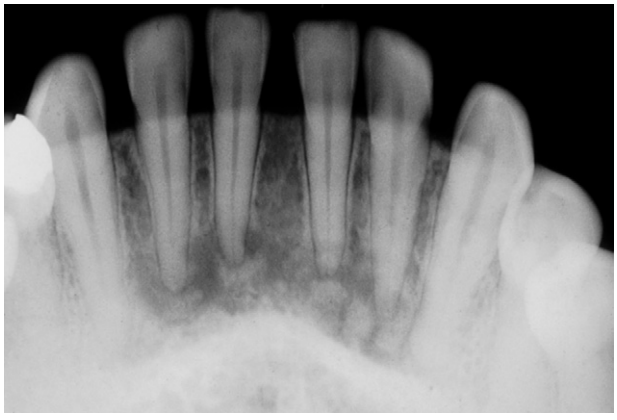

■ **FIGURE 11-42 Periapical cemento-osseous dysplasia,** radiopaque phase.



■ **FIGURE 11-43 Periapical cemento-osseous dysplasia** associated with a molar tooth.

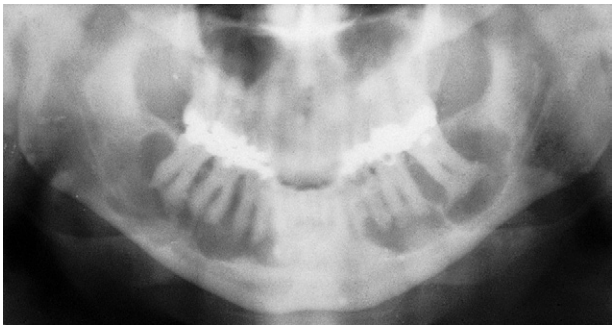

■ **FIGURE 11-44 Florid cemento-osseous dysplasia** of the mandible.

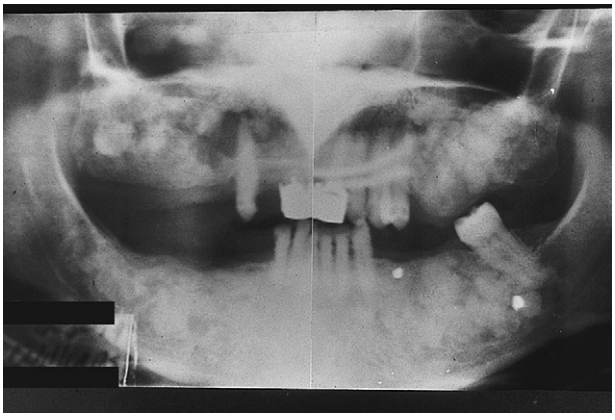

■ **FIGURE 11-45 Florid cemento-osseous dysplasia** of the mandible and maxilla. (Reproduced with permission from Regezi JA, Sciubba JJ, Pogrel MA: Atlas of Oral and Maxillofacial Pathology. Philadelphia, 2000, WB Saunders, Figure 7-62.)

BOX 11-15 FLORID CEMENTO-OSSEOUS DYSPLASIA

Exuberant variant of periapical cement-osseous dysplasia
Large lucency with opaque zones
Predominantly mandible in adults
Confused clinically with diffuse sclerosing osteomyelitis
Asymptomatic unless secondarily infected
Teeth are vital
Diagnosis from clinical radiographic correlation
No treatment unless secondarily infected

asymptomatic, except when the complication of osteomyelitis occurs. Women, especially black women, are predominantly affected, usually between 25 and 60 years of age. The condition typically is bilateral and may affect all four quadrants. A curious finding has been the concomitant appearance of traumatic (simple) bone cysts in affected tissue. Radiographically, FCOD appears as diffuse radiopaque masses throughout the alveolar segment of the jaws. A ground-glass or cystlike appearance may be seen.

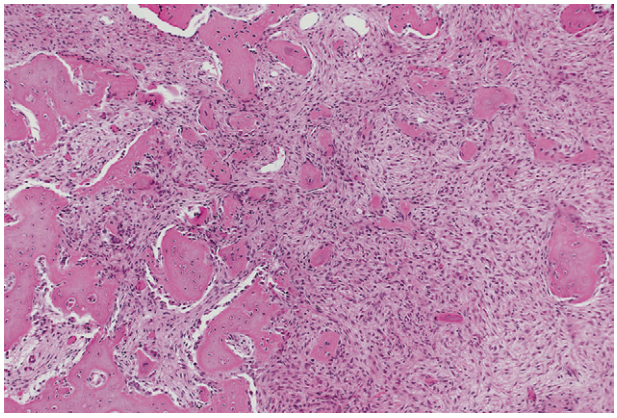

■ **FIGURE 11-46 Periapical cemento-osseous dysplasia.** This lesion has a heterogeneous benign fibro-osseous appearance.

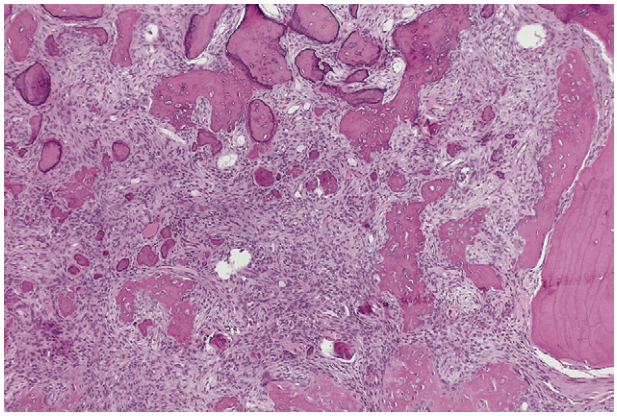

■ **FIGURE 11-47 Florid cemento-osseous dysplasia.** This lesion has a heterogeneous benign fibro-osseous appearance.

Histopathology. Periapical cemento-osseous dysplasia represents a mixture of benign fibrous tissue, bone, and cementum (Figure 11-46). Calcified tissue is arranged in trabeculae, spicules, or larger irregular masses. Reversal lines eventually are seen, and osteoblasts, cementoblasts, or both line the islands of hard tissue. Chronic inflammatory cells may also be seen. Microscopically, periapical cemento-osseous dysplasia may appear very similar to chronic osteomyelitis and ossifying fibroma.

Microscopically, FCOD is a heterogeneous lesion consisting of a benign fibrous stroma that contains irregular trabeculae of mature and immature bone and cementum-like material (Figure 11-47). Because FCOD is an asymptomatic, self-limited process, no treatment is required. In cases in which secondary infection occurs, antibiotics and sequestrectomy may be necessary.

Differential Diagnosis. Age, gender, location, radiographic appearance, and tooth vitality considered together are diagnostic of this condition. When one or more of these factors are atypical, diagnostic considerations include chronic osteomyelitis, ossifying fibroma, and periapical granuloma or cyst. In the opaque stage, odontoma, osteoblastoma, and focal sclerosing osteomyelitis are diagnostic possibilities.

The clinical differential diagnosis of FCOD includes diffuse sclerosing osteomyelitis, Paget's disease, and familial gigantiform cementoma. Paget's disease can be ruled out with biopsy and determination of serum alkaline phosphatase (elevated in Paget's disease, normal in FCOD). Chronic diffuse sclerosing osteomyelitis would be symptomatic and would have a different radiographic appearance. Also, inflammatory cells would be evident in biopsy tissue.

Treatment. No treatment is required for periapical cemento-osseous dysplasia or FCOD. Once the opaque stage is reached, the lesion usually stabilizes and causes no complications. Because teeth remain vital throughout the entire process, they should not be extracted, and endodontic procedures should not be performed.

BOX 11-16 AMELOBLASTIC FIBROMA/ FIBRO-ODONTOMA

Occurs in children and teenagers
Often associated with an impacted tooth
Composed of neoplastic epithelium and neoplastic myxomatous connective tissue
Treatment by curettage or excision
Excellent prognosis; rarely recurs
Malignant counterpart is rare

MIXED (EPITHELIAL AND MESENCHYMAL) TUMORS

Ameloblastic Fibroma and Ameloblastic Fibro-odontoma

Ameloblastic fibroma and ameloblastic fibro-odontoma are considered together because they appear to be slight variations of the same benign neoplastic process (Box 11-16). Except for the presence of an odontoma, people afflicted with either of these two lesions share similar features of age, gender, and location. The biological behaviors of these lesions are also similar. Both are benign mixed odontogenic tumors composed of neoplastic epithelium and mesenchyme with microscopically identical soft tissue components.

Clinical Features. These neoplasms occur predominantly in children and young adults. The mean age is about 12 years, and the upper age limit is around 40 years. The mandibular molar-ramus area is the favored location for these lesions, although they may appear in any region. There is no gender predilection.

Radiographically, these lesions are well circumscribed and usually are surrounded by a sclerotic margin (Figures 11-48 and 11-49). They may be unilocular or multilocular

and may be associated with the crown of an impacted tooth. An opaque focus that appears within the ameloblastic fibro-odontoma is due to the presence of an odontoma. This lesion therefore appears as a combined lucent-opaque lesion; the ameloblastic fibroma is completely lucent radiographically.



■ **FIGURE 11-48 Ameloblastic fibroma** of the left mandible. The lesion is a well-circumscribed lucency.



■ **FIGURE 11-49 Ameloblastic fibro-odontoma** as represented in the right molar-ramus area of this skull radiograph. Note odontoma between impacted teeth.

Histopathology. These lesions are lobulated in general configuration and usually are surrounded by a fibrous capsule. The tumor mass is composed predominantly of primitive-appearing myxoid connective tissue (Figures 11-50 and 11-51). The general absence of collagen gives this component a resemblance to dental pulp. Evenly distributed throughout the tumor mesenchyme are ribbons or strands of odontogenic epithelium that typically are two cells wide. Rarely, the epithelium may be more follicular in appearance, resembling ameloblastoma. The epithelial component has been compared microscopically to the dental lamina that proliferates from oral epithelium in the early stages of tooth development.

In ameloblastic fibro-odontoma, one or more foci contain enamel and dentin. This may be seen in the form of a compound or complex odontoma, the presence of which does not alter treatment or prognosis (Figure 11-52).

Differential Diagnosis. When ameloblastic fibroma (fibro-odontoma) presents with the clinical features (age, location) and radiographic pattern that are typical for these

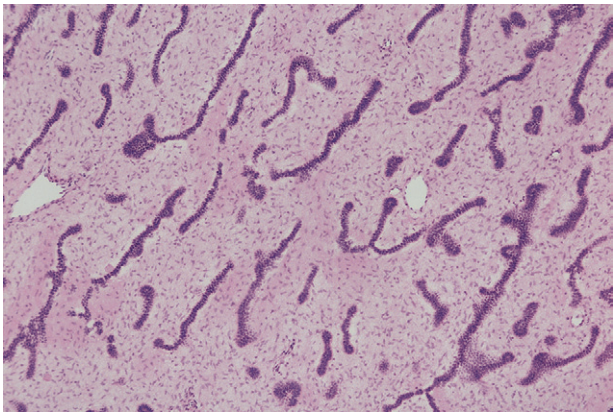

■ **FIGURE 11-50 Ameloblastic fibroma** composed of pale myxoid stroma with numerous strands of odontogenic epithelium.

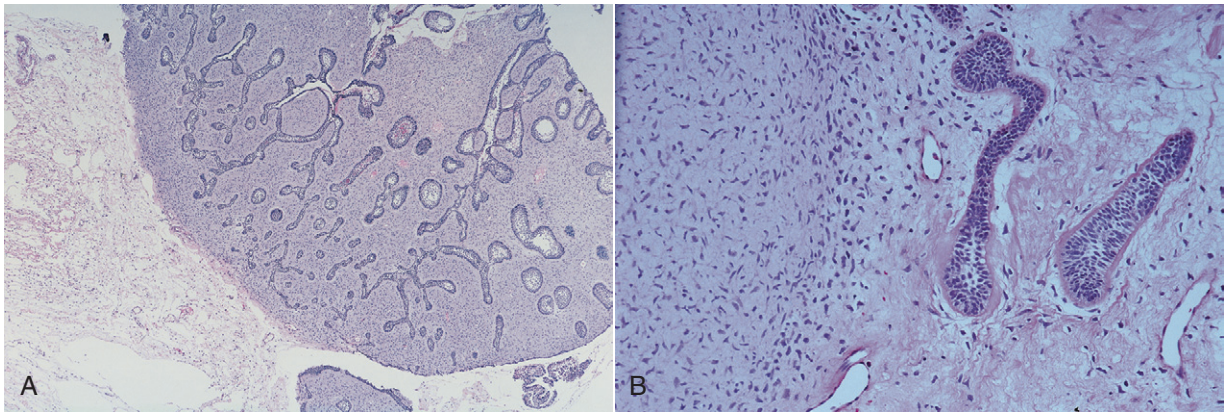

■ **FIGURE 11-51 Ameloblastic fibroma. A,** Lobular circumscribed pattern. **B,** Myxoid stroma and odontogenic strands.

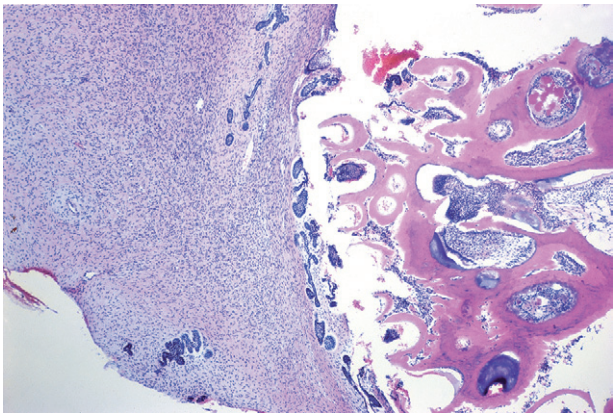

■ **FIGURE 11-52 Ameloblastic fibro-odontoma.** Note odontoma at right.

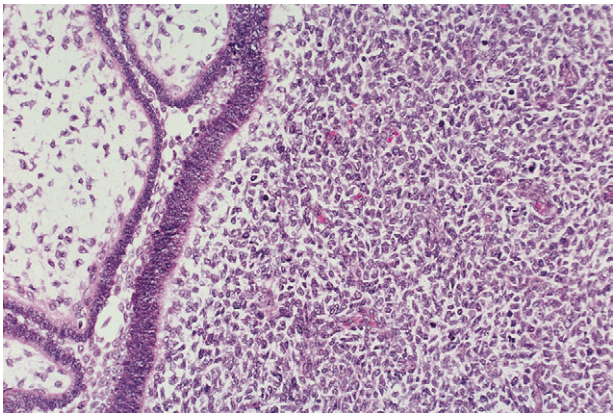

■ **FIGURE 11-53 Ameloblastic fibrosarcoma** with a malignant mesenchymal component.

lesions, the diagnosis is usually apparent. When clinical features are outside the usual boundaries, differential diagnosis for ameloblastic fibroma should include ameloblastoma, odontogenic myxoma, dentigerous cyst, odontogenic keratocyst, central giant cell granuloma, and histiocytosis. The differential diagnosis for ameloblastic fibro-odontoma includes lesions with mixed radiographic patterns such as calcifying epithelial odontogenic tumor, calcifying odontogenic cyst, developing odontoma, and possibly AOT. Microscopically, this lesion must be differentiated from hyperplastic follicular sacs, in which proliferation of odontogenic rests is seen.

Treatment. Because of tumor encapsulation and the general lack of invasive capacity, this lesion is treated through a conservative surgical procedure such as curettage or excision. Recurrences have been documented, but they are uncommon.

A rare malignant counterpart known as *ameloblastic fibrosarcoma* has been documented as arising in the jaws de novo or from preexisting or recurrent ameloblastic fibroma (Figure 11-53). In this lesion, the mesenchymal component has the appearance of a fibrosarcoma, and the epithelial component appears as it does in the benign lesion. Clinically, ameloblastic fibrosarcoma occurs at about 30 years of age and more often in the mandible than in the maxilla. Symptoms of pain and paresthesia may be present. This locally aggressive lesion has metastatic potential. Resection is therefore the treatment of choice.

Odontoma

Odontomas are *mixed odontogenic tumors,* in that they are composed of both epithelial and mesenchymal dental hard tissues. These fully differentiated tissues are a composite of enamel and dentin. Biologically, odontomas can be regarded as hamartomas rather than neoplasms.

BOX 11-17 ODONTOMA

Most common odontogenic tumor
Regarded as a hamartoma rather than a neoplasm
Children
Asymptomatic
  Discovered on routing radiographic examination *or* when it blocks eruption of a tooth
Compound type
  Composed of multiple miniature teeth
  Most commonly found in anterior maxilla
Complex type
  Conglomerate mass of enamel and dentin
  Most commonly found in the posterior jaws
Treated by enucleation; does not recur

These calcified lesions take one of two general configurations. They may appear as numerous miniature or rudimentary teeth, in which case they are known as *compound odontomas,* or they may appear as amorphous conglomerations of hard tissue, in which case they are known as *complex odontomas.* They are the most common odontogenic tumors.

Clinical Features. Odontomas are lesions of children and young adults; most are discovered in the second decade of life (Box 11-17). The range does, however, extend into later adulthood. The maxilla is affected slightly more often than the mandible. There is also a tendency for compound odontomas to occur in the anterior jaws, and for complex odontomas to occur in the posterior jaws. There does not appear to be a significant gender predilection. Clinical signs suggestive of an odontoma include a retained deciduous tooth, an impacted tooth, and alveolar swelling (Figure 11-54). These lesions generally produce no symptoms.

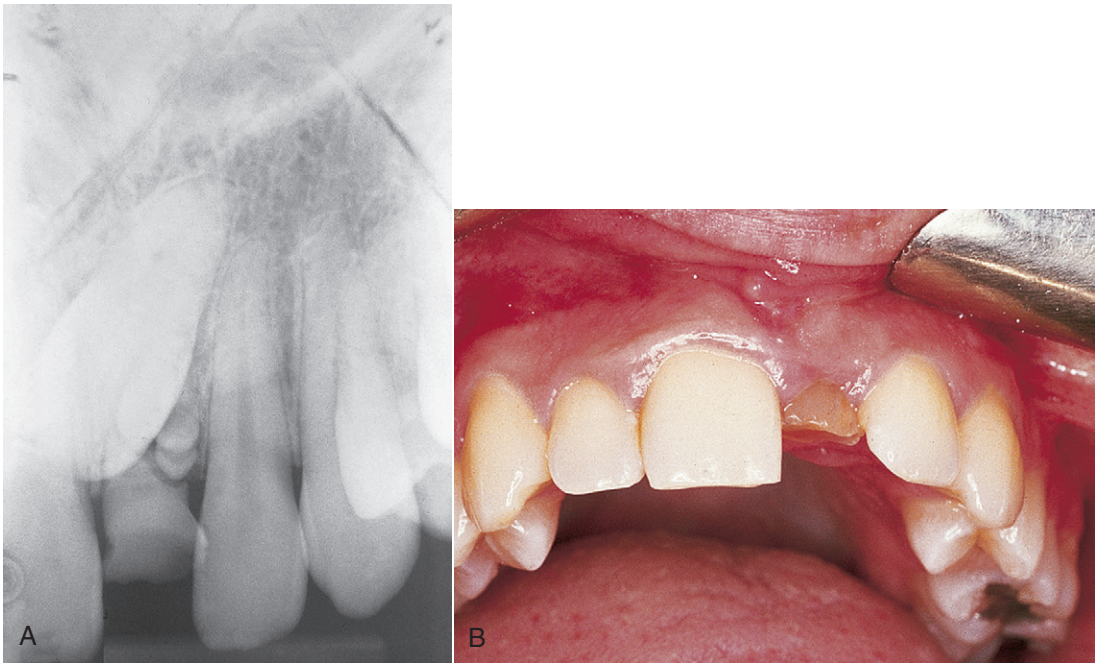

■ **FIGURE 11-54 A, Compound odontoma** blocking the eruption of a permanent tooth. **B,** Retained deciduous tooth overlying compound odontoma.

Radiographically, compound odontomas typically appear as numerous tiny teeth in a single focus. This focus is typically found in a tooth-bearing area, between roots or over the crown of an impacted tooth. Complex odontomas appear in the same regions, but as amorphous, opaque masses (Figures 11-55 and 11-56). Lesions discovered during early stages of tumor development are primarily radiolucent, with focal areas of opacity representing early calcification of dentin and enamel.

Histopathology. Normal-appearing enamel, dentin, cementum, and pulp may be seen in these lesions. A prominent enamel matrix and the associated enamel organ are often seen before final maturation of hard tissues (Figure 11-57). So-called ghost cell keratinization is seen occasionally in the enamel-forming cells of some odontomas. This microscopic feature has no significance other than to indicate the potential of these epithelial cells to keratinize.

Differential Diagnosis. Compound odontomas are diagnostic on radiographic examination. Complex odontomas usually present a typical radiographic appearance because of their solid opacification in relationship to teeth. However, a differential diagnosis might include other opaque jaw lesions such as focal sclerosing osteitis, osteoma, periapical cemental dysplasia, ossifying fibroma, and cementoblastoma.

Treatment. Odontomas have very limited growth potential, although an occasional complex odontoma may achieve considerable mass. Enucleation is curative, and recurrence is not a problem.



■ **FIGURE 11-55 Complex odontoma** in the anterior mandible.

A rare variant known as *odontoameloblastoma* has been described. This is essentially an ameloblastoma in which there is focal differentiation into an odontoma. Until more is known of the behavior of this rare lesion, it should be treated as an ameloblastoma.

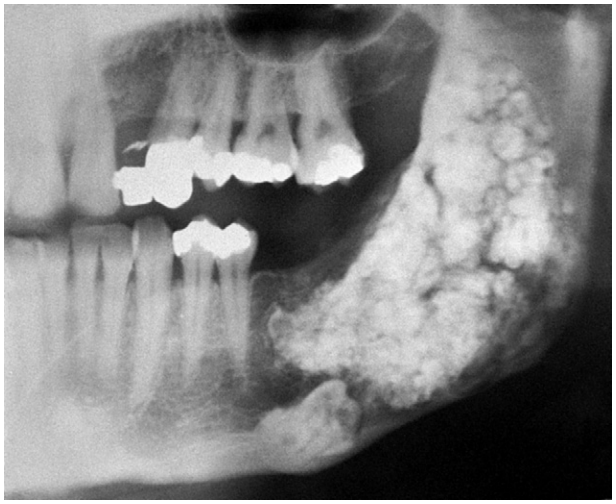

■ **FIGURE 11-56 Complex odontoma** occupying most of the mandibular ramus.

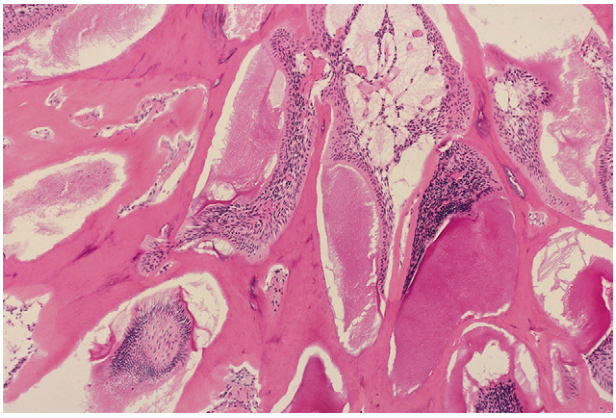

■ **FIGURE 11-57 Complex odontoma** (decalcified) showing a network of pink dentin and islands of bluish enamel matrix.

BIBLIOGRAPHY

Odontogenic Tumors

Aviel-Ronen S, Liokumovich P, Rahima D et al: The amyloid deposit in calcifying epithelial odontogenic tumor is immunoreactive for cytokeratins. Arch Pathol Lab Med 124:872–876, 2000.

Batra P, Prasad S, Prakash H: Adenomatoid odontogenic tumour: review of the literature and case report. J Can Dent Assoc 71:250–253, 2005.

Buchner A, Merrell PW, Carpenter WM: Relative frequency of central odontogenic tumors: a study of 1,088 cases from northern California and comparison to studies from other parts of the world. J Oral Maxillofac Surg 64:1343–1652, 2006.

Carlson ER, Marx RE: The ameloblastoma: primary, curative surgical management. J Oral Maxillofac Surg 64:484–494, 2006.

Chen Y, Wang JM, Li TJ: Ameloblastic fibroma: a review of published studies with special reference to its nature and biological behavior. Oral Oncol 43:960–969, 2007.

Daley TD, Wysocki GP: Relative incidence of odontogenic tumors and oral and jaw cysts in a Canadian population. Oral Surg Oral Med Oral Pathol 77:276–280, 1994.

Demian N, Harris RJ, Abramovich K et al: Malignant transformation of calcifying epithelial odontogenic tumor is associated with loss of p53 transcriptional activity: a case report with review of literature. J Oral Maxillofac Surg 68:1964–1973, 2010.

Ebert CS, Jr, Dubin MG, Hart CF et al: Clear cell odontogenic carcinoma: a comprehensive analysis of treatment strategies. Head Neck 27:510–542, 2005.

Gomes CC, Duarte AP, Diniz MG et al: Current concepts of ameloblastoma pathogenesis. J Oral Pathol Med 39:585–591, 2010.

Handlers J, Abrams A, Melrose R et al: Central odontogenic fibroma. J Oral Maxillofac Surg 49:46–54, 1991.

Hendarmin L, Sandra F, Nakao Y et al: TNF-alpha played a role in induction of Akt and MAPK signals in ameloblastoma. Oral Oncol 41:375–382, 2005.

Kawabata T, Takahashi K, Sugai M et al: Polymorphisms in PTCHI affect the risk of ameloblastoma. J Dent Res 84:812–816, 2005.

Kumamoto H: Molecular pathology of odontogenic tumors. J Oral Pathol Med 35:65–74, 2006.

Kumamoto H, Ohki K, Ooya K: Expression of p63 and p73 in ameloblastomas. J Oral Pathol Med 34:220–226, 2005.

Kumamoto H, Ooya K: Expression of tumor necrosis factor alpha, TNF-related apoptosis-inducing ligand, and their associated molecules in ameloblastomas. J Oral Pathol Med 34:287–294, 2005.

Kumamoto H, Ooya K: Immunohistochemical analysis of Bcl-2 family proteins in benign and malignant ameloblastomas. J Oral Pathol Med 28:343–349, 1999.

Kusama K, Katayama Y, Oba K et al: Expression of hard alpha-keratins in pilomatrixoma, craniopharyngioma, and calcifying odontogenic cyst. Am J Clin Pathol 123:376–381, 2005.

Leiser Y, Abu-El-Naaj I, Peled M: Odontogenic myxoma: a case series and review of the surgical management. J Cranio-Maxillofac Surg 37:206–209, 2009.

Li TJ, Browne RM, Matthews JB: Expression of proliferating cell nuclear antigen (PCNA) and Ki-67 in unicystic ameloblastoma. Histopathology 26:219–228, 1995.

Lu Y, Mock D, Takata T et al: Odontogenic ghost cell tumor: report of four new cases and review of the literature. J Oral Pathol Med 28:323–329, 1999.

MacDonald-Jankowski DS: Focal cemento-osseous dysplasia: a systematic review. Dentomaxillofac Radiol 37:350–360, 2008.

Murphy CL, Kessler DP, Foster JS et al: Odontogenic ameloblast-associated protein nature of the amyloid found in calcifying epithelial odontogenic tumors and unerupted tooth follicles. Amyloid 15:89–95, 2008.

Nakamura N, Mitsuyasu T, Higuchi Y et al: Growth characteristics of ameloblastoma involving the inferior alveolar nerve: a clinical and histopathologic study. Oral Surg Oral Med Oral Pathol Oral Radiol Endod 91:557–562, 2001.

Philipsen HP, Reichart PA: Unicystic ameloblastoma: a review of 193 cases from the literature. Oral Oncol 34:317–325, 1998.

Philipsen HP, Reichert PA, Nikai H et al: Peripheral ameloblastoma: biological profile based on 160 cases from the literature. Oral Oncol 37:17–27, 2001.

Philipsen HP, Reichart PA, Zhang K et al: Adenomatoid odontogenic tumor: biologic profile based on 499 cases. J Oral Pathol Med 20:149–158, 1991.

Pogrel MA, Montes DM: Is there a role for enucleation in the management of ameloblastoma? Int J Oral Maxillofac Surg 38:807–812, 2009.

Rosenstein T, Pogrel MA, Smith RA et al: Cystic ameloblastoma: behavior and treatment of 21 cases. J Oral Maxillofac Surg 59:1311–1316, 2001.

Sandra F, Hendarmin L, Kukita T et al: Ameloblastoma induces osteoclastogenesis: a possible role of ameloblastoma in expanding in the bone. Oral Oncol 41:637–644, 2005.

Sauk JJ, Nikitakis NG, Scheper MA: Are we on the brink of nonsurgical treatment for ameloblastoma? Oral Surg Oral Med Oral Pathol Oral Radiol Endod 110:68–78, 2010.

Sciubba JJ, Fantasia JE, Kahn LB: Tumors and Cysts of the Jaws, Washington, DC, 2001, Armed Forces Institute of Pathology.

Slootweg PJ: p53 protein and Ki-67 reactivity in epithelial odontogenic lesions: an immunohistochemical study. J Oral Pathol Med 24:393–397, 1995.

Thomas G, Pandey M, Mathew A et al: Primary intraosseous carcinoma of the jaw: pooled analysis of the world literature and report of two cases. Int J Oral Maxillofac Surg 30:349–355, 2001.

Thompson IO, van Rensberg LJ, Phillips VM: Desmoplastic ameloblastoma: correlative histopathology, radiology, and CT-MR imaging. J Oral Pathol Med 25:405–410, 1996.

Van Dam SD, Uni KK, Keller EE: Metastasizing (malignant) ameloblastoma: review of a unique histopathologic entity and report of Mayo Clinic experience. J Oral Maxillofac Surg 68:2962–2974, 2010.

Werle H, Blake FA, Reichelt U et al: Clear-cell odontogenic carcinoma: a new case and long-term follow-up of an old case and review of the literature. J Oral Maxillofac Surg 67:1342–1348, 2009.

Younis RH, Scheper MA, Lindquist CC et al: Hybrid central odontogenic fibroma with giant cell granuloma-like component: case report and review of literature. Head Neck Pathol 2:222–226, 2008.

Zhang L, Chen XM, Sun ZJ et al: Epithelial expression of SHH signaling pathway in odontogenic tumors. Oral Oncol 42:398–408, 2006.

CHAPTER 12

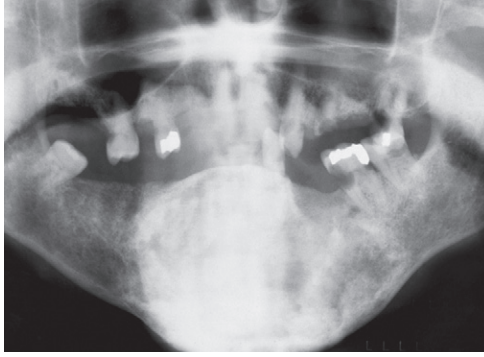

Benign Nonodontogenic Tumors

Jeffery C.B. Stewart

OSSIFYING FIBROMA
Etiology and Pathogenesis
Clinical Features
Histopathology
Differential Diagnosis
Treatment and Prognosis

FIBROUS DYSPLASIA
Etiology and Pathogenesis
Clinical Features
Histopathology
Differential Diagnosis
Treatment and Prognosis

CEMENTO-OSSEOUS DYSPLASIA

OSTEOBLASTOMA/OSTEOID OSTEOMA
Clinical Features
Histopathology
Differential Diagnosis
Treatment and Prognosis

OSTEOMA
Clinical Features
Histopathology
Differential Diagnosis
Treatment and Prognosis

DESMOPLASTIC FIBROMA
Clinical Features
Histopathology
Differential Diagnosis
Treatment and Prognosis

CHONDROMA

CENTRAL GIANT CELL GRANULOMA
Etiology and Pathogenesis
Clinical Features
Histopathology
Differential Diagnosis
Treatment and Prognosis

GIANT CELL TUMOR

HEMANGIOMA OF BONE
Clinical Features
Histopathology
Differential Diagnosis
Treatment and Prognosis

LANGERHANS CELL DISEASE
Etiology and Pathogenesis
Clinical Features
Histopathology
Differential Diagnosis
Treatment and Prognosis

TORI AND EXOSTOSES
Etiology and Pathogenesis
Clinical Features
Histopathology
Treatment and Prognosis

CORONOID HYPERPLASIA
Etiology and Pathogenesis
Clinical Features
Histopathology
Differential Diagnosis
Treatment and Prognosis

OSSIFYING FIBROMA

Ossifying fibroma is a benign neoplasm of bone that has the potential for excessive growth, bone destruction, and recurrence. It is clinically and microscopically similar, if not identical, to cementifying fibroma. Composed of a fibrous connective tissue stroma in which new bone is formed, it is classified as one of the benign fibro-osseous lesions of the jaws (Boxes 12-1 and 12-2).

Etiology and Pathogenesis

Ossifying fibroma is of undetermined cause (Box 12-3). Although chromosome translocations have been identified in a few cases of ossifying fibroma, genetic studies have been insufficient to determine the molecular mechanisms that underlie the development of this tumor.

Clinical Features

Ossifying fibroma is an uncommon lesion that tends to occur during the third and fourth decades of life, and in women more than men. It is a slow-growing, asymptomatic, and expansile lesion. In the head and neck, ossifying fibroma may be seen in the jaws and craniofacial bones. Lesions of the jaws characteristically arise in the tooth-bearing regions, most often in the mandibular premolar-molar area (Figure 12-1). The slow but persistent growth of the tumor may ultimately produce expansion and thinning of the buccal and lingual cortical plates, although perforation and mucosal ulceration are rare (Figures 12-2 and 12-3). Most of these lesions are solitary, although instances of multiple

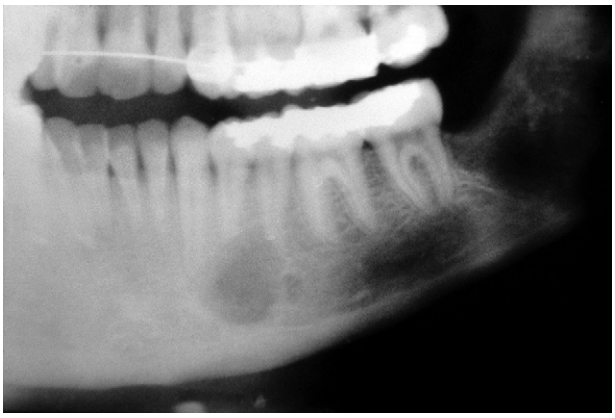

■ **FIGURE 12-1 Ossifying fibroma** of the left mandible. The lesion is relatively radiolucent at apices of premolars.



■ **FIGURE 12-2 Ossifying fibroma** in the anterior mandible showing cortical expansion.

BOX 12-1 FIBRO-OSSEOUS LESIONS OF THE JAWS

Generic microscopic term
Benign fibrous stroma with immature bone
Includes reactive, dysplastic, neoplastic lesions
Histologic overlap
Diagnosis based on clinical pathologic correlation

BOX 12-2 FIBRO-OSSEOUS LESIONS OF THE JAWS: ENTITIES MOST COMMONLY INCLUDED

Ossifying fibroma
Fibrous dysplasia
Cemento-osseous dysplasia
  Periapical/focal
  Florid
Chronic osteomyelitis

BOX 12-3 OSSIFYING FIBROMA

CLINICAL FEATURES
Third and fourth decades
Mandible > maxilla
Well circumscribed
Lucent or lucent/opaque pattern
Continuous growth

HISTOPATHOLOGY
Cellular fibrous matrix
Islands/trabeculae of new bone
Osteoblasts; no osteoclasts
Relatively homogeneous pattern
No inflammatory cells

TREATMENT
Curettage/excision

>, More frequently affected than.

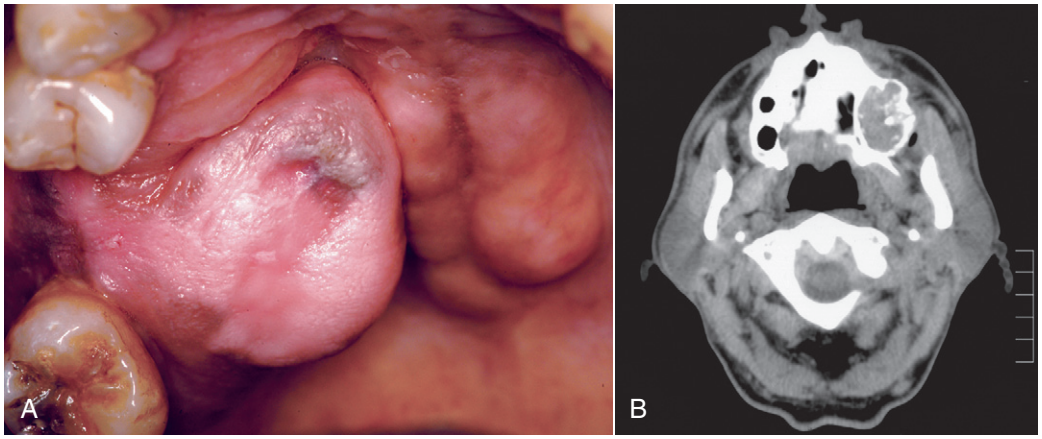

■ **FIGURE 12-3 A** and **B, Ossifying fibroma** of the maxilla showing marked cortical expansion. Note incidental finding of torus palatinus in **A.**

BOX 12-4 OSSIFYING FIBROMA VARIANTS

JUVENILE TRABECULAR OSSIFYING FIBROMA
Younger patients
Aggressive clinical course
Cellular (benign) stroma
Trabecular or spherical bone

JUVENILE PSAMMOMATOID OSSIFYING FIBROMA
Biologically same as ossifying fibroma
Spheric islands of bone (cementum)
Bone and cementum microscopically identical

synchronous lesions have been reported; a familial background for synchronous lesions is rare.

The most important radiographic feature of this lesion is the well-circumscribed, sharply defined border. Ossifying fibromas otherwise present a variable appearance, depending on the density of calcifications present. Lesions may be relatively radiolucent because of evenly dispersed, calcified new bone. Lesions may also appear as unilocular or multilocular radiolucencies that bear a resemblance to odontogenic lesions. A mixed radiolucent-radiopaque image is seen when islands of tumor bone are densely calcified. The roots of teeth may be displaced; less commonly, tooth resorption is seen.

The term *juvenile (aggressive) ossifying fibroma* was used in the literature to describe two variants of ossifying fibroma that occur in younger patients (Box 12-4). Currently these two entities are referred to as *juvenile trabecular ossifying fibroma (JTOF)* and *juvenile psammomatoid ossifying fibroma (JPOF).* Juvenile trabecular ossifying fibroma (JTOF) typically occurs in children and adolescents; only about 20% of cases occur in those older than 15 years. The lesion occurs almost exclusively in the maxilla and mandible and rarely in extragnathic locations. JTOF is characterized by progressive and sometimes rapid growth but rarely pain. Radiographically, the tumor has a defined border and can range from radiodense to radiolucent. Microscopically, JTOF is highly cellular and contains trabeculae or spheroids of new bone. Following complete excision, recurrences of JTOF are infrequent. By contrast, the juvenile psammomatoid ossifying fibroma (JPOF) occurs principally in the extragnathic craniofacial bones, particularly the paranasal sinuses and periorbital bones, where it may cause exophthalmos, proptosis, sinusitis, and nasal symptoms. JPOF occurs in a slightly older population compared with JTOF. Microscopically, JPOF is formed by relatively cellular stroma containing small, rounded calcifications (psammomatoid). Treatment consists of surgical excision, but up to 30% of cases will show recurrences, sometimes multiple and over a span of many years.

Cementifying fibroma and cemento-ossifying fibroma are terms occasionally used when the bony islands in these jaw tumors are round or spheroidal. These occur in similar age groups and locations, exhibit comparable clinical characteristics, and have the same biological behavior. They are, for all practical purposes, the same lesion as ossifying fibroma.

Histopathology

Ossifying fibroma is composed of fibrous connective tissue with well-differentiated spindled fibroblasts. Cellularity is uniform but may vary from one lesion to the next. Collagen fibers are arranged haphazardly, although a whorled, storiform pattern may be evident. Bony spheroids, trabeculae, or islands are evenly distributed throughout the fibrous stroma (Figures 12-4 to 12-6). Bone is immature and often is surrounded by osteoblasts. Osteoclasts are infrequently seen.

Differential Diagnosis

Distinguishing between ossifying fibroma and fibrous dysplasia is the primary diagnostic challenge. These lesions may exhibit similar clinical, radiographic, and microscopic features. The most helpful feature in distinguishing the two

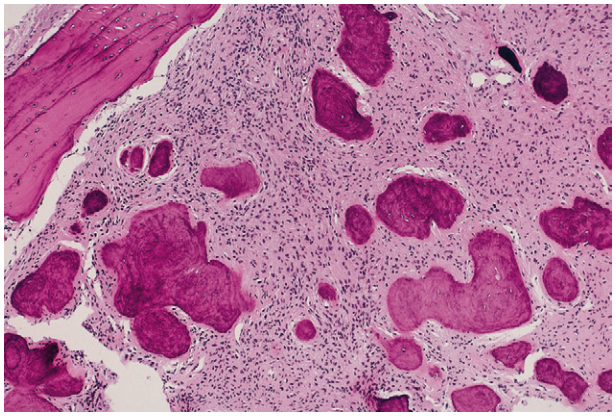

■ **FIGURE 12-4 Ossifying fibroma** exhibiting islands of new bone in fibroblastic matrix. Note cortex at upper left.

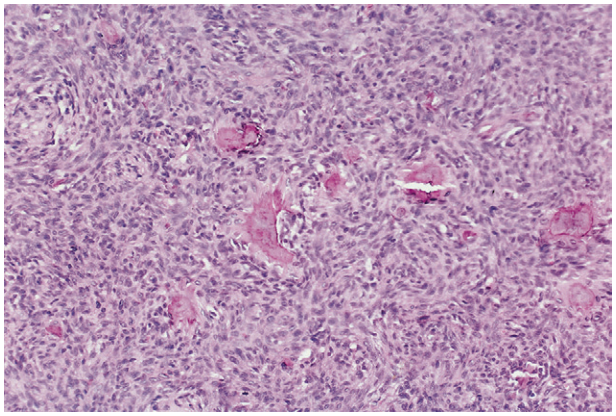

■ **FIGURE 12-5 Ossifying fibroma** with cellular stroma and small bony islands.

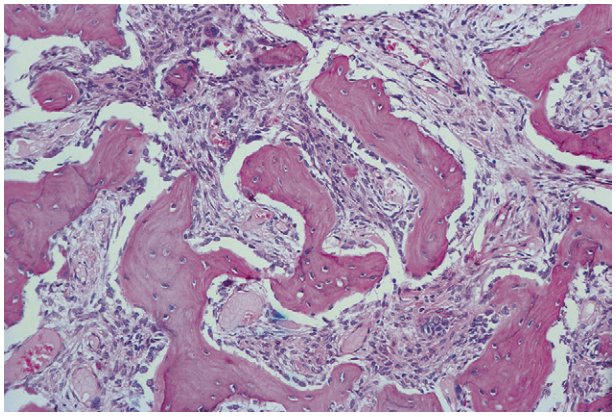

■ **FIGURE 12-6 Ossifying fibroma** composed of bony trabeculae in benign fibroblast matrix.

is the well-circumscribed radiographic appearance of ossifying fibroma and the ease with which it can be separated from normal bone. In most cases, the well-defined appearance of ossifying fibroma is evident radiographically. Historically, differentiating the two lesions was based primarily on histologic criteria. Fibrous dysplasia was reported to contain only woven bone, without evidence of osteoblastic rimming of bone. The presence of more mature lamellar bone was believed to be characteristic of ossifying fibroma. Most authorities now acknowledge that these criteria are unreliable, because both types of bone and cellular features may be found in either lesion.

Other differential considerations are osteoblastoma, focal cemento-osseous dysplasia, and focal osteomyelitis. Osteoblastoma is evident in a slightly younger age group and is often characterized by pain. In addition, osseous trabeculae in these lesions are rimmed by abundant plump osteoblasts, and a central nidus may be evident. Periapical cemento-osseous dysplasia in posterior teeth may appear radiographically similar and may require a biopsy to separate it from ossifying fibroma. Focal osteomyelitis is associated with a source of inflammation and may be accompanied by pain and swelling.

Treatment and Prognosis

Treatment of ossifying fibroma is most often accomplished by surgical removal using curettage or enucleation. The lesion can typically be separated easily from the surrounding normal bone. Recurrence is described only rarely after removal.

FIBROUS DYSPLASIA

Fibrous dysplasia is a condition in which normal medullary bone is replaced by an abnormal fibrous connective tissue proliferation in which new, nonmaturing bone is formed (Box 12-5). A genetic defect involving Gsα protein appears to underlie this process.

BOX 12-5 FIBROUS DYSPLASIA

CLINICAL FEATURES
First and second decades (stabilizes at puberty and very slow growth thereafter)
Maxilla > mandible (one or more bones)
Ribs, femur, tibia also affected
Unilateral diffuse opacity
Asymptomatic; self-limiting
Serum laboratory values normal

HISTOPATHOLOGY
New fibrillar bone trabeculae
Few osteoblasts; no osteoclasts
Homogeneous pattern
Vascular matrix
No inflammatory cells

TREATMENT
Surgical recontouring for cosmetics (after growth spurt)
Regrowth in 25% of treated cases

>, More frequently affected than.

Etiology and Pathogenesis

The name given to fibrous dysplasia was originally intended to indicate that the condition represented a dysplastic growth resulting from deranged mesenchymal cell activity or a defect in the control of bone cell activity. Genetic studies, however, have provided evidence that it may be better classified as a neoplastic process. Mutations of the *GNAS I* gene encoding for the alpha subunit of a transmembrane-signaling G protein (Gsα) appear to be present in fibrous dysplasia. This genetic alteration may ultimately affect the proliferation and differentiation of fibroblasts/osteoblasts that make up these lesions.

Clinical Features

This disease most commonly presents as an asymptomatic, slow enlargement of involved bone. Fibrous dysplasia may involve a single bone or several bones concomitantly. *Monostotic fibrous dysplasia* is the designation used to describe the process in one bone. *Polyostotic fibrous dysplasia* applies to cases in which more than one bone is involved. *McCune-Albright syndrome* consists of polyostotic fibrous dysplasia, cutaneous melanotic pigmentations (café-au-lait macules), and endocrine abnormalities. The most commonly reported endocrine disorder consists of precocious sexual development in girls. Acromegaly, hyperthyroidism, hyperparathyroidism, and hyperprolactinemia have also been described. *Jaffe-Lichtenstein syndrome* is characterized by multiple bone lesions of fibrous dysplasia and skin pigmentations.

Monostotic fibrous dysplasia is much more common than the polyostotic form, accounting for as many as 80% of cases. Jaw involvement is common in this form of the disease. Other bones that are commonly affected are the ribs and the femur. Fibrous dysplasia occurs more often in the maxilla than in the mandible (Figure 12-7). Maxillary lesions may extend to involve the maxillary sinus, zygoma, sphenoid bone, and floor of the orbit. This form of the disease, with involvement of several adjacent bones, has been referred to as *craniofacial fibrous dysplasia.* The most common site of occurrence with mandibular involvement is in the body portion.

The slow, progressive enlargement of the affected jaw is usually painless and typically presents as a unilateral swelling. As the lesion grows, facial asymmetry becomes evident and may be the initial presenting complaint. The dental arch is generally maintained, although displacement of teeth, malocclusion, and interference with tooth eruption may occasionally occur. Tooth mobility is not seen.

This condition characteristically has its onset during the first or second decade of life. Rarely, the lesion presents later in life, although this may only reflect the insidious, asymptomatic nature of fibrous dysplasia. Monostotic fibrous dysplasia generally exhibits an equal gender distribution; the polyostotic form tends to occur more commonly in females.

Fibrous dysplasia has a variable radiographic appearance that ranges from a radiolucent lesion to a uniformly radiopaque mass (Figures 12-8 to 12-10). The classic lesion has been described as having a radiopaque change that imparts a "ground-glass" or "peau d'orange" effect. This characteristic image, which is most identifiable on intraoral radiographs, is not, however, pathognomonic. Lesions of fibrous dysplasia may also present as unilocular or multilocular radiolucencies, especially in long bones. A third pattern, most commonly seen in patients with long-standing disease, is a mottled radiolucent and radiopaque appearance. Additional radiographic features that have been described include a fingerprint bone pattern and superior displacement of the mandibular canal in mandibular lesions.

An important distinguishing feature of fibrous dysplasia is the poorly defined radiographic and clinical margins of the lesion. The process appears to blend into the surrounding normal bone without evidence of a circumscribed border. In addition, these lesions are often elliptic as opposed to spheric.

Laboratory values for patients with monostotic fibrous dysplasia, specifically, serum calcium, phosphorus, and alkaline phosphatase, are usually within normal ranges for patients with monostotic disease. However, these serum chemistry markers may be altered in patients with McCune-Albright syndrome.

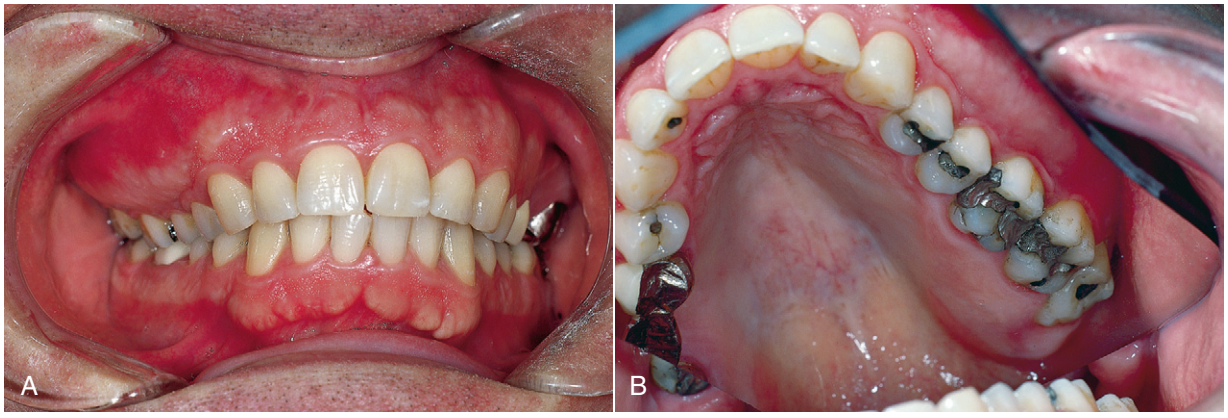

■ **FIGURE 12-7 A** and **B, Fibrous dysplasia** of the right maxilla demonstrating asymmetric expansion. **B** is mirror image.



■ **FIGURE 12-8 Fibrous dysplasia** of the maxilla and skull base as demonstrated on a computed tomography (CT) scan.



■ **FIGURE 12-9 Fibrous dysplasia** of the right maxilla causing a characteristic diffuse ground-glass effect.

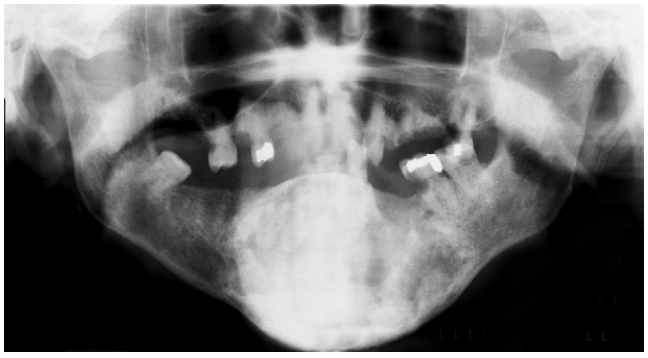

■ **FIGURE 12-10 Fibrous dysplasia** of the mandible.

Histopathology

Fibrous dysplasia consists of a slightly to moderately cellular fibrous connective tissue stroma that contains foci of irregularly shaped trabeculae of immature bone (Figures 12-11 and 12-12). A relatively constant ratio of fibrous tissue to bone throughout a given lesion is characteristic. The fibroblasts exhibit uniform spindle-shaped nuclei, and mitotic figures

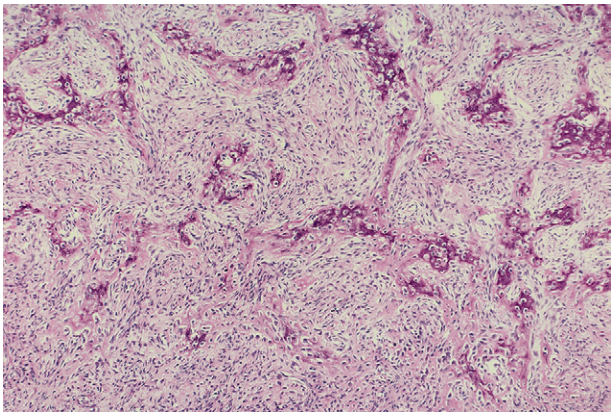

■ **FIGURE 12-11 Fibrous dysplasia** exhibiting fibroblastic matrix and uniform distribution of bony trabeculae (*purple,* not decalcified).

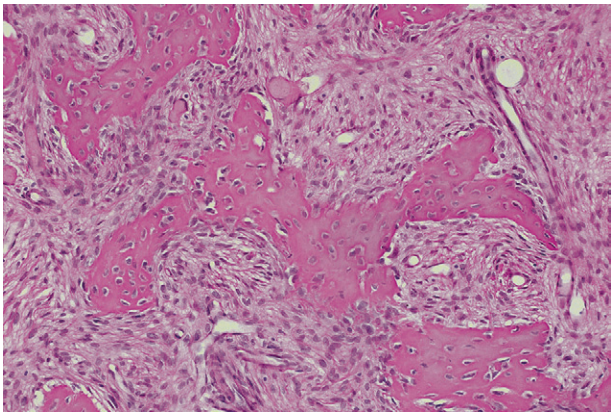

■ **FIGURE 12-12 Fibrous dysplasia** showing vascular fibroblastic matrix and irregular trabeculae of new bone.

are not seen. The bony trabeculae assume irregular shapes likened to Chinese characters (the pictograms used in Chinese writing), and they do not display any functional orientation. The bone is predominantly woven in type and appears to arise directly from the collagenous stroma without prominent osteoblastic activity. In a mature fibrous dysplasia lesion, lamellar bone may be found. Capillaries typically are prominent and uniformly distributed.

Differential Diagnosis

The primary differential consideration for fibrous dysplasia of the jaws is ossifying fibroma. As previously noted, clinical, radiographic, and microscopic features must be considered together to distinguish these processes. The well-circumscribed ossifying fibroma as compared with the diffuse fibrous dysplasia often serves as the differentiating factor. Additional features that aid in distinguishing these processes are listed in Box 12-6.

Chronic osteomyelitis occasionally may mimic the radiographic appearance of fibrous dysplasia. Inflammation, often

BOX 12-6 FIBROUS DYSPLASIA VS. OSSIFYING FIBROMA

FIBROUS DYSPLASIA	OSSIFYING FIBROMA
First and second decades	Third and fourth decades
Maxilla > mandible	Mandible > maxilla
Diffuse opacity	Circumscribed
Self-limited	Continuous growth
One or more bones	One bone
Vascular matrix	Cellular fibrous matrix
Woven bone trabeculae	Bony islands and trabeculae
Stabilizes at puberty	Not hormone related
Recontour for cosmetics	Excise

>, More frequently affected than.

BOX 12-7 OSTEOBLASTOMA

Large counterpart of osteoid osteoma
- Osteoblastoma >1.5 cm
- Osteoid osteoma <1.5 cm

50% are painful
Second decade is characteristic age
Circumscribed
Benign cellular (osteoblasts) neoplasm with new bone in scant fibrous stroma
Treatment by excision; few recurrences

mild, is present in osteomyelitis and may be accompanied by symptoms that include tenderness, pain, or drainage. Periostitis is a radiographic feature of osteomyelitis. The slowly progressive, asymptomatic nature of fibrous dysplasia usually allows differentiation from malignant tumors of bone.

Treatment and Prognosis

After a variable period of prepubertal growth, fibrous dysplasia characteristically stabilizes, although a slow advance may be noted into adulthood. Small lesions therefore may require no treatment other than biopsy confirmation and periodic follow-up. Large lesions that have caused cosmetic or functional deformity may be treated by surgical recontouring. This procedure generally is deferred until after stabilization of the disease process. En bloc resections for complete removal are impractical and unnecessary because the lesions are relatively large and poorly delineated.

Medical management with bisphosphonates has been reported to improve symptoms of pain and bone density, but their long-term effects have yet to be determined. Whether other drugs that control osteoclast activity in use or in development will provide beneficial effects is speculative.

Malignant transformation is a rare complication of fibrous dysplasia (less than 1% of cases) that has been described usually in patients with the polyostotic type. Many of the reported patients were treated with radiation therapy, suggesting a role for radiation in the transformation process, although malignant change has been documented in the absence of radiation treatment.

CEMENTO-OSSEOUS DYSPLASIA

The term *cemento-osseous dysplasia* refers to a disease process of the jaws for which the precise cause is unknown. Cemento-osseous dysplasia describes a spectrum of disorders that include periapical cemento-osseous dysplasia, focal cemento-osseous dysplasia, and florid cemento-osseous dysplasia—apparently similar disease processes distinguished on the basis of extent of involvement of affected portions of the jaws (see Chapter 11 for a comprehensive discussion). Cemento-osseous dysplasia, ossifying fibroma, and fibrous dysplasia have been classified as fibro-osseous lesions of the jaws. These fibro-osseous diseases represent a diverse group of reactive, dysplastic, and neoplastic lesions characterized microscopically by the replacement of normal bone with a collagenous matrix containing trabeculae of immature bone and, in some instances, cementum-like material (see Boxes 12-1 and 12-2).

OSTEOBLASTOMA/OSTEOID OSTEOMA

Osteoblastoma is an uncommon primary lesion of bone that occasionally arises in the maxilla or the mandible (Box 12-7). *Osteoid osteoma* is thought to represent a smaller version of the same tumor, although some prefer to separate these lesions into two distinct entities. These are benign neoplasms of undetermined cause, although a genetic defect has been suggested. Clinically and histologically, they may be confused with osteosarcoma.

Clinical Features

The designation of *osteoblastoma* is used for lesions larger than 1.5 cm in diameter; the designation of *osteoid osteoma* is used for lesions measuring 1.5 cm or less. These lesions arise most often in vertebrae and long bones and less commonly in the jaws and other craniofacial bones. The posterior tooth–bearing regions of the maxilla and mandible are the usual sites of jaw involvement (Figure 12-13). Lesions have been reported as arising in medullary or periosteal sites. The bony cortices may be expanded and tender to palpation.

Most cases occur during the second decade, with 90% of lesions appearing before the age of 30 years. Males are affected more often than females by a ratio of approximately 2 to 1.

Pain, often quite severe, is usually associated with osteoid osteoma and can also be a feature of osteoblastoma.



■ **FIGURE 12-13 Osteoblastoma** of the right mandible.

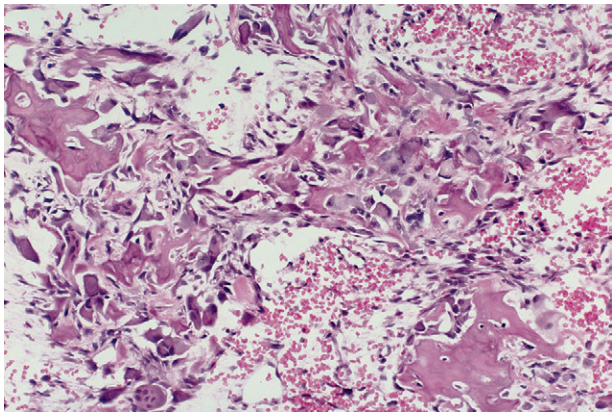

■ **FIGURE 12-14 Osteoblastoma** showing abundant prominent osteoblasts adjacent to new bone.

Localized swelling may occur alone or along with pain. Aspirin or nonsteroidal anti-inflammatory drugs relieve symptoms, including nocturnal pain, associated with osteoid osteoma. This relief is less likely to be seen with osteoblastoma. The duration of signs or symptoms of osteoblastoma ranges from weeks to years.

Radiographically, lesions are well circumscribed and have a mixed lucent-opaque pattern. A thin radiolucency may be noted surrounding a variably calcified central tumor mass. Sclerosis of perilesional bone, a constant feature of osteoid osteoma, may be absent in osteoblastoma. Occasionally, a peripheral sun ray pattern of new bone production may mimic osteosarcoma.

Histopathology

These lesions are composed of irregular trabeculae of osteoid and immature bone within a stroma containing a prominent vascular network (Figure 12-14). The bony trabeculae exhibit various degrees of calcification. Remodeling of the osseous tissue may be evident in the form of basophilic reversal lines. Several layers of plump, hyperchromatic osteoblasts typically line the bony trabeculae. Stromal cells generally are small and slender, although osteoblast-like cells and multinucleated giant cells may be noted in these areas.

Differential Diagnosis

Differential diagnosis considerations include cementoblastoma, ossifying fibroma, fibrous dysplasia, and osteosarcoma. Cementoblastoma can be differentiated from osteoblastoma because the former lesion arises from the surface of a tooth root and is fused to it. Ossifying fibroma is not painful and microscopically does not have the numbers of osteoblasts seen in osteoblastoma/osteoid osteoma. Fibrous dysplasia has poorly defined radiographic margins and does not have prominent osteoblasts microscopically.

The relatively rapid onset and the pain associated with some osteoblastomas necessitate differentiation from osteosarcoma. In biopsy specimens, the hyperchromatic, large osteoblasts noted in osteoblastoma resemble the malignant cells of osteosarcoma. Cytologic atypia, abnormal mitotic figures, delicately calcified tumor osteoid, and a heterogeneous pattern—all features of osteosarcoma—are not seen in osteoblastoma/osteoid osteoma.

Treatment and Prognosis

A conservative surgical approach (curettage or local excision) is curative in virtually all cases. In rare instances, these tumors have been associated with a tendency to invade tissues locally and to recur subsequently. The term *aggressive osteoblastoma* has been suggested for such lesions, but most authorities believe that this is an unnecessary subclassification. Rare examples of malignant transformation of osteoblastoma have also been reported.

OSTEOMA

Osteomas are benign tumors that consist of mature, compact, or cancellous bone. Osteomas that arise on the surface of bone are referred to as *periosteal osteomas,* whereas those that develop centrally within bone are *endosteal osteomas.* Osteomas are relatively rare in the jaws. The cause of these lesions is unknown, although trauma, infection, and developmental abnormalities have been suggested as contributing factors.

Clinical Features

Osteomas are most commonly identified during the second to fifth decades of life, and males are affected more often than females. Osteomas are usually solitary, except in patients with Gardner's syndrome.

Periosteal osteomas present clinically as asymptomatic, slow-growing, bony, hard masses. Asymmetry may be noted when lesions enlarge to sufficient proportion. Endosteal osteomas occurring within medullary bone may be discovered during routine radiographic examination as dense,

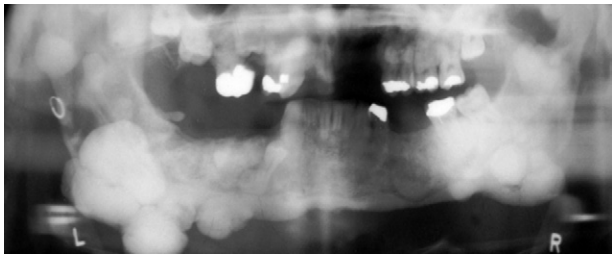

■ **FIGURE 12-15 Osteomas** of Gardner's syndrome.

well-circumscribed radiopacities, because extensive growth must take place before cortical expansion is evident. Osteomas may arise in the maxilla or mandible, as well as in facial and skull bones and within paranasal sinuses. Symptoms occasionally accompany these tumors. Headaches, recurrent sinusitis, and ophthalmologic complaints have been noted, depending on the lesion location.

Gardner's syndrome, inherited as an autosomal-dominant disorder, is characterized by intestinal polyposis, multiple osteomas, fibromas of the skin, epidermal and trichilemmal cysts, impacted permanent and supernumerary teeth, and odontomas (Figure 12-15). The genetic defect is found in a small region on the long arm of chromosome 5 (5q21), where the familial adenomatous polyposis (APC) gene resides. Most patients with Gardner's syndrome do not exhibit the complete spectrum of clinical disease expression. Osteomas associated with this syndrome may be found in the jaws (especially the mandibular angle) and in facial and long bones. Intestinal polyps associated with Gardner's syndrome are commonly located in the colon and rectum. Significantly, these polyps, found microscopically to be adenomas, exhibit a very high rate of malignant transformation to invasive colorectal carcinoma.

Histopathology

Two distinct histologic variants of osteoma have been described. One form is composed of relatively dense, compact bone with sparse marrow tissue. The other form consists of lamellar trabeculae of cancellous bone with abundant fibrofatty marrow. Osteoblasts may be numerous, but osteoclasts are sparse.

Differential Diagnosis

Osteomas should be distinguished from exostoses of the jaws. Exostoses are bony excrescences on the buccal aspect of alveolar bone. These lesions are of reactive or developmental origin and are not thought to be true neoplasms. Osteoblastomas and osteoid osteomas, which might also be considered in a differential diagnosis, are likely to be painful and may exhibit a more rapid rate of growth than osteomas. Osteomas may be confused radiographically with odontomas or focal sclerosing osteomyelitis.

BOX 12-8 DESMOPLASTIC FIBROMA

Young adults (<30 years of age)
Bony counterpart of fibromatosis
Microscopic differential
- Odontogenic fibroma
- Odontogenic fibromyxoma
- Low-grade fibrosarcoma
- Follicular sac

Recurrence potential

Treatment and Prognosis

Treatment of osteoma consists of surgical excision. Lesions should be excised for the purpose of establishing the diagnosis. In some instances, periodic observation of small, asymptomatic osteomas is appropriate treatment. Osteomas do not recur following surgical removal.

DESMOPLASTIC FIBROMA

Desmoplastic fibroma is a benign, locally aggressive lesion of bone that can be considered the bony counterpart of fibromatosis (Box 12-8). The tumor usually appears in long bones and the pelvis but occasionally may affect the jaws. The cause of desmoplastic fibroma is unknown. The lesion usually exhibits locally aggressive clinical behavior, suggesting a neoplastic process. The potential role of genetic, endocrine, and traumatic factors in the pathogenesis of the lesion has led to speculation that it might represent an exuberant reactive proliferation.

Clinical Features

Most cases of desmoplastic fibroma of the jaws have occurred in patients younger than 30 years, with a mean age of 14 years. There appears to be no gender predilection. The mandible, usually the body-ramus region, is affected more often than the maxilla (Figure 12-16). The lesions are slowly progressive and asymptomatic, eventually causing swelling of the jaw.

Radiographically, desmoplastic fibroma may be unilocular or multilocular (Figure 12-17). The radiographic margins may be well demarcated or poorly defined. Cortical perforation and root resorption may be seen.

Histopathology

The lesion consists of interlacing bundles and whorled aggregates of densely collagenous tissue that contains uniform spindled and elongated fibroblasts (Figure 12-18). Some areas may exhibit hypercellularity with plumper fibroblast nuclei. However, cytologic atypia and mitotic figures are not found. Bone is not produced by lesional tissue. In contrast



■ **FIGURE 12-16 Desmoplastic fibroma.** Microscopic differential diagnosis included fibrosarcoma. (Reproduced with permission from Regezi JA, Sciubba JJ, Pogrel MA: Atlas of Oral and Maxillofacial Pathology. Philadelphia, 2000, WB Saunders, Figure 9-15.)

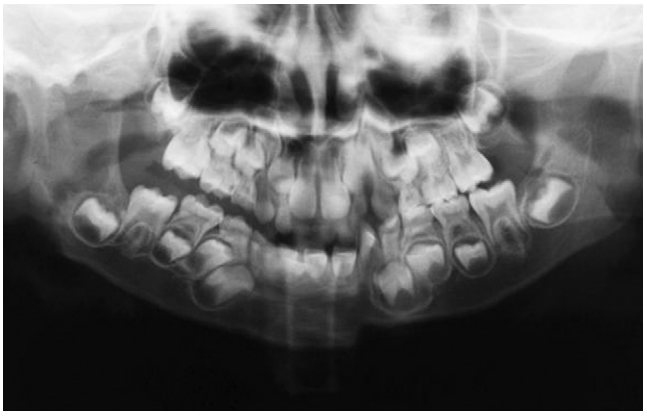

■ **FIGURE 12-17 Desmoplastic fibroma** in the right ramus of a 7-year-old boy.

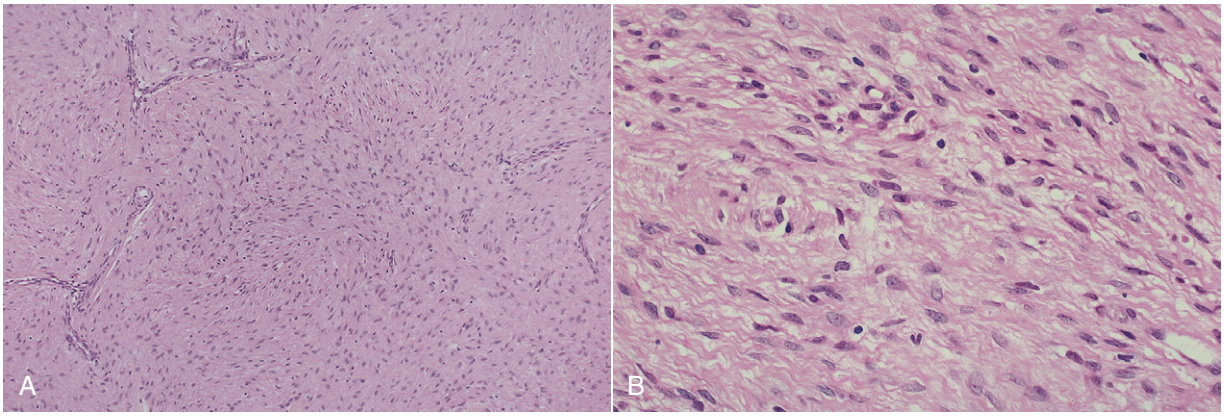

■ **FIGURE 12-18 A and B, Desmoplastic fibroma.** Note evenly distributed and benign-appearing fibroblasts in collagenous stroma.

to soft tissue desmoid-type fibromatosis, in which nuclear expression of beta-catenin protein and beta-catenin gene mutations are common, these findings are not consistently found in desmoplastic fibroma of bone.

Differential Diagnosis

Differential radiographic diagnostic considerations include odontogenic cysts, odontogenic tumors, and nonodontogenic lesions that typically occur in this age group. The presence of aggressive features, such as cortical perforation, or local symptoms might suggest the possibility of a malignancy. In some cases, histopathologic distinction between desmoplastic fibroma and well-differentiated fibrosarcoma may be difficult. The latter would exhibit greater cellularity, mitotic figures, and nuclear pleomorphism. Some similarities are noted histologically with central odontogenic fibroma, a nonaggressive lesion that contains odontogenic rests.

Treatment and Prognosis

Surgical resection of the lesion is generally reported as the treatment of choice. Curettage alone has been associated with a significant recurrence rate.

CHONDROMA

Chondroma is a benign cartilaginous tumor of unknown cause. Chondromas are rarely seen in the jaws, especially in comparison with their occurrence in other skeletal sites.

A chondroma commonly appears as a painless, slowly progressive swelling. Gradual expansion of the lesion rarely results in mucosal ulceration. Most lesions of the craniofacial complex arise in the nasal septum and ethmoid sinuses. Chondromas of the maxilla are most often found in the anterior region, where cartilaginous remnants of development are located. Mandibular chondromas have been noted in the body and symphysis areas, as well as in the coronoid

process and the condyle. Chondromas occur with equal incidence in both genders, with the majority of tumors appearing before 50 years of age. The radiographic appearance of the chondroma is variable, but it often presents as an irregular radiolucent area. Foci of calcification may be evident within the radiolucent lesion.

The lesion consists of well-defined lobules of mature hyaline cartilage. The chondrocytes are small and contain single, regular nuclei. The degree of cellularity varies considerably from one area to another within the chondroma. The principal diagnostic problem rests in microscopically distinguishing chondroma from a well-differentiated chondrosarcoma. The latter exhibits a heterogeneous pattern with cytologically atypical and irregularly spaced chondrocytes.

Chondromas are surgically excised, and recurrence is unusual. Any recurrence should be cause for reconsidering the original diagnosis in favor of the possibility of low-grade malignancy.

CENTRAL GIANT CELL GRANULOMA

Central giant cell granuloma (CGCG), or giant cell lesion, is a benign proliferation of fibroblasts and multinucleated giant cells that occurs almost exclusively within the jaws (Box 12-9). The tumor typically presents as a solitary radiolucent lesion of the mandible or maxilla.

Etiology and Pathogenesis

Thought to represent a reparative response to intrabony hemorrhage and inflammation, CGCG was once regarded as a reactive lesion. However, because of its unpredictable and occasionally aggressive behavior, and because of its possible relationship to the giant cell tumor of long bones, CGCG is best classified as a benign neoplasm.

BOX 12-9 CENTRAL GIANT CELL GRANULOMA

CLINICAL FEATURES

Most patients younger than 30 years of age; females affected more often than males
Lucency; mandible > maxilla; anterior jaw > posterior jaw
Recurrences unpredictable (10% to 50%)

HISTOPATHOLOGY

Benign fibroblast matrix (in cell cycle)
Giant cells variable (size, number, distribution)
Few to many mitotic figures
Cannot separate aggressive from nonaggressive lesions

TREATMENT

Traditional excision vs. medical management—calcitonin (osteoclast inhibition)

>, More frequently affected than.

The primary tumor cells of CGCGs are fibroblasts. Secondary cells, which are microscopically the most prominent, are multinucleated giant cells. Accessory cells, seen in considerably smaller numbers, include macrophages, factor XIIIa dendritic cells, and endothelial cells. Fibroblasts make up the proliferative component of CGCGs, because they express proteins that are indicative of cells in the cell cycle. Tumor fibroblasts are also believed to be responsible for recruitment and retention of monocytes and subsequently for transformation into multinucleated giant cells (Figures 12-19 and 12-20).

Clinical Features

CGCG is an uncommon lesion that occurs less commonly than its relatively trivial peripheral counterpart. Lesions are found predominantly in children and young adults, with most cases (75%) presenting before 30 years of age. Females are affected more often than males in a ratio of 2 to 1.

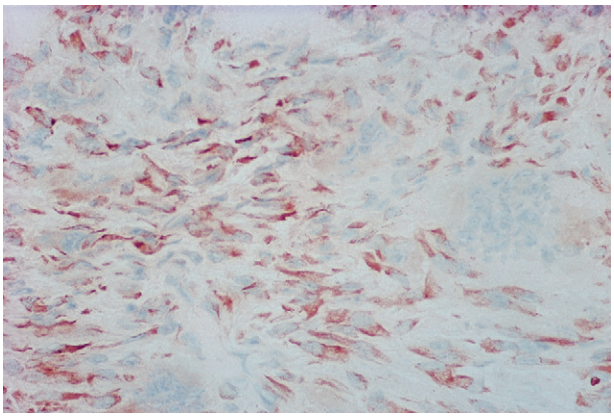

■ **FIGURE 12-19 Central giant cell granuloma** immunohistochemically stained for fibroblast-associated antigen. Note that stromal cells stain positive *(red)*.

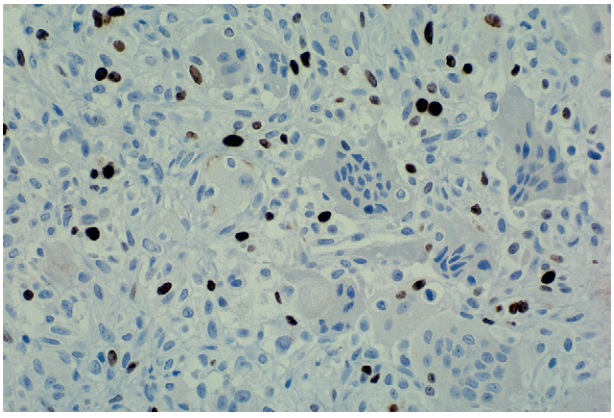

■ **FIGURE 12-20 Central giant cell granuloma** immunohistochemically stained for Ki-67 proliferation protein, showing that proliferating cells are located in the stromal component.

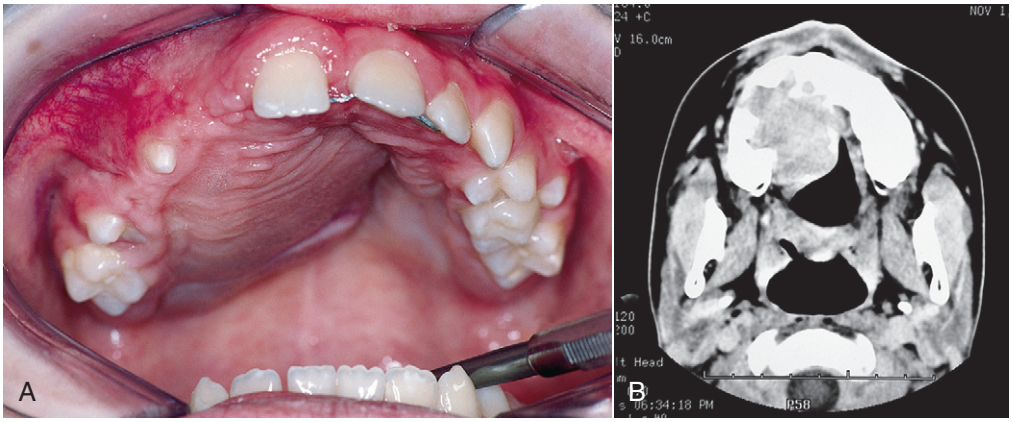

■ **FIGURE 12-21 Central giant cell granuloma.** Mass in right maxilla **(A)** is depicted on computed tomography (CT) scan **(B)**.



■ **FIGURE 12-22 Central giant cell granuloma** of the anterior mandible.

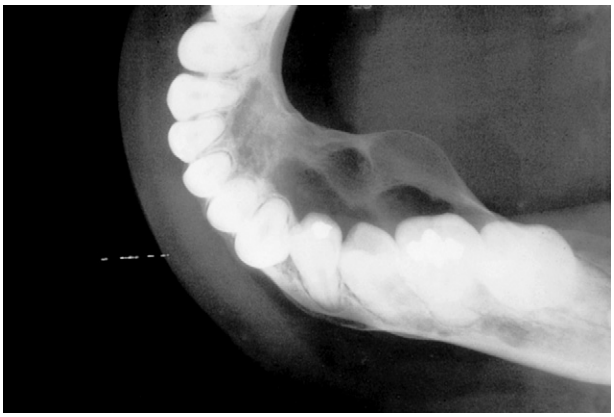

■ **FIGURE 12-23 Central giant cell granuloma** showing loculations and cortical expansion.

CGCG occurs almost exclusively in the maxilla and mandible, although isolated cases in facial bones and small bones of the hands and feet have been reported (Figure 12-21). Lesions are seen more commonly in the mandible than in the maxilla (Figure 12-22). These lesions tend to involve the jaws anterior to the permanent molar teeth, with occasional extension across the midline. Rarely, lesions involve the posterior jaws, including the mandibular ramus and condyle.

CGCG typically produces painless expansion or swelling of the affected jaw. Cortical plates are thinned; however, perforation with extension into soft tissues is uncommon. Radiographic features of CGCG consist of a multilocular or, less commonly, unilocular radiolucency of bone (Figure 12-23). The margins of the lesion are relatively well demarcated, often presenting a scalloped border. In some instances, CGCG pursues a more aggressive clinical and radiographic course. These "aggressive" CGCGs may cause pain or paresthesia. They exhibit rapid growth, root resorption, perforation of cortical bone, and a higher recurrence rate.

Histopathology

CGCG is composed of uniform fibroblasts in a stroma containing various amounts of collagen. Hemosiderin-laden macrophages and extravasated erythrocytes are usually evident, although capillaries are small and inconspicuous. Multinucleated giant cells are present throughout the connective tissue stroma, and they may be seen in patches or distributed evenly (Figures 12-24 and 12-25). Foci of osteoid may be present, particularly around the peripheral margins of the lesion.

No microscopic features distinguish aggressive CGCGs from nonaggressive ones. Numbers of mitotic figures, cellularity, giant cell numbers, giant cell nuclei numbers, and giant cell pattern are not useful in predicting behavior or outcome.

Differential Diagnosis

The clinical differential diagnosis for a solitary or multilocular CGCG includes ameloblastoma, odontogenic myxoma, and odontogenic keratocyst. For patients in the characteristic young age range for CGCG, ameloblastic fibroma, ossifying fibroma, and adenomatoid odontogenic tumor might be added to this list.

The microscopic appearance of CGCG is virtually identical to that of the giant cell lesion associated with hyperparathyroidism (Box 12-10). This process must be differentiated on the basis of biochemical tests. An elevated serum level of parathyroid hormone indicates primary hyperparathyroidism.

The giant cell tumor of (long) bone may exhibit histologic features similar to those of CGCG, although the former tends to have larger giant cells with more nuclei and a homogeneous pattern. Giant cell tumor is believed to occur rarely in the jaws, although differentiation from CGCG can be difficult.

Other giant cell–containing look-alikes or entities containing multinucleated giant cells include aneurysmal bone cyst and cherubism. Diagnosis of aneurysmal bone cyst is made by identification of sinusoidal blood spaces within the tumor mass. Cherubism is diagnosed on clinical, pathologic, and genetic (*SH3BP2* mutations) grounds. Of note is that the so-called cherubism gene, *SH3BP2,* is not mutated in CGCG. Patients who develop multiple giant cell lesions may represent a rare syndrome known as Noonan-like/multiple giant cell lesion syndrome. These patients have many phenotypic features in common with Noonan syndrome, as well as mutations in the *PTPN11* gene.

Treatment and Prognosis

Surgical management of these lesions is the treatment of choice. Excision or curettage of the tumor mass followed by removal of the peripheral bony margins results in a good prognosis and a low recurrence rate. A somewhat higher rate of recurrence has been reported in lesions arising in children and young teens. Lesions with aggressive clinical features also exhibit a tendency to recur, often necessitating more extensive surgical approaches, including resection. Although numerous medical therapies have been tried in an attempt

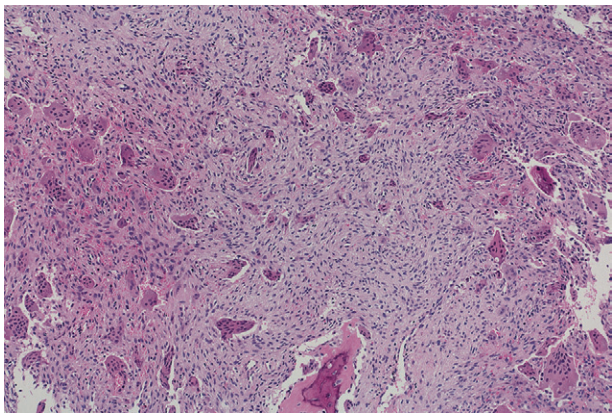

■ **FIGURE 12-24 Central giant cell granuloma** demonstrating characteristic patchy giant cell distribution in a fibroblastic matrix.

BOX 12-10 CENTRAL GIANT CELL GRANULOMA: MICROSCOPIC DIFFERENTIAL

HYPERPARATHYROIDISM
Elevated serum parathormone and alkaline phosphatase
Multiple bone lesions; loss of lamina dura

ANEURYSMAL BONE CYST
Blood-filled sinusoids present

CHERUBISM
Symmetric lesions
Family history
Perivascular collagen cuffing

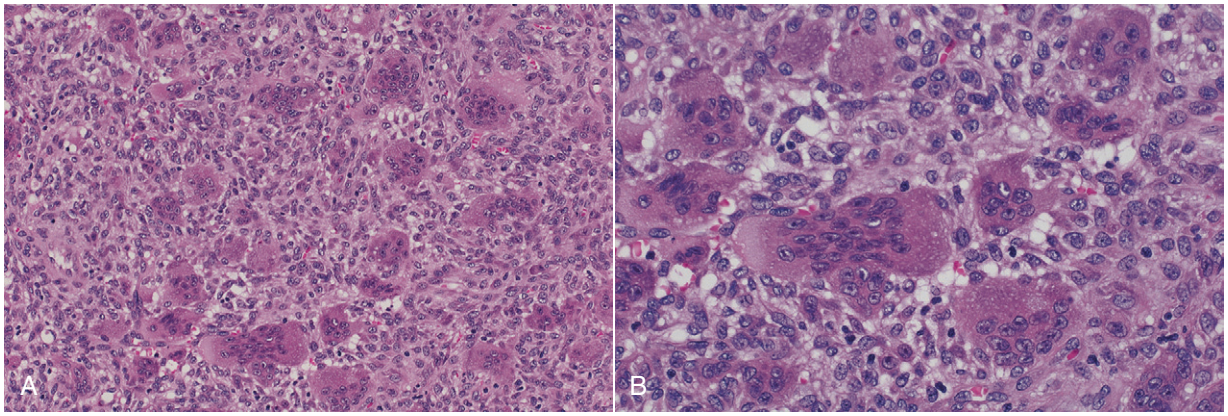

■ **FIGURE 12-25 A** and **B, Central giant cell granuloma.** Note cellular matrix and evenly distributed giant cells.

to control aggressive CGCGs, reports have been anecdotal and not part of a clinical controlled study. Intralesional injections of corticosteroids have been proposed, but results are varied and the rationale of this therapy is questionable. Exogenous calcitonin may have some merit in the treatment of aggressive lesions. Preliminary data suggest that lesions may stabilize or regress after several months of therapy. Interferon-alpha has been proposed as an additional treatment modality on the basis of an antiangiogenic mode of action. Its efficacy, as an adjunct or primary mode of therapy, has yet to be determined. Bisphosphonates, because of their inhibitory effects on osteoclasts, have been suggested as an alternative or adjunct to surgery.

GIANT CELL TUMOR

Giant cell tumors are true neoplasms that arise most commonly in long bones, especially in the area of the knee joint. These tumors exhibit a wide spectrum of biological behavior from benign to malignant. The relationship between this lesion and CGCG is controversial. Most regard the giant cell tumor as distinct from CGCG, acknowledging the very rare occurrence of giant cell tumor within the jaws.

Giant cell tumors, although rare, have been reported in the jaws. Other sites of involvement in the head and neck include the sphenoid, ethmoid, and temporal bones. Giant cell tumors are most often seen in the third and fourth decades of life. Lesions exhibit slow growth and bone expansion, or they produce rapid growth, pain, or paresthesia. Radiographically, the giant cell tumor produces a radiolucent image.

Microscopically, this tumor is characterized by the presence of numerous multinucleated giant cells dispersed evenly among monocyte-macrophages and spindle cells (Figure 12-26). It has been proposed that the spindle cells represent the neoplastic cells in this tumor, and that the monocyte-macrophages are reactive, giving rise to giant cells through recruitment and induction factors (e.g., tumor necrosis factor [TNF]-alpha, macrophage colony-stimulating factor) secreted by the tumor spindle cells.

Stromal cellularity is usually prominent, with minimal collagen production. Giant cells in giant cell tumors usually are larger and contain more nuclei than the corresponding cells of CGCG. Significant variation is noted, however, such that any given lesion may present diagnostic difficulty because of considerable histologic overlap. Giant cell tumors may contain inflammatory cells and areas of necrosis while exhibiting a relative absence of hemorrhage and hemosiderin deposition. Osteoid formation is noted less often than in giant cell granulomas.

Surgical excision is the treatment of choice for giant cell tumors. Promising clinical results have been associated with the use of antiosteoclastogenic drugs (bisphosphonates, monoclonal antibody to RANK ligand). These lesions exhibit a greater tendency to recur after treatment than do giant cell granulomas. Although too few cases have been reported in the jaws to predict recurrence rates, it is noteworthy that 30% of lesions in long bones recur after curettage.

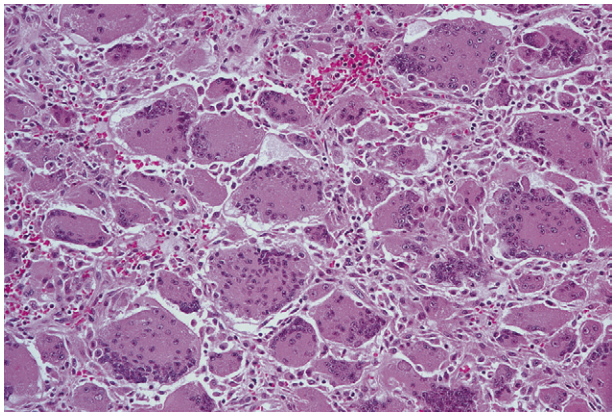

■ **FIGURE 12-26 Giant cell tumor** showing particularly large giant cells with abundant nuclei.

HEMANGIOMA OF BONE

Hemangiomas of bone are rare intraosseous vascular malformations that, when seen in the jaws, can mimic both odontogenic and nonodontogenic lesions. Difficult-to-control hemorrhage is a notable complication of surgical intervention.

Clinical Features

More than half of central hemangiomas of the jaws occur in the mandible, especially the posterior region. The lesion occurs approximately twice as often in females as in males. The peak age of discovery is the second decade of life.

A firm, slow-growing, asymmetric expansion of the mandible or maxilla is the most common patient complaint. Spontaneous gingival bleeding around teeth in the area of the hemangioma may also be noted. Paresthesia or pain, as well as vertical mobility of involved teeth, is occasionally evident. Bruits or pulsation of large lesions may be detected with careful auscultation or palpation of the thinned cortical plates. Trophic effects of the hemangioma on adjacent hard and soft tissues are common. Significantly, hemangiomas may be present with no signs or symptoms.

Radiographically, more than half of jaw hemangiomas occur as multilocular radiolucencies that have a characteristic soap bubble appearance (Figure 12-27). A second form of these lesions consists of a rounded, radiolucent lesion in which bony trabeculae radiate from the center of the lesion, producing angular loculations. Less commonly, hemangiomas appear as cystlike radiolucencies. The lesions may produce resorption of the roots of teeth in the area.



■ **FIGURE 12-27 Hemangioma of bone** showing honeycomb radiographic pattern with associated root resorption.

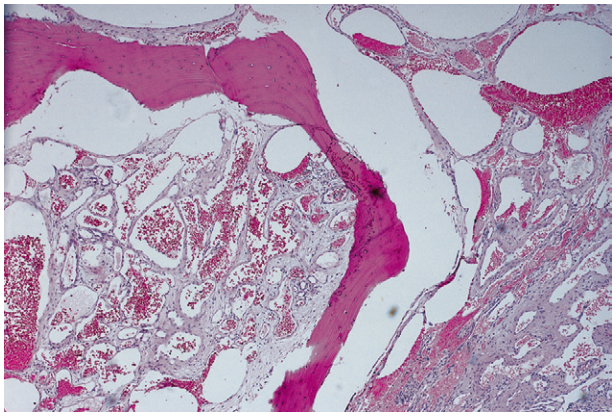

■ **FIGURE 12-28 Hemangioma of bone.** Note numerous vascular channels surrounded by trabeculae of bone.

Histopathology

Hemangiomas of bone represent a proliferation of blood vessels (Figure 12-28). Most intrabony hemangiomas are of the cavernous type (large-caliber vessels); fewer are of the capillary type (small-caliber vessels). However, separation of hemangiomas into one of these two microscopic subtypes is academic, because no differences in biological behavior are noted.

Differential Diagnosis

The differential diagnosis of multilocular hemangioma of bone includes ameloblastoma, odontogenic myxoma, odontogenic keratocyst, CGCG, and aneurysmal bone cyst. A unilocular lesion may be easily confused with other cystic processes that occur within the jaws. Angiography often provides useful information in establishing the diagnosis of hemangioma.

BOX 12-11 LANGERHANS CELL DISEASE: CLASSIFICATION

Eosinophilic granuloma (chronic localized): solitary or multiple bone lesions
Hand-Schüller-Christian (chronic disseminated): bone lesions, exophthalmos, diabetes insipidus
Letterer-Siwe (acute disseminated): bone, skin, internal organs affected

Treatment and Prognosis

The most significant feature of hemangioma of bone is that these lesions may prove life threatening if improperly managed. Extraction of teeth in an area involved by a central vascular lesion may result in potentially fatal bleeding. It is imperative to perform needle aspiration of any central lesion that may be of vascular origin before performing a biopsy.

Methods used in the treatment of hemangioma of bone include surgery, radiation therapy, sclerosing agents, cryotherapy, and presurgical embolization techniques. The vascular supply of a given lesion, as well as its size and location, must be evaluated before a given treatment method is selected.

LANGERHANS CELL DISEASE

Langerhans cell disease (LCD), formerly known as *histiocytosis X* and *idiopathic histiocytosis,* is a disorder characterized by a proliferation of cells exhibiting phenotypic characteristics of Langerhans cells. Clinical manifestations of this process range from solitary or multiple bone lesions to disseminated visceral, skin, and bone lesions.

Historically, the term *histiocytosis X* was used to encompass three disorders: eosinophilic granuloma, Hand-Schüller-Christian syndrome, and Letterer-Siwe disease (Box 12-11). These entities were grouped together because of their similar microscopic appearance, despite the diverse manner of clinical disease expression. *Eosinophilic granuloma,* or *chronic localized LCD,* refers to solitary or multiple bone lesions only. *Hand-Schüller-Christian syndrome,* or *chronic disseminated LCD,* is a specific clinical triad of lytic bone lesions, exophthalmos, and diabetes insipidus. Many affected persons also exhibit lymphadenopathy, dermatitis, splenomegaly, or hepatomegaly. *Letterer-Siwe disease,* or *acute disseminated LCD,* is a malignant process characterized by a rapidly progressive, often fatal course. Widespread organ, bone, and skin involvement by the proliferative process in infants has been the common presentation.

BOX 12-12 LANGERHANS CELL DISEASE

Proliferation of Langerhans cells
- Cells are CD1a+ and S-100+
- Cells contain Birbeck granules (ultrastructure)

Few macrophages (histiocytes) are present
Cause unknown
Any age; three variants
Radiograph shows punched-out noncorticated lesions or "floating teeth"
Several treatment options
Prognosis good to excellent; depends on form

Etiology and Pathogenesis

The etiology and pathogenesis of LCD remain obscure, although the cell of origin is now known (Box 12-12). Ultrastructural and immunohistochemical similarities have demonstrated that LCD tumor cells are similar to normal Langerhans cells that reside in epidermis and mucosa. How LCD develops from normal Langerhans cells or their precursor cells is unknown.

The acute form of this disease and some cases of the chronic forms are thought to represent a neoplastic transformation. However, abnormalities of DNA content in the proliferative cells have been demonstrated in only a few cases of LCD. More recent investigations in a limited number of patients have demonstrated clonal proliferation of Langerhans cells, supporting the concept of a neoplastic process. It has been suggested that the disease may result from exuberant reaction to an unknown antigenic challenge. Evidence is emerging that some patients with LCD may exhibit defects in certain aspects of the cell-mediated arm of the immune system. A deficiency of suppressor T cells, as well as low levels of serum thymic factor, suggests the presence of a thymic abnormality in this disease. These immunologic defects may affect normal regulatory mechanisms, with resultant Langerhans cell proliferation.

Clinical Features

LCD is generally a condition of children and young adults, but the age range extends to older adults. Monostotic and polyostotic forms of the disorder may affect virtually any bone of the body. The skull, mandible, ribs, vertebrae, and long bones are often involved (Figure 12-29). Oral changes may be the initial presentation in all forms of this disorder. Skin, mucosal, or bone involvement in the head and neck region was noted in more than 80% of children in one study. Tenderness, pain, and swelling are common patient complaints. Loosening of teeth in the area of the affected alveolar bone is a common occurrence. The gingival tissues are often inflamed, hyperplastic, and ulcerated. Oral mucosal lesions in the form of submucosal nodules, ulcers, and leukoplakia have been described.

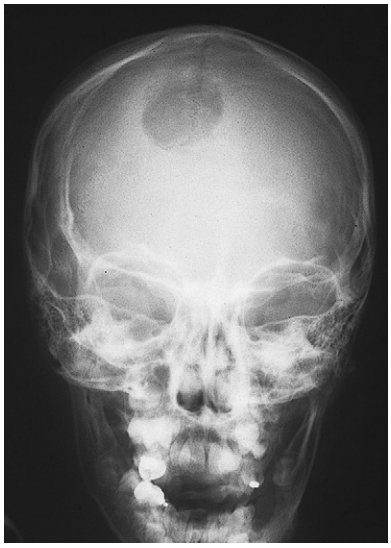

■ **FIGURE 12-29 Langerhans cell disease** of the skull. (Reproduced with permission from Regezi JA, Sciubba JJ, Pogrel MA: Atlas of Oral and Maxillofacial Pathology. Philadelphia, 2000, WB Saunders, Figure 8-24.)

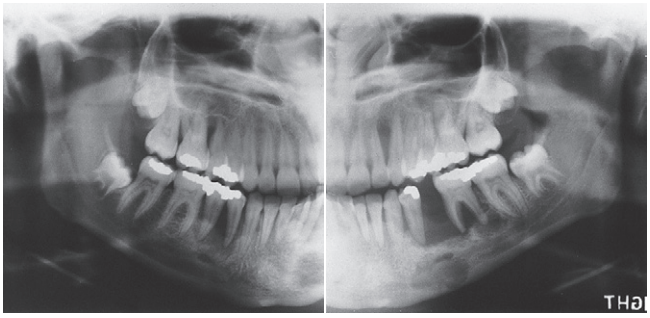

■ **FIGURE 12-30 Langerhans cell disease.** Note bilateral mandibular lesions.

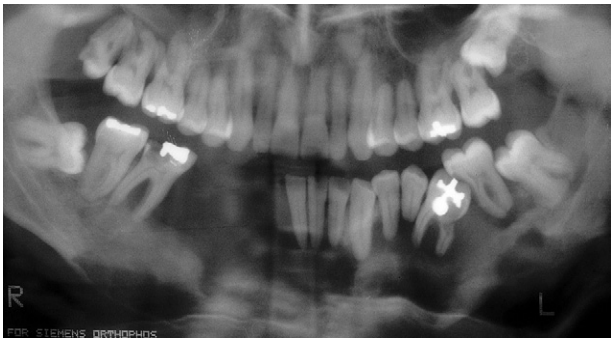

■ **FIGURE 12-31 Langerhans cell disease** resulting in marked destruction of the mandible. (Courtesy Dr. Jerry R. Sorensen.)

The jaws may exhibit solitary or multiple radiolucent lesions (Figures 12-30 and 12-31). Lesions often affect the alveolar bone, causing the teeth to appear as if they were floating in space. Bone lesions with a sharply circumscribed, punched-out appearance may occur in the central aspect of the mandible or maxilla. These lesions occasionally are

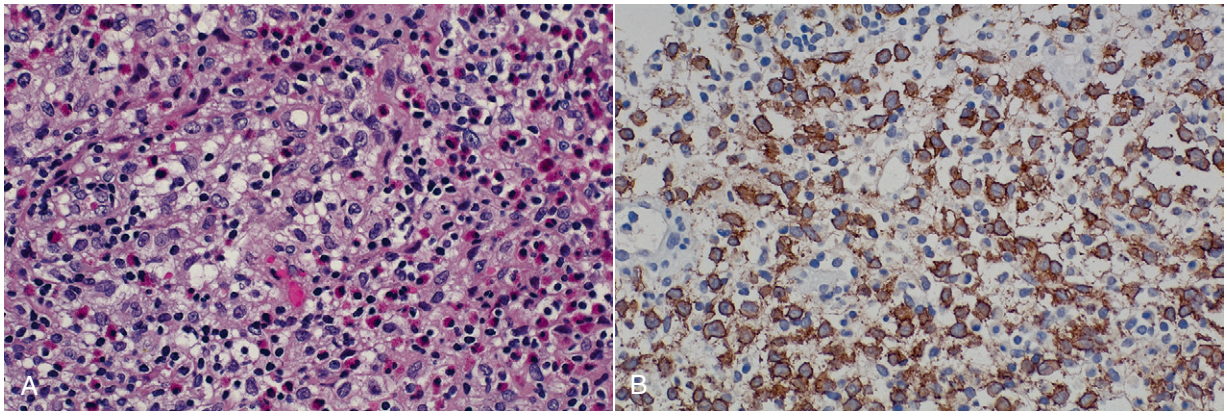

■ **FIGURE 12-32 Langerhans cell disease. A,** Lesion is composed of pale Langerhans cells, eosinophils, and other chronic inflammatory cells. **B,** Immunohistochemical stain for Langerhans cell–specific CD1a antigen shows positive staining *(brown)* of tumor cells.

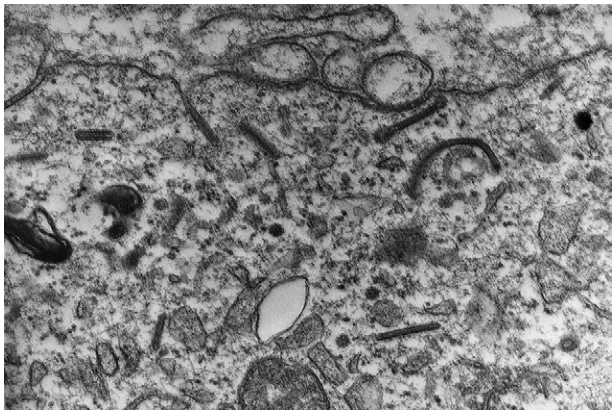

■ **FIGURE 12-33 Langerhans cell disease,** electron micrograph of tumor cell cytoplasm exhibiting rod-shaped Langerhans cell (Birbeck) granules.

located exclusively in a periapical site, where they may mimic periapical inflammatory lesions. Jaw lesions may be accompanied by bone involvement elsewhere in the skeleton. Cervical lymphadenopathy, mastoiditis, and otitis media are head and neck manifestations that often present with multifocal involvement.

Histopathology

LCD is characterized by the proliferation of large cells with abundant cytoplasm, indistinct cell borders, and oval to reniform nuclei. These cells most often are arranged in sheets and may be admixed with various numbers of eosinophils and other inflammatory cells (Figure 12-32). A second population of macrophages is often evident. Multinucleated giant cells and foci of necrosis may be noted. The ultrastructure of the tumor cells shows unique, rod-shaped cytoplasmic structures, which are identical to Birbeck granules, present in normal Langerhans cells (Figure 12-33). Immunohistochemical stains show that the tumor cells express CD1a antigen, S-100 protein, and human leukocyte antigens (HLA)-DR; this is also characteristic of normal Langerhans cells. It should be noted that CD1a is a specific marker for normal Langerhans cells and the pathologic cells in LCD. The monoclonal antibody reactive to CD1a is effective for immunohistochemical analysis of formalin-fixed tissue, replacing the less specific anti–S-100 protein for the confirmation of LCD.

Differential Diagnosis

The classic presentation of LCD in the jaws often results in loosening or premature exfoliation of teeth and precocious eruption of permanent teeth. Under these conditions, a differential diagnosis should include juvenile or diabetic periodontitis, hypophosphatasia, leukemia, cyclic neutropenia, agranulocytosis, and primary or metastatic malignant neoplasms. Lesions located in a periapical site may be confused with a periapical cyst or granuloma; the presence of pulp vitality excludes this possibility.

Solitary radiolucent lesions in the central aspects of the jaws should be differentiated from odontogenic tumors and cysts. Numerous well-circumscribed radiolucencies may suggest multiple myeloma, although this occurs in a much older age group. Histologic examination of tissue removed for a biopsy generally serves to distinguish this disorder from the other entities listed.

Treatment and Prognosis

The acute disseminated form commonly occurs during the first years of life and pursues a rapidly progressive course. The primary method of treatment involves the use of chemotherapeutic agents (Box 12-13). The disease may be fatal despite intensive treatment. Patients with a poor prognosis have been treated with allogenic bone marrow transplantation with some success.

BOX 12-13 LANGERHANS CELL DISEASE: TREATMENT

LOCALIZED DISEASE
Curettage
Radiation, low dose
Intralesional corticosteroid injection
Rare spontaneous regression

DISSEMINATED DISEASE
Immunosuppressive agents, corticosteroids

Disseminated visceral and bone involvement in somewhat older children often behaves in a more chronic fashion. Individual lesions may be managed effectively with surgical curettage or low-dose radiation therapy. Cytotoxic agents, such as vincristine sulfate, cyclophosphamide, and methotrexate, often in conjunction with systemic corticosteroids, may be used for widespread or visceral involvement. The prognosis in this form of the disease is more optimistic, with half of patients surviving for 10 to 15 years.

The localized form of LCD occurs in older children, adolescents, and young adults. These lesions may be treated successfully with vigorous surgical curettage, although intralesional corticosteroid injections and low-dose radiotherapy have been reported to be effective. Spontaneous regression of restricted disease has been reported, making treatment in some cases unnecessary. Involved teeth generally are sacrificed at the time of surgical therapy because of the absence of bony support. The prognosis for this form of the disorder is good. Patients must be evaluated for additional bone or visceral involvement, which is usually manifested within the first 6 months after detection of the original lesion. Long-term follow-up is necessary to rule out the possibility of recurrent disease.

TORI AND EXOSTOSES

Tori and exostoses are nodular protuberances of mature bone; their precise designation depends on the anatomic location. These lesions are of little clinical significance. They are non-neoplastic and rarely are a source of discomfort. The mucosa surfacing these lesions occasionally may be traumatically ulcerated, producing a slow-healing, painful wound or, less commonly, osteomyelitis. Surgical removal for the purpose of prosthetic rehabilitation may be necessary.

Etiology and Pathogenesis

The precise cause of these lesions remains obscure, although evidence has suggested that the torus may be an inherited condition. A simple dominant pattern of inheritance was identified for palatal tori in a study of Venezuelan and Japanese populations. One investigator has indicated that both genetic and environmental factors determine the development of mandibular tori. The palatal torus is relatively prevalent in certain populations such as Asians, Native Americans, and the Inuit (Eskimos). Incidence in the general population of the United States is between 20% and 25%.

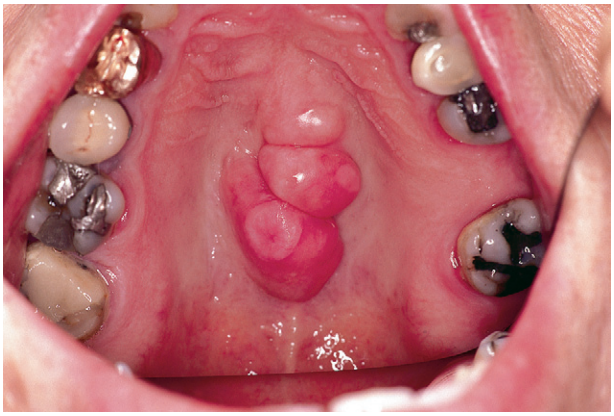

■ **FIGURE 12-34** Torus palatinus with mucosal ulceration.

Mandibular tori are seen more commonly in certain groups such as blacks and some Asian populations. Overall incidence in the United States is estimated to be between 6% and 12%. The presence of mandibular tori was studied in patients with migraine headaches and temporomandibular disorders. A positive association suggested a possible role of parafunctional habits in the origin of this condition.

The cause of exostoses is unknown. It has been suggested that the bony growths represent a reaction to increased or abnormal occlusal stresses of the teeth in involved areas.

Clinical Features

Torus Palatinus. The palatal torus is a sessile, nodular mass of bone that appears along the midline of the hard palate (Figure 12-34). This lesion occurs in females twice as often as it does in males in some populations, with significant racial and ethnic differences reported. The palatal torus usually appears during the second or third decade of life, although it may be noted at any age. The bony mass exhibits slow growth and generally is asymptomatic. These lesions are often present in a symmetric fashion along the midline of the hard palate. Tori have been noted to form various configurations such as nodular, spindled, lobular, or flat. Large tori may be evident on radiographs as diffuse radiopaque lesions.

Torus Mandibularis. Mandibular tori are bony exophytic growths that appear along the lingual aspect of the mandible superior to the mylohyoid ridge (Figure 12-35). These tori are almost always bilateral, occurring in the premolar region. Infrequently, a torus may be noted on one side only. These



■ **FIGURE 12-35** Torus mandibularis.



■ **FIGURE 12-37** Buccal exostosis.



■ **FIGURE 12-36** Buccal exostosis.

lesions are asymptomatic, exhibiting slow growth during the second and third decades of life.

Mandibular tori may arise as solitary nodules or as multiple nodular masses that appear to coalesce. A significant gender predilection is not evident. It is curious that mandibular and palatal tori do not often occur together in the same individual.

Exostoses. Exostoses are multiple (or single) bony excrescences that are less common when compared with tori. They are asymptomatic bony nodules that are present along the buccal aspect of alveolar bone (Figures 12-36 and 12-37). Lesions are noted most often in the posterior portions of both the maxilla and the mandible. Rarely, exostoses have occurred under skin grafts to gingiva (vestibuloplasties) and subjacent to pontics of fixed bridges.

Histopathology

These lesions are composed of hyperplastic bone consisting of mature cortical and trabecular bone. The outer surface exhibits a smooth, rounded contour.

Treatment and Prognosis

Treatment of tori and exostoses is unnecessary unless it is required for prosthetic considerations, or in cases of frequent trauma to the overlying mucosa. Recurrence after surgical excision is only rarely seen.

CORONOID HYPERPLASIA

Hyperplasia of the coronoid processes of the mandible is an uncommon condition that is often associated with limited mandibular motion.

Etiology and Pathogenesis

The cause of this process remains unknown. A history of trauma is present in many instances; however, the precise relationship between the traumatic episode and the onset of coronoid enlargement has been difficult to establish. Coronoid enlargement appears to represent a hyperplastic process, although it has been suggested that the lesion may be neoplastic. Unilateral coronoid hyperplasia may be the result of a solitary osteochondroma; bilateral coronoid hyperplasia is apparently the result of a different process. Most cases have been reported in males, leading some investigators to suggest an X-linked inherited origin. However, some cases have been reported in females—a finding that seems to preclude this possibility. Increased activity of the temporalis muscle with unbalanced condylar support has also been postulated as a causative factor.

Clinical Features

Hyperplasia of the coronoid processes is often bilateral, although unilateral enlargement has been noted. Bilateral coronoid hyperplasia typically results in limited mandibular movement, which is progressive over time.

The disorder is usually painless and, with a few exceptions, is not associated with facial swelling or asymmetry.

Coronoid hyperplasia has been reported most often in young male patients. The age of onset is typically around puberty, although presentation for evaluation may be delayed for many years. Some cases have been noted, especially in females, before puberty and during adult life.

Enlarged and elongated coronoid processes are evident radiographically, although the general shape of the processes is usually normal. Unilateral coronoid hyperplasia often results in misshapen or mushroom-shaped coronoid processes on radiographs. Temporomandibular joint radiographs are unremarkable.

Histopathology

Enlarged coronoid processes consist of mature, hyperplastic bone. The bone may be partially covered by cartilaginous and fibrous connective tissue.

Differential Diagnosis

Bilateral coronoid hyperplasia rarely presents diagnostic difficulties. However, cases of unilateral coronoid hyperplasia must be differentiated from osseous and chondroid neoplasms.

Treatment and Prognosis

Treatment consists of surgical excision of the hyperplastic coronoid processes. Postoperative physiotherapy is also advocated. Long-term functional improvement has been variably successful as measured by an increase in mouth opening after surgical intervention. Recurrence has been reported rarely.

BIBLIOGRAPHY

Alawi F: Benign fibro-osseous diseases of the maxillofacial bones: a review and differential diagnosis. Am J Clin Pathol 118:S50–S70, 2002.

Allen CE, McClain KL: Langerhans cell histiocytosis: a review of past, current and future therapies. Drugs Today (Barc) 43:627–643, 2007.

Brannon RB, Fowler CB: Benign fibro-osseous lesions: a review of current concepts. Adv Anat Pathol 8:126–143, 2001.

Bridge JA: Cytogenetics and experimental models. Curr Opin Oncol 8:284–288, 1996.

Bunel K, Sindet-Pedersen A: Central hemangioma of the mandible. Oral Surg Oral Med Oral Pathol 75:565–570, 1993.

Candelere GA, Glorieux FH, Prud'homme J et al: Increased expression of the C-fos proto-oncogene in bone from patients with fibrous dysplasia. N Engl J Med 332:1546–1551, 1995.

Carinci F, Piattelli A, Martinelli M et al: Genetic profiling of central giant cell granuloma of the jaws. J Craniofac Surg 16:399–407, 2005.

Chapurlat RD, Orcel P: Fibrous dysplasia of bone and McCune-Albright syndrome. Best Pract Res Clin Rheumatol 22:55–69, 2008.

Clifford T, Lamey PJ, Fartash L: Mandibular tori, migraine and temporomandibular disorders. Br Dent J 180:382–384, 1996.

Dal Cin P, Scoit R, Brys P et al: Recurrent chromosome aberrations in fibrous dysplasia of the bone: a report of the CHAMP study group: chromosomes and morphology. Cancer Genet Cytogenet 122:30–32, 2000.

de Lange J, van den Akker HP: Clinical and radiological features of central giant-cell lesions of the jaw. Oral Surg Oral Med Oral Pathol Oral Radiol Endod 99:464–470, 2005.

de Lange J, van den Akker HP, van den Berg H: Central giant cell granuloma of the jaws: a review of the literature with emphasis on therapy options. Oral Surg Oral Med Oral Pathol Oral Radiol Endod 104:603–615, 2007.

Egeler RM, D'Angio GJ: Langerhans cell histiocytosis. J Pediatr 127:1–11, 1995.

Engel JD, Supancic JS, Davis LF: Arteriovenous malformation of the mandible: life-threatening complications during tooth extraction. J Am Dent Assoc 126:237–242, 1995.

Feller L, Wood NH, Khammissa RAG et al: The nature of fibrous dysplasia. Head Face Med 5:22–26, 2009.

Fili S, Karalaki M, Schaller B: Therapeutic implications of osteoprotegrin. Cancer Cell Int 9:26–33, 2009.

Giannico G, Holt GE, Holmar KC et al: Osteoblastoma characterized by a three-way translocation: report of a case and review of the literature. Cancer Genet Cytogenet 195:168–171, 2009.

Idowu BD, Thomas G, Frow R et al: Mutations in SH3BP2, the cherubism gene, were not detected in central or peripheral giant cell tumours of the jaw. Br J Oral Maxillofac Surg 46:229–230, 2008.

Harris M: Central giant cell granulomas of the jaws regress with calcitonin therapy. Br J Oral Maxillofac Surg 31:89–94, 1993.

Haug RH, Hauer C, DeCamillo AJ et al: Benign osteoblastoma of the mandible: report of a case. J Oral Maxillofac Surg 48:743–748, 1990.

Hegtvedt AK, Terry BC, Burkes EJ et al: Skin graft vestibuloplasty exostosis: a report of two cases. Oral Surg Oral Med Oral Pathol 69:149–152, 1990.

Hopkins KM, Huttula CS, Kahn MA et al: Desmoplastic fibroma of the mandible: review and report of two cases. J Oral Maxillofac Surg 54:1249–1254, 1996.

Kaban LB, Mulliken JR, Ezekowitz RA et al: Antiangiogenic therapy of a recurrent giant cell tumor of the mandible with interferon alfa-2a. Pediatrics 103:1145–1149, 1999.

Kaplan I, Calderon S, Buchner A: Peripheral osteoma of the mandible: a study of 10 new cases and analysis of the literature. J Oral Maxillofac Surg 52:467–470, 1994.

Kauzman A, Li SQ, Bradley G et al: Central giant cell granuloma of the jaws: assessment of cell cycle proteins. J Oral Pathol Med 33:170–176, 2004.

Landesberg R, Eisig S, Fennoy I et al: Alternative indications for bisphosphonate therapy. J Oral Maxillofac Surg 67(5 suppl):27–34, 2009.

Lee JS, Tartaglia M, Gelb BD et al: Phenotypic and genotypic characterisation of Noonan-like/multiple giant cell lesion syndrome. J Med Genet 42:e11–e15, 2005.

Lucas DR, Unni KK, McLeod RA et al: Osteoblastoma: clinicopathologic study of 306 cases. Hum Pathol 25:117–134, 1994.

MacDonald-Jankowski DS: Fibroosseous lesions of the face and jaws. Clin Radiol 59:11–25, 2004.

Marie PJ, de Pollak C, Chanson P et al: Increased proliferation of osteoblastic cells expressing the activating Gs alpha mutation in

monostotic and polyostotic fibrous dysplasia. Am J Pathol 150:1059–1069, 1997.

Mascarello JT, Krous HF, Carpenter PM: Unbalanced translocation resulting in the loss of the chromosome 17 short arm in an osteoblastoma. Cancer Genet Cytogenet 69:65–67, 1993.

McLoughlin PM, Hopper C, Bowley NB: Hyperplasia of the mandibular coronoid process: an analysis of 31 cases and a review of the literature. J Oral Maxillofac Surg 53:250–255, 1995.

O'Malley M, Pogrel MA, Stewart JCB et al: Central giant cell granulomas of the jaws: phenotype and proliferation-associated markers. J Oral Pathol Med 26:159–163, 1997.

Pammer J, Weninger W, Hulla H et al: Expression of regulatory apoptotic proteins in peripheral giant cell granulomas and lesions containing osteoclast-like giant cells. J Oral Pathol Med 27:267–271, 1998.

Petrikowski CG, Pharoah MJ, Lee L: Radiographic differentiation of osteogenic sarcoma, osteomyelitis, and fibrous dysplasia of the jaws. Oral Surg Oral Med Oral Pathol Oral Radiol Endod 80:744–750, 1995.

Pogrel MA: The management of lesions of the jaws with liquid nitrogen cryotherapy. J Calif Dent Assoc 23:54–57, 1995.

Polandt K, Engels C, Kaiser E et al: Gs alpha gene mutations in monostotic fibrous dysplasia of bone and fibrous dysplasia-like low-grade central osteosarcoma. Virchows Arch 439:170–175, 2001.

Riminucci M, Fisher LW, Shenker A et al: Fibrous dysplasia of bone in the McCune-Albright syndrome. Am J Pathol 151:1587–1600, 1997.

Sakamoto A, Oda Y, Iwamoto Y et al: A comparative study of fibrous dysplasia and osteofibrous dysplasia with regard to Gs alpha mutation at the Arg201 codon: polymerase chain reaction-restriction fragment length polymorphism analysis of paraffin-embedded tissues. J Mol Diagn 2:67–72, 2000.

Seah YH: Torus palatinus and torus mandibularis: a review of the literature. Aust Dent J 40:318–321, 1995.

Shapeero LG, Vanel D, Ackerman LV et al: Aggressive fibrous dysplasia of the maxillary sinus. Skeletal Radiol 22:563–568, 1993.

Slootweg PJ, Muller H: Differential diagnosis of fibroosseous lesions: a histological investigation of 30 cases. J Craniomaxillofac Surg 18:210–214, 1990.

Slootweg PJ, Panders AK, Koopmans R et al: Juvenile ossifying fibroma: an analysis of 33 cases with emphasis on histopathological aspects. J Oral Pathol Med 23:385–388, 1994.

Souza PEA, Paim JFO, Carvalhais JN et al: Immunohistochemical expression of p53, MDM2, Ki-67 and PCNA in central giant cell granuloma and giant cell tumor. J Oral Pathol Med 28:54–58, 1999.

Soysa NS, Alles N: NF-kappaB functions in osteoclasts. Biochem Biophys Res Commun 378:1–5, 2009.

Stoll M, Freund M, Schmid H et al: Allogeneic bone marrow transplantation for Langerhans cell histiocytosis. Cancer 66:284–288, 1990.

Takeuchi T, Takenoshita Y, Kubo K et al: Natural course of jaw lesions in patients with familial adenomatosis coli (Gardner's syndrome). Int J Oral Maxillofac Surg 22:226–230, 1993.

Terry BC, Jacoway JR: Management of central giant cell lesions: an alternative to surgical therapy. Oral Maxillofac Surg Clin North Am 6:579–600, 1994.

Thomas DM, Skubitz KM: Giant cell tumour of bone. Curr Opin Oncol 21:338–344, 2009.

Titgemeyer C, Grois N, Minkov M et al: Pattern and course of single-system disease in Langerhans cell histiocytosis data from the DAL-HX 83- and 90-study. Med Pediatr Oncol 37:108–114, 2001.

Ueno H, Ariji E, Tanaka T et al: Imaging features of maxillary osteoblastoma and its malignant transformation. Skeletal Radiol 23:509–512, 1994.

Waldron CA: Fibro-osseous lesions of the jaws. J Oral Maxillofac Surg 51:828–835, 1993.

Whitaker SB, Waldron CA: Central giant cell lesions of the jaws: a clinical, radiologic, and histopathologic study. Oral Surg Oral Med Oral Pathol 75:199–208, 1993.

Willman CL, Busque L, Griffith BB et al: Langerhans'-cell histiocytosis (histiocytosis X): a clonal proliferative disease. N Engl J Med 331:154–160, 1994.

CHAPTER 13

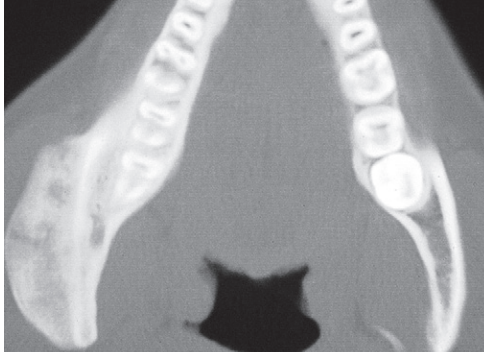

Inflammatory Jaw Lesions

PULPITIS

PERIAPICAL ABSCESS

ACUTE OSTEOMYELITIS

CHRONIC OSTEOMYELITIS (CHRONIC OSTEITIS)

Bisphosphonate-Related Osteonecrosis
Chronic Osteomyelitis With Proliferative Periostitis (So-called Garré's Osteomyelitis)
Diffuse Sclerosing Osteomyelitis
Focal Sclerosing Osteitis

Osteomyelitis, by definition, is inflammation, not necessarily infection (by a microorganism), of bone and bone marrow. The term *osteitis* may be substituted for *osteomyelitis* to indicate inflammation of bone. In the mandible and maxilla, most cases are related to a microbial (usually bacterial) infection that reaches the bone through nonvital teeth, periodontal lesions, or traumatic injuries. This, coupled with the patient's host resistance factors, determines the clinical presentation, the extent of the inflammatory process, and the speed with which the infection develops. Recognized subtypes of osteomyelitis are closely related and essentially represent differences in the causative agent and the host response. The primary justification for separation of osteomyelitis into various subtypes lies in the differences in treatment and prognosis for each. It is important to be aware of clinical and radiographic presentations when making differential diagnoses of bone lesions.

PULPITIS

All the principles of inflammation that apply to any other body organ apply to lesions of the dental pulp. In addition, dental pulp has some unique features that make it unusually fragile and sensitive. First, it is encased by hard tissue (dentin/enamel) that does not allow for the usual swelling associated with the exudate of the acute inflammatory process. Second, there is no collateral circulation to maintain vitality when the primary blood supply is compromised. Third, biopsies and direct applications of medication are impossible without causing necrosis of the entire pulp. Fourth, pain and increasing levels of sensitivity are the only signs that can be used to determine the severity of pulpal inflammation.

Because of referred pain and the lack of proprioceptors (position sensors) in the pulp, localizing the problem to the correct tooth can often be a considerable diagnostic challenge. Also there may be a poor correlation between clinical symptoms and pathologic changes occurring in the pulp. The level of pulpal inflammation is determined through a combination of clinical criteria. Results of electric, heat, cold, and percussion tests must be added to the patient history, clinical

examination, and clinician experience to arrive at the most appropriate diagnosis for the correct tooth. Generally, the more intense the pain and the longer the duration of symptoms, the greater the damage to the pulp. Severe symptoms usually indicate irreversible damage.

Etiology. In the dental pulp, just as it is in any other tissue, inflammation is the response to injury. In addition, the pulpal response includes stimulation of odontoblasts to deposit reparative dentin at the site to help protect the pulp. If the injury is severe, the result is, instead, necrosis of these cells.

Caries is the most common form of injury that causes pulpitis. The degree of damage depends on the rapidity and extent of hard tissue destruction. Entry of bacteria into the pulpal tissue through a carious lesion is not necessary for pulpitis to occur, but this appears to be an important factor in the intensification of the inflammatory response. Pulpal microbiology adjacent to carious dentin demonstrates a diverse flora, including gram-positive anaerobes low numbers of lactobacilli. Operative dental procedures associated with cavity and crown preparations may also trigger an inflammatory response in the dental pulp. The heat, friction, chemicals, and filling materials associated with restoration of teeth are all potential irritants. It is well known that less damage occurs when a cooling water spray is used during tooth preparation than when no water is used. It is also well established that an insulating base (such as zinc oxide and eugenol under amalgam restorations or glass ionomer under a composite restoration) can provide significant protection of the pulp from irritating chemicals used in the preparation of nonmetallic restorative materials and from heat transferred through large metallic fillings.

Other types of injury that may trigger pulpitis are trauma, especially when it is severe enough to cause root or crown fracture, and periodontal disease that has extended to an apical or lateral root foramen.

Clinical and Histopathologic Features. Several detailed classifications of pulpitis that are based on histopathologic changes have been proposed. Because of the difficulty in correlating clinical features with microscopy, these schemes have proved to be of little practical value. Instead, most practitioners prefer a simple classification that is helpful in the clinical setting relative to treatment and prognosis (Table 13-1).

Focal Reversible Pulpitis. Focal reversible pulpitis is an acute, mild inflammatory pulpal reaction that typically follows carious destruction of a tooth or placement of a large metallic filling without an insulating base. It causes hypersensitivity to thermal and electrical stimuli. The pain is mild to moderate and is typically intermittent. As the name implies, the changes are focal (subjacent to the injurious agent) and reversible if the cause is removed. Microscopically, the predominant feature is dilation and engorgement of blood vessels (hyperemia). Exudation of plasma proteins also occurs, but this is difficult to appreciate in microscopic sections.

Acute Pulpitis. The inflammatory response of acute pulpitis may occur as progression of focal reversible pulpitis, or it may represent an acute exacerbation of an already established chronic pulpitis. Pulpal damage may range in severity from simple acute inflammation marked by vessel dilation, exudation, and neutrophil chemotaxis to focal liquefaction necrosis (pulp abscess) to total pulpal suppurative necrosis. Constant, severe, tooth-associated pain is the usual presenting complaint. Pain is intensified with the application of heat or cold, although in cases in which liquefaction of the pulp has occurred, cold may in fact alleviate the symptoms. If there is an opening from the pulp to the oral environment, symptoms may be lessened because of escape of the exudate that causes pressure on and chemical irritation of pulpal and periapical nerve tissues.

In the early phases of acute pulpitis, the tooth may be hyperreactive to electrical stimulation, but as pulp damage increases, sensitivity is reduced until there is no response. Because the exudate is confined primarily to the pulp rather than the periapical tissues, percussion tests generally elicit a response that differs little from normal.

Chronic Pulpitis. Chronic pulpitis is an inflammatory reaction that results from long-term, low-grade injury or occasionally from quiescence of an acute process. Symptoms, characteristically mild and often intermittent, appear over an extended period. A dull ache may be the presenting complaint, or the patient may have no symptoms at all. As the pulp deteriorates, responses to thermal and electrical stimulation are reduced. Microscopically, lymphocytes, plasma cells, and fibrosis appear in the chronically inflamed pulp. Unless an acute exacerbation of the chronic process occurs, neutrophils are not evident.

TABLE 13-1 PULPITIS AND PERIAPICAL DISEASES

	Pain	Vitality Tests	Radiographs
Reversible pulpitis	Mild	Reversible sensitivity to cold	No change
Acute pulpitis	Severe, constant	Hyperresponse to none	No change
Chronic pulpitis	Mild, intermittent	Reduced response	No change
Acute periapical abscess	Severe; pain on percussion	No response	No change
Periapical granuloma	None to slight	No response	Lucency
Periapical cyst	None to slight	No response	Lucency

Chronic Hyperplastic Pulpitis. This special form of chronic pulpitis occurs in the molar teeth (both primary and permanent) of children and young adults. Involved teeth exhibit large carious lesions that open into the coronal pulp chamber. Rather than undergoing necrosis, the pulp tissue reacts in a hyperplastic manner, producing a red mass of reparative granulation tissue that extrudes through the pulp exposure. This type of reaction is believed to be related to the open root foramen, through which a relatively rich blood supply flows.

Symptoms seldom occur because there is no exudate under pressure, and generally no nerve tissue is proliferating with the granulation tissue. Although the pulp tissue is viable, the process is not reversible, and endodontic therapy or tooth extraction may be necessary. The well-vascularized granulation tissue mass often becomes epithelialized, presumably by autotransplantation of epithelial cells from nearby mucosal surfaces.

Treatment and Prognosis. If the cause is identified and eliminated, focal reversible pulpitis should recede, returning the pulp to a normal state. If inflammation progresses into an acute pulpitis with neutrophil infiltrates and tissue necrosis, recovery is unlikely, regardless of attempts to remove the cause. Endodontic therapy or tooth extraction is the only available treatment at this stage.

With chronic pulpitis, pulpal death is the characteristic end result (Figure 13-1). Removal of the cause may slow the process or occasionally may save the vitality of the pulp. Endodontic therapy or extraction is typically required. Chronic hyperplastic pulpitis is essentially an irreversible end stage that is treated with pulp extirpation and an endodontic filling or extraction.

PERIAPICAL ABSCESS

Etiology. Numerous sequelae may follow untreated pulp necrosis and are dependent on the virulence of the microorganisms involved and the integrity of the patient's overall defense mechanisms (Figure 13-2). From its origin in the pulp, the inflammatory process extends into the periapical tissues, where it may present as a granuloma or cyst (if chronic) or an abscess (if acute). Acute exacerbation of a chronic lesion may also be seen. Necrotic pulpal tissue debris, inflammatory cells, and bacteria, particularly anaerobes, all serve to stimulate and sustain the periapical inflammatory process.

Clinical Features. Patients with periapical abscesses typically have severe pain in the area of the nonvital tooth caused by pressure and the effects of inflammatory chemical mediators on nerve tissue. The exudate and neutrophilic infiltrate of an abscess put pressure on surrounding tissue, often resulting in slight extrusion of the tooth from its socket. Pus associated with a lesion, if not focally constrained, seeks the path of least resistance and spreads into contiguous structures (Figures 13-3 to 13-5). The affected area of the jaw may be tender to palpation, and the patient may be hypersensitive

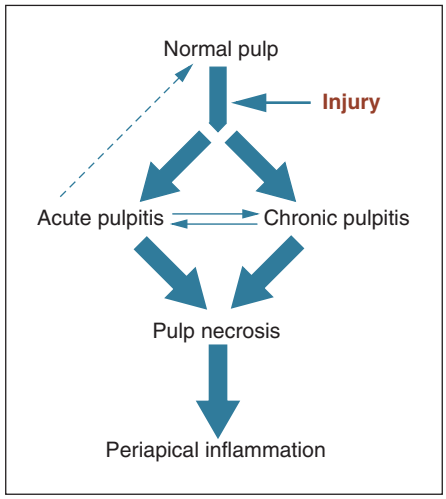

■ **FIGURE 13-1** Pulpitis pathways.

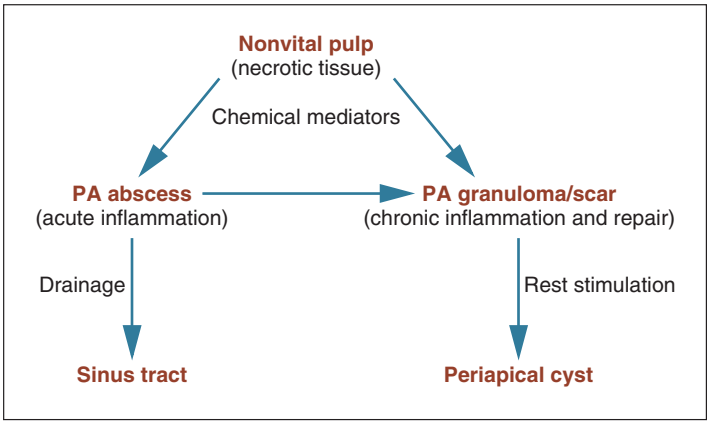

■ **FIGURE 13-2** Pathogenesis of periapical inflammation.



■ **FIGURE 13-3 Parulis (gingival abscess)** in maxillary mucosa and representing pus extension from a periapical abscess.

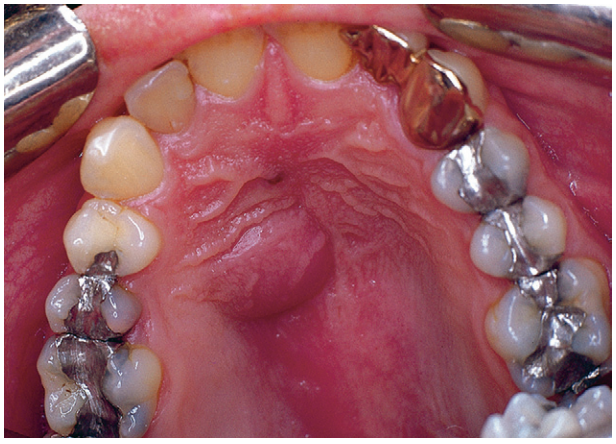

■ **FIGURE 13-4 Palatal abscess** representing extension of a periapical abscess.



■ **FIGURE 13-5 Cutaneous abscess** related to extension from a mandibular periapical abscess.

to tooth percussion. The involved tooth is unresponsive to electrical and thermal tests because of pulp necrosis.

Because of the rapidity with which this lesion develops, time is generally insufficient for significant amounts of bone resorption to occur. Therefore, radiographic changes are slight and usually are limited to mild radiographic thickening of the apical periodontal membrane space. However, if a periapical abscess develops as a result of acute exacerbation of a chronic periapical granuloma, a radiolucent lesion is evident. The *periapical granuloma* represents the result of chronic inflammation at the apex of a nonvital tooth. This is a sequela of pulp necrosis, which may develop through acute or low-grade chronic inflammation. Notably, other, more serious conditions can occur in a periapical position (Box 13-1). Various clinical clues may alert the clinician that the periapical lesion may not be a simple dental granuloma (Box 13-2).

Histopathology. Microscopically, a periapical abscess appears as a zone of liquefaction composed of proteinaceous exudate, necrotic tissue, and viable and dead neutrophils (pus). Adjacent tissue containing dilated vessels and a neutrophilic infiltrate surrounds the area of liquefaction necrosis.

BOX 13-1 PERIAPICAL PATHOLOGY

INFLAMMATORY
Periapical granuloma
Scar
Cyst
Chronic abscess
Actinomycosis

BENIGN
Traumatic bone cyst
Nasopalatine canal cyst
Langerhans cell disease
Adenomatoid odontogenic tumor
Periapical cemento-osseous dysplasia
Ossifying fibroma

BENIGN, AGGRESSIVE
Odontogenic keratocyst
Calcifying odontogenic cyst
Central giant cell granuloma
Ameloblastoma
Calcifying epithelial odontogenic tumor
Myxoma

MALIGNANT
Metastasis
Lymphoma
Myeloma

BOX 13-2 NONINFLAMMATORY PERIAPICAL DISEASE: SIGNS AND SYMPTOMS

Paresthesia or atypical pain
No relationship to periodontal ligament or lamina dura
Large lesions and lesions with ill-defined margins
Tooth vitality positive or equivocal

With chronicity, an abscess develops into a granuloma, which is composed of granulation tissue and fibrous tissue infiltrated by variable numbers of neutrophils, lymphocytes, plasma cells, and macrophages. (*Note:* Periapical granuloma is to be distinguished from granulomatous inflammation, which is a distinctive type of chronic inflammation that is characteristic of certain diseases [e.g., tuberculosis, sarcoidosis, histoplasmosis] and features a predominance of macrophages and often multinucleated giant cells.) Acute flare of a periapical granuloma would show an abundant neutrophilic infiltrate, in addition to granulation tissue and chronic inflammatory cells.

Treatment and Prognosis. Treatment of an acute periapical abscess requires observance of the standard principles of management of acute inflammation. Drainage should be established through an opening in the tooth itself or through the soft tissue surrounding the jaw, if cellulitis has developed. Antibiotics directed against the offending organism are required. Management must be thoughtful and skilled because the consequences of delayed or inappropriate treatment can be significant and occasionally life threatening.

Spread of an abscess may occur through one of several avenues. It may progress through the buccal cortical bone and gingival soft tissue, establishing a natural drain or sinus tract. The same type of situation may occur in the palate or skin; this depends on the original location of the abscess and the path of least resistance. If a drain is not established, the purulent exudate can cause an abscess or *cellulitis* in the soft tissues of the face, oral cavity, or neck. Cellulitis is an acute inflammatory process that is diffusely spread throughout the tissue rather than localized, as with an abscess. This variant is a result of infection by virulent organisms that produce enzymes that allow rapid spread through tissue. Bilateral cellulitis of the submandibular and sublingual spaces has been called *Ludwig's angina.*

A dangerous situation occurs when acute infection involves major blood vessels, possibly resulting in bacteremia. Also, retrograde spread of the infection through facial emissary veins to the cavernous sinus may set up the necessary conditions for thrombus formation. *Cavernous sinus thrombosis* is an often fatal emergency situation.

Treatment of periapical granulomas and cysts is discussed in Chapter 10.

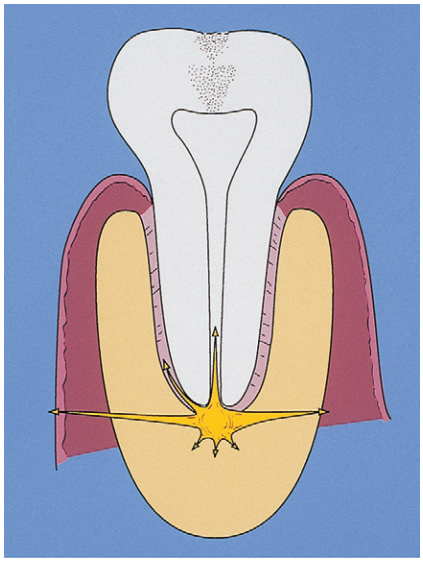

■ **FIGURE 13-6** Potential spread of pus from a mandibular **periapical abscess.** (Reproduced with permission from Regezi JA, Sciubba JJ, Pogrel MA: Atlas of Oral and Maxillofacial Pathology. Philadelphia, 2000, WB Saunders, Figure 10-11.)

ACUTE OSTEOMYELITIS

Etiology. Acute inflammation of the bone and bone marrow of the mandible and maxilla results most often from extension of a periapical abscess (Figure 13-6). The second most common cause of acute osteomyelitis is physical injury, such as occurs with fracture or surgery. Osteomyelitis may also result from bacteremia.

Most cases of acute osteomyelitis are infectious. Almost any organism may be part of the etiologic picture, although staphylococci and streptococci are identified most often.

Clinical Features. Pain is the primary feature of this inflammatory process. Pyrexia, painful lymphadenopathy, leukocytosis, and other signs and symptoms of acute infection are commonly present. Paresthesia of the lower lip occasionally occurs with mandibular involvement. In the development of a clinical differential diagnosis, the presence of this symptom should also suggest malignant mandibular neoplasms.

To be visible by conventional radiography, a lesion must have resorbed or demineralized approximately 60% of the bone. Therefore unless the inflammatory process has been present for some time, radiographic evidence of acute osteomyelitis usually is not present. Over time, diffuse radiolucent changes begin to appear as more bone is resorbed and replaced by infection.

Histopathology. A purulent exudate occupies the marrow spaces in acute osteomyelitis. Bony trabeculae show reduced osteoblastic activity and increased osteoclastic resorption. If an area of bone necrosis occurs (sequestrum), osteocytes are lost and the marrow undergoes liquefaction.

Treatment. Acute osteomyelitis usually is treated with antibiotics and drainage. Ideally, the causative agent is identified, and an appropriate antibiotic is selected through sensitivity testing in the laboratory. Surgery may also be part of the treatment and ranges from simple sequestrectomy to excision with autologous bone replacement. Each case should be judged individually because of variations in disease severity, the organisms involved, and the patient's overall health.

CHRONIC OSTEOMYELITIS (CHRONIC OSTEITIS)

Etiology. Chronic osteomyelitis may be one of the sequelae of acute osteomyelitis (untreated or inadequately treated), or it may represent a long-term, low-grade inflammatory reaction that never went through a significant or clinically noticeable acute phase (Box 13-3 and Table 13-2). In either event, acute and chronic forms of osteomyelitis have many similar causative factors. Most cases are infectious, and, as in most infections, the clinical presentation and the course are directly dependent on the virulence of the microorganism involved and the patient's resistance. The anatomic location, immunologic status, nutritional status, and patient's age, as well as the presence of preexisting systemic factors, such as Paget's disease, osteopetrosis, or sickle cell disease, are other factors that affect the presentation and course.

Identification of a specific infectious agent involved in chronic osteomyelitis is usually difficult both microscopically and microbiologically. Sample error is significant because of small, difficult-to-reach bacterial foci, or because of contamination of the lesion by resident flora. Previously taken antibiotics reduce the chances of culturing the causative organism. Although a causative agent often is not confirmed, most investigators believe that bacteria (e.g., staphylococci, streptococci, *Bacteroides, Actinomyces*) are responsible for the vast majority of cases of chronic osteomyelitis.

Osteoradionecrosis. (See also Chapter 2.) Bone irradiated as part of head and neck cancer treatment is particularly susceptible to infection. Because of reduced vascularity and osteocyte destruction, osteoradionecrosis may occur in up to 20% of patients who have undergone local tumoricidal irradiation. Secondary infection generally follows. Typical precipitating or triggering events include periapical inflammation resulting from nonvital teeth, extractions, periodontal disease, and fractures communicating with skin or mucosa.

Clinical Features. The mandible, especially the molar area, is much more commonly affected than the maxilla. This may relate, in part, to the more diffuse blood supply and the greater proportion of cancellous bone in the maxilla. Pain is usually present but varies in intensity, and it is not necessarily related to the extent of disease. The duration of symptoms is generally proportional to the extent of disease. Swelling of the jaw is a commonly encountered sign; loose teeth and sinus tracts are seen less often. Anesthesia is very uncommon.

Radiographically, chronic osteomyelitis appears primarily as a radiolucent lesion that may show focal zones of opacification. The lucent pattern is often described as moth-eaten because of its mottled radiographic appearance (Figures 13-7 and 13-8). Lesions may be very extensive, and margins are often indistinct.

BOX 13-3 CHRONIC OSTEOMYELITIS/ OSTEITIS

DEFINITION

Inflammation of bone and bone marrow

CLINICAL FEATURES

Symptoms vary from mild to moderate pain
Exudate often not present
Radiographic image mottled; sclerosis typically occurs with time

HISTOPATHOLOGY

Low-grade lesions contain few inflammatory cells
May mimic (clinically and microscopically) benign fibro-osseous lesions

TABLE 13-2 CHRONIC OSTEOMYELITIS: TYPES AND FEATURES

	Etiology	Clinical Features	Radiographs	Treatment
Chronic osteomyelitis	Most infectious (bacteria)	Variable pain, swelling, drainage	Lucent or mottled pattern	Appropriate antibiotic, sequestrectomy
Chronic osteomyelitis with proliferative periostitis	Sequela of tooth abscess, extraction	Usually associated with lower molar; periosteum involved; children	Lucent or mottled pattern with concentric periosteal opacities	Tooth removal, antibiotics
Diffuse sclerosing osteomyelitis	Probably low-grade infection, pulpitis, periodontal disease	Occasional pain, swelling, drainage; mandible	Opacification throughout jaw	Antibiotics; find cause and, if possible, treat
Focal sclerosing osteitis	Low-grade focal bone irritation (e.g., pulpitis)	Asymptomatic; found on routine examination	Opaque mass, usually at root apex	Treat offending tooth



■ **FIGURE 13-7 Chronic osteomyelitis** in the region of third molar extraction.

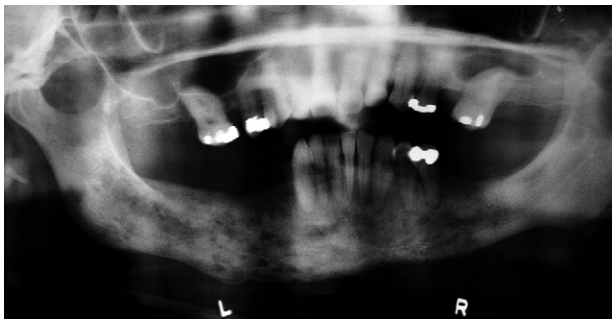

■ **FIGURE 13-8 Chronic osteomyelitis** of the mandible associated with periodontal disease. Note moth-eaten radiolucent appearance.

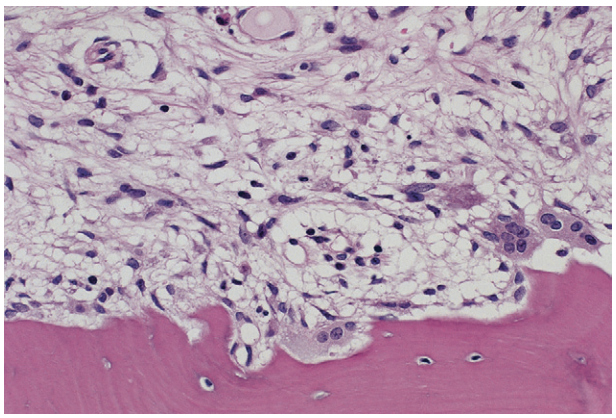

■ **FIGURE 13-9 Chronic osteomyelitis** showing fibrous marrow and osteoclastic resorption of resident bone.

Histopathology. The inflammatory reaction in chronic osteomyelitis can vary from very mild to intense. In mild cases, microscopic diagnosis can be difficult because of similarities to fibro-osseous lesions such as ossifying fibroma and fibrous dysplasia. A few chronic inflammatory cells (lymphocytes and plasma cells) are seen in a fibrous marrow (Figure 13-9). Both osteoblastic and osteoclastic activity may be seen, along with irregular bony trabeculae—unlikely features of fibro-osseous lesions. In advanced chronic osteomyelitis, necrotic bone (sequestrum) may be present, as evidenced by both necrotic marrow and necrotic osteocytes. Reversal lines reflect the waves of deposition and resorption of bone. Inflammatory cells are more numerous and osteoclastic activity more prominent than in mild cases.

Treatment. The basic treatment of chronic osteomyelitis centers on the selection of appropriate antibiotics and the proper timing of surgical intervention. Culture and sensitivity testing should be carried out. Occasionally, combinations of antibiotics may be more successful than single agents. The duration of antibiotic administration may be relatively extended.

When a sequestrum develops, surgical removal appears to hasten the healing process. Excision of other nonvital bone, sinus tracts, and scar tissue has been advocated. In cases in which the potential for pathologic fracture is significant, immobilization is required.

In recalcitrant cases of chronic osteomyelitis and in most cases of osteoradionecrosis, the use of *hyperbaric oxygen* has provided significant benefit for patients. In difficult cases, hyperbaric oxygen used in conjunction with antibiotics or surgery appears to be generally better than any of these methods used alone. The rationale for using hyperbaric oxygen is related to its stimulation of vascular proliferation, collagen synthesis, and osteogenesis. Contraindications include the presence of viral infections, optic neuritis, known residual or recurrent malignancies, and some lung diseases. The regimen typically used in this treatment adjunct involves placing a patient in a closed chamber with 100% oxygen at two atmospheres of pressure for 2 hours per day for several weeks. The elevated tissue oxygen levels achieved with this technique reach a limited maximum level by the end of therapy, but the effects appear to be long lasting. Specific hyperbaric oxygen protocols vary, however, with some advocating debridement or excision after hyperbaric oxygen therapy.

Bisphosphonate-Related Osteonecrosis

Bisphosphonate Description. Bisphosphonates are stable synthetic analogs of inorganic pyrophosphate, a product of many cellular biochemical reactions. In the context of bone metabolism, the biological importance of inorganic pyrophosphate lies in its role in the regulation of bone mineralization. Similar to their natural counterpart, bisphosphonates have an affinity for hydroxyapatite crystals and therefore are preferentially taken up by bone. Bisphosphonates have been modified to act primarily as inhibitors of osteoclast-mediated resorption.

Diseases most commonly treated with these drugs include osteoporosis, Paget's disease, malignancies metastatic to bone (especially breast and prostate cancers), hypercalcemia of malignancy, and multiple myeloma. Other diseases such

TABLE 13-3 BISPHOSPHONATES CURRENTLY PRESCRIBED

Generic Name	Brand Name	Route of Administration
Pamidronate	Aredia	Intravenous
Alendronate	Fosamax	Oral
Ibandronate	Boniva	Oral
Risedronate	Actonel	Oral
Zoledronic acid	Zometa, Reclast, Aclasta	Intravenous

as fibrous dysplasia, osteogenesis imperfecta, primary hyperparathyroidism, and giant cell tumors of bone have been treated with bisphosphonates with some success. Bisphosphonates are commonly utilized for diseases characterized by an imbalance in bone metabolism due to excessive bone resorption. These drugs therefore are used to prevent skeletal events such as pathologic fracture, hypercalcemia, and spinal cord compression in cancer patients and pathologic fracture in patients with osteoporosis.

Currently prescribed second- and third-generation nitrogen-containing bisphosphonates are markedly more potent than their predecessors (Table 13-3). The most potent drug (zoledronic acid) generally used cancer treatment (multiple myeloma, breast cancer, prostate cancer, and others), osteoporosis, and Paget's disease is administered intravenously. Less potent bisphosphonates are predominantly used to treat osteoporosis, as well as other diseases. Bisphosphonate intravenous injection is by far the more efficient route of administration, because absorption from the gastrointestinal (GI) tract is less than 5%. Dosing can occur daily, weekly, monthly, or even yearly, depending on drug potency and route of administration. For example, zoledronic acid given intravenously for management of osteoporosis can suppress osteoclastic bone resorption for up to 1 year.

Mechanisms of Action. Bisphosphonates are selectively adsorbed on bony mineral surfaces, where they eventually are taken up by osteoclasts during periods of bone remodeling (resorption). Once internalized, bisphosphonates disrupt intracellular signaling pathways, leading to inhibition of osteoclast function and ultimately to osteoclast apoptosis. It is believed that a similar intracellular signal disruption may occur in some tumor cells, potentially giving bisphosphonates an antitumor effect. Another possible antitumor effect has been linked to a reduction in serum vascular endothelial growth factor (VEGF), which suppresses tumor angiogenesis. Other cells, such as osteocytes, osteoblasts, monocytes, and some lymphocytes, appear to be able to internalize bisphosphonates, but with different and apparently less significant effects.



■ **FIGURE 13-10 Bisphosphonate-related osteonecrosis of the maxilla.** Note exposed bone.

Maximum drug effect is reached within 3 months—earlier for intravenous injections. The half-life of bisphosphonates in the blood is several hours, whereas the half-life in bone is measured in terms of years.

Benefits and Risks of Bisphosphonate Therapy. Bisphosphonates, with their antiosteoclastic activity, help control diseases in which excessive bone resorption is a primary (e.g., osteoporosis) or secondary (e.g., cancer metastasis) phenomenon. In the latter case, they can alleviate bone pain, help prevent spinal cord compression, and retard pathologic fractures. Although these are palliative effects, some evidence suggests that survival may be improved when bisphosphonates are used as an adjunct to standard anticancer chemotherapy. It has also been suggested that bisphosphonates can inhibit bone loss associated with endocrine therapy in breast and prostate cancers.

Although the benefits of bisphosphonate therapy may be impressive, their use is not without risk. Many adverse effects have been cited, including esophageal irritation, impairment of renal function, hypocalcemia, and fracture due to oversuppression of bone remodeling, cardiac atrial fibrillation, and osteonecrosis of the jaws. Risk increases with higher drug dosage, longer duration of therapy, greater drug potency, and intravenous (vs. oral) route of administration.

Bisphosphonate-Related Osteonecrosis of the Jaws. Bisphosphonate-related osteonecrosis of the jaws has been defined as exposed jaw bone for longer than 8 weeks in a patient who has received current or previous treatment with a bisphosphonate medication without evidence of local malignancy or prior radiotherapy to the site (Figure 13-10). Jaw pain is the usual presenting symptom, and exposed bone is the obvious sign. Radiographic evidence may include sclerosis, sequestrum formation, and nonhealing extraction sockets (Figure 13-11). Periapical dental films or panoramic



■ **FIGURE 13-11 Bisphosphonate-related osteonecrosis of the mandible.**

BOX 13-4 BISPHOSPHONATE-RELATED OSTEONECROSIS RISK FACTORS

DRUG ASSOCIATED
High drug dosage
Long duration of drug usage
High drug potency
Intravenous (as opposed to oral) route of administration

DENTAL OR LOCAL FACTORS
Poor oral hygiene
Ill-fitting dentures
Periodontal disease
Dentoalveolar infection

SYSTEMIC FACTORS
Patient medications
  Cancer chemotherapeutic drugs
  Systemic corticosteroids
Diabetes mellitus
Smoking

imaging usually provides sufficient evidence of osteonecrosis, although computed tomography and volumetric cone beam tomography may be useful. Potential sequelae at the site of osteonecrosis include tooth mobility, infection, exudation, sinus/fistulous tract formation, and pathologic fracture.

Precipitating Events and Risk Factors for Jaw Disease. Most (>90%) cases of osteonecrosis have been associated with intravenous bisphosphonates, usually in cancer patients receiving zoledronic acid or pamidronate. The incidence has been estimated at 1 to 10 per 100 oncology patients receiving intravenous bisphosphonates, and between 1 per 10,000 to 100,000 noncancer patients taking oral bisphosphonates. Osteonecrosis can present as early as 1 year after initiation of intravenous drugs, and 3 years after the start of oral drugs, depending on the patient's medical and dental comorbidities and other medications, and whether surgical trauma of the jaws has occurred.

As expected and likely related to differences in the composition and vascular perfusion of the jaws, 70% of cases of osteonecrosis have been reported in the mandible. Lesions have been precipitated predominantly by tooth extraction (70%) or other dentoalveolar surgery. Trauma to mucosa overlying bony prominences is a likely precipitating factor. Approximately 10% to 20% of cases of jaw osteonecrosis have been attributed to "spontaneous" events.

Risk factors (Box 13-4) for bisphosphonate-related osteonecrosis of the jaws that have been reported or suggested include poor oral hygiene, ill-fitting dentures, periodontal disease, and dentoalveolar infections. Contributing systemic factors that are believed to be significant in the pathogenesis of this problem include patient medications (cancer chemotherapeutic agents and systemic corticosteroids) that can negatively affect bone metabolism and angiogenesis, some systemic diseases (e.g., diabetes mellitus), the cancer itself, metastatic disease, and smoking.

Treatment of Bisphosphonate-Related Osteonecrosis of the Jaws. The diagnosis of osteonecrosis is based on history, oral examination, and radiographic imaging. Once confirmed, treatment is controversial and ranges from conservative local measures such as the use of an antimicrobial rinse (such as chlorhexidine) to the possible use of systemic antibiotics. This should occur in the context of a meticulous oral hygiene regimen. Conservative sequestrectomy of necrotic tissue may be of benefit in many cases. Resection of the affected area has been reported to be of considerable value in eliminating this problem if more conservative measures fail. Resection has also been advocated in the management of early cases, so as to prevent progression of the disease. Another therapeutic approach that has some proven benefit is the utilization of hyperbaric oxygen, although additional studies are warranted.

Dental Management of Patients Undergoing Bisphosphonate Therapy. Ideally, patients who are about to begin bisphosphonate therapy should be educated about the potential oral complications of osteonecrosis and the risk factors associated with it. They should be evaluated by a dental professional for caries, periodontal disease, periapical disease, and jaw lesions. Any disease, including dental impaction, should be addressed/treated at this time. A scrupulous oral hygiene regimen should be initiated and maintained, along with regular recall visits. No contraindication

to continuing regular dental care is known for patients on any bisphosphonate regimen.

If the patient is already on a bisphosphonate regimen, this approach should still be used in an attempt to circumvent the need for extractions in the future. If dentoalveolar surgery does become necessary, a conservative approach is recommended. Because of the protracted bony half-life of bisphosphonates, stopping the drug regimen to do surgery probably is not necessary. In the event of a periapical cyst/granuloma, conservative endodontic therapy is recommended. Placement of dental implants in patients on bisphosphonate therapy has not been sufficiently studied, although the risk for osteonecrosis seems to be relatively low in patients taking low-potency oral bisphosphonates.

Chronic Osteomyelitis With Proliferative Periostitis (so-called Garré's Osteomyelitis)

Etiology. Chronic osteomyelitis with proliferative periostitis, commonly referred to as Garré's osteomyelitis, is essentially a subtype of osteomyelitis that has a prominent periosteal inflammatory reaction as an additional component. It most often results from periapical abscess of a mandibular molar tooth, or from infection associated with tooth extraction or partially erupted molars. It is most common in children.

The eponym *Garré's osteomyelitis* was applied to this condition after the author, Dr. C. Garré, described in an 1893 German language paper the clinical features of 72 patients with osteomyelitis. The disease that he described was most common in the femur, with only three cases occurring in the jaws. In the absence of histologic and radiographic findings, which were unavailable at the time of the report, it is likely that Garré was describing a form of recalcitrant, acute osteomyelitis that occurred in both adults and children. It was not chronic osteomyelitis with proliferative periostitis. Therefore, the term *Garré's osteomyelitis,* although widely used in reference to this condition, is inaccurate.

Clinical Features. This variety of osteomyelitis is uncommonly encountered. It has been described in the tibia, and in the head and neck area, it is seen in the mandible. It typically involves the posterior mandible and usually is unilateral. Patients characteristically present with an asymptomatic bony, hard swelling with normal-appearing overlying skin and mucosa (Figure 13-12, *A*). On occasion, slight

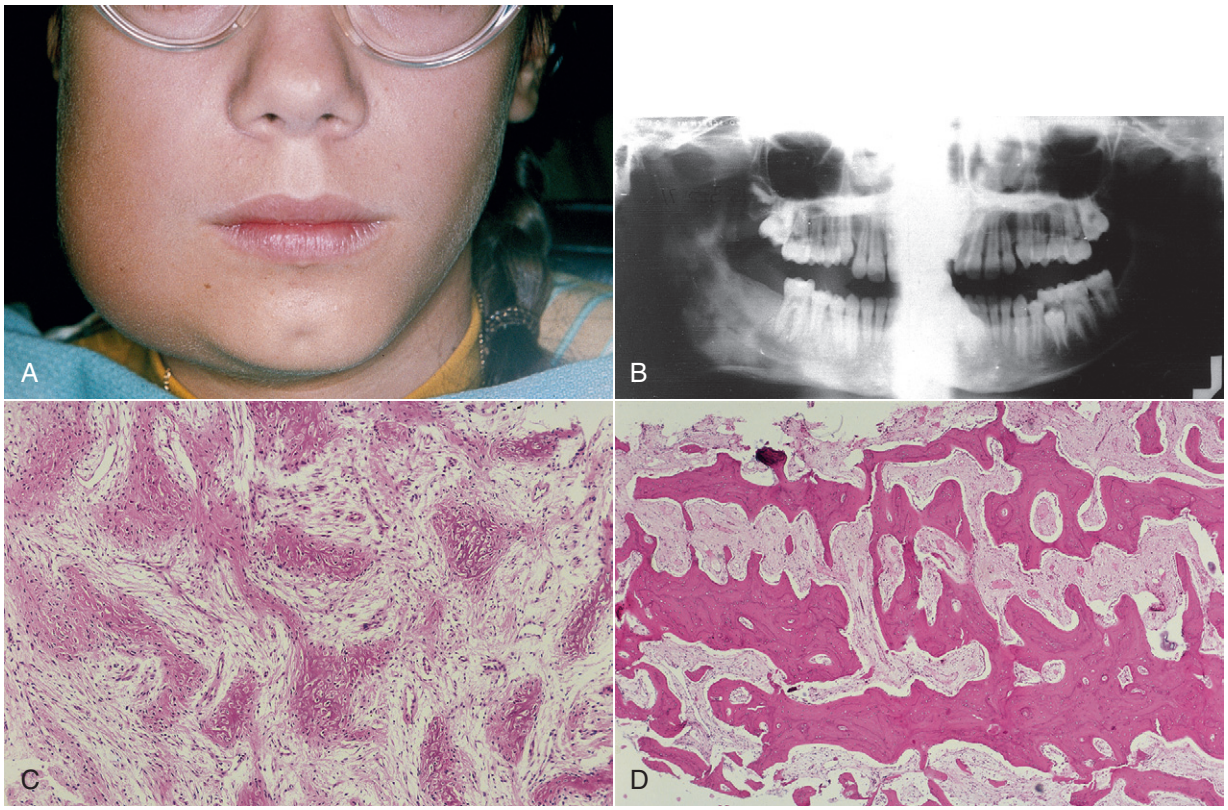

■ **FIGURE 13-12 Chronic osteomyelitis with proliferative periostitis (Garré's osteomyelitis)** of the right mandible **(A). B,** Note periosteal expansion in the radiograph. **C,** Tissue from the central mandible is minimally inflamed and has a fibro-osseous appearance. **D,** Periosteal tissue shows sclerotic laminations.

tenderness may be noted. This presentation necessitates differentiation of this process from benign mandibular neoplasms. Radiographs and a biopsy provide a definitive diagnosis.

Radiographically, the lesion appears centrally as a mottled, predominantly lucent lesion in a pattern consistent with that of chronic osteomyelitis. The feature that provides the distinctive difference is the periosteal reaction. This, best viewed on an occlusal radiograph, appears as an expanded cortex, often with concentric or parallel opaque layers (Figure 13-12, *B*). Trabeculae perpendicular to the onion-skin layers may also be apparent.

Histopathology. Reactive new bone typifies the subperiosteal cortical response. Perpendicular orientation of new trabeculae to redundant cortical bone is best seen under low magnification. Osteoblasts dominate in this area, and both osteoblasts and osteoclasts are seen centrally. Marrow spaces contain fibrous tissue with scattered lymphocytes and plasma cells. Inflammatory cells are often surprisingly scant, making microscopic differentiation from fibro-osseous lesions a diagnostic challenge (Figure 13-12, *C* and *D*).

Treatment. Identification and removal of the offending agent are of primary importance in chronic osteomyelitis with proliferative periostitis. Removal of the involved tooth is usually required. Antibiotics are generally included early in this treatment. The mandible then undergoes gradual remodeling without additional surgical intervention.

Diffuse Sclerosing Osteomyelitis

Etiology. Diffuse sclerosing osteomyelitis represents an inflammatory reaction in the mandible or maxilla, believed to occur in response to a microorganism of low virulence. Bacteria generally are suspected as causative agents, although they are seldom specifically identified. Chronic periodontal disease, which appears to provide a portal of entry for bacteria, is important in the origin and progression of diffuse sclerosing osteomyelitis. Carious nonvital teeth are less often implicated.

Clinical Features. This condition may be seen at any age, in either sex, and in any race, but it tends to occur most often in middle-aged black women. The disease is typified by a protracted chronic course with acute exacerbations of pain, swelling, and occasionally drainage.

Radiographically, this process is diffuse, typically affecting a large part of the jaw (Figures 13-13 and 13-14). The lesion is ill defined. Early lucent zones may appear in association with sclerotic masses. In advanced stages, sclerosis dominates the radiographic picture. Periosteal thickening may also be seen. Radiographic scintigraphy using technetium-99m may be particularly useful in evaluating the extent of this condition.

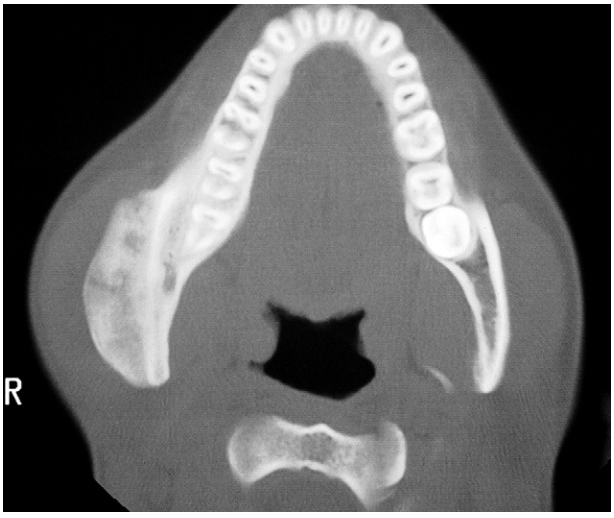

■ **FIGURE 13-13 Diffuse sclerosing osteomyelitis** of the right mandible in a computed tomography (CT) scan.

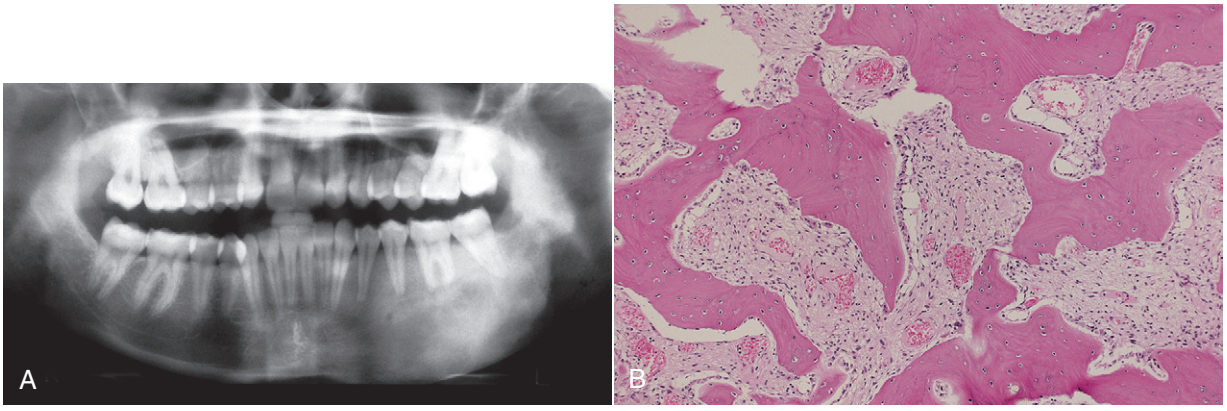

■ **FIGURE 13-14 A** and **B, Diffuse sclerosing osteomyelitis** of the left mandible. Biopsy specimen shows thick trabeculae, fibrous marrow, and scattered lymphocytes. (Courtesy Dr. Bruce A. Shapton.)

Histopathology. The microscopic changes of this condition are inflammatory. Fibrous replacement of marrow is noted. A chronic inflammatory cell infiltrate and occasionally a neutrophilic infiltrate are also seen. Bony trabeculae exhibit irregular size and shape and may be lined by numerous osteoblasts. Focal osteoclastic activity is also present. The characteristic sclerotic masses are composed of dense bone, often exhibiting numerous reversal lines.

Differential Diagnosis. Chronic sclerosing osteomyelitis shares many clinical, radiographic, and histologic features with florid osseous dysplasia. The two should be separated, because the former is an inflammatory/infectious process, and the latter is a bony dysplastic process. Treatment and prognosis therefore are different. Florid osseous dysplasia appears to be an extensive form of periapical cemental dysplasia; unlike diffuse sclerosing osteomyelitis, it may exhibit anterior periapical lesions and traumatic or simple bone cysts. Furthermore, florid osseous dysplasia usually is asymptomatic and appears as a fibro-osseous lesion lacking an inflammatory cell infiltrate.

Treatment. The management of diffuse sclerosing osteomyelitis is problematic because of the relatively avascular nature of affected tissue, and because of the large size of the lesion. Even with aggressive treatment, the course is protracted.

If a causative factor such as periodontal disease or a carious tooth can be identified, it should be eliminated. Antibiotics, the mainstay of treatment, are especially helpful during painful exacerbations. Surgical removal of the diseased area is usually an inappropriate procedure because of the extent of the disease. However, decortication of the affected site has resulted in improvement in some cases. Low-dose corticosteroids have also been used with some success. Hyperbaric oxygen therapy may prove to be a valuable adjunct. Treatment with pamidronate has shown promising results.

Focal Sclerosing Osteitis

Etiology. Focal sclerosing osteitis is a relatively common phenomenon that is believed to represent a focal bony reaction to a low-grade inflammatory stimulus. It usually is seen at the apex of a tooth with long-standing pulpitis. This lesion occasionally may be adjacent to a sound, unrestored tooth, suggesting that other causative factors such as malocclusion may be operative.

Synonyms for focal sclerosing osteitis include *focal sclerosing osteomyelitis, bony scar, condensing osteitis,* and *sclerotic bone.* The term *focal periapical osteopetrosis* has also been used to describe idiopathic lesions associated with normal, caries-free teeth.

Clinical Features. Focal sclerosing osteitis may be found at any age but typically is discovered in young adults. Patients usually are asymptomatic, and most lesions are discovered on routine radiographic examination. Most lesions are found at the apices of mandibular first molars, and a minority are associated with mandibular second molars and premolars (Figure 13-15). When teeth are extracted, these lesions remain behind indefinitely (Figure 13-16).



■ **FIGURE 13-15 Focal sclerosing osteitis** at the apex of the first molar.



■ **FIGURE 13-16 Focal sclerosing osteitis.** Residual after tooth extraction.

Radiographically, one of several patterns may be seen (Figure 13-17). The lesion may be uniformly opaque, it may have peripheral lucency with an opaque center, it may have an opaque periphery with a lucent center, or it may be composed of confluent or lobulated opaque masses.

Histopathology. Microscopically, the lesions are masses of dense sclerotic bone. Connective tissue is scant, as are inflammatory cells.

Differential Diagnosis. Differential diagnosis should include periapical cemental dysplasia, osteoma, complex odontoma, cementoblastoma, osteoblastoma, and hypercementosis. In most cases, however, diagnosis can be made

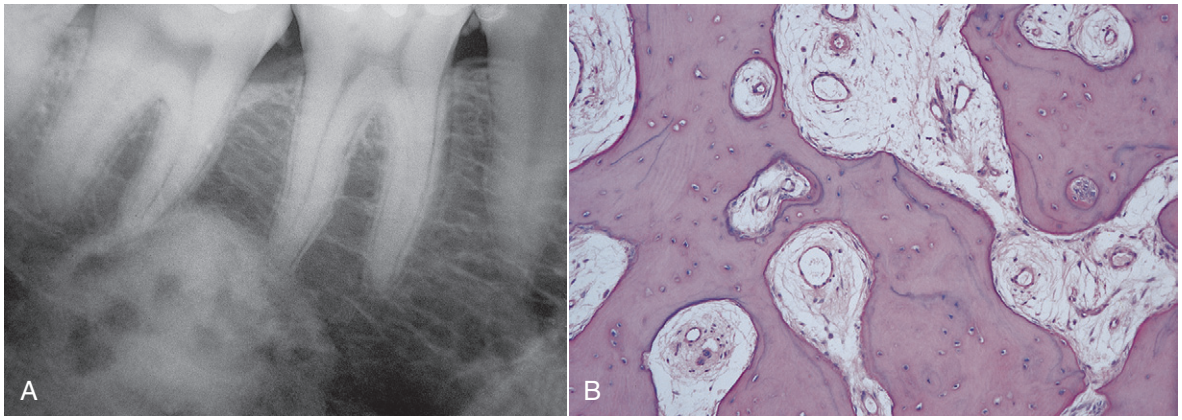

■ **FIGURE 13-17 A and B, Focal sclerosing osteitis.** Biopsy specimen shows dense sclerotic trabeculae and fibrous marrow with a few lymphocytes.

with confidence on the basis of historical and radiographic features.

Treatment. Because it is believed to represent a physiologic bone reaction to a known stimulus, the lesion itself need not be removed. A biopsy might be contemplated to rule out more significant lesions that received serious consideration in the differential diagnosis. The inflamed pulp that stimulated the focal sclerosing osteomyelitis should be treated. The decision about whether the tooth should be restored, treated endodontically, or extracted should be made on a case-by-case basis according to findings.

BIBLIOGRAPHY

Assael LA: Oral bisphosphonates as a cause of bisphosphonate-related osteonecrosis of the jaws: clinical findings, assessment of risks, and preventive strategies. J Oral Maxillofac Surg 67(2 suppl):35–43, 2009.

Badros A, Weikel D, Salama A, et al: Osteonecrosis of the jaw in multiple myeloma patients: clinical features and risk factors. J Clin Oncol 24:945–952, 2006.

Brook I, Frazier E, Gher M: Aerobic and anaerobic microbiology of periapical abscess. Oral Microbiol Immunol 6:123–125, 1991.

Carlson ER, Basile JD: The role of surgical resection in the management of bisphosphonate-related osteonecrosis of the jaws. J Oral Maxillofac Surg 67(5 suppl):85–94, 2009.

Drake MT, Clarke BL, Khosla S: Bisphosphonates: mechanism of action and role in clinical practice. Mayo Clin Proc 83:1032–1045, 2008.

Epstein J, van der Meij E, McKenzie M, et al: Postradiation osteonecrosis of the mandible. Oral Surg Oral Med Oral Pathol Oral Radiol Endod 83:657–662, 1997.

Fedele S, Kumar N, Davies R, et al: Dental management of patients at risk of osteochemonecrosis of the jaws: a critical review. Oral Dis 15:527–537, 2009.

Freiberger JJ: Utility of hyperbaric oxygen in treatment of bisphosphonate-related osteonecrosis of the jaws. J Oral Maxillofac Surg 67:96–106, 2009.

Hahn C, Falkler W, Minah G: Microbiological studies of carious dentin from human teeth with irreversible pulpitis. Arch Oral Biol 36:147–153, 1991.

Hess LM, Jeter JM, Benham-Hutchins M, et al: Factors associated with osteonecrosis of the jaws among bisphosphonate users. Am J Med 121:475–483, 2008.

Khan AA, Sandor GK, Dore E, et al: Bisphosphonate associated osteonecrosis of the jaw. J Rheumatol 36:478–490, 2009.

Kim S: Neurovascular interactions in the dental pulp in health and inflammation. J Endod 16:48–53, 1990.

King AE, Umland EM: Osteonecrosis of the jaw in patients receiving intravenous or oral bisphosphonates. Pharmacotherapy 28:667–677, 2008.

Madrid C, Sanz M: What impact do systemically administered bisphosphonates have on oral implant therapy? A systematic review. Clin Oral Implants Res 20(suppl 4):87–95, 2009.

Marx RE, Carlson ER, Smith BR, et al: Isolation of *Actinomyces* species and *Eikenella corrodens* from patients with chronic diffuse sclerosing osteomyelitis. J Oral Maxillofac Surg 52:26–33, 1994.

Marx RE, Sawatari Y, Fortin M, et al: Bisphosphonate-induced exposed bone (osteonecrosis/osteopetrosis) of the jaws: risk factors, recognition, prevention, and treatment. J Oral Maxillofac Surg 63:1567–1575, 2005.

Melo MD, Obeid F: Osteonecrosis of the jaws in patients with a history of receiving bisphosphonate therapy. J Am Dent Assoc 136:1675–1681, 2005.

Migliorati CA, Casiglia J, Epstein J, et al: Managing the care of patients with bisphosphonate-associated osteonecrosis: an American Academy of Oral Medicine position paper. J Am Dent Assoc 136:1658–1668, 2005.

Palaska PK, Cartsos V, Zavras AI: Bisphosphonates and time to osteonecrosis development. Oncologist 14:1154–1166, 2009.

Papapetrou PD: Bisphosphonate-associated adverse events. Hormones (Athens) 8:96–110, 2009.

Ruggiero SL, Mehrotra B, Rosenberg TJ, et al: Osteonecrosis of the jaws associated with the use of bisphosphonates: a review of 63 cases. J Maxillofac Surg 62:527–534, 2004.

Russell RGG: Bisphosphonates: mode of action and pharmacology. Pediatrics 119:S150–S162, 2007.

Soubrier M, Dubost JJ, Ristori JM, et al: Pamidronate in the treatment of diffuse sclerosing osteomyelitis of the mandible. Oral Surg Oral Med Oral Pathol Oral Radiol Endod 92:637–640, 2001.

Vahtsevanos K, Kyrgidis A, Verrou E, et al: Longitudinal cohort study of risk factors in cancer patients of bisphosphonate-related osteonecrosis of the jaws. J Clin Oncol 27:5356–5362, 2009.

Van den Wyngaert T, Huizing MT, Fossion E, et al: Bisphosphonates in oncology: rising stars or fallen heroes. Oncologist 14:181–191, 2009.

Wessel JH, Dodson TB, Zavras AI: Zoledronate and other risk factors associated with osteonecrosis of the jaw in cancer patients: a case-control study. J Oral Maxillofac Surg 66:625–631, 2008.

Wood RE, Nortje CJ, Grotepass F, et al: Periostitis ossificans versus Garré's osteomyelitis. I. What did Garré really say? Oral Surg Oral Med Oral Pathol 65:773–777, 1988.

Zarychanski R, Elphee E, Walton P, et al: Osteonecrosis of the jaw associated with pamidronate therapy. Am J Hematol 81:73–75, 2006.

CHAPTER 14

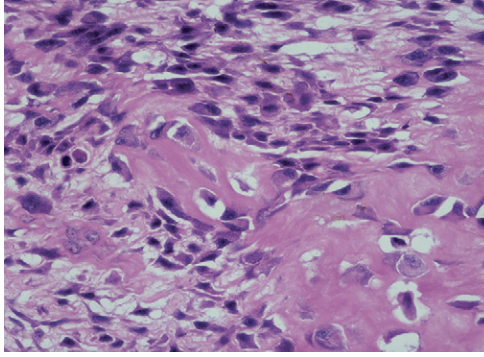

Malignancies of the Jaws

Richard J. Zarbo, Eric R. Carlson

OSTEOSARCOMA
JUXTACORTICAL OSTEOSARCOMA
PAROSTEAL OSTEOSARCOMA
PERIOSTEAL OSTEOSARCOMA
CHONDROSARCOMA
Mesenchymal Chondrosarcoma
EWING'S SARCOMA AND PRIMITIVE NEUROECTODERMAL TUMOR
BURKITT'S LYMPHOMA
PLASMA CELL NEOPLASMS
Multiple Myeloma
Solitary Plasmacytoma of Bone
METASTATIC CARCINOMA

Malignant nonodontogenic tumors of the jaws, both primary and metastatic, are rare in comparisons of soft tissue and mucosal malignancies. Despite their infrequent occurrence, diagnosis of a malignant jaw tumor has serious prognostic implications, often requiring oncologic surgery, radiation, and/or chemotherapy. Generally, these tumors cause signs and symptoms that often are highly suggestive of malignancy (Box 14-1). Tumors discussed in this chapter are those arising from the hard tissues (osteosarcoma and chondrosarcoma) and those nonosseous tumors that frequently involve the mandible and the maxilla (Ewing's sarcoma, Burkitt's lymphoma, plasma cell malignancies, and metastatic carcinoma).

OSTEOSARCOMA

Osteosarcomas account for approximately 20% of all sarcomas and, after plasma cell neoplasias, are the most common primary bone tumors. Approximately 5% of osteosarcomas occur in the jaws, with an incidence of less than 1 case in 1.5 million persons per year (Box 14-2). Osteosarcomas can arise de novo or in the setting of several preexisting bone abnormalities such as *Paget's disease, fibrous dysplasia, multiple osteochondromas, bone infarct, chronic osteomyelitis,* and *osteogenesis imperfecta.* Osteosarcoma can also arise in two cancer susceptibility syndromes: hereditary retinoblastoma (RB) and Li-Fraumeni syndrome. Patients with RB inherit a mutation of the retinoblastoma gene on one chromosome and then develop a second mutation of the other retinoblastoma allele. Affected patients develop retinoblastoma of the eye and have an increased risk of sarcoma such as osteosarcoma later in life. Patients with Li-Fraumeni syndrome inherit germline mutations of the *p53* gene and have an increased risk of developing a variety of tumors including osteosarcoma. Some osteosarcomas have been preceded by radiation therapy to the affected bone for unrelated or antecedent disease. A vast majority of osteosarcomas involve the long bones, especially in the knee. Osteosarcomas can also be classified by their site of origin as (1) the conventional

BOX 14-1 MALIGNANCY IN THE JAWS: SIGNS AND SYMPTOMS

Paresthesia
Pain
Loose teeth, vertical mobility, premature loss
Tooth resorption more likely than displacement
Rapid growth
Acquired malocclusion
Radiographic changes
  Uniformly widened periodontal membrane space
  Ill-defined lesion

BOX 14-2 OSTEOSARCOMA OF THE JAWS

ETIOLOGY
No known risk factors
Genes that may be altered—*p53, Rb, met, fos, sas, mdm2, cdk4,* and *prim1*

CLINICAL FEATURES
Swelling, pain, paresthesia, periodontal ligament invasion, tooth mobility/displacement
Mean age—35 years; age range from 8 to 85 years
Males and females equally affected; mandible > maxilla

HISTOPATHOLOGY
Malignant cells producing osteoid
Well differentiated
Chondroblastic osteosarcoma most common subtype

TREATMENT
Resection to multimodality; good prognosis

type, arising within the medullary cavity; (2) juxtacortical tumors, arising from the periosteal surface; and (3) extraskeletal osteosarcomas, arising in soft tissue.

Osteosarcomas are characterized by complex chromosomal aberrations in both number and structure. Gains of 8q23 are present in up to 50% of tumors and correlate with poor prognosis. Increased copy number of the 8q24 region containing the *MYC* gene has been identified in up to 40% of tumors. Despite the complex karyotype, no specific chromosomal translocation has been identified in osteosarcoma. Alterations in several genes have been consistently identified in osteosarcoma and may contribute to development of the tumor. These include amplifications of *MET, FOS, SAS, MDM2, CDK4,* and *PRIM1*. Protein expression of defective/amplified genes results in loss of control of cell proliferation and differentiation (see the discussion on pathogenesis of squamous cell carcinoma in Chapter 2).

Clinical Features. Similar to their counterpart in the long bones, conventional osteosarcomas involving the mandible and maxilla display a slight predilection for males (60%).

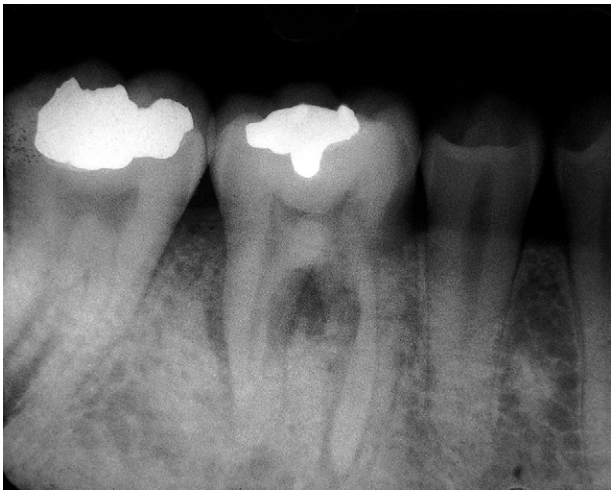

■ **FIGURE 14-1 Osteosarcoma** surrounding the roots of the first molar tooth. Note widened periodontal ligament.

Although the peak incidence of osteosarcoma of the skeleton occurs in the second decade, cases arising in the jaws generally present one to two decades later, with a mean age of 35 years (range, 8 to 85 years). About 10% of osteosarcomas of the jaws occur in persons older than 60 years of age; more than half of these individuals have some underlying bone condition such as Paget's disease. The mandible is more commonly affected than the maxilla by a ratio of 1.7 to 1. A majority (60%) of mandibular osteosarcomas arise in the body of the mandible; other common sites include the symphysis, angle of the mandible, ascending ramus, and temporomandibular joint. A nearly equal incidence of tumors involving the alveolar ridge and maxillary antrum is found in the maxilla, with few cases affecting the palate.

The most common presentation of jaw osteosarcoma is localized pain and swelling. In some cases, loosening and displacement of teeth may occur, as well as paresthesia caused by involvement of the inferior alveolar nerve. Maxillary tumors display similar clinical symptoms but may also cause paresthesia of the infraorbital nerve, epistaxis, nasal obstruction, or eye problems such as proptosis and diplopia. Mucosal ulceration usually is not seen until late-stage disease. The average duration of symptoms before diagnosis is 3 to 4 months.

The radiographic appearance of conventional (intramedullary) osteosarcoma is variable, reflecting the degree of calcification of the tumor. There appears to be little relationship between the radiographic pattern and the histologic subtype of osteosarcoma. Early osteosarcomas that involve the alveolar process may be characterized by localized widening of the periodontal ligament space of one or two teeth (Figures 14-1 and 14-2). The widened space results from tumor invasion of the periodontal ligament and resorption of surrounding alveolar bone (Figure 14-3). Advanced tumors can be visualized as "moth-eaten" radiolucencies or as irregular, poorly marginated radiopacities. Most of these

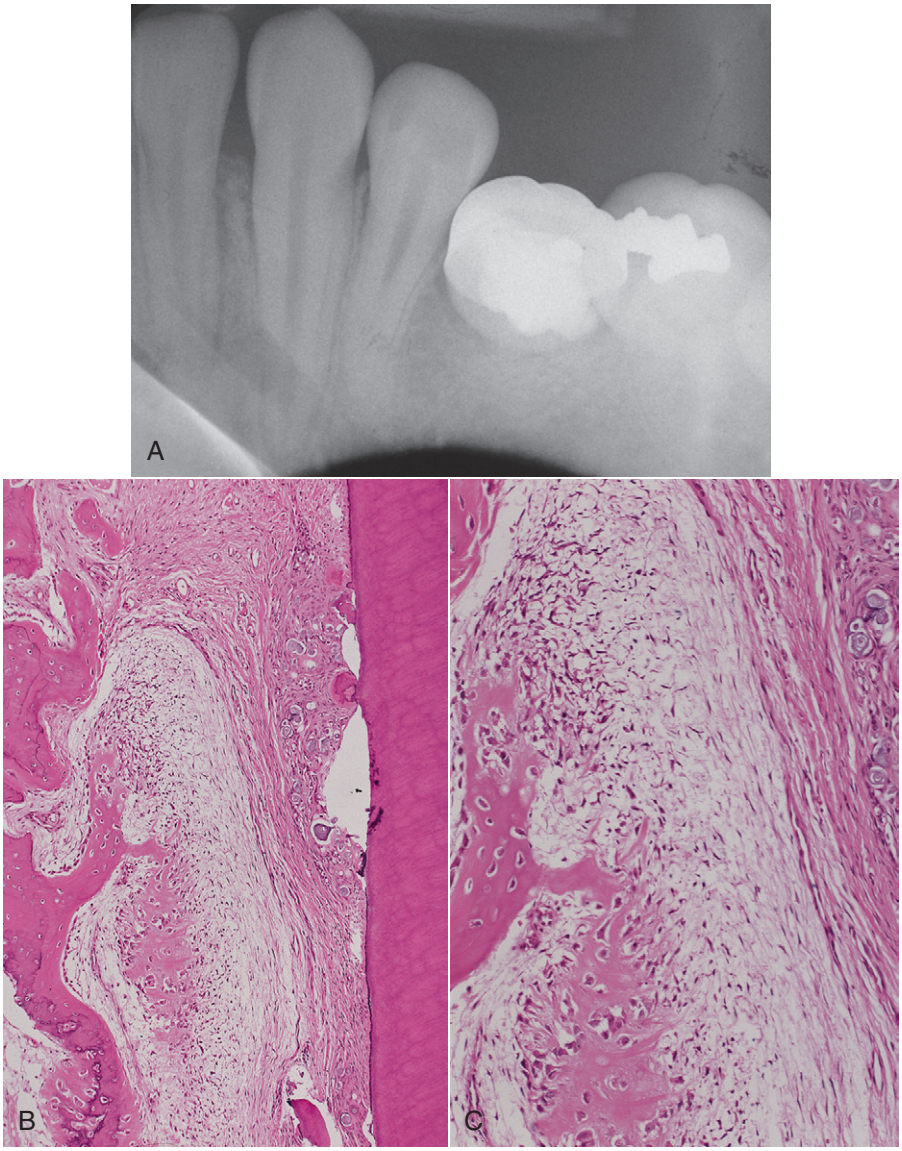

■ **FIGURE 14-2 A** through **C, Osteosarcoma** between a mandibular lateral incisor and a canine. Note slight widening of periodontal ligaments of both teeth. **B** and **C,** Surgical specimen shows a malignant bone-producing neoplasm occupying the periodontal ligament space. The tooth is to the right, and alveolar bone is to the left.

neoplasms have mixed radiographic features. A characteristic "sunray" or "sunburst" radiopaque appearance due to periosteal reaction may be seen in jaw lesions but is not diagnostic of osteosarcoma (Figures 14-4 and 14-5).

Histopathology. Microscopically, all osteosarcomas have in common a sarcomatous (malignant spindle cell) stroma that directly produces osteoid (Figures 14-6 and 14-7). Histologic subtypes are recognized and have been designated as *chondroblastic* when formed malignant cartilage predominates (most common) (Figure 14-8), *osteoblastic* when malignant bone and osteoid predominate, and *fibroblastic* when spindle cells predominate (Figure 14-9). An additional variant, designated as *telangiectatic,* contains multiple blood-filled aneurysmal spaces lined by malignant cells but rarely occurs in the head and neck region. Some osteosarcomas contain multinucleated giant cells so plentiful that this form may be mistaken for a central giant cell granuloma.

Central low-grade osteosarcoma is a rare variant that may involve the jaws. Microscopically, it resembles fibrous dysplasia because of the minimally atypical spindle cell proliferation with occasional mitotic figures and bone spicules. The microscopic diagnosis poses a challenge because of its deceptively bland features. Unlike fibrous dysplasia, the radiographic appearance is usually that of an invasive intramedullary growth with poor margination and cortical

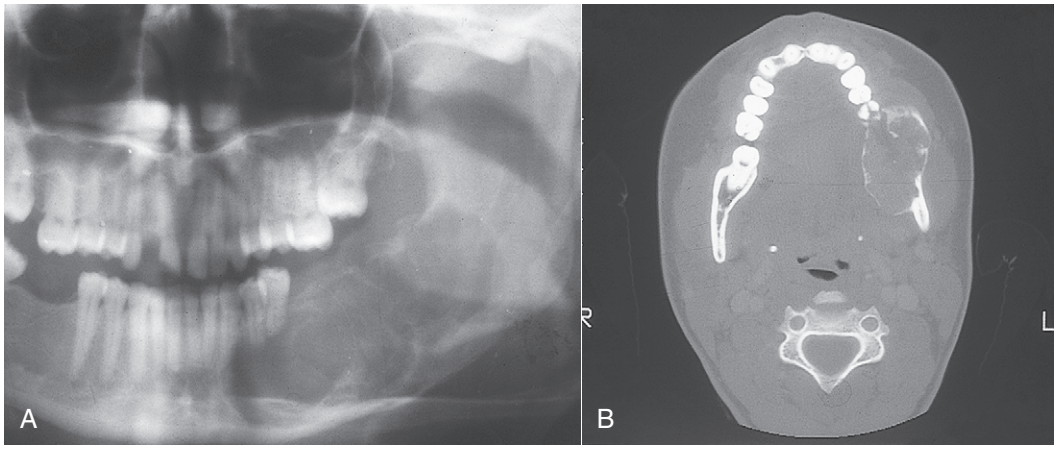

■ **FIGURE 14-3 Osteosarcoma** of the mandible. **A,** Panoramic radiograph. **B,** Computed tomography (CT) scan. (Reproduced with permission from Regezi JA, Sciubba JJ, Pogrel MA: Atlas of Oral and Maxillofacial Pathology. Philadelphia, 2000, WB Saunders, Figures 11-1 and 11-2.)

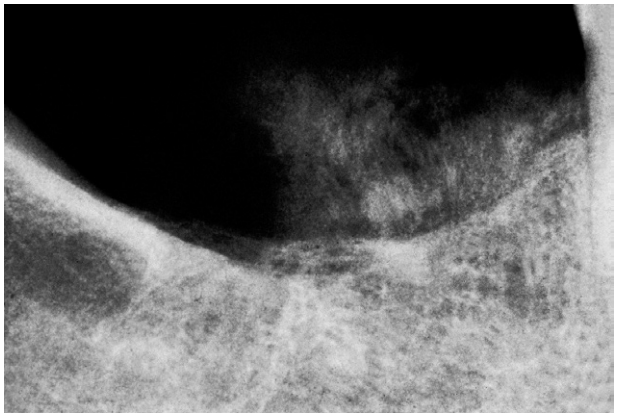

■ **FIGURE 14-4 Osteosarcoma** of the mandible showing a sunburst pattern of tumor bone radiating from the alveolar ridge.

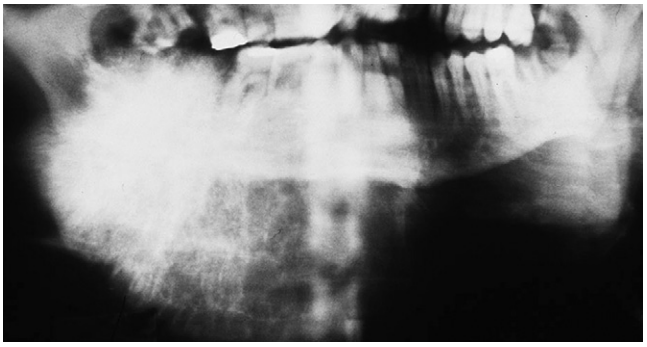

■ **FIGURE 14-5 Osteosarcoma of the mandible** exhibiting sunburst pattern.

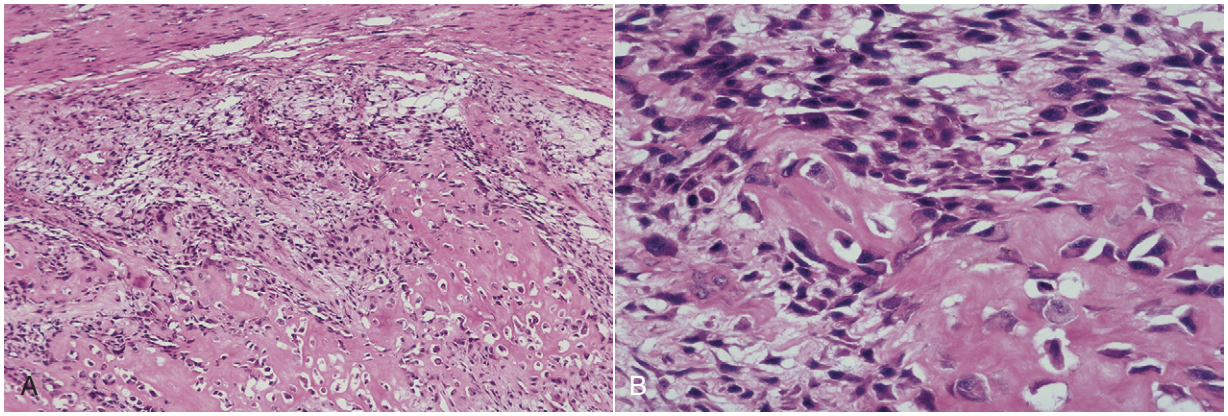

■ **FIGURE 14-6 A** and **B, Osteosarcoma** composed of atypical cells in association with tumor bone.

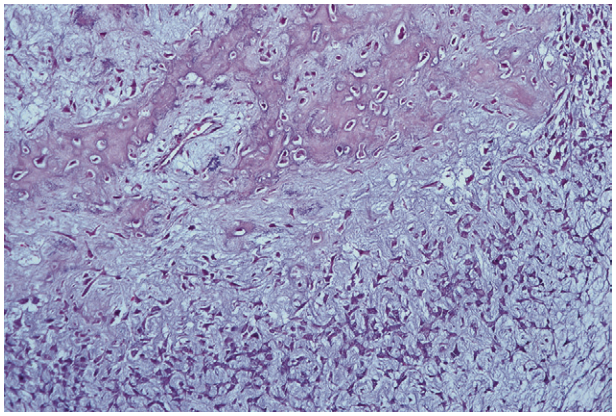

■ **FIGURE 14-7 Osteosarcoma** exhibiting a partially myxoid microscopic appearance.

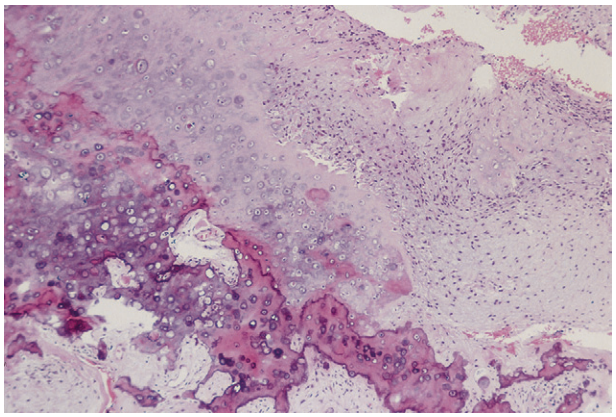

■ **FIGURE 14-8 Chondroblastic osteosarcoma.** Note cartilage and bone at lower left.

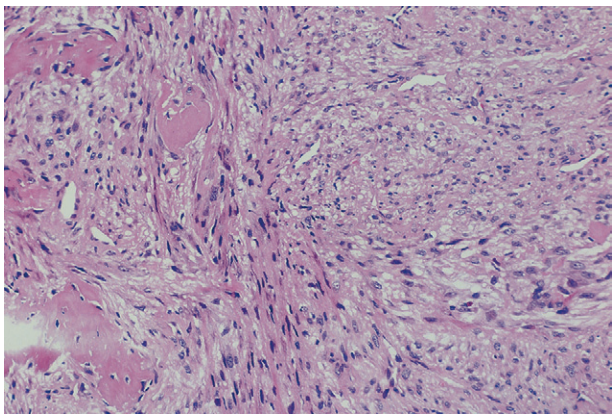

■ **FIGURE 14-9 Fibroblastic osteosarcoma** composed of spindled tumor cells and small islands of tumor bone.

destruction. Also unlike fibrous dysplasia, the proliferation permeates bone marrow, may extend through the periosteum, and may invade soft tissues. Recurrent tumor or long-standing low-grade osteosarcoma may transform to conventional high-grade osteosarcoma (Figure 14-10).

All histologic variants of conventional osteosarcoma reflect the multipotentiality of neoplastic mesenchymal cells in producing osteoid, cartilage, and fibrous tissue (see earlier). Such histologic subclassification, however, bears no prognostic significance. Attempts to further grade conventional intramedullary osteosarcomas are often problematic because of the heterogeneity of tumor morphology and, with the exception of central low-grade osteosarcoma, have proved to have little prognostic value.

Differential Diagnosis. Uniform widening of the periodontal ligament space of involved teeth appears to be characteristic of early osteosarcoma that involves the alveolus. However, this focal radiographic defect may also be seen with other malignancies surrounding the teeth. Uniform widening of periodontal ligament spaces surrounding all teeth may be seen in scleroderma. Moth-eaten radiolucencies are common to other malignancies, chronic osteomyelitis, and several benign neoplasms. A sclerotic radiographic appearance of osteosarcoma may be seen in other entities such as metastatic carcinoma (particularly prostatic carcinoma) and in the calcifying epithelial odontogenic tumor, which is often associated with an impacted tooth.

The histologic diagnosis hinges on identification of the malignant spindle cells producing osteoid. Many jaw osteosarcomas are predominantly chondroblastic, however, and may be misdiagnosed as chondrosarcoma. Osteosarcoma with a predominant fibroblastic component may be misdiagnosed as fibrous dysplasia, fibrosarcoma, or another pleomorphic sarcoma of bone. It has been suggested that overexpression of MDM2 and CDK4 proteins may help differentiate low-grade osteosarcomas from benign bone conditions and tumors.

Management. Management of sarcomas of the facial skeleton involves combinations of surgery, chemotherapy, and radiotherapy. Surgical management of osteosarcoma of the mandible, however, is the mainstay of therapy and possesses numerous characteristics similar to the management of carcinoma of the jaw, with some notable differences. These similarities include required attention to surrounding anatomic barriers with their appropriate sacrifice (Figure 14-11). Invasion of anatomic barriers surrounding any head and neck tumor may be assessed by physical examination and/or special imaging studies. When a small sarcoma originates within the medullary component of the mandible, cortical bone is the first anatomic barrier the tumor encounters that forestalls its growth. Once the cortical bone is violated, the less robust periosteum is subsequently encountered. With continued growth, muscle, mucosa, and skin ultimately become invaded by the malignancy. The general approach to

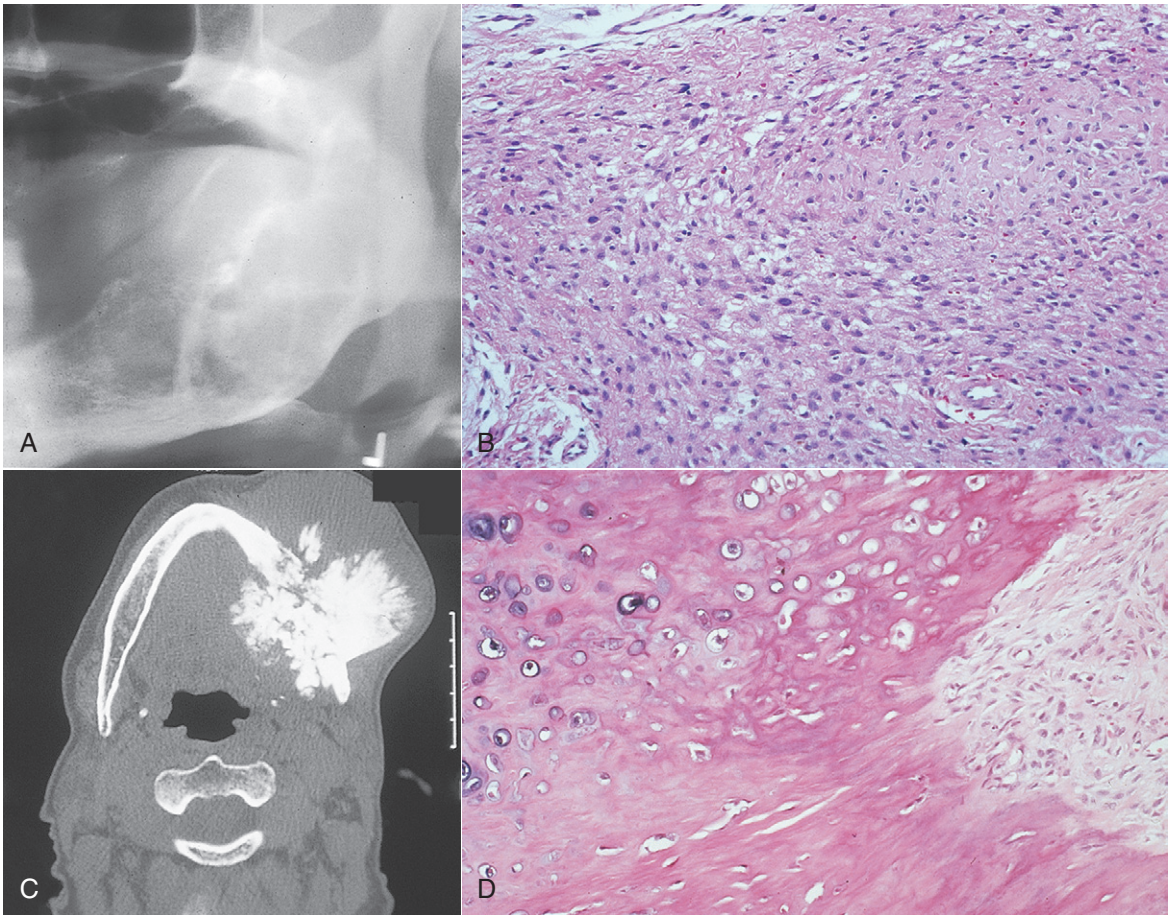

■ **FIGURE 14-10 A, Central low-grade osteosarcoma** of the mandible. **B,** Surgical specimen. **C,** Computed tomography (CT) scan of persistent tumor 15 years later, now a high-grade tumor. **D,** Surgical specimen of the high-grade tumor (chondroblastic osteosarcoma). (Reproduced with permission from Regezi JA, Sciubba JJ, Pogrel MA: Atlas of Oral and Maxillofacial Pathology. Philadelphia, 2000, WB Saunders, Figures 11-10 and 11-13.)

malignant tumor surgery of the head and neck is that at least one uninvolved anatomic barrier margin should be included on the tumor specimen as part of the en bloc resection. This practice allows better analysis of tumor margins. The main difference between resection of carcinoma in bone and resection of sarcoma lies in the recommended linear bony margin. Whereas carcinomas may be resected with a 2 cm linear margin in bone, it generally is recommended that sarcoma resections should include a 3 cm margin. Attention to proper anatomic barrier sacrifice, as well as inclusion of the recommended linear bony margin, enhances the potential for long-term palliation or cure of patients with sarcoma of the jaw.

Although sarcomas most commonly are managed surgically, it is now recognized that chemotherapy plays an important role in some patients with these tumors. Chemotherapy may be administered preoperatively (neoadjuvant chemotherapy) or postoperatively (adjuvant chemotherapy). In fact, it has been a time-honored protocol to strongly consider the administration of neoadjuvant chemotherapy in most of these patients, and the administration of adjuvant chemotherapy in all of these patients. One study examined the effects of neoadjuvant chemotherapy on histology of the tumor following this therapy. Neoadjuvant chemotherapy was utilized in 30 of 44 patients with osteosarcoma of the head and neck. The histologic response to neoadjuvant chemotherapy was classified as unfavorable in 22 of 30 patients (73%). An unfavorable response was one in which little or no response to chemotherapy occurred, or in which tumors had areas of acellular tumor osteoid and necrotic and/or fibrotic material attributable to the effects of chemotherapy in the background of viable tumor. By contrast, a favorable response to neoadjuvant chemotherapy was one with predominant areas of acellular tumor osteoid, necrosis, and/or fibrotic material with only scattered foci of histologically viable tumor cells, or no areas of histologically viable tumor following chemotherapy. Neoadjuvant chemotherapy was not found to significantly improve local control, distant metastases, or recurrence-free survival. This notwithstanding, when a favorable response to neoadjuvant chemotherapy was observed histologically, improved local recurrence-free survival, distant recurrence-free survival,

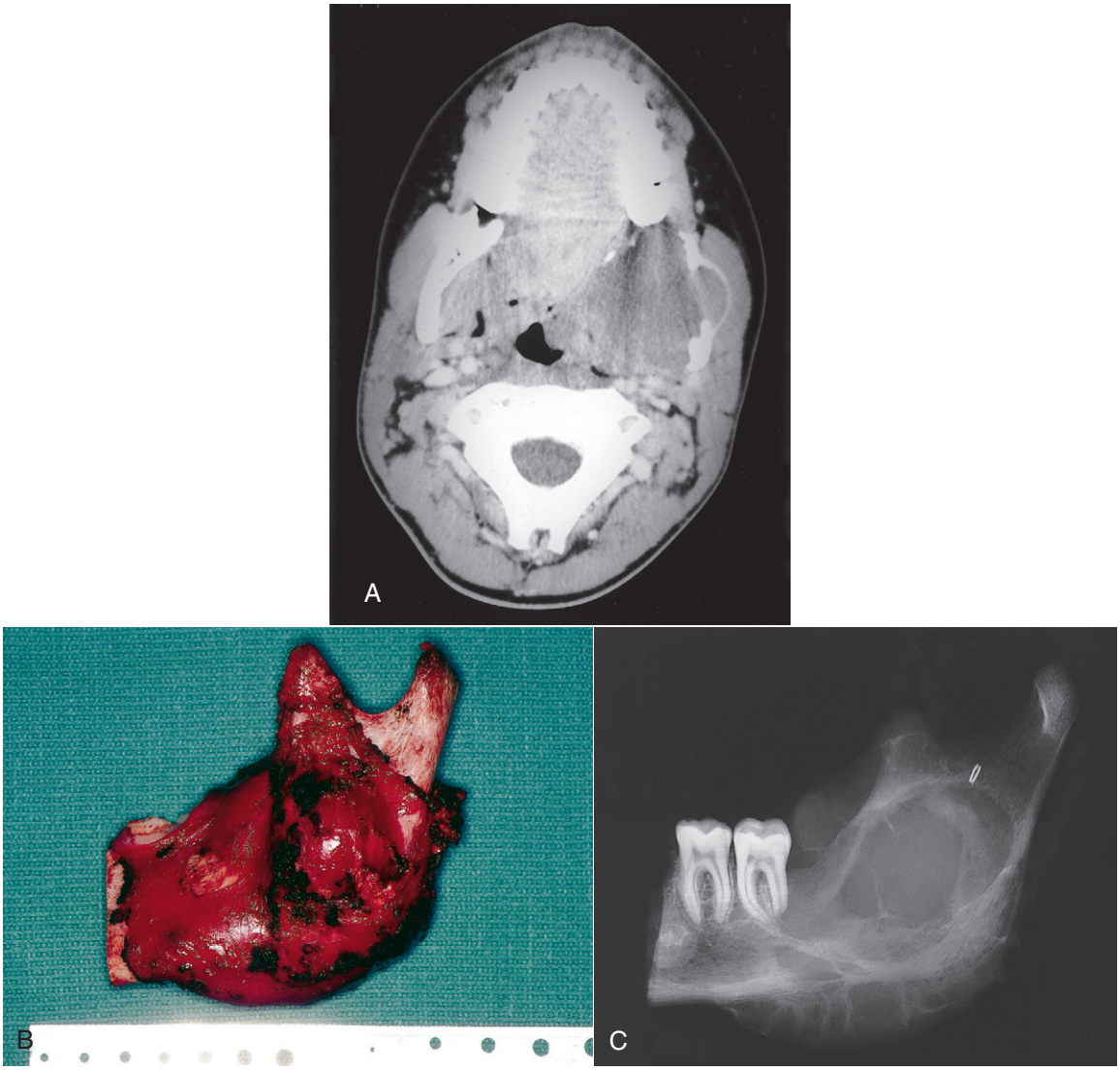

■ **FIGURE 14-11 Jaw sarcoma treatment. A,** Axial computed tomography (CT) scan of a large fibrosarcoma of the mandible with extension into the lateral pharynx. **B,** Tumor resection required wide margins, including sacrifice of the condyle. Appropriate sacrifice of surrounding anatomic barriers allows for negative margins on the specimen. **C,** The specimen radiograph confirms the inclusion of acceptable linear bony margins with the specimen. (Reproduced with permission from Regezi JA, Sciubba JJ, Pogrel MA: Atlas of Oral and Maxillofacial Pathology. Philadelphia, 2000, WB Saunders, Figures 11-10 and 11-13.)

and overall recurrence-free survival were realized. Therefore administration of neoadjuvant chemotherapy may be recommended for patients with high-grade osteosarcoma of the head and neck, or for whom initial resection is likely to incur the risk of positive surgical margins or a poor functional result.

The administration of adjuvant chemotherapy is perhaps as controversial as the administration of neoadjuvant chemotherapy, and certainly is contested to a similar degree. Of particular note is the observation of the National Cancer Database that no difference in 5-year survival rates is seen between patients treated with surgery and adjuvant chemotherapy and those treated with just surgery for osteosarcoma of the head and neck. Nonetheless, it is common practice for patients to receive adjuvant chemotherapy following resection of most sarcomas of the head and neck. However, the most favorable prognostic index in this cohort of patients is the attainment of negative surgical margins.

Most studies indicate that intramedullary sarcomas of the jawbones show no response to radiation therapy. The principles of management of sarcoma of the jaw are consistent for all subtypes of sarcoma.

Moreover, management of all variants of osteosarcoma, including low-grade osteosarcoma, postradiation osteosarcoma, intramedullary osteosarcoma, and juxtacortical osteosarcoma, is identical. Studies demonstrate that conservative management of those sarcomas with an otherwise inherently better prognosis than the others will lead to local recurrence

and will increase the tendency toward distant metastasis. These two scenarios are associated with greatly diminished survival rates, thereby justifying aggressive surgical management from the outset.

Prognosis. Overall, 5-year survival rates of 25% to 40% are reported for jaw osteosarcoma. Patients with mandibular tumors generally fare better than those with maxillary tumors. As with most malignant jaw tumors, initial radical surgery results in a superior survival rate of 80% as compared with a 25% survival rate with local or conservative surgery. Osteosarcoma of the jaw commonly recurs (40% to 70%), with a metastatic rate of 25% to 50%. Osteosarcomas are more likely to metastasize to lung and to brain than to regional lymph nodes. Once the disease has become metastatic, the mean survival time is 6 months. Nearly 80% of patients who die of the disease do so within the first 2 years. Local recurrences and isolated metastatic deposits are treated by surgical excision and chemotherapy.

JUXTACORTICAL OSTEOSARCOMA

In contrast to conventional (intramedullary) osteosarcomas, juxtacortical (parosteal and periosteal) osteosarcomas arise at the periphery of bone at the periosteal surface, with distinct clinical, histologic, and radiographic features, as well as different biological behaviors. Juxtacortical osteosarcomas are uncommon neoplasms that account for approximately 5% of all osteosarcomas of the skeleton; they are rarely seen in the jaw. Most juxtacortical osteosarcomas arising in the jaw are of the biologically low-grade parosteal subtype or, rarely, the periosteal subtype.

PAROSTEAL OSTEOSARCOMA

Parosteal osteosarcoma occurs over a wide age range, with a peak incidence at 39 years (Figures 14-12 and 14-13). More than 95% of cases affect the long bones, most commonly the distal femoral metaphysis, and at these sites there is a female predominance (3 to 2); when the jaws are affected, there is a male predominance. The tumor typically presents as a long-standing, slow-growing, swelling or palpable mass, often accompanied by a dull, aching sensation. Radiographically, the tumor often is radiodense (radiopaque) and is attached to the external surface of bone by a broad sessile base. It often is more radiodense at the base than at the periphery. The broad pedicle is not continuous radiographically with the underlying marrow cavity. A radiolucent clear space, corresponding to the periosteum, often can be identified between the tumor and the underlying cortex.

Histologically, parosteal osteosarcomas are well differentiated and are characterized by a spindle cell stroma with minimal atypia and rare mitotic figures separating irregular trabeculae of woven bone (Figure 14-14). The periphery is less ossified than the base; the lesion may have a lobulated cartilaginous cap, or it may be irregular because of linear

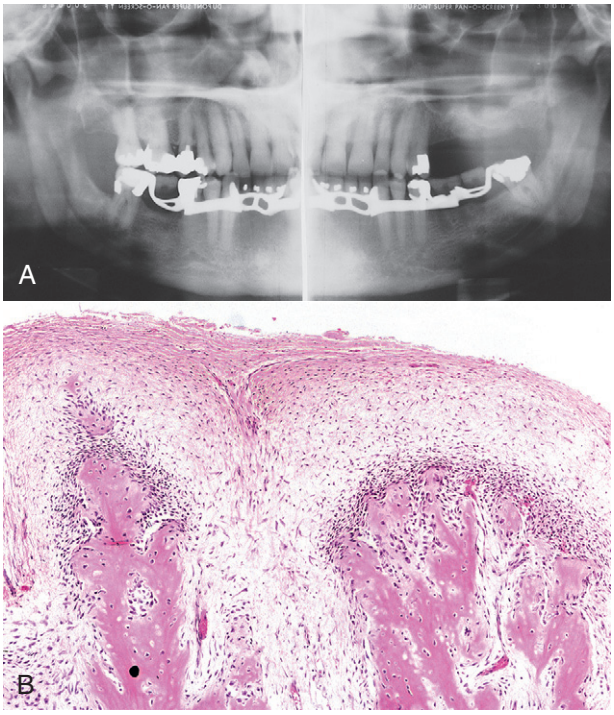

■ **FIGURE 14-12 A** and **B, Parosteal osteosarcoma** of the left maxilla. Biopsy specimen shows a pale peripheral myxoid zone overlying a cellular zone and tumor osteoid.



■ **FIGURE 14-13 Parosteal osteosarcoma.** Gross specimen shows a white mass covering the ramus and condyle.

extensions into soft tissue. Medullary involvement is unusual at initial presentation, but approximately 20% of tumors, especially recurrent ones, exhibit invasion of the underlying bone. This does not seem to affect the prognosis adversely. The bland histologic appearance of parosteal osteosarcoma raises the possibility of osteoma, osteochondroma, and exostosis.

PERIOSTEAL OSTEOSARCOMA

Periosteal osteosarcoma occurs much less often than does parosteal osteosarcoma. It has a 2:1 male predominance and a peak age of occurrence of 20 years. Tumors commonly

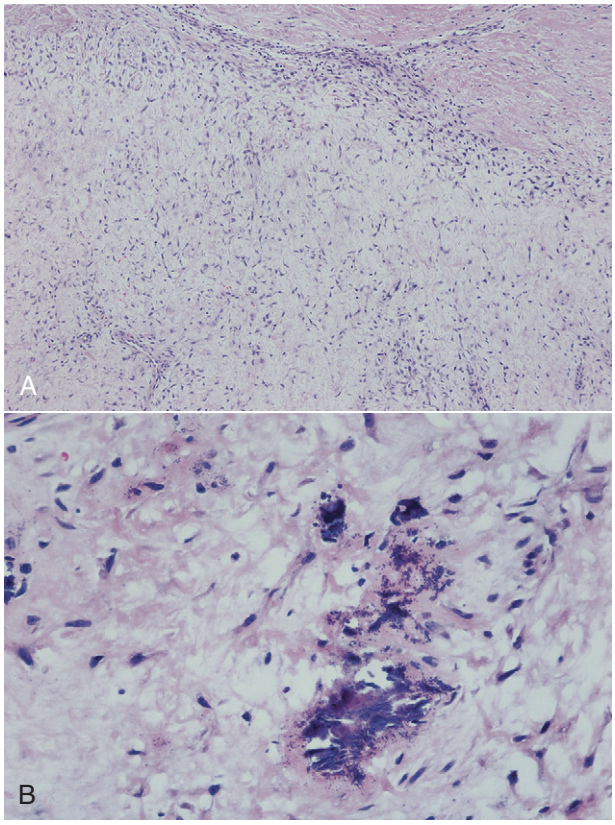

■ **FIGURE 14-14 A** and **B, Parosteal osteosarcoma** exhibiting a myxoid microscopic appearance with foci of atypical calcification of irregular osteoid **(B).**

involve the upper tibial metaphysis. Periosteal osteosarcoma is very rare in the jaw.

The radiographic appearance of periosteal osteosarcoma is distinct from that of parosteal osteosarcoma. The cortex of involved bone is radiographically intact and sometimes is thickened, with no tumor involvement of the underlying marrow cavity. The tumor most often is radiolucent, corresponding to its predominantly cartilaginous component, and it has a more poorly defined periphery. On occasion, a periosteal reaction in the form of Codman's triangle may be noted, along with variably sized perpendicular calcified spicules of bone radiating from the cortex. Overall, the periosteal osteosarcoma tumor matrix is not as radiographically dense or homogeneous as that of the parosteal osteosarcoma.

Microscopically, periosteal osteosarcoma is composed of lobules of poorly differentiated malignant cartilage; it often shows central ossification. The malignant cartilage and osteoid appear to radiate from an intact cortex. The osteoid present in this variant is fine and lacelike, and it is found in the chondroid islands among intervening malignant spindle cells. These histologic features can be identical to those of intramedullary osteosarcoma; therefore radiographic correlation is necessary to make the diagnosis. Malignant cytologic features also distinguish this variant of juxtacortical osteosarcoma from the parosteal type. In periosteal osteosarcoma, minimal tumor infiltration into cortical bone is typical without medullary involvement. This feature helps differentiate this lesion from a chondroblastic intramedullary osteosarcoma that has permeated the cortex and formed a soft tissue mass.

Juxtacortical osteosarcomas must be completely removed by en bloc resection or by radical excision. A significant local recurrence rate can be expected if the underlying cortical bone is not removed with these lesions. The overall 5-year survival rate for juxtacortical osteosarcoma of the skeleton is 80%. In one series of juxtacortical osteosarcomas, pulmonary metastases developed in 13% of patients with parosteal osteosarcomas, and in 22% of those with periosteal osteosarcomas. Overall, the survival rate for juxtacortical osteosarcomas is better than that for conventional intramedullary osteosarcomas. However, it is not known whether juxtacortical osteosarcomas of the jaws are substantially different in biological behavior from those occurring in long bones. Meaningful conclusions comparing the treatment and prognosis of parosteal and periosteal osteosarcomas in the jaws cannot be made because of the few reported cases and the various methods of treatment used (curettage, local excision, and radical resection).

CHONDROSARCOMA

Chondrosarcomas arising in the mandible and the maxilla are extremely rare and have accounted for approximately 1% of all chondrosarcomas arising in the skeleton. The appearance of benign cartilaginous tumors in the jaws is also rare. The microscopic distinction between a benign chondroma and a low-grade chondrosarcoma is often challenging and not well defined, and clinical experience dictates that well-differentiated chondrogenic neoplasms in the jaws should be considered potentially malignant and handled accordingly. Chondrosarcomas most commonly arise de novo, but secondary chondrosarcoma arising in preexisting benign cartilaginous lesions such as osteochondroma or enchondroma is recognized but exceptionally rare. Patients with Maffucci's syndrome (multiple enchondromas and multiple hemangiomas) and Ollier's disease (multiple enchondromas without hemangiomas) have a significant risk of developing chondrosarcoma.

Clinical Features. Chondrosarcomas more often involve the maxillofacial area (60%) than the mandible (40%). Lesions arising in the maxilla usually involve the anterior region (lateral incisor–canine region) and the palate. Mandibular chondrosarcomas occur most often in the premolar and molar regions, symphysis, and coronoid process, and occasionally in the condylar process. There is no distinct gender predilection. Chondrosarcomas predominate in adulthood and old age. Although the mean age of occurrence of chondrosarcoma is 60 years, almost half of jaw lesions have arisen in the third and fourth decades of life.

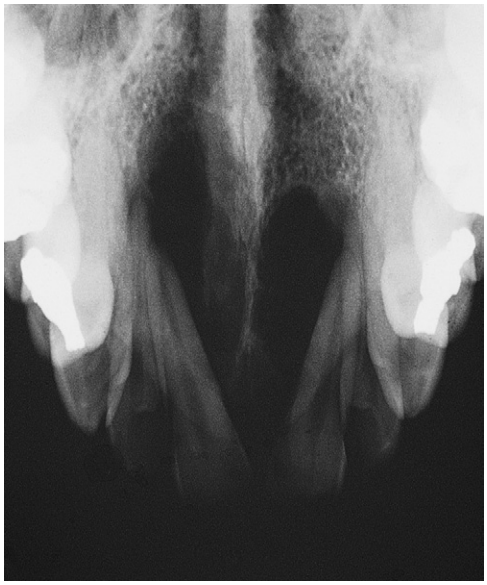

■ **FIGURE 14-15 Chondrosarcoma** of the anterior maxilla.

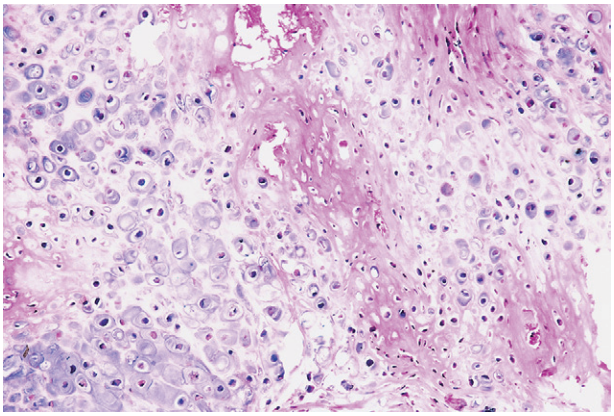

■ **FIGURE 14-16 Chondrosarcoma** showing a sheet of atypical cartilage.

The most common signs are painless swelling and expansion of affected bones, resulting in loosening of teeth or ill-fitting dentures. Pain, visual disturbances, nasal signs, and headache may result from extension of chondrosarcoma from the jaw to contiguous structures.

The radiographic appearance of chondrosarcoma varies from moth-eaten radiolucencies that are solitary or multilocular to diffusely opaque lesions (Figure 14-15). Many chondrosarcomas contain mottled densities corresponding to areas of calcification and ossification. Localized widening of the periodontal ligament space may also be seen in chondrosarcoma. Computed tomography (CT) visualization of cartilaginous neoplasms is the preferred method to image chondrosarcoma, particularly to assess the peripheral extent of the tumor, compared with panoramic or other plain radiographs. A multilocular radiographic appearance may suggest a differential diagnosis of ameloblastoma, central giant cell granuloma, odontogenic myxoma, and odontogenic keratocyst, whereas other patterns may suggest metastatic carcinoma, osteosarcoma, and calcifying epithelial odontogenic tumor.

Histopathology. The histologic appearance of chondrosarcoma is variable (Figure 14-16). Most tumors arising in the jaws are well differentiated. The prognostic significance of the pathologic grading of chondrosarcomas is well established. The incidence of metastatic disease has been shown to be 0%, 10%, and 70% for chondrosarcomas of histologic grade I, grade II, and grade III, respectively. Grade I chondrosarcomas often have a lobular architecture; they range from proliferations resembling benign cartilage to those with increased numbers of chondrocytes in a chondroid to myxomatous stroma. Grade II tumors often have a myxoid stroma with enlarged chondrocyte nuclei displaying occasional mitotic figures. Increased cellularity is often noted at the periphery of the cartilaginous lobules. Grade III chondrosarcomas are markedly cellular, often with a spindle cell component. Mitotic figures may be numerous.

Differential Diagnosis. The microscopic differential diagnosis of chondrosarcoma may include benign chondroma, which is rare in the jaws and should be considered only if the lesion is a small, incidental finding. The histology more commonly evokes the possibility of the chondroblastic variant of osteosarcoma, which accounts for nearly 50% of osteosarcomas in the jaw. This latter entity is recognized when adequate tissue sampling reveals foci of malignant osteoid formation. In addition, chondroid areas of pleomorphic adenoma arising in overlying soft tissues may mimic cartilaginous tumors of bone. Chondromyxoid fibroma is a rare, benign neoplasm of bone that may resemble chondrosarcoma because of the presence of large atypical cells; however, it has a distinctly lobulated appearance with a prominent myxoid element and focal calcifications. Synovial chondromatosis involving the temporomandibular joint may also simulate chondrosarcoma.

Treatment and Prognosis. Because chondrosarcomas are radioresistant neoplasms, wide local or radical surgical excision is the treatment of choice. Therefore the location of the primary lesion and the adequacy of surgical resection (tumor-free margins) are of prime prognostic significance for chondrosarcoma of the jaw. In addition, the pathologic grade of chondrosarcoma is indicative of its innate biological behavior and propensity for metastasis. The most common cause of death due to chondrosarcoma of the jaw is uncontrolled local recurrence and extension into adjacent vital structures. Metastasis, more common with high-grade chondrosarcoma, is generally to lung or bone. The usual clinical course of chondrosarcoma is long, with recurrences not uncommonly occurring 5 years or even 10 to 20 years after therapy. The 5-year survival rate for chondrosarcoma of the

jaws (15% to 20%) appears to be poorer than that for chondrosarcoma in other body sites.

Mesenchymal Chondrosarcoma

Mesenchymal chondrosarcoma is a rare form of chondrosarcoma that is both histologically distinct and clinically unique compared with chondrosarcoma arising in bone. Although it can occur at any age, the peak incidence is in the second and third decades. Translocations involving chromosomes 13 and 21 have been reported in skeletal and extraskeletal mesenchymal chondrosarcomas.

As many as one third of mesenchymal chondrosarcomas arise in soft tissue. Those that arise in bone show a predilection for the maxilla, mandible, and ribs. In one series of 15 mesenchymal chondrosarcomas of bone, one third occurred in the jaws. Most tumors arise between the ages of 10 and 30 years, with a nearly equal gender distribution. This presentation is distinctly different from other forms of chondrosarcoma that occur in older adults (mean age of 60 years).

Similar to the situation with the other malignant neoplasms discussed, pain and at times swelling are the usual presenting symptoms. The radiologic appearance is of a lytic lesion that may be ill defined or sharply defined. Most contain stippled or large areas of calcification.

The characteristic histologic appearance of mesenchymal chondrosarcoma is that of an anaplastic small cell malignancy containing zones of readily identifiable and often well-formed malignant cartilage. The undifferentiated small cell proliferation resembles Ewing's sarcoma and often displays a hemangiopericytoma-like growth pattern. It has been suggested that the small cell undifferentiated proliferation represents precartilaginous mesenchyme.

Appropriate sampling of these tumors demonstrates bimorphic proliferation of undifferentiated small cells alternating with areas of cartilage. The latter finding distinguishes mesenchymal chondrosarcoma from similar-appearing Ewing's sarcoma, solitary fibrous tumor, and even synovial sarcoma.

Mesenchymal chondrosarcoma is a highly malignant neoplasm that requires wide surgical excision. Similar to other chondrosarcomas, it is relatively radioresistant. The 5-year survival rate is 50%, and the 10-year survival rate is 20%. The prognosis for jaw lesions is somewhat better. In addition to local recurrence, mesenchymal chondrosarcomas show a significant rate of distant metastases, often to lung and bone. Detection of metastatic disease in survivors may be delayed until 12 to 22 years after treatment of the primary tumor.

EWING'S SARCOMA AND PRIMITIVE NEUROECTODERMAL TUMOR

Ewing's sarcoma is a rare round cell malignancy showing neuroectodermal differentiation that was first described by James Ewing in 1921. The cause is unknown, the cell of origin uncertain, and even the multipotentiality of antigenic expression controversial. Ewing's sarcoma is related to the primitive neuroectodermal tumor (PNET), sharing a common chromosome translocation t(11;22)(q24;q12) in approximately 85% of these tumors. This translocation results in juxtaposition of the *EWS* and *FLI-1* genes. Another translocation, t(21;22)(q22;q12), found in 10% to 15% of cases, fuses the *EWS* gene to the *ERG* gene. Ewing's sarcoma accounts for approximately 6% of all malignant bone tumors. Approximately 4% of Ewing's sarcomas have arisen in the bones of the head and neck, with 1% occurring in the jaws. Most involve the bones of the lower extremity or pelvis. When the jaws are involved, the predilection is for the ramus of the mandible, with few cases reported in the maxilla. Because Ewing's sarcoma has a propensity to metastasize to other bones, the possibility that jawbone involvement represents metastatic disease from another skeletal site should always be considered.

Clinical Features. Ewing's sarcoma is rare, accounting for 6% to 8% of primary malignant bone tumors, but it is the second most common sarcoma in bone and soft tissue in children. Ninety percent of Ewing's sarcomas occur between the ages of 5 and 30 years, and more than 60% affect males. The mean age of occurrence for primary tumors involving bones of the head and neck is 11 years. Pain and swelling are the most common presenting symptoms. Involvement of the mandible or maxilla may result in facial deformity, destruction of alveolar bone with loosening of teeth, and mucosal ulcers. Radiographic findings in the jaws are nonspecific and may simulate an infectious or malignant process (Figure 14-17). The most characteristic appearance is that of a moth-eaten destructive radiolucency of the medullary bone and erosion of the cortex with expansion. A variable periosteal onion-skin reaction also may be seen. A significant number of patients also have a soft tissue mass.



■ **FIGURE 14-17 Ewing's sarcoma** of the mandibular ramus in a 4-year-old boy.

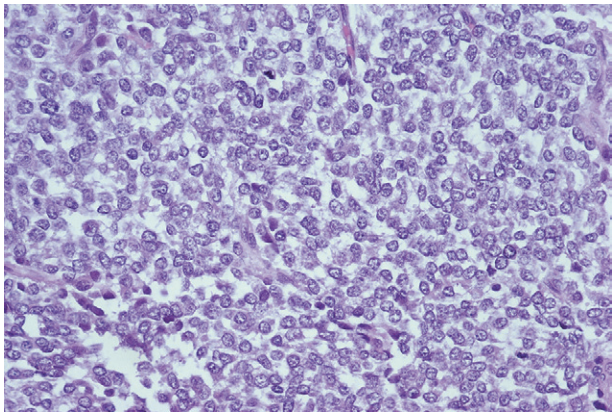

■ **FIGURE 14-18 Ewing's sarcoma** demonstrating characteristic round-cell cytologic morphology.

Histopathology. With an adequate biopsy specimen, Ewing's sarcoma is recognized microscopically as a proliferation of uniform, closely packed cells that may be compartmentalized by fibrous bands. The round to oval nuclei have finely dispersed chromatin and inconspicuous nucleoli (Figure 14-18). The cytoplasm characteristically stains with the periodic acid–Schiff stain but is digested with diastase, indicating the presence of glycogen. Although glycogen staining by this technique is helpful in diagnosis, some otherwise histologically acceptable cases of Ewing's sarcoma have yielded negative results. In addition, other tumors that mimic Ewing's sarcoma may contain glycogen. CD99 is highly expressed in most Ewing's sarcomas and PNETs. Often, cytogenetics to identify the characteristic chromosome translocations is needed to establish the diagnosis.

Differential Diagnosis. Microscopically, Ewing's sarcoma is sufficiently undifferentiated or anaplastic that its appearance is readily simulated by other so-called small, round cell tumors that occur in childhood and adolescence. This differential diagnosis includes lymphoma/leukemia, metastatic neuroblastoma, mesenchymal chondrosarcoma, small cell osteosarcoma, and, although rare for this age group, metastatic carcinoma. Routine light microscopy can be used to discriminate between these similar-appearing neoplasms, but electron microscopy, immunohistochemistry, and cytogenetics often must be used to reach a conclusive diagnosis. By electron microscopy, the cells of Ewing's sarcoma are characterized by pools of cytoplasmic glycogen, sparse organelles, and rare primitive intercellular junctions. By immunohistochemistry, all Ewing's sarcomas contain abundant vimentin intermediate filaments. The presence of other classes of intermediate filaments has been demonstrated in frozen tissue specimens. PNETs and Ewing's sarcomas lack morphologic evidence of neural morphologic differentiation, but they share a high level of expression of the CD99 antigen. Neural markers such as neuron-specific enolase are also expressed by a high proportion of tumors. By cytogenetic analysis, the t(11;22)(q24;q12) or (21;22)(q22;q12) translocation can be identified.

Treatment and Prognosis. The highly malignant nature of this sarcoma is reflected in its propensity for metastasis, especially to lungs, other bones, and lymph nodes. Multiple-method treatment protocols, involving surgery or radiation for local control and chemotherapy for systemic micrometastases, have dramatically improved the formerly dismal 10% 5-year survival rate. With these newer intensive therapies, 80% 2-year disease-free survival rates and 60% 5-year actuarial survival rates have been reported. Clinical features associated with a poor prognosis include presentation before age 10 years, the presence of metastatic disease, systemic symptoms, a high erythrocyte sedimentation rate, an elevated serum lactate dehydrogenase value, and thrombocytosis. In addition, the site of involvement appears to be of prognostic significance in Ewing's sarcomas—patients with mandibular tumors are noted to have a more favorable overall survival time than those with any other bone site of origin.

BURKITT'S LYMPHOMA

Burkitt's lymphoma (see also Chapter 9) is a high-grade non-Hodgkin's lymphoma that is endemic in Africa and occurs only sporadically in North America and Western Europe. It was first described in 1958 by the surgeon Denis Burkitt as a jaw malignancy occurring with high frequency in African children. By 1961, additional reports demonstrated the distinctive clinical and pathologic features of this tumor, by then confirmed to be a malignant lymphoma. Subsequently, nonendemic forms of Burkitt's lymphoma were recognized in the United States. The endemic and sporadic forms of Burkitt's lymphoma are histologically and immunophenotypically identical. Clinical differences exist, however, between the endemic and sporadic forms.

Both sporadic and endemic forms of Burkitt's lymphoma are characterized by a translocation of the distal part of chromosome 8 containing the c-*myc* oncogene to the immunoglobulin heavy chain gene locus on chromosome 14. Two other translocations are recognized, but common to all is involvement of the c-*myc* gene. These translocations may be directly involved in the enhanced tumor cell proliferation of Burkitt's lymphoma, which has been shown to have one of the highest proliferation rates of any neoplasm in humans, with a potential doubling time of 24 hours and a growth fraction of nearly 100%.

Clinical Features. In Africa, lymphoma accounts for 50% of all childhood malignancies, but it constitutes only 6% to 10% of childhood malignancies in the United States and Europe. Whereas the endemic form of Burkitt's lymphoma has a peak incidence between 3 and 8 years of age and a 2:1 male predominance, the sporadic form affects a slightly older age group, with a mean age of 11 years, and has no gender



■ **FIGURE 14-19 Burkitt's lymphoma** of the left maxilla.



■ **FIGURE 14-20 Burkitt's lymphoma** presenting as a periapical radiolucency (mandibular left first molar). The patient also had lip paresthesia.

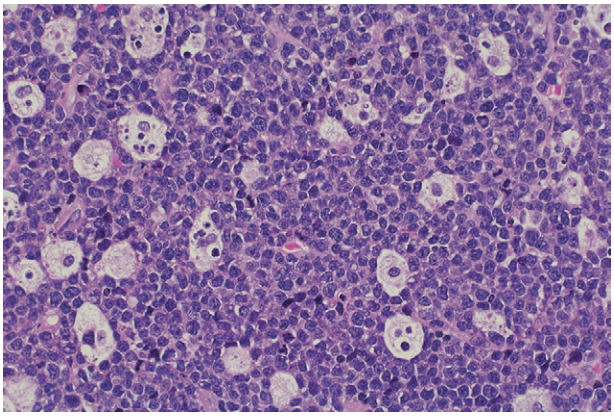

■ **FIGURE 14-21 Burkitt's lymphoma** exhibiting starry sky effect. Pale cells are tingible body macrophages.

predilection. An overwhelming majority (77%) of cases of sporadic Burkitt's lymphoma occur in whites.

Endemic Burkitt's lymphoma typically involves the mandible, maxilla, and abdomen, with extranodal involvement of the retroperitoneum, kidneys, liver, ovaries, and endocrine glands. The incidence of jaw tumors in endemic Burkitt's lymphoma is related to the age of the patient; 88% of those younger than 3 years of age and only 25% of those older than 15 years of age show jaw involvement. Involvement of the jaws is relatively uncommon in the sporadic form of this disease, occurring in approximately 10% of cases. Sporadic Burkitt's lymphoma presents most often as an abdominal mass involving the mesenteric lymph nodes or ileocecal region, often with an intestinal obstruction. Involvement of the retroperitoneum, gonads, and other viscera occurs less often. Although predominantly an extranodal disease, involvement of cervical lymph nodes or bone marrow has also been noted. A notable difference between endemic and nonendemic forms of Burkitt's lymphoma is that the Epstein-Barr virus genome can be detected in 95% of endemic cases but in only 10% of sporadic cases.

When the mandible and the maxilla are involved, the initial focus is usually in the posterior region, more commonly in the maxilla than in the mandible (Figure 14-19). Tumors in the sporadic form appear more localized, whereas in the endemic form, they more commonly involve all four quadrants. The usual signs associated with jaw lesions are an expanding intraoral mass and mobility of the teeth. Pain and paresthesia are occasionally present. In addition to a facial mass, in the sporadic disease, toothache is a common complaint, as is paresthesia of the lip. Burkitt's lymphoma has also been noted to invade the dental pulp, especially in developing teeth. Radiographically, a moth-eaten, poorly marginated destruction of bone is observed (Figure 14-20). The cortex may be expanded, eroded, or perforated, with soft tissue involvement.

Histopathology. Burkitt's lymphoma is a neoplastic B-cell proliferation that contains cell-surface B-lineage differentiation antigens and monoclonal surface immunoglobulin. The proliferation is extremely monomorphic, composed of medium-sized lymphocytes with round nuclei and three to five small basophilic nucleoli. Throughout the lymphoid proliferation are numerous scattered macrophages containing nuclear debris, contributing to the so-called starry sky appearance (Figure 14-21). Immunohistochemical stain for Ki-67 protein shows almost all cells in cell cycle—a feature that can be useful in diagnosis. The histologic differential diagnosis includes other subtypes of non-Hodgkin's lymphoma, undifferentiated carcinoma and sarcoma, metastatic neuroblastoma, and acute leukemia.

Treatment and Prognosis. At one time, Burkitt's lymphoma was invariably fatal within 4 to 6 months of diagnosis. However, because of its high proliferation rate, Burkitt's lymphoma has proved to be extremely sensitive to combination chemotherapy and therefore is potentially curable. The endemic and sporadic forms of Burkitt's lymphoma show similar excellent response rates to chemotherapy, with similar rates of relapse and survival. With combination chemotherapy, the overall 2-year survival rate is 55%, with a range of 80% for low-stage disease and 40% for advanced-stage disease.

PLASMA CELL NEOPLASMS

Multiple Myeloma

Plasma cell neoplasms (see also Chapter 9) are derived from bone marrow stem cells of B-lymphocyte lineage, and they are functionally differentiated in their ability to produce and secrete immunoglobulin. Because these tumors are derived from a single neoplastic clone, they are associated with the production of monoclonal immunoglobulin components, with the immunoglobulin light chain restricted to the kappa or the lambda type. These tumors may present in soft tissue as extramedullary plasmacytoma, in bone as a solitary lytic lesion known as plasmacytoma of bone, or, most commonly, as part of the multifocal disseminated disease, multiple myeloma. Eighty percent of extramedullary plasmacytomas involve the head and neck region, with a predilection for the nasopharynx, nasal cavity, paranasal sinuses, and tonsils. These tumors have also been reported in the gingiva, palate, floor of mouth, and tongue. Solitary plasmacytoma of bone is rare in the jaws; it more commonly appears in the ileum, femur, humerus, thoracic vertebrae, and skull. Multiple myeloma is a disease of the hematopoietic marrow–bearing bone of the skeleton, but 70% to 95% of affected individuals have had radiographic involvement of the bones of the maxilla or mandible (Box 14-3).

Clinical Features. Rarely encountered before the fifth decade of life, multiple myeloma appears at a mean age of 63 years. It has a slight male predominance. Involvement of the jaws may be asymptomatic or may produce pain, swelling, expansion, numbness, mobility of teeth, or pathologic fracture. Rarely is there an associated soft tissue mass. Some patients may exhibit weakness, weight loss, anemia, and hyperviscosity syndromes. Approximately 10% of patients with multiple myeloma develop *systemic amyloidosis,* a condition associated with other systemic diseases (Box 14-4) (see also discussion on multiple myeloma in Chapter 9). Eighty-five percent of patients with multiple myeloma have abnormal results on a skeletal radiographic survey. Although remaining patients have an apparently normal radiographic series, they demonstrate plasmacytosis on marrow aspirate or a biopsy specimen.

The most common peripheral blood abnormality is anemia with rouleaux (stacks of red blood cells) formation and, rarely, circulating plasma cells. The production of monoclonal immunoglobulin components by neoplastic plasma cells results in an excess of abnormal protein that circulates in serum and often can be detected in urine. On serum protein electrophoresis, most patients with myeloma are found to have a decreased quantity of normal immunoglobulin and an abnormal monoclonal immunoglobulin protein peak, known as an *M spike.* The immunoglobulin is usually of the immunoglobulin (Ig)G or IgA class, with a monoclonal light chain component. Some plasma cell neoplasms may secrete only a monoclonal light chain. These monoclonal immunoglobulin components can be demonstrated by immunoelectrophoresis of both serum and urine in approximately 95% of patients with myeloma. Urinary monoclonal light chains, so-called Bence Jones proteinuria, may be detected in approximately 50% of patients with myeloma. Two percent of myeloma cases are nonsecretory, although monoclonal immunoglobulin may be demonstrated within plasma cell cytoplasm by the immunoperoxidase method.

The radiographic appearance of myeloma can vary. Typically seen are multiple sharply punched-out but noncorticated radiolucent areas of bone destruction in the jaws and in many of the hematopoietic marrow–containing bones of the skeleton (Figures 14-22 and 14-23). Plasma cell tumors in the jaws may be expansile and on rare occasions may be osteosclerotic. The finding of a solitary plasma cell tumor in the jaw more often is a manifestation of systemic disease than a manifestation of a solitary plasmacytoma of bone.

Histopathology. Microscopically, all clinical manifestations of plasma cell tumors are similar. Tumors are composed of a monotonous proliferation of neoplastic plasma cells that may display a wide range of differentiation, from mature-appearing plasma cells to less well-differentiated

BOX 14-3 MULTIPLE MYELOMA

ORIGIN

B-lymphocyte malignancy; monoclonal population; abnormal monoclonal immunoglobulin produced

CLINICAL AND LABORATORY FEATURES

Types—multiple, solitary, extramedullary
Patients older than 50 years
Pain, swelling, numbness
Weight loss, weakness, anemia, bleeding, infection, amyloidosis (10%)
Punched-out skeletal lesions
Bence Jones protein (light chains) in urine
M protein in serum

TREATMENT

Chemotherapy; poor prognosis

BOX 14-4 AMYLOIDOSIS

Occurs in 10% of myeloma patients
May appear secondary to chronic disease (e.g., rheumatoid arthritis, chronic osteomyelitis, chronic renal failure)
Kidney, heart, gastrointestinal tract, liver, spleen commonly affected
Oral lesions seen in tongue (macroglossia), gingiva

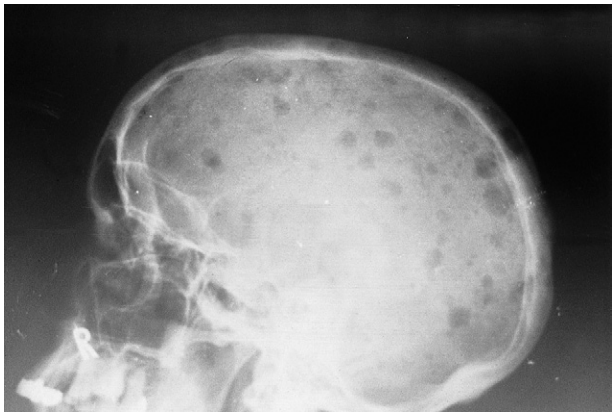

■ **FIGURE 14-22 Multiple myeloma** of the skull as punched-out radiolucencies.

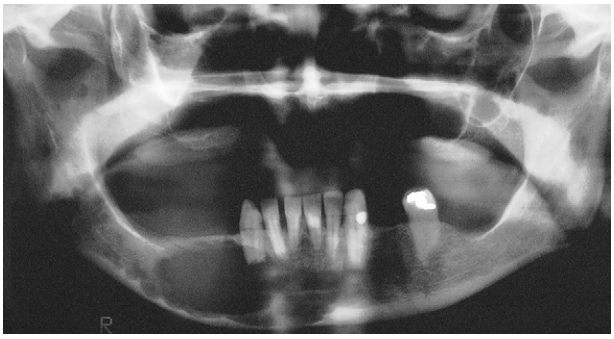

■ **FIGURE 14-23 Multiple myeloma** presenting as a radiolucency of the mandible. (Courtesy Dr. Steven Rowan.)

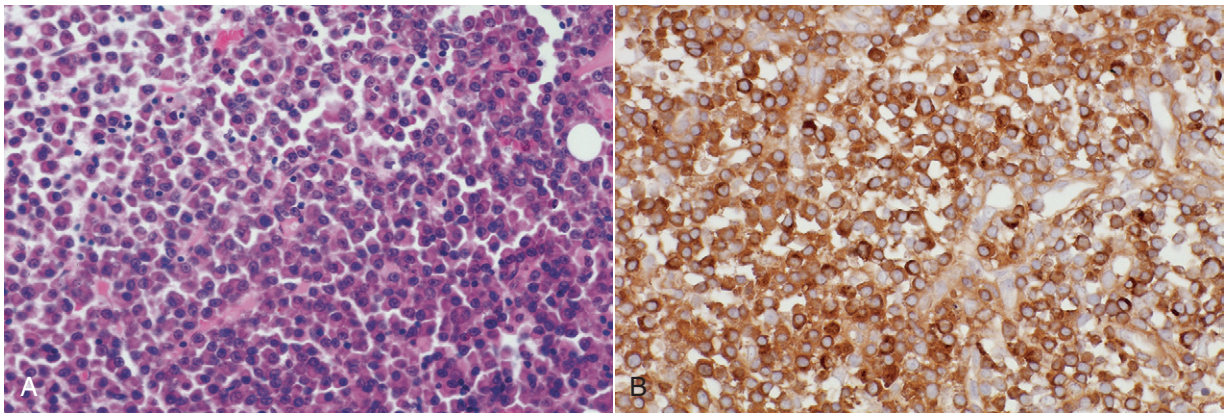

■ **FIGURE 14-24 Multiple myeloma. A,** Sheet of atypical plasma cells. **B,** With the use of immunohistochemistry, all cells stained positive *(brown)* for lambda light chains, demonstrating monoclonality of the tumor (cells were negative for kappa light chains).

forms resembling immunoblastic large cell lymphomas. Abundant plasma cells within bone marrow can be distinguished from the plasma cells of chronic osteomyelitis or periapical granuloma by the associated proliferation of small vessels and fibroblasts with admixed neutrophils and macrophages in the reactive lesions. In addition, a monoclonal population of CD79a+ or CD138+ cells expressing only one of the two immunoglobulin light chains (kappa or lambda) can be demonstrated using immunohistochemistry or by in situ hybridization methods. This is referred to as *light chain restriction.* A non-neoplastic population of plasma cells will contain a population of kappa to lambda expressing cells ranging from 3:1 to 1:1 (Figure 14-24).

Differential Diagnosis. Although the punched-out lytic appearance is characteristic, the radiographic differential diagnosis of these jaw lesions includes other malignant neoplasms of the jaws, such as metastatic carcinoma, lymphoma, and Langerhans cell disease. Therefore diagnosis must be confirmed by a biopsy specimen or aspirate. Histologically, very poorly differentiated plasma cell neoplasms may simulate other relatively undifferentiated malignant neoplasms, such as lymphoma, leukemia, undifferentiated carcinoma, metastatic malignant melanoma, and neuroblastoma. These entities can be distinguished by immunoperoxidase detection of the leukocyte common antigen in lymphomas/leukemias, cytokeratin in carcinomas, S-100 protein and melanoma-associated antigens in melanoma, and neuron-specific enolase in neuroblastoma. Plasma cell tumors do not express these antigens, but they express CD79a and CD138.

Treatment and Prognosis. Most patients with myeloma die of infection or, less commonly, of renal failure, disseminated myeloma, cardiac complications, or hematologic complications of hemorrhage or thrombosis. Multiple myeloma is treated with chemotherapeutic alkylating agents and steroids and with local radiation directed to painful bone lesions. Other therapeutic regimens (none curative) have included combination chemotherapy, bone marrow transplantation, the proteasome inhibitor bortezomib, and thalidomide (or analogs). Bisphosphonates are often added to prevent bone fracture. The overall median survival time is related to the stage of disease and ranges from longer than

60 months in patients with low stage I disease to 23 months in those presenting with high stage III disease. Indicators of prognosis correlate with the myeloma cell burden and include hemoglobin level, serum calcium level, serum and urine M-component, degree of bone involvement, and creatinine levels indicative of renal failure.

Solitary Plasmacytoma of Bone

Similar to multiple myeloma, solitary plasmacytoma of bone is a disease of adulthood, with a mean age of 50 years at presentation and predominance in men. Solitary plasmacytomas rarely occur in the jaws, but when they do, they are often located in the angle of the mandible. For a diagnosis of solitary plasmacytoma to be established, a radiologic bone survey and random bone marrow aspirate and biopsy specimen should reveal no evidence of plasmacytosis in other areas of the body. However, 30% to 75% of cases of solitary plasmacytoma of bone eventually progress to multiple myeloma. It is not possible to predict which patients will develop disseminated disease and which will not. As with multiple myeloma, the clinical symptoms include pain, swelling, and pathologic fracture.

Radiographically, solitary plasmacytoma is a well-defined lytic lesion that may be multilocular, resembling the appearance of central giant cell granuloma. Solitary plasmacytomas may destroy the cortical bone and spread into adjacent soft tissue. Unlike those with multiple myeloma, patients with solitary plasmacytoma of bone have a normal peripheral blood picture and a normal differential and clinical chemistry profile. In up to 25% of cases of solitary plasmacytoma of bone, a monoclonal immunoglobulin can be demonstrated in serum or urine. Biopsy material of solitary plasmacytoma of bone reveals a histologic appearance identical to that of multiple myeloma, with a monotonous proliferation of neoplastic plasma cells producing monoclonal immunoglobulin components.

Solitary plasmacytoma of bone is treated primarily by local radiotherapy. Accessible lesions may be surgically excised, followed by radiation therapy. Ten percent to 15% of patients have local recurrence of the solitary plasmacytoma, and small numbers of patients may develop an additional solitary plasmacytoma of bone. Although a significant proportion of cases progress to multiple myeloma, the overall survival time of patients with solitary plasmacytoma is 10 years, in contrast to the 20-month mean survival time of patients initially diagnosed with multiple myeloma. This appears to indicate that many solitary plasmacytomas are biologically low-grade, but slowly progressive, forms of multiple myeloma.

METASTATIC CARCINOMA

The most common malignancy affecting skeletal bones is metastatic carcinoma. However, metastatic disease to the mandible and maxilla is unusual; it is estimated that 1% of malignant neoplasms metastasize to these sites (Box 14-5). Approximately 80% of these metastases are to the mandible, 14% to the maxilla, and 5% to both jaws. Occasionally, metastatic deposits are seen in the gingiva with a clinical appearance that simulates pyogenic granuloma. In adults, metastases to the jaws most commonly originate from primary carcinoma of the breast in women and of the lung in men. Other common primary sites in decreasing order of frequency are the prostate, gastrointestinal tract, kidney, colon, and rectum. In children, neuroblastoma of adrenal glands is the most common primary site in the first decade of life, but bone malignancies are the most common primary site in the second decade of life. Jawbone metastasis may be the first sign of malignancy in as many as 30% of cases.

Clinical Features. Individuals likely to be affected by metastatic carcinoma to the jaws are in the older age groups, most in the fifth to seventh decades of life, with an average age of 45 years, reflecting the greater prevalence of malignancy in this population. The mechanism of spread to the jaws is usually hematogenous from the primary visceral neoplasm or from lung metastases. Within the jaw, the premolar-molar region, the angle, and the body of the mandible are more commonly involved by metastatic disease (Figures 14-25 to 14-27). Bone pain, loosening of teeth, lip paresthesia, bone swelling, gingival mass, and pathologic fracture may be clinically evident.

BOX 14-5 MALIGNANCIES MOST LIKELY TO METASTASIZE TO THE JAW

Breast carcinoma
Lung carcinoma
Prostate adenocarcinoma
Colorectal carcinoma
Renal cell carcinoma



■ **FIGURE 14-25 Metastatic adenocarcinoma of the breast** to the mandibular ramus.



■ **FIGURE 14-26 Metastatic adenocarcinoma of the breast** to the mandibular body.



■ **FIGURE 14-27 Metastatic cancer** (undetermined primary site) to the gingiva.

Most jaw metastases appear radiographically as poorly marginated, radiolucent defects. Some metastatic carcinomas, notably prostate and thyroid, are characterized by an osteoblastic process. Although the appearance of osteomyelitis is of a moth-eaten radiolucency, it rarely expands the cortical bone and typically shows a periosteal reaction.

Histopathology. The histologic appearance of metastatic carcinoma can be extremely variable, reflecting the tumor type and grade of tumor differentiation (Figures 14-28 to 14-30). A prominent desmoplastic stromal response is often present. The diagnosis of metastatic carcinoma can be verified in difficult cases with an immunohistochemical staining for cytokeratin, which is present in all carcinoma cells. Through immunohistochemistry, antibodies to tumor type–specific antigens that are reactive in formalin-fixed, paraffin-embedded material and capable of pointing to a primary site in the prostate, lung, breast, colon, or kidney are becoming increasingly available. Differential expression of cytokeratins 7 and 20 (CK7, CK20, respectively) and villin may also be useful (Table 14-1) in establishing the origin of a metastatic primary carcinoma when the primary is not known. Other examples include identification of Epstein-Barr virus (EBV) in a carcinoma, suggesting a nasopharynx primary, and human papillomavirus (HPV)16 in a basaloid carcinoma, suggesting an oropharynx (tonsil) primary. It is anticipated that with advances in monoclonal antibody development, this technique will be very useful in identifying carcinomas of unknown metastatic origin.

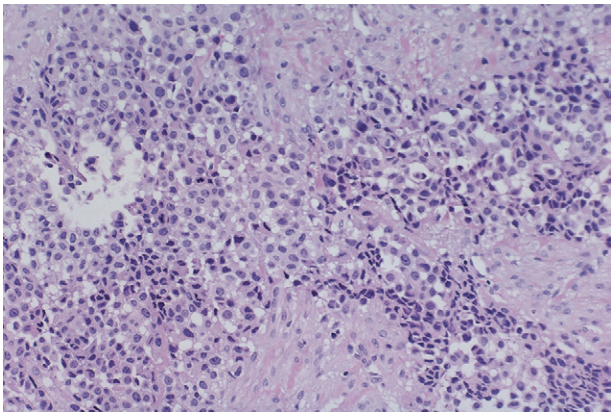

■ **FIGURE 14-28 Metastatic breast cancer** excised from a mandibular radiolucency.

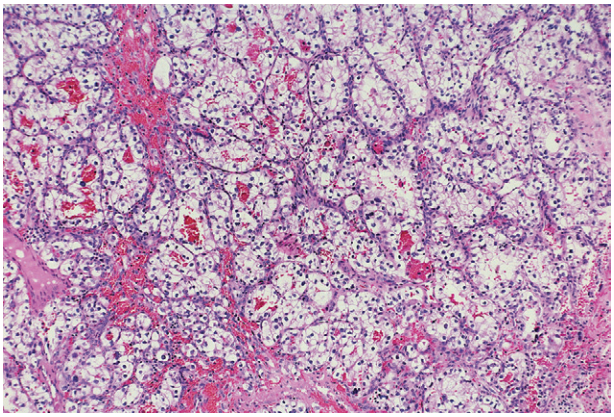

■ **FIGURE 14-29 Metastatic renal clear cell carcinoma** excised from a periapical radiolucency.

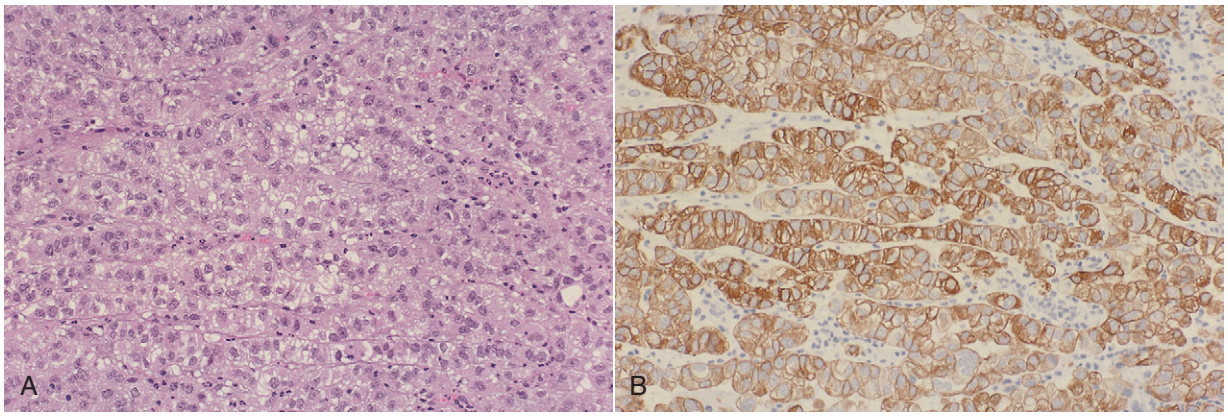

■ **FIGURE 14-30 A** and **B, Metastatic lung cancer** presenting as a mandibular radiolucency. **B,** Immunohistochemical stain for CK7 (cytokeratin 7) was helpful in determining the source of the primary lesion.

TABLE 14-1 CYTOKERATIN 7, 20, AND VILLIN EXPRESSION IN VARIOUS EPITHELIAL MALIGNANCIES

Lung (adeno)	CK7+/CK20–/villin+
Lung (SCC)	CK7–/CK20–
Colon	CK7–/CK20+/villin+
Breast	CK7+/CK20–/villin–
Kidney	CK7–/CK20–/villin–
Prostate	CK7–/CK20–

SCC, Squamous cell carcinoma.

Differential Diagnosis. The differential diagnosis of intrabony, poorly differentiated carcinoma includes anaplastic sarcoma, lymphoma, and amelanotic melanoma. The very rare primary intraosseous carcinoma of probable odontogenic origin is considered in Chapter 11. The presence of cytokeratin within the tumor cells is diagnostic of carcinoma. Immunoperoxidase stains for the leukocyte common antigen verify a diagnosis of lymphoma/leukemia, whereas immunoreactivity with melanoma-associated antigens and S-100 protein indicates a diagnosis of melanoma. Although many of these sophisticated diagnostic techniques can be used to identify the nature of an anaplastic neoplasm, there is no substitute for an accurate medical history and physical examination, especially in the diagnosis of metastatic carcinoma.

Osteonecrosis Related to Metastatic Disease. Osteonecrosis of the jaw in cancer patients for whom bisphosphonate medications have been prescribed has been recognized since 2003 (BRONJ, see Chapter 13). At to this time, clinicians considered osteonecrosis of the jaws in patients receiving bisphosphonate medications a distinct entity, possibly failing to recognize the historical presence of osteonecrosis of the jaws in patients with osteomyelitis exhibiting sequestra, diabetes, and immune compromise (acquired immunodeficiency syndrome [AIDS]), and in those patients who had undergone systemic chemotherapy for a variety of malignant diagnoses, with or without metastatic disease. Whereas osteonecrosis of the jaws in a cancer patient might be atributable to bisphosphonate use, there are some instances in which metastatic disease itself may be the cause of the osteonecrosis. Thus surgical resection of the dead bone not only treats the condition but also permits histopathologic evaluation for the presence or absence of tumor.

Treatment and Prognosis. Metastatic carcinoma of the jaw requires further work-up to identify the primary site and to stage the degree of metastatic involvement. This is useful in identifying whether the jaw metastasis represents a solitary focus or, as is often the case, is merely the clinical sign of disseminated skeletal disease. A single focus may be treated by surgical excision or chemoradiotherapy. Generalized skeletal metastases are usually an ominous event and are treated palliatively. The prognosis for patients with metastatic carcinoma of the jaws is grave, with a dismal 10% 5-year survival rate, and more than two thirds of patients dying within a year.

BIBLIOGRAPHY

Osteosarcoma

Bennett JH, Thomas G, Evans AW, et al: Osteosarcoma of the jaws: a 30-year retrospective review. Oral Surg Oral Med Oral Pathol Oral Radiol Endod 90:323–333, 2000.

Gadwal SR, Gannon FH, Fanburg-Smith JC, et al: Primary osteosarcoma of the head and neck in pediatric patients. Cancer 91:598–605, 2001.

Ha PK, Eisele DW, Frassica FJ, et al: Osteosarcoma of the head and neck: a review of the Johns Hopkins experience. Laryngoscope 109:964–969, 1999.

Kurt A-M, Unni KK, McLeod RA, et al: Low-grade intraosseous osteosarcoma. Cancer 65:1418–1428, 1990.

Longhi A, Benassi MS, Molendini L, et al: Osteosarcoma in blood relatives. Oncol Rep 8:131–136, 2001.

Lopes MA, Nikitakis NG, Ord RA, et al: Amplification and protein expression of chromosome 12q13-15 genes in osteosarcomas of the jaws. Oral Oncol 37:566–571, 2001.

Okada K, Frassica FJ, Sim FH, et al: Parosteal osteosarcoma: a clinicopathological study. J Bone Joint Surg Am 76:366–378, 1994.

Patel SG, Meyers P, Huvos AG, et al: Improved outcomes in patients with osteogenic sarcoma of the head and neck. Cancer 95:495–503, 2002.

Ragazzini P, Gamberi G, Benassi MS, et al: Analysis of SAS gene and CDK4 and MDM2 proteins in low-grade osteosarcoma, Cancer Detect Prevent 23:129–136, 1999.

Smith RB, Apostolakis LW, Karnell LH: National Cancer Data Base report on osteosarcoma of the head and neck. Cancer 98:1670–1680, 2003.

Wunder JS, Eppert K, Burrow SR, et al: Co-amplification and overexpression of CDK4, SAS, and MDM2 occurs frequently in human parosteal osteosarcomas. Oncogene 18:783–788, 1999.

Chondrosarcoma

Hackney F, Aragon S, Aufdemorte T, et al: Chondrosarcoma of the jaws: clinical findings, histopathology and treatment. Oral Surg Oral Med Oral Pathol 71:139–143, 1991.

Naumann S, Krallman PA, Unni KK, et al: Translocation der(13;21)(q10;q10) in skeletal and extraskeletal mesenchymal chondrosarcoma. Mod Pathol 15:572–576, 2002.

Saito K, Unni KK, Wollan PC, et al: Chondrosarcoma of the jaw and facial bones. Cancer 76:1550–1558, 1995.

Tien N, Chaisuparat R, Fernandes R, et al: Mesenchymal chondrosarcoma of the maxilla: case report and literature review. J Oral Maxillofac Surg 65:1260–1266, 2007.

Vencio EF, Reeve CM, Unni KK, et al: Mesenchymal chondrosarcoma of the jaw bones: clinicopathologic study of 19 cases. Cancer 82:2350–2355, 1998.

Ewing's Sarcoma

de Alava E, Gerald WL: Molecular biology of the Ewing's sarcoma/primitive neuroectodermal tumor family. J Clin Oncol 18:204–213, 2000.

Delattre O, Zucman J, Melot T, et al: The Ewing family of tumors—a subgroup of small-round-cell tumors defined by specific chimeric transcripts. N Engl J Med 331:294–299, 1994.

Sandberg AA, Bridge JA: Updates on cytogenetics and molecular genetics of bone and soft tissue tumors: Ewing sarcoma and peripheral primitive neuroectodermal tumors. Cancer Genet Cytogenet 123:1–26, 2000.

West DC: Ewing sarcoma family of tumors. Curr Opin Oncol 12:323–329, 2000.

Plasma Cell Neoplasms

Falk RH, Comenzo RL, Skinner M: The systemic amyloidosis. N Engl J Med 337:898–909, 1997.

Oken MM: Multiple myeloma: prognosis and standard treatment. Cancer Invest 15:57–64, 1997.

Metastatic Carcinoma

Campbell F, Herrington CS: Application of cytokeratin 7 and 20 immunohistochemistry to diagnostic pathology. Curr Diagn Pathol 7:113–122, 2001.

Chu P, Wu E, Weiss LM: Cytokeratin 7 and cytokeratin 20 expression in epithelial neoplasms: a survey of 435 cases. Mod Pathol 13:962–972, 2000.

Hirshberg A, Leibovich P, Buchner A: Metastatic tumors to the jawbones: analysis of 390 cases. J Oral Pathol Med 23:337–341, 1994.

Osteonecrosis Related to Metastatic Disease

Carlson ER, Basile JD: The role of surgical resection in the management of bisphosphonate-related osteonecrosis of the jaws. J Oral Maxillofacial Surg 67(suppl 1):85–95, 2009.

Frei M, Bornstein MM, Schaller B, et al: Bisphosphonate-related osteonecrosis of the jaw combined with jaw metastasis of prostate adenocarcinoma: report of a case. J Oral Maxillofac Surg 68:863–867, 2010.

Hankey GT: Osteomyelitis (necrosis) of the jaws—its pathology and treatment. Br Dent J 65:549–559, 1938.

Khamaisi M, Regev E, Yarom N, et al: Possible association between diabetes and bisphosphonate related jaw osteonecrosis. J Clin Endocrinol Metab 92:1172–1175, 2007.

Otto S, Schuler K, Ihrler S, et al: Osteonecrosis of metastases of the jaw of both? Case report and review of the literature. J Oral Maxillofac Surg 68:1185–1188, 2010.

SanGiacomo T, Tan PM, Loggi EG, et al: Progressive osseous destruction as a complication of HIV-periodontitis. Oral Surg Oral Med Oral Pathol 70:476–479, 1990.

Schwartz HC: Osteonecrosis of the jaws: a complication of cancer chemotherapy. Head Neck Surg 4:251–253, 1982.

Sung EC, Chan SM, Sakura K, et al: Osteonecrosis of the maxilla as a complication to chemotherapy: a case report. Spec Care Dentist 22:142–146, 2002.



CHAPTER 15

Metabolic and Genetic Diseases

METABOLIC CONDITIONS

Paget's Disease
Hyperparathyroidism
Hyperthyroidism
Hypothyroidism
Hypophosphatasia
Infantile Cortical Hyperostosis
Phantom Bone Disease
Acromegaly

GENETIC ABNORMALITIES

Cherubism
Osteopetrosis
Osteogenesis Imperfecta
Cleidocranial Dysplasia
Crouzon's Syndrome (Craniofacial Dysostosis)
Treacher Collins Syndrome (Mandibulofacial Dysostosis)
Pierre Robin Syndrome (Pierre Robin Sequence)
Marfan's Syndrome
Ehlers-Danlos Syndrome
Down Syndrome (Trisomy 21)
Hemifacial Atrophy
Hemifacial Hypertrophy
Clefts of the Lip and Palate
Fragile X Syndrome

METABOLIC CONDITIONS

Paget's Disease

Paget's disease, or osteitis deformans, is a chronic, slowly progressive metabolic disorder of bone of undetermined cause (Box 15-1). Etiologic theories include infection by paramyxovirus and mutations in several genes that are involved in osteoclastogenesis. Altered osteoclast development and function result in abnormal bone remodeling. Osteoblast function may also be abnormal in Paget's disease. This condition generally progresses through several stages that include an initial resorptive phase, followed by a vascular phase, and eventually by a sclerosing phase.

Clinical Features. Paget's disease is a hyperactive bone turnover state that typically occurs in patients older than 50 years. It is relatively common and has been reported to occur in 3% to 4% of the middle-aged population and in as many as 10% to 15% of the elderly. In approximately 14% of cases, a positive family history can be elicited. Paget's disease has a 3:2 male predilection, and it seems to occur more often in patients of Northern European descent.

The most common sites of involvement include the pelvis, skull, tibia, vertebrae, humerus, and sternum. The jaws are affected in approximately 20% of patients, and the maxilla is involved twice as often as the mandible (Figure 15-1). At initial presentation, symptoms often relate to deformity or pain in the affected bone(s). Bone pain is described as deep and aching. A perception of elevated skin temperature over the affected bone is often noted because of the hypervascularity of the underlying bone. Neurologic complaints—including headache, auditory or visual disturbances, facial paralysis, vertigo, and weakness—may be related, in large part, to narrowing of the skull foramina, resulting in compression of vascular and neural elements. Approximately 10% to 20% of patients are asymptomatic and are incidentally diagnosed after radiographic or laboratory studies are performed for unrelated problems.

BOX 15-1 PAGET'S DISEASE

- A progressive metabolic disturbance of many bones; undetermined cause
- Commonly affects the spine, femurs, cranium, pelvis, and sternum
- Adults, typically older than 50 years
- Symptoms—bone pain, headache, altered vision and hearing, facial paralysis, vertigo
- Oral signs
  - Bilateral, symmetric jaw enlargement—15% of all patients with Paget's disease; maxilla > mandible
  - Acquired diastemas, ill-fitting denture, patchy opacities, hypercementosis
- Oral complications
  - Early bleeding following jaw surgery
  - Late jaw fracture, osteomyelitis

>, Affected more frequently than.

Classically, dental patients who wear complete dentures may complain of newly acquired poor prosthetic adaptation and function as the maxilla symmetrically enlarges. The alveolar ridge ultimately widens, with relative flattening of the palatal vault. When teeth are present, increased spacing, as well as loosening, is noted. In severe cases, continued enlargement of the maxilla or mandible can make closure of the lips difficult or impossible.

Classic radiographic findings in the late stage of Paget's disease are due to bony sclerosis providing a patchy radiopaque pattern described as resembling cotton or wool. In the jaws, this pattern of bone change may be associated with hypercementosis or resorption of tooth roots, loss of lamina dura, and obliteration of the periodontal ligament space (Figures 15-2 and 15-3).

Histopathology. In the initial resorptive phase, random overactive osteoclastic bone resorption is evident. Resorbed bone is replaced by vascularized connective tissue in

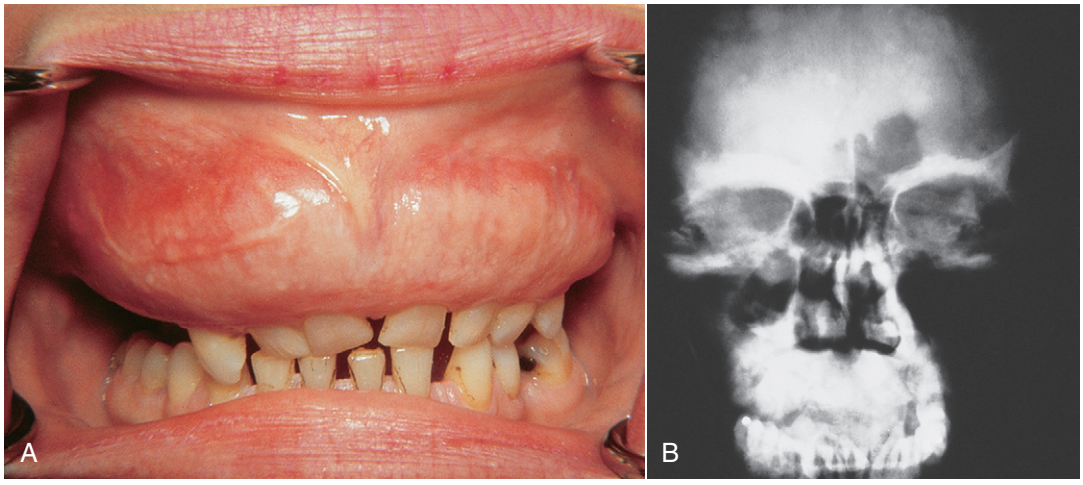

■ **FIGURE 15-1 A** and **B, Paget's disease** of the maxilla. Note uniform, symmetric enlargement in **A** and opacification of the maxilla and skull in **B.**



■ **FIGURE 15-2 Paget's disease** of the mandible with associated root resorption.



■ **FIGURE 15-3 Paget's disease** of the mandible with associated hypercementosis.

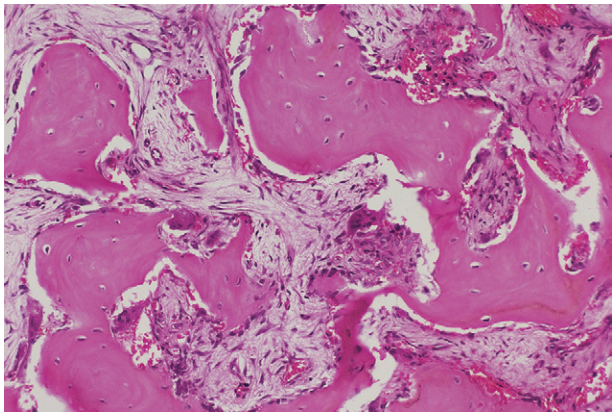

■ **FIGURE 15-4 Paget's disease** with fibrotic marrow and numerous osteoblasts and osteoclasts.

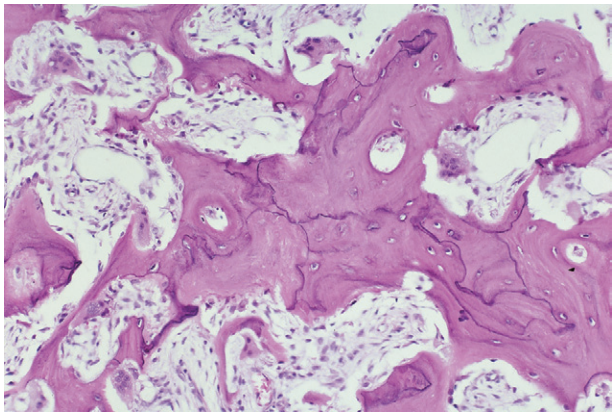

■ **FIGURE 15-5 Paget's disease** showing a mosaic bone pattern with reversal lines and prominent capillaries.

company with prominent osteolysis and osteogenesis. Bone eventually develops a dense mosaic pattern as a result of reversal lines in increasingly sclerotic bone, as osteoclasts give way to osteoblasts (Figures 15-4 and 15-5).

The laboratory can provide important information about the diagnosis of Paget's disease. Serum calcium and serum phosphate levels are normal in the presence of markedly elevated alkaline phosphatase levels. The intense osteoblastic activity in this metabolically active bone is believed to be responsible for the elevated alkaline phosphatase levels. The amount of bone resorption may be correlated with increases in urinary calcium and hydroxyproline levels.

Treatment. The primary indicator for therapeutic intervention is patient discomfort. Elevation of alkaline phosphatase levels to twice normal levels is also an indication for treatment. Therapy has been directed at controlling osteoclast formation and function. The use of calcitonin and bisphosphonate has been effective. Both suppress bone resorption and deposition, as reflected in a reduction in the biochemical indices, including alkaline phosphatase and urinary hydroxyproline levels. A 50% reduction in either index constitutes a good therapeutic response (see Chapter 13 for complications of bisphosphonate therapy).

Paget's disease is a slowly progressive disorder, but it is seldom fatal. Relief of symptoms, particularly bone pain, with oral or intravenous bisphosphonates is beneficial. Complications include skeletal deformity, weakened bones, neurologic deficits, and pathologic fracture. Heart failure may also be an important complication of Paget's disease as a consequence of the hypervascular bone. In the early vascular phase, bleeding following any type of bone surgery (e.g., tooth extraction) can be problematic. In a small percentage of cases, malignant transformation into osteosarcoma may occur. Depending on the series reported, this has ranged from 1% to 15%.

BOX 15-2 HYPERPARATHYROIDISM

Primary hyperparathyroidism—parathyroid adenoma, adenocarcinoma, hyperplasia
Secondary hyperparathyroidism—compensatory hyperplasia for low serum calcium levels caused by renal failure, malabsorption, or vitamin D deficiency
Elevated serum parathormone (PTH), calcium, and alkaline phosphatase levels and decreased phosphate levels
Kidney stones, metastatic calcification, osteoporosis, fibroblastic/giant cell tumors of bone, neurologic alterations, arrhythmias, polyuria

Hyperparathyroidism

Hyperparathyroidism may be one of three types: primary, secondary, or hereditary (Box 15-2). Rarely, hyperparathyroidism may be associated with a Noonan-type syndrome, a complex, autosomal-dominant inherited trait comprising short stature, unusual facies, mental retardation, and cardiac defects.

Primary hyperparathyroidism is characterized by hypersecretion of parathyroid hormone from one or more hyperplastic parathyroid glands (3%), a parathyroid adenoma (90%), or, less commonly, an adenocarcinoma (3%). Characteristic abnormal laboratory findings include elevated parathormone levels and elevated calcium and alkaline phosphatase levels resulting from parathormone stimulation of osteoclast-mediated bone resorption, from decreasing calcium excretion in the kidneys, and from increased intestinal resorption.

Secondary hyperparathyroidism occurs as a compensatory response to hypocalcemia, as may be found in renal failure, in patients undergoing renal dialysis, and in those with intestinal malabsorption syndromes. In these patients, vitamin D_3, which is activated in the kidney, is reduced. Vitamin D_3 is required for calcium absorption and metabolism. The hereditary form has been shown to be an

autosomal-dominant condition mapped to chromosome 1q21-q31, the location of the *HRPT2* endocrine tumor gene.

Clinical Features. The disease spectrum of primary hyperparathyroidism ranges from asymptomatic cases (diagnosed by routine serum calcium determinations) to severe cases manifesting as lethargy and occasionally coma. The incidence increases with age and is greater in postmenopausal women. Early symptoms include fatigue, weakness, nausea, anorexia, arrhythmias, polyuria, thirst, depression, and constipation. Bone pain and headaches are often reported.

Several clinical features are associated with primary form of this disease, classically described as "stones, bones, groans, and moans." Lesions of the kidneys, skeletal system, gastrointestinal tract, and nervous system are responsible for this syndrome complex. The renal component includes the presence of renal calculi or, more rarely, nephrocalcinosis associated with hypercalcemia.

Gastrointestinal manifestations include peptic ulcer resulting from the increase in gastric acid, pepsin, and serum gastrin levels. Rarely, pancreatitis may develop as a result of obstruction of the smaller pancreatic ducts by calcium deposits.

Neurologic manifestations may become evident when serum calcium levels are very high, exceeding 16 to 17 mg/dL. In such instances, coma or parathyroid crisis may occur. Loss of memory and depression are common, and, rarely, true psychosis may appear. Some of the neurologic findings may be attributed to calcium deposits in the brain.

Severe osseous changes (called, in the past, *osteitis fibrosa cystica*) are the result of significant bone demineralization, with fibrous replacement producing radiographic changes that appear cystlike. In the jaws, these lesions microscopically resemble central giant cell granuloma. Less obvious radiographic changes may include an osteoporotic appearance of the mandible and maxilla, reflecting more generalized resorption (Figure 15-6). Loosening of the teeth may occur, as well as corresponding obfuscation of trabecular detail and overall cortical thinning. Partial loss of the lamina dura is seen in a minority of patients with hyperparathyroidism (Figures 15-7 and 15-8). Pulpal obliteration, with complete calcification of the pulp chamber and canals, has been reported in association with secondary hyperparathyroidism.



■ **FIGURE 15-6 Hyperparathyroidism** producing numerous mandibular radiolucencies.

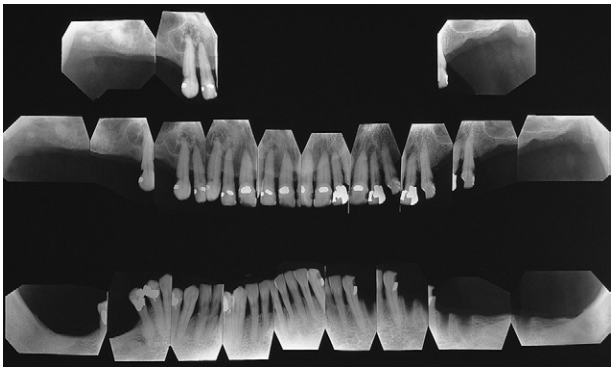

■ **FIGURE 15-7 Hyperparathyroidism** resulting in loss of lamina dura.

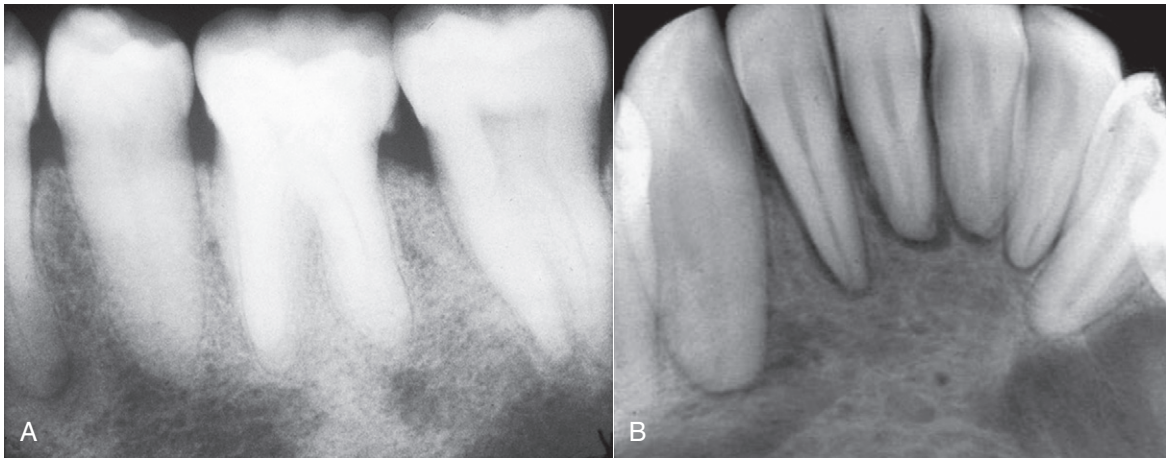

■ **FIGURE 15-8 A** and **B, Hyperparathyroidism** showing mandibular radiolucencies and loss of lamina dura.

Histopathology. The bone lesions of hyperparathyroidism, although not specific, are important in establishing the diagnosis. The bony trabeculae exhibit osteoclastic resorption, as well as the formation of osteoid trabeculae by large numbers of osteoblasts. In these areas, a delicate fibrocellular stroma contains numerous multinucleated giant cells. Accumulations of hemosiderin and extravasated red blood cells are noted. As a result, the tissues may appear reddish brown, accounting for the term *brown tumor.* The lesions are microscopically identical to central giant cell granulomas.

Treatment. Management of primary hyperparathyroidism is aimed at eliminating the parathyroid pathology and monitoring the fall in C-terminal parathyroid hormone concentration. Surgery is the treatment of choice in most instances because it offers the best opportunity for long-term cure. Medical management (bisphosphonates) may be used in some instances. Treatment of secondary hyperparathyroidism caused by increased parathyroid function resulting from chronic renal failure is aimed at management of kidney disease and control or suppression of parathyroid hormone suppression with vitamin D analogs and/or calcimimetics (e.g., cinacalcet). Dental and oral considerations in this form of hyperparathyroidism are similar to those in the primary form of the disease.

Hyperthyroidism

Hyperfunction of the thyroid gland, or hyperthyroidism, encompasses several conditions. It is characterized by excessive amounts of the thyroid hormones triiodothyronine (T_3) and thyroxine (T_4) or by increased levels of thyroid-stimulating hormone (TSH) and associated hypermetabolism. In adults, hyperthyroidism occurs with an incidence of 3 cases per 10,000 per year, with a distinct female preponderance of approximately 5 : 1.

The most common disorder leading to clinical hyperthyroidism is Graves' disease, which accounts for 70% to 85% of all cases. The cause is believed to be auto-immune. It appears to be related to the production of abnormal thyroid stimulator (long-acting thyroid stimulator [LATS]), which differs chemically and functionally from TSH. LATS is able to bind the thyroid-TSH receptors in preference to TSH and to remain bound for prolonged periods. The LATS substance is immunoglobulin (Ig)G produced by B cells, which is capable of inducing thyroid hyperplasia and increasing iodine uptake by the thyroid, free of any pituitary gland influence. Thyrotoxicosis may also result from excess stimulation of the thyroid gland via the hypothalamic-pituitary axis, or by secretion of thyroid hormone from ectopic, endogenous, or exogenous sources.

Heat intolerance, hyperhidrosis, and palmar erythema are common findings. Fine motor tremor and muscle weakness, palpitations, diarrhea, anxiety, weight loss, and menstrual dysfunction are also commonly encountered. Patients may complain of an altered complexion and thinning, brittle hair.

BOX 15-3 ORAL MANIFESTATIONS OF HYPERPARATHYROIDISM, HYPERTHYROIDISM, AND HYPOPHOSPHATASIA

Hyperparathyroidism: multiple jaw lucencies (giant cell lesions); loss of lamina dura; pulp calcifications
Hyperthyroidism: premature exfoliation and eruption of teeth; osteoporosis
Hypophosphatasia: premature loss of teeth; reduced cementum and dentin; short roots; large pulps

Ocular changes include upper lid retraction and so-called lid lag on normal blinking. The bright-eyed stare that often results from upper lid retraction may be further accentuated by exophthalmos. Pretibial myxedema and acropachy may be found in patients with Graves' disease.

Cardiac manifestations are among the earliest and most consistent features of this disease. Increased metabolic activity places greater demand on the cardiovascular system; accordingly, increases in stroke volume, pulse rate, and cardiac output are usually observed.

Although the oral manifestations of this condition are not specific, they are consistent (Box 15-3). In children, premature or accelerated exfoliation of deciduous teeth and the concomitant rapid eruption of permanent teeth are often noted. In adults, osteoporosis of the mandible and maxilla may be found. On occasion, patients may complain of a burning tongue, as well as other, nonspecific symptoms. Of interest is a reported threefold increase in the incidence of dental erosion in these patients in comparison with euthyroid control subjects.

Medical treatment consists of thyroid-suppressive drug therapy or radioactive iodine administration, which essentially inactivates the hyperfunctional thyroid tissue. Thyroid-suppressive drugs include thiocarbamides such as propylthiouracil and methimazole. These drugs inhibit iodine oxidation and iodination of tyrosyl residues—two steps in the synthesis of thyroid hormones. Surgical treatment remains an option, although the potential for inadvertent parathyroid gland removal and subsequent hypoparathyroidism is a risk.

Of clinical importance is the need to reduce stress to minimize the risk of precipitating a thyroid crisis in patients with poorly controlled disease. The use of certain drugs such as epinephrine and atropine is contraindicated, because they may precipitate a thyroid storm, which is a life-threatening state of thyroid hormone–induced hypermetabolism.

Hypothyroidism

Hypothyroidism is a systemic condition that is caused by reduced production of thyroid hormone. This results from a number of factors including congenital defect, iodine

BOX 15-4 HYPOTHYROIDISM

Delayed skeletal and dental development
Sexual immaturity
Edema of face, eyes, lips, tongue
Mental lethargy
Skin changes—dry, cold, scaly
Slow pulse
Fatigue, lethargy
Anemia—microcytic, hypochromic

deficiency goiter, autoimmune (Hashimoto's) thyroiditis, diseases of the pituitary and hypothalamus, and idiopathic causes. The common result of these etiologic factors is cretinism when the condition occurs in children, and myxedema when it occurs in adults.

The key clinical features are listed in Box 15-4. Diagnosis is based on the history, the physical examination, and determination of serum levels of TSH, and tetraiodothyronine (T_4). In typical hypothyroid patients with primary disease, T_4 levels are low (sometimes normal) and TSH levels are high (compensatory pituitary reaction). In secondary disease in which the pituitary gland is malfunctioning, both T_4 and TSH levels are low. Treatment is based on gradual replacement with synthetic and natural thyroid hormone preparations.

Hypophosphatasia

Hypophosphatasia represents a deficiency of alkaline phosphatase. This hereditary disorder is transmitted in an autosomal-recessive manner. Of dental significance is that this unusual genetic metabolic disease is one of the main causes of premature loss of the primary dentition. (Other conditions in which premature tooth exfoliation may be seen include cyclic neutropenia, idiopathic histiocytosis, juvenile periodontitis, acrodynia, rickets, and Papillon-Lefèvre syndrome.) Although the primary dentition is nearly exclusively involved, adolescent and adult patients with this condition may also experience dental abnormalities, including reduced marginal alveolar bone, abnormal root cementum, focal areas of dentin resorption, altered mineralization of coronal dentin, and large coronal pulp chambers of the molar dentition.

The chief clinical features of hypophosphatasia include enlarged pulp chambers of the primary teeth, alveolar bone loss with a predisposition for the anterior portion of the mandible and maxilla, and hypoplasia or aplasia of cementum over the root surface. Root development may be deficient, especially toward the apex. The crowns of the involved teeth demonstrate rickets-type changes, which are characterized chiefly by hypoplastic enamel defects. Enamel hypoplasia, increased pulp spaces, and premature tooth exfoliation are present in the permanent and primary dentitions. Dental abnormalities are the result of inadequate formation of both dentin and cementum.

Long bones show inadequate levels of mineralization with abnormally wide osteoid seams. Serum chemistry studies indicate a reduction in alkaline phosphatase levels, with concomitant urinary findings of detectable phosphoethanolamine. Tissue levels of alkaline phosphatase likewise are decreased in this disorder.

Four clinical types of hypophosphatasia have been recognized:

1. A congenital type has a 75% rate of neonatal mortality.
2. An early infantile type appears within the first 6 months of life, with a mortality rate of 50%. Renal calcinosis, as well as risks of cranial synostosis, delayed motor development, and premature loss of teeth, may accompany this disease.
3. A late infantile or childhood type begins between 6 and 24 months of age. Skeletal findings tend to be less pronounced, but abnormalities of long bone structures, including irregular ossifications at the metaphysis, may be observed, along with rickets-type changes at the costochondral junctions. Of importance in this form of the disease is premature loss of the anterior primary teeth, often the first sign of the illness.
4. The adult type, although distinctly uncommon, is characterized by bone pain, pathologic fractures, and a childhood history of rickets.

No successful treatment is known, apart from controlling the hypercalcemia that results from the hypophosphatasia. Large doses of vitamin D occasionally have produced partial improvement, although hypercalcemia and soft tissue calcinosis may result from such an approach. Genetic counseling of the family, as well as early diagnosis, is of great value.

Infantile Cortical Hyperostosis

Infantile cortical hyperostosis, or Caffey's disease, is a self-limited, short-lived proliferative bone disease of undetermined origin. It is characterized by cortical thickening of various bones, most commonly the mandible (80% of cases), and less commonly the clavicles, long bones, maxilla, ribs, and scapulae. Pain, fever, and hyperirritability may precede or develop concurrently with the swelling. From 75% to 90% of cases demonstrate mandibular involvement, typically over the angle and ascending ramus symmetrically. Sporadic cases of infantile cortical hyperostosis almost always show mandibular involvement, and familial cases demonstrate such involvement approximately 60% of the time.

In addition to the osseous changes, swelling of overlying soft tissues usually occurs. There are no gender, racial, or geographic predilections. The characteristic age of onset is usually by the seventh month of life; the average age of onset is 9 weeks.

Radiographically, an expansile hyperostotic process is visible over the cortical surface, with rounding or blunting

of the mandibular coronoid process. Initially, the hyperostotic element is separated from the underlying bone by a thin radiolucent line.

Diagnosis may be facilitated by the use of technetium (^{99m}Tc) scans, which are often positive, before routine radiographic detection is begun. Laboratory findings that are helpful in establishing the diagnosis include an elevated erythrocyte sedimentation rate, increased phosphatase levels, anemia, leukocytosis, and occasionally thrombocytopenia or thrombocytosis.

Infantile cortical hyperostosis is usually a self-limiting process, with treatment generally directed at supportive care. Systemic corticosteroids and nonsteroidal anti-inflammatory drugs have been used with some success. This disease has a tendency to follow an uneven, although predictable, course, with possible relapses and remissions. During such recurrences or relapses, nonsteroidal anti-inflammatory drugs have been recommended to control symptoms and halt progression of the disease, suggesting that prostaglandins may have a role in the origin. The resolution phase ranges from 6 weeks to 23 months, with an average duration of 9 months. Radiographic and histologic resolution may take up to several years, with a generally excellent prognosis, despite the possibility of recurrences and occasional residual effects, such as severe malocclusion and mandibular asymmetry.

Phantom Bone Disease

Phantom bone disease, also known as massive osteolysis, Gorham's disease, or vanishing bone disease, is an unusual process characterized by post-traumatic or spontaneous slow, progressive, localized destruction of bone. It is a non-neoplastic condition characterized by a proliferative vascular and connective tissue response. Fibrovascular tissue may completely replace the involved bone, but the mechanism of bone destruction and resorption is unknown. This is a rare entity of unknown cause, with fewer than 150 cases reported since its initial description in 1838. The process has been described in virtually every bone in the body, with 15 cases reported in the maxillofacial region.

No ethnic or gender predilection has been noted. There appears to be no genetic basis for transmission. Various studies, including metabolic, endocrine, and neurologic tests, have not been helpful in determining the cause of phantom bone disease.

In most patients, the disease develops before the fourth decade of life, although it has been described in patients ranging from 18 months to 72 years of age. Onset of the disease is insidious; pain usually is not a feature unless concomitant pathologic fracture of the involved bone occurs. Progressive atrophy of the affected bone, resulting in significant deformity, constitutes a useful diagnostic sign of massive osteolysis. Although most cases involve a single bone, the disease may be polyostotic, usually affecting contiguous bones. This disease is progressive but variable—over time, the bone may completely disappear, or it may spontaneously stabilize. Significant regeneration has not been reported.

The earliest radiographic sign of the disease has been reported to be one or more intermedullary subcortical radiolucencies of variable size, usually with indistinct margins and thin radiopaque borders. In time, these foci enlarge and coalesce, eventually involving the cortex. A characteristic tapering ultimately occurs when long bones are affected.

Laboratory studies fail to show biochemical abnormalities. Microscopically, replacement of bone by connective tissue with many dilated capillaries and anastomosing vascular channels is noted. As the disease progresses, dissolution of both medullary and cortical bone is seen. A fibrotic band, thought to represent residual periosteum, persists.

No effective treatment for phantom bone disease is known, although moderate doses of radiation therapy (40 to 45 Gy in 2-Gy fractions) have resulted in good outcomes with few long-term complications. Limited success has been attained with bone grafts and implants.

Acromegaly

Acromegaly is a rare condition with a prevalence of approximately 50 to 70 cases per million population and an incidence of 3 cases per million per year. This disease is characterized by bony and soft tissue overgrowth and metabolic disturbances. These changes occur as a result of chronic hypersecretion of growth hormone subsequent to closure of the epiphyseal plates. If hypersecretion occurs before epiphyseal closure, gigantism results.

Etiology. The cause in more than 90% of cases is hypersecretion of growth hormone from a benign pituitary adenoma, subsequent to epiphyseal closure. The pituitary tumor may occasionally produce prolactin along with growth hormone (somatomedin C) or other hormones, including TSH or adrenocorticotropic hormone (ACTH). Such adenomas, although most common in the pituitary gland itself, may also arise in ectopic locations along the migration path of tissue from Rathke's pouch. In general, growth hormone levels correlate proportionately with the size of the adenoma, as well as with the overall severity of the disease.

Clinical Features. Acromegaly presents most often in the fourth decade, with an even gender distribution and no racial or geographic predominance. This disorder is of insidious onset, and diagnosis is often delayed for many years. Younger patients have more aggressive tumors and develop clinically recognizable acromegaly more rapidly.

Clinical signs and symptoms result from local effects of the expanding pituitary mass and the effects of excess growth hormone secretion (Figure 15-9). Affected individuals present with hyperhidrosis; coarse body hair; muscle weakness; paresthesia, especially carpal tunnel syndrome; dysmenorrhea; and decreased libido or impotence. Sleep apnea, hypertension, and heart disease are also encountered.



■ **FIGURE 15-9 A** to **C, Acromegaly** of the jaw and hand.

Skin tag formation is common and may be a marker for colonic polyps. In the facial bones and the jawbones, new periosteal bone formation may be seen, as well as cartilaginous hyperplasia and ossification. Resultant orofacial changes include frontal bossing, nasal bone hypertrophy, and relative mandibular prognathism or prominence. Enlargement of the paranasal sinuses, as well as secondary laryngeal hypertrophy, produces a rather deep, resonant voice, which is typical of acromegaly. Overall coarsening of the facial features is noted, resulting from connective tissue hyperplasia.

Oral manifestations include enlargement of the mandible and maxilla, with secondary separation of teeth resulting from alveolar overgrowth. Condylar hyperplasia with concomitant bone formation at the anterior portion of the mandible and a distinct increase in the gonial angle produces a rather typical dental malocclusion and prognathism. A complete posterior cross-bite is a common finding in such a circumstance. Thickened oral mucosa, increased salivary gland tissue, macroglossia, and prominent lips are also noted in most instances. It has been reported that with concomitant changes in mandibular structure, marked alterations in the diameter of the inferior alveolar canal, myofascial pain dysfunction syndrome, and speech abnormalities may result. The demonstration of growth hormone levels that are nonsuppressible by glucose loading is diagnostic. Computed tomography or magnetic resonance imaging of the sella turcica may help confirm the diagnosis of acromegaly-associated tumor. Radioimmunoassay studies of somatomedin C may be used as a routine screening test.

Treatment. Treatment is related to normalization of growth hormone levels, with concomitant preservation of normal pituitary function. Traditionally, transsphenoidal surgery has been the therapeutic mainstay for acromegaly. Conventional radiotherapy and radiosurgery are alternatives. Primary medical management using somatostatin analogs and growth receptor antagonists has shown promise.

Successful management may be reflected in reversal of soft tissue abnormalities, although many of the facial deformities may persist. In such instances, corrective oral and maxillofacial surgery may be indicated, including mandibular osteotomy and partial glossectomy.

GENETIC ABNORMALITIES

Cherubism

Cherubism is a benign hereditary condition that is transmitted as an autosomal-dominant trait. Penetrance is 100% in males and 50% to 75% in females, with a 2:1 male predominance. Sporadic cases have also been seen. Mutations in the *SH3BP2* gene have been reported in patients with this condition. Cherubism has been classified by some investigators as

BOX 15-5 CHERUBISM: CLINICAL FEATURES

Symmetric (bilateral), asymptomatic swelling of the jaws
Mandible—lingual surface unchanged, condyles spared
Maxilla—elevation of orbital floor causes upward gaze
Buccal expansion to 12 years of age, then stabilization
Regression after 2 to 4 years and resolution by age 30
"Soap bubble" radiolucencies

an autoinflammatory disease (i.e., a genetically determined chronic noninfectious inflammatory disorder).

Clinical Features. Cherubism affects the maxilla and/or mandible and usually is found in children by 5 years of age (Box 15-5). The term *cherubism* has been used to describe patients with cherubic facies of marked fullness of the jaws and cheeks and upwardly gazing eyes. The mandibular angle, ascending ramus, retromolar region, and posterior maxilla are most often affected. The coronoid process can also be involved, but the condyles are always spared. A vast majority of cases occur only in the mandible. The bony expansion is most often bilateral, although unilateral involvement has been reported. The specific gene maps to chromosome 4p16.3, which encodes the SH3-binding protein, SH3BP2.

Patients typically have painless symmetric enlargement of the posterior region of the mandible, with expansion of the alveolar process and ascending ramus. The clinical appearance may vary from barely discernible posterior swelling of a single jaw to marked anterior and posterior expansion of both jaws, resulting in masticatory, speech, and swallowing difficulties (Figures 15-10 and 15-11). Intraorally, a hard, nontender swelling can be palpated in the affected area.

With maxillary disease, involvement of the orbital floor and the anterior wall of the antrum occurs. Superiorly directed pressure on the orbit results in increasing prominence of the sclera and the appearance of upturned eyes. The palatal vault may be reduced or obliterated. Maxillary involvement usually results in the greatest deformity. All four quadrants of the jaws may be simultaneously involved with this painless process of bony expansion (Figure 15-12). Premature exfoliation of the primary dentition may occur as early as 3 years of age. Displacement of developing tooth follicles results in poor development of selective permanent teeth and ectopic eruption or impaction. Permanent teeth may be missing or malformed, with the mandibular second and third molars most often affected. Significant malocclusions can be anticipated even with unifocal involvement.

Submandibular and upper cervical lymphadenopathy are common, although reactive regional lymphadenopathy, particularly of submandibular lymph nodes, usually subsides after 5 years of age. Intelligence is unaffected. Serum calcium and phosphorous levels are within normal limits, but alkaline phosphatase levels may be elevated.

Radiographic surveys may provide the only signs of disease. Radiographic lesions characteristically appear as numerous well-defined multilocular radiolucencies of the jaws. The borders are distinct and are divided by bony trabeculae. Seen in the mandible are expansion and thinning of the cortical plate with occasional perforation; displacement of the inferior alveolar canal may be noted. An occlusal



■ **FIGURE 15-10 Cherubism** resulting in fullness of the maxilla.



■ **FIGURE 15-11 Cherubism** of the right and left mandibular rami.



■ **FIGURE 15-12 Cherubism** of all four quadrants in an 8-year-old boy.

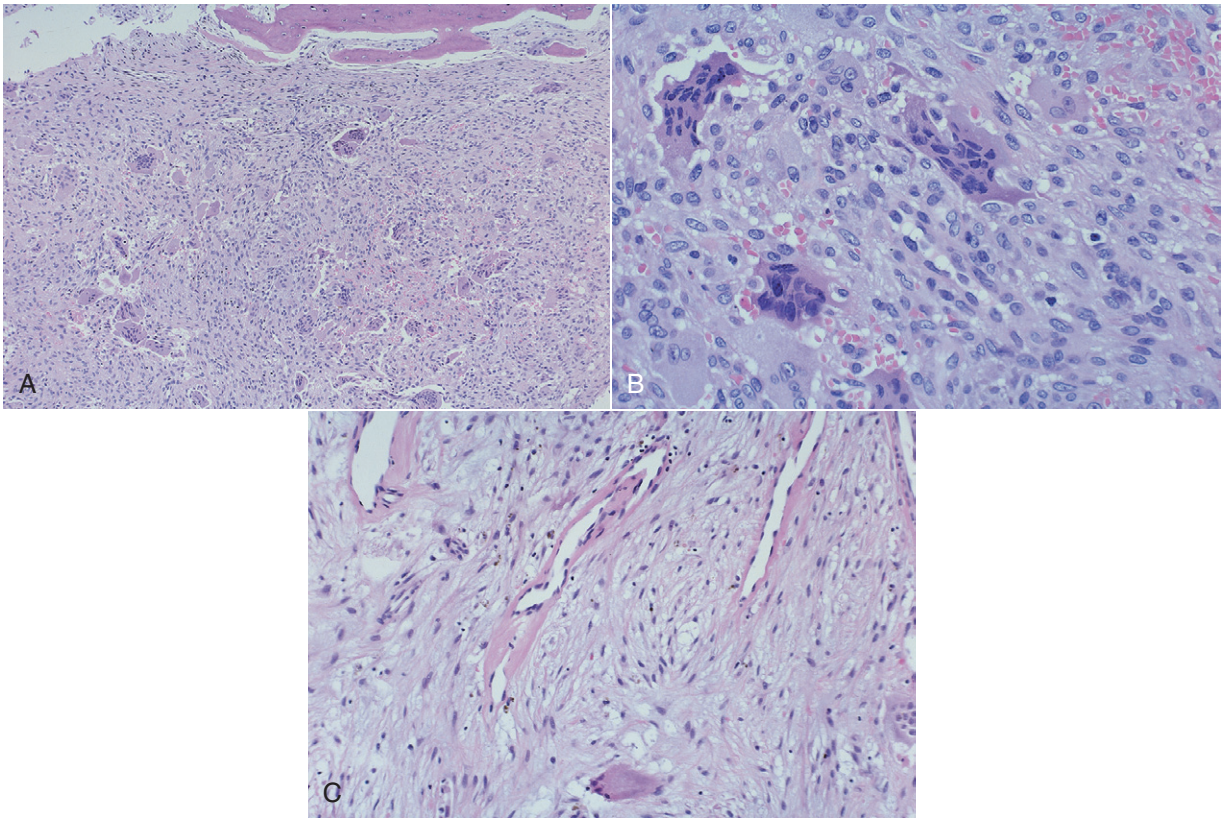

■ **FIGURE 15-13 A** through **C, Cherubism** biopsy specimen showing multinucleated giant cells in fibroblastic stroma. Note eosinophilic perivascular cuffing in **C.**

radiograph of the maxilla may give a soap bubble–like picture, with maxillary antrum obliteration. Unerupted teeth are often displaced and appear to be floating in the cystlike spaces.

Histopathology. Histologically, the lesions are composed of a vascularized fibrous stroma containing multinucleated giant cells, resembling central giant cell granuloma (Figure 15-13). Mature lesions exhibit a large amount of fibrous tissue and fewer giant cells. A distinctive feature that is often present is eosinophilic perivascular cuffing of collagen surrounding small capillaries throughout the lesion.

Treatment and Prognosis. The prognosis is relatively good, particularly if the disease is limited to one jaw, especially the mandible. After a rapid pace of bone expansion, the disease is usually self-limiting and regressive. Radiographic evidence of the condition tends to persist. Although it is generally accepted that spontaneous regression begins at puberty, with relatively good resolution by age 30, no long-term follow-up of spontaneous resolution has been documented. Surgical intervention must be based on the need to improve function, prevent debility, and satisfy esthetic considerations. If necessary, conservative curettage of the lesion with bone recontouring may be performed.

Osteopetrosis

Osteopetrosis, also known as Albers-Schönberg disease, is a rare hereditary bone condition characterized by a generalized symmetric increase in skeletal density due to defective bone resorption. Mutations in genes associated with osteoclastogenesis have been identified in patients with this disease. It can be divided into three clinical groups: (1) the infantile-malignant form is autosomal recessive in nature and is fatal within the first 2 to 3 years of life in the absence of treatment; (2) an intermediate autosomal-recessive type is nonfatal but clinically aggressive, with onset usually within the first decade; and (3) an autosomal-dominant form is the least severe, with full life expectancy but with considerable morbidity resulting from orthopedic alterations.

The characteristic feature of osteopetrosis is absence of physiologic bone resorption caused by reduced osteoclastic activity. Lack of bone resorption and remodeling results in accumulation of bone mass and manifests in skeletal disturbances, including sclerosis of bone marrow, decreased hematopoietic activity, and growth retardation. In mice with phenotypic features of osteopetrosis, the genetic abnormality resides in the granulocyte-macrophage colony-stimulating factor (GM-CSF). This abnormality has not been identified in humans.

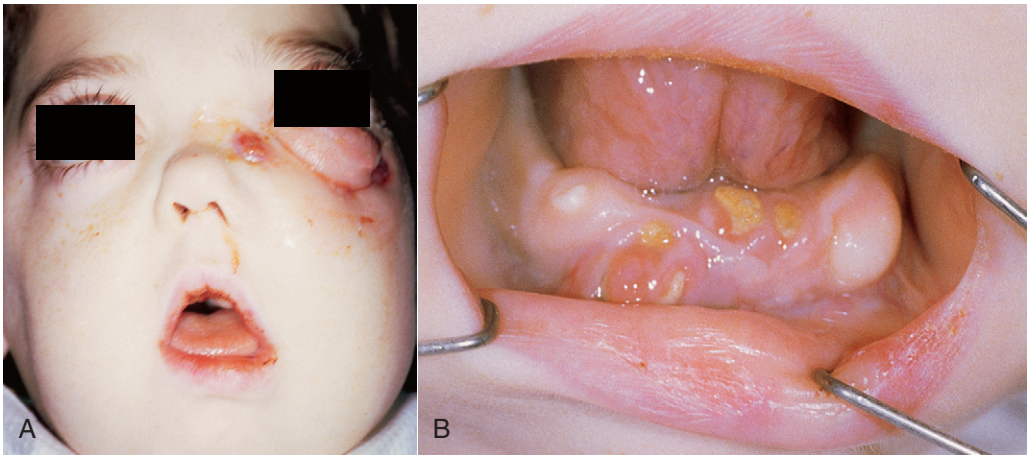

■ **FIGURE 15-14 A** and **B, Osteopetrosis** in a child. Note infraorbital draining sinuses caused by secondary osteomyelitis, and note malformed teeth in an irregular jaw.



■ **FIGURE 15-15 Osteopetrosis** showing generalized opacification of the jaws and skull.

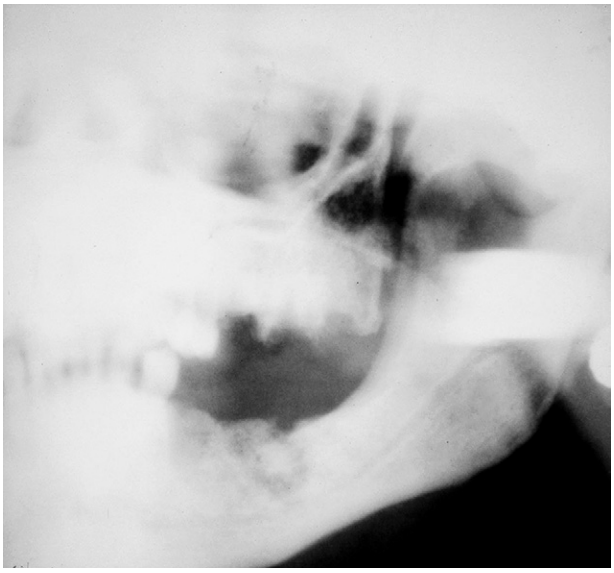

■ **FIGURE 15-16 Osteopetrosis** showing sclerotic change in the jaws and skull.

Clinical Features. Bone pain is the most common symptom. Cranial nerve compression may result in blindness, deafness, anosmia, ageusia, and sometimes facial paralysis. Normal cortical and cancellous bone is replaced by a dense, poorly structured bone that is fragile and has a propensity for pathologic fracture.

Delayed dental eruption is due to bony ankylosis, absence of alveolar bone resorption, and the formation of pseudo-odontomas during apicogenesis. Premature exfoliation may be due to a defect in the periodontal ligament.

The clinically benign adult form of osteopetrosis may not be diagnosed until the third or fourth decade. Optic and facial nerve impairment is often present as a result of narrowing of the cranial foramina and resultant pressure on the nerves. The first sign of the disease often is pathologic fracture.

Dental findings include delayed eruption, congenitally absent teeth, unerupted and malformed teeth, and enamel hypoplasia (Figure 15-14). Decreased alveolar bone production, a defective and abnormally thickened periodontal ligament, and marked mandibular prognathism have been reported. An elevated caries index may be a result of enamel hypoplasia. This has serious implications because of the propensity for development of osteomyelitis resulting from inadequate host response caused by the diminished vascular component of osteopetrotic bone. Osteomyelitis is a serious complication of the disease; it occurs most often in the mandible and occasionally in the maxilla, scapula, and extremities (Figure 15-15).

Radiographic findings are characteristic of this disease (Figure 15-16). The classic bone-within-bone radiographic presentation is due to a defect in metaphyseal bone

remodeling, resulting in greatly thickened cortices and medullary space obliteration. Skeletal density generally is greatly increased because of uniform diffuse sclerosing of all bones. The mandible is less often involved than other bones. Loss of the distinct interface between cortical and medullary bone appears, along with clubbing of the long bones with transverse peripheral banding.

Histopathology. Osteopetrosis is histologically characterized by normal production of bone with absence of physiologic bone resorption. The pattern of endochondral bone formation is disrupted, with a decrease in osteoclastic function and a compensatory increase in the number of osteoclasts. This results in failure to develop normal lamellar structure in the bone and absence of definable marrow cavities. Biopsy specimens of endochondral bone exhibit a core of calcified cartilage surrounded by bone matrix.

Treatment and Prognosis. The prognosis for infantile osteopetrosis is poor, and patients rarely survive adolescence. Recent medical advances designed to increase osteoclast differentiation and activity may prove helpful. Bone marrow transplantation has been performed in severe childhood or malignant forms of this disease in an effort to provide monocyte precursors of osteoclasts.

Death results from secondary infection or anemia. The adult variety is more variable and insidious. Bone involvement is similar to that seen in the infantile recessive type but usually is less severe. The diagnosis often is not made until a pathologic fracture occurs. The differential diagnosis should include osteomalacia, Paget's disease, hyperparathyroidism, acromegaly, and malignant bone disease.

Osteogenesis Imperfecta

Osteogenesis imperfecta represents a genetically heterogeneous group of heritable defects of connective tissue. Classically, this condition or syndrome may include fragile bones, blue sclerae, ligament laxity, hearing loss, and dentinogenesis imperfecta. Some affected patients exhibit extreme bone fragility with numerous fractures and die during the perinatal period; others suffer only mild bone fragility and live a normal life span. Clinical presentation and severity are extremely variable. Patients with osteogenesis imperfecta are classified according to their clinical and radiographic manifestations, as well as by inheritance pattern. Four distinct types have been identified: two inherited as autosomal-dominant traits, one inherited as an autosomal-recessive trait, and one inherited as both an autosomal-dominant and an autosomal-recessive trait. The presence of numerous long bone fractures early in life with dentinogenesis imperfecta, blue sclerae, or both is sufficient to establish the diagnosis. Early hearing loss in a patient or a member of the family with a history of fragile bones is highly suggestive of the disorder.

Biochemical findings suggest that osteogenesis imperfecta syndromes are a result of inborn errors of collagen metabolism. Most forms of the disease are believed to be caused by mutations in the structural genes for collagen protein (COL 1A1 and COL 1A2).

Clinical Features. Osteogenesis imperfecta type I is characterized by osteoporosis, bone fragility, blue sclerae, and conductive hearing loss in adolescents and adults. Fractures may be present at birth in 10% of patients or may commence during infancy or childhood. Considerable variability is seen in age of onset, frequency of fractures, and degree of skeletal deformity. Generally, birth weight and height are normal. Mild short stature is postnatal in onset and relates to the degree of involvement of the limbs and spine. Long bone deformities tend to be mild, with bowing of the limbs and angulation deformities occurring at previous fracture sites. Progressive kyphoscoliosis is seen in 20% of adults and may be severe. Hearing impairment, which usually begins in the second decade of life, is present in 35% of adults. Dentinogenesis imperfecta (see Chapter 16) is present in some patients with osteogenesis imperfecta type I.

Osteogenesis imperfecta type II is a lethal syndrome, and half of all patients are stillborn. It has an autosomal-recessive mode of transmission, although spontaneous cases have been reported. It is characterized in infancy by low birth weight, short stature, and broad thighs extending at right angles to the trunk. The limbs are short, curved, and grossly deformed. The skin is thin and frail and may be torn during delivery. Cranial vault ossification is lacking, and the facies is notable for hypotelorism, that is, a small beaked nose with a triangular shape. Defects in skeletal ossification lead to extreme bone fragility and frequent fractures, even during delivery. Dental abnormalities have been found, including atubular dentin with a lacework of argyrophilic fiber structures, an absence of predentin, and an abundance of argyrophilic fibers in the coronal pulp.

Osteogenesis imperfecta type III is a rare disorder characterized in neonates by severe bone fragility, multiple fractures, and progressive skeletal deformity. Sclerae are blue at birth, but the color normalizes with age; adolescents and adults exhibit normal sclera coloration. Childhood mortality is high because of cardiopulmonary complications, and the prognosis is poor because of severe kyphoscoliosis. Individuals with type III disease exhibit the shortest stature of all patients with osteogenesis imperfecta. Dentinogenesis imperfecta is found in some patients with osteogenesis imperfecta type III.

Osteogenesis imperfecta type IV is a dominantly inherited osteopenia leading to bone fragility, without the other classic features associated with osteogenesis imperfecta syndromes. The sclerae are bluish at birth only. Onset of fractures ranges from birth to adulthood, and skeletal deformities are extremely variable. Bowing of the lower limbs at birth may be the only feature of this syndrome, and progressive deformities of the long bones and the vertebral column may

occur without fracture. Spontaneous improvement often occurs with puberty. Dentinogenesis imperfecta is seen in some patients with osteogenesis imperfecta type IV. The incidence of hearing impairment in adults is low.

Treatment and Prognosis. No specific treatment is available for this condition. However, bisphosphonates have been used recently to improve bone density. The effect of the drug on fracture rate and bone growth is questionable. Management of fractures may be a significant orthopedic challenge. Rehabilitation and physical therapy for recurrent fractures, limb deformities, and kyphoscoliosis are suggested. Middle ear surgery may correct hearing loss. With the onset of puberty, the severity of this problem often lessens. When dentinogenesis imperfecta is present, management is focused around preservation of the teeth. Generally, the primary dentition is more problematic. To prevent wear and improve esthetic appearance, full crown coverage may be necessary.

Because of the wide variation in clinical expression, the prognosis ranges from very good (dominant form) to very poor (recessive form). Genetic counseling is essential, and patient support groups may provide needed emotional support to affected individuals and their families.

Cleidocranial Dysplasia

Cleidocranial dysplasia is notable for aplasia or hypoplasia of the clavicles, characteristic craniofacial malformations, and the presence of numerous supernumerary and unerupted teeth.

Etiology and Pathogenesis. Cleidocranial dysplasia is transmitted by an autosomal-dominant mode of inheritance with high penetrance and variable expressivity. A recessive form has been reported. Mutations in the transcription factor RUNX2, a regulator of bone differentiation, are the cause of this condition. About one third of cases are sporadic and appear to represent new mutations. It occurs with equal frequency among males and females, and there is no racial predilection. Most patients with the disorder are of normal intelligence.

Intramembranous and endochondral bones in the skull are affected, resulting in a sagittally diminished cranial base, transverse enlargement of the calvarium, and delayed closure of the fontanels and sutures. Hydrocephalic pressure on unossified regions of the skull, especially the fontanels, causes biparietal and frontal bossing and extension of the cranial vault. The deficiency of the clavicles is responsible for the long appearance of the neck and the narrow shoulders. Combined abnormalities of the middle third of the face and the dental alveolar complex result in the characteristic facial appearance.

Delayed or failed eruption of the teeth has been associated with lack of cellular cementum. It has been postulated that failure of cementum formation may be due to mechanical resistance to eruption by dense alveolar bone overlying the unerupted teeth. The formation of supernumerary teeth is due to incomplete or severely delayed resorption of the dental lamina, which is reactivated at the time of crown completion of the normal permanent dentition.

Clinical Features. The clinical appearance of cleidocranial dysplasia is so distinct that it is pathognomonic. The stature is mildly to moderately shortened, with the neck appearing long and narrow and the shoulders markedly drooped. Complete or partial absence of clavicular calcification, with associated muscle defects, results in hypermobility of the shoulders, allowing for variable levels of approximation in an anterior plane (Figures 15-17 and 15-18).

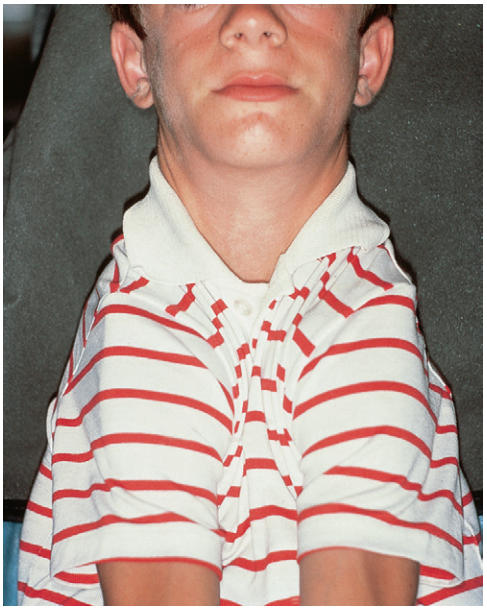

■ **FIGURE 15-17 Cleidocranial dysplasia** in a patient able to approximate his shoulders because of hypoplastic clavicles.

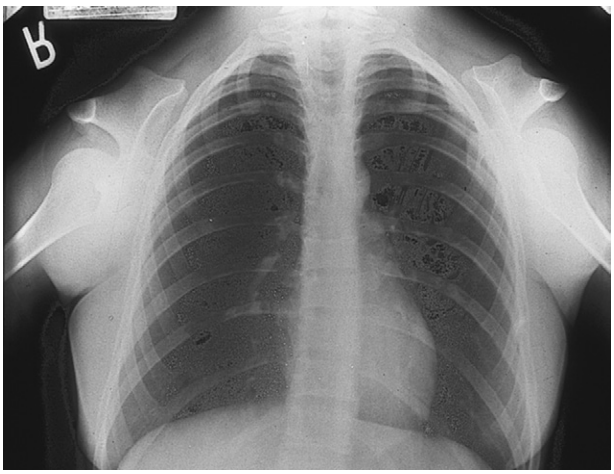

■ **FIGURE 15-18 Cleidocranial dysplasia** illustrating hypoplasia of clavicles. (Reproduced with permission from Regezi JA, Sciubba JJ, Pogrel MA: Atlas of Oral and Maxillofacial Pathology. Philadelphia, 2000, WB Saunders, Figure 12-23.)

The head is large and brachycephalic. Patients have pronounced frontal, parietal, and occipital bossing. The facial bones and paranasal sinuses are hypoplastic, giving the face a small and short appearance. The nose is broad based, with a depressed nasal bridge. Ocular hypertelorism is often present. The entire skeleton may be affected, with defects of the pelvis, long bones, and fingers. Hemivertebrae and posterior wedging of the thoracic vertebrae may contribute to the development of kyphoscoliosis and pulmonary complications.

Maxillary hypoplasia gives the mandible a relatively prognathic appearance, although some patients may show variable mandibular prognathism caused by increased length of the mandible in conjunction with a short cranial base. The palate is narrow and highly arched, and the incidence of submucosal clefts and complete or partial clefts of the palate involving the hard and soft tissues is increased. Nonunion of the symphysis of the mandible is seen.

Formation, maturation, and eruption of the deciduous dentition are usually normal. Extreme delay in physiologic root resorption occurs, however, and the result is prolonged exfoliation of primary teeth. Eruption of the permanent dentition is severely delayed, and many teeth fail to erupt. Unerupted supernumerary teeth are often present in all regions (Figure 15-19). They develop on completion of normal crown formation in the permanent dentition lingual and occlusal to the normal unerupted crown. Only one supernumerary tooth per normal tooth is generally noted. Overretention of deciduous teeth, failure of eruption of permanent teeth, numerous supernumerary teeth, and maxillary hypoplasia result in severe malocclusion.

Radiographic findings of clinical significance pertain to abnormalities of the craniofacial region, dentition, clavicles, and pelvis. Radiographs of the skull classically exhibit patent fontanels and wormian bones, broad and anomalous cranial sutures, and underdeveloped paranasal sinuses. The clavicles may be aplastic unilaterally or bilaterally, or they may be hypoplastic, appearing as small fragments attached to the sternum or the acromial process. The mandible and the maxilla contain many unerupted and supernumerary teeth, which often are malpositioned.

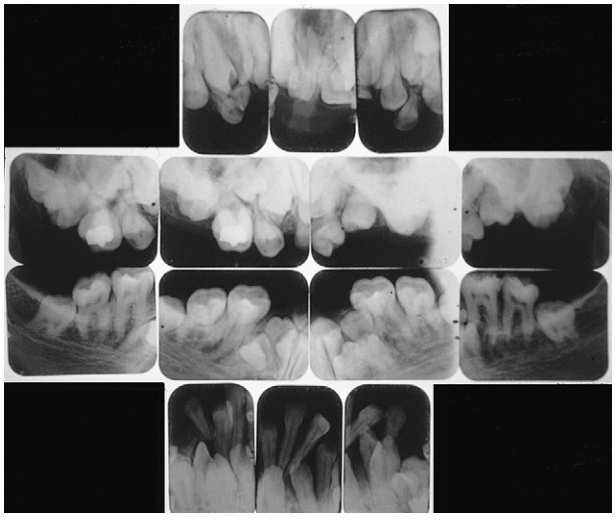

■ **FIGURE 15-19 Cleidocranial dysplasia** showing unerupted supernumerary teeth.

Treatment. No specific treatment is available for patients with cleidocranial dysplasia. Genetic counseling is most important. Protective headgear may be recommended while fontanels remain patent. The current mode of therapy for the dental anomalies combines early surgical intervention with orthodontic therapy. Extraction of supernumerary teeth and overretained primary teeth, when the root formation of succedaneous teeth is greater than 50%, is followed by surgical exposure of unerupted teeth and orthodontic treatment. Early surgical exposure of unerupted teeth has resulted in stimulation of cementum formation and eruption of the dentition with normal root formation. Orthognathic surgery for correction of the dental-facial deformity, postsurgical orthodontics, and the use of prosthetics can be anticipated.

Crouzon's Syndrome (Craniofacial Dysostosis)

Crouzon's syndrome is characterized by variable cranial deformity, maxillary hypoplasia, and shallow orbits, with exophthalmos and divergent strabismus. The character of the cranial deformity depends on the sutures affected, the degree of involvement, and the sequence of sutural fusion. Increased interpupillary distance and exophthalmos are constant features of Crouzon's syndrome and develop in early childhood as a result of premature synostosis of the coronal suture. Systemic complications include mental retardation, hearing loss, speech and visual impairment, and convulsions.

Etiology and Pathogenesis. Craniofacial dysostosis is inherited in an autosomal-dominant mode, with complete penetrance and variable expressivity. About one third of reported cases arise spontaneously. The genetic abnormality is thought to be a missense mutation in the fibroblast growth factor receptor 2 *(FGFR2)* gene. The severity of expression of the disease increases in successive siblings, with the youngest child most severely affected.

Craniosynostosis results when premature fusion of the cranial sutures occurs. The cause is not known, but premature closure of these sutures can initiate changes in the brain as a result of increased intracranial pressure.

Deformities of the cranial bones and orbital cavities are the result of fusion of sutures and increased intracranial pressure. Underdevelopment of the supraorbital ridges and overgrowth of the sphenoid wing result in small and shallow orbits; this further leads to exophthalmos and reduced orbital volume. Hypertelorism is accentuated by downward and forward displacement of the ethmoid plate. Abnormalities of the bony orbit account for several functional ocular abnormalities. Severe distortion of the cranial base leads to



■ **FIGURE 15-20 Treacher Collins syndrome. A,** Note sloping palpebral fissures and colobomas of the lower eyelids. **B,** Microtia and preauricular hair extension.

reduced maxillary growth and nasopharyngeal hypoplasia with potential upper airway restriction.

Clinical Features. Patients with Crouzon's syndrome have a characteristic facies that often is described as froglike. Midface hypoplasia and exophthalmos are striking. Patients have relative mandibular prognathism, with the nose resembling a parrot's beak. The upper lip and the philtrum are usually short, and the lower lip often droops. The cranial deformity is dependent on which sutures are involved. Proptosis with strabismus and orbital hypertelorism is common. Optic nerve damage occurs in 80% of cases.

Oral findings include severe maxillary hypoplasia, resulting in narrowing of the maxillary arch and a compressed, high-arched palate. Bilateral posterior lingual cross-bites are common. Premature posterior occlusion caused by the inferiorly positioned maxilla results in an anterior open bite.

Radiographs of the skull reveal obliterated suture lines with obvious bony continuity. A hammered-silver appearance is often seen in regions of the skull where compensatory deformity cannot occur. Lordosis of the cranial base is apparent on lateral skull projections, and angular deformities with vertical sloping of the anterior cranial fossa can be visualized. A large calvarium with hypoplasia of the maxilla, shallow orbits, and a relatively large mandible is common.

Treatment and Prognosis. Age at onset and the degree of craniosynostosis influence the severity of the complications, which range from craniofacial dystrophy to hearing loss, speech and visual impairment, and mental retardation. With a high degree of suspicion, the condition is often identifiable at birth. Ultrasonic prenatal diagnosis of exophthalmos has been reported. Early recognition is essential to guide growth and development of the face and cranium. Surgical intervention may be necessary if exophthalmos is progressive, optic nerve damage or visual acuity is impaired, evidence of developing mental deficiency is noted, or intracranial pressure continues to rise. Treatment includes the surgical placement of artificial sutures to allow growth of the brain while minimizing intracranial pressure and secondary calvarial deformities. Orthodontic treatment with subsequent orthognathic surgical intervention has been successful in managing the concomitant dentofacial deformity.

Treacher Collins Syndrome (Mandibulofacial Dysostosis)

Treacher Collins syndrome primarily affects structures developing from the first branchial arch, but it also involves the second branchial arch to a minor degree. Individuals have a convex facial profile with a prominent nose and a retrusive chin. It is generally a bilateral anomaly with a characteristic facies, including downward sloping of the palpebral fissures, colobomas of the lower eyelid, mandibular and midface hypoplasia, and deformed pinnas (Figure 15-20).

Etiology and Pathogenesis. Treacher Collins syndrome is transmitted by an autosomal-dominant mode of inheritance, although about half of cases are due to spontaneous mutation. Mutations are thought to occur in the *TCOF1* gene that encodes a nuclear phosphoprotein known as *treacle*. The gene has a high degree of penetrance, but variable expressivity is common. Affected siblings are remarkably similar, and the syndrome becomes progressively more severe in succeeding generations. This disorder is relatively rare, with an incidence between 0.5 and 10.6 cases per 10,000 births.

It is believed that the embryologic and morphologic defects that result in phenotypic expression of this syndrome begin as early as the sixth to seventh embryonic week. A defect in the stapedial artery during embryogenesis may be responsible for the anatomic deficits seen. Stapedial artery dysfunction gives rise to defects of the stapes and incus and the first arch vessels supplying the maxilla. Failure of the inferior alveolar artery to develop an ancillary vascular supply gives rise to mandibular abnormalities. Improper orientation and hypoplasia of the mandibular elevator muscles, resulting from an aplastic or hypoplastic zygomatic arch, may be contributory.

Mandibular retrognathia and midface vertical excess may be accentuated by the pull of abnormally oriented mandibular elevator muscles, causing a backward rotation in the mandibular growth pattern. The syndrome seems to be limited to defects of the bones and soft tissue of the face. Vascularization of the posterior portion of the second visceral arch by the stapedial artery seems unimpaired.

Clinical Findings. Treacher Collins syndrome is a manifestation of combined developmental anomalies of the second and, mainly, first branchial arches. It includes various degrees of hypoplasia of the mandible, maxilla, zygomatic process of the temporal bone, and external and middle ear. Abnormalities of the medial pterygoid plates and hypoplasia of the lateral pterygoid muscles are common. Right-to-left asymmetry of the deformities is generally seen. In the fully expressed syndrome, the facial appearance is characteristic and is often described as birdlike or fishlike.

Notched or linear colobomas of the outer third of the lower eyelids are found in 75% of patients. The lower eyelashes are absent medial to the colobomas in about 50% of patients. Antimongoloid obliquity, or downward slanting of the palpebral fissures, is striking.

Congenital atresia of the external auditory canal and microtia are often present. The ears are low set, with deformed, crumpled, or absent pinnae. Middle ear defects include fibrous bands of the long process of the incus, malformed and fixed stapes and malleus, and accompanying conductive hearing loss. Ear tags and blind fistulas are often located between the pinna and the commissures of the mouth.

Atypical hair growth in the shape of a tonguelike process extends from the hairline toward the cheeks. Other associated anomalies such as skeletal deformities and facial clefts may be concomitant.

Oral findings include cleft palate in about 30% of patients and macrostomia in 15% of patients. A high-arched palate and dental malocclusion consisting of apertognathia and widely separated and displaced teeth are common. Severe mandibular hypoplasia is most characteristic. The underdeveloped zygomaticomaxillary complex leads to a clinically severe midface deficiency.

Treacher Collins syndrome is notable for characteristic radiographic findings, including downward sloping floors of the orbits, a peaked bony nasal contour, an aplastic or hypoplastic zygomatic process of the temporal bone, and an obtuse mandibular angle. Lateral cephalograms demonstrate antegonial notching and a broad curvature of the mandible. The peculiar broad and concave nature of the inferior border of the mandible is characteristic and helps distinguish this condition from other syndromes involving the mandible. The condyle and coronoid processes are often flattened or aplastic.

Treatment and Prognosis. Treatment is directed at correction or reconstruction of existing deformities. Neutralization of conductive hearing loss through surgery and hearing aids is helpful. Ophthalmologic surgery is often performed to correct eye deformities through orbital reconstruction. Extensive orthodontic treatment can be anticipated before orthognathic surgical reconstruction of the mandible and maxilla.

Pierre Robin Syndrome (Pierre Robin Sequence)

The clinical presentation of micrognathia, glossoptosis, and high-arched or cleft palate in neonates has been termed *Pierre Robin syndrome.* This malformation complex can occur as an isolated finding or as a component of various syndromes or developmental anomalies. The mandibular retrognathia and hypoplasia is considered the primary malformation. Respiratory and feeding problems are prevalent and may result in episodic airway obstruction, infant hypoxia, malnutrition, and failure to thrive.

Etiology and Pathogenesis. The incidence of Pierre Robin syndrome is 5.3 to 22.7 per 100,000 births, and 39% of infants exhibit no additional abnormalities. Of the remaining infants, 25% have known syndromes, and 36% have one or more anomalies that are not part of a known syndrome. Candidate genes *(GAD67, PVRL1, SOX9)* for this syndrome have been proposed.

Fetal malposition and interposition of the tongue between the palatal shelves have long been considered the etiologic catalysts for palatal deformity and micrognathia. Arrest of mandibular development may prevent descent of the tongue and failure of palatal shelf elevation and fusion. Evidence suggests that the primary defect may be due to genetically influenced metabolic growth disturbances of the maxilla and mandible, rather than to mechanical obstruction by the tongue during embryogenesis. Organogenetic differences lead to the variable presentation of micrognathia and cleft palate.

Clinical Features. Infants present with severe micrognathia and mandibular hypoplasia. A U-shaped cleft palate is a common but not constant feature, and in some instances, the palate is highly arched. Glossoptosis is the result of retropositional attachment of the genioglossus muscle caused by the retrognathic mandible. The geniohyoid muscle is foreshortened, so that support to the hyoid bone and strap muscles of the larynx is compromised.

Treatment and Prognosis. Respiratory and feeding problems are common in the immediate postnatal and neonatal periods. Constant medical supervision may be necessary to prevent airway obstruction and hypoxia, cor pulmonale, gastroesophageal reflux, bronchopneumonia, and exhaustion. In most cases, conservative repositioning of the infant and frequent prone positioning are sufficient to prevent upper airway obstruction, by making optimal use of the effects of gravity during resting and feeding. Continuous

pulse oximetry and apnea monitoring are prudent during the neonatal period. In severe cases with chronic upper airway obstruction and failure to thrive, intraoral or nasopharyngeal airway placement, some surgical form of tongue and lip adhesion, and even tracheostomy as a last resort may be considered. Feeding infants with mandibular hypoplasia requires expertise and patience. Nasogastric feeding tubes may be required. After the first few months of life, mandibular growth and improved control of tongue musculature result in significant abatement of symptoms.

Growth of the mandible is remarkable during the first 4 years of life, and a normal profile is often achieved between 4 and 6 years of age. Some patients have a residual mild mandibular retrognathia requiring treatment later in life.

Marfan's Syndrome

Marfan's syndrome is a heritable disorder of connective tissue that is characterized by abnormalities of the skeletal, cardiovascular, and ocular systems. It is currently estimated that 23,000 Americans have Marfan's syndrome. Diagnosis is problematic because of the extreme variability of clinical expression. The disorder is notable for a number of sudden catastrophic deaths that have occurred in affected (undiagnosed) athletes.

Etiology and Pathogenesis. Marfan's syndrome is an inherited autosomal-dominant disorder that affects 1 in 10,000 individuals. There are no ethnic, racial, or gender predilections. The condition exhibits complete but extremely variable penetrance, with offspring of an affected individual having a 50% chance of acquiring the disorder. Approximately 15% to 35% of cases arise spontaneously as a result of gamete gene mutation in the ovum or sperm; a greater number occur with increasing paternal age. Diagnosis is currently based on characteristic abnormalities of the musculoskeletal, ocular, and cardiovascular systems and a positive family history. Because most features progress with age, the diagnosis is often more obvious in older persons. The gene for Marfan's syndrome has been located on chromosome 15 and will provide for diagnostic testing in pairs at risk. Recent studies involving factors responsible for assisting in microfibril formation have identified the gene for fibrillin *(FBN1)* as the disease-causing gene in this disorder. The Marfan gene is believed to produce a change in one of the proteins that provides strength to a component of connective tissue, probably collagen.

Clinical Features. Patients characteristically possess a tall, slender stature with relatively long legs and arms, large hands with long fingers, and loose joints. The arms, legs, and digits are disproportionately long compared with the patient's trunk. Chest deformities include a protrusion or indentation of the breast bone (pectus carinatum or pectus excavatum, respectively). The normal thoracic kyphosis is often absent, leading to a straight back. Various degrees of scoliosis are present. Oral findings include a narrow, high-arched palate and dental crowding. The face appears long and narrow.

The cardiovascular system is affected in nearly all persons. Mitral valve prolapse as a result of myxomatous change occurs in 75% to 85% of affected patients, and a small percentage develop mitral regurgitation. Cystic medionecrosis of the aorta occurs, resulting in ascending aortic dilation, aortic regurgitation, and heart failure. A significant consequence of this change to the medial layer of the aorta is progressive dissection, which may lead to aneurysms, placing patients at great risk for death.

Ocular findings include dislocation of the lens (ectopia lentis), which occurs in half of these patients. The most common eye anomaly, however, is myopia (nearsightedness). Retinal detachment occurs infrequently, but it is more prevalent after lens removal.

Treatment and Prognosis. Morbidity and mortality are directly related to the degree of connective tissue abnormality in involved organ systems. Cardiovascular abnormalities of dilation of the ascending aorta and mitral valve prolapse, subluxation of the lens of the eye, chest cavity deformities and scoliosis, and the potential for pneumothorax are serious prognostic indicators.

Treatment of patients with Marfan's syndrome consists of annual medical examination with a cardiovascular emphasis, frequent ophthalmologic examination, scoliosis screening, and echocardiography. Physical activity is often restricted and redirected in an attempt to protect the aorta.

Antibiotic prophylaxis has been recommended for infective endocarditis, regardless of clinical evidence of valvular disease. Beta-blockers such as propranolol are often used to reduce aortic stress and have been shown to significantly reduce both the rate of aortic dilation and the risk of serious complications. Mortality has been drastically reduced with the use of composite grafts to replace the aortic valve and the region containing the aortic aneurysm. The prognosis for untreated aneurysms of the ascending aorta is extremely poor.

Ehlers-Danlos Syndrome

Ehlers-Danlos syndrome is an uncommon inherited disorder of connective tissue that is clinically characterized by joint hypermobility, skin hyperextensibility, and fragility. Clinical manifestations of the disease are due to inherited defects in collagen metabolism. In addition to the skin and joint anomalies, severe cardiovascular and gastrointestinal complications may occur and coexist.

The condition has been classified into eight variants. The periodontal form (Ehlers-Danlos syndrome type VIII) is characterized by rapidly progressing periodontal disease, resulting in complete tooth loss by the second or third decade of life.

Etiology and Pathogenesis. Various subtypes of Ehlers-Danlos syndrome are inherited as autosomal-dominant, autosomal-recessive, and X-linked traits. Clinical presentations of recessively inherited forms are more severe.

At least 10 subtypes of Ehlers-Danlos syndrome have been classified on the basis of genetic, biochemical, and clinical characteristics. For instance, in the potentially lethal type IV variant, mutations in the gene for type III procollagen have been identified. Mutations in the lysyl hydroxylase gene are associated with the type XI variant, whereas types VIIa and VIIb are related to type I collagen gene mutations.

From a clinical standpoint, defects in type III collagen formation are associated with spontaneous rupture of the aorta or intestines—tissues rich in type III collagen. Deficiencies in collagen hydroxylysine are the result of depressed levels of lysyl hydroxylase. Others may have a defect in collagen metabolism, preventing the conversion of procollagen to collagen. Also, a disorder of copper metabolism has been noted in some patients.

Clinical Features. Classic clinical features include marked hyperelasticity of the skin and extreme laxity of the joints. The skin may be stretched for several centimeters, but when released, it resumes its former contours. Skin manifestations include a velvety appearance with a high degree of fragility and a tendency toward bruising. Minor trauma may produce ecchymoses, bleeding, and large, gaping wounds with poor healing tendencies and "cigarette paper" scar formation, which is especially evident on the forehead and lower legs and over pressure points. Other cutaneous findings include molluscoid pseudotumors, redundant skin on the palms and soles, and subcutaneous lipid-containing cysts, which may calcify.

Articular hypermobility is variable. It may be of sufficient severity to cause spontaneous dislocation of the joints. Extreme joint laxity leads to genu recurvatum (back knee), flat feet, habitual joint dislocation, kyphoscoliosis, and other skeletal deformities.

Patients may have severe cardiovascular, gastrointestinal, and pulmonary manifestations. Cardiovascular anomalies include dissecting aortic aneurysm, mitral valve prolapse, and rupture of major blood vessels. Most patients have a bleeding diathesis that may consist of a tendency to bruise or that may be severe, with hematoma formation and bleeding from the nose, gut, lungs, and urogenital tract.

Rupture of the bowel and bladder may occur. Pulmonary problems include spontaneous pneumothorax and respiratory impairment resulting from chest wall deformities. Hernias, gastrointestinal diverticula, and ocular defects may be encountered.

Orofacial features include a narrow maxilla, a flattened midface, and a wide nasal bridge. Other facial findings include hypertelorism, epicanthal folds, a hollowed appearance of the eyes, and scarring of the forehead and chin. Fragility of gingival and mucosal tissues may be problematic. The incidence of temporomandibular joint dysfunction is increased as a result of profound laxity of the joint, contributing to hypermobility and dislocation. Marked extensibility of the tongue, enabling contact with the tip of the nose, has been described.

Dental findings include deep anatomic grooves and excessive cuspal height of the molars and premolars. Stunted or dilacerated roots and the presence of free-floating coronal pulp stones resulting from alteration and calcification of intrapulpal vascular structures have been noted. Irregular composition of dentinal tubules, denticles, and enamel hypoplasia are often seen.

Treatment and Prognosis. The prognosis is dependent on the severity of the systemic manifestations. The cardiovascular status of all patients should be evaluated and closely monitored. Sudden death in youth or early adult life may occur as the result of dissecting aneurysms and ruptured arteries.

Surgical intervention must be tempered in light of connective tissue fragility. Joint ligament repair is often unsuccessful because of suture failure. Wound healing usually is delayed, and prolonged bleeding may occur after injury. Osteoarthritis is a common complication in patients with repeated dislocations.

Down Syndrome (Trisomy 21)

Down syndrome is a common and easily recognizable chromosomal aberration. The incidence is reported to be 1 in 600 to 1 in 700 live births; however, more than half of affected fetuses spontaneously abort during early pregnancy. Approximately 10% to 15% of all institutionalized patients have Down syndrome.

Most cases of trisomy 21 (94%) are caused by nondisjunction, resulting in an extra chromosome. The remaining patients with Down syndrome have various chromosome abnormalities. The translocation type occurs in 3%, mosaicism occurs in 2%, and rare chromosomal aberrations make up the remaining 1% of cases. The incidence of this condition rises with increasing maternal age.

Etiology and Pathogenesis. Possible origins of Down syndrome include undetected mosaicism in a parent, repeated exposure to the same environmental insult, genetic predisposition to nondisjunction, an ovum with an extra chromosome 21, and preferential survival in utero of trisomy 21 embryos and fetuses with increasing maternal age. Parents of any age who have had one child with trisomy 21 have a significant risk (about 1%) of having a similarly affected child—a risk of recurrence equivalent to that affecting births to a mother older than 45 years. No racial, social, economic, or gender predilections have been identified.

Clinical Features. Patients with Down syndrome present with numerous characteristic clinical findings and various common systemic manifestations (Figure 15-21). A number



■ **FIGURE 15-21 A** and **B,** Down syndrome facies. Note high-arched palate with decreased width and length in **B.**

of common phenotypic findings in children with Down syndrome have been identified; these can assist in establishing a diagnosis.

Various degrees of mental retardation occur in all patients with Down syndrome. Most mildly affected individuals are highly functioning and are able to perform well in a workshop environment. Dementia affects about 30% of patients with Down syndrome, and early aging is common. After age 35, nearly all individuals develop the neuropathologic changes analogous to those found in Alzheimer's disease, although 70% exhibit no clinically detectable behavioral changes. These two disorders have many neuropathologic and neurochemical similarities, and an increased risk for Down syndrome has been found in families with a predilection for Alzheimer's disease.

In Down syndrome, the skull is brachycephalic, with a flat occiput and a prominent forehead. A third or fourth fontanel is present, and all fontanels are large and have extended patency. Sagittal suture separation greater than 5 mm is present in 98% of affected individuals. Frontal and sphenoid sinuses are absent, and the maxillary sinus is hypoplastic in more than 90% of patients. Midface skeletal deficiency is quite marked, with ocular hypotelorism, a flattened nasal bridge, and relative mandibular prognathism.

The eyes are almond shaped, with upward-slanting palpebral fissures, epicanthic folds, and Brushfield's spots of the iris often noted. Other ocular anomalies include convergent strabismus, nystagmus, refractive errors, keratoconus, and congenital cataracts.

Congenital heart disease is present in 30% to 45% of all patients with Down syndrome. Anomalies include atrioventricular communication, partial endocardial cushion abnormalities, and ventricular septal defects. One study revealed a 50% prevalence of mitral valve prolapse; one third of these patients had negative auscultatory findings. Tetralogy of Fallot, patent ductus arteriosus, and secundum atrial septal defects are seen less often.

It appears that T-cell and probably B-cell function is aberrant, with some affected children being more susceptible to infectious disease. Respiratory tract infections are extremely common. Thyroid dysfunction occurs in upward of 50% of all patients. The incidence of acute lymphocytic leukemia and hepatitis B antigen carrier status are increased.

Skeletal problems include hypoplasia of the maxilla and sphenoid bones, rib and pelvic abnormalities, hip dislocation, and patellar subluxation. Of particular concern is the presence of atlantoaxial instability in 12% to 20% of persons with Down syndrome; this is caused by increased laxity of the transverse ligaments between the atlas and the odontoid process. Delay in recognizing this condition may result in irreversible spinal cord damage, which might occur during manipulation of the neck in patients undergoing dental therapy or general anesthesia.

Oral manifestations of Down syndrome are common. The tongue is often fissured, and macroglossia is usually relative to the small oral cavity, although true macroglossia is possible. An open-mouth posture is common because a narrow nasopharynx and hypertrophied tonsils and adenoids cause upper airway compromise. A protruding tongue and habitual mouth breathing result in drying and cracking of the lips. Palatal width and length are significantly decreased, and a bifid uvula and cleft lip and palate are

occasionally observed. Elevated concentrations of sodium, calcium, and bicarbonate ion have been demonstrated in parotid saliva.

The dentition exhibits a number of characteristic anomalies, and periodontal disease is prevalent. The incidence of dental caries, however, appears to be no greater than in normal individuals. Given the existence of poor oral hygiene, this may reflect the greater buffering capacity of the saliva or the ability to control dietary intake in institutional and home settings. A defective immune system and neutrophil motility defects directly contribute to rampant and precocious periodontal disease.

Eruption of the primary and permanent dentitions is delayed in 75% of cases. Abnormalities in eruption sequence occur often. Hypodontia occurs in both dentitions, and microdontia is often seen. Developmental tooth anomalies, including crown and root malformations, are often present. Almost 50% of patients with Down syndrome exhibit three or more dental anomalies. Enamel hypocalcification occurs in about 20% of patients.

Occlusal disharmonies consisting of malocclusion caused by relative prognathism, posterior cross-bites, apertognathia, and severe crowding of the anterior teeth are common. Posterior cross-bites are of maxillary basal bone origin, whereas anterior open bites are due to dental-alveolar discrepancies.

Treatment and Prognosis. Infants with Down syndrome that includes significant congenital heart disease have a poor prognosis. Causes of death commonly include cardiopulmonary complications, gastrointestinal malformations, and acute lymphoblastic leukemia.

Recent technologic advances in cardiovascular diagnosis have brought about marked improvement in the prognosis. Newborns require chest x-ray studies, electrocardiograms, echocardiograms, and subsequent pediatric cardiac consultation if cardiovascular anomalies are detected.

Regular ophthalmologic and audiologic follow-ups are extremely important. They can intercept early visual and hearing problems that may affect learning and development. Detection of atlantoaxial instability may prevent a catastrophic spinal injury.

Dental therapy is directed at prevention of dental caries and periodontal disease. Frequent follow-up and establishment of stringent home care regimens are critical. Highly functioning children may be candidates for orthodontic intervention and subsequent maxillofacial surgery, if required. Guidelines established by the American Heart Association for antibiotic prophylaxis should be followed for those patients with congenital heart disease.

Hemifacial Atrophy

Hemifacial atrophy is a rare disorder that represents a progressive unilateral atrophy of the face. It occasionally may affect other regions on the same side of the body. The cause of this condition is totally unknown, although trauma, dysfunction of the peripheral nervous system, infection, and genetic abnormalities have been suggested.

Hemifacial atrophy typically appears during young adulthood. The most common early sign is a painless cleft or furrow near the midline of the face. The condition involves both soft tissue and bone of the affected side. Orally, the tongue, lips, and salivary glands may show hemiatrophy. Developing teeth may show incomplete root development and delayed eruption. Unilateral involvement of the brain, ears, larynx, esophagus, diaphragm, and kidneys has been reported. Various associated ophthalmologic conditions are often encountered.

Progressive hemifacial atrophy associated with contralateral jacksonian epilepsy, trigeminal neuralgia, and changes in the eyes and hair is known as *Romberg's syndrome.* Unilateral atrophy of the upper lip with visible exposure of the maxillary teeth on the affected side is characteristic in moderately and severely involved cases.

The differential diagnosis should include facial hypoplasia, scleroderma, fat necrosis, and oculoauriculovertebral-related disorders. The distinction between Romberg's syndrome and localized scleroderma is often difficult and depends on the absence or presence of skin pigmentation and other inflammatory changes.

Hemifacial Hypertrophy

Congenital hemihypertrophy is a rare disorder characterized by gross body asymmetry. It may be simple, limited to a single digit; segmental, involving a specific region of the body; or complex, encompassing half the body. The enlargement is usually unilateral, although limited bilateral crossover does occur. All tissues in the region of abnormal growth may be involved, but a selective number of tissues are occasionally affected. Histologically, it has been determined that there is an actual increase in the number of cells present, rather than an increase in cell size. This condition classically presents as a unilateral, localized overgrowth of the facial soft tissues, bones, and teeth (Figure 15-22).

Etiology and Pathogenesis. Gross asymmetry has been found in 1 in 86,000 patients, with a 3:2 female preponderance. In males, involvement of the right side is more common. Almost all cases appear to be sporadic. Equal numbers of segmental and complex forms are known, with neither side of the body exhibiting a greater incidence of involvement. Wilms' tumor is the most common neoplasm reported in association with hemihypertrophy.

Multiple causative factors have been implicated in the development of hemihypertrophy, including anatomic and functional vascular or lymphatic abnormalities, endocrine dysfunction, an altered intrauterine environment, central nervous system disturbances, chromosome abnormalities, and asymmetric cell division. Etiologic heterogeneity may be responsible for the varied clinical presentation, affecting



■ **FIGURE 15-22 Hemifacial hypertrophy** as part of epidermal nevus syndrome.

single or multiple systems, and the degree of tissue involvement.

Clinical Features. The varieties and complexities of hemihypertrophy have resulted in a wide range of reported dentofacial findings. In some patients, the face is involved solely, but unilateral facial enlargement is often associated with hypertrophy of a portion of the body. The tissues involved often are not affected uniformly, accentuating the variable clinical presentation.

Craniofacial findings include asymmetry of the frontal bone, maxilla, palate, mandible, alveolar process, condyles, and associated overlying soft tissue. The skin may be thickened, with excessive secretions by sebaceous and sweat glands and hypertrichosis. The pinnae often are remarkably enlarged. Unilateral enlargement of one of the cerebral hemispheres may be responsible for mental retardation in 15% to 20% of patients, and for the occurrence of seizure disorders.

Oral findings are quite striking, affecting the dentition and the tongue to a significant degree. The tongue is unilaterally hyperplastic and often is distorted in appearance, with a distinct midline demarcation. Fungiform papillae are usually enlarged and resemble soft polypoid excrescences. Dysgeusia has been reported. Intraoral soft tissues are thickened and anatomically enlarged, and are often described as overabundant and lying in soft, velvety folds.

Dental findings include abnormalities in crown size and root size and shape, as well as precocious development and eruption. Permanent canines, premolars, and first molars are most often enlarged. When the primary dentition is affected, abnormalities are limited to the second molars and, less commonly, the canines. Unilateral macrodontia approaches but does not exceed a 50% increase in crown dimension in mesiodistal and buccolingual diameters. Root size and shape are proportionately enlarged or uncommonly shortened, and premature apical development is usual. The primary teeth on the affected side calcify, erupt, and exfoliate sooner than the contralateral teeth. Eruption of the affected permanent teeth by age 4 or 5 years has been reported.

Dental malocclusions are common because of asymmetric growth of the maxilla, mandible, and alveolar process and abnormalities of tooth morphology and eruption patterns. Midline deviations, severely canted occlusal planes, and open bites are common.

Lateral and posterior-anterior cephalograms demonstrate pronounced bony asymmetry and facial bone hypertrophy, as well as evidence of hypertrophied soft tissues, such as tonsillar enlargement. Root anomalies, crown enlargement, and evidence of premature eruption are easily identifiable by panoramic or periapical radiography.

Differential Diagnosis. The diagnosis of true congenital hemifacial hypertrophy rests on the presence of unilateral hypertrophy of the craniofacial structures and associated soft tissue, including the dentition. Perception of contralateral dissimilarity may be difficult and often is subjective, resulting in delayed diagnosis of congenital hemifacial hypertrophy in the infant. Angio-osteohypertrophy (Klippel-Trénaunay-Weber syndrome) can be ruled out by the absence of an overlying cutaneous nevus flammeus. Neurofibromatosis may cause gross enlargement of the soft tissue and skeleton of half the face, but it does not affect tooth size or the eruption sequence. Lymphangioma and hemangioma are characterized by soft tissue enlargement; they do not affect tooth morphology. Acromegaly produces symmetric bilateral jaw enlargement. Fibrous dysplasia, craniofacial dysostosis, and chronic inflammatory disease also should be ruled out.

Congenital hemifacial hypertrophy has been reported concomitantly with conductive hearing loss, seizure disorders, and Wilms' tumor. Other syndromes and conditions that produce soft and hard tissue hypertrophy and asymmetry include Russell's (or Russell-Silver) syndrome, congenital lymphedema, arteriovenous aneurysms, multiple exostoses, and facial tumors of childhood.

Treatment and Prognosis. During infancy and childhood, patients should be examined frequently to facilitate early identification of potential neoplasms involving the liver, adrenal glands, and kidneys. Growth and development should be observed closely for evidence of mental impairment or abnormalities of sexual development.

Abnormalities during the mixed dentition phase are related to tooth size–arch size discrepancies and abnormalities in the eruption sequence. Asymmetric growth of the

craniofacial complex and the dental alveolus requires early orthodontic intervention, including space maintenance, minor tooth movement, and functional appliances. Surgical reconstruction of hard and soft tissue anomalies to improve function and esthetics must be anticipated.

The common association of congenital hemihypertrophy with vascular anomalies, embryonal neoplasms, and mental retardation requires a multidisciplinary team of dental and medical specialists.

Clefts of the Lip and Palate

Clefts of the lip and palate are commonly encountered congenital anomalies that often result in severe functional deficits of speech, mastication, and deglutition. The prevalence of associated congenital malformations and of learning disabilities caused by hearing deficits is often increased.

Generally, clefts of the lip and palate are classified into four major types: (1) cleft lip, (2) cleft palate, (3) unilateral cleft lip and palate, and (4) bilateral cleft lip and palate. Other clefts of the lip and mouth include lip pits, linear lip indentations, submucosal clefts of the palate, bifid uvula and tongue, and numerous facial clefts extending through the nose, lips, and oral cavity. Clefting deformities are extremely variable in character; they may range from furrows in the skin and mucosa to extensive cleavages involving muscle and bone. A combination of cleft lip and palate is the most commonly seen cleft deformity.

Etiology and Pathogenesis. Cleft lip and palate accounts for approximately 50% of all cases, whereas isolated cleft lip and isolated cleft palate each occur in about 25% of cases. The incidence of cleft lip and cleft palate has been reported to be 1 in 700 to 1000 births, with variable racial predilection. Isolated cleft palate is less common, with an incidence of 1 in 1500 to 3000 births. Cleft lip with or without cleft palate is more common in males, and cleft palate alone is more common in females.

Most cases of cleft lip and/or cleft palate can be explained by the multifactorial threshold hypothesis. The multifactorial inheritance theory implies that many contributory risk genes interact with one another and the environment and collectively determine whether a threshold of abnormality is breached, resulting in a defect in the developing fetus. Multifactorial or polygenic inheritance explains the transmission of isolated cleft lip or palate, and it is extremely useful in predicting occurrence risks of this anomaly among family members of an affected individual.

Disruption of normal patterns of facial growth, including deficiencies of any of the facial processes, may lead to maldevelopment of the lips and palate. Cleft lip generally occurs at about the sixth to seventh week in utero; it is a result of failure of the epithelial groove between the medial and lateral nasal processes to be penetrated by mesodermal cells.

Cleft palate is a result of epithelial breakdown at about the eighth week of embryonic development, with ingrowth failure of mesodermal tissue and lack of lateral palatal segment fusion. Most embryologists believe that true tissue deficiencies exist in all cleft deformities, and that actual anatomic structures are absent. Various degrees of cleft lip and palate may occur, ranging from mild notching of the vermilion border or bifid uvula to severe bilateral complete clefts of the lip, alveolus, and entire palate.

Clinical Features. The Veau system of classification for cleft lip and palate is widely used by clinicians; it helps to describe the variety of lip and palatal clefts seen. This system classifies cleft lip and cleft palate separately into four major categories, with emphasis on the degree of cleft present.

Cleft lip may vary from a pit or a small notch in the vermilion border to a complete cleft extending into the floor of the nose (Figures 15-23 to 15-25). According to the Veau classification, a class I cleft of the lip is a unilateral notching of the vermilion border that does not extend into the lip. If the unilateral notching of the vermilion extends into the lip



■ **FIGURE 15-23 Cleft lip.**



■ **FIGURE 15-24 Complete unilateral cleft** extending through the alveolus and into the floor of the nose.



■ **FIGURE 15-25** Cleft (bifid) uvula.

but does not involve the floor of the nose, this is designated as a class II cleft. Class III lip clefts are unilateral clefts of the vermilion border extending through the lip into the floor of the nose. Any bilateral cleft of the lip that exhibits incomplete notching or a complete cleft is classified as a class IV cleft.

Cleft deformities of the palate can also be divided into four clinical types using the Veau system. A cleft limited to the soft palate is a class I palatal cleft. Class II clefts are defects of the hard and soft palate; they extend no farther than the incisive foramen and therefore are limited to the secondary palate. Clefts of the secondary palate may be complete or incomplete. A complete cleft includes the soft and hard palate, extending to the incisive foramen. An incomplete cleft involves the velum and a portion of the hard palate, not extending to the incisive foramen. Complete unilateral clefts extending from the uvula to the incisive foramen in the midline and the alveolar process unilaterally are designated as class III palatal clefts. Class IV clefts are complete bilateral clefts involving the soft and hard palate and the alveolar process on both sides of the premaxilla, leaving it free and often mobile.

Submucosal clefts are not included in this system of classification, but they can be identified clinically by the presence of a bifid uvula, palpable notching of the posterior portion of the hard and soft palate, and the presence of a zona pellucida (a thin, translucent membrane) covering the defect.

Clefts of the soft palate, including submucosal clefts, are often associated with velopharyngeal incompetence or eustachian tube dysfunction. Recurrent otitis media and hearing deficits are common complications. Palatal pharyngeal incompetence results from failure of the soft palate and pharyngeal wall to make contact during swallowing and speech, thus preventing the necessary muscular seal between the nasopharynx and the oropharynx. Speech often is characterized by air emission from the nose and has a hypernasal quality.

The prevalence of dental anomalies associated with cleft lip and palate is remarkable. Abnormalities of tooth number, size, morphology, calcification, and eruption have been well described. Both deciduous and permanent dentitions may be affected. The lateral incisor in the vicinity of the cleft is often involved, but teeth outside the cleft area exhibit developmental defects to a greater degree than is seen in unaffected patients.

The incidence of congenitally missing teeth is high, especially among deciduous and permanent maxillary lateral incisors adjacent to the alveolar cleft. The prevalence of hypodontia increases directly with the severity of the cleft. Complete unilateral and bilateral alveolar clefts are often associated with supernumerary teeth as well, usually the maxillary lateral incisors. Tooth formation is often delayed, and enamel hypoplasia, microdontia or macrodontia, and fused teeth are often seen.

Treatment and Prognosis. The prognosis is dependent on the severity of the cleft disorder. Esthetic considerations and hearing and speech deficits often result in significant developmental problems.

Treatment is chronologically sequenced and often requires a multidisciplinary team concept because of the extensive nature of the problem and its impact on the child and the immediate family. Craniofacial or cleft palate teams are made up of dental, medical, and surgical specialists, with the assistance of allied health professionals in social services, child development, and hearing and speech therapy.

Generally, cleft lip repair is accomplished during early infancy when the child is stable, weighs at least 10 lb, and has hemoglobin levels of 10 mg/dL. Cheiloplasty often is required later in life. Orthodontic or surgically-placed orthopedic devices are being used in infants to guide the dentoalveolar segments into normal anatomic relationships and to facilitate plastic surgical closure. Closure of soft palate defects with sliding or pharyngeal flaps by 1 year of age is often recommended to promote normal speech development. Palatal obturators are often fabricated for infants who have cleft palate disorders and who are having difficulty feeding or are regurgitating food or liquids through the nasal cavity. Early audiologic and speech evaluation is highly recommended, and hearing aids are often indicated to prevent associated learning problems in children who have cleft palate and frequent episodes of otitis media. Chronic otitis media and associated low-frequency hearing loss are results of improper orientation of the eustachian tubes and inserting muscles, resulting in middle ear fluid stasis and retrograde infection.

Preventive dental services are extremely important, because an intact dentition is the foundation for future orthodontic therapy. Treatment often is required to correct developmental dental defects. Orthodontic treatment sometimes is initiated during the primary dentition to correct unilateral and bilateral posterior maxillary cross-bites and to retract an anteriorly displaced premaxillary segment.

Once into the mixed dentition phase of development, conventional orthodontic therapy is initiated to establish a

normal maxillary arch form. This is often done in preparation for an autogenous bone graft (commonly iliac crest) to the alveolar cleft to re-establish maxillary arch continuity. It is recommended that the grafting procedure be performed when root formation of the unerupted permanent tooth associated with the alveolar defect (usually the maxillary canine) has reached one-quarter to one-half completion. These teeth have been shown to successfully erupt passively or mechanically through the graft site, consolidating the arch, preserving the graft, and re-establishing alveolar competence.

Further orthodontic treatment, followed by orthognathic surgery, is often required for those patients with significant dentofacial deformities. Frequent plastic surgical procedures to correct the esthetics and function of the vermilion border, lip, philtrum, and nose can be anticipated.

Fragile X Syndrome

It has long been recognized that among the mentally deficient in the general population, more men than women are affected. The large percentage of mentally disabled males and the historical documentation of families with affected male and unaffected female children are highly suggestive of an X-linked inheritance pattern. Since the report in 1943 of a family with 11 severely retarded males delivered to an apparently unaffected mother, multiple case reports have identified a syndrome (fragile X syndrome) characterized by X-linked mental retardation, macro-orchidism, and a characteristic phenotypic presentation.

Etiology and Pathogenesis. The fragile X syndrome, believed to account for 30% to 50% of all families with X-linked mental retardation, takes its name from an identifiable fragile site on the X chromosome that is a reliable diagnostic marker. It is now recognized that X-linked mental retardation may be as common as Down syndrome in males; it accounts for approximately 25% of all mentally disabled males, with an incidence of 0.3 to 1 affected child per 1000 male births. The finding of 20% to 30% of female carriers with various degrees of mental retardation may be explained by lyonization or random inactivation of one of the X chromosomes.

The family history remains the primary tool for recognition of patients with X-linked mental retardation. Specific cytogenetic studies can aid in the diagnosis of fragile X syndrome. In affected males, 4% to 50% (median, 20%) of cells exhibit the chromosome change—an abnormal secondary constriction near the terminal end of the long arm (q) of the X chromosome. This segment is often broken at this fragile site, hence the designation of "fragile X." In 50% of female carriers, the fragile X chromosome cannot be detected at all. Abnormalities of speech have been noted in the fragile X syndrome, and it has been theorized that major genes related to verbal function are located on the X chromosome and are disrupted at the fragile site. Recent genetic and biochemical studies have isolated a specific nucleotide alteration. This involves an expanded *CGG* repeat at one end (5′) of the *FMR1* gene, which in turn is related to a methylation step in the production of FMR protein. Degrees of altered methylation by way of *FMR* gene product may help explain the range of clinical findings.



■ **FIGURE 15-26 Fragile X syndrome,** consisting of mental retardation, a long narrow face, and large ears.

Clinical Features. The classic clinical presentation is that of a mentally retarded male with postpubescent macro-orchidism, large ears, prognathism, and a long, narrow face with a high forehead and prominent supraorbital ridges (Figure 15-26). Other findings include hyperextensible joints, mitral valve prolapse, cleft palate, and an association with Pierre Robin syndrome. Patients have a characteristic repetitive jocular speech and may exhibit hyperactive behavior or autism. The characteristic speech pattern, termed *cluttering,* is hurried and presents as repetitive sentences that come out in a rush. The hands are often large and fleshy, and the iris may be pale. Hand biting has been reported. Oral findings include a high-arched palate, prominent lateral palatine ridges, anterior and posterior dental cross-bites, and increased occlusal attrition. A high-normal birth weight is common, and an increased head circumference during infancy and childhood is noted.

The degree of mental retardation is variable, even among affected siblings. Results of testicular biopsies and endocrine function tests are found to be within normal limits.

Treatment and Prognosis. The significance of identification of X-linked retardation in families cannot be overemphasized. Because the syndrome is inherited as an X-linked trait and the fragile X site can be identified in 30% to 50% of

families with X-linked mental retardation, early diagnosis and genetic counseling are imperative.

Fragile X syndrome screening of the mentally retarded population has proved to be cost-effective. Genetic counseling of families with positive histories may help to advise potential or proven carriers of the risks of bearing an affected child. Currently, the only reliable means of prenatal diagnosis is by examination of fetal chromosomes. There is no method of excluding carrier status in females who do not express the fragile X chromosome.

Mitral valve prolapse has been reported to occur in as many as 80% of males afflicted with this syndrome, supporting the need for definitive cardiac evaluation before dental therapy.

BIBLIOGRAPHY

Metabolic Conditions

Aghi M, Blevins LS Jr: Recent advances in the treatment of acromegaly. Curr Opin Endocrinol Diabetes Obes 16:304–307, 2009.

Bernstein RM, Zaleske DJ: Familial aspects of Caffey's disease. Am J Orthop 24:777–781, 1995.

Carrillo R, Morales A, Rodriguez-Peralto JL et al: Benign fibro-osseous lesions in Paget's disease of the jaws. Oral Surg Oral Med Oral Pathol 71:588–592, 1991.

Dickson GR, Hamilton A, Hayes D et al: An investigation of vanishing bone disease. Bone 11:205–210, 1990.

Drueke TB, Ritz E: Treatment of hyperparathyroidism in CKD patients with cinacalcet and/or vitamin D derivatives. Clin J Am Soc Nephrol 4:234–241, 2009.

Dunbar SF, Rosenberg A, Mankin H et al: Gorham's massive osteolysis: the role of radiation therapy and a review of the literature. Int J Radiol Oncol Biol Phys 26:491–497, 1993.

Ezzat S, Forster MJ, Berchtold P et al: Acromegaly: clinical and biochemical features in 500 patients. Medicine 73:233–240, 1994.

Farrugia MC, Summerlin DJ, Krowiak E et al: Osteonecrosis of the mandible or maxilla associated with the use of new generation bisphosphonates. Laryngoscope 116:115–120, 2006.

Freedy RM, Bell KA: Massive osteolysis (Gorham's disease) of the temporomandibular joint. Ann Otol Rhinol Laryngol 101:1018–1020, 1992.

Helfrich MH, Hocking LJ: Genetics and aetiology of Paget's disorders of bone. Arch Biochem Biophys 15:172–182, 2008.

Hosking D: Pharmacological therapy of Paget's and other metabolic bone diseases. Bone 38:S3–S7, 2006.

Houston MS, Hay ID: Practical management of hyperthyroidism. Am Fam Physician 41:909–916, 1990.

Kanzler A, Farmand M, DiGiacomi B et al: Pathologic changes in the face and skull in acromegaly. Swiss Dent J 13:35–44, 1992.

Katznelson L: An update on treatment strategies for acromegaly. Expert Opin Pharmacother 9:2273–2280, 2008.

Khan A, Grey A, Shoback D: Medical management of asymptomatic primary hyperparathyroidism: proceedings of the third international workshop. J Clin Endocrinol Metab 94:373–381, 2009.

Layfield R: The molecular pathogenesis of Paget disease of bone. Expert Rev Mol Med 9:1–13, 2007.

Melmed S: Acromegaly pathogenesis and treatment. J Clin Invest 119:3189–3202, 2009.

Merkow RL, Lane JM: Paget's disease of bone. Orthop Clin North Am 21:171–189, 1990.

Michou L, Collet C, Laplanche JL et al: Genetics of Paget's disease of bone. Joint Bone Spine 73:243–248, 2006.

Mornet E: Hypophosphatasia. Orphanet J Rare Dis 2:40–47, 2007.

Nakai K, Komaba H, Fukagawa M: Management of mineral and bone disorder in chronic kidney disease: quo vadis? Ther Apher Dial 13(suppl 1):S2–S6, 2009.

Olsson A, Matsson L, Blomquist HK et al: Hypophosphatasia affecting the permanent dentition. J Oral Pathol Med 25:343–347, 1996.

Parisien M, Silverberg SJ, Shane E et al: Bone disease in primary hyperparathyroidism. Endocrinol Metab Clin North Am 19:19–34, 1990.

Petti GH Jr: Hyperparathyroidism. Otolaryngol Clin North Am 23:339–355, 1990.

Piatelli A: Symmetrical pulpal obliteration in mandibular first molars. J Endod 18:515–516, 1992.

Ralston SH: Pathogenesis of Paget's disease. Bone 43:819–825, 2008.

Reddy SV: Etiologic factors in Paget's disease of bone. Cell Mol Life Sci 63:391–398, 2006.

Reginster JY, Lecont MP: Efficacy and safety of drugs for Paget's disease of bone. Bone 17(suppl 5):485S–488S, 1995.

Rubin DJ, Levin RM: Neurologic complications of Paget disease of bone. Endocr Pract 15:158–166, 2009.

Singer FR: Paget's disease: when to treat and when not to treat. Nat Rev Rheumatol 5:483–489, 2009.

Szabo J, Heath B, Hill VM et al: Hereditary hyperparathyroidism-jaw tumor syndrome: the endocrine gene *HRPT2* maps to chromosome 1q21-q31. Am J Hum Genet 56:944–950, 1995.

Thomas DW, Tate RJ, Shepherd JP: Paget's disease of bone: current concepts in pathogenesis and treatment. J Oral Pathol Med 23:12–16, 1994.

Thometz JG, DiRaimiondi CA: A case of recurrent Caffey's disease treated with naproxen. Clin Orthop 323:304–309, 1996.

van Damme PA, Mooren RE: Differentiation of multiple giant cell lesions, Noonan-like syndrome and (occult) hyperparathyroidism. Int J Oral Maxillofac Surg 23:32–36, 1994.

van den Bos T, Handoko G, Niehof A et al: Cementum and dentin in hypophosphatasia. J Dent Res 84:1021–1025, 2005.

Genetic Abnormalities

Augarten A, Sagy M, Yahav J et al: Management of upper airway obstruction in Pierre Robin syndrome. Br J Oral Maxillofac Surg 28:105–108, 1990.

Basel D, Steiner RD: Osteogenesis imperfecta: recent findings shed new light on this once well-understood condition. Genet Med 11:375–385, 2009.

Bull MJ, Givan DC, Sadove AM et al: Improved outcome in Pierre Robin syndrome: effect of multidisciplinary evaluation and management. Pediatrics 86:294–301, 1990.

Callewaert B, Malfait F, Loeys B et al: Ehlers-Danlos syndromes and Marfan syndrome. Best Pract Res Clin Rheumatol 22:165–189, 2008.

Castillo H, Samson-Fang L: Effects of bisphosphonates in children with osteogenesis imperfecta: an AACPDM systemic review. Dev Med Child Neurol 51:17–29, 2009.

Daw JL Jr, Patel PK: Management of alveolar clefts. Clin Plast Surg 31:303–313, 2004.

de Vries BB, Jansen CC, Duits AA et al: Variable FMR1 gene methylation of large expansions leads to variable phenotype in three males from one fragile X family. J Med Genet 33:1007–1010, 1996.

D'Hulst C, Kooy RF: Fragile X syndrome: from molecular genetics to therapy. J Med Genet 46:577–584, 2009.

Eppley BL, van Aalst JA, Robey A et al: The spectrum of orofacial clefting. Plast Reconstr Surg 115:101e–114e, 2005.
Felix R, Hofstetter W, Cecchini MG: Recent developments in the understanding of osteopetrosis. Eur J Endocrinol 134:143–156, 1996.
Ferguson PJ, El-Shanti HI: Autoinflammatory bone disorders. Curr Opin Rheumatol 19:492–498, 2007.
Fraser FC: The genetics of cleft lip and cleft palate. Am J Hum Genet 22:336–352, 1970.
Fridrich KL, Fridrich HH, Kempf KK et al: Dental implications in Ehlers-Danlos syndrome. Oral Surg Oral Med Oral Pathol 69:431–435, 1990.
Gluckman E: Bone marrow transplantation in children with hereditary disorders. Curr Opin Pediatr 8:42–44, 1996.
Gorlin RJ, Cohen MM, Levin LS: Syndromes of the Head and Neck, 3rd ed, New York, NY, 1990, Oxford University Press.
Jacenko O: c-fos and bone loss: a proto-oncogene regulator osteoclast lineage determination. Bioassays 17:277–281, 1995.
Jakobsen LP, Knudsen MA, Lespinasse J et al: The genetic basis of the Pierre Robin sequence. Cleft Palate Craniofac J 43:155–259, 2006.
Jensen BL, Kreiborg S: Development of the dentition in cleidocranial dysplasia. J Oral Pathol Med 19:89–93, 1990.
Jones JE, Friend GW: Cleft orthotics and obturation. Oral Maxillofac Surg Clin North Am 3:517–529, 1991.
Kainulainen K, Pulkkinen L, Savolainen A et al: Location on chromosome 15 of the gene defect causing Marfan syndrome. N Engl J Med 323:935–939, 1990.
Keane MG, Pyeritz RE: Medical management of Marfan syndrome. Circulation 27:2802–2813, 2008.
Kivirikko KI: Collagens and their abnormalities in a wide spectrum of diseases. Ann Med 25:113–126, 1993.
Lee JY, Jung YS, Kim SA et al: Investigation of the *SH3BP2* gene mutation in cherubism. Acta Med Okayama 62:209–212, 2008.
Leitman SA, Prescott NL, Hicks DG et al: *SH3BP2* is rarely mutated in exon 9 in giant cell lesions outside cherubism. Clin Orthop Relat Res 459:22–27, 2007.
Loesch DZ, Hay DA, Mulley J: Transmitting males and carrier females in fragile X-revisited. Am J Med Genet 51:392–399, 1994.
Meng XM, Yu SF, Yu GY: Clinicopathologic study of 24 cases of cherubism. J Oral Maxillofac Surg 34:350–356, 2005.
Mundlos S, Otto F, Mulliken JB et al: Mutations involving the transcription factor CBFA1 cause cleidocranial dysplasia. Cell 89:773–779, 1997.
Mundy GR: Cytokines and local factors which affect osteoclast function. Int J Cell Cloning 10:215–222, 1992.
Murthy J, Bhaskar LVKS: Current concepts in genetics of nonsyndromal clefts. Indian J Plast Surg 42:68–81, 2009.
Nunn JH, Durning P: Fragile X (Martin Bell) syndrome and dental care. Br Dent J 168:160, 1990.
Prockop DJ, Kivirikko KI: Collagens: molecular biology, diseases, and potentials for therapy. Annu Rev Biochem 64:403–434, 1995.
Prockop DJ, Kuivaniemi H, Tromp G: Molecular basis of osteogenesis imperfecta and related disorders of bone. Clin Plast Surg 21:407–413, 1994.
Ramesar RS, Greenberg J, Martin R et al: Mapping of the gene for cleidocranial dysplasia in historical Cape Town (Arnold) kindred and evidence for locus homogeneity. J Med Genet 33:511–514, 1996.
Ranalli DN, Guzman R, Schmutz JA: Craniofacial and intraoral manifestations of congenital hemifacial hyperplasia: report of case. ASDC J Dent Child 57:203–208, 1990.
Reinhardt DP, Chalberg SC, Sakai LY: The structure and function of fibrillin. CIBA Found Symp 192:128–143, 1995.
Richardson A, Deussen FF: Facial and dental anomalies in cleidocranial dysplasia: a study of 17 cases. Int J Pediatr Dent 4:225–231, 1994.
Rousseau F, Heitz D, Biancalana V et al: Direct diagnosis by DNA analysis of the fragile X syndrome of mental retardation. N Engl J Med 325:1673–1681, 1991.
Sakai D, Trainor PA: Treacher Collins syndrome: unmasking the role of Tcof1/treacle. Int J Biochem Cell Biol 41:1229–1232, 2008.
Shen Z, Zou CC, Yang RW et al: Cleidocranial dysplasia: report of 3 cases and literature review. Clin Pediatr (Phila) 48:194–198, 2008.
Spengler DE: Staging in cleft lip and palate habilitation. Oral Maxillofac Surg Clin North Am 3:489–499, 1991.
Stark Z, Savarirayan R: Osteopetrosis. Orphanet J Rare Dis 4:5–16, 2009.
Tiegs RD: Heritable metabolic and dysplastic bone diseases. Endocrinol Metab Clin North Am 19:133–173, 1990.
Tiziani V, Reichenberger E, Buzzo CL et al: The gene for cherubism maps to chromosome 4p16. Am J Hum Genet 65:158–166, 1999.
Trummer T, Brenner R, Just W et al: Recurrent mutations in the *COL1A2* gene in patients with osteogenesis imperfecta. Clin Genet 59:338–342, 2001.
Ueki Y, Tiziani V, Santanna C et al: Mutations in the gene encoding c-abl-binding protein SH3 BP2 cause cherubism. Nat Genet 28:125–126, 2001.
Ulseth JO, Hestnes A, Stovner LJ et al: Dental caries and periodontitis in persons with Down syndrome. Special Care Dent 11:71–74, 1991.
Ward LM, Lalic L, Roughly PJ et al: Thirty three novel *COL1A1* and *COL1A2* mutations in patients with osteogenesis imperfecta types I-IV. Hum Mutat 17:434–439, 2001.
Yeswell HN, Pinnell SR: The Ehlers-Danlos syndromes. Semin Dermatol 12:229–240, 1993.



CHAPTER 16

Abnormalities of Teeth

ALTERATIONS IN SIZE
Microdontia
Macrodontia

ALTERATIONS IN SHAPE
Gemination
Fusion
Concrescence
Dilaceration
Dens Invaginatus
Dens Evaginatus
Taurodontism
Supernumerary Roots
Enamel Pearls
Attrition, Abrasion, Erosion

ALTERATIONS IN NUMBER
Anodontia
Impaction
Supernumerary Teeth

DEFECTS OF ENAMEL
Environmental Defects of Enamel
Amelogenesis Imperfecta

DEFECTS OF DENTIN
Dentinogenesis Imperfecta
Dentin Dysplasia

DEFECTS OF ENAMEL AND DENTIN
Regional Odontodysplasia

ABNORMALITIES OF DENTAL PULP
Pulp Calcification
Internal Resorption
External Resorption

ALTERATIONS IN COLOR
Exogenous Stains
Endogenous Stains

ALTERATIONS IN SIZE

Microdontia

In generalized microdontia, all teeth in the dentition appear smaller than normal. Teeth may actually be measurably smaller than normal, as in pituitary dwarfism, or they may be relatively small in comparison with a large mandible and maxilla.

In focal, or localized, microdontia, a single tooth is smaller than normal. The shape of these microdonts is often altered with the reduced size. This phenomenon is most commonly seen with maxillary lateral incisors in which the tooth crown appears cone or peg shaped, prompting the designation *peg lateral* (Figure 16-1). An autosomal-dominant inheritance pattern has been associated with this condition. Peg laterals are of no significance other than cosmetic appearance. The second most commonly seen microdont is the maxillary third molar, followed by supernumerary teeth (Figure 16-2).

Macrodontia

Generalized macrodontia is characterized by the appearance of enlarged teeth throughout the dentition. This may be absolute, as seen in pituitary gigantism, or it may be relative owing to a disproportionately small maxilla and mandible. The latter results in crowding of teeth and possibly an abnormal eruption pattern caused by insufficient arch space.

Focal, or localized, macrodontia is characterized by an abnormally large tooth or group of teeth. This relatively uncommon condition usually is seen with mandibular third molars. In the rare condition known as *hemifacial hypertrophy,* teeth on the affected side are abnormally large compared with the unaffected side.



■ **FIGURE 16-1** Peg laterals.

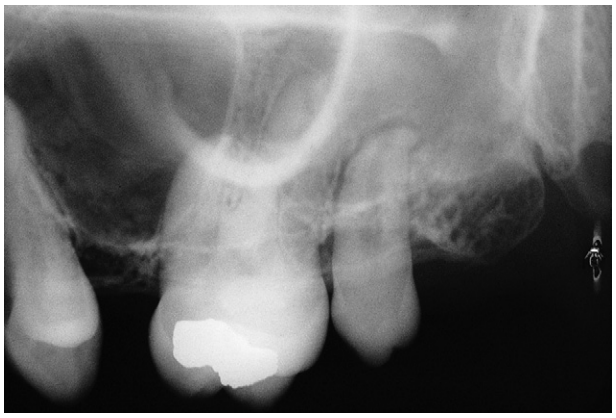

■ **FIGURE 16-2** Microdont.



■ **FIGURE 16-3** Gemination.



■ **FIGURE 16-4** Fusion.

ALTERATIONS IN SHAPE

Gemination

Gemination is the fusion of two teeth from a single enamel organ (Figure 16-3). The typical result is partial cleavage, with the appearance of two crowns that share the same root canal. Complete cleavage, or twinning, occasionally occurs, resulting in two teeth from one tooth germ. Although trauma has been suggested as a possible cause, the cause of gemination is unknown. These teeth may be cosmetically unacceptable and may cause crowding.

Fusion

Fusion is the joining of two developing tooth germs, resulting in a single large tooth structure (Figures 16-4 and 16-5). The fusion process may involve the entire length of the teeth, or it may involve the roots only, in which case cementum and dentin are shared. Root canals may also be separate or shared. It may be impossible to differentiate fusion of normal and supernumerary teeth from gemination. The cause of this condition is unknown, although trauma has been suggested.

Concrescence

Concrescence is a form of fusion in which adjacent, already formed teeth are joined by cementum (Figure 16-6). This may take place before or after eruption of teeth and is believed to be related to trauma or overcrowding. Concrescence is most commonly seen in association with the maxillary second and third molars. This condition is of no significance, unless one of the teeth involved requires extraction. Surgical sectioning may be required to save the other tooth.

Dilaceration

Dilaceration is an extraordinary curving or angulation of tooth roots (Figure 16-7). The cause of this condition has been related to trauma during root development. Movement of the crown or of the crown and part of the root from the remaining developing root may result in sharp angulation after the tooth completes development. Hereditary factors are believed to be involved in a small number of cases. Eruption generally continues without problems. However,



■ **FIGURE 16-5** Fusion.



■ **FIGURE 16-6** Concrescence.



■ **FIGURE 16-7** Dilaceration.

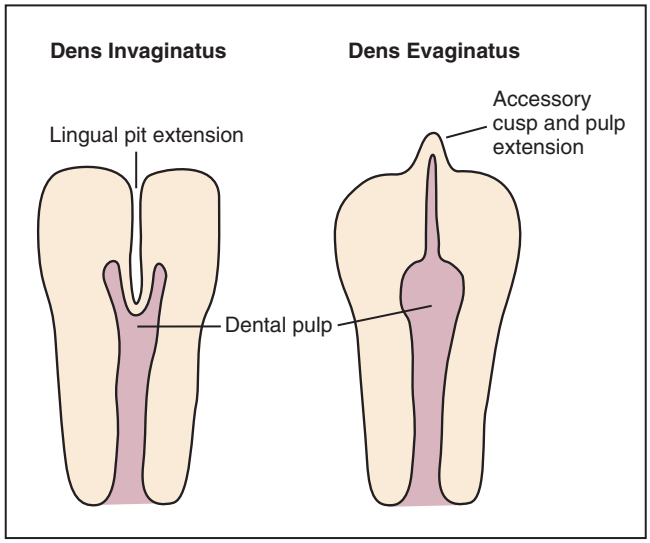

■ **FIGURE 16-8** Morphology of dens invaginatus and dens evaginatus.

extraction may be difficult. Obviously, if root canal fillings are required in these teeth, the procedure is challenging.

Dens Invaginatus

Also known as dens in dente or tooth within a tooth, dens invaginatus is an uncommon tooth anomaly that represents an exaggeration or accentuation of the lingual pit (Figures 16-8 and 16-9).

This defect ranges in severity from superficial, in which only the crown is affected, to deep, in which both the crown and the root are involved. The permanent maxillary lateral incisors are most commonly involved, although any anterior tooth may be affected. Bilateral involvement is commonly seen. The cause of this developmental condition is unknown. Genetic factors are believed to be involved in only a small percentage of cases.

Because the defect cannot be kept free of plaque and bacteria, dens invaginatus predisposes the tooth to early decay and subsequent pulpitis. Prophylactic filling of the pit is recommended to avoid this complication. Because the defect may often be identified on radiographic examination before tooth eruption, the patient can be prepared in advance of the procedure. In cases in which pulpitis has led to nonvitality, endodontic procedures may salvage the affected tooth.

Dens Evaginatus

Dens evaginatus is a relatively common developmental condition affecting predominantly premolar teeth (Leung's premolars) (Figures 16-10 to 16-12). It has been reported almost exclusively in Asians, Inuits, and Native Americans. The defect, which is often bilateral, is an anomalous tubercle, or cusp, located at the center of the occlusal surface. Because of occlusal abrasion, the tubercle wears relatively quickly,

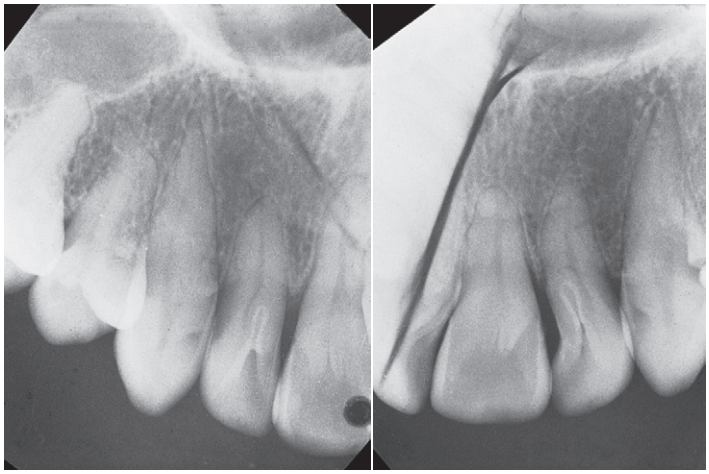

■ **FIGURE 16-9 Dens invaginatus of lateral incisors.**



■ **FIGURE 16-10 Dens evaginatus** of mandibular second premolars. (Reproduced with permission from Regezi JA, Sciubba JJ, Pogrel MA: Atlas of Oral and Maxillofacial Pathology. Philadelphia, 2000, WB Saunders, Figure 12-38.)

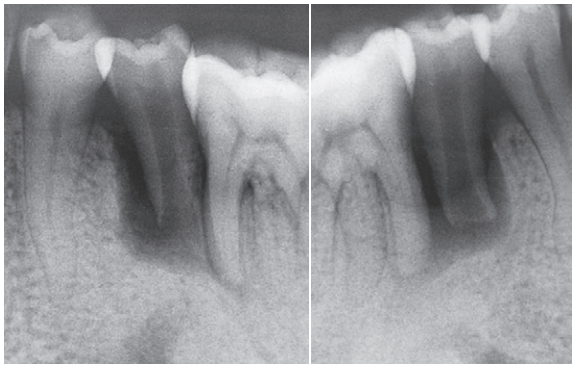

■ **FIGURE 16-11 Dens evaginatus** with associated periapical lesions. (Reproduced with permission from Regezi JA, Sciubba JJ, Pogrel MA: Atlas of Oral and Maxillofacial Pathology. Philadelphia, 2000, WB Saunders, Figure 12-39.)

causing early exposure of an accessory pulp horn that extends into the tubercle. This may result in periapical pathology in young, caries-free teeth, often before completion of root development and apical closure, making root canal fillings more difficult. Judicious grinding of the opposing tooth or the accessory tubercle to stimulate secondary dentin formation may prevent the periapical sequelae associated with this defect. Sealants, pulp capping, and partial pulpotomy have been suggested as measures to allow complete root development.



■ **FIGURE 16-12 Dens evaginatus.** Ground section showing pulpal extension through dentin to the surface of a worn occlusal cusp.

Taurodontism

Taurodontism is a variation in tooth form in which teeth have elongated crowns or apically displaced furcations, resulting in pulp chambers that have increased apical-occlusal height (Figure 16-13). Because this abnormality

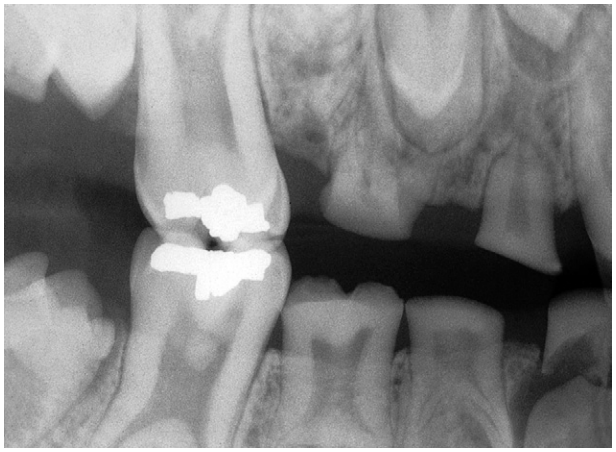

■ **FIGURE 16-13** Taurodontism.

resembles teeth in bulls and other ungulates, the term *taurodontism* was coined. Various degrees of severity may be seen, but subclassifications that have been developed to describe them appear to be of academic interest only. Taurodontism may be seen as an isolated incident, in families, and in association with syndromes such as Down syndrome and Klinefelter's syndrome; it was also seen in the now-extinct Neanderthals. Although taurodontism is generally an uncommon finding, it has been reported to have a relatively high prevalence in Eskimos, and incidence has been reported to be as high as 11% in a Middle Eastern population. Other than a possible relationship to other genetically determined abnormalities, taurodontism is of little clinical significance unless the tooth becomes nonvital, in which case it becomes a challenging endodontic problem. No treatment is required.

Supernumerary Roots

Accessory roots are most commonly seen in mandibular canines, premolars, and molars (especially third molars). They are rarely found in upper anterior teeth and mandibular incisors. Radiographic recognition of an extraordinary number of roots becomes important when extractions or root canal fillings are necessary.

Enamel Pearls

Droplets of ectopic enamel, or so-called enamel pearls, may occasionally be found on the roots of teeth (Figure 16-14). They occur most commonly in the bifurcation or trifurcation of teeth but may appear on single-rooted premolar teeth as well. Maxillary molars are more commonly affected than mandibular molars. These deposits are occasionally supported by dentin and rarely may have a pulp horn extending into them. This developmental disturbance of enamel formation may be detected on radiographic examination. It generally is of little significance except when located in an area of periodontal disease. In such cases, it may contribute to the extension of a periodontal pocket, because a periodontal ligament attachment would not be expected and hygiene would be more difficult.



■ **FIGURE 16-14** Enamel pearl.



■ **FIGURE 16-15 Abrasion** of tooth roots associated with toothbrushing.

Attrition, Abrasion, Erosion

Attrition is the physiologic wearing of teeth as a result of mastication. It is an age-related process that varies from one individual to another. Factors such as diet, dentition, jaw musculature, and chewing habits can significantly influence the pattern and extent of attrition.

Abrasion is the pathologic wearing of teeth caused by an abnormal habit or abnormal use of abrasive substances orally (Figures 16-15 and 16-16). Pipe smoking, tobacco chewing, aggressive toothbrushing, and use of abrasive dentifrices are

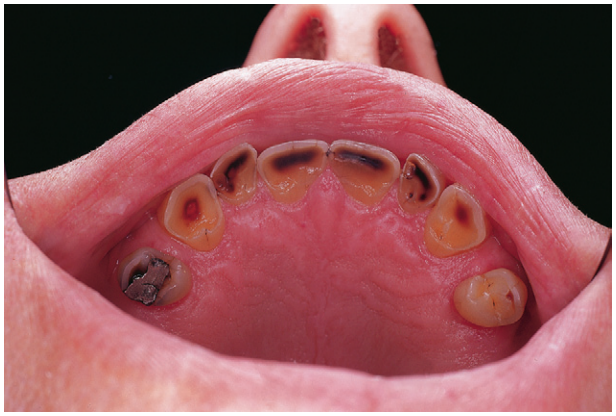

■ **FIGURE 16-16 Abrasion** of teeth associated with cigar chewing.



■ **FIGURE 16-18 Anodontia** of a permanent second premolar with ankylosis of an erupted primary molar.



■ **FIGURE 16-17 Erosion** related to acid in soft drinks.

among the more common causes. The location and pattern of abrasion are directly dependent on the cause, with so-called toothbrush abrasion along the cementoenamel junction an easily recognized pattern.

Erosion is the loss of tooth structure through a nonbacterial chemical process (Figure 16-17). Most commonly, acids are involved in the dissolution process from an external or an internal source. Externally, acid may be found in the work environment (e.g., battery manufacturing) or in the diet (e.g., citrus fruits, acid-containing soft drinks). The internal source of acid is most probably regurgitation of gastric contents. This may be seen in any disorder of which chronic vomiting is a part. Self-induced vomiting, as a component of bulimia or, less commonly, anorexia nervosa, has become an increasingly important cause of dental erosion and other oral abnormalities. The pattern of erosion associated with vomiting is usually generalized tooth loss on the lingual surfaces of maxillary teeth. However, all surfaces may be affected, especially in individuals who compensate for fluid loss by excessive intake of fruit juices. In many cases of tooth erosion, no cause is found.

ALTERATIONS IN NUMBER

Anodontia

Absence of teeth is known as *anodontia*. This condition is further qualified as *complete anodontia,* when all teeth are missing; as *partial anodontia* or *hypodontia,* when one or several teeth are missing (Figure 16-18); as *pseudoanodontia,* when teeth are absent clinically because of impaction or delayed eruption; or as *false anodontia,* when teeth have been exfoliated or extracted. Partial anodontia is relatively common. Congenitally missing teeth are usually third molars, followed by second premolars and maxillary lateral incisors.

Traditionally, hypodontia has been thought to be the result of a single dominant gene. More recent evidence using two multiple-threshold models has shown that hypodontia better fits a polygenic (caused by both environmental and genetic factors) rather than a single major gene model. The prevalence of any type of hypodontia in the general population is 4.6%, and there is no significant difference between males and females. The prevalence of maxillary lateral incisor absence is 2.1% and is significantly lower in males than in females. The prevalence of absence of the second premolars is 1.9% for the general population, with no significant difference between males and females. These findings suggest that different forms of hypodontia may be caused by, or associated with, different gene loci or genetic factors. However, the gene responsible for oligodontia or hypodontia has not yet been located.

Complete anodontia is rare but is often associated with a syndrome known as *hereditary ectodermal dysplasia,* which usually is transmitted as an X-linked recessive disorder. Partial anodontia is more typical of this syndrome, however (Figures 16-19 and 16-20). The few teeth that are present are usually conical. Hair, cutaneous appendages, and nails are also poorly developed in this syndrome. Dental implants have been used to replace missing teeth with good success.



■ **FIGURE 16-19 Hereditary ectodermal dysplasia** with **partial anodontia (hypodontia).**



■ **FIGURE 16-21 Supernumerary premolar.**

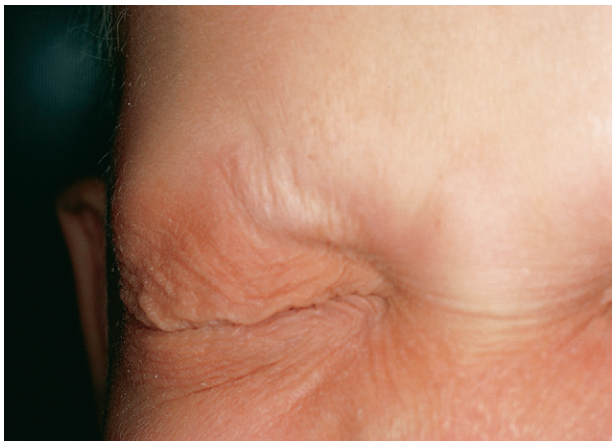

■ **FIGURE 16-20 Hereditary ectodermal dysplasia** resulting in lack of hair (including eyebrows and eyelashes) and poorly developed sweat glands.

Traditionally, dental prosthetics have provided patients with improved esthetics and masticatory function.

Impaction

Impaction of teeth is a common event that most often affects the mandibular third molars and maxillary canines. Less commonly, premolars, mandibular canines, and second molars are involved. It is rare to see impactions of incisors and first molars. Impaction occurs because of obstruction from crowding or from some other physical barrier. Occasionally, it may be due to an abnormal eruption path, presumably caused by unusual orientation of the tooth germ. *Ankylosis,* the fusion of a tooth to surrounding bone, is another cause of impaction. This usually occurs in association with erupted primary molars. It may result in impaction of a subjacent permanent tooth. The reason for ankylosis is unknown, but it is believed to be related to periapical inflammation and subsequent bone repair. With focal loss of the periodontal ligament, bone and cementum become inextricably mixed, causing fusion of the tooth to alveolar bone.

Supernumerary Teeth

Extra, or supernumerary, teeth in the dentition most probably result from continued proliferation of the permanent or primary dental lamina to form a third tooth germ (Figure 16-21). The resulting teeth may have a normal morphology or may be rudimentary and miniature. Most are isolated events, although some may be familial and others may be syndrome associated (Gardner's syndrome and cleidocranial dysplasia). Supernumerary teeth are found more often in the permanent dentition than in the primary dentition and are much more commonly seen in the maxilla than in the mandible (10 to 1). The anterior midline of the maxilla is the most common site, in which case the supernumerary tooth is known as a *mesiodens* (Figures 16-22 and 16-23). The maxillary molar area (fourth molar or paramolar) is the second most common site. The significance of supernumerary teeth is that they occupy space. When they are impacted, they may block the eruption of other teeth, or they may cause delayed eruption or maleruption of adjacent teeth. If supernumerary teeth erupt, they may cause malalignment of the dentition and may be cosmetically objectionable.

Teeth appearing at the time of birth are known as *natal teeth,* and those appearing within 6 months following birth are called *neonatal teeth.* Most of these teeth represent prematurely erupted deciduous teeth, usually mandibular central incisors. A small percentage represent supernumerary teeth. Prematurely erupted primary teeth should be preserved (provided they cause no injury to the infant or the mother), and supernumeraries should be extracted. Not to be confused with either of these phenomena is the appearance of common gingival or dental lamina cysts of the newborn.

Supernumerary teeth appearing after loss of the permanent teeth are known as *postpermanent dentition*. This is

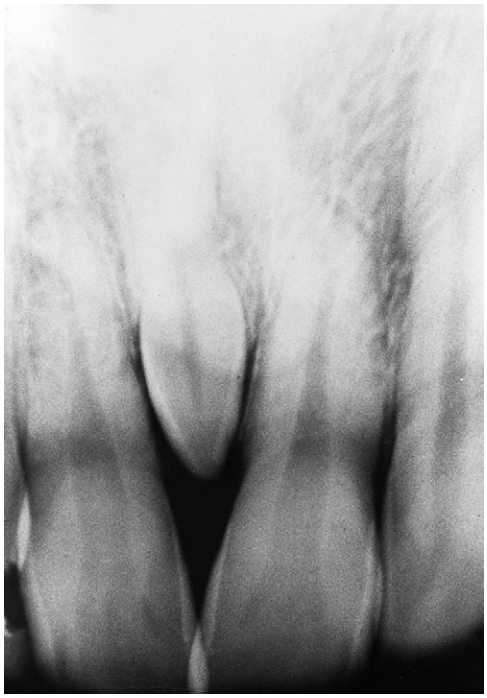

■ **FIGURE 16-22** Mesiodens.



■ **FIGURE 16-23 Mesiodens** erupted.

generally regarded as a rare event. Most teeth appearing after extraction of the permanent teeth are believed to arise from eventual eruption of previously impacted teeth.

DEFECTS OF ENAMEL

Environmental Defects of Enamel

During enamel formation, ameloblasts are susceptible to various external factors that may be reflected in erupted teeth. Metabolic injury, if severe enough and long enough, can cause defects in the quantity and shape of enamel or in the quality and color of enamel. Quantitatively defective enamel, when of normal hardness, is known as *enamel hypoplasia* (Figures 16-24 and 16-25). Qualitatively defective



■ **FIGURE 16-24** Enamel hypoplasia.



■ **FIGURE 16-25 Enamel hypoplasia** believed to be caused by childhood rickets.

enamel, in which normal amounts of enamel are produced but are hypomineralized, is known as *enamel hypocalcification* (Figure 16-26). In this defect, the enamel is softer than normal. The extent of the enamel defect is dependent on three conditions: (1) the intensity of the causative factor, (2) the duration of the factor's presence, and (3) the time at which the factor occurs during crown development. Factors that lead to ameloblast damage are highly varied, although the clinical signs of defective enamel are the same.

Causative factors may occur locally, affecting only a single tooth, or they may act systemically, affecting all teeth in which enamel is being formed. Local trauma or abscess formation can adversely affect the ameloblasts overlying a developing crown, resulting in enamel hypocalcification or hypoplasia. Affected teeth may have areas of coronal discoloration, or they may have actual pits and irregularities. This is most commonly seen in permanent teeth in which the overlying deciduous tooth becomes abscessed or is physically forced into the enamel organ of the permanent tooth. The resulting hypoplastic or hypocalcified permanent tooth is sometimes known as *Turner's tooth*.



■ **FIGURE 16-26** Enamel hypocalcification (Turner's tooth).



■ **FIGURE 16-27** Fluorosis.



■ **FIGURE 16-28** Fluorosis.

For systemic factors to have an effect on developing permanent teeth, they generally must occur after birth and before the age of 6 years. During this time, the crowns of all permanent teeth (with the exception of the third molars) develop. Because most enamel defects affect anterior teeth and first molars, systemic factors occur predominantly during the first 18 months of life. Primary teeth and possibly the tips of first permanent molars and permanent central incisors may reflect ameloblast dysfunction occurring in utero, because these are the teeth undergoing enamel calcification during this period. Specific causes of systemically induced enamel defects are often obscure, but the defects usually are attributed to childhood infectious diseases. This, however, has not been well substantiated with research data. Other cited causes of enamel hypoplasia or hypocalcification include nutritional defects such as rickets, congenital syphilis, birth trauma (neonatal line in primary teeth), fluoride, and idiopathic factors. The enamel hypoplasia that may be seen with congenital syphilis is rather characteristic. In utero infection by *Treponema pallidum* affects the developing permanent incisors and first molars. Affected incisors, also known as *Hutchinson's incisors,* are tapered incisally and are notched centrally on the incisal edge. Affected molars, also known as *mulberry molars,* show a lobulated or crenated occlusal surface.

Ingestion of drinking water containing fluoride at levels greater than 1 part per million during the time crowns are being formed may result in enamel hypoplasia or hypocalcification, also known as *fluorosis* (Figures 16-27 and 16-28). Endemic fluorosis is known to occur in areas where the drinking water contains excessive naturally occurring fluoride. As with other causative agents, the extent of damage is dependent on duration, timing, and intensity or concentration. Mild to moderate fluorosis ranges clinically from white enamel spots to mottled brown-and-white discolorations. Severe fluorosis appears as pitted, irregular, and discolored enamel. Although fluoride-induced enamel hypoplasia or hypocalcification is caries resistant, it may be cosmetically objectionable, making esthetic dental restorations desirable.

Amelogenesis Imperfecta

Amelogenesis imperfecta is a clinically and genetically heterogeneous group of disorders of enamel formation that affect both dentitions (Table 16-1). Most cases of amelogenesis imperfecta fall into one of two clinical types: *hypoplastic* or *hypocalcified* (Figures 16-29 to 16-31). A third type, known as *hypomaturation,* has been added to the list. Numerous subtypes of the three major groups are also recognized; these are based on different inheritance patterns, clinical appearances, and radiographic features.

Several genes that are involved in enamel formation (amelogenin, enamelin, kallikrein 4, MMP20, others) are mutated in various forms of this condition. The hereditary patterns range from autosomal dominant or recessive to X-linked dominant or recessive. Most cases of amelogenesis imperfecta are inherited as an autosomal-dominant trait, with clinical manifestations being somewhat variable. Mutations in the enamelin gene are believed to be responsible for the phenotypic changes. X-linked amelogenesis imperfecta manifests itself differently in males and females. Affected

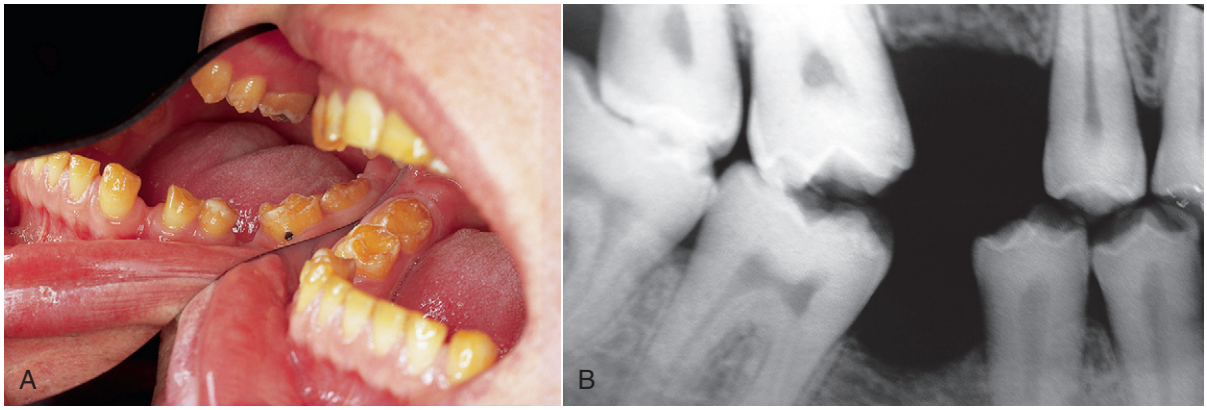

■ **FIGURE 16-29 A** and **B, Amelogenesis imperfecta,** hypoplastic type.



■ **FIGURE 16-30 Amelogenesis imperfecta,** hypoplastic type.



■ **FIGURE 16-31 Amelogenesis imperfecta,** hypocalcified type.

TABLE 16-1 HEREDITARY CONDITIONS OF TEETH

	Amelogenesis Imperfecta	Dentinogenesis Imperfecta	Dentin Dysplasia
Heredity	Many patterns	Autosomal dominant	Autosomal dominant
Teeth affected	All teeth, both dentitions	All teeth, both dentitions	All teeth, both dentitions
Tooth color	Yellow	Yellow	Normal
Tooth shape	Smaller, pitted	Extreme occlusal wear	Normal
X-ray findings	Normal pulps/dentin; reduced enamel	Obliterated pulps, short roots, bell crowns	Obliterated pulps, periapical cysts/ granulomas
Systemic manifestations	No	Osteogenesis imperfecta occasionally	No
Treatment	Full crowns	Full crowns	None; early tooth loss

males may have a very thin, smooth enamel layer, whereas females may have thicker enamel with vertical grooves as a result of X chromosome inactivation (Lyon phenomenon). The defective protein in X-linked disease has been shown to be due to mutations in the amelogenin gene.

In the *hypoplastic* type of amelogenesis imperfecta, teeth erupt with insufficient amounts of enamel, ranging from pits and grooves in one patient to complete absence (aplasia) in another. Because of reduced enamel thickness in some cases, abnormal contour and absent interproximal contact points may be evident. In the *hypocalcified* type, the quantity of enamel is normal, but it is soft and friable, so that it fractures and wears readily. The color of the teeth varies from tooth to tooth and from patient to patient—from white opaque to yellow to brown. Teeth also tend to darken with age as a result of exogenous staining. Radiographically, enamel appears reduced in bulk, often showing a thin layer over occlusal and interproximal surfaces. Dentin and pulp chambers appear normal. Although the enamel is soft and irregular, teeth are not caries prone. Treatment focuses on esthetics

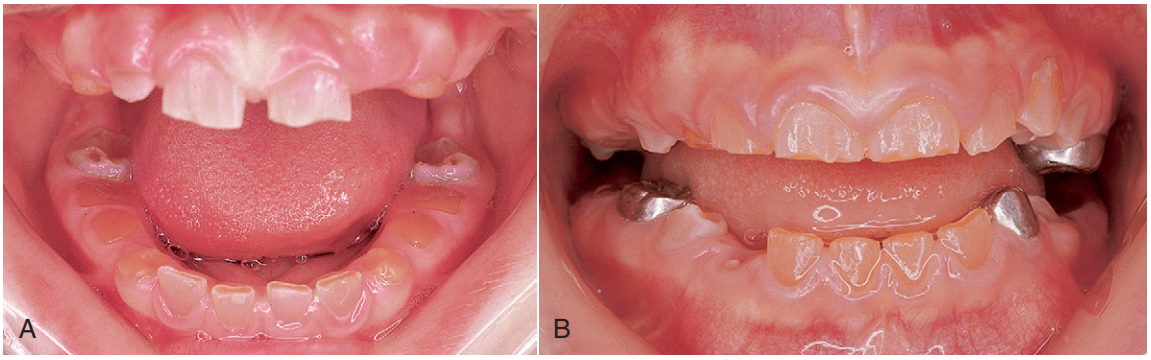

■ **FIGURE 16-32 Dentinogenesis imperfecta. A** and **B,** Brothers.



■ **FIGURE 16-33 Dentinogenesis imperfecta.**

and protection of tooth tissue. Restorative dental procedures at an early age not only preserve teeth but have a significant effect on the patient's self-esteem.

DEFECTS OF DENTIN

Dentinogenesis Imperfecta

Dentinogenesis imperfecta is an autosomal-dominant trait with variable expressivity (Figures 16-32 and 16-33). Mutations in the dentin sialophosphoprotein gene have been described. It typically affects the dentin of both primary and permanent dentitions. Because of the clinical discoloration of teeth, this condition has also been known as (hereditary) *opalescent dentin*.

Dentinogenesis imperfecta has been divided into three types. In type I or syndrome-associated, in which the dentin abnormality occurs in patients with concurrent osteogenesis imperfecta, primary teeth are more severely affected than permanent teeth. In type II, patients have only dentin abnormalities and no bone disease. In type III, or the Brandywine type (discovered in a triracial population in Brandywine, Maryland), only dental defects occur. This type is similar to type II, but has some clinical and radiographic variations. Features of type III that are not seen in types I and II include multiple pulp exposures, periapical radiolucencies, and a variable radiographic appearance.

Dentinogenesis imperfecta has an autosomal dominant pattern of inheritance. Dentinogenesis imperfecta type I (syndromal dentinogenesis imperfecta) is caused by mutations in the genes that encode collagen type I. Dentinogenesis imperfecta types II and III, on the other hand, have been shown to be related to mutations in a gene known as dentin sialophosphoprotein that encodes noncollagen proteins of dentin. Other genes that encode dentin proteins, such as osteopontin, do not appear to be mutated in dentinogenesis imperfecta.

Clinically, all three types share numerous features. In both dentitions, the teeth exhibit an unusual translucent, opalescent appearance, with color variation from yellow-brown to gray. The entire crown appears discolored because of the abnormal underlying dentin. Although the enamel is structurally and chemically normal, it fractures easily, resulting in rapid wear. The enamel fracturing is believed to be due to the poor support provided by abnormal dentin, and possibly in part to the absence of the microscopic scalloping normally seen between dentin and enamel, which is believed to help mechanically lock the two hard tissues together. Overall tooth morphology is unusual for its excessive constriction at the cementoenamel junction, giving the crowns a tulip or bell shape. Roots are shortened and blunted. The teeth do not exhibit any greater susceptibility to caries, and they may in fact show some resistance because of the rapid wear and absence of interdental contacts.

Radiographically, types I and II exhibit identical changes. Opacification of dental pulps occurs as the result of continued deposition of abnormal dentin. The short roots and the bell-shaped crowns are also obvious on radiographic examination. In type III, the dentin appears thin and the pulp chambers and root canals extremely large, giving the appearance of thin dentin shells—hence the previous designation of *shell teeth*.

Microscopically, the dentin of teeth in dentinogenesis imperfecta contains fewer, but larger and irregular, dentinal tubules. The pulpal space is nearly completely replaced over

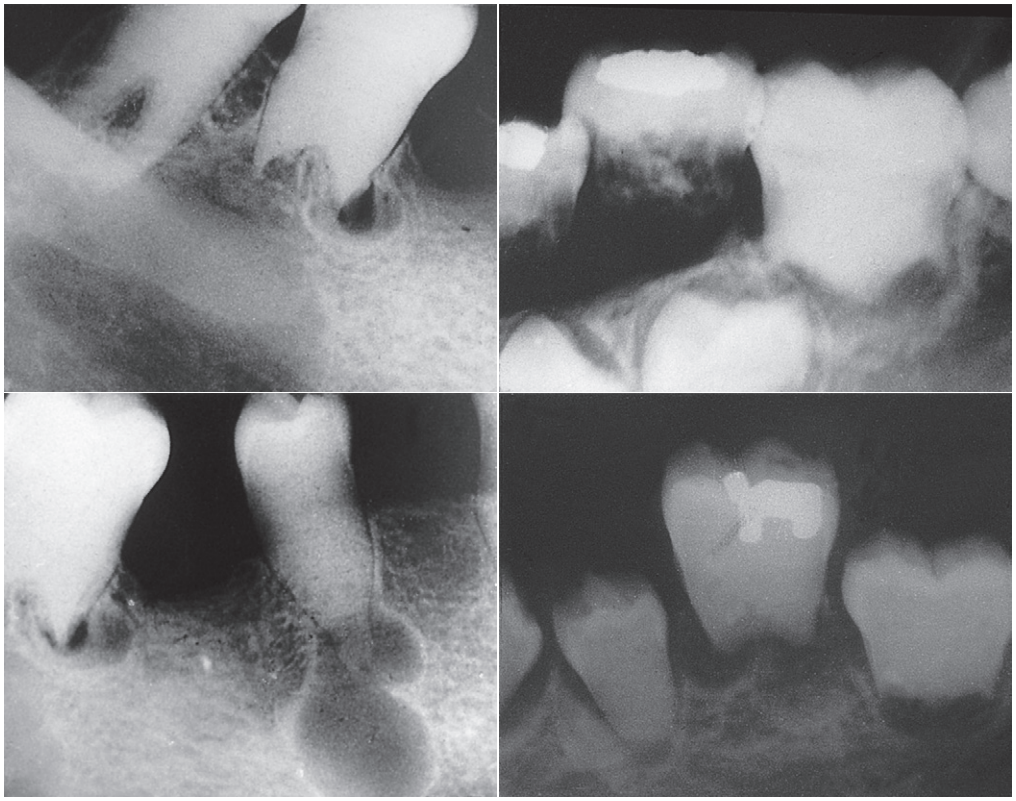

■ **FIGURE 16-34 Dentin dysplasia, type I.** Note obliterated pulps, short roots, and periapical lesions.

time by irregular dentin. Enamel appears normal, but the dentinoenamel junction is smooth instead of scalloped.

Treatment is directed toward protecting tooth tissue from wear and toward, thereby improving the esthetic appearance of the teeth. Generally, fitting with full crowns at an early age is the treatment of choice. Despite the qualitatively poor dentin, support for the crowns is adequate. These teeth should not be used as abutments because the roots are prone to fracture under stress.

Dentin Dysplasia

Dentin dysplasia, subdivided into types I and II, is another autosomal-dominant condition that affects dentin (Figures 16-34 and 16-35). The incidence of this rare disorder is approximately 10 times less than that of dentinogenesis imperfecta. As in dentinogenesis imperfecta II and III, genetic mutations occur in the dentin sialophosphoprotein gene in dentin dysplasia type II. Genetic lesions have yet to be elucidated in dentin dysplasia type I.

In dentin dysplasia type II, the color of the primary dentition is opalescent and the permanent dentition is normal; in type I, both dentitions are of normal color. The coronal pulps in type II are usually large (thistle tube appearance) and are filled with globules of abnormal dentin. Also, periapical lesions are not a regular feature of type II, as they are of type I.

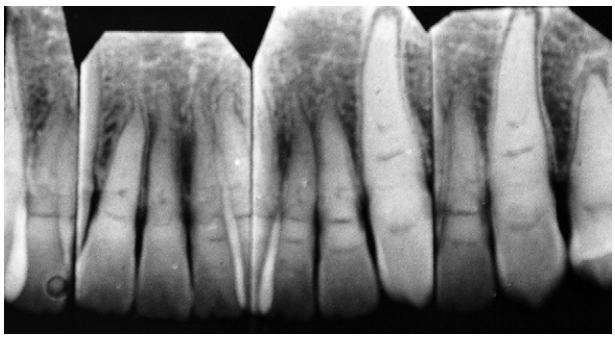

■ **FIGURE 16-35 Dentin dysplasia, type II.** Note horizontal ribbons (chevrons) of dental pulp.

Clinically, the crowns in dentin dysplasia type I appear to be normal in color and shape. Premature tooth loss may occur because of short roots or periapical inflammatory lesions. Teeth show greater resistance to caries when compared with normal teeth.

Radiographically, in dentin dysplasia type I, roots appear extremely short and pulps are almost completely obliterated. Residual fragments of pulp tissue appear typically as horizontal lucencies (chevrons). Periapical lucencies are typically seen; they represent chronic abscesses, granulomas, or cysts. In dentin dysplasia type II, deciduous teeth are similar in radiographic appearance to those in type I, but permanent

teeth exhibit enlarged pulp chambers that have been described as thistle tube in appearance.

Microscopically, the enamel and the immediately subjacent dentin appear normal. Deeper layers of dentin show atypical tubular patterns, with amorphous, atubular areas and irregular organization. On the pulpal side of the normal-appearing mantle of dentin, globular or nodular masses of abnormal dentin are seen.

Treatment is directed toward retention of teeth for as long as possible. However, because of the short roots and periapical lesions, the prognosis for prolonged retention is poor. This dental condition has not been associated with any systemic connective tissue problems.

DEFECTS OF ENAMEL AND DENTIN

Regional Odontodysplasia

Regional odontodysplasia is a dental abnormality that involves the hard tissues derived from both epithelial (enamel) and mesenchymal (dentin and cementum) components of the tooth-forming apparatus (Figures 16-36 and 16-37). The teeth in a region or quadrant of the maxilla or mandible are affected to the extent that they exhibit short roots, open apical foramina, and enlarged pulp chambers. The thinness and poor mineralization quality of the enamel and dentin layers have given rise to the term *ghost teeth*. One or both dentitions may be affected. The permanent teeth are more affected than the primary teeth, and the maxillary anterior teeth are more affected than other teeth. Eruption of the affected teeth is delayed or does not occur.

The cause of this rare dental abnormality is unknown, although numerous causative factors have been suggested, including trauma, nutritional deficiency, infection, metabolic abnormality, systemic disease, local vascular compromise, and genetic influences.

Because of the poor quality of the affected teeth, their removal is usually indicated. The resulting edentulous zone can then be restored with a prosthesis or implant.



■ **FIGURE 16-36 Regional odontodysplasia,** left maxilla.



■ **FIGURE 16-37 Regional odontodysplasia** (ghost teeth).

ABNORMALITIES OF DENTAL PULP

Pulp Calcification

Pulp calcification is a rather common phenomenon that occurs with increasing age for no apparent reason (Figures 16-38 and 16-39). There appears to be no relation to inflammation, trauma, or systemic disease. Pulp calcification may be of microscopic size or may be large enough to be detected radiographically. Calcifications may be diffuse (linear) or nodular (pulp stones). The diffuse, or linear, deposits are typically found in the root canals and generally are parallel to the blood vessels. Pulp stones usually are found in the pulp chamber. When they are composed predominantly of dentin,

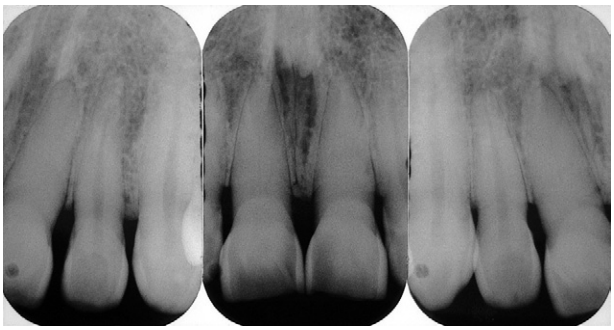

■ **FIGURE 16-38 Pulp calcification,** diffuse.

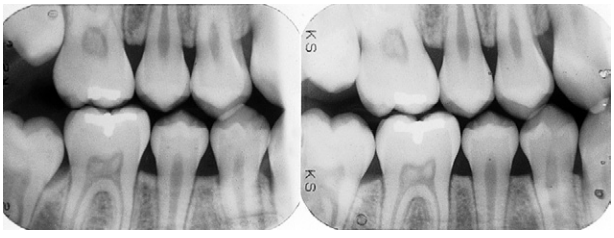

■ **FIGURE 16-39 Pulp calcification.** Pulp stones are evident in the molars.

they are referred to as *true denticles;* when they represent foci of dystrophic calcification, they are referred to as *false denticles*. Pulp stones occasionally are subdivided into attached and free types, depending on whether they are incorporated into the dentin wall or are surrounded by pulpal tissue.

Pulp stones appear to have no clinical significance. They are not believed to be a source of pain and are not associated with any form of pulpitis. They may, however, be problematic during endodontic therapy of nonvital teeth.

Internal Resorption

Resorption of the dentin of the pulpal walls may be seen as part of an inflammatory response to pulpal injury, or it may be seen in cases in which no apparent trigger can be identified (Figures 16-40 and 16-41). The resorption occurs as a result of activation of osteoclasts or dentinoclasts on internal surfaces of the root or crown. Resorption lacunae containing these cells and chronic inflammatory cells are seen. Reversal lines may also be found in adjacent hard tissue, indicating attempts at repair. In time, the root or crown is perforated by the process, making the tooth useless.

Any tooth may be involved, and usually only a single tooth is affected, although cases in which more than one tooth is involved have been described. In advanced cases, teeth may appear pink because of the proximity of pulp tissue to the tooth surface. Until root fracture or communication with a periodontal pocket occurs, patients generally have no symptoms.



■ **FIGURE 16-40 Internal resorption.**

The treatment of choice is root canal therapy before perforation. Once communication between pulp and periodontal ligament occurs, the prognosis for saving the tooth is very poor. Occasionally, the process may spontaneously stop for no apparent reason.

External Resorption

Resorption of teeth from external surfaces may have one of several causes (Figures 16-42 to 16-46). This change may be the result of an adjacent pathologic process, such as



■ **FIGURE 16-41 Internal resorption.**

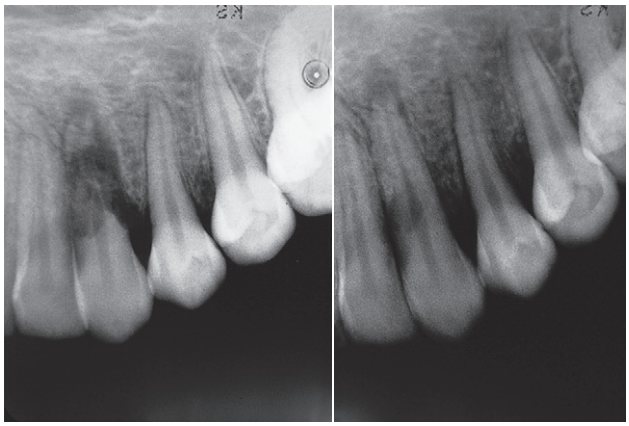

■ **FIGURE 16-42 External resorption.**

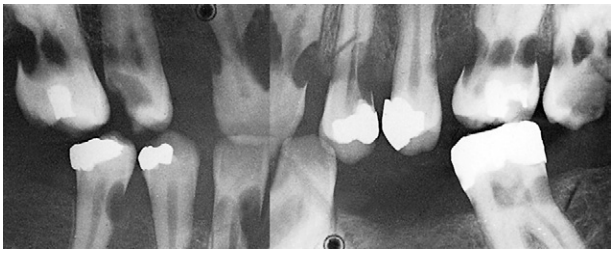

■ **FIGURE 16-43 External resorption,** cervical area.

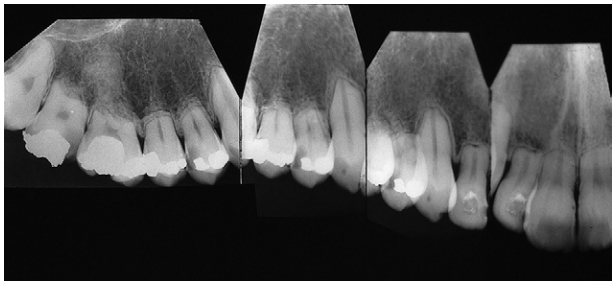

■ **FIGURE 16-44 External resorption,** apical.



■ **FIGURE 16-45 External resorption** of an impacted tooth.



■ **FIGURE 16-46 External resorption** induced by a central giant cell granuloma.

(1) chronic inflammatory lesions, (2) cysts, (3) benign tumors, or (4) malignant neoplasms. The pathogenesis of external resorption from these causes has been related to the release of chemical mediators, increased vascularity, and pressure. External resorption of teeth may also be seen in association with (1) trauma, (2) reimplantation or transplantation of teeth, or (3) impaction. Trauma that causes injury to or necrosis of the periodontal ligament may initiate resorption of tooth roots. This trauma may result from a single event, from malocclusion, or from excessive orthodontic forces. Because reimplanted and transplanted teeth are nonvital and have no surrounding viable periodontal ligament, they eventually are resorbed and replaced by bone. This is basically a natural physiologic process in which the calcified collagen matrix of the tooth serves as a framework for the deposition of new, viable bone. Impacted teeth, when they impinge or exert pressure on adjacent teeth, may cause root resorption of the otherwise normally erupted tooth. Impacted teeth themselves occasionally may undergo resorption. The cause of this phenomenon is unknown, although it is believed to be related to partial loss of the protective effect of the periodontal ligament or reduced enamel epithelium.

Finally, external resorption of erupted teeth may be idiopathic. This may occur in one or more teeth. Any tooth may be involved, although molars are least likely to be affected. One of two patterns may be seen. In one, resorption occurs immediately apical to the cementoenamel junction, mimicking a pattern of caries associated with xerostomia. In external resorption, however, the lesions occur on root surfaces below the gingival epithelial attachment. In the other pattern of external resorption, the process starts at the tooth apex and progresses occlusally.

External resorption is a particularly frustrating type of dental abnormality for both patients and practitioners because there is no plausible or evident explanation for the condition and no effective treatment. Over an extended clinical course, resorption eventually causes loss of the affected tooth.

ALTERATIONS IN COLOR

Exogenous Stains

Stains on the surfaces of teeth that can be removed with abrasives are known as *exogenous* or *extrinsic stains*. The color change may be caused by pigments in dietary substances (e.g., coffee, "betel" areca nut, tobacco) or by the colored by-products of chromogenic bacteria in dental plaque. Chromogenic bacteria are believed to be responsible for brown, black, green, and orange stains observed predominantly in children. Brown and black stains typically are seen in the cervical zone of teeth, either as a thin line along the gingival margin or as a wide band. This type of stain is also often found on teeth adjacent to salivary duct orifices. Green stain is tenacious and usually is found as a band on the labial surfaces of the maxillary anterior teeth. Blood pigments are thought to contribute to the green color. Orange or yellow-orange stains appear on the gingival third of teeth in a small percentage of children. These generally are easily removed.

Endogenous Stains

Discoloration of teeth resulting from deposits of systemically circulating substances during tooth development is defined as *endogenous* or *intrinsic staining*.



■ **FIGURE 16-47 Tetracycline stain.** Note the yellow color (tetracycline) of the posterior teeth and the gray color of the anterior teeth, in which oxidation of endogenous tetracycline has occurred.

Systemic ingestion of *tetracycline* during tooth development is a well-known cause of endogenous staining of teeth (Figure 16-47). Tetracycline binds calcium and therefore is deposited in developing teeth and bones. The bright yellow color of the drug is reflected in subsequently erupted teeth. The fluorescent property of tetracycline can be demonstrated with an ultraviolet light in clinically erupted teeth. Over time, the tetracycline oxidizes, resulting in a change from yellow to gray or brown with loss of its fluorescent quality. Because tetracycline can cross the placenta, it may stain primary teeth if taken during pregnancy. If it is administered between birth and age 6 or 7 years, permanent teeth may be affected. Only a small minority of children given tetracycline for various bacterial diseases, however, exhibit clinical evidence of discoloration. Staining is directly proportional to the age at which the drug is administered and the dose and duration of drug usage.

The significance of tetracycline staining lies in its cosmetically objectionable appearance. Because other, equally effective antibiotics are available, tetracycline should not be prescribed for children younger than 7 years except in unusual circumstances.

It should be noted that minocycline, a semisynthetic derivative of tetracycline, can stain the roots of adult teeth. It also may stain skin and mucosa in a diffuse or patchy pattern (see Chapter 5).

Rh incompatibility (erythroblastosis fetalis) has been cited as a cause of endogenous staining in primary teeth. Because of red blood cell hemolysis resulting from maternal antibody destruction of fetal red blood cells, blood breakdown products (bilirubin) are deposited in developing primary teeth. The teeth appear green to brown. Treatment is not required because only primary teeth are affected.

Congenital porphyria, one of several inborn errors of porphyrin metabolism, is also a potential cause of endogenous pigmentation. This autosomal-recessive trait is associated with photosensitivity, vesiculobullous skin eruptions, red urine, and splenomegaly. Teeth may appear red to brown because of deposition of porphyrin in the developing teeth. Affected teeth fluoresce red with ultraviolet light.

Liver disease, *biliary atresia,* and *neonatal hepatitis* may produce discoloration of the primary dentition. In biliary atresia, the teeth may assume a green discoloration; a yellowish-brown color is noted in cases of neonatal hepatitis. This is a result of the deposition or incorporation of bilirubin in developing enamel and dentin.

BIBLIOGRAPHY

Ahlquist M, Grondahl H: Prevalence of impacted teeth and associated pathology in middle-aged and older Swedish women. Community Dent Oral Epidemiol 19:116–119, 1991.

Aine L, Backstrom MC, Maki R et al: Enamel defects in primary and permanent teeth of children born prematurely. J Oral Pathol Med 29:403–409, 2000.

Alvesalo L, Varrela J: Taurodontism and the presence of an extra Y chromosome: study of 47 XYY males and analytical review. Hum Biol 63:31–38, 1991.

Barron MJ, McDonnell ST, Mackie I et al: Hereditary dentine disorders: dentinogenesis imperfecta and dentine dysplasia. Orphanet J Rare Dis 20:31–40, 2008.

Beattie ML, Kim JW, Gong SG et al: Phenotypic variation in dentinogenesis imperfecta/dentin dysplasia linked to 4q21. J Dent Res 85:329–333, 2006.

Chapple JR, Nunn JH: The oral health of children with clefts of the lip, palate, or both. Cleft Palate Craniofac J 38:525–528, 2001.

Crawford PJM, Alred M, Bloch-Zupan A: Amelogenesis imperfecta. Orphanet J Rare Dis 2:17–27, 2007.

Dankner E, Harari D, Rotstein I: Dens evaginatus of anterior teeth: literature review and radiographic survey of 15,000 teeth. Oral Surg Oral Med Oral Pathol Oral Radiol Endod 81:472–475, 1996.

Dong J, Gu TT, Simmons D et al: Enamelin maps to human chromosome 4q21 within the autosomal dominant amelogenesis imperfecta locus. Eur J Oral Sci 108:353–358, 2000.

Kim JW, Simmer JP: Hereditary dentin defects. J Dent Res 86:392–399, 2007.

Kurisu K, Tabata MJ: Human genes for dental anomalies. Oral Dis 3:223–228, 1997.

McKnight DA, Simmer JP, Hart PS et al: Overlapping mutations cause DD and DGI. J Dent Res 87:1108–1111, 2008.

Peck S, Peck L, Kataja M: Mandibular lateral incisor-canine transposition, concomitant dental anomalies, and genetic control. Angle Orthod 68:455–466, 1998.

Rajpar MH, Harley K, Laing K et al: Mutation of the gene encoding enamel-specific protein, enamelin, causes autosomal-dominant amelogenesis imperfecta. Hum Mol Genet 10:1673–1677, 2001.

Sandor GKB, Carmichael RP, Coraza L et al: Genetic mutations in certain head and neck conditions of interest to the dentist. J Can Dent Assoc 67:577–584, 2001.

Seow WK: Enamel hypoplasia in the primary dentition: a review. ASDC J Dent Child 58:441–452, 1991.

Stephanopoulos G, Garefalaki ME, Lyroudia K: Genes and related proteins involved in amelogenesis imperfecta. J Dent Res 84: 1117–1126, 2005.

Tervonen SA, Stratmann U, Mokrys K et al: Regional odontodysplasia: a review of the literature and report of four cases. Clin Oral Investig 8:45–51, 2004.

Thesleff I: Genetic basis of tooth development and dental defects. Acta Odontol Scand 58:191–194, 2000.

Uyeno DS, Lugo AL: Dens evaginatus: a review. ASDC J Dent Child 63:328–332, 1996.

Vaikuntam J, Tatum NB, McGuff HS: Regional odontodysplasia: review of the literature and report of a case. J Clin Pediatr Dent 21:35–40, 1996.

Vastardis H: The genetics of human tooth agenesis: new discoveries for understanding dental anomalies. Am J Orthod Dentofacial Orthop 117:650–656, 2000.

Wright J: The molecular etiologies and associated phenotypes of amelogenesis imperfecta. Am J Genet A 140:2547–2555, 2006.

Wright JT: Normal formation and development defects of the human dentition. Pediatr Clin North Am 47:975–1000, 2000.

Wright JT, Hall KI, Yamauche M: The enamel proteins in human amelogenesis imperfecta. Arch Oral Biol 42:149–159, 1997.

Yap AK, Klineberg I: Dental implants in patients with ectodermal dysplasia and tooth agenesis: a critical review of the literature. Int J Prosthodont 22:268–276, 2009.

Clinical Overview

MUCOSAL (SURFACE) LESIONS

Vesiculobullous Diseases
Ulcerative Conditions
White Lesions
Red-Blue Lesions
Pigmented Lesions
Verrucal-Papillary Lesions

SUBMUCOSAL SWELLINGS (BY REGION)

Gingival Swellings
Floor-of-Mouth Swellings
Lips and Buccal Mucosal Swellings
Tongue Swellings
Palatal Swellings
Neck Swellings

DIFFERENTIAL DIAGNOSIS APPROACH TO JAW LESIONS

Cysts of the Jaws and Neck
Odontogenic Tumors
Benign Nonodontogenic Tumors
Inflammatory Jaw Lesions
Malignancies of the Jaws
Metabolic and Genetic Diseases

VESICULOBULLOUS DISEASES

Disease	Clinical Features	Cause	Significance
Herpes simplex infections			
Primary herpetic gingivostomatitis	Multiple painful oral ulcers preceded by vesicles; may have similar perioral and skin lesions; fever and gingivitis usually present; usually affects children younger than 5 years of age	Herpes simplex virus type 1 (occasionally type 2)	Self-limited; heals in about 2 weeks; reactivation of latent virus results in secondary infections; circulating antibodies provide only partial immunity
Secondary herpes simplex infection	Multiple small ulcers preceded by vesicles; prodromal symptoms of tingling, burning, or pain; most common on lip, intraorally on palate and attached gingiva; adults and young adults usually affected; very common; called *herpetic whitlow* when occurs around fingernail	Herpes simplex virus—represents reactivation of latent virus and not reinfection; commonly precipitated by stress, sunlight, cold temperature, low resistance, and immunodeficiency	Self-limited; heals in about 2 weeks without scar; lesions infectious during vesicular stage; patient must be cautioned against autoinoculation; herpes type 1 infections have not been linked convincingly to oral cancer; any site affected in AIDS patients
Varicella	Painful pruritic vesicles and ulcers in all stages on trunk and face; few oral lesions; common childhood disease	Varicella-zoster virus	Self-limited; recovery uneventful in several weeks; vaccine available
Herpes zoster	Unilateral multiple ulcers preceded by vesicles distributed along a sensory nerve course; very painful; usually on trunk, head, and neck; rare intraorally; adults	Reactivation of varicella-zoster virus	Self-limited, but may have a prolonged, painful course; seen in debilitation, trauma, neoplasia, and immunodeficiency
Hand-foot-and-mouth disease	Painful ulcers preceded by vesicles on hands, feet, and oral mucosa; usually children; rare	Coxsackie viruses	Self-limited; recovery uneventful in about 2 weeks
Herpangina	Multiple painful ulcers in posterior oral cavity and pharynx; lesions preceded by vesicles; children most commonly affected; seasonal occurrence; rare	Coxsackie viruses	Self-limited; recovery uneventful in less than a week

Continued



■ **FIGURE 1** Primary herpes simplex infection.



■ **FIGURE 2** Secondary herpes simplex infection of the lips.



■ **FIGURE 3** Secondary herpes simplex infection of the palate.

VESICULOBULLOUS DISEASES—cont'd

Disease	Clinical Features	Cause	Significance
Measles (rubeola)	Oral Koplik's spots precede maculopapular skin rash; fever, malaise, plus other symptoms of systemic viral infection	Measles virus	Self-limited; recovery uneventful in about 2 weeks
Pemphigus vulgaris	Multiple painful ulcers preceded by bullae; middle age; positive Nikolsky's sign; progressive disease; remissions or control with therapy; rare	Autoimmune; antibodies directed against desmosome-associated protein, desmoglein 3	Without treatment, may be fatal; significant morbidity from steroid therapy; oral lesions precede skin lesions in half of cases; prognosis improved if treated early
Mucous membrane pemphigoid	Multiple painful ulcers preceded by vesicles and bullae; lesion may heal with scar; positive Nikolsky's sign; may affect mucous membranes of oral cavity, eyes, and genitals; middle-aged or elderly women; uncommon; clinically may be confused with lichen planus, chronic lupus erythematosus of gingiva, and hypersensitivity	Autoimmune; antibodies directed against basement membrane antigens, laminin 5, BP180, others	Protracted course; may cause significant morbidity if severe; ocular scarring may lead to symblepharon or blindness; death uncommon
Bullous pemphigoid	Skin disease (trunk and extremities) with infrequent oral lesions; ulcers preceded by bullae; no scarring; elderly persons	Basement membrane autoantibodies detected in tissue and serum	Chronic course; remissions; uncommon
Dermatitis herpetiformis	Skin disease with rare oral involvement; vesicles and pustules; pruritic exacerbations and remissions typical; young and middle-aged adults	Unknown; IgA deposits in sites of lesions; usually associated with gluten enteropathy	Chronic course that may require diet restriction or drug therapy
Epidermolysis bullosa	Multiple ulcers preceded by bullae; positive Nikolsky's sign; inheritance pattern determines age of onset during childhood and severity; may heal with scar; primarily a skin disease, but oral lesions often present; rare	Hereditary, autosomal dominant or recessive; acquired adult form also exists	Severe, debilitating disease that may be fatal in recessive form; simple operative procedures may elicit bullae; acquired form less debilitating

AIDS, Acquired immunodeficiency syndrome; *BP*, bullous pemphigoid antigen; *Ig*, immunoglobulin.

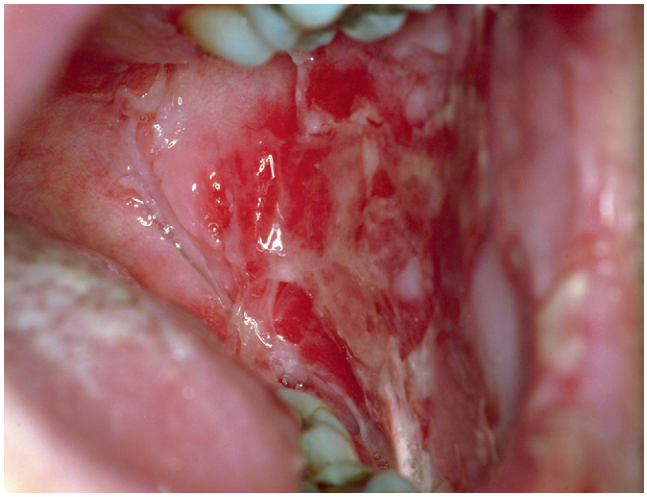

■ **FIGURE 4** Pemphigus vulgaris.



■ **FIGURE 5** Pemphigus vulgaris.



■ **FIGURE 6** Mucous membrane pemphigoid.

ULCERATIVE CONDITIONS

Disease	Clinical Features	Cause	Significance
Reactive lesions	Painful ulcer covered by yellow fibrin membrane; diagnosis usually evident from appearance when combined with history; common; traumatic factitial injuries are diagnostic challenge	Trauma, chemicals, heat, radiation	Self-limited; heals in days to weeks; factitial injuries follow unpredictable course
Syphilis	*Primary* (chancre)—single, indurated, nonpainful ulcer at site of spirochete entry; spontaneously heals in 4–6 weeks *Secondary*—maculopapular rash on skin; oral ulcers covered by membrane (mucous patches) orally *Tertiary*—gummas, cardiovascular and central nervous system lesions *Congenital*—dental abnormalities (mulberry molars, notched incisors), deafness, interstitial keratitis (Hutchinson's triad)	Spirochete—*Treponema pallidum*	Primary and secondary forms are highly infectious; mimics other diseases clinically; if untreated, secondary form develops in 2–10 weeks; a minority of patients develop tertiary lesions; latency periods, in which there is no clinically apparent disease seen between primary and secondary stages and between secondary and tertiary stages; untreated, 30% progress to tertiary stage
Gonorrhea	Typically, genital lesions, with rare oral manifestations, painful erythema or ulcers, or both	*Neisseria gonorrhoeae*	May be confused with many oral ulcerative diseases
Tuberculosis	Indurated, chronic ulcer that may be painful—on any mucosal surface	*Mycobacterium tuberculosis*	Lesions are infectious; oral lesions almost always a result of lung lesions; differential diagnosis includes oral cancer and chronic traumatic ulcer
Leprosy	Skin disease, with rare oral nodules/ulcers	*Mycobacterium leprae*	Rare in United States but relatively common in Southeast Asia, India, South America
Actinomycosis	Typically seen in mandible, with draining skin sinus; wood-hard nodule with sulfur granules	*Actinomyces israelii*	Infection follows entry through a surgical site, periodontal disease, or open root canal

Continued



■ **FIGURE 7** Chronic traumatic ulcer.



■ **FIGURE 8** Acute ulcers (cotton roll injury).

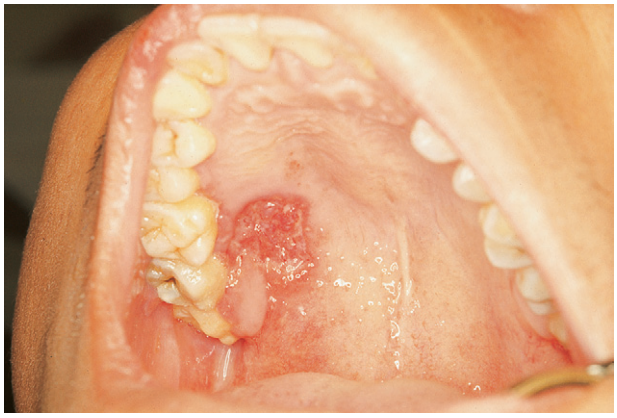

■ **FIGURE 9** Tuberculosis of the palate.

ULCERATIVE CONDITIONS—cont'd

Disease	Clinical Features	Cause	Significance
Noma	Necrotic, nonhealing ulcer of gingiva or buccal mucosa; rare; affects children	Anaerobes in patient whose systemic health is compromised	Often associated with malnutrition; may result in severe tissue destruction
Deep fungal diseases	Indurated, nonhealing, frequently painful, chronic ulcer, usually following implantation of organism from lung	*Histoplasma capsulatum, Coccidioides immitis,* others	Oral lesions are a result of systemic lesions; some types are endemic
Subcutaneous fungal diseases	Nonspecific ulcers of skin and, rarely, mucosa	Usually *Sporothrix schenckii*	Sporotrichosis usually follows inoculation via thorny plants
Opportunistic fungal infections	Occurs in compromised host; necrotic; nonhealing ulcer(s)	*Mucormycosis, Rhizopus*, others	Known collectively as *phycomycosis;* may mimic syphilis, midline granuloma, others; frequently fatal
Aphthous ulcers	Recurrent, painful ulcers found on tongue, vestibular mucosa, floor of mouth, and faucial pillars; not found on skin, vermilion, attached gingiva, or hard palate; usually round or oval; ulcers not preceded by vesicles; *minor type*—usually solitary, <0.5 cm in diameter; common; *major type*—severe, heals in up to 6 weeks with scar greater than 0.5 cm in diameter; *herpetiform type*—multiple, recurrent crops of ulcers	Unknown; probably an immune defect mediated by T cells; may be associated with hypersensitivity, deficiencies, malabsorption, or family history; not caused by virus; precipitated by stress, trauma, hormonal changes, certain foods	Painful nuisance disease; rarely debilitating, except major type; recurrences are the rule; more severe in patients with AIDS; may be seen in association with Behçet's syndrome, Crohn's disease, or gluten-sensitive enteropathy (celiac sprue)
Behçet's syndrome	Minor aphthae; eye lesions (uveitis, conjunctivitis); genital lesions (ulcers); arthritis occasionally seen	Probably an immune defect; possibly autoimmune heredity and presence of HLA-B51 may be factors	Biopsy shows vasculitis and laboratory studies give nonspecific results; complications may be significant

Continued



■ **FIGURE 10** Histoplasmosis of the lip.



■ **FIGURE 11** Minor aphthous ulcer.



■ **FIGURE 12** Major aphthous ulcer.

ULCERATIVE CONDITIONS—cont'd

Disease	Clinical Features	Cause	Significance
Reiter's syndrome	Arthritis, urethritis, conjunctivitis, or uveitis; oral ulcers; usually in white men in third decade	Unknown; immune response to bacterial antigen; usually follows STD or *Shigella* dysentery; HLA-B27	Duration of weeks to months; may be recurrent
Erythema multiforme	Sudden onset; painful, widespread, superficial ulcers; crusted ulcers on vermilion of lips; usually self-limited; young adults; may also have target or iris lesions of skin; may be recurrent, especially in spring and fall; some cases become chronic; uncommon	Unknown; may be associated with hypersensitivity; may follow drug ingestion or infection such as herpes labialis or *Mycoplasma* pneumonia	Cause should be investigated; can be debilitating, especially in severe forms, erythema multiforme major (Stevens-Johnson syndrome) and toxic epidermal necrolysis
Lupus erythematosus	Usually painful erythematous and ulcerative lesions on buccal mucosa, gingiva, and vermilion; radiating white keratotic areas may surround lesions; chronic *discoid type*—generally affects skin and mucous membrane only; acute *systemic type*—skin lesions may be erythematous with scale (classic sign is butterfly rash across bridge of nose); also may have joint, kidney, and heart lesions; middle-aged women; uncommon	Immune defect; patient develops autoantibodies, especially antinuclear antibodies	*Discoid type* may cause discomfort and cosmetic problems; *systemic type* has variable prognosis from good to poor
Drug reactions	May affect skin or mucosa; erythema, white lesions, vesicles, ulcers may be seen; history of recent drug ingestion is important	Potentially any drug via stimulation of immune system	Reactions, such as anaphylaxis or angioedema, may require emergency care; highly variable clinical picture can make diagnosis difficult
Contact allergy	Lesions caused by direct contact with foreign antigen; erythema, vesicles, ulcers may be seen	Potentially any foreign antigen that contacts skin or mucosa; cinnamon frequently cited	Patch testing may be helpful for diagnosis; history is important

Continued

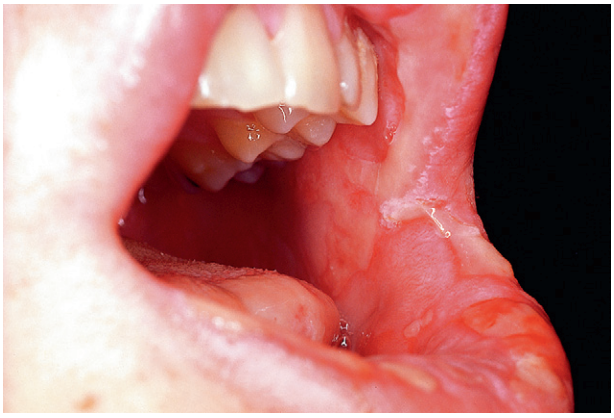

■ **FIGURE 13** Erythema multiforme.



■ **FIGURE 14** Lupus erythematosus.



■ **FIGURE 15** Contact hypersensitivity, buccal mucosa and palatal gingiva.

ULCERATIVE CONDITIONS—cont'd

Disease	Clinical Features	Cause	Significance
Wegener's granulomatosis	Inflammatory lesions (necrotizing vasculitis) of lung, kidney, and upper airway; may affect gingiva when intraoral; rare	Unknown; possibly immune defect or infection	May become life threatening as a result of tissue destruction in any of the three involved sites
Midline granuloma	Destructive, necrotic, nonhealing lesions of nose, palate, and sinuses; biopsy shows nonspecific inflammation; distinct from Wegener's granulomatosis; rare	Represents NK/T-cell lymphoma	Poor prognosis; death may follow erosion into major blood vessels
Chronic granulomatous disease	Recurrent infections in various organs; oral ulcers; males; rare	Genetic disease (X linked)	Altered neutrophil and macrophage function results in inability to kill bacteria and fungi
Cyclic neutropenia	Oral ulcers with periodicity; infection; adenopathy; periodontal disease	Mutations in neutrophil elastase gene	Rare blood dyscrasia
Squamous cell carcinoma of the oral cavity	Indurated, nonpainful ulcer with rolled margins; most commonly found on lateral tongue and floor of mouth; males affected twice as often as females; clinical appearance may also include a white or red patch or mass	DNA alterations due to carcinogens such as tobacco, UV light, human papillomavirus (oropharynx); alcohol acts as cocarcinogen	Overall 5-year survival rate is about 60%; improved prognosis if found in early stages, poor prognosis if metastasis to regional lymph nodes
Carcinoma of maxillary sinus	Patient may have symptoms of sinusitis or referred pain to teeth; may cause malocclusion or mobile teeth; may appear as ulcerative mass in palate or alveolus	Unknown	Prognosis only fair; metastases are not uncommon

AIDS, Acquired immunodeficiency syndrome; *HLA*, human leukocyte antigen; *NK*, natural killer; *STD*, sexually transmitted disease; *UV*, ultraviolet.



■ **FIGURE 16** Midline granuloma.



■ **FIGURE 17** Squamous cell carcinoma, floor of mouth.

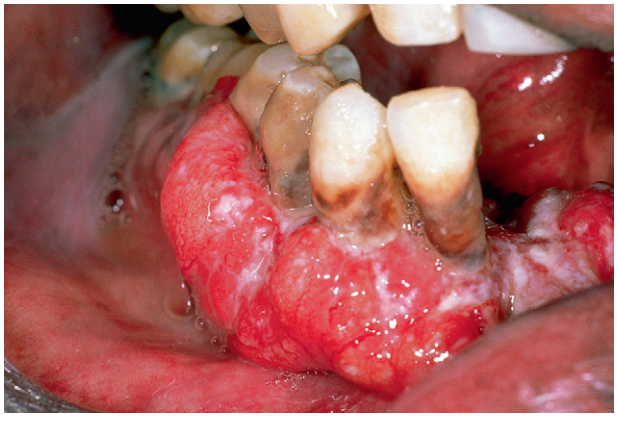

■ **FIGURE 18** Squamous cell carcinoma, gingiva.

WHITE LESIONS

Disease	Clinical Features	Cause	Significance
Leukoedema	Common uniform opacification of buccal mucosa bilaterally	Unknown	Remains indefinitely; no ill effects
White sponge nevus	Asymptomatic, bilateral, dense, shaggy, white or gray, generalized opacification; primarily buccal mucosa affected, but other membranes may be involved; rare	Hereditary, autosomal dominant (keratin 4 and/or 13)	Remains indefinitely; no ill effects
Hereditary benign intraepithelial dyskeratosis	Asymptomatic, diffuse, shaggy white lesions of buccal mucosa, as well as other tissues; eye lesions—white plaques surrounded by inflamed conjunctiva; rare	Hereditary, autosomal dominant, duplication of chromosome 4q35	Remains indefinitely
Follicular keratosis	Keratotic papular lesions of skin and, infrequently, mucosa; lesions are numerous and asymptomatic	Genetic, autosomal dominant, mutation in *ATP2A2* gene	Chronic course with occasional remissions
Focal (frictional) hyperkeratosis	Asymptomatic white patch, commonly on edentulous ridge, buccal mucosa, and tongue; does not rub off; common	Chronic irritation, low-grade trauma	May regress if cause eliminated
White lesions associated with smokeless tobacco	Asymptomatic white folds surrounding area where tobacco is held; usually found in labial and buccal vestibules; common	Chronic irritation from snuff or chewing tobacco	Increased risk for development of verrucous and squamous cell carcinoma after many years
Nicotine stomatitis	Asymptomatic, generalized opacification of palate with red dots representing salivary gland orifices; common	Heat and smoke associated with combustion of tobacco	Rarely develops into palatal cancer

Continued

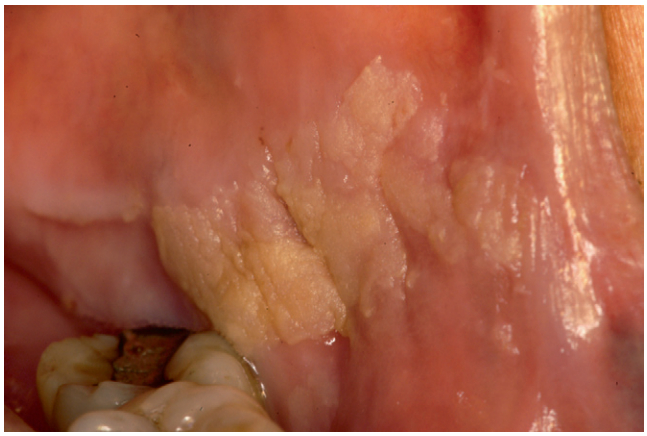

■ **FIGURE 19** Hyperkeratosis, buccal mucosa.



■ **FIGURE 20** Hyperkeratosis, snuff dipper's pouch.



■ **FIGURE 21** Nicotine stomatitis.

WHITE LESIONS—cont'd

Disease	Clinical Features	Cause	Significance
Actinic cheilitis	Lower lip—atrophic epithelium, poor definition of vermilion-skin margin, focal zones of keratosis; common	UV light (especially UVB, 2900–3200 nm)	May result in squamous cell carcinoma
Idiopathic leukoplakia	Asymptomatic white patch; cannot be wiped off; males affected more than females	Unknown; may be related to tobacco and alcohol use	May recur after excision; 5% are malignant and 5% become malignant; higher risk of carcinoma if dysplasia present
Hairy leukoplakia	Filiform to flat patch on lateral tongue, often bilateral, occasionally on buccal mucosa; asymptomatic	Epstein-Barr virus infection	Seen in 20% of HIV-infected patients; marked increase in AIDS; may occur in non–AIDS-affected immunosuppressed patients
Hairy tongue	Elongation of filiform papillae; asymptomatic	Unknown; may follow antibiotic, corticosteroid use, tobacco habit	Benign process; may be cosmetically objectionable
Geographic tongue (erythema migrans)	White annular lesions with atrophic red centers; pattern migrates over dorsum of tongue; varies in intensity and may spontaneously disappear; occasionally painful; common	Unknown	Completely benign; spontaneous regression after months to years

Continued



■ **FIGURE 22** Idiopathic leukoplakia.



■ **FIGURE 23** Hairy leukoplakia.



■ **FIGURE 24** Geographic tongue.

WHITE LESIONS—cont'd

Disease	Clinical Features	Cause	Significance
Lichen planus	Bilateral white striae (Wickham's); asymptomatic except when erosions are present; seen in middle age; buccal mucosa most commonly affected, with lesions occasionally on tongue, gingiva, and palate; skin lesions occasionally present and are purple pruritic papules; forearm and lower leg most commonly affected skin areas	Unknown; may be precipitated by stress; may be hyperimmune condition mediated by T cells	May regress after many years; treatment may only control disease; rare malignant transformation
Dentifrice-associated slough	Asymptomatic, slough of filmy parakeratotic cells	Mucosal reaction to components in toothpaste	None
Candidiasis	Painful elevated plaques (fungus) that can be wiped off, leaving eroded, bleeding surface; associated with poor hygiene, systemic antibiotics, systemic disease, debilitation, reduced immune response; chronic infection may result in erythematous mucosa without obvious white colonies; common	Opportunistic fungus—*Candida albicans* and rarely other *Candida* species	Usually disappears 1–2 weeks after treatment; some chronic cases require long-term therapy
Mucosal burns	Painful white fibrin exudate covering superficial ulcer with erythematous ring; common	Chemicals (aspirin, phenol), heat, electrical burns	Heals in days to weeks
Submucous fibrosis	Areas of opacification with loss of elasticity; any oral region affected; rare	May be due to hypersensitivity to dietary constituents such as areca (betel nut), capsaicin	Irreversible; predisposes to oral cancer

Continued



■ **FIGURE 25** Lichen planus.



■ **FIGURE 26** Lichen planus.



■ **FIGURE 27** Candidiasis.

WHITE LESIONS—cont'd

Disease	Clinical Features	Cause	Significance
Fordyce's granules	Multiple asymptomatic, yellow, flat or elevated spots seen primarily in buccal mucosa and lips; seen in a majority of patients; many consider them to be a variation of normal	Developmental	Ectopic sebaceous glands of no significance
Ectopic lymphoid tissue	Asymptomatic elevated yellow nodules <0.5 cm in diameter; usually found on tonsillar pillars, posterolateral tongue, and floor of mouth; covered by intact epithelium; common	Developmental	No significance; lesions remain indefinitely and are usually diagnostic clinically
Gingival cyst	Small, usually white to yellow nodule; multiple in infants, solitary in adults; common in infants, rare in adults	Proliferation and cystification of dental lamina rests	In infants, lesions spontaneously rupture or break; recurrence not expected in adults
Parulis	Yellow-white gingival swelling caused by submucosal pus	Periodontitis or tooth abscess	Periodic drainage until primary cause is eliminated
Lipoma	Asymptomatic, slow-growing, well-circumscribed, yellow or yellow-white mass; benign neoplasm of fat; occurs in any area	Unknown	Seems to have limited growth potential intraorally; recurrence not expected after removal

AIDS, Acquired immunodeficiency syndrome; *HIV*, human immunodeficiency virus; *UV*, ultraviolet; *UVB*, ultraviolet B.



■ **FIGURE 28** Fordyce's granules *(bottom)*.



■ **FIGURE 29** Ectopic lymphoid tissue, floor of mouth.



■ **FIGURE 30** Gingival cyst.

RED-BLUE LESIONS

Disease	Clinical Features	Cause	Significance
Congenital hemangiomas and vascular malformations	Red or blue lesion that blanches when compressed; extent of lesion usually difficult to determine; skin, lips, tongue, and buccal mucosa most commonly affected; common on skin, uncommon in mucous membrane, rare in bone; part of Sturge-Weber syndrome; telangiectasias (small focal dilations of terminal blood vessels) blanch when compressed; commonly found in sun-damaged skin and seen with hereditary hemorrhagic telangiectasia (HHT)	Some are benign congenital neoplasms, others are caused by abnormal vessel morphogenesis (vascular malformation); *HHT*—autosomal dominant; *venous varix*—congenital or induced by UV light	May remain quiescent or may gradually enlarge; hemorrhage may be a significant complication; often a cosmetic problem; *HHT*—epistaxis and GI bleeding may be a problem
Pyogenic granuloma	Asymptomatic red mass composed of granulation tissue; most commonly seen in gingiva; may occur during pregnancy; may be secondarily ulcerated; common	Trauma or chronic irritation; size modified by hormonal changes	Remains indefinitely; recurrence if incompletely excised; reduction in size if cause removed or after pregnancy
Peripheral giant cell granuloma	Asymptomatic red mass of gingiva composed of fibroblasts and multinucleated giant cells; found most often in adults in the former area of deciduous teeth; produces cup-shaped lucency when in edentulous areas; uncommon	Trauma or chronic irritation	Remains indefinitely if untreated; a reactive lesion; clinical appearance similar to that of pyogenic granuloma
Erythroplakia	Asymptomatic red velvety patch usually found in floor of mouth or retromolar area in adults; seen in older adults; red lesions may have foci of white hyperkeratosis (speckled erythroplakia)	Tobacco and alcohol	Most (90%) are in situ or invasive squamous cell carcinoma
Kaposi's sarcoma	May be part of AIDS; usually on skin, but may be oral, especially in palate; red to blue macules or nodules; rare, except in immunodeficiency	Endothelial cell proliferation related to cytokine/growth factor imbalance; HHV8 is part of etiology	Fair prognosis; poor when part of AIDS; incidence on the decline in AIDS patients

AIDS, Acquired immunodeficiency syndrome; *HHV8*, human herpesvirus 8; *UV*, ultraviolet light.

Continued



■ **FIGURE 31** Vascular malformation.

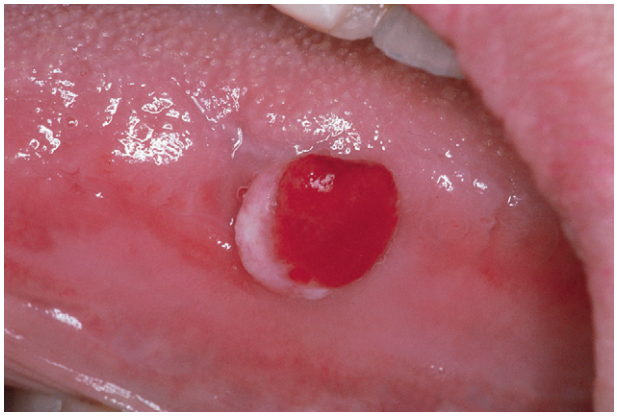

■ **FIGURE 32** Pyogenic granuloma.



■ **FIGURE 33** Peripheral giant cell granuloma.

RED-BLUE LESIONS—cont'd

Disease	Clinical Features	Cause	Significance
Median rhomboid glossitis	Red lobular elevation anterior to circumvallate papillae in midline	Chronic *Candida* infection	Little significance; treat *Candida albicans* infection
Geographic tongue	White annular lesions with atrophic, red centers; white (keratotic) areas may be poorly developed, leaving red patches on dorsum of tongue; occasionally painful; common	Unknown	Little significance except when painful; not premalignant
Psoriasis	Chronic skin disease with rare oral lesions; red skin lesions covered with silvery scales; oral lesions red to white patches	Unknown	Must have skin lesions to confirm oral disease; exacerbations and remissions are typical
Vitamin B deficiency	Generalized redness of tongue caused by atrophy of papillae; may be painful; may have an associated angular cheilitis; rare in United States	B complex deficiency	Remains until therapeutic levels of vitamin B are administered
Anemia (pernicious and iron deficiency)	May result in generalized redness of tongue caused by atrophy of papillae; may be painful; patients may have angular cheilitis; females more commonly affected than males; Plummer-Vinson syndrome—anemia (iron deficiency), mucosal atrophy, predisposition for oral cancer	Some forms acquired, some hereditary	Some types may be life threatening; oral manifestations disappear with treatment; complication of oral cancer with Plummer-Vinson syndrome
Burning mouth syndrome	Wide range of oral complaints, usually without any visible tissue changes; especially middle-aged women; uncommon in males	Multifactorial (e.g., *C. albicans*, vitamin B deficiency anemias, xerostomia, idiopathic, psychogenic peripheral neuropathy)	May persist despite treatment
Scarlet fever	Pharyngitis, systemic symptoms, strawberry tongue	Group A streptococci	Complications of rheumatic fever and glomerulonephritis

Continued



■ **FIGURE 34** Median rhomboid glossitis.



■ **FIGURE 35** Geographic tongue.



■ **FIGURE 36** Vitamin B deficiency.

RED-BLUE LESIONS—cont'd

Disease	Clinical Features	Cause	Significance
Erythematous candidiasis	Painful, hyperemic palate under denture; angular cheilitis; red, painful mucosa	Chronic *C. albicans* infection; poor oral hygiene and ill-fitting denture are frequent predisposing factors	Discomfort may prevent wearing denture; not allergic or premalignant
Plasma cell gingivitis	Red, painful tongue; angular cheilitis; red gingiva	Possible allergic reaction to dietary antigen such as mint- or cinnamon-flavored chewing gum	Gingival lesions similar to lupus, lichen planus, and pemphigoid lesions
Drug reactions and contact allergies	Red, vesicular, or ulcerative eruption	Hypersensitivity reaction to allergen	Hypersensitivity reactions to drugs or HSV may produce erythema multiforme pattern clinically
Petechiae and Ecchymoses			
Traumatic lesions	Hemorrhagic spot (red, blue, purple, black) composed of extravasated blood in soft tissue; does not blanch with compression; may be seen anywhere in skin or mucous membranes after trauma; changes color as blood is degraded and resorbed	Follows trauma such as that caused by tooth extraction, tooth bite, fellatio, chronic cough, vomiting	Resolves in days to weeks; no sequelae
Blood dyscrasias	Hemorrhagic spots (small—petechiae, large—ecchymoses) on mucous membranes resulting from extravasated blood; may be spontaneous or may follow minor trauma; spots do not blanch with compression; color varies with time; uncommon in general practice, but dental personnel may be first to observe	Lack of clotting factor, reduced numbers of platelets for various reasons, or lack of vessel integrity	May be life threatening; must be investigated, diagnosed, and treated

AIDS, Acquired immunodeficiency syndrome; *GI*, gastrointestinal; *HHV8*, human herpesvirus 8; *HSV,* herpes simplex virus; *UV*, ultraviolet.



■ **FIGURE 37** Erythematous candidiasis.

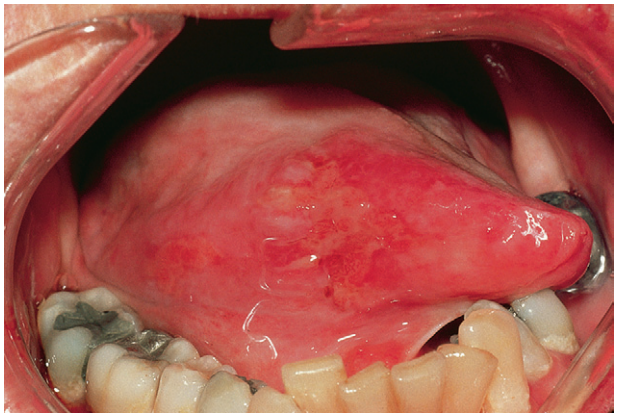

■ **FIGURE 38** Drug reaction.



■ **FIGURE 39** Petechiae, blood dyscrasia.

PIGMENTED LESIONS

Disease	Clinical Features	Cause	Significance
Physiologic pigmentation	Symmetric distribution; does not change in intensity; does not alter surface morphology	Normal melanocyte activity	None
Smoking-associated melanosis	Gingival pigmentation; especially women taking birth control pills	Component in smoke stimulates melanocytes	Cosmetic; may herald smoking-associated lesions elsewhere
Oral melanotic macule	Flat oral pigmentation less than 1 cm in diameter; lower lip, gingiva, buccal mucosa, palate usually affected; may represent oral ephelis, perioral lesions associated with Peutz-Jeghers syndrome, Addison's disease, or postinflammatory pigmentation	Unknown; postinflammatory; or trauma	Remains indefinitely; no malignant potential
Neuroectodermal tumor of infancy	Pigmented, radiolucent, benign neoplasm in maxilla of newborns; pigment is melanin; rare	Unknown; tumor cells of neural crest origin	Recurrence unlikely

Continued



■ **FIGURE 40** Physiologic pigmentation.



■ **FIGURE 41** Smoking-associated melanosis.

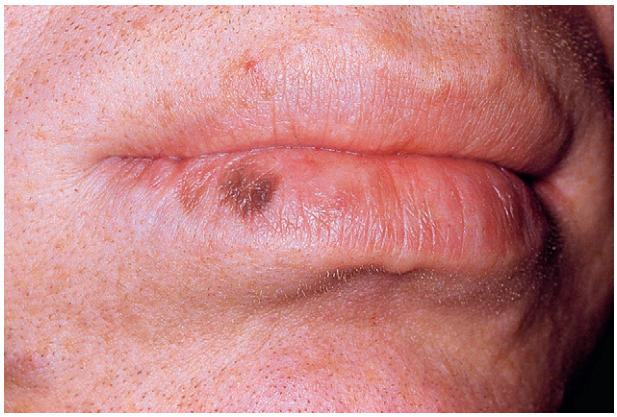

■ **FIGURE 42** Melanotic macule.

PIGMENTED LESIONS—cont'd

Disease	Clinical Features	Cause	Significance
Nevomelanocytic nevus	Elevated pigmentations; often nonpigmented when intraoral; uncommon orally; blue nevi seen in palate	Unknown; due to nests of nevus cells	Remains indefinitely; oral nevi cannot be separated from melanoma clinically
Melanoma	Malignancy of melanocytes; some have a radial growth phase of years' duration (in situ type) before vertical growth phase, but invasive type has only vertical growth phase; oral melanoma may appear first as insignificant spot, especially on palate and gingiva; adults affected	UV light may be carcinogenic on skin; unknown for oral lesions	Skin—65% 5-year survival; oral—20% 5-year survival; in situ melanomas have better prognosis than invasive melanomas; unpredictable metastatic behavior
Amalgam tattoo	Asymptomatic gray-pigmented macule found in gingiva, tongue, palate, or buccal mucosa adjacent to amalgam restoration; may be seen radiographically if particles are large; no associated inflammation; common	Traumatic implantation of amalgam	Remains indefinitely and changes little; no ill effects
Heavy-metal pigmentation	Dark line along marginal gingiva due to precipitation of metal; rare	Intoxication by metal vapors (lead, bismuth, arsenic, mercury) from occupational exposure	Exposure may affect systemic health; gingiva pigmentation of cosmetic significance
Minocycline pigmentation	Gray pigmentation of palate, skin, scars, and bone, and rarely, of formed teeth	Ingestion of minocycline	Must differentiate from melanoma; drug may cause intrinsic staining of teeth

UV, ultraviolet.



■ **FIGURE 43** Blue nevus.

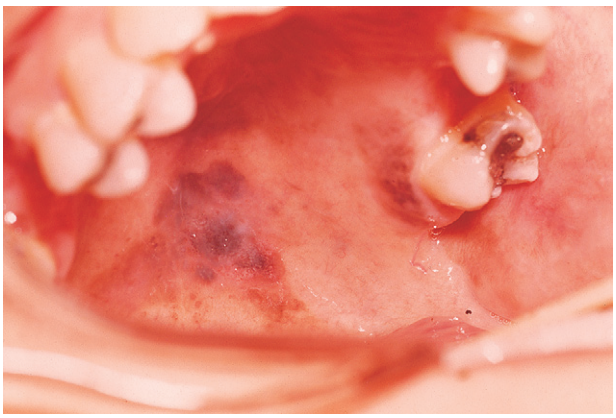

■ **FIGURE 44** Melanoma.



■ **FIGURE 45** Amalgam tattoo.

VERRUCAL-PAPILLARY LESIONS

Disease	Clinical Features	Cause	Significance
Papillary hyperplasia	Painless papillomatous "cobblestone" lesion of hard palate in denture wearers; usually red as a result of inflammation; common	Soft tissue reaction to ill-fitting denture and probable fungal overgrowth	Lesion is not premalignant; may show significant regression if denture taken away from patient; topical antifungals may help
Condyloma latum	Clinically similar to papillary hyperplasia; part of secondary syphilis	*Treponema pallidum*	Prognosis good with treatment
Squamous papilloma	Painless exophytic granular to cauliflower-like lesions; predilection for tongue, floor of mouth, palate, uvula, lips, faucial pillars; generally solitary; soft texture; white or same color as surrounding tissue; young adults and adults; common	Most caused by papillomavirus; some unknown	Lesion has no known malignant potential; recurrence rare
Oral verruca vulgaris	Painless papillary lesion usually with white surface projections caused by keratin production; may be regarded as a type of papilloma; children and young adults; common on skin, uncommon intraorally	Human papillomavirus (HPV)	Little significance; may be multiple and a cosmetic problem
Condyloma acuminatum	Painless, pedunculated to sessile, exophytic, papillomatous lesion; adults; same color as or lighter than surrounding tissue; patient's sexual partner has similar lesions; rare in oral cavity	Human papillomavirus	Oral lesions acquired through autoinoculation or sexual contact with infected partner; recurrence common

Continued



■ **FIGURE 46** Papillary hyperplasia.

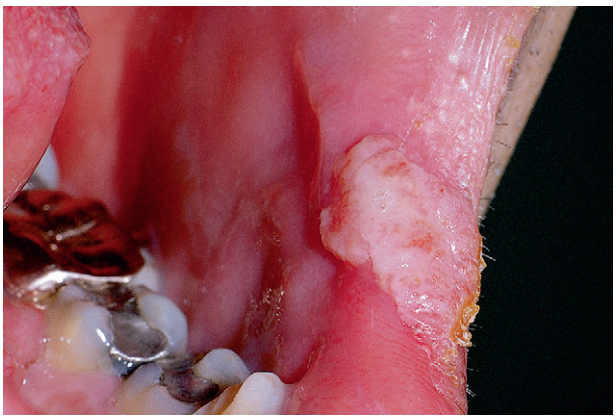

■ **FIGURE 47** Condyloma latum.

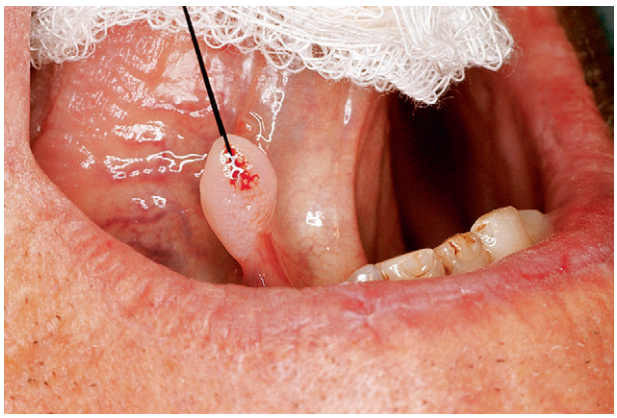

■ **FIGURE 48** Papilloma.

VERRUCAL-PAPILLARY LESIONS—cont'd

Disease	Clinical Features	Cause	Significance
Focal epithelial hyperplasia	Multiple soft nodules on lips, tongue, buccal mucosa; asymptomatic	Papillomavirus (HPV 13 and 32)	Little significance; may be included in differential diagnosis of mucosal nodules
Keratoacanthoma	Well-circumscribed, firm, elevated lesion with central keratin plug; may cause pain; develops rapidly over 4–8 weeks and involutes in 6–8 weeks; found on sun-exposed skin and lips; rare intraorally; predilection for men	Unknown	Difficult to differentiate clinically and microscopically from squamous cell carcinoma; may heal with scar
Verrucous carcinoma	Broad-based, exophytic, indurated lesions; usually found in buccal mucosa or vestibule; men most frequently affected; uncommon	May be associated with use of tobacco	Slow-growing malignancy; well differentiated, with better prognosis than usual squamous cell carcinoma; growth pattern is more expansile than invasive; metastasis uncommon
Pyostomatitis vegetans	Multiple small pustules in oral mucosa; males more than females	Unknown	May be associated with bowel disease such as ulcerative colitis or Crohn's disease
Verruciform xanthoma	Solitary, pebbly, elevated or depressed lesion occurring anywhere in oral mucous membrane; color ranges from white to red; rare	Unknown	Limited growth potential; does not recur



■ **FIGURE 49** Focal epithelial hyperplasia.



■ **FIGURE 50** Keratoacanthoma.

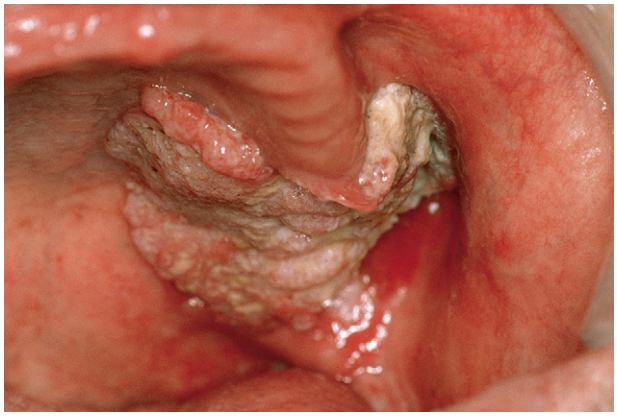

■ **FIGURE 51** Verrucous carcinoma.

GINGIVAL SWELLINGS

Disease	Clinical Features	Cause	Significance
Pyogenic granuloma	Asymptomatic red mass found primarily on gingiva but may be found anywhere on skin or mucous membrane where trauma has occurred; common	Reaction to trauma or chronic irritation	May recur if incompletely excised; usually does not cause bone resorption
Peripheral giant cell granuloma	Asymptomatic red mass of gingiva; cannot be clinically separated from pyogenic granuloma; uncommon	Reaction to trauma or chronic irritation	Completely benign behavior; unlike central counterpart; recurrence not anticipated
Peripheral fibroma	Firm mass; color same as surrounding tissue; no symptoms; common; may be pedunculated or sessile	Reaction to trauma or chronic irritation	Represents overexuberant repair process with proliferation of scar; occasional recurrence seen with peripheral ossifying fibroma
Parulis	Red mass (or yellow if pus filled) occurring usually on buccal gingiva of children and young adults; usually without symptoms	Sinus tract from periodontal or periapical abscess	Cyclic drainage occurs until underlying problem is eliminated
Exostosis	Bony hard nodule(s) covered by intact mucosa found attached to buccal aspect of alveolar bone; asymptomatic; common; usually appears in adulthood	Unknown	No significance except in denture construction

Continued

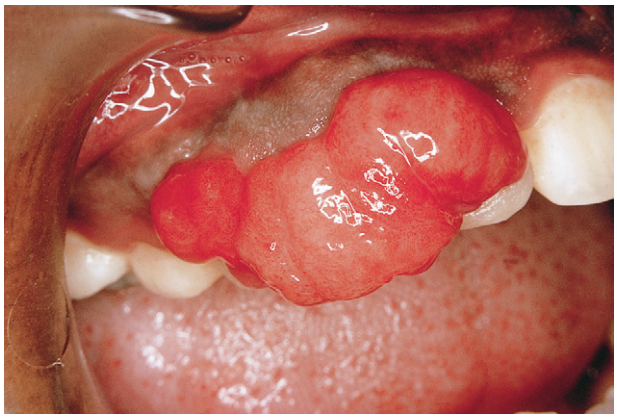

■ **FIGURE 52** Pyogenic granuloma.

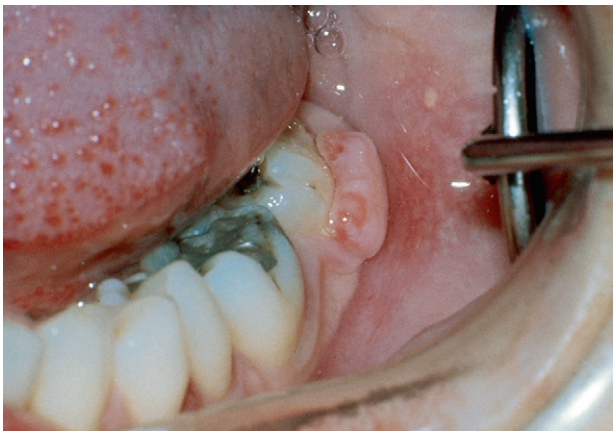

■ **FIGURE 53** Peripheral (ossifying) fibroma.



■ **FIGURE 54** Exostoses.

GINGIVAL SWELLINGS—cont'd

Disease	Clinical Features	Cause	Significance
Gingival cyst	Small, elevated, yellow to pink nodule(s); multiple in infants, solitary in adults; common in infants, rare in adults	Proliferation and cystification of dental lamina rests	Known as *Bohn's nodules* or *Epstein's pearls* in infants; lesions are unroofed during mastication; adult lesions do not occur
Eruption cyst	Bluish (fluid- or blood-filled) sac over crown of erupting tooth; uninflamed and asymptomatic; uncommon	Hemorrhage into follicular space between tooth crown and reduced enamel epithelium	None; should not be confused with neoplasm
Congenital epulis of newborn	Firm, pedunculated or sessile mass attached to gingiva in infants; same color as or lighter than surrounding tissue; rare	Unknown	Benign neoplasm of granular cells similar to granular cell tumor of adult; does not recur
Generalized hyperplasia	Firm, increased bulk of free and attached gingiva; usually asymptomatic; pseudopockets; nonspecific type common, others (drug induced, hormone modified, leukemia induced, genetically influenced) uncommon to rare	Local gingival irritants plus systemic drugs (phenytoin [Dilantin], nifedipine, cyclosporine), hormone imbalance, leukemia, or hereditary factors/syndromes	Cosmetic, as well as hygienic, problem; causative factors should be eliminated if possible; control of local factors can lead to improvement



■ **FIGURE 55** Gingival cyst (between canine and lateral incisor).



■ **FIGURE 56** Eruption cyst.



■ **FIGURE 57** Generalized gingival hyperplasia.

FLOOR-OF-MOUTH SWELLINGS

Disease	Clinical Features	Cause	Significance
Mucus retention cyst (ranula)	Elevated, fluctuant, bluish white mass in lateral floor of mouth; cyclic swelling often; usually painful; uncommon	Sialolith blockage of duct or traumatic severance of duct	Most are due to sialoliths, some are due to severance of duct with extravasation of mucin into soft tissues; recurrence not uncommon
Lymphoepithelial cyst	Asymptomatic nodules covered by intact epithelium <1 cm in diameter; any age; characteristically found on faucial pillars, floor of mouth, ventral and posterior-lateral tongue; yellowish pink; uncommon within oral cavity, common in major salivary glands	Developmental defect	Ectopic lymphoid tissue of no significance; recurrence not expected
Dermoid cyst	Asymptomatic mass in floor of mouth (usually midline) covered by intact epithelium of normal color; young adults; feels doughy on palpation; rare	Proliferation of multipotential cells; stimulus unknown	Recurrence not expected; called *teratoma* when tissues from all three germ layers are present, and *dermoid* when secondary skin adnexa are present
Salivary gland tumor	Solitary, firm, asymptomatic mass usually covered by epithelium; malignant tumors may cause pain, paresthesia, or ulceration; young adults and adults; most common intraorally in palate, followed by tongue, upper lip, and buccal mucosa; uncommon	Unknown	Approximately half of minor salivary gland tumors are malignant; malignancies may metastasize to bones and lungs, as well as to regional lymph nodes; pleomorphic adenoma is most common benign neoplasm
Mesenchymal neoplasm	Firm, asymptomatic tumescence covered by intact epithelium; may arise from any connective tissue cell	Unknown	Benign tumors not expected to recur; malignancies rare



■ **FIGURE 58** Mucus retention cyst (ranula).

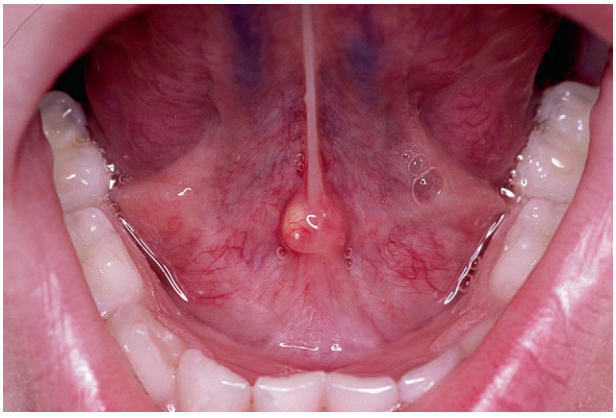

■ **FIGURE 59** Lymphoepithelial cyst, lingual frenum.



■ **FIGURE 60** Dermoid cyst, midline of neck.

LIPS AND BUCCAL MUCOSAL SWELLINGS

Disease	Clinical Features	Cause	Significance
Focal fibrous hyperplasia (oral fibroma)	Firm, asymptomatic nodule covered by epithelium unless secondarily traumatized; usually found along line of occlusion in buccal mucosa and lower lip; common	Reaction to trauma or chronic irritation	Represents hyperplastic scar; limited growth potential, and no malignant transformation seen
Salivary gland tumor	Solitary, firm, asymptomatic mass usually covered by epithelium; malignant tumors may cause pain, paresthesia, or ulceration; young adults and adults; most common intraorally in palate, followed by tongue, upper lip, and buccal mucosa; uncommon	Unknown	Approximately half of minor salivary gland tumors are malignant; malignancies may metastasize to bones and lungs, as well as to regional lymph nodes; pleomorphic adenoma is most common benign neoplasm
Mucus retention cyst	Solitary, usually asymptomatic, mobile, nontender; covered by intact epithelium; color same as surrounding tissue; adults over 50 years of age; common in palate, cheek, floor of mouth; uncommon in upper lip, rare in lower lip	Blockage of salivary gland excretory duct by sialolith	Recurrence not anticipated if associated gland removed; clinically indistinguishable from more significant salivary gland neoplasms
Mucus extravasation phenomenon	Bluish nodule (normal color if deep) usually covered by epithelium; may be slightly painful and have associated acute inflammatory reaction; most frequently seen in lower lip and buccal mucosa, rare in upper lip; adolescents and children; common	Traumatic severance of salivary gland excretory duct	Recurrence expected if contributing salivary gland is not removed, or if adjacent ducts are severed
Mesenchymal neoplasm	Firm, asymptomatic tumescence covered by intact epithelium; may arise from any connective tissue cell	Unknown	Benign tumors not expected to recur; malignancies rare



■ **FIGURE 61** Focal fibrous hyperplasia.



■ **FIGURE 62** Mucus extravasation phenomenon, mandibular vestibule.



■ **FIGURE 63** Mucus extravasation phenomenon.

TONGUE SWELLINGS

Disease	Clinical Features	Cause	Significance
Focal fibrous hyperplasia	Firm, asymptomatic nodule covered by epithelium unless secondarily traumatized; usually found along line of occlusion in buccal mucosa and lower lip; common	Reaction to trauma or chronic irritation	Represents hyperplastic scar; limited growth potential, and no malignant transformation seen
Pyogenic granuloma	Asymptomatic red mass found primarily on gingiva but may be found anywhere on skin or mucous membrane where trauma has occurred; common	Reaction to trauma or chronic irritation	May recur if incompletely excised; usually does not cause bone resorption
Granular cell tumor	Painless elevated tumescence covered by intact epithelium; color same as or lighter than surrounding tissue; strong predilection for dorsum of tongue but may be found anywhere; any age; uncommon	Unknown; cell of origin possibly; Schwann cell; granularity due to cytoplasmic autophagosomes	Does not recur; of significance in that it must be differentiated from other lesions; no malignant potential
Neurofibroma/ palisaded encapsulated neuroma	Soft, single or multiple, asymptomatic nodules covered by epithelium; same as or lighter than surrounding mucosa; most frequently seen on tongue, buccal mucosa, and vestibule but may be seen anywhere; any age; uncommon	Unknown; cell of origin is probably Schwann cell; *NF-1* gene mutation if part of neurofibromatosis syndrome	Recurrence not expected; multiple neurofibromas should suggest neurofibromatosis-1 (von Recklinghausen's disease of nerve, which includes neurofibromas and >6 café-au-lait macules); palisaded encapsulated neuromas are not syndrome associated
Mucosal neuroma	Multiple; lips, tongue, buccal mucosa; may be associated with MEN III syndrome	Unknown; MEN III syndrome is autosomal dominant	MEN III syndrome (pheochromocytoma, medullary carcinoma of thyroid, and mucosal neuromas)
Salivary gland tumor	Solitary, firm, asymptomatic mass usually covered by epithelium; malignant tumors may cause pain, paresthesia, or ulceration; young adults and adults; most common intraorally in palate, followed by tongue, upper lip, and buccal mucosa; uncommon	Unknown	Approximately half of minor salivary gland tumors are malignant; malignancies may metastasize to bones and lungs, as well as to regional lymph nodes; pleomorphic adenoma is most common benign neoplasm
Lingual thyroid	Nodular mass in base of tongue; may cause dysphagia; young adults; rare	Incomplete descent of thyroid anlage to neck	Lingual thyroid may be patient's only thyroid tissue

MEN III, Multiple endocrine neoplasia syndrome type III.



■ **FIGURE 64** Focal fibrous hyperplasia.



■ **FIGURE 65** Granular cell tumor, lateral tongue.



■ **FIGURE 66** Mucosal neuromas of multiple endocrine neoplasia syndrome type III.

PALATAL SWELLINGS

Disease	Clinical Features	Cause	Significance
Mucus extravasation phenomenon	Bluish nodule (normal color if deep) usually covered by epithelium; may be slightly painful and have associated acute inflammatory reaction; most frequently seen in lower lip and buccal mucosa, rare in upper lip; adolescents and children; common	Traumatic severance of salivary gland excretory duct	Recurrence expected if contributing salivary gland not removed or if adjacent ducts are severed
Salivary gland tumor	Solitary, firm, asymptomatic mass usually covered by epithelium; malignant tumors may cause pain, paresthesia, or ulceration; young adults and adults; most common intraorally in palate, followed by tongue, upper lip, and buccal mucosa; uncommon	Unknown	Approximately half of minor salivary gland tumors are malignant; malignancies may metastasize to bones and lungs, as well as to regional lymph nodes; pleomorphic adenoma is most common benign neoplasm
Palatal abscess from periapical lesion	Painful, pus-filled, fluctuant tumescence of hard palate; color same as or redder than surrounding tissue; associated with nonvital tooth	Extension of periapical abscess through palatal bone	Pus may spread to other areas, seeking path of least resistance
Lymphoma	Asymptomatic, spongy to firm tumescence of hard palate; rare in adults; increased frequency in patients with AIDS	Unknown	May represent primary lymphoma (non-Hodgkin's type); lymphoma work-up indicated; high-grade lesions seen in patients with AIDS
Torus	Asymptomatic, bony, hard swelling of hard palate (torus palatinus); bony, exophytic growths along lingual aspect of mandible (torus mandibularis); torpid growth; young adults and adults; affects up to 25% of population	Unknown	No significance; should not be confused with other palatal lesions
Neoplasm of maxilla or maxillary sinus	Palatal swelling with or without ulceration; pain or paresthesia; may cause loosening of teeth or malocclusion; denture may not fit; any age; rare	Unknown	May represent benign or malignant jaw neoplasm or carcinoma of maxillary sinus; poor prognosis for malignant lesions

AIDS, Acquired immunodeficiency syndrome.

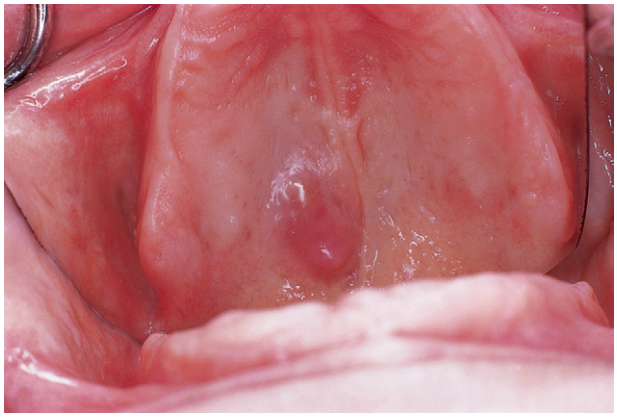

■ **FIGURE 67** Mucus extravasation phenomenon.

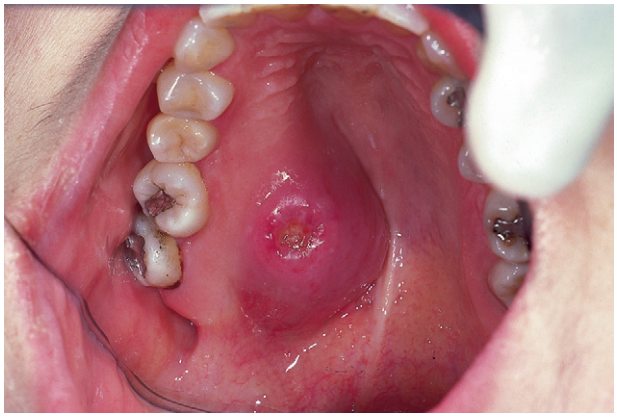

■ **FIGURE 68** Mixed tumor.



■ **FIGURE 69** Lymphoma.

NECK SWELLINGS

Disease	Clinical Features	Cause	Significance
Branchial cyst	Asymptomatic uninflamed swelling in lateral neck; soft or fluctuant; children and young adults; rare	Developmental proliferation of epithelial remnants within lymph nodes	Clinical diagnostic problem
Lymphadenitis—nonspecific, bacterial, fungal	Single or multiple painful nodules (lymph nodes) in neck, especially submandibular and jugulodigastric areas; lesions are usually soft when acute and usually are not fixed to surrounding tissue; nonspecific type common	Any oral inflammatory condition, especially dental abscess; oral tuberculosis, syphilis, or deep fungus may affect neck nodes	Neck disease often reflects oral disease
Metastatic carcinoma to lymph nodes	Usually single but may be multiple (rarely bilateral), indurated masses; fixed and nonpainful; most frequently affects submandibular and jugulodigastric nodes; adults	Metastatic oral cancer; occasionally may come from nasopharyngeal lesion	Signifies advanced disease with poorer prognosis
Lymphoma	Single or bilateral swellings in lateral neck; indurated, asymptomatic, and often fixed; patient may have weight loss, night sweats, and fever; young adults and adults; uncommon	Unknown	After diagnostic biopsy, staging procedures are done; prognosis poor to excellent, depending on stage and classification; increased frequency in patients with AIDS
Parotid lesion	When tail of parotid affected, neck mass may occur; *neoplasm*—indurated, asymptomatic, single lump (Warthin's tumor—may be bilateral); *Sjögren's syndrome*—bilateral, diffuse, soft swelling plus sicca complex, affects primarily older women; *infection*—unilateral, diffuse, soft, painful mass	*Neoplasm*—unknown; *Sjögren's syndrome*—autoimmune; *infection*—viral, bacterial, or fungal; *metabolic disease*—diabetes, alcoholism	Requires diagnosis and treatment by experienced clinician

Continued



■ **FIGURE 70** Branchial (cervical lymphoepithelial) cyst.



■ **FIGURE 71** Metastatic carcinoma to multiple neck nodes.



■ **FIGURE 72** Lymphoma, submandibular node.

NECK SWELLINGS—cont'd

Disease	Clinical Features	Cause	Significance
Carotid body tumor	Firm, movable mass in neck at carotid bifurcation; bruit and thrill may be apparent; adults; rarely hereditary	Neoplastic transformation of carotid body cells; SDHD gene mutation	Morbidity from surgery may be profound because of tumor attachment to carotid sheath
Epidermal cyst	Elevated nodule in skin of neck (or face); usually uninflamed and asymptomatic; up to several centimeters in size; covered by epidermis and near skin surface; common	Epithelial rest proliferation	Recurrence not expected; more superficially located than other neck lesions discussed
Lymphangioma	Spongy, diffuse, painless mass in dermis; may become large; lighter than surrounding tissue to red-blue; crepitance; children; rare	Developmental	May be disfiguring or cause respiratory distress
Thyroglossal tract cyst	Midline swelling in neck above level of thyroid gland; often moves when swallowing; may develop sinus tract; most common developmental cyst of neck	Failure of complete descent of thyroid tissue from foramen caecum with subsequent cystification	Recurrence not uncommon because of tortuous course of cystic lesion
Thyroid gland tumor	Midline swelling in area of thyroid gland; firm, asymptomatic; uncommon	Unknown	Prognosis poor to excellent, depending on stage and histologic type of tumor
Dermoid cyst	Swelling in floor of mouth or midline of neck; young adults	Unknown	Recurrence not expected

AIDS, Acquired immunodeficiency syndrome; *SDHD*, succinic dehydrogenase.



■ **FIGURE 73** Lymphangioma.



■ **FIGURE 74** Thyroglossal tract cyst (sinus tract opening).



■ **FIGURE 75** Dermoid cyst.

CYSTS OF THE JAWS AND NECK

Disease	Clinical Features	Radiographic Appearance	Other Features
Periapical (radicular) cyst	Any age; peaks in third through sixth decades; common; apex of any nonvital erupted tooth, especially anterior maxilla	Well-defined lucency at apex of nonvital tooth	Cannot be distinguished radiographically from periapical granuloma; develops from inflammatory stimulation of rests of Malassez; incomplete enucleation results in *residual cyst*; chronic process and usually asymptomatic; common
Dentigerous cyst	Young adults; associated most commonly with impacted mandibular third molars and maxillary third molars and cuspids	Well-defined lucency around crown of impacted teeth	Some become very large, with rare possibility of pathologic fracture; complication of neoplastic transformation of cystic epithelium to ameloblastoma and, rarely, to squamous cell or mucoepidermoid carcinoma; common; *eruption cyst*—gingival tumescence developing as a dilation of follicular space over crown of erupting tooth
Lateral periodontal cyst	Adults; lateral periodontal membrane, especially mandibular cuspid and premolar area	Well-defined lucency; usually unilocular but may be multilocular	Usually asymptomatic; associated tooth is vital; origin from rests of dental lamina; some keratocysts are found in a lateral root position; gingival cyst of adult may be soft tissue counterpart
Gingival cyst of newborn	Newborn; gingival soft tissues	Usually not apparent on radiograph	Newborns—common, multiple, no treatment; adult gingival cyst is rare, solitary, and treated by local excision

Continued



■ **FIGURE 76** Periapical cyst associated with a carious tooth.

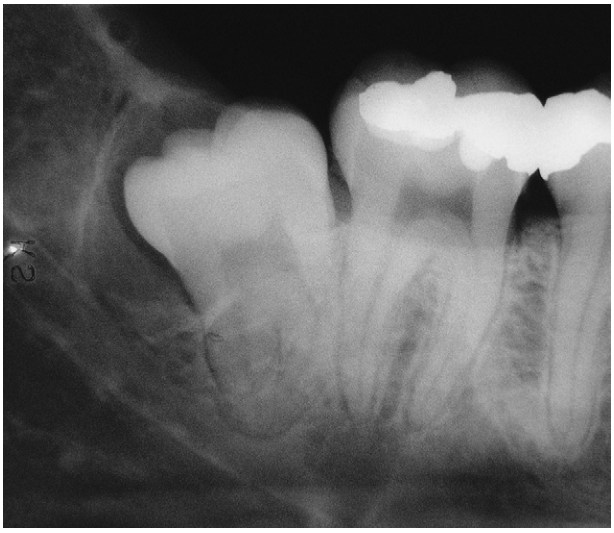

■ **FIGURE 77** Dentigerous cyst.



■ **FIGURE 78** Lateral periodontal cyst.

CYSTS OF THE JAWS AND NECK—cont'd

Disease	Clinical Features	Radiographic Appearance	Other Features
Odontogenic keratocyst (keratocystic odontogenic tumor)	Any age, especially adults; mandibular molar-ramus area favored; may be found in position of dentigerous, lateral root, periapical cyst	Well-defined lucency; unilocular or multilocular	Recurrence rate of 5%–62%; may exhibit aggressive behavior; may be part of nevoid basal cell carcinoma syndrome (keratocysts, skeletal anomalies, basal cell carcinomas)
Calcifying odontogenic cyst	Any age; maxilla favored; gingiva second most common site	Well-defined lucency; may have opaque foci	Origin and behavior are in dispute; ghost cell keratinization characteristic; may exhibit aggressive behavior; rare
Glandular odontogenic cyst	Any age; mandible favored	Well-defined lucency	Recurrence potential
Globulomaxillary lesion	Any age; between roots of maxillary cuspid and lateral incisor	Well-defined oval or pear-shaped lucency	Teeth are vital; asymptomatic; anatomic designation; represents one of several different odontogenic cysts/tumors
Nasolabial cyst	Adults; soft tissue of upper lip, lateral to midline	No change	Origin likely from remnants of nasolacrimal duct; rare
Nasopalatine canal cyst	Any age; nasopalatine canal or papilla	Well-defined midline maxillary lucency; may be oval or heart shaped	Teeth are vital; may be symptomatic if secondarily infected; may be difficult to differentiate from normal canal; common

Continued



■ **FIGURE 79** Odontogenic keratocyst.



■ **FIGURE 80** Globulomaxillary lesion.

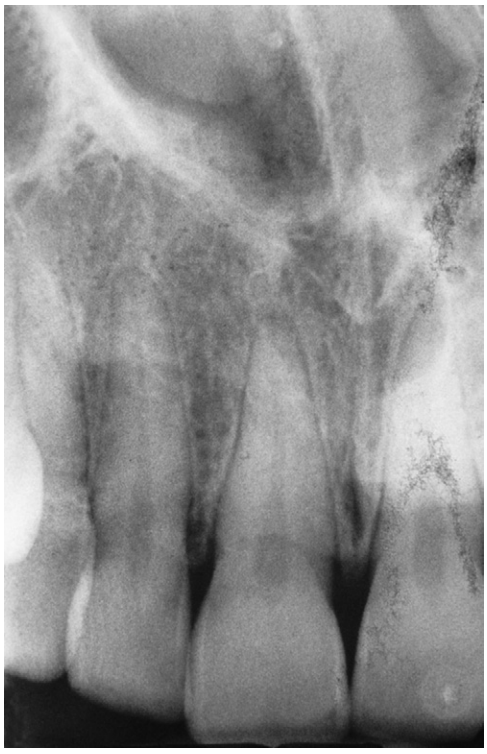

■ **FIGURE 81** Nasopalatine canal cyst.

CYSTS OF THE JAWS AND NECK—cont'd

Disease	Clinical Features	Radiographic Appearance	Other Features
Median mandibular lesion	Any age; midline of mandible	Well-defined lucency	Teeth are vital; asymptomatic; represents one of several different odontogenic cysts/tumors
Aneurysmal bone cyst	Second decade favored; either jaw; also long bones and vertebrae	Lucency, may be poorly defined; may have honeycomb or soap bubble appearance	Represents vascular lesion in bone consisting of blood-filled sinusoids; blood wells up when lesion is entered; cause and pathogenesis unknown; rare; follow-up important
Traumatic (simple) bone cyst	Second decade favored; mandible favored	Well-defined lucency often extending between roots of teeth	Represents dead space in bone without epithelial lining; cause and pathogenesis unknown; uncommon in oral region; often part of florid osseous dysplasia
Static (Stafne) bone cyst	Developmental defect; mandibular molar area below alveolar canal	Well-defined oval lucency; does not change with time	Represents lingual depression of mandible; filled with salivary gland or other soft tissue from floor of mouth; asymptomatic; an incidental finding that requires no biopsy or treatment; uncommon
Focal osteoporotic bone marrow defect	Adults; mandible favored	Lucency; often in edentulous areas	Contains hematopoietic marrow; probably represents unusual healing in bone; must be differentiated from other, more significant lesions; uncommon

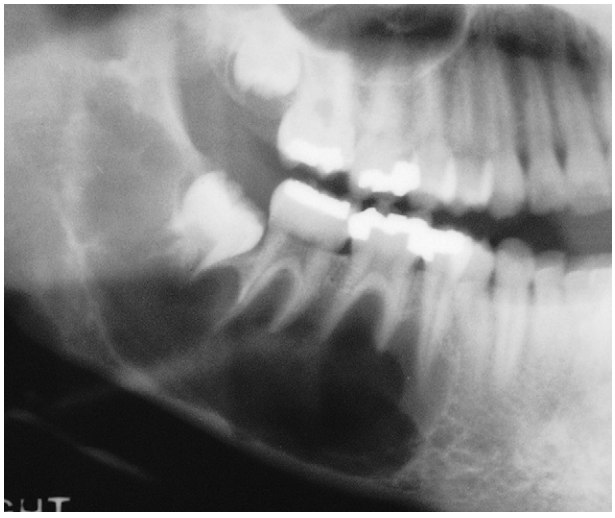

■ **FIGURE 82** Traumatic bone cyst.

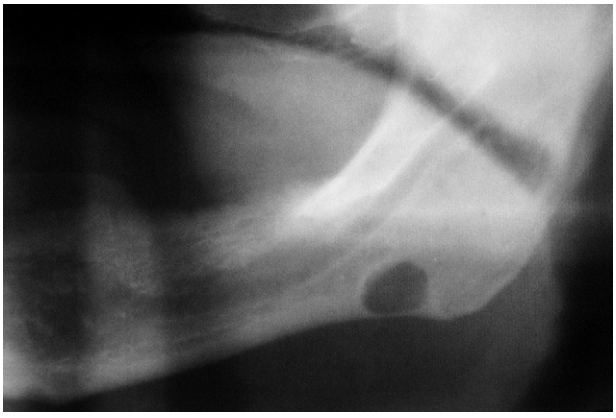

■ **FIGURE 83** Static bone cyst.

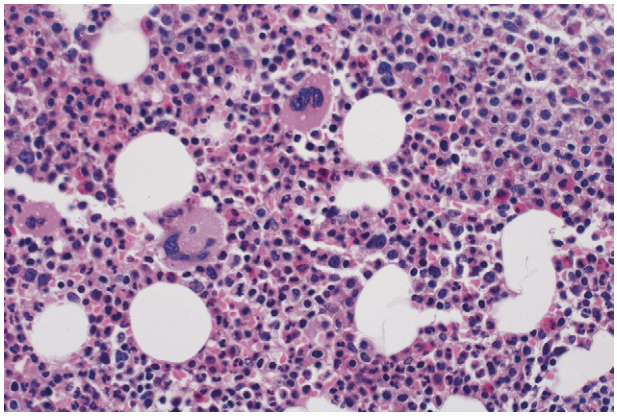

■ **FIGURE 84** Hematopoietic bone marrow defect.

ODONTOGENIC TUMORS

Disease	Clinical Features	Radiographic Appearance	Other Features
Ameloblastoma	Fourth and fifth decades; mandibular molar-ramus area favored	Lucent; usually well circumscribed; unilocular or multilocular	May arise in wall of dentigerous cyst; may exhibit aggressive behavior; rarely metastasizes (usually to lung); recurrence rate lower for cystic type; asymptomatic, uncommon
Squamous odontogenic tumor	Mean age of 40 years; second through seventh decades; alveolar process; anterior more than posterior	Lucency	Conservative therapy; few recurrences, rare
Calcifying epithelial odontogenic tumor (Pindborg tumor)	Mean age around 40 years; second through tenth decades; mandibular molar-ramus area favored	Lucent with or without opaque foci; usually well circumscribed; unilocular or multilocular	Behavior and prognosis are similar to those for ameloblastoma; rare
Clear cell odontogenic tumor	Seventh decade; mandible, maxilla	Lucency	Rare
Adenomatoid odontogenic tumor	Second decade; anterior jaws	Well-defined lucency; may have opaque foci	Usually associated with crown of impacted tooth; no symptoms
Odontogenic myxoma	Mean age of about 30 years; ages 10 to 50 years; any area of jaws	Lucent lesion; often multilocular or honeycombed; may be poorly defined peripherally	Tumors may exhibit aggressive behavior; no symptoms; uncommon; recurrence not uncommon
Central odontogenic fibroma	Any age; any area of jaws	Lucency; usually multilocular	Two microscopic subtypes exhibit same benign clinical behavior; differentiate from desmoplastic fibroma
Cementifying fibroma	Fourth and fifth decades; posterior mandible	Well-defined lucent lesion; may have opaque foci	Asymptomatic; grows by local expansion; recurrence unlikely; rare

Continued

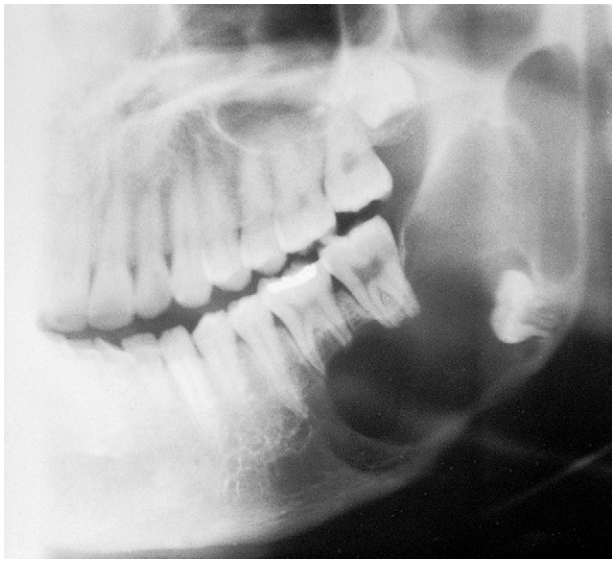

■ **FIGURE 85** Ameloblastoma.



■ **FIGURE 86** Adenomatoid odontogenic tumor.

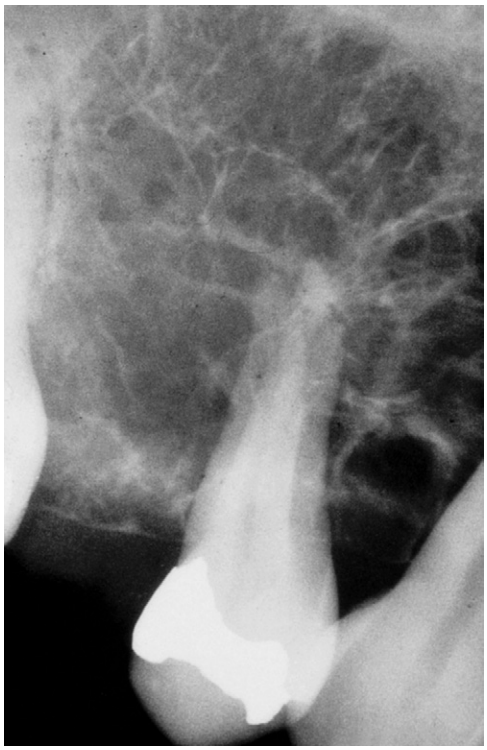

■ **FIGURE 87** Odontogenic myxoma.

ODONTOGENIC TUMORS—cont'd

Disease	Clinical Features	Radiographic Appearance	Other Features
Cementoblastoma	Second and third decades; root of posterior tooth; mandible more than maxilla	Opaque lesion; attached to and replaces root; opaque spicules radiate from central area	May cause cortical expansion; tooth and lesion removed together; no symptoms; rare
Periapical cementoosseous dysplasia	Fifth decade; mandible, especially apices of anterior teeth; usually more than one tooth affected	Starts as periapical lucencies that eventually become opaque in months to years	May be a reactive process; always associated with vital teeth; requires no treatment; asymptomatic; common; rare variant known as *florid cementoosseous dysplasia* represents severe form that may affect one to four quadrants and may have complications of chronic osteomyelitis and traumatic bone cysts
Odontoma	Second decade; any location, especially anterior mandible and maxilla	Opaque; *compound type*—tooth shapes apparent; *complex type*—uniform opaque mass	May block eruption of a permanent tooth; *complex type* rarely causes cortical expansion, no recurrence; *compound type* appears as many miniature teeth; *complex type* is conglomeration of enamel and dentin; probably represents hamartoma rather than neoplasm; common
Ameloblastic fibroma and ameloblastic fibroodontoma	First and second decades; mandibular molar-ramus area; often in a dentigerous relationship with tooth	Well-defined lucency; may be multilocular and large; fibroodontoma may have associated opaque mass representing an odontoma	Well encapsulated; recurrence not expected; no symptoms; if odontoma present, lesion is called *ameloblastic fibroodontoma*; rare



■ **FIGURE 88** Periapical cementoosseous dysplasia.



■ **FIGURE 89** Odontoma.



■ **FIGURE 90** Ameloblastic fibroodontoma.

BENIGN NONODONTOGENIC TUMORS

Disease	Clinical Features	Radiographic Appearance	Other Features
Ossifying fibroma	Third and fourth decades; body of mandible favored	Well-defined lucency, may have opaque foci	Slow growing and asymptomatic; may be indistinguishable from cementifying fibroma; does not recur; microscopy often similar to that of fibrous dysplasia; uncommon
Fibrous dysplasia	First and second decades; maxilla favored	Poorly defined radiographic mass; diffuse opacification often described as ground glass	Slow growing and asymptomatic; causes cortical expansion; may cease growing after puberty; cosmetic problem treated by recontouring. Variants: *monostotic*—one bone affected; *polyostotic*—more than one bone affected; *Albright's syndrome*—fibrous dysplasia plus café-au-lait macules and endocrine abnormalities (precocious puberty in females); *Jaffe-Lichtenstein syndrome*—multiple bone lesions of fibrous dysplasia and skin pigmentations
Osteoblastoma	Second decade; either jaw	Well-defined, lucent to opaque lesion	Diagnostic feature of pain; determination by microscopy often difficult; may be confused with osteosarcoma; recurrence not expected; rare
Chondroma	Any age; any location, especially anterior maxilla and posterior mandible	Relative lucency; may have opacities	May be difficult to separate microscopically from well-differentiated chondrosarcoma; rare
Osteoma	Any age; either jaw	Well defined	Asymptomatic; may be part of Gardner's syndrome (osteomas, intestinal polyps, cysts and fibrous lesions of skin, supernumerary teeth); rare

Continued



■ **FIGURE 91** Ossifying fibroma.



■ **FIGURE 92** Fibrous dysplasia.

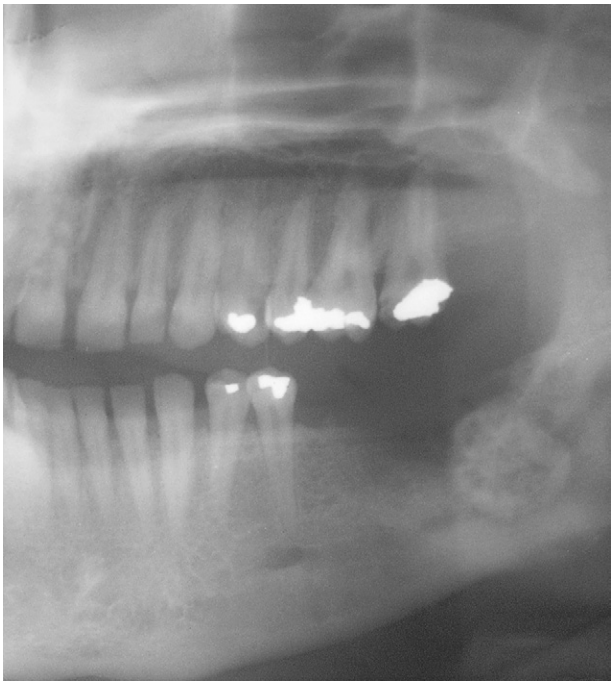

■ **FIGURE 93** Osteoblastoma.

BENIGN NONODONTOGENIC TUMORS—cont'd

Disease	Clinical Features	Radiographic Appearance	Other Features
Central giant cell granuloma	Children and young adults; either jaw	Usually well-defined lucency; may be multilocular or, less frequently, unilocular	May exhibit aggressive behavior; low recurrence rate; asymptomatic; uncommon; rule out hyperparathyroidism
Hemangioma of bone	Young adults; either jaw	Lucent lesion; may resemble honeycomb or may be multilocular	Hemorrhage is significant complication with treatment; asymptomatic; rare
Langerhans cell disease	Children and young adults; any bone	Single or multiple lucent lesions; some described as punched out; lesions around root apices sometimes described as resembling floating teeth	Three variants: *Letterer-Siwe syndrome (acute disseminated)*—organs and bone affected, infants, usually fatal; *Hand-Schüller-Christian syndrome (chronic disseminated)*—bone lesions, exophthalmos, diabetes insipidus, and organ lesions; children, fair prognosis; *eosinophilic granuloma (chronic localized)*—bone lesions only, children and adults, good prognosis; surgery, radiation, or chemotherapy; cause unknown
Tori and exostoses	Adults; palate, lingual mandible, and buccal aspect of alveolar bone	May appear as opacity when large	Torus palatinus in 25% of population, torus mandibularis in 10%; cause unknown; little significance
Coronoid hyperplasia	Young adults; coronoid process of mandible	Opaque enlargement	Cause unknown; may affect jaw function

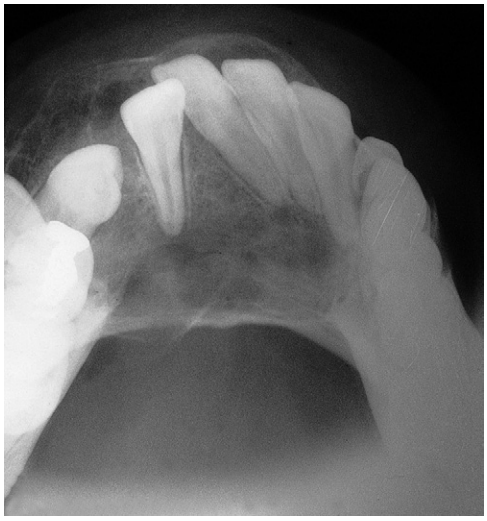

■ **FIGURE 94** Central giant cell granuloma.

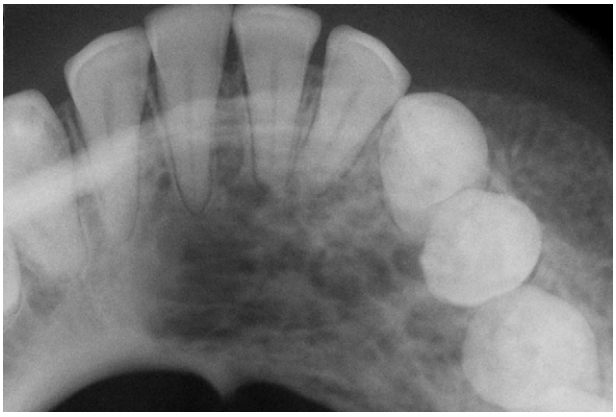

■ **FIGURE 95** Hemangioma.



■ **FIGURE 96** Mandibular tori (exostoses).

INFLAMMATORY JAW LESIONS

Disease	Clinical Features	Radiographic Appearance	Other Features
Acute osteomyelitis	Any age; mandible favored	Little radiographic change early; after 1–2 weeks, a diffuse lucency appears	Pain or paresthesia may be present; pus producing if due to *Staphylococcus* infection; uncommon in severe form; most frequently caused by extension of periapical infection
Chronic osteomyelitis	Any age; mandible favored	Focal or diffuse; lucent with sclerotic foci described as moth-eaten pattern; *focal sclerotic type*—well-defined opacification; *diffuse sclerotic type*—diffuse opacification; *Garré's type*—onion-skin periosteum	Usually asymptomatic but may be painful; most cases related to chronic inflammation in bone of dental origin; many cases not treated; nonvital teeth should be extracted or root canals filled; common; *Garré's type* treated by endodontics or extraction of offending tooth

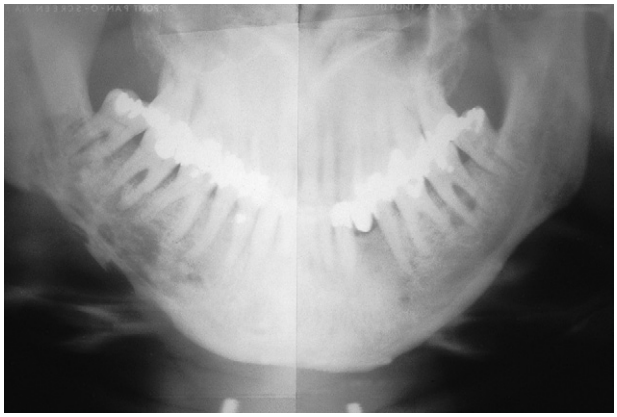

■ **FIGURE 97** Chronic osteomyelitis in radiated mandible.

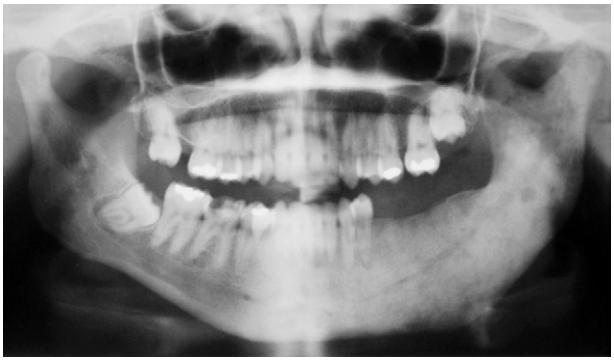

■ **FIGURE 98** Diffuse sclerosing osteomyelitis.

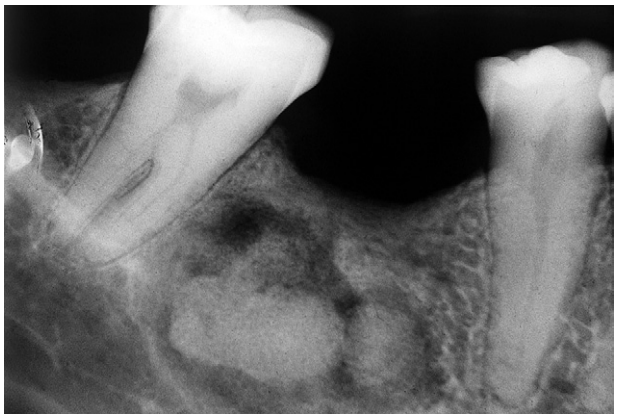

■ **FIGURE 99** Focal sclerosing osteitis.

MALIGNANCIES OF THE JAWS

Disease	Clinical Features	Radiographic Appearance	Other Features
Osteosarcoma	Third and fourth decades; mandible or maxilla; juxtacortical subtype arises from periosteum	Poorly defined lucency, often with spicules of opaque material; sunburst pattern may be seen; juxtacortical lesion appears as radiodense mass on periosteum	Swelling, pain, and paresthesia are diagnostic features; patients may have vertical mobility of teeth and uniformly widened periodontal ligament space; prognosis fair to poor, good prognosis for juxtacortical lesions
Chondrosarcoma	Adulthood and old age; maxilla favored slightly	Poorly defined, lucent to moderately opaque	Swelling, pain, or paresthesia may be present; prognosis fair to poor, better if in mandible; often misdiagnosed as benign cartilage lesion; rare
Burkitt's lymphoma	Children; mandible or maxilla	Diffuse lucency	Malignancy of B lymphocytes linked to Epstein-Barr virus; pain or paresthesia may be presenting symptom; prognosis fair; rare in United States

Continued



■ **FIGURE 100** Osteosarcoma.



■ **FIGURE 101** Postradiation chondrosarcoma, third molar area.

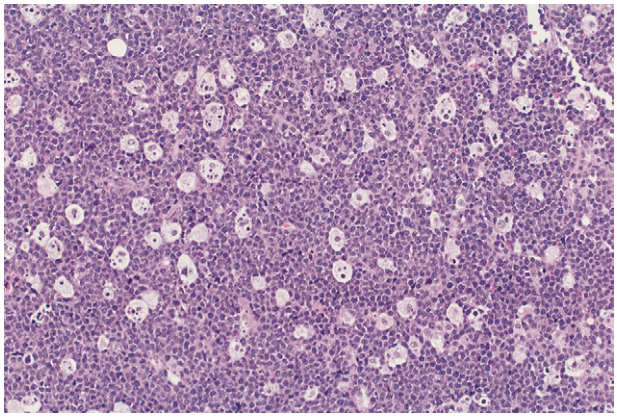

■ **FIGURE 102** Burkitt's lymphoma ("starry sky" microscopy).

MALIGNANCIES OF THE JAWS—cont'd

Disease	Clinical Features	Radiographic Appearance	Other Features
Ewing's sarcoma	Children and young adults; mandible favored	Diffuse lucency; poorly defined; periosteal onion-skin reaction may be present; may be multilocular	Swelling, pain, or paresthesia may be present; prognosis is poor; malignant cell is of unknown origin; rare
Multiple myeloma	Adults; mandible favored	Well-defined lucencies described as punched-out lesions; some lesions diffuse	Swelling, pain, or numbness may be presenting complaint; Bence Jones protein in urine of a majority of patients; rare to have only jaw lesions; prognosis is poor; solitary lesions eventually become disseminated
Metastatic carcinoma	Adults; mandible favored; occasionally gingiva	Ill-defined, destructive lucency; may be multilocular; some tumors may have opaque foci (e.g., prostate, breast, lung)	Pain or paresthesia common; origin is most likely from a malignancy of breast, kidney, lung, colon, prostate, or thyroid; uncommon

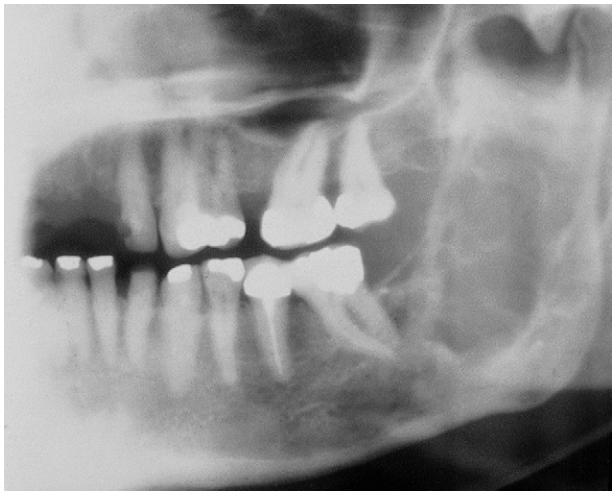

■ **FIGURE 103** Multiple myeloma, mandibular ramus.

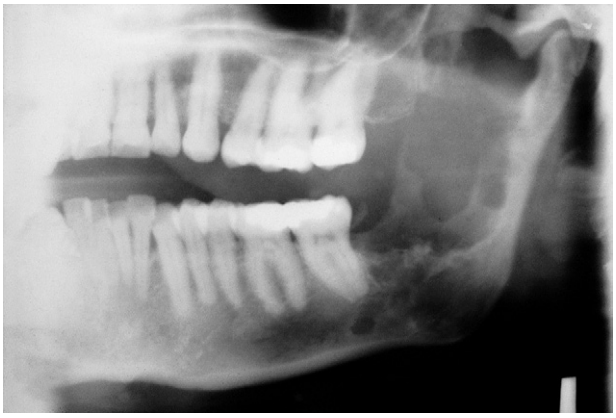

■ **FIGURE 104** Metastatic breast cancer, mandibular ramus.



■ **FIGURE 105** Metastatic osteosarcoma to the anterior mandible.

METABOLIC AND GENETIC DISEASES

Disease	Clinical Features	Radiographic Appearance	Other Features
Paget's disease	Age over 40 years; maxilla favored; bilateral and symmetric; affects entire bone	Diffuse lucent to opaque bone changes; opaque lesions described as cotton wool; hypercementosis, loss of lamina dura, obliteration of periodontal ligament space, and root resorption may be seen	Patients develop pain, deafness, blindness, and headache caused by bone changes; initial complaint may be that denture is too tight; diastemas may develop; complications of hemorrhage early, infection and fracture late; alkaline phosphate elevated; cause unknown but affects bone metabolism
Hyperparathyroidism	Any age; mandible favored	Usually well-defined lucency(ies); may be multilocular; a minority of patients show loss of lamina dura	Usually asymptomatic; microscopically identical to central giant cell granuloma; serum calcium elevated; most caused by parathyroid adenoma; rare
Acromegaly	Adults (after closure of epiphyses); mandible; uniform, bilateral	Large jaw; splayed teeth	Excess production of growth hormone after closure of epiphyses (condylar growth becomes active); prognathism, diastemas may appear; rare

Continued

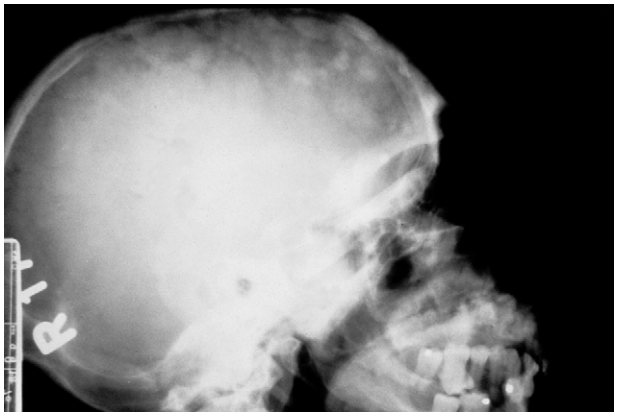

■ **FIGURE 106** Paget's disease of the cranium.



■ **FIGURE 107** Paget's disease of the mandible.



■ **FIGURE 108** Acromegaly.

METABOLIC AND GENETIC DISEASES—cont'd

Disease	Clinical Features	Radiographic Appearance	Other Features
Infantile cortical hyperostosis	Infants; mandible and other bones of skeleton	Cortical thickening/sclerosis	Cause unknown; self-limited; treatment is supportive
Phantom bone disease	Young adults; mandible more than maxilla	Gradual lucency of entire bone	Cause unknown; no treatment
Cherubism	Children; mandible favored; uniform, bilateral	Bilateral multilocular lucencies	Autosomal-dominant inheritance pattern; cherub-like face; microscopy similar to that for central giant cell granuloma; process stabilizes after puberty; rare
Osteopetrosis	Children and adults; both jaws (and skull)	Diffuse, homogeneous, and symmetric opacification; may cause arrested root development and delayed eruption	Dominant forms are infantile, recessive (severe), and adult; intermediate form also recessive but has mild presentation; results in inhibition of bone resorption; patients can develop anemia, blindness, and deafness; dental complication of infection and fracture; rare

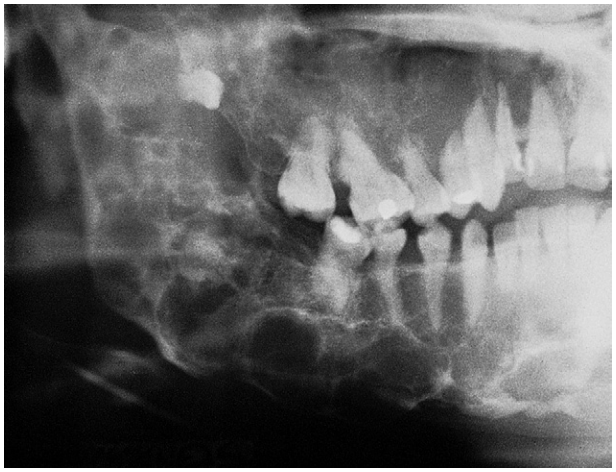

■ **FIGURE 109** Cherubism.

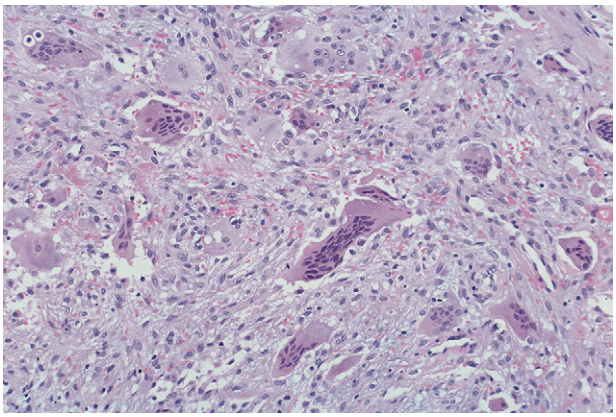

■ **FIGURE 110** Cherubism.

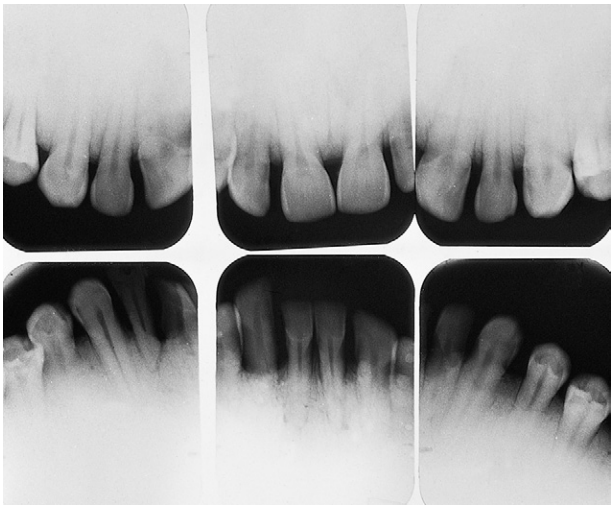

■ **FIGURE 111** Osteopetrosis.

Index

A

A. israelii. *See Actinomyces israelii*
Abrasion, 377-378, 377f-378f
Abscess, periapical
  clinical features of, 316-317, 317b-318b, 317f
  etiology of, 316, 316f
  histopathology of, 317-318
  treatment and prognosis for, 318
Acantholysis, 11
Acid-fast bacilli, 29
Acquired angioedema, 47, 47f
Acquired immunodeficiency syndrome (AIDS). *See* AIDS
Acromegaly
  clinical features of, 353-354, 354f
  etiology of, 353
  overview of, O-53f, O-53t-O-54t
  salivary gland enlargement and, 196
  treatment of, 354
Actinic cheilitis
  clinical features of, 90, 90b, 90f
  etiology and pathogenesis of, 90
  histopathology of, 90, 90f
  overview of, O-14t-O-17t
  treatment of, 90-91
Actinic keratoses, 91
Actinomyces israelii, 32-33
Actinomycosis
  clinical features of, 32-33, 34f
  differential diagnosis for, 33
  etiology/pathogenesis of, 32
  histopathology of, 33, 33f
  overview of, O-6t-O-12t
  treatment of, 33
Acute candidiasis (thrush), 105-106, 105f-106f
Acute disseminated LCD. *See* Letterer-Siwe disease
Acyclovir, treatment of HSV and, 6
ADAM, 19
Addison's disease
  oral melanotic macule and, 136-137, 136b, 137f
  overview of, O-24t-O-25t
Adenoameloblastoma, 279
Adenocarcinoma not otherwise specified, 221
Adenocarcinoma, basal cell, 223, 223f
Adenocarcinoma, polymorphous low-grade
  clinical features of, 214-215, 215b
  histopathology of, 215, 215f-216f
  treatment and prognosis for, 216
Adenoma, basal cell
  clinical features of, 206
  histopathology of, 206-207, 206f
  introduction to, 204b, 206
  treatment and prognosis for, 207
Adenoma, canalicular
  clinical features of, 207
  histopathology of, 207, 207f
  treatment and prognosis for, 208
Adenoma, membranous basal cell, 206
Adenoma, pleomorphic, 205, 337. *See also* Tumor, mixed
Adenoma, sebaceous, 210
Adenoma, solid pattern basal cell, 206, 206f
Adenoma, trabecular form basal cell, 206, 207f
Adenoma, tubular form basal cell, 206, 206f
AFP. *See* Facial pain, atypical (AFP)
Ageusia, 201
AIDS (acquired immunodeficiency syndrome)
  benign cystic lymphoepithelial lesions and, 226
  hairy leukoplakia and, 87, O-14t-O-17t
  Kaposi's sarcoma and, O-18t-O-22t
  lymphoma and, O-34t
  oral warts and, 150
Albers-Schönberg disease. *See* Osteopetrosis
Albright's syndrome, 138
Alcohol, 52
Alkaline phosphatase, 352
Allergic gingivostomatitis. *See* Gingivitis, plasma cell
Allergy, contact
  clinical features of, 48-49, 48f
  diagnosis of, 49
  etiology/pathogenesis of, 48
  histopathology of, 49
  immunologic abnormalities and, 131
  overview of, O-6t-O-12t, O-11f, O-18t-O-22t
  treatment of, 49
Alveolar ridge keratosis, 94-95
Amalgam tattoo (focal argyrosis)
  clinical features of, 145, 145f
  differential diagnosis for, 145
  etiology of, 145
  histopathology of, 145, 145f
  overview of, O-24t-O-25t, O-25f
Ameloblastoma
  biological subtypes of, 272-275, 273b, 274f
Ameloblastoma (*Continued*)
  clinical features of, 271-272, 272b, 272f-273f
  differential diagnosis for, 277
  histopathology of, 275-277, 275b, 276f
  overview of, O-43t-O-45t, O-44f
  pathogenesis of, 271, 271b, 271f
  treatment and prognosis for, 277
Ameloblastoma, basal cell, 275-277
Ameloblastoma, basaloid, 275-277
Ameloblastoma, cystic, 273-274, 274b, 274f
Ameloblastoma, desmoplastic, 272, 275-277, 276f
Ameloblastoma, extraosseous. *See* Ameloblastoma, peripheral
Ameloblastoma, granular cell, 275-277, 276f
Ameloblastoma, malignant, 274-275, 275f
Ameloblastoma, peripheral, 272-273, 273b
Ameloblastoma, plexiform, 275-277, 276f
Ameloblastoma, sinonasal, 275
Amelogenesis imperfecta, 381-383, 382t
American Joint Committee on Cancer (AJCC)
  Cancer Staging Manual of, 64
Amyloidosis, 241-242, 241f-242f, 242t
Amyloidosis, systemic, 341, 341b
Anaplastic large cell lymphoma (ALCL), 237-238, 237f
Anatomic assessment, 60-61
Ancient schwannoma, 178
Anemia, O-18t-O-22t
  multiple myeloma and, 341
Anemia, pernicious
  burning mouth syndrome and, 126
  clinical features of, 125
  etiology of, 125
  treatment of, 126
Angio-osteohypertrophy syndrome, 117
  hemifacial hypertrophy and, 367
Angioedema, 47
Angioedema, hereditary, 47
Angiofibroma, giant cell
  clinical features of, 168
  histopathology of, 168
  treatment of, 168
Angiofibroma, juvenile nasopharyngeal. *See* Angiofibroma, nasopharyngeal
Angiofibroma, nasopharyngeal
  clinical features of, 169
  histopathology of, 169
  treatment of, 169
Angioleiomyoma. *See* Vascular leiomyoma
Angiosarcoma, 175

Page numbers followed by "f" refer to illustrations, "t" refer to tables, and "b" refer to boxes.

Angular cheilitis, 106-107, 125
Ankylosis, 379
Ann Arbor staging system
non-Hodgkin's lymphoma and, 230, 230b
Anodontia, 378-379, 378f
Anodontia, complete, 378-379
Anodontia, partial, 378
Anti-S-100, 143-144
Antidepressant therapy, burning mouth syndrome and, 128
Antineutrophil cytoplasmic antibody (cANCA), 49-50
Antineutrophil perinuclear antibody (pANCA), 49-50
Antinuclear antibody (ANA), 102
Antral carcinoma, 72
ANUG (acute necrotizing ulcerative gingivitis), 5-6
AOT. *See* Tumor, adenomatoid odontogenic (AOT)
Aphthous ulcer
clinical features of, 38, 38t
differential diagnosis for, 38t, 40
etiology of, 37-38, 37b, 37t
herpetiform ulcers and, 39, 40f
histopathology of, 39-40
major ulcers and, 38-39, 40f
minor ulcers and, 38, 38f-39f
overview of, O-6t-O-12t, O-9f
treatment of, 40-41, 41b
antibiotics and, 41
other drugs and, 41
Apoptosis, 55
Areca (betel) nut, 109
Argyrosis, focal. *See* Amalgam tattoo (focal argyrosis)
Arsphenamine, 26
Aspergillus, 36, 36f
Attrition, 377
Atypia, 93, 94b
Atypical melanocytic proliferation, 142
Auer rods, 243
Axillary freckling, 138, 179

B

Bacillary angiomatosis, 124, 222-223
Bacille Calmette-Guérin (BCG) vaccine, 32
Bacterial infections
actinomycosis and, 32-33
gonorrhea and, 29
leprosy and, 32
noma and, 33-34
syphilis and, 26-29
tuberculosis and, 29-32
Bacteroidaceae, 33-34
Bad breath. *See* Halitosis
Bandler syndrome, 137
Bartonella henselae, 124
Bartonella quintana, 124
Bean's syndrome. *See* Vascular malformation, congenital
Behçet's syndrome
clinical features of, 42, 42b, 42f
diagnosis of, 42
etiology of, 42
Behçet's syndrome (*Continued*)
histopathology of, 42
overview of, O-6t-O-12t
treatment of, 42-43
Bence Jones proteinuria, 341
Beta-pleated sheet, 241-242
Betel nut. *See* Areca (betel) nut
Biliary atresia, 388
Bismuth line, 146-147
Bisphosphonate
description of, 320-321, 321t
mechanisms of action and, 321
Bisphosphonate therapy
benefits/risks of, 321
dental management during, 322-323
BL. *See* Burkitt's lymphoma (BL)
Blandin-Nuhn glands, 187
Blastoid variant, 235
Blastomycosis, 34
Blood dyscrasia, 131b, O-18t-O-22t, O-23f
Blue rubber bleb nevus syndrome. *See* Vascular malformation, congenital
Blunderbuss foramen, 179
Bohn's nodule. *See* Cyst, gingival of newborn
Bone cyst, aneurysmal
clinical features of, 263, 263f
differential diagnosis for, 263
etiology and pathogenesis of, 263
giant cell granuloma and, 305
histopathology of, 263, 263f
introduction to, 262-263, 263b
overview of, O-38t-O-42t
treatment and prognosis for, 263
Bone infarct, 328-329
Bone marrow defect, focal osteoporotic, 265, 265f, O-38t-O-42t
Bone marrow defect, hematopoietic, O-42f
Bony margin, linear, 332-333
Bony scar. *See* Osteitis, focal sclerosing
Bowel disease, pyostomatitis vegetans and, 160
Bowen's disease, 122
BP180. *See* Bullous pemphigoid antigen 180 (BP180)
Brachytherapy, 65-67
BRAF, 143
Brandywine type dentinogenesis imperfecta, 383
Brown tumor, 351
Buccal lymph node, 227
Bullous pemphigoid (BP)
clinical features of, 18
etiology/pathogenesis of, 17-18
histopathology/immunopathology for, 18
overview of, O-2t-O-4t
treatment of, 18
Bullous pemphigoid antigen 180 (BP180), 15, 17-18
Bullous pemphigoid antigens 230 (BP230), 17-18
Bullous variant, of lichen planus, 98
Burkitt's lymphoma (BL)
clinical features of, 339-340, 340f
histopathology of, 340, 340f
introduction to, 339-340
Burkitt's lymphoma (BL) (*Continued*)
non-Hodgkin's lymphoma and, 229-231, 236, 236f
overview of, O-51f, O-51t-O-52t
treatment and prognosis for, 340
Burkitt's lymphoma, endemic, 236, 340
Burkitt, Denis, 339
Burning mouth syndrome
clinical features of, 127, 127t
diagnosis of, 127
etiology of, 126, 126t
histopathology of, 127
introduction to, 126-128
overview of, O-18t-O-22t
treatment of, 127-128

C

C-myc gene, 339
Cacogeusia, 201
Café-au-lait macule, 138, 138b, 138f, 178-180, 179f
Albright syndrome and, 297
Caffey's disease. *See* Infantile cortical hyperostosis
Calcifying epithelioma of Malherbe, 259
cANCA. *See* Antineutrophil cytoplasmic antibody (cANCA)
Cancer, oral, 3
Cancrum oris. *See* Noma
Candida albicans
burning mouth syndrome and, 126
candidal leukoplakia and, 107
hairy leukoplakia and, 86
oral cancer and, 52
topical steroids and, 14
Candidal leukoplakia, 107
Candidiasis
clinical features of, 105-107, 105b (*See also Candida albicans*)
differential diagnosis for, 107
etiology and pathogenesis of, 104-105, 105b
histopathology of, 107, 108f
introduction to, 104-108, 104b
overview of, O-14t-O-17t, O-16f
treatment and prognosis of, 108b
Candidiasis, atrophic circumoral type, 107
Candidiasis, chronic hyperplastic, 107
Candidiasis, erythematous, 106, O-18t-O-22t, O-23f
Candidiasis, mucocutaneous, 107
Carcinoma in situ, 93-94
Carcinoma of maxillary sinus
clinical features of, 71-72, 72f
diagnosis of, 72
etiology of, 71
histopathology of, 72
overview of, O-6t-O-12t
treatment/prognosis for, 72
Carcinoma of the skin, basal cell
clinical features of, 72-73, 73f
histopathology of, 73, 73f
introduction to, 72
treatment of, 73
Carcinoma, acinic cell
clinical features of, 219-220, 220f
histopathology of, 220, 221f

Carcinoma, acinic cell (*Continued*)
treatment and prognosis for, 221
Carcinoma, adenoid cystic
clinical features of, 216, 216b, 217f
de-differentiated form of, 216-218
histopathology of, 216-218, 217f-218f
treatment and prognosis for, 218
Carcinoma, ameloblastic, 274-275, 275f
Carcinoma, basaloid-squamous, 59-60
Carcinoma, buccal mucosa, 57-58
Carcinoma, cervical, 3
Carcinoma, clear cell, 218, 219b, 219f-220f
Carcinoma, epimyoepithelial, 222, 222f
Carcinoma, floor of mouth, 31f, 57, 57f-58f
Carcinoma, gingiva, 57-58, 58f
Carcinoma, hyalinizing clear cell, 218
Carcinoma, lingual, 56-57, 56f-57f
Carcinoma, lip, 56, 56f
Carcinoma, medullary thyroid, 181
Carcinoma, metastatic
clinical features of, 343-345, 343f-344f
differential diagnosis for, 344-345
histopathology of, 344, 344f-345f, 345t
introduction to, 343-345, 343b
lymph nodes and, O-36f, O-36t-O-37t
overview of, O-51t-O-52t, O-52f
treatment and prognosis for, 345
Carcinoma, mucoepidermoid
clinical features of, 212-213, 212b, 213f
histopathology of, 213, 213f-214f, 213t
introduction to, 211-212
prognosis and treatment of, 213-214
Carcinoma, palatal, 58, 58f-59f
Carcinoma, papillary squamous cell, 59
verrucous carcinoma and, 157, 157f
Carcinoma, primary intraosseous, 275
Carcinoma, retromolar trigone, 67
Carcinoma, salivary duct, 222-223
Carcinoma, spindle cell, 59, 60f
Carcinoma, terminal duct. *See* Adenocarcinoma, polymorphous low-grade
Carcinoma, tonsil squamous cell, 52
Carcinoma, verrucous. *See also* Leukoplakia, proliferative verrucous (PVL)
clinical features of, 156, 156f-157f
differential diagnosis for, 157
etiology of, 156, 156b
histopathology of, 156-157, 157f
human papillomavirus and, 52
overview of, O-26t-O-27t, O-27f
squamous cell carcinoma and, 57-59, 70
treatment and prognosis of, 157-159
Caries, 315
Cartilage, malignant, 336
Caseous necrosis, 31
Castleman's disease, 122
CD marker, 233t
CDK4. *See* Cyclin-dependent kinase 4 (CDK4)
Celiac disease, 37
Cell adhesion protein, 55
Cell, centrocyte-like (CCL), 235
Cellulitis, 318
Cementoblastoma
clinical features of, 284, 284b, 285f
differential diagnosis for, 285
Cementoblastoma (*Continued*)
histopathology of, 285, 285f
overview of, O-43t-O-45t
treatment of, 285
CEOT. *See* Tumor, calcifying epithelial odontogenic (CEOT)
Cervical caries, radiation-associated, 68b, 69, 69f
Cervicofacial actinomycosis, 32-33, 34f
Chancre, 26-27, 27b
Chemical burns, 108, 109f
Chemoradiation. *See* Concurrent chemotherapy (chemoradiation)
Chemotherapy, adjuvant, 333-334
with radiotherapy, 68
Chemotherapy, neoadjuvant, 333-334
Cherubism
central giant cell granuloma and, 305, O-53t-O-54t, O-54f
clinical features of, 355-356, 355b, 355f
histopathology of, 356, 356f
treatment and prognosis for, 356
Chewing tobacco, 52
Chickenpox. *See* Varicella-zoster virus (VZV) infection
Chondroblastic osteosarcoma, 330, 332f
Chondroma, 302-303, O-47t-O-49t
Chondromyxoid fibroma, 337
Chondrosarcoma
clinical features of, 336-338, 337f
differential diagnosis for, 337
histopathology of, 337, 337f
introduction to, 336-338
mesenchymal chondrosarcoma and, 338
overview of, O-51f, O-51t-O-52t
treatment and prognosis for, 337-338
Chondrosarcoma, mesenchymal, 338
Chromogenic bacteria, 387
Chronic disseminated LCD. *See* Hand-Schüller-Christian syndrome
Chronic localized LCD. *See* Eosinophilic granuloma
Cinnamon, 48-49
Cirrhosis, alcoholic, 195-196
Clear cell variant (myoepithelioma), 208
Cleft lip, 368
Cleft lip and palate, bilateral, 368
Cleft lip and palate, unilateral, 368
Cleft palate, 368
Cleft, submucosal, 369
Clefts of lip and palate
clinical features of, 368-369, 368f-369f
etiology and pathogenesis of, 368
introduction to, 368-370
treatment and prognosis for, 369-370
Clonal evolution, 52
Cluttering, 370
COC. *See* Cyst, calcifying odontogenic (COC)
Coccidioidomycosis, 34
Codman's triangle, 336
Cold sores, 2
Computed tomography (CT). *See* CT (computed tomography)
Concrescence, 374, 375f
Concurrent chemotherapy (chemoradiation), 67-68
Condyloma acuminatum
clinical features of, 153, 153f
differential diagnosis for, 154
etiology and pathogenesis of, 153
histopathology of, 153-154
overview of, O-26t-O-27t
treatment and prognosis for, 154
Condyloma latum, 153, O-26f, O-26t-O-27t
Cone beam computed tomography (CBCT), 248
Conformal radiotherapy technique, 65
Congenital epulis of newborn, O-28t-O-29t
Congenital vascular anomalies
congenital hemangiomas/congenital vascular malformations as, 114-115
encephalotrigeminal angiomatosis as, 116-117
hereditary hemorrhagic telangiectasia as, 117
Contrast sialography, 197
Conventional dose-fractionation schedule, 67
Corps ronds, 82
Corticosteroid preparations, topical, 41b
Cowden's syndrome, 154, 165
Coxsackie type A virus, 8-10
Craniofacial dysostosis. *See* Crouzon's syndrome
Craniosynostosis, 360
CREST syndrome, 117
Crohn's disease, 37-38, 39f, 154
Crouzon's syndrome
clinical features of, 361
etiology and pathogenesis of, 360-361
treatment and prognosis for, 361
Crowe's sign. *See* Axillary freckling
Cryptococcus infection, 34
CT (computed tomography), 60-61, 61f
CYBB gene, 50-51
Cyclin D1 (CCND1), 143
Cyclin-dependent kinase 4 (CDK4), 143
Cyclosporine, 166
Cyst of palatine papilla, 261
Cyst, apical periodontal. *See* Cyst, periapical
Cyst, Botryoid odontogenic, 250
Cyst, branchial
clinical features of, 266
differential diagnosis for, 266
histopathology of, 266, 266f
introduction to, 265-266, 266b
overview of, O-36f, O-36t-O-37t
treatment of, 266
Cyst, buccal bifurcation, 252-253
Cyst, calcifying odontogenic (COC)
clinical features of, 259-260, 260f
differential diagnosis for, 260
etiology and pathogenesis of, 259
histopathology of, 260, 260f
introduction to, 259, 259b
overview of, O-38t-O-42t
treatment and prognosis 60, 260
Cyst, cervical lymphoepithelial. *See* Cyst, branchial
Cyst, definition of, 246
Cyst, dentigerous
clinical features of, 251-253, 251b, 252f
differential diagnosis for, 253

Cyst, dentigerous (*Continued*)
etiology and pathogenesis of, 251
histopathology of, 253, 253f
overview of, O-38t-O-42t, O-39f
treatment of, 253
Cyst, dermoid
clinical features of, 266-267, 267f
histopathology of, 267, 267f
introduction to, 266, 267b
overview of, O-30f, O-36t-O-37t, O-37f
treatment of, 267
Cyst, eruption, 253-254, 254f, O-28t-O-29t, O-29f
Cyst, gingival
clinical features of, 111
etiology and pathogenesis of, 111
histopathology of, 111
introduction to, 111
overview of, O-14t-O-17t, O-17f, O-28t-O-29t, O-29f
treatment of, 111
Cyst, gingival of adult, 249, 250f-251f. *See also* Cyst, lateral periodontal
Cyst, gingival of newborn, 111, 251, 251f, O-38t-O-42t
Cyst, glandular odontogenic
clinical features of, 254, 254b, 254f
histopathology of, 254, 254f-255f
overview of, O-38t-O-42t
radiographic features of, 254
treatment and prognosis for, 254-255
Cyst, incisive canal. *See* Cyst, nasopalatine canal
Cyst, intraoral lymphoepithelial, 266f
Cyst, lateral periodontal
clinical features of, 250, 250b, 250f
differential diagnosis for, 250
etiology and pathogenesis of, 249-250
histopathology of, 250, 250f
overview of, O-38t-O-42t, O-39f
treatment and prognosis of, 251
Cyst, lymphoepithelial, 228-229. *See also* Ectopic lymphoid tissue
differential diagnosis for, 228
ectopic lymphoid tissue and, 110
histopathology of, 228, 228f
introduction to, 228, 228f
overview of, O-30f
treatment of, 229
Cyst, maxillary sinus retention
clinical features of, 190
etiology and pathology of, 190
histopathology of, 190
treatment of, 190
Cyst, median mandibular, 261
Cyst, median palatine, 261
Cyst, mucus retention
clinical features of, 188-189, 189f
differential diagnosis for, 189
etiology and pathology of, 188, 188b
histopathology of, 189, 190f
overview of, O-30f, O-31t
treatment and prognosis for, 189
Cyst, nasolabial, 261, O-38t-O-42t
Cyst, nasopalatine canal
clinical features of, 261-262, 262b, 262f
differential diagnosis for, 262
Cyst, nasopalatine canal (*Continued*)
etiology and pathogenesis of, 261
histopathology of, 262, 262f
overview of, O-38t-O-42t, O-41f
treatment and prognosis for, 262
Cyst, nonodontogenic
globulomaxillary cyst/lesion as, 261-262
median mandibular cyst as, 261
nasolabial cyst as, 261
nasopalatine canal cyst as, 261-262
Cyst, odontogenic
calcifying odontogenic cyst as, 259-261
dentigerous cyst as, 251-253
eruption cyst as, 253-254
gingival cyst of newborn as, 251
glandular odontogenic cyst as, 254-255
lateral periodontal cyst as, 249-251
odontogenic keratocyst/keratocystic odontogenic tumor as, 255-259
periapical cyst as, 246-249
Cyst, orthokeratinized odontogenic, 257, 258f
Cyst, paradental, 252-253, 253f
Cyst, periapical
clinical features of, 247-248, 248b, 248f
differential diagnosis for, 249
etiology and pathogenesis of, 246, 247f, 247t
histopathology of, 248-249, 248f-249f
overview of, O-38t-O-42t, O-39f
Cyst, radicular. *See* Cyst, periapical
Cyst, residual, 249, 249f
Cyst, sialo-odontogenic, 254
Cyst, static bone, 264-265, 264b, 265f, O-38t-O-42t, O-42f
Cyst, thyroglossal tract
clinical features of, 268
differential diagnosis of, 268
histopathology of, 268, 268f
introduction to, 267-268, 267b, 268f
overview of, O-36t-O-37t, O-37f
treatment of, 268
Cyst, traumatic bone
clinical features of, 264, 264f
histopathology of, 264, 264f
introduction to, 263-264, 264b
overview of, O-38t-O-42t, O-42f
pathogenesis of, 264
treatment and prognosis for, 264
Cyst/lesion, globulomaxillary, 260f, 261, 261b, O-38t-O-42t, O-41f
Cystic hygroma, 174
Cysts of jaws and neck
nonodontogenic cysts as, 261-262
odontogenic cysts as, 246-261
overview of, O-38t-O-42t
pseudocysts as, 262-265
soft tissue cysts of neck as, 265-268
Cytomegalic inclusion disease. *See* Sialadenitis, cytomegaloviral

D

Darier's disease. *See* Keratosis, follicular
Darier-White disease. *See* Keratosis, follicular
Dens evaginatus, 375-376, 376f
Dens in dente. *See* Dens invaginatus
Dens invaginatus, 375, 375f-376f
Dental lamina cysts of newborn. *See* Cyst, gingival of newborn
Dentin, defects of. *See also* Enamel and dentin defects
dentin dysplasia and, 384-385
dentinogenesis imperfecta and, 383-384
Dentin, opalescent, 383
Dentinogenesis imperfecta, 383, 383f
Dentition, postpermanent, 379-380
Denture hyperplasia. *See* Fibrous hyperplasia, denture-induced
Dermatitis herpetiformis
clinical features of, 18
etiology/pathogenesis of, 18
histopathology/immunopathology of, 18
overview of, O-2t-O-4t
treatment/prognosis for, 18
Diabetes mellitus, 196
DIF testing. *See* Direct immunofluorescence (DIF) testing
Dilaceration, 374-375, 375f
Direct immunofluorescence (DIF) testing, 12-14, 13f
Discoid lupus erythematosus (DLE), 102, 102t, 103f-104f
Distal femoral metaphysis, 335
DLE. *See* Discoid lupus erythematosus (DLE)
Down syndrome
clinical features of, 364-366, 365f
etiology and pathogenesis of, 364
introduction to, 364-366
treatment and prognosis for, 366
Drug reactions
clinical features of, 46-47, 47f, 48b
diagnosis of, 47-48
etiology/pathogenesis of, 46, 46b
histopathology of, 47
immunologic abnormalities and, 131
overview of, O-6t-O-12t, O-18t-O-22t, O-23f
treatment of, 48
Ductal papilloma, 210-211
Ductal papilloma, inverted, 210, 211f
Dysgeusia
burning mouth syndrome and, 126
taste disturbances and, 201
Dyskeratosis, hereditary benign intraepithelial, O-14t-O-17t
Dysphagia, sideropenic, 52
Dysplasia, 93, 94b
Dysplasia, cemento-osseous, 294b, 299
Dysplasia, cleidocranial
clinical features of, 359-360, 359f
etiology and pathogenesis of, 359, 360f
treatment of, 360
Dysplasia, dentin, 384-385, 384f
Dysplasia, fibrous
clinical features of, 297, 297f-298f
differential diagnosis for, 298-299, 299b
etiology and pathogenesis of, 297
histopathology of, 298, 298f
introduction to, 296-299, 296b
osteosarcoma and, 328-329
overview of, O-47t-O-49t, O-48f
treatment and prognosis for, 299

Dysplasia, fibrous craniofacial, 297
Dysplasia, florid cemento-osseous (FCOD), 285-286, 286b, 286f-287f
Dysplasia, florid osseous, 264
Dysplasia, focal cemento-osseous, 285
Dysplasia, hereditary ectodermal, 378-379, 379f
Dysplasia, monostotic fibrous, 297
Dysplasia, periapical cemento-osseous
clinical features of, 285-286, 286f
differential diagnosis for, 287
histopathology of, 287, 287f
introduction to, 285, 285b
overview of, O-43t-O-45t, O-46f
treatment of, 287
Dysplasia, polyostotic fibrous, 297

E

EBRT. *See* External beam radiotherapy (EBRT)
EBV. *See* Epstein-Barr virus (EBV)
Ecchymoses
clinical features of, 132, 132f
diagnosis of, 132
etiology of, 131-132
overview of, O-18t-O-22t
Ectopic lymphoid tissue, 110, 110f, O-14t-O-17t, O-17f
EGFR. *See* Epidermal growth factor receptor (EGFR)
Ehlers-Danlos syndrome
clinical features of, 364
etiology and pathogenesis of, 364
introduction to, 363-364
treatment and prognosis for, 364
Ehrlich, Dr. Paul, 26
Electrical burn, 108-109
EM. *See* Erythema multiforme (EM)
EM major, 44-45, 45f
Enamel and dentin defects, 385
Enamel hypocalcification, 380, 381f
Enamel pearls, 377, 377f
Enamel, defects in. *See also* Enamel and dentin defects
amelogenesis imperfecta and, 381-383
environmental defects and, 380-381
Enamel, environmental defects of, 380-381
Encephalotrigeminal angiomatosis, 116-117, 117f
Endogenous stains, 387-388
Entovirus 71 (EV71), 8-9
Enzyme-linked immunosorbent assay (ELISA), 29
Eosinophil-rich CD30-positive lymphoproliferative disorder, 238
Eosinophilic granuloma, 307
Eosinophilic granuloma of soft tissue, 238
Eosinophilic ulcer of oral mucosa, 238
Epidermal cyst, O-36t-O-37t
Epidermal growth factor receptor (EGFR), 53-55, 68
Epidermolysis bullosa
clinical features of, 19-20, 19f
etiology/pathogenesis of, 19
overview of, O-2t-O-4t
treatment/prognosis for, 20
Epimyoepithelial islands, 199
Epithelioid cell, 31
Epstein's pearls, 111, 251
Epstein-Barr virus (EBV)
Burkitt's lymphoma and, 52, O-51t-O-52t
endemic Burkitt's lymphoma and, 236, 340
hairy leukoplakia and, 86, O-14t-O-17t
Sjögren's syndrome and, 197
Epulis fissuratum. *See* Fibrous hyperplasia, denture-induced
Erosion, 378, 378f
Erosive form, lichen planus, 98
Eruption hematoma, 253-254
Erythema migrans. *See* Tongue, geographic
Erythema multiforme (EM)
clinical features of, 43-45, 43b, 44f-45f
differential diagnosis for, 45, 45t
etiology/pathogenesis of, 43
histopathology of, 45, 45f
overview of, O-6t-O-12t, O-11f
treatment of, 46
Erythematous form, lichen planus, 98
Erythroblastosis fetalis. *See* Rh incompatibility, teeth stain and
Erythrocyte sedimentation rate (ESR), 129
Erythroleukoplakia. *See* Leukoplakia, speckled
Erythroplakia
clinical features of, 121-122, 121b, 121f
differential diagnosis for, 122
etiology of, 121
histopathology of, 122
overview of, O-18t-O-22t
treatment of, 122, 122f
ESR. *See* Erythrocyte sedimentation rate (ESR)
Esthesioneuroblastoma. *See* Neuroblastoma, olfactory
European Organization for Research and Treatment of Cancer (EORTC), 68
Ewing's sarcoma
clinical features of, 338-339, 338f
differential diagnosis for, 339
histopathology of, 339, 339f
introduction to, 338-339
overview of, O-51t-O-52t
treatment and prognosis for, 339
Excision therapy, 74
Excision, wide local, 60
Exogenous stains, 387
Exostosis, 310-311, 311f, O-28f, O-28t-O-29t, O-47t-O-49t, O-49f. *See Also* Tori
External beam radiotherapy (EBRT), 65
External resorption, 386-387, 386f-387f
Extramedullary plasmacytoma, 239-241
Extravascular lesions, petechiae/ecchymoses, 131-132
Extrinsic stains. *See* Exogenous stains

F

F-fluorodeoxyglucose (FDG). *See* FDG
F-misonidazole (FMISO), 64
Facial lymph node, 227
Facial pain, atypical (AFP), 130
Facies leprosa, 32
Factitial injury, 22
False anodontia, 378
False denticles, 385-386
Familial adenomatous polyposis (FAP) associated fibromatosis, 170-171
FCOD. *See* Dysplasia, florid cemento-osseous (FCOD)
FDG (F-fluorodeoxyglucose), 60-61, 64
Fetor ex oris. *See* Halitosis
Fever blister, 2
FGF. *See* Fibroblastic growth factor (FGF)
Fibro-odontoma, ameloblastic, 289f, O-43t-O-45t, O-46f
Fibroblastic, 330
Fibroblastic growth factor (FGF), 55
Fibroma, cementifying, 295, O-43t-O-45t. *See also* Fibroma, ossifying
Fibroma, cemento-ossifying, 295
Fibroma, central odontogenic, 283-284, 284b, 284f, O-43t-O-45t
Fibroma, desmoplastic
central odontogenic fibroma and, 283-284
clinical features of, 301, 302f
differential diagnosis for, 302
histopathology of, 301-302, 302f
introduction to, 301, 301b
treatment of, 302
Fibroma, giant cell, 163-164, 164f
Fibroma, juvenile ossifying, 295, 295b
Fibroma, juvenile psammomatoid ossifying (JPOF), 295
Fibroma, juvenile trabecular ossifying (JTOF), 295
Fibroma, oral, 164
Fibroma, ossifying
clinical features of, 294-295, 294f-295f
differential diagnosis for, 295-296
etiology and pathogenesis of, 294, 294b
histopathology of, 295, 296f
introduction to, 294, 294b
overview of, O-47t-O-49t, O-48f
treatment and prognosis for, 296
Fibroma, peripheral
clinical features of, 163, 163f
differential diagnosis for, 164
histopathology of, 163-164
overview of, O-28f, O-28t-O-29t
treatment of, 164
Fibroma, peripheral odontogenic, 163
Fibroma, peripheral ossifying, 163, 164f
Fibroma, traumatic, 164
Fibroma/fibro-odontoma, ameloblastic
clinical features of, 287-288, 288f
differential diagnosis for, 288-289
histopathology of, 288, 288f-289f
introduction to, 287, 287b
overview of, O-43t-O-45t
treatment of, 289
Fibromatosis
clinical features of, 171
histopathology of, 171, 171f
introduction to, 170-171
treatment of, 171
Fibromatosis, multicentric, 170-171
Fibromatosis, sporadic, 170-171
Fibromyxoma, odontogenic, 283

Fibrosarcoma
clinical features of, 172, 172f
histopathology of, 172, 172f
introduction to, 171-172
treatment of, 172
Fibrosarcoma, ameloblastic, 289, 289f
Fibrosis, submucous, O-14t-O-17t
clinical features of, 109
etiology of, 109
histopathology of, 109-110, 109f
treatment and prognosis of, 110
Fibrous histiocytoma, benign
clinical features of, 173
histopathology of, 173, 173f
treatment of, 173
Fibrous histiocytoma, malignant (MFH)
clinical features of, 173
histopathology of, 173
introduction to, 173
treatment of, 173
Fibrous hyperplasia, denture-induced
clinical features of, 165, 165f
etiology of, 165
treatment of, 165
Fibrous hyperplasia, focal
clinical features of, 164-165, 164f
differential diagnosis for, 165
etiology of, 164, 164b
histopathology of, 165, 165f
overview of, O-31f, O-33f
treatment of, 165
Fissural cyst, 261
Fissured (plicated) tongue, 95-96
Fite stain, 29, 31, 31f
Flavor, 201
Fluorosis, 381, 381f
Fluorosis, endemic, 381
FMISO. *See* F-misonidazole (FMISO)
Focus, 198
Foliate papillae, 226
Folic acid, 37
deficiency of, 125
Follicular colonization, 235
Fordyce's granules, 110, 110f, O-14t-O-17t, O-17f
Fragile X syndrome
clinical features of, 370, 370f
etiology and pathogenesis of, 370
treatment and prognosis for, 370-371
Freckles, 136-137
Frictional hyperkeratosis. *See* Hyperkeratosis, focal
Functional imaging, 60-61, 61f
Fungal disease. *See* Fungal infections
Fungal infection, deep
clinical features of, 35, 35b, 35f
differential diagnosis for, 35
etiology/pathogenesis of, 34, 34b, 34t
histopathology of, 35, 35f
introduction to, 34-36
overview of, O-6t-O-12t
treatment of, 35-36
Fungal infection, opportunistic, 36-37
Fungal infection, subcutaneous, 36
overview of, O-6t-O-12t
sporotrichosis and, 36
Fungal infections, opportunistic
overview of, O-6t-O-12t
phycomycosis and aspergillosis as
clinical features of, 36, 36f
differential diagnosis of, 36-37
etiology/pathogenesis of, 36
histopathology of, 36
treatment of, 37
Fusion, 374, 374f-375f
Fusobacterium necrophorum, 33-34

G

Gangrenous stomatitis. *See* Noma
Gardner's syndrome, 301, 301f
Garré's osteomyelitis, 323. *See also* Osteomyelitis, chronic w/proliferative periostitis
Gemination, 374, 374f
Genetic abnormalities
cherubism as, 354-356
clefts of lip and palate as, 368-370
cleidocranial dysplasia as, 359-360
Crouzon's syndrome as, 360-361
Down syndrome as, 364-366
Ehlers-Danlos syndrome as, 363-364
fragile X syndrome as, 370-371
hemifacial atrophy as, 366
hemifacial hypertrophy as, 366-368
Marfan's syndrome as, 363
osteogenesis imperfecta as, 358-359
osteopetrosis as, 356-358
Pierre Robin syndrome as, 362-363
Treacher Collins syndrome as, 361-362
Genetic disease, O-53t-O-54t
German measles, 10
Ghost cell keratinization, 259
Ghost teeth, 385, 385f
Giant cell arteritis, 129-130
Giant cell granuloma, peripheral
clinical features of, 120, 120f
differential diagnosis for, 120
etiology of, 120
histopathology of, 120, 120f
overview of, O-18t-O-22t, O-19f, O-28t-O-29t
treatment of, 120
Gigantism, 353
Gingivitis, acute necrotizing ulcerative (ANUG). *See* ANUG
Gingivitis, plasma cell, O-18t-O-22t
clinical features of, 130, 130f-131f
etiology of, 130
histopathology of, 130-131
treatment of, 131
Gingivitis, pregnancy, 166
Gingivostomatitis, primary herpetic
herpes simplex infections and, O-2t-O-4t
HSV clinical features and, 3, 3b, 3f
Globulomaxillary, 261
Glomerulonephritis, 103-104
Glossitis, antibiotic, 106
Glossitis, benign migratory. *See* Tongue, geographic
Glossitis, Hunter's, 125
Glossitis, median rhomboid, 107
Glossopharyngeal neuralgia, 129
Glossoptosis, 362
Gluten-sensitive enteropathy, 37
Gonorrhea
clinical features of, 29
differential diagnosis for, 29
overview of, O-6t-O-12t
treatment of, 29
Gorham's disease. *See* Phantom bone disease
Grading, of tumor, 70
Grains, 82
Gram stain, 29
Granuloma of tongue, traumatic, 238
Granuloma, central giant cell, O-47t-O-49t, O-49f
Granuloma, central giant cell (CGCG)
clinical features of, 303-304, 304f
differential diagnosis for, 305, 305b
etiology and pathology of, 303, 303f
histopathology of, 304, 305f
introduction to, 303, 303b
treatment and prognosis for, 305-306
Granuloma, midline
clinical features of, 50, 50f
histopathology of, 50
non-Hodgkin's lymphoma and, 229
overview of, O-6t-O-12t, O-13f
treatment of, 50
Wegener's granulomatosis and, 49-50, 50t
Granuloma, midline lethal, 50, 238
Granuloma, oral traumatic, 238
Granuloma, periapical, 246, 247f, 317
Granuloma, pyogenic
clinical features of, 118-119, 119f
differential diagnosis for, 119-120
etiology of, 118, 119t
histopathology of, 119, 119f
overview of, O-18t-O-22t, O-19f, O-28f, O-28t-O-29t, O-32t
treatment of, 120
Granuloma, traumatic, 25, 25f
Granuloma, traumatic ulcerative (TEG), 238
Granuloma, traumatic ulcerative w/stromal eosinophilia, 238. *See also* Granuloma, traumatic
Granuloma, usage of term, 25
Granulomatous disease, chronic, 50-51, O-6t-O-12t
Graves' disease, 351
Growth factor, 55
Growth factor receptors, 55
Gum boil. *See* Parulis
Gummas, 27-28
Gutka, 109

H

H&E stained sections. *See* Hematoxylin and erosion (H&E) stained sections
Halitosis, 202-203, 203b
Hand-foot-and-mouth disease (HFM)
clinical features of, 9, 9f
differential diagnosis for, 9
etiology/pathogenesis of, 8-9
herpes simplex infections and, O-2t-O-4t

Hand-foot-and-mouth disease (HFM) (*Continued*)
histopathology of, 9
treatment of, 9
Hand-Schüller-Christian syndrome, 307
Hansen's disease. *See* Leprosy
HBID. *See* Hereditary benign intraepithelial dyskeratosis (HBID)
Head and neck SCC (HNSCC), 67-68
Heck's disease. *See* Hyperplasia, focal epithelial
Heerfordt's syndrome, 194
Hemangioma of bone
clinical features of, 306, 307f
differential diagnosis for, 307
histopathology of, 307, 307f
overview of, O-47t-O-49t, O-49f
treatment and prognosis for, 307
Hemangioma, capillary congenital, 114
Hemangioma, cavernous congenital, 114
Hemangioma, congenital
clinical features of, 114-115, 115f
diagnosis for, 115
etiology of, 114, 115t
histopathology of, 115
treatment of, 115
Hemangioma, epithelioid
clinical features of, 227
differential diagnosis for, 228
etiology of, 227
histopathology of, 227-228
introduction to, 227
treatment of, 228
Hemangiomas, congenital, O-18t-O-22t
Hemangiopericytoma, 174-175
Hematopoietic bone marrow defect. *See* Bone marrow defect, focal osteoporotic
Hematoxylin and erosion (H&E) stained sections, 36, 41-42
Hemifacial atrophy, 366
Hepatitis, neonatal, 388
Hereditary benign intraepithelial dyskeratosis (HBID)
clinical features of, 81
etiology of, 81
histopathology of, 81
treatment of, 81
Hereditary disease, epidermolysis bullosa and, 19-20
Hereditary retinoblastoma (RB) syndrome, 328-329
Hereditary white lesion conditions
follicular keratosis as, 81-82
hereditary benign intraepithelial dyskeratosis as, 81
leukoedema as, 79-80
white sponge nevus as, 80-81
Herman spots, 10
Herpangina
clinical features of, 10, 10f
differential diagnosis for, 10
etiology/pathogenesis of, 10
herpes simplex infections and, O-2t-O-4t
treatment of, 10
Herpes labialis, 4
Herpes simplex virus (HSV) infection
clinical features of
herpetic whitlow and, 4-5
immunodeficiency and, 4
primary herpetic gingivostomatitis and, 3
secondary herpes simplex infection and, 3-4
differential diagnosis for, 5-6
drug-reactions and, O-18t-O-22t
erythema multiforme and, 45, 45t
histopathology of, 5, 5f
introduction to, 1-6, 3b, 3f
overview of, O-2t-O-4t, O-3f
pathogenesis of, 1-3, 2f
treatment for, 6
Herpes simplex virus (HSV) infection, secondary
HSV clinical features and, 3-4, 4b, 4f-5f
overview of
of the lips, O-2t-O-4t, O-3f
of the palate, O-3f
Herpes zoster. *See also* Varicella-zoster virus (VZV) infection
overview of, O-2t-O-4t
VZV clinical features and, 7
VZV pathogenesis and, 7
Herpetic whitlow
HSV clinical features and, 4-5, 5f
overview of, O-2t-O-4t
HFM. *See* Hand-foot-and-mouth disease (HFM)
HHT. *See* Telangiectasia, hereditary hemorrhagic
HHV8. *See* Human herpesvirus 8 (HHV8)
Highly active retroviral therapy (HAART), 123-124
oral warts and, 150
Histiocytosis X, 307. *See also* Langerhans cell disease
Histoplasmosis, 34
of the lip, O-9f
HIV (human immunodeficiency virus)
hairy leukoplakia and, 86, O-14t-O-17t
herpes simplex virus and, 2
lymphoepithelial cysts and, 228
oral warts and, 150
HLA. *See* Human leukocyte antigen (HLA)
HLA-B27, 43
HLA-B51, 37-38, 42
HMB45, 143-144
HNSCC. *See* Head and neck SCC (HNSCC)
Hodgkin's lymphoma
clinical features of, 230b, 239
differential diagnosis for, 239
histopathology of, 239
treatment and prognosis for, 239
Honeycomb, 277-278
HPV. *See* Human papillomavirus (HPV)
HSV. *See* Herpes simplex virus (HSV) infection
HSV type 1 (HSV1), 2-3
aphthous ulcers and, 37t
HSV type 2 (HSV2), 2-3
HSV-seropositive patient, 2
Human herpesvirus 8 (HHV8), 122
Kaposi's sarcoma and, O-18t-O-22t
Human immunodeficiency virus. *See* HIV (human immunodeficiency virus)
Human leukocyte antigen (HLA)
dermatitis herpetiformis and, 18
Reiter's syndrome and, O-6t-O-12t
Human papillomavirus (HPV)
condyloma acuminatum and, 153
focal epithelial hyperplasia and, 154
oral cancer and, 52
oral verruca vulgaris and, 149, O-26t-O-27t
verrucal-papillary lesions and, 149-150, 150t
verrucous carcinoma and, 156
Hutchinson's incisor, 381
Hutchinson's triad, 28
Hyaline bodies, 249
Hygroma colli, 174
Hyperbaric oxygen, 320, 322
Hyperkeratosis palmaris et plantaris, 82
Hyperkeratosis, focal
clinical features of, 82-83, 82f-83f, 83b
diagnosis of, 83, 83t
etiology of, 82
histopathology of, 83, 83f
of edentulous ridge, O-14f
overview of, O-14t-O-17t
snuff dipper's pouch and, O-14f
treatment of, 83
Hyperlipoproteinemia, type I, 196
Hyperparathyroidism
clinical features of, 350, 350f
histopathology of, 351
introduction to, 349-351, 349b
overview of, O-53t-O-54t
treatment of, 351
Hyperparathyroidism, secondary, 349-351
Hyperplasia, adenomatoid
clinical features of, 192
differential diagnosis for, 192
histopathology of, 192
treatment and prognosis for, 192
Hyperplasia, angiolymphoid with eosinophilia (ALHE). *See* Hemangioma, epithelioid
Hyperplasia, Condylar, 354
Hyperplasia, coronoid
clinical features of, 311-312
differential diagnosis for, 312
etiology and pathogenesis of, 311
histopathology of, 312
overview of, O-47t-O-49t
treatment and prognosis for, 312
Hyperplasia, dilantin, 166
Hyperplasia, focal epithelial
clinical features of, 154, 154f
differential diagnosis for, 154
etiology and pathogenesis of, 154
histopathology of, 154
overview of, O-26t-O-27t, O-27f
treatment of, 154-155
Hyperplasia, follicular lymphoid, 227
Hyperplasia, general gingival
clinical features of, 166, 167f
etiology of, 166, 166b
histopathology of, 166-167
treatment of, 167

Hyperplasia, generalized, O-28t-O-29t, O-29f
Hyperplasia, inflammatory. *See* Hyperplasia, denture-induced fibrous
Hyperplasia, lymphoid, 226-227, 227f
Hyperplasia, papillary
clinical features of, 152, 152f
differential diagnosis for, 152-153
etiology of, 152
histopathology of, 152, 152f
nodular lesions and, 107
overview of, O-26f, O-26t-O-27t
treatment and prognosis for, 153
Hyperplasia, reactive
denture-induced fibrous hyperplasia and, 165
focal fibrous hyperplasia and, 164-165
generalized gingival hyperplasia and, 166-167
introduction to, 163
peripheral fibroma and, 163-164
Hyperplasia, reactive lymphoid, 227
Hyperplastic scar. *See* Fibroma, peripheral
Hypertelorism, 360-361
Hyperthyroidism, 351, 351b
Hypertrophy, hemifacial
clinical features of, 367
differential diagnosis for, 367
etiology and pathogenesis of, 366-367
introduction to, 366-368, 367f
macrodontia and, 373
treatment and prognosis for, 367-368
Hypocalcified amelogenesis imperfecta, 381-383, 382f
Hypodontia, 378
Hypogeusia, 201
Hypomaturation amelogenesis imperfecta, 381
Hypophosphatasia, 352
Hypoplasia, enamel, 380f
Hypoplasia, maxillary, 360
Hypoplastic amelogenesis imperfecta, 381-383, 382f
Hypothyroidism, 351-352, 352b

I

Idiopathic destructive disease, 238
Idiopathic histiocytosis. *See* Langerhans cell disease
IgA. *See* Immunoglobulin A (IgA)
Image-guided radiation therapy (IGRT), 65
Immunodeficiency, secondary herpes and, 4
Immunoglobulin (lg), O-2t-O-4t
Immunoglobulin A (IgA), 18
Immunologic diseases
aphthous ulcers and, 37-41, O-6t-O-12t
Behçet's syndrome and, 42-43
bullous pemphigoid and, 17-18
chronic granulomatous disease and, 50-51
chronic ulcerative stomatitis and, 41-42
contact allergies and, 48-49
cyclic neutropenia and, 51
dermatitis herpetiformis and, 18
drug reactions and, 46-48
erythema multiforme and, 43-46
Immunologic diseases (*Continued*)
linear immunoglobulin A disease and, 18-19
midline granuloma and, 50
mucous membrane pemphigoid and, 15-17
pemphigus vulgaris and, 11-15
Reiter's syndrome and, 43
Wegener's granulomatosis and, 49-50
Immunosialadenitis, 199
Impaction, 379
IMRT. *See* Intensity-modulated radiation therapy (IMRT)
Infantile cortical hyperostosis, 352-353, O-53t-O-54t
Intensity-modulated radiation therapy (IMRT), 65, 67f
Interstitial radiotherapy (ISRT), 65-67
Interleukin 8 (IL-8), 55
Internal resorption, 386, 386f
International Union Against Cancer (UICC) Classification of Malignant Tumors by, 64
Interstitial implant, 65-67
Intercellular adhesion molecule (ICAM), 55
Intradermal nevus, 140-141
Intraductal papilloma, 210-211, 211f
Intrinsic factor, 125
Intrinsic stains. *See* Endogenous stains
Iodide mumps, 192
Ipsilateral EBRT technique, 65, 66f
Iris freckling, 179
Iron, 37
Iron deficiency, 52
Iron deficiency anemia
burning mouth syndrome and, 126
clinical features of, 126
diagnosis of, 126
etiology of, 126
treatment of, 126
ISRT. *See* Interstitial radiotherapy (ISRT)

J

Jaffe-Lichtenstein syndrome, 297
Jaw
inflammatory lesions of
acute osteomyelitis as, 318-319
bisphosphonate-related osteonecrosis as, 320-326
chronic osteomyelitis as, 319-320
overview of, O-50t
periapical abscess as, 316-318
pulpitis as, 314-316
malignancies of
Burkitt's lymphoma as, 339-340
chondrosarcoma as, 336-338
Ewing's sarcoma/primitive neuroectodermal tumor as, 338-339
introduction to, 328, 329b
juxtacortical osteosarcoma as, 335
metastatic carcinoma as, 343-345
osteosarcoma as, 328-335
overview of, O-51t-O-52t
parosteal osteosarcoma as, 335
periosteal osteosarcoma as, 335-336
plasma cell neoplasms as, 341-343
Jaw claudication, 129
Jaw lesions, differential diagnosis approach to
benign nonodontogenic tumors and, O-47t-O-49t
cysts of jaw and neck and, O-38t-O-42t
inflammatory lesions and, O-50t
jaw malignancies and, O-51t-O-52t
metabolic and genetic diseases and, O-53t-O-54t
odontogenic tumors and, O-43t-O-45t

K

Kaposi's sarcoma
clinical features of, 122-124, 122f-123f, 123b, 123t
differential diagnosis for, 124
etiology of, 122
histopathology of, 124, 124f
overview of, O-18t-O-22t
treatment of, 124
Kaposi's sarcoma herpesvirus (KSHV), 122
Keratin, 58-59
Keratinocytes, epidermal, 73
Keratoacanthoma
clinical features of, 155, 155f
differential diagnosis for, 155
etiology of, 155
histopathology of, 155, 155f
overview of, O-26t-O-27t, O-27f
treatment and prognosis of, 156
Keratoconjunctivitis sicca, 196
Keratosis, follicular, O-14t-O-17t
clinical features of, 82
etiology and pathogenesis of, 81-82
histopathology of, 82
treatment and prognosis for, 82
Kimura's disease, 227
Klippel-Trenaunay syndrome, 117
Klippel-Trénaunay-Weber syndrome, 367
Koplik spots
German measles and, 10
measles and, 10-11, O-2t-O-4t
Kveim test, 195

L

LAD. *See* Linear immunoglobulin A disease (LAD)
Langerhans cell disease
clinical features of, 308-309, 308f
differential diagnosis for, 309
etiology and pathogenesis of, 308, 308b
histopathology of, 309, 309f
introduction to, 307, 307b
overview of, O-47t-O-49t
treatment and prognosis for, 309-310, 310b
Langerhans giant cells, 31
Laugier-Hunziker syndrome, 137
LCD. *See* Langerhans cell disease
LE. *See* Lupus erythematosus (LE)
Lead line, 146-147
Leiomyoma, 182-183, 182t, 183f
Leiomyosarcoma, 182-183, 183f
Leiomyosarcoma, oral, 183
Lentigo, 137

Leprosy
clinical features of, 32
diagnosis of, 32
etiology/pathogenesis of, 32
overview of, O-6t-O-12t
histopathology of, 32
treatment of, 32
Leprosy, lepromatous, 32
Leprosy, tuberculoid, 32
Lesion, benign lymphoepithelial (BLEL), 199
Lesion, kissing, 107
Lesion, median mandibular, O-38t-O-42t
Lesion, melanocytic
café-au-lait macules as, 138
introduction to, 134, 135f
melanoacanthoma as, 141
melanoma as, 141-144
nevomelanocytic nevus as, 139-141
oral melanotic macule as, 136-138
physiologic pigmentation as, 135
pigmented neuroectodermal tumor of infancy as, 138-139
smoking-associated melanosis as, 135-136
Lesion, parotid, O-36t-O-37t
Lesion, salivary lymphoepithelial, 199
Lesion, secondary primary, 70-71
Lesions, connective tissue
fat lesions and, 184-185
fibrous lesions and, 163-173
introduction to, 163
muscle lesions and, 182-184
neural lesions and, 175-182
vascular lesions and, 173-175
Lesions, fat
lipoma and, 184-185
liposarcoma and, 185
Lesions, fibrous
fibrohistiocytic tumors and, 172-173
neoplasms and, 167-172
reactive hyperplasias and, 163-167
Lesions, idiopathic
pyostomatitis vegetans as, 159-160
verruciform xanthoma as, 160-161
Lesions, intravascular
congenital vascular anomalies and, 114-117
immunologic abnormalities and, 130-131
metabolic-endocrine conditions and, 124-130
neoplasms and, 121-124
reactive lesions and, 118-121
Lesions, kidney, 103-104
Lesions, lymphoid
developmental lesions as, 228-229
neoplasms as, 229-243
reactive lesions as, 226-228
Lesions, mucosal
pigmented lesions and, O-24t-O-25t
red-blue lesions and, O-18t-O-22t
ulcerative conditions and, O-6t-O-12t
verrucal-papillary lesions and, O-26t-O-27t
vesiculobullous disease and, O-2t-O-4t
white lesions and, O-14t-O-17t
Lesions, muscle
neoplasms and, 182-184
reactive lesions and, 182
Lesions, neural
neoplasms and, 175-182
reactive lesions and, 175
Lesions, nonepithelial white-yellow
candidiasis and, 104-108
ectopic lymphoid tissue and, 110
Fordyce's granules and, 110
gingival cysts and, 111
lipoma and, 111
mucosal burns and, 108-109
parulis and, 111
submucous fibrosis and, 109-110
Lesions, nonmelanocytic
amalgam tattoo as, 145
drug induced pigmentation as, 145-146
heavy-metal pigmentation as, 146-147
Lesions, pigmented
melanocytic lesions as, 134-144
nonmelanocytic lesions as, 145-147
overview of, O-24t-O-25t
Lesions, preneoplastic/neoplastic
actinic cheilitis and, 90-91
actinic keratoses and, 91
idiopathic leukoplakia and, 91-95
Lesions, reactive
intravascular lesions as
peripheral giant cell granuloma and, 120
pyogenic granuloma and, 118-120
scarlet fever and, 120-121
varix/acquired vascular malformations as, 118
lymphoid lesions as
epithelioid hemangioma and, 227-228
lymphoid hyperplasia and, 226-227
muscle lesions as
myositis ossificans and, 182
neural lesions as
traumatic neuroma and, 175
overview of, O-6t-O-12t
salivary gland diseases and
adenomatoid hyperplasia and, 192
maxillary sinus retention cyst/pseudocyst and, 190
mucus extravasation phenomenon and, 187-188
mucus retention cyst and, 188-189
necrotizing sialometaplasia and, 191-192
traumatic ulcerations and, 22-26
white lesions as
dentifrice-associated slough and, 89
focal (frictional) hyperkeratosis and, 82-83
hairy leukoplakia and, 86-87
hairy tongue and, 88-89
nicotine stomatitis and, 85-86
smokeless tobacco and, 83-85
Lesions, reactive and congenital, 173-174
Lesions, reactive/infectious
condyloma acuminatum as, 153-154
condyloma latum as, 153
focal epithelial hyperplasia as, 154-155
Lesions, reactive/infectious (*Continued*)
papillary hyperplasia as, 152
squamous papilloma/oral wart as, 149-152
Lesions, red-blue, O-18t-O-22t
Lesions, traumatic, O-18t-O-22t
Lesions, vascular
neoplasms and, 174-175
reactive/congenital lesions and, 173-174
Lesions, verrucal-papillary, O-26t-O-27t
idiopathic lesions as, 159-161
neoplasms as, 155-159
reactive/infectious lesions as, 149-155
Lesions, white
hereditary conditions of, 79-82
nonepithelial white-yellow lesions and, 104-111
other white lesions
geographic tongue and, 95-97
lichen planus and, 97-102
lupus erythematosus and, 102-104
overview of, O-14t-O-17t
preneoplastic/neoplastic lesions of, 90-95
reactive lesions of, 79
smokeless tobacco and, 102t
Letterer-Siwe disease, 307
Leukemia
acute leukemia and, 243
blood dyscrasia and, 131
chronic leukemia and, 243
gingival enlargement and, 166
introduction to, 242
Leukemia, acute, 243
Leukemia, acute lymphocytic (ALL), 243
Leukemia, acute myeloid (AML), 243
Leukemia, B-cell chronic lymphocytic/small lymphocytic lymphoma (B-CLL/SLL), 235-236, 235f
Leukemia, chronic, 243
Leukemia, chronic lymphocytic (CLL), 243
Leukemia, chronic myeloid (CML), 243, 243f
Leukoedema
clinical features of, 79, 80f
differential diagnosis for, 79-80
etiology and pathogenesis of, 79
histopathology of, 79
overview of, O-14t-O-17t
treatment and prognosis for, 80
Leukoplakia, 91. *See also* Leukoplakia, idiopathic
Leukoplakia, hairy
clinical features of, 86, 87b, 87f
differential diagnosis for, 87
etiology and pathogenesis of, 86, 86b
histopathology of, 86-87, 88f
overview of, O-14t-O-17t, O-15f
treatment and prognosis for, 87
Leukoplakia, idiopathic
clinical features of, 91-93, 92b, 92f-93f
differential diagnosis for, 94-95
etiology and pathogenesis of, 91, 91f-92f
histopathology of, 93-94, 94f
introduction to, 91-95
overview of, O-14t-O-17t, O-15f
treatment and prognosis of, 95, 95f

Leukoplakia, proliferative verrucous (PVL), 93. *See also* Carcinoma, verrucous
verrucous carcinoma and, 157, 158b, 158f-159f
Leukoplakia, speckled (erythroleukoplakia), 93, 93f
Leung's premolar, 375-376
lg. *See* Immunoglobulin (lg)
Li-Fraumeni syndrome, 328-329
Lichen planus
clinical features of, 98-99, 98b, 99f-100f
differential diagnosis for, 101
etiology and pathogenesis of, 97-98, 97f
histopathology of, 99-101, 100f-101f
introduction to, 97-102
overview of, O-14t-O-17t, O-16f
treatment and prognosis of, 101-102
Lichenoid drug reaction, 47, 48b
Liesegang rings, 278
Light chain restriction, 341-342, 342f
Linear immunoglobulin A disease (LAD), 18-19, 19f
Lingual thyroid, 268f, O-32t
Lingual tonsil, 110
Lip and buccal mucosal swellings, O-31t
Lipoma, 111, 184-185, 184f, O-14t-O-17t
Liposarcoma, 185, 185f
Lips, secondary herpes simplex infection of, O-3f
Lisch spots, 179
Lobular carcinoma of salivary glands. *See* Adenocarcinoma, polymorphous low-grade
Long-acting thyroid stimulator (LATS), 351
Ludwig's angina, 318
Lukes-Butler system, 239
Lupus erythematosus (LE)
clinical features of
discoid lupus erythematosus and, 102
systemic lupus erythematosus and, 102-104
differential diagnosis for, 104
etiology and pathogenesis of, 102
histopathology of, 104, 104f
introduction to, 102-104
overview of, O-6t-O-12t, O-11f
treatment of, 104
Lupus pernio, 194
Lymphadenitis, O-36t-O-37t
Lymphadenopathy, 36
Lymphangioma
clinical features of, 174, 174b, 174f
etiology of, 173
histopathology of, 174, 174f
overview of, O-36t-O-37t, O-37f
treatment of, 174
Lymphangioma, cavernous, 174
Lymphoma
lymphoid lesions and, 229
overview of, O-35f-O-36f, O-36t-O-37t
Lymphoma of MALT. *See* Lymphoma, extranodal marginal zone
Lymphoma, B-cell, 229-231
Lymphoma, diffuse, 232-233
Lymphoma, diffuse B-cell, 233-234, 234f
Lymphoma, extranodal marginal zone, 229, 234-235, 235f
Lymphoma, follicular, 232-233
Lymphoma, follicular B-cell, 234
Lymphoma, mantle cell, 235
Lymphoma, nasofacial natural killer/T-cell (Nasofacial NK/T-cell lymphoma), 238
Lymphoma, NK/T-cell
midline granuloma and, 50
Lymphoma, plasmablastic, 237
Lymphoma, small lymphocytic, 235-236
Lymphoma, sporadic Burkitt's, 340
Lymphomas associated w/HIV infection, 237, 237f
Lymphomatoid granulomatosis, 238
Lymphoproliferative disease of palate, 227
Lyon phenomenon, 381-382

M

M spike, 341
M. avium, 29
M. bovis, 29
M. intracellulare, 29
M. tuberculosis, 29-31
Macrodontia, 373
Macroglossia, 174, 174b
Macule, oral melanotic, O-24f, O-24t-O-25t
clinical features of, 136-137, 136b, 136f-137f
differential diagnosis for, 137-138, 138b
histopathology of, 137, 137f
treatment of, 138
Maffucci's syndrome, 336
MAGIC syndrome, 42
Magnetic resonance imaging (MRI). *See* MRI (magnetic resonance imaging)
Major histocompatibility (MHC) antigen, 2
Malignant reticulosis, midline, 238
Mandibulofacial dysostosis. *See* Treacher Collins syndrome
Mantoux skin test, 30
Marfan's syndrome, 362
clinical features of, 363
etiology and pathogenesis of, 363
treatment and prognosis for, 363
MART-1, 143-144
Massive osteolysis. *See* Phantom bone disease
Matrix metalloproteinase (MMP), 22, 41, 53-55, 248-249
Matrix metalloproteinase 3 (MMP3), 109
MC1R. *See* Melanocortin 1 receptor (MC1R)
McCune-Albright syndrome, 297
Measles (rubeola)
clinical features of, 10-11, 10f
differential diagnosis for, 11
etiology/pathogenesis of, 10
histopathology of, 11
overview of, O-2t-O-4t
treatment of, 11
Melanoacanthoma, 141
Melanocortin 1 receptor (MC1R), 143
Melanocyte, 134
Melanocyte-stimulating hormone (MSH), 137
Melanoma
cutaneous melanoma and, 141-142
differential diagnosis for, 144
etiology of, 143
Melanoma (*Continued*)
immunohistochemistry of, 143-144
oral melanoma and, 142-143
overview of, O-24t-O-25t, O-25f
treatment and prognosis for, 144
Melanoma, cutaneous, 141-142
Melanoma, in situ, 142, 142f, 144f
Melanoma, invasive, 142, 142f-143f
Melanoma, oral, 141-142, 142f-144f, 144b
Melanosis, smoking-associated, O-24f, O-24t-O-25t
Melanosome, 134
MEN III syndrome (multiple endocrine neoplasia syndrome type III)
mucosal neuroma and, O-32t
MEN syndrome type III, mucosal neuroma of. *See also* MEN III syndrome (multiple endocrine neoplasia syndrome type III)
clinical features of, 180, 181f
etiology of, 180, 180t
histopathology of, 181, 181f
overview of, O-33f
treatment of, 181
Mental retardation, X-linked, 370
Mercury intoxication, chronic, 147
Mesenchymal cells, 120
Mesiodens, 379, 380f
Metabolic conditions
acromegaly as, 353-354
hyperparathyroidism as, 349-351
hyperthyroidism as, 351
hypophosphatasia as, 352
hypothyroidism as, 351-352
infantile cortical hyperostosis as, 352-353
introduction to, 195-196
overview of, O-53t-O-54t
Paget's disease as, 347-349
phantom bone disease as, 353
Metabolic-endocrine conditions
burning mouth syndrome as, 126-128
iron deficiency anemia as, 126
other oral-facial pain conditions as, 128-130
pernicious anemia as, 125-126
vitamin B deficiencies as, 124-125
Metastatic disease
osteonecrosis and, 345
MFH. *See* Fibrous histiocytoma, malignant (MFH)
Microdontia, 373, 374f
Microvascular decompression (MVD), 128-129
Mitral valve prolapse, 371
MMP. *See* Matrix metalloproteinase (MMP); Mucous membrane pemphigoid (MMP)
Moeller's glossitis, 125
Mohs' surgery, 74
Molecular targeted agent, 68
Morphea, 199
MRI (magnetic resonance imaging), 60-61
MRND. *See* Neck dissection, modified radical (MRND)
MSH. *See* Melanocyte-stimulating hormone (MSH)
Mucinosis, oral focal, 169

Mucocele, 187
Mucocele, superficial, 187
Mucor, 36
Mucormycosis. *See Phycomycosis*
Mucosa-associated lymphoid tissue (MALT), 229
Mucosal burn
clinical features of, 108-109, 109f
etiology of, 108
histopathology of, 109
overview of, O-14t-O-17t
treatment of, 109
Mucositis, radiation, 68-69, 68b, 69f
Mucous membrane pemphigoid (MMP)
clinical features of, 15-16, 16b
differential diagnosis for, 17, 17t
etiology/pathogenesis of, 15
histopathology/immunopathology of, 16-17, 16f-17f
introduction to, 15-17, 15f-16f
overview of, O-2t-O-4t, O-5f
treatment/prognosis for, 17
Mucus extravasation phenomenon
clinical features of, 187f
differential diagnosis for, 188
etiology and pathology of, 187, 187f
histopathology of, 188, 188f
overview of, O-31f, O-35f
treatment and prognosis for, 188
Mulberry molar, 381
Multiple hamartoma syndrome, 165
Mumps
clinical features of, 192
etiology and pathogenesis of, 192
introduction to, 192
treatment and prognosis for, 192-193
MVD. *See* Microvascular decompression (MVD)
Mycobacterium leprae, 32
Mycobacterium tuberculosis, 29
Myeloma, multiple
clinical features of, 341, 342f
differential diagnosis for, 342
histopathology of, 341-342, 342f
introduction to, 341-343, 341b
lymphoid lesions as, 239-242, 240f-241f
overview of, O-51t-O-52t, O-52f
treatment and prognosis for, 342-343
Myoblastoma, granular cell. *See* Tumor, granular cell
Myoepithelial sialadenitis, 199
Myoepithelioma, 208, 208f
Myositis ossificans, 182
Myositis, proliferative, 169
Myxoma
clinical features of, 168
histopathology of, 168-169, 168t
treatment of, 169
Myxoma syndrome, 137
Myxoma, nerve sheath, 168-169
Myxoma, odontogenic
clinical features of, 282-283, 282f
differential diagnosis for, 283
histopathology of, 283, 283f
introduction to, 282, 282b
overview of, O-43t-O-45t, O-44f
treatment of, 283

N

N-RAS, 143, 169
National Cancer Database, 334
Natural killer (NK), O-6t-O-12t
NBCCS. *See* Nevoid basal cell carcinoma syndrome (NBCCS)
Neck dissection, 60-63, 64f
Neck dissection, bilateral supraomohyoid, 63, 64f
Neck dissection, comprehensive, 62-63
Neck dissection, modified radical (MRND), 62-63, 63f
Neck swelling, O-36t-O-37t
Neck, soft tissue cysts of
branchial cyst/cervical lymphoepithelial cyst as, 265-266
dermoid cysts as, 266-267
thyroglossal tract cyst as, 267-268
Neisseria gonorrhoeae, 29
Neoplasm, benign
basal cell adenoma and, 206-207
canalicular adenoma and, 207-208
ductal papilloma and, 210-211
introduction to, 203, 204b, 204t
mixed tumor and, 204-206
myoepithelioma and, 208
oncocytic tumor and, 208-210
sebaceous adenoma and, 210
Neoplasm, malignant
acinic cell carcinoma and, 218-221
adenocarcinoma not otherwise specified, 221
adenoid cystic carcinoma and, 216-218
clear cell carcinoma and, 218
introduction to, 211, 211b-212b, 212t
mucoepidermoid carcinoma and, 211-214
polymorphous low-grade adenocarcinoma and, 214-216
Neoplasm, mesenchymal, O-30t-O-31t
Neoplasms
fibrous lesions as
fibromatosis and, 170-171
fibrosarcoma and, 171-172
giant cell angiofibroma and, 168
myofibroblastic tumors and, 170
myxoma and, 168-169
nasopharyngeal angiofibroma and, 169
nodular fasciitis and, 169-170
solitary fibrous tumor and, 167-168
synovial sarcoma and, 172
intravascular lesions as
erythroplakia and, 121-122
Kaposi's sarcoma and, 122-124
lymphoid lesions as
granulocytic sarcoma and, 243
Hodgkin's lymphoma and, 238-239
leukemias and, 242-243
lymphoma and, 229
multiple myeloma/plasmacytoma and, 239-242
non-Hodgkin's lymphoma and, 229-238
Neoplasms (*Continued*)
muscle lesions as
leiomyoma/leiomyosarcoma and, 182-183
rhabdomyoma/rhabdomyosarcoma and, 183-184
of maxilla/maxillary sinus and, O-34t
reactive lesions as
granular cell tumors and, 175-177
malignant peripheral nerve sheath tumor and, 181-182
mucosal neuroma of MEN syndrome type III and, 180-181
neurofibroma and, 178-180
olfactory neuroblastoma and, 182
palisaded encapsulated neuroma and, 181
schwannoma and, 177-178
ulcerative conditions as
basal cell carcinoma of skin and, 72-73
carcinoma of maxillary sinus and, 71-72
squamous cell carcinoma of oral cavity and, 51-71
squamous cell carcinoma of skin and, 73-74
vascular lesions as
angiosarcoma and, 175
hemangiopericytoma and, 174-175
verrucal-papillary lesions as
keratoacanthoma as, 155-156
verrucous carcinoma as, 156-159
Neoplasms, plasma cell
multiple myeloma as, 341-343
solitary plasmacytoma of bone as, 343
Neurilemmoma. *See* Schwannoma
Neuroblastoma, olfactory, 182, 182f
Neurofibroma. *See also* Neurofibromatosis
clinical features of, 178-179, 178f-179f
differential diagnosis for, 180
etiology of, 178
histopathology of, 179-180, 180f
treatment of, 180
Neurofibroma, plexiform, 179
Neurofibromatosis, 178, 179f
Neuroma, neurofibroma/palisaded encapsulated, O-32t
Neuroma, palisaded encapsulated, 181, 181f
Neuroma, solitary circumscribed. *See* Neuroma, palisaded encapsulated
Neuroma, traumatic
clinical features of, 175, 175f
etiology of, 175
histopathology of, 175, 176f
treatment of, 175
Neutropenia, cyclic, 51, O-6t-O-12t
Neutrophil elastase (ELA2), 51
Nevoid basal cell carcinoma syndrome (NBCCS), 255, 258-259, 258b, 258f-259f
Nevus, 139
Nevus cell, 134
Nevus flammeus. *See* Encephalotrigeminal angiomatosis
Nevus, blue. *See* Nevus, nevomelanocytic

Nevus, compound, 140-141
Nevus, dysplastic, 141
Nevus, intramucosal, 140-141
Nevus, junctional, 140-141
Nevus, melanocytic, 139
Nevus, nevocellular, 139
Nevus, nevomelanocytic
clinical features of, 140, 140b, 140f
differential diagnosis for, 141
etiology of, 139, 140f
histopathology of, 140-141, 141f
overview of, O-24t-O-25t, O-25f
treatment of, 141
Nevus, pigmented, 139
Nevus, white sponge (WSN)
clinical features of, 80, 80b, 80f
differential diagnosis for, 80, 81t
histopathology of, 80, 81f
overview of, O-14t-O-17t
treatment of, 81
NF2 tumor suppressor gene, 138
NHL. *See* Non-Hodgkin's lymphoma (NHL)
Niacin deficiency, 125
Nicotinamide adenine dinucleotide phosphate (NADPH)-oxidase complex, 50-51
Nicotine stomatitis
clinical features of, 85, 85b, 85f-86f
etiology of, 85
histopathology of, 85, 86f
overview of, O-14f, O-14t-O-17t
papillary hyperplasia and, 152-153
treatment and prognosis for, 85-86
Nifedipine, 166
Nikolsky's sign
mucous membrane pemphigoid and, 16
pemphigus vulgaris and, O-2t-O-4t
NK. *See* Natural killer (NK)
Nocardia asteroides, 32
Nodular fasciitis
clinical features of, 169
differential diagnosis for, 169-170, 170t
histopathology of, 169, 170f
treatment of, 170
Noma
clinical features of, 34
etiology/pathogenesis of, 33-34
overview of, O-6t-O-12t
treatment of, 34
Noma neonatorum, 34
Non-Hodgkin's lymphoma (NHL)
anaplastic large cell lymphoma and, 237-238
B-cell chronic lymphocytic leukemia/small lymphocytic lymphoma and, 235-236
Burkitt's lymphoma and, 236
classification of, 229
clinical features of, 230-231, 231t, 232f-233f
diffuse B-cell lymphoma and, 233-234
eosinophil-rich CD30-positive lymphoproliferative disorder and, 238
etiology of, 230, 230t
extranodal marginal zone lymphoma and, 234-235
Non-Hodgkin's lymphoma (NHL) (*Continued*)
follicular B-cell lymphoma and, 234
introduction to, 229
lymphomas associated w/HIV infection and, 237
mantel cell lymphoma and, 235
nasofacial natural killer/T-cell lymphoma and, 238
specific lymphomas and, 230t, 232-233, 233t-234t
staging of, 230, 230b
treatment and prognosis for, 231
Nonconventional (altered) fractionation schedules, 67
Nontropical sprue, 37
Noonan-like/multiple giant cell lesion syndrome, 305
Nuclear medicine, 197
Nuclear regulatory protein, 55

O

Occult neck disease, 61-62
Ocular hypertelorism, 360
Odontalgia, atypical, 130
Odontoameloblastoma, 290
Odontodysplasia, regional, 385, 385f
Odontogenic keratocyst (OKC)
clinical features of, 255-256, 255b, 256f
differential diagnosis for, 258, 258f
etiology and pathogenesis of, 255, 255b
histopathology of, 256-257, 257b, 257f-258f
overview of, O-38t-O-42t, O-41f
treatment and prognosis for, 258-259
Odontoma, O-43t-O-45t, O-46f
clinical features of, 289-290, 289b, 290f-291f
differential diagnosis for, 290
histopathology of, 290, 291f
treatment of, 290
Odontoma, complex, 289
Odontomas, compound, 289
Ollier's disease, 336
Oncocytoma, malignant, 209
Oncogene, 54, 54b
Oral cavity SCC, 67. *See also* Squamous cell carcinoma (SCC)
Oral squamous papilloma. *See* Wart, squamous papilloma/oral
Organelles, 134
Osteitis, 314
Osteitis fibrosa cystica, 350
Osteitis, chronic. *See* Osteomyelitis, chronic
Osteitis, condensing. *See* Osteitis, focal sclerosing
Osteitis, focal sclerosing
clinical features of, 325, 325f-326f
differential diagnosis for, 325-326
etiology of, 325
histopathology of, 325
treatment of, 326
Osteoblastoma, aggressive, 300
Osteoblastoma/osteoid osteoma
clinical features of, 299-300, 300f
differential diagnosis for, 300
histopathology of, 300
Osteoblastoma/osteoid osteoma (*Continued*)
introduction to, 299, 299b
overview of, O-47t-O-49t, O-48f
treatment and prognosis for, 300
Osteochondroma, multiple, 328-329
Osteogenesis imperfecta
clinical features of, 358-359
introduction to, 358-359
treatment and prognosis for, 359
Osteoid osteoma. *See* Osteoblastoma/osteoid osteoma
Osteoma
clinical features of, 300-301
differential diagnosis for, 301
histopathology of, 301
overview of, O-47t-O-49t
treatment and prognosis for, 301
Osteoma, endosteal, 300-301
Osteomyelitis, 314
Osteomyelitis w/proliferative periostitis, chronic
clinical features of, 323-324, 323f
etiology of, 323
histopathology of, 323f, 324
treatment of, 324
Osteomyelitis, acute, O-50f
clinical features of, 318
etiology of, 318-319, 318f
histopathology of, 318
treatment of, 319
Osteomyelitis, chronic, O-50f
clinical features of, 319, 320f
etiology of, 319, 319b, 319t
osteoradionecrosis and, 319
histopathology of, 320
osteosarcoma and, 328-329
treatment of, 320
Osteomyelitis, chronic w/proliferative periostitis, 323-324
Osteomyelitis, diffuse sclerosing, 324-325
clinical features of, 324, 324f
differential diagnosis for, 325
etiology of, 324
histopathology of, 325
treatment of, 325
Osteonecrosis, 68b, 70, 70f-71f
related to metastatic disease, 322
Osteonecrosis of jaws, bisphosphonate-related
introduction to, 321-322, 321f-322f
precipitating events/risk factors for jaw disease and, 322, 322b
treatment of, 322
Osteonecrosis, bisphosphonate-related
benefits/risks of therapy and, 321
bisphosphonate description and, 320-321
dental management during therapy for, 322-323
mechanisms of action and, 321
Osteopetrosis, O-53t-O-54t, O-54f
clinical features of, 357-358, 357f
histopathology of, 358
introduction to, 356-358
treatment and prognosis for, 358
Osteopetrosis, focal periapical, 325

Osteoradionecrosis, 319
of mandible, 65-67
Osteosarcoma
clinical features of, 329-330, 329f-331f
differential diagnosis for, 332
histopathology of, 330-332, 331f-332f
introduction to, 328-335, 329b
management of, 332-335, 334f
overview of, O-51f-O-52f, O-51t-O-52t
prognosis for, 335
Osteosarcoma, central low-grade, 330-332, 333f
Osteosarcoma, fibroblastic, 330, 332f
Osteosarcoma, Juxtacortical, 335
periosteal osteosarcoma and, 336
Osteosarcoma, osteoblastic, 330
Osteosarcoma, parosteal, 335, 335f-336f
Osteosarcoma, periosteal, 300-301, 335-336
Osteosarcoma, telangiectatic, 330
Osteosarcomas, parosteal juxtacortical, 335-336
Out-in messaging, 197

P

p16 gene, 143
Paan, 109
Paget's disease
clinical features of, 347-348, 348f
histopathology of, 348-349, 349f
introduction to, 347-349, 348b
osteosarcoma and, 328-329
overview of, O-53f, O-53t-O-54t
treatment of, 349
Palatal abscess, from periapical lesion, O-34t
Palatal carcinoma, 58f
Palatal swellings, O-34t
Palate, secondary herpes simplex infection of, O-3f
Palatine cyst of newborn, 251
pANCA. *See* Antineutrophil perinuclear antibody (pANCA)
Papillary cystadenoma lymphomatosum, 209-210, 209f
Para-aminobenzoic acid (PABA), 90-91
Parkes-Weber syndrome, 117
Parotitis, juvenile variant of, 193-194
Parulis, 111, 111f, O-14t-O-17t, O-28t-O-29t
PAS. *See* Periodic acid-Schiff (PAS)
Paterson-Kelly syndrome, 52. *See also* Leukoplakia, idiopathic
Peg lateral, 373, 374f
Pemphigus vegetans, 14
Pemphigus vulgaris
clinical features of, 11, 12b, 12f-13f
differential diagnosis for, 14
etiology/pathogenesis of, 11, 12f
histopathology/immunopathology of, 11-14, 13f
overview of, O-2t-O-4t, O-5f
treatment/prognosis for, 14-15
introduction to, 14-15
systemic steroids and, 14-15, 15b
topical steroids and, 14, 14b
types of, 11-15
Penicillin, 29
Periadenitis mucosa necrotica recurrens, 38-39
Periodic acid-Schiff (PAS), 107
Perioral dermatitis, 107
PET (positron emission tomography), 60-61, 64
PET/CT scan, 61, 62f
Petechiae
clinical features of, 132, 132f
diagnosis of, 132
etiology of, 131-132
overview of, O-18t-O-22t
Peutz-Jeghers syndrome
oral melanotic macule and, 136-137, 136b, 137f
overview of, O-24t-O-25t
Phantom bone disease, 353, O-53t-O-54t
Phenytoin (Dilantin), 166
Phycomycosis, 36
Picornavirus, hand-foot-and-mouth disease and, 8
Pierre Robin sequence. *See* Pierre Robin syndrome
Pierre Robin syndrome
clinical features of, 362
etiology and pathogenesis of, 362
treatment and prognosis for, 362-363
Pigmentation, cutaneous, 68b, 69
Pigmentation, drug-induced, 145-146, 146b, 146f
Pigmentation, heavy-metal
clinical features of, 146-147, 146f
etiology of, 146
overview of, O-24t-O-25t
significance of, 147
Pigmentation, minocycline, 145-146, 146f, O-24t-O-25t
Pigmentation, postinflammatory, 135, 135f
Pigmentation, physiologic
clinical features of, 135, 135f
differential diagnosis for, 135
histopathology of, 135
overview of, O-24f, O-24t-O-25t
Pilomatrixoma, 259
Pindborg tumor. *See* Tumor, calcifying epithelial odontogenic
Pituitary adrenocorticotropic hormone (ACTH), 137
Plaque form, lichen planus, 98
Plasma cell gingivostomatitis. *See* Gingivitis, plasma cell
Plasmacytoma of bone, solitary, 343
multiple myeloma/plasmacytoma and, 239-240
Plummer-Vinson syndrome. *See also* Leukoplakia, idiopathic
anemia and, O-18t-O-22t
iron deficiency anemia and, 126
squamous cell carcinoma of oral cavity and, 52
Plunging ranula, 188
Polymorphonuclear leukocyte (PMN), 248-249
Polymorphous reticulosis, 238
Polymyalgia rheumatica, 129
Porphyria, congenital, 388
Porphyromonas gingivalis, 202
Port-wine stain. *See* Encephalotrigeminal angiomatosis
Positron emission tomography (PET). *See* PET
Post-herpetic neuralgia, 129
Prednisone, 14-15
Primary adrenocortical insufficiency. *See* Addison's disease
Primary hyperparathyroidism, 349-350
Primary Sjögren's syndrome, 196, 199
Protein, signal transduction and, 55
Pseudoanodontia, 378
Pseudocyst
clinical features of, 190
differential diagnosis for, 190
etiology and pathogenesis of, 190
histopathology of, 190
of jaws and neck
aneurysmal bone cysts as, 261-262
focal osteoporotic bone marrow defect as, 265
static bone cyst as, 264-265
traumatic bone cysts as, 263-264
treatment of, 190
Pseudosarcomatous fasciitis. *See* Nodular fasciitis
Psoriasis, O-18t-O-22t
PTCH gene, 255
Pulp calcification, 385-386, 385f
Pulp stones, 385-386
Pulp, dental
abnormalities of
external resorption and, 386-387
internal resorption and, 386
pulp calcification and, 385-386
pulpitis and, 314-315
Pulpitis
clinical and histopathologic features of, 315-316, 315t
acute pulpitis and, 315
chronic hyperplastic pulpitis and, 316
chronic pulpitis and, 315
focal reversible pulpitis and, 315
etiology of, 315
introduction to, 314
treatment and prognosis for, 316, 316f
Pulpitis, acute, 315
Pulpitis, chronic, 315
Pulpitis, chronic hyperplastic, 316
Pulpitis, focal reversible, 315
Purified protein derivative (PPD), 30
Pus, 317
PVL. *See* Leukoplakia, proliferative verrucous (PVL)
Pyostomatitis vegetans, O-26t-O-27t
clinical features of, 159-160, 159f
histopathology of, 160, 160f
introduction to, 159
treatment and prognosis for, 160

R

Radiation complications, 68-70, 68b, 69f
Radiation Therapy Oncology Group (RTOG), 67
Radiograph, dental panoramic, 64

Radiotherapy management
of squamous cell carcinoma of oral cavity
adjuvant chemotherapy with radiotherapy for, 68
adjuvant radiotherapy for, 68
clinical evaluation and staging for, 64-65
combined surgery/radiotherapy and, 68
concurrent chemotherapy for, 67-68
conventional dose-fractionation schedules for, 67
molecular targeted agents with radiation for, 68
nonconventional fractionation schedules for, 67
palliative radiotherapy for, 68
primary radiotherapy for, 65-67
prognosis for, 70-71
therapeutic radiation complications and, 68-70
Radiotherapy, adjuvant, 68
Radiotherapy, palliative, 68
Radiotherapy, primary, 65-67, 65f-66f
Radiotherapy, three-dimensional conformal (3DCRT), 65
Ranula, 187. *See also* Cyst, mucus retention
Rapid plasmin reagin (RPR), 29
RBC. *See* Red blood cell (RBC)
REAL/WHO system. *See* Revised European American Lymphoma (REAL) scheme; World Health Organization (WHO)
Red blood cell (RBC), 124
Reed-Sternberg cells, 229
Hodgkin's lymphoma and, 239
Reiter's syndrome
clinical features of, 43
diagnosis of, 43
etiology of, 43
overview of, O-6t-O-12t
treatment of, 43
Rendu-Osler-Weber syndrome. *See* Telangiectasia, hereditary hemorrhagic
Resection, 60, 61f
Rests of Malassez, 246, 247t, 280
Rests of Serres, 111
Reticular form, lichen planus, 98
Retrocuspid papilla, 163-164
Reverse smoking, 51-52, 85-86
Revised European American Lymphoma (REAL) scheme, 229t, 230
Rh incompatibility, teeth stain and, 388
Rhabdomyoma, 183-184, 183f
Rhabdomyosarcoma, 183-184, 184f
Rhizopus, 36
Rhomboid glossitis, median, O-18t-O-22t, O-21f
Riga-Fede disease, 22
Romberg's syndrome, 366
Roots, supernumerary, 377
RTOG. *See* Radiation Therapy Oncology Group (RTOG)
RTOG/Intergroup, 68
Rubella. *See* German measles
Rushton bodies, 249
Russell bodies, 248-249
Rye system, 239

S

S. schenckii. *See Sporothrix schenckii*
Saber shin, 28
Sabouraud agar, 36
Saddle nose, 28
Salivary gland diseases
benign neoplasms as, 203-211
infectious sialadenitis as, 192-203
malignant neoplasms as, 211-221
rare tumors as, 221-223
reactive lesions as, 187-192
Sanguinaria, 89, 89f. *See also* Slough, dentifrice-associated
Sarcoidosis
clinical features of, 194-195, 195b
diagnosis of, 195
etiology of, 194, 194b
histopathology of, 195, 195f
treatment and prognosis for, 195
Sarcoma, granulocytic, 243, 244f
Sarcoma, pleomorphic. *See* Fibrous histiocytoma, malignant (MFH)
Sarcoma, synovial (SS), 172
Scarlet fever, 120-121, O-18t-O-22t
SCC. *See* Squamous cell carcinoma (SCC)
Schaumann body, 195
Schwannoma
clinical features of, 178, 178t
etiology of, 177
histopathology of, 178, 178f
treatment of, 178
Scleroderma
clinical features of, 199-200, 199f-200f
introduction to, 199
treatment of, 200
Sclerotic bone. *See* Osteitis, focal sclerosing
Selective neck dissection, 63, 63f
Selective serotonin reuptake inhibitor (SSRI), 128
Sexually transmitted disease (STD), Reiter's syndrome and, O-6t-O-12t
Shingles. *See* Varicella-zoster virus (VZV) infection
Sialadenitis, bacterial
clinical features of, 193
etiology and pathogenesis of, 193
treatment and prognosis for, 193-194
Sialadenitis, cytomegaloviral, 193
Sialadenitis, infectious
bacterial sialadenitis and, 193-194
cytomegaloviral sialadenitis and, 193
halitosis and, 202-203
metabolic conditions and, 195-196
mumps and, 192-193
salivary lymphoepithelial lesion and, 199
sarcoidosis and, 194-195
scleroderma and, 199-200
Sjögren's syndrome and, 196-199
taste disturbances and, 201-202
xerostomia and, 200-201
Sialadenitis, obstructive. *See* Cyst, mucus retention
Sialadenitis, subacute necrotizing, 192
Sialadenitis, submandibular gland, 192
Sialadenoma papilliferum, 210, 210f
Sialadenosis, 195
Sialolith, 188, 188b, 190f
Sialometaplasia, necrotizing, 25
clinical features of, 191, 191f
differential diagnosis for, 192
etiology and pathogenesis of, 191
histopathology of, 191-192, 191f
introduction to, 191, 191b
treatment and prognosis for, 192
Sialosis, 195
Sinus thrombosis, cavernous, 318
Sinusitis, 71-72
Sjögren's syndrome
clinical features of, 197-198, 197f, 198b
diagnosis of, 198
etiology of, 196-197
histopathology of, 198, 198f
introduction to, 196, 196b
parotid lesion and, O-36t-O-37t
treatment of, 199
Sjögren's syndrome, secondary, 196, 198b
Skin tag, 353-354
Skin, radiation treatment and, 69
SLE. *See* Systemic lupus erythematosus (SLE)
Slough, dentifrice-associated, 89, 89f, O-14t-O-17t
Smokeless tobacco
oral cancer and, 52
white lesions associated with
clinical features of, 84-85, 84b, 84f
etiology of, 84
histopathology of, 85, 85f
introduction to, 83-84
treatment and prognosis for, 85
Smoker's melanosis. *See* Smoking-associated melanosis
Smoking, tobacco, 51-52
Smoking-associated melanosis
clinical features of, 135, 136f
differential diagnosis for, 136, 136b
etiology and pathogenesis of, 135
histopathology of, 135-136
treatment of, 136
Snuff, 52, 84
Snus, 83
Solar cheilitis. *See* Actinic cheilitis
Solar keratoses. *See* Actinic keratoses
Sonic hedgehog (SHH) pathway, 271
Sporothrix schenckii, 36
Sporotrichosis
clinical features of, 36
diagnosis of, 36
etiology/pathology of, 36
histopathology of, 36
treatment of, 36
Squamous cell carcinoma (SCC), 281f
of buccal mucosa, 57-58
of floor of mouth, 31f, 57, 57f-58f
of gingiva, 57-58, 58f, O-13f
of lips, 56, 56f

Squamous cell carcinoma (SCC) (*Continued*)
of oral cavity
clinical features of, 56-58
differential diagnosis for, 60
etiology of, 51-52
histopathology of, 58-60, 59f-60f
introduction to, 51, 51f
overview of, O-6t-O-12t
pathogenesis of, 52-56, 53f-55f, 54b
prognosis for, 70-71
radiotherapy management of, 64-71
surgical management of, 60-64, 61f
of palate, 58, 58f-59f
of salivary glands, 223
of the skin
clinical features of, 74, 74f
histopathology of, 74
introduction to, 73
treatment of, 74
of tongue, 56-57, 56f-57f
SSRI. *See* Selective serotonin reuptake inhibitor (SSRI)
Stafne's bone defect. *See* Cyst, static bone
Stage, as prognosis indicator, 70
Stapedial artery dysfunction, 361
STD. *See* Sexually transmitted disease (STD)
Stevens-Johnson syndrome, 44-45
Stomatitis, antibiotic, 106
Stomatitis, chronic ulcerative, 41-42, 41f
Strawberry gingivitis, 49
Strawberry nevus. *See* Hemangioma, congenital
Streptococcal infection, scarlet fever and, 120-121
Streptococcus sanguis, 37
Sturge-Weber syndrome. *See also* Encephalotrigeminal angiomatosis
congenital hemangiomas and, O-18t-O-22t
Subacute lupus, 102
Sulfur granules, 32-33
Sun exposure, 72
Surgery-radiotherapy, combined, 68
Sutton's disease, 38-39
Swelling, floor-of-mouth, O-30t
Swelling, gingival, O-28t-O-29t
Swellings, submucosal
floor-of-mouth and, O-30t
gingival and, O-28t-O-29t
lip and buccal mucosal and, O-31t
neck and, O-36t-O-37t
palatal and, O-34t
tongue and, O-32t
Syndrome of inappropriate secretion of antidiuretic hormone (SIADH), 63
Syphilis
clinical features of, 27-28, 27b, 27f-28f
condyloma latum and, 153
differential diagnosis for, 28-29
etiology/pathogenesis of, 26-27, 26f, 27b
histopathology of, 28
overview of, O-6t-O-12t
treatment of, 29
Syphilis, congenital, 27
Systemic lupus erythematosus (SLE), 102-104, 103f
Systemic scleroderma, 199

T

T. pallidum. *See Treponema pallidum (T. pallidum)*
Taste disturbances, 201, 202b
Taurodontism, 376-377, 377f
TB. *See* Tuberculosis (TB)
TCA. *See* Tricyclic antidepressant (TCA)
Technetium (^{99m}Tc) scan, 353
Teeth, abnormalities of
alterations in color as, 387-388
alterations in number as, 378-380
alterations in shape as, 374-378
alterations in size as, 373
defects of dentin as, 383-385
defects of enamel and dentin as, 385
defects of enamel as, 380-383
Teeth, hereditary conditions of, 382t
Teeth, natal, 379
Teeth, neonatal, 379
Teeth, shell, 383
Teeth, supernumerary, 379-380, 379f
Telangiectasia, hereditary hemorrhagic (HHT), 117, 117f
congenital hemangiomas and, O-18t-O-22t
Telangiectasias, 68b, 69, 69f
Telomeres, 55-56
Temporal arteritis. *See* Giant cell arteritis
Tenascin, 55
Tetracycline stain, 388, 388f
TGF-α. *See* Transforming growth factor-alpha (TGF-α)
Thalidomide, 32
Thayer-Martin medium, 29
Thermal burn, 108
Thrush. *See* Acute candidiasis (thrush)
Thyroid gland, hyperthyroidism and, 351
Thyrotoxicosis, 351
Tine skin test, 30
TNM. *See* Tumor, node, metastasis (TNM)
Tobacco, 109
Tongue swellings, O-32t
Tongue, geographic
clinical features of, 95-96, 95b, 96f
differential diagnosis for, 96-97
etiology of, 95
histopathology of, 96, 96f
overview of, O-14t-O-22t, O-15f, O-21f
treatment and prognosis for, 97
Tongue, hairy, O-14t-O-17t
clinical features of, 88, 88f, 89b
diagnosis of, 89
etiology of, 88
histopathology of, 89
introduction to, 88-89
treatment and prognosis for, 89
Tonsil, oral, 226-227
Tooth color, alterations in
endogenous stains and, 387-388
exogenous stains and, 387
Toothache, 71-72
Tori
clinical features of, 310-311
exostosis and, 311
torus mandibularis and, 310-311
torus palatinus and, 310
etiology and pathogenesis of, 310
histopathology of, 311
overview of, O-47t-O-49t, O-49f
treatment and prognosis for, 311
Torus mandibularis, 310-311, 311f
Torus palatinus, 310, 310f
Total iron-binding capacity (TIBC), 126
Transcutaneous electric nerve stimulation (TENS), 129
Transforming growth factor-alpha (TGF-α), 53-54
Treacher Collins syndrome
clinical findings for, 362
etiology and pathogenesis of, 361-362
introduction to, 361-362, 361f
treatment and prognosis for, 362
Treponema pallidum (T. pallidum), 26f
environmental defects of enamel and, 381
syphilis and, 26-27
Tricyclic antidepressant (TCA), 128
Trigeminal neuralgia, 128-129
Trisomy 21. *See* Down syndrome
True denticles, 385-386
Tuberculosis (TB)
clinical features of, 30-31, 30b, 31f
differential diagnosis for, 31
etiology/pathogenesis of, 29-30, 30f
histopathology of, 31, 31f
of the palate, O-7f
overview of, O-6t-O-12t
treatment of, 31-32
Tumor
of salivary gland, O-30t-O-32t, O-34t
of thyroid gland, O-36t-O-37t
Tumor of infancy, neuroectodermal, O-24t-O-25t
Tumor of infancy, pigmented neuroectodermal
clinical features of, 139, 139f
differential diagnosis for, 139
etiology of, 138-139
histopathology of, 139, 139f
treatment and prognosis for, 139
Tumor suppressor gene, 54, 54b
Tumor, adenomatoid odontogenic (AOT)
clinical features of, 279, 279f-280f
differential diagnosis for, 280
histopathology of, 280, 280f-281f
introduction to, 279, 279b
overview of, O-43t-O-45t, O-44f
treatment of, 280
Tumor, benign nonodontogenic, O-47t-O-49t
Tumor, biphasic, 172
Tumor, calcifying epithelial odontogenic (CEOT)
clinical features of, 277-278, 278f
differential diagnosis for, 278
histopathology of, 278, 278f-279f

Tumor, calcifying epithelial odontogenic (CEOT) (*Continued*)
introduction to, 277, 277b
treatment of, 279
Tumor, carcinoma ex-mixed, 206, 221-222, 222f
Tumor, carotid body, O-36t-O-37t
Tumor, clear cell odontogenic, 280-281, 281b, 281f, O-43t-O-45t
Tumor, congenital gingival granular cell, 176, 176b, 177f
Tumor, dermal analog. *See* Adenoma, membranous basal cell
Tumor, extramedullary myeloid. *See* Sarcoma, granulocytic
Tumor, fibrohistiocytic
benign fibrous histiocytoma and, 173
introduction to, 172-173
malignant fibrous histiocytoma and, 173
Tumor, ghost cell odontogenic, 259
Tumor, giant cell, 306, 306f
Tumor, granular cell
clinical features of, 176, 176b, 176f
differential diagnosis for, 177
etiology of, 175-176
histopathology of, 176-177, 177f
overview of, O-33f
treatment of, 177
Tumor, keratocystic odontogenic (KCOT). *See* Odontogenic keratocyst (OKC)
Tumor, malignant mixed, 221-222
Tumor, malignant peripheral nerve sheath (MPNST), 178-179, 181-182
Tumor, mesenchymal
cementifying fibroma as, 284
cementoblastoma as, 284-285
central odontogenic fibroma as, 283-284
odontogenic myxoma as, 282-283
periapical cemento-osseous dysplasia as, 285-287
Tumor, metastasizing mixed, 221-222
Tumor, mixed
clinical features of, 204-205, 204b, 204f
histopathology of, 205, 205f
introduction to, 204
overview of, O-35f
treatment and prognosis for, 205-206
Tumor, mixed odontogenic. *See* Odontoma
Tumor, monophasic, 172
Tumor, node, metastasis (TNM) system, 70, 71b, 71f, 71t
Tumor, odontogenic, O-43t-O-45t
Tumor, odontogenic calcifying epithelial, O-43t-O-45t
Tumor, oncocytic
oncocytoma and, 208-209, 208f
papillary cystadenoma lymphomatosum and, 209-210
Tumor, pregnancy, 118
Tumor, primitive neuroectodermal (PNET), 318. *See also* Ewing's sarcoma
Tumor, rare
basal cell adenocarcinoma and, 223
carcinoma ex-mixed tumor/malignant mixed tumor/metastasizing mixed tumor, 221-222
squamous cell carcinoma and, 223
Tumor, salivary gland, O-30t
Tumor, solitary fibrous, 167-168, 167b, 168f
Tumor, squamous odontogenic, 280, O-43t-O-45t
Tumors, benign nonodontogenic
cemento-osseous dysplasia as, 299
central giant cell granuloma as, 303-306
chondroma as, 302-303
coronoid hyperplasia as, 311-312
desmoplastic fibroma as, 301-302
fibrous dysplasia as, 296-299
giant cell tumor as, 306
hemangioma of bone as, 306-307
Langerhans cell disease as, 307-310
ossifying fibroma as, 294-296
osteoblastoma/osteoid osteoma as, 299-300
osteoma as, 300-301
tori and exostoses as, 310-311
Tumors, epithelial
adenomatoid odontogenic tumor as, 279-280
ameloblastoma as, 270-277
calcifying epithelial odontogenic tumor as, 277-279
clear cell odontogenic tumor as, 280-281
squamous odontogenic tumor as, 280
Tumors, mixed (epithelial/mesenchymal)
ameloblastic fibroma/ameloblastic fibro-odontoma tumors as, 287-289
odontoma as, 289-290
Tumors, myofibroblastic
clinical features of, 170
histopathology of, 170, 171f
treatment of, 173-175
Tumors, odontogenic
epithelial tumor as, 270-281
introduction to, 270, 271b
mesenchymal tumor as, 282-287
mixed tumor as, 287-290
Turner's tooth, 380, 381f
Tzanck cell, 11-12

U

Ulcer, acute, O-7f
Ulcer, chronic traumatic, O-7f
Ulcer, definition of, 22
Ulcer, herpetiform aphthous, 39, 40f
Ulceration, traumatic
clinical features of, 23-25, 23b, 23f-24f
diagnosis of, 25-26
etiology of, 22-23
histopathology of, 25, 25f
treatment of, 26
Ulcerative conditions
bacterial infections and, 26-34
fungal infections and, 34-37
immunologic diseases and, 37-51
neoplasms and, 51-74
overview of, O-6t-O-12t
reactive lesions and, 22-26
Ultraviolet B. *See* UVB light
Ultraviolet light. *See* UV light
Urinary monoclonal light chain, 341
UV light
actinic cheilitis and, O-14t-O-17t
as carcinogenic agent, 52
congenital hemangiomas and, O-18t-O-22t
cutaneous melanoma and, 141-142
melanoma and, O-24t-O-25t
squamous cell carcinoma of oral cavity and, O-6t-O-12t
UVB light
actinic cheilitis and, 90, O-14t-O-17t
as carcinogenic agent, 52
Uveoparotid fever, 194

V

Valacyclovir, primary genital herpes treatment and, 6
Valley fever. *See* Coccidioidomycosis
Vanishing bone disease. *See* Phantom bone disease
Varicella. *See also* Sexually transmitted disease (STD); Varicella-zoster virus (VZV) infection
overview of, O-2t-O-4t
Varicella-zoster virus (VZV) infection
clinical features of
herpes zoster and, 7, 8f
varicella and, 7, 7f
differential diagnosis for, 8
histopathology of, 7-8
introduction to, 6-8, 6b
pathogenesis of
herpes zoster and, 7
varicella and, 6-7
treatment of, 8
Varix, 118, 118f
Vascular endothelial growth factor (VEGF), 55
Vascular leiomyoma, 183
Vascular malformation, acquired, 118, 118f
Vascular malformation, congenital
clinical features of, 114-115, 116f
diagnosis of, 115
etiology of, 114, 115t
histopathology of, 115
overview of, O-18t-O-22t, O-19f
treatment of, 115
Veau system, of cleft deformities, 368-369
VEGF. *See* Vascular endothelial growth factor (VEGF)
Venereal Disease Research Laboratory test (VDRL), 29
Venous varix. *See* Varix
Vermilion, 90
Verruca vulgaris, oral, O-26t-O-27t
Verruciform xanthoma
clinical features of, 160
differential diagnosis for, 161
histopathology of, 160, 160f
introduction to, 160
overview of, O-26t-O-27t
treatment of, 161
Vesiculobullous disease
hereditary disease and, 19-20
immunologic disease and, 11-19

Vesiculobullous disease (*Continued*)
introduction to, O-2t-O-4t
viral disease and, 1-11
Vincent's infection. *See* ANUG (acute necrotizing ulcerative gingivitis)
Viral disease
hand-foot-mouth disease and, 8-9
herpangina and, 10
herpes simplex infection and, 1-6
introduction to, 1-11, 2t
measles and, 10-11
varicella-zoster infection and, 6-8
Viral shedding, 3
Vitamin A analog, 102
Vitamin B deficiency
burning mouth syndrome and, 126
clinical features of, 125, 125f
diagnosis/treatment of, 125
etiology of, 124-125
overview of, O-18t-O-22t, O-21f
Vitamin B_{12}. *See* Anemia, pernicious
Vitamin D_3, 349-350
von Recklinghausen's disease of skin. *See* Neurofibromatosis

W

Waldeyer's ring, 229-230
Wart, dysplastic oral, 151, 151b, 152f
Wart, squamous papilloma/oral
clinical features of, 150b, 150f
etiology of, 149-150
histopathology of, 150-151, 151f
introduction to, 149, 150t
overview of, O-26f, O-26t-O-27t
treatment and prognosis for, 151-152
Warthin's tumor. *See also* Papillary cystadenoma lymphomatosum
parotid lesion and, O-36t-O-37t
Wegener's granulomatosis, 238
clinical features of, 49, 49f
diagnosis of, 49-50
etiology of, 49
Wegener's granulomatosis (*Continued*)
histopathology of, 49, 50f, 50t
overview of, O-6t-O-12t
treatment of, 50
Wickham's striae, 98
Witkop's disease. *See* Hereditary benign intraepithelial dyskeratosis (HBID)
World Health Organization (WHO), non-Hodgkin's lymphoma classification and, 230
WSN. *See* Nevus, white sponge (WSN)

X

Xanthoma cell, 160
Xerostomia, 68b, 69, 196
burning mouth syndrome and, 126
clinical features of, 201
etiology of, 200-201, 200b
treatment of, 201, 201b

Z

Ziehl-Neelsen stain, 29, 31