NINTH EDITION

WOELFEL'S Dental Anatomy

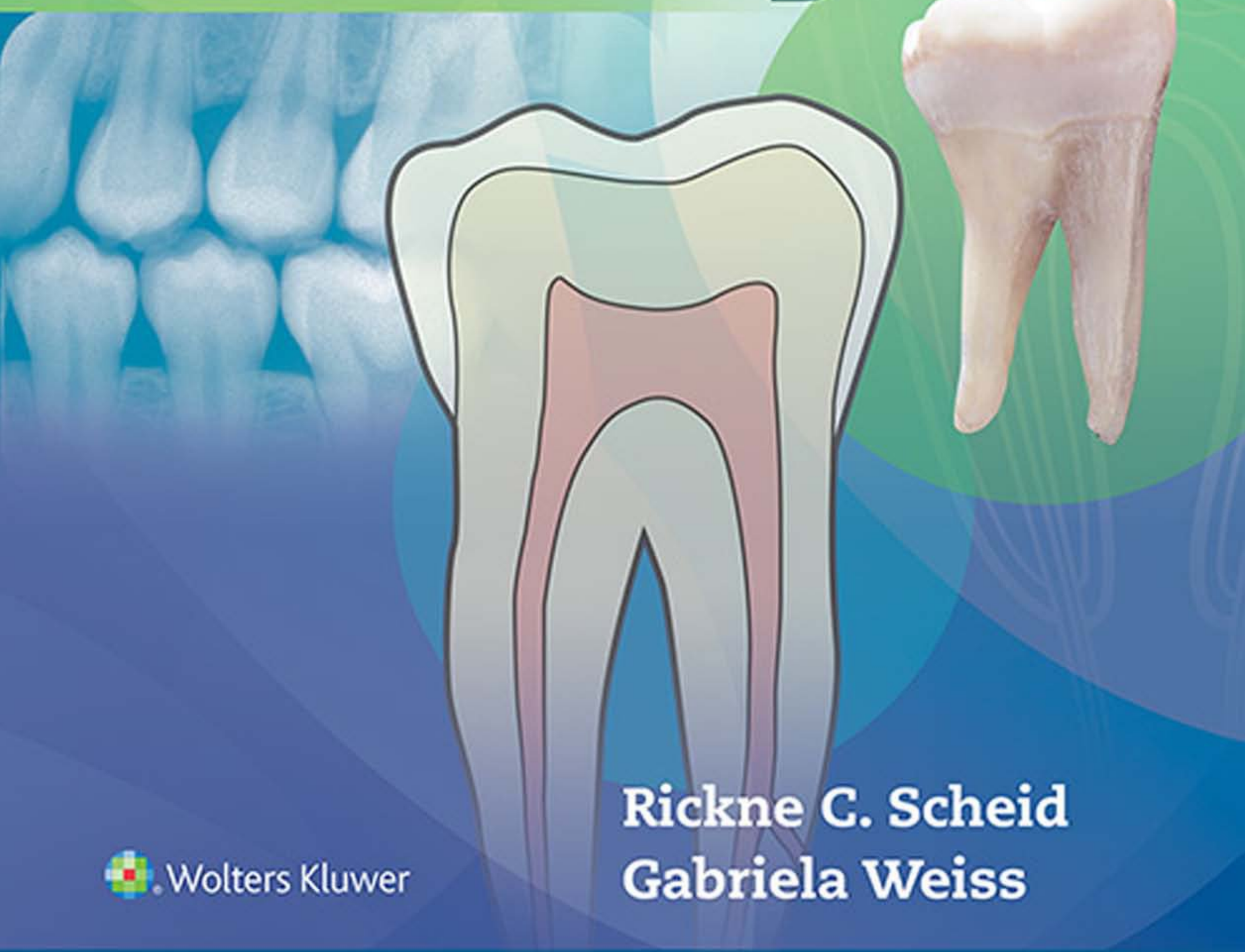

Rickne C. Scheid
Gabriela Weiss

Wolters Kluwer

WOELFEL'S

Dental Anatomy

NINTH EDITION

WOELFEL'S

Dental Anatomy



NINTH EDITION

Rickne C. Scheid, DDS, MEd

Associate Professor Emeritus
The Ohio State University College of Dentistry
Columbus, Ohio

Gabriela Weiss, DDS

Associate Professor
The Ohio State University College of Dentistry
Columbus, Ohio

Wolters Kluwer

Philadelphia • Baltimore • New York • London
Buenos Aires • Hong Kong • Sydney • Tokyo

Acquisitions Editor: Jonathan Joyce
Product Development Editor: John Larkin
Editorial Assistant: Tish Rogers
Marketing Manager: Leah T omson
Production Project Manager: David Saltzberg
Design Coordinator: Steve Druding
Manufacturing Coordinator: Margie Orzech
Prepress Vendor: SPi Global

Ninth Edition

Copyright © 2017 Wolters Kluwer

Copyright © 1998, 2002, 2008, 2012 Wolters Kluwer Health / Lippincott Williams & Wilkins. All rights reserved. T is book is protected by copyright. No part of this book may be reproduced or transmitted in any form or by any means, including as photocopies or scanned-in or other electronic copies, or utilized by any information storage and retrieval system without written permission from the copyright owner, except for brief quotations embodied in critical articles and reviews. Materials appearing in this book prepared by individuals as part of their official duties as U.S. government employees are not covered by the above-mentioned copyright. To request permission, please contact Wolters Kluwer at Two Commerce Square, 2001 Market Street, Philadelphia, PA 19103, via email at permissions@lww.com, or via our website at lww.com (products and services).

9 8 7 6 5 4 3 2 1

Printed in China (or the United States of America)

Library of Congress Cataloging-in-Publication Data
Names: Scheid, Rickne C., author. | Weiss, Gabriela (Gabriela Alejandra), author.
Title: Woelfel's dental anatomy / Rickne C. Scheid, Gabriela Weiss.
Other titles: Dental anatomy
Description: Ninth edition. | Philadelphia : Wolters Kluwer, [2016] | Includes bibliographical references and index.
Identifiers: LCCN 2015038917 | ISBN 9781496320223 (paperback)
Subjects: | MESH: Tooth—anatomy & histology—Outlines. | Jaw—anatomy & histology—Outlines. | Mouth—anatomy & histology—Outlines.
Classification: LCC QM311 | NLM WU 18.2 | DDC 611/.314—dc23 LC record available at http://lccn.loc.gov/2015038917

T is work is provided "as is," and the publisher disclaims any and all warranties, express or implied, including any warranties as to accuracy, comprehensiveness, or currency of the content of this work.

T is work is no substitute for individual patient assessment based upon healthcare professionals' examination of each patient and consideration of, among other things, age, weight, gender, current or prior medical conditions, medication history, laboratory data and other factors unique to the patient. T e publisher does not provide medical advice or guidance and this work is merely a reference tool. Healthcare professionals, and not the publisher, are solely responsible for the use of this work including all medical judgments and for any resulting diagnosis and treatments.

Given continuous, rapid advances in medical science and health information, independent professional verification of medical diagnoses, indications, appropriate pharmaceutical selections and dosages, and treatment options should be made and healthcare professionals should consult a variety of sources. When prescribing medication, healthcare professionals are advised to consult the product information sheet (the manufacturer's package insert) accompanying each drug to verify, among other things, conditions of use, warnings and side effects and identify any changes in dosage schedule or contraindications, particularly if the medication to be administered is new, infrequently used or has a narrow therapeutic range. To the maximum extent permitted under applicable law, no responsibility is assumed by the publisher for any injury and/or damage to persons or property, as a matter of products liability, negligence law or otherwise, or from any reference to or use by any person of this work.

LWW.com

About the Authors

Rickne c. Scheid, ddS, Med



Dr. Rickne Scheid received his DDS in 1972 at T e Ohio State University and was inducted into the dental honorary fraternity, Omicron Kappa Upsilon. After serving in the U.S. Navy Dental Corps, he practiced part-time practice and taught at his alma mater from 1974 until 2006 when he retired with Emeriti status. His appointments at the College of Dentistry were in the Division of Dental Hygiene, the Section of Restorative and Prosthetic Dentistry, and the Section of Primary Care. While teaching, he earned his Masters in Education with honors in 1980. T roughout his teaching career, he authored or coauthored nearly 50 scientific papers and abstracts and developed and directed 12 courses, including the Dental Anatomy course. He directed this course for 10 years, lecturing to both dental and dental hygiene students. Further, he helped develop and annually co-direct numerous continuing education courses including a review course for dental hygienists returning to practice, a dental anatomy review course for dentists and dental auxiliaries, and an expanded functions course for dental auxiliaries. He was inducted into the dental hygiene honorary, Sigma Phi Alpha, in 1989 and has received numerous dental and dental hygiene student teaching awards as well as the peer-evaluated Postle Teaching Award in 1996. In retirement, he has presented continuing education courses at the university and has served as an evaluator for the Commission on Dental Testing for Expanded Functions Dental Auxiliaries in Ohio.

Gabriela Weiss, ddS



Dr. Gabriela Weiss received her DDS in 1986 from the National University of Tucuman, Argentina, where she graduated as Valedictorian. After graduation, she completed a clinical fellowship in Occlusion and Oral Rehabilitation in Argentina. T e following year she was awarded the F.A.M.U., an honor given to the Outstanding Professional Female. In 1988, she moved to California in the United States where she worked in a private practice. T en, in 1994, she moved to Michigan to pursue her passion for teaching at the University of Michigan Dental School where she taught Operative and Prosthetic Dentistry courses and became director of Dental Anatomy and Occlusion. She continued teaching these courses and directing dental anatomy at two other dental schools, first at University of Pittsburgh and later at T e Ohio State University College of Dentistry where she is currently an Associate Professor. She recently developed a course designed to improve the hand skills of prospective dental students. Students have recognized her passion and talent for teaching by presenting her with 14 Student Government Teaching Awards over the years.

Reviewers

- Nancy Andrews, RDH, BSHRP, MEd, Assistant Professor, William Rainey Harper College, Palatine, Illinois
- Kimberly Beistle, PhD, RDH, CDA, Program Coordinator, Professor, Dental Hygiene and Medical Imaging, Ferris State University, Big Rapids, Michigan
- Amy Booth, CDA, RDH, MEd, School of Dental Hygiene, Quinsigamond Community College, Worcester, Massachusetts
- Lynn Ann Bryan, BSDH, RDH, MEd, Clinical Associate Professor, School of Dentistry, Marquette University, Milwaukee, Wisconsin
- Joanna Campbell, RDH, MA, MA, Associate Professor, Health Professions Division, Dental Hygiene, Bergen Community College, Paramus, New Jersey
- Alison Collins, CDA, MS, Director, Dental Assistant Program, Northwestern Michigan College, Traverse City, Michigan
- Daniel Collins, DDS, Instructor, Allied Health Professions, Dental Hygiene Program, Columbus State Community College, Columbus, Ohio
- Deborah Corning-Hamilton, RDH, Ontario Dental Education Institute, Ancaster, Ontario, Canada
- Michelle Cummins, RDH, BSDH, Faculty Instructor, Department of Health Professions, Lane Community College, Eugene, Oregon
- Pam Davidson, RDH, MEd, Executive Director, Dental Hygiene Program, University of Arkansas–Fort Smith, Fort Smith, Arkansas
- Indu Dhir, AAS, BS, RDH, MS, Dip Dist Educ, Program Director, Canadian Academy of Dental Hygiene, Mississauga, Ontario, Canada
- Ann Dickinson, CDA, RDH, BS, MS, School of Dental Hygiene, Remington College, Nashville, Tennessee
- Candida Ditzler, CDA, RDA BBA, Dental Assistant Program Coordinator/instructor, Cape May County Technical School, Cape May, New Jersey
- Eric Dixon, DMD, Dental Assisting and Dental Hygiene Integrated Program, Big Sandy Community and Technical College, Prestonsburg, Kentucky
- Donna Eastabrooks, CDA, RDH, MA, PhD, College of Heath Science & Public Health, Dental Hygiene, Eastern Washington University, Cheney, Washington
- Cinda Fife, LDH, BGS, Clinical Assistant Professor, Dental Education, College of Health and Human Services, Indiana University Northwest, Gary, Indiana
- Tammy Fisher, RDH, BS, Concorde Career College, Dallas, Texas,
- Deborah Holexa, RDH, BS, MAEd, Dental Hygiene Program Director, Mesa Community College, Mesa, Arizona
- T eresa Roma Jasinevicius, DDS, MEd, Associate Professor, School of Dental Medicine, Case Western Reserve University, Cleveland, Ohio
- Marlaina Lantzy, RDH, BAS, MSDH, Instructor, Dental Programs Department, Hagerstown Community College, Hagerstown, Maryland
- Judith E. Romano-DiLorenzo, RDH, BS, MA, Department Chair, Dental Hygiene Program, Hudson Valley Community College, Rochester, New York
- Jose Vivas, DDS, Clinical Associate Professor, School of Dentistry, University Of Michigan, Ann Arbor, Michigan

Preface to the Ninth Edition

Woelfel's Dental Anatomy is primarily intended as a study guide for dental students, dental hygiene students, dental assistants, and dental laboratory technicians as they master the details of tooth morphology and their usefulness in the dental office. The book provides dental and dental hygiene students with basic knowledge required when answering dental anatomy questions on the national board examinations, but it goes well beyond by discussing the application of tooth morphology and terminology as it relates to the practice of dentistry. Five chapters provide an introductory overview to periodontics, endodontics, occlusion, restorative dentistry, and forensic dentistry. The book with its Power Point lecture slides and test items for teachers and its many learning exercises was designed for instructors of dental anatomy courses as a teaching manual during lectures, discussion periods, and laboratory sessions, as well as during early clinical experiences. It is also useful as a reference in the dental office.

New in This Edition

Over 120 new color illustrations were added in this edition, especially in the first six chapters where unique traits of each type of each tooth are best learned by visualizing multiple examples of teeth from different views. Further, to facilitate learning, many existing illustrations were reorganized and improved by adding new labels, arrows, color highlights, and tooth numbers.

Chapters that provide the introduction to the specialty areas of dentistry were updated to include the most current terminology and new topics including the description of healthy tissues surrounding dental implants. The chapter on forensic dentistry was expanded to include more current examples of the relevance of forensic dentistry. Further, several new examples of anomalies were added, as well as several new anatomical structures of the head including the location and clinical relevance of paranasal sinuses.

Finally, the authors developed numerous critical thinking exercises that require the learner to search the Internet for specific images and answer questions that serve to expand the learner's appreciation of topics covered within the book.

book Features

The book is organized into three parts. Part I, **Comparative Tooth Anatomy**, includes six chapters. The first chapter begins with an introduction to terminology and concepts related to tooth morphology that provides the foundation for the next four chapters on adult tooth traits. In these chapters, the authors present similarities and differences using drawings, photographs, and many summary tables. Primary teeth and their eruption patterns are discussed in Chapter 6.

Part II, **Application of Tooth Anatomy in Dental Practice**, has seven chapters. The first two chapters include a discussion of roots of the adult teeth related to the external surfaces and supporting tissues involved in periodontal therapy and the internal anatomy of the roots involved in endodontic therapy. Other chapters include a contemporary overview of ideal occlusion, operative and restorative dentistry, and forensic dentistry. Finally, there is an extensive discussion about many commonly encountered dental anomalies as well as a chapter designed to help students draw, carve, and sketch teeth.

Part III, **Anatomical Structures of the Oral Cavity**, includes two chapters. One chapter presents the relationship of the teeth to landmarks of the skull, the temporomandibular joints, and the muscles, nerves, blood supply, and lymph drainage associated with the oral cavity. The other chapter includes a description of normal oral structures observed during a head and neck cancer screening examination and shows sites for injections for local anesthetic relative to the underlying nerve locations.

Each chapter includes methods designed to help you, the reader, master the content, and put it to practice immediately.

- **Topic list:** Each chapter begins with a list of topics presented in the same order as the sections within that chapter.
- **Learning objectives:** In each chapter, learning objectives are presented to help you appreciate what you can expect to learn as you read and that you can reference after you study to ensure that you have mastered the specified knowledge and skills.
- **New terms:** As each new term is encountered for the first time, it is highlighted in **bold print** and is defined within the text at that time, often with references to figures, diagrams, and tables to improve understanding. The bold print is helpful when searching for important terms that are listed alphabetically in the index at the end of the book.
- **Glossary:** New in this edition is an extensive glossary providing brief definitions of all important terms presented in this edition. However, many terms in dentistry are best appreciated by referring to illustrations or photographs for a complete understanding. Terms in the index include the page where you can find the term (in bold) along with its definition, and often, a reference to an associated illustration for the best learning.
- **Pronunciations:** New terms that may be difficult to pronounce have phonetic suggestions placed within brackets [like this] immediately after the word is first encountered.
- **Review questions with answers:** Many chapters or sections end with a series of review questions to test the learner's mastery of the objectives. These questions, in

many cases, cover concepts similar to those included on past dental and dental hygiene national examinations. For the convenience of quick and convenient feedback, the answers are presented immediately following the questions.

- **Learning exercises:** Most chapters include a number of learning exercises. T ese exercises are presented at intervals where the authors feel an active learning experience would be helpful for you to understand and/or apply the topic. T ese exercises may suggest that you examine extracted teeth or tooth models, or skulls (or skull models), or perform specific self- or partner examinations. New in this edition are many guided searches on the Internet designed to expose the learner to many examples of concepts discussed in that chapter. More advanced exercises (as in Chapter 13) provide methods for drawing and sketching teeth, and carving teeth from wax, thus helping you to become intimately familiar with tooth shape and terminology.
- **Summary tables:** T roughout the text, the authors have included numerous tables to summarize the many facts presented within the text. T ese tables are helpful when reviewing the highlights of content found within each section.
- **Original illustrations and drawings:** For complete understanding and clinical application of each topic, the authors have included a variety of photographs, illustrations, and original colorized drawings selected and designed to illustrate key points and improve learning. Over 120 new color illustrations have been added to this edition. Also, on thePoint® companion Web site, there is an image bank for instructors containing all of the illustrations and drawings in the text that can be used when lecturing.
- **Appendix of comparative dental anatomy:** T is text's unique Appendix is designed to help the learner visualize the many tooth similarities and differences that are often difficult to understand with words alone. Each adult tooth class is referenced on two separate appendix pages. T e first page includes traits (each trait is identified with a different letter) that are common to all teeth within that class. T e second page is devoted to the differences (each identified with a letter) between the types of teeth within each class and differences between teeth in each arch. In addition, two appendix pages illustrate the unique characteristics of anterior and posterior primary teeth. T e layout on these pages makes it easy to compare the differences between teeth because views of each tooth type are lined up on the same page next to other teeth in that class. As each tooth characteristic is described within the chapters on tooth morphology (Chapters 1 to 6), reference is frequently made to the illustrated representation of that characteristic on an appendix page as follows: T e word "Appendix" is followed by the page number and letter denoting items being discussed (e.g., "Appendix 1a" refers you to the Appendix, page 1, item "a"). T e authors recommend that you copy each Appendix page (front and back sides) or print out these pages from the online source thePoint® provided for this book, and place them in a separate loose-leaf notebook to facilitate study and minimize page turns as you read chapters two through six. When used in this fashion, these pages provide you with increased convenience (since fewer page turns are required when referencing all of the tooth characteristics within each chapter), easier learning (since the complex terminology used to describe each characteristic is best learned by visualizing that characteristic and comparing it to other similar teeth), and a separate study guide (since all lettered traits for each type of tooth are described on the back of each appendix page).
- **Research data:** T is text is unique since it includes both original and reviewed research findings based on the study of thousands of teeth, casts, and mouths. Information on crown and root dimensions was obtained from measurements of a convenient sample of 4572 teeth extracted by Ohio dentists and studied by Dr. Julian Woelfel and his dental hygiene students at T e Ohio State University between 1974 and 1979. T e data from these studies are presented throughout the text by using superscript letters like this (data[A]) that refer to the data listed by letters at the end of the chapters. For example, the text states that a mesial marginal groove is a distinguishing characteristic of the maxillary first premolar,[A] and at the end of the chapter under A, you are told that this occurred in 97% of the 600 premolars studied, which means that, on the average, 3% may not have this groove, whereas only 37% of maxillary second premolars are likely to have this groove.

Su GGeSTio n S Fo R STu d yin G Te eTh

Spend time thinking about and comprehending each new concept as you read. After all, you are learning the "foreign" language of dental anatomy that you will be using for the rest of your professional lives. Have fun looking at teeth as though you were a tooth detective. Take notes, sketch different views of each tooth, and take advantage of all learning exercises, references to figures, and the appendix. Ask questions until your curiosity is satisfied. T e authors hope this book will stimulate your interest and involvement in the wonderful and fascinating field of dentistry and that you will consider this book to be a worthwhile addition to your library even after your formal education is complete.

As you begin learning the characteristics that differentiate each type of tooth as described in Part I, you need to be aware of the considerable variation in tooth morphology that can occur from one person to the next. Keep in mind that tooth sizes and characteristics cited within the text do not apply to all patients' teeth but are based on average sizes or particular morphology occurring with the greatest frequency. Observe the similarities and differences between each type of tooth by comparing the many photos of teeth included in this book.

Since a picture is worth a thousand words, it is very important that you refer to all figures whenever they are referenced in order to maximize learning. In most cases, important traits are emphasized or clarified in the illustration legends, so read the legends as you study each figure. Also, try covering the labels on each illustration in order to test yourself on the terms you are learning. Be sure to test your knowledge by participating in all learning exercises, and answer all test items included in each chapter to make sure you do not need to review the material before proceeding. When studying each table, try to list as many traits as you can for each tooth and see how many traits you have not remembered. Finally, it is imperative that you refer to the Appendix items as they are discussed to make sure that you can visualize each trait that is being discussed, and later, review the traits listed on the back of each appendix page to assure that you understand each concept. If a description of a trait is not clear, turn the page over in order to visualize the trait. After studying each chapter, refer back to the objectives presented at the beginning of the chapter and ask yourself if you have mastered each one. As you become familiar with the many similarities and differences of tooth morphology, you can later apply your knowledge during patient treatment, evaluation, and education.

As you read the description of tooth morphology, it would be ideal to use a dental explorer on an actual tooth or model to "feel" the contours being described since you will eventually be required to evaluate, reproduce, and/or clean the surfaces of these tooth contours with specific dental instruments. T e best resource for learning about teeth is a collection of as many intact extracted teeth as you are able to acquire. A dentist, if presented with a quart jar of bleach, will remember his or her own student days and will probably be glad to put extracted teeth in the jar. Do not expect these teeth to be clean or sorted out; sorting is your job. While handling these teeth, it is critical to follow the guidelines for infection control presented here:

Gu id el in eS Fo R STeRil izin G a n d STu d yin G exTRa c Te d TeeTh

Using protective gloves and a mask, tooth specimens should be scraped clean with a knife. Soaking for several hours in hydrogen peroxide before scraping is helpful. After scraping to remove hard deposits and soft tissue, tooth specimens should be further cleansed by soaking for 20 minutes in 4 ounces of household bleach containing 2 tablespoons of Calgon (a water softener). Teeth can then be placed in water (in a beaker covered with tin foil) to be autoclaved for 40 minutes at 121°C and 15 psi (Pantera E, Schuster G. J Dent Ed 1990;54(5):284). Once prepared, teeth should be kept moist, either by soaking in water or, as suggested by Dr. Kim Loos, DDS, by soaking in 25% glycerin and 75% water (parentsplace.com, February 28, 2001).

a d d iTio n a l Re So u Rc eS

Woelfel's Dental Anatomy includes additional resources for both instructors and students that are available on the book's companion Web site at http://thePoint.lww.com/Scheid9e

instructor Resources

Approved adopting instructors will be given access to the following additional resources:

- PowerPoint Presentations
- Interactive image bank with the option of displaying images with or without labels
- Test Generator
- Answers to end-of-chapter Critical T inking Questions

Student Resources

Students who have purchased Woelfel's Dental Anatomy have access to the following additional resources:

- Image labeling exercises
- Interactive image bank with the option of displaying images with or without labels
- PowerPoint Presentations

In addition, purchasers of the text can access the searchable Full Text Online by going to the Woelfel's Dental Anatomy Web site at http://thePoint.lww.com/Scheid9e

See the inside front cover of this text for more details, including the passcode you will need to gain access to the Web site.

Acknowledgments

During my first year teaching at T e Ohio State University College of Dentistry in 1974, I was fortunate to be assigned to teach in a laboratory for dental anatomy where I worked with and was mentored by, Dr. Julian Woelfel. He asked me to contribute the chapter on Operative Dentistry in the third edition in 1984. Little did I realize that in 1994, he would select me to coauthor the fifth edition of a text on the very topic I began teaching in 1974: dental anatomy. During the preparation for the fifth and sixth editions, Julian permitted me great latitude in reorganizing the text to ref ect my teaching style since I used this text as I taught over 135 dental and dental hygiene students each year. During this major reorganization, I was careful to maintain the unique aspects that he had incorporated into previous editions. T is includes the results of his personal, science-based research, which formed the basis for many of the conclusions presented within this text: on everything from the average mandibular hinge opening to the frequency of Carabelli cusp formation and the comparative sizes of primary and permanent teeth. In the seventh edition, Dr. Woelfel entrusted me to take over the text.

I would like to express my appreciation to all of the contributors to this and previous editions of this book. My thanks goes to Dr. Woelfel for selecting me to take over the book and teaching me to be meticulous, and for his many contributions to this text; to his wife, Marcile, who helped tremendously in typing and editing previous editions; and to the following colleagues who updated chapters in this edition: Dr. Binnaz Leblebicioglu and Dr. Lewis Claman (Periodontal anatomy), Dr. D. Stanley Sharples, II (Restorative dentistry), and Dr. Shereen Azer (Occlusion), Dr. John Nusstein (Endodontics), and Dr. Daniel Jolly (Forensic Dentistry) and Dr. Burak Yilmaz (who helped with the photography for this edition). I would also like to recognize Ms. Dorothy Permar, who conceived and wrote the first edition in 1974, and Dr. Robert Rashid, Dr. T eodore Berg, Jr., Dr. Al Reader, and Ms. Connie Sylvester, who contributed to previous editions. Finally, a special thanks goes to my co-author, Dr. Gabriela Weiss, who collaborated with me to incorporate the many improvements and additional teaching exercises and test items, and in the daunting task of editing and proofing each chapter.

Rickne C. Scheid, DDS, MEd

abouT d R. Julian Woelfel



Professor Emeritus Julian Woelfel, known primarily for his expertise in complete dentures, research, and occlusion, has taught clinical dentistry for 40 years in the College of Dentistry at T e Ohio State University, Columbus, Ohio. He served as an Army prosthodontist in Texas for 2 years, conducted clinical research for the American Dental Association at the National Bureau of Standards in Washington, District of Columbia, for 3 years, and was a visiting professor in Japan, Taiwan, England, and Brazil. Dr. Woelfel has lectured in 18 foreign countries. He has published 85 scientific articles, 8 editions of this Dental Anatomy textbook, and chapters in 5 other dental books. Dr. Woelfel also has published scientific dental articles in Japan, Bulgaria, and Brazil. He holds patents on two inventions that are used in Europe and the United States for accurately recording jaw relation. In addition to Dr. Woelfel's love for students and teaching, he had a part-time dental practice limited to partial and complete dentures for 33 years. One of his proudest accomplishments has been this textbook. In 1967, he was the first recipient of the International Association of Dental Research Award for Research in Prosthodontics and was awarded a Life Membership in the Japanese Nihon University Dental Alumni Association. In 1972, the New York Prosthodontic Society selected him for the Jerome and Dorothy Schweitzer Award for Outstanding and Continuing Research in Prosthodontics. In 1992, the Ohio Dental Association chose Dr. Woelfel for the prestigious Callahan Award, and in 2004, he was the recipient of the Distinguished Alumnus Award from the Ohio Dental Alumni Association. He is a Life Member of Sigma Xi, the International Association for Dental Research, the American Prosthodontic Society, Sigma Phi Alpha Dental Hygiene Honor Society, and the ADA, AES, FDI, FICD, and FACD.

Comments or suggestions may be submitted to Dr. Scheid on e-mail (scheid.2@osu.edu).

Contents

About the Authors v

Reviewers vi

Preface to the Ninth Edition vii

Acknowledgments x

Part 1 Comparative Tooth Anatomy 1

1 Basic Terminology for Understanding Tooth Morphology 3
2 Morphology of the Permanent Incisors. 49
3 Morphology of the Permanent Canines 78
4 Morphology of Premolars 96
5 Morphology of Permanent Molars. 135
6 Primary (and Mixed) Dentition 182

Part 2 Application of Tooth Anatomy in Dental Practice 213

7 Periodontal Anatomy 215
8 Application of Root and Pulp Morphology Related to Endodontic Therapy 249
9 Functional Occlusion and Malocclusion 268
10 Treating Decayed, Broken, and Missing Teeth 304
11 Dental Anomalies. 336
12 Forensic Dentistry. 358
13 Guidelines for Drawing, Sketching, and Carving Teeth. 375

Part 3 Anatomic Structures of the Oral Cavity 389

14 Structures That Form the Foundation for Tooth Function. 391
15 Oral Examination: Normal Anatomy of the Oral Cavity 449

Appendix 481

Glossary for Woelfel's Dental Anatomy 503

Index 523

PART

1

Comparative Tooth Anatomy

The six chapters in this part of the book provide a detailed description of each type of tooth in an adult and in a child.

1 Basic Terminology for Understanding Tooth Morphology

The background terminology and tooth morphology concepts presented in this chapter are divided into 10 sections as follows:

I. Naming teeth based on location within the normal, complete human dentition
   - A. Complete primary dentition
   - B. Complete permanent dentition

II. Tooth identification systems: Universal, World Dental Federation (International), and Palmer Numbering Systems

III. Terminology used to describe the tissues of a tooth (and definition of anatomic crown and root)

IV. Introduction to the periodontium (and definition of clinical crown and root)

V. Terminology used to define tooth surfaces
   - A. Terms that identify outer surfaces (toward the cheeks or lips) of anterior versus posterior teeth
   - B. Terms that identify inner surfaces (toward the tongue) of maxillary versus mandibular teeth
   - C. Terms that differentiate biting surfaces of anterior versus posterior teeth
   - D. Terms that differentiate approximating surfaces of teeth
   - E. Terms to denote tooth surface junctions or dimensions
   - F. Divisions (thirds) of the crown or root (for purposes of description)
   - G. Root-to-crown ratio

VI. Terminology used to describe the morphology of a tooth
   - A. Morphology of an anatomic crown
   - B. External morphology of the anatomic root
   - C. Cervical line (cementoenamel junction or CEJ) curvature
   - D. Relative size

VII. Terminology related to the ideal tooth alignment of teeth in dental arches
   - A. Midroot axis line and tooth alignment
   - B. Crest of curvature (height of contour) on the facial and lingual surface
   - C. Contact areas (or proximal crests of curvature)
   - D. Embrasure spaces

VIII. Ideal occlusion: inter (between) arch relationship of teeth

IX. Tooth development from lobes

X. Interesting variations in animal teeth compared to human teeth using dental formulae

Objectives

This chapter is designed to prepare the learner to perform the following:

- Based on location in the normal, complete primary dentition, name all 20 teeth by arch, quadrant, type (when applicable), and class.
- Based on location in the normal, complete permanent dentition, name all 32 teeth by arch, quadrant, type (when applicable), and class.

(Continued)

- Use the Universal Numbering System to identify permanent and primary teeth.
- Use the Palmer and International Tooth Numbering Systems to identify teeth, and "translate" them to the Universal System.
- Identify and describe the supportive structures of the teeth (periodontium).
- Identify and describe the four tissues of a tooth and their location, mineral content, and function.
- Differentiate an anatomic crown and root from a clinical crown and root.
- Name each tooth surface on anterior and posterior teeth.
- From all views, divide a tooth crown and root into thirds and label each third.
- Define terms used to describe a specific dimension of a tooth.
- Describe and identify (by name) common tooth rounded elevations, ridges, depressions, and grooves for each type of tooth.
- Describe and recognize the parts of a root.
- Describe and identify the attributes of ideal tooth alignment and embrasure spaces relative to other teeth within the arch, including the cusp or incisal edge position relative to the tooth's midroot axis line (proximal views), location of crests of curvature and proximal contacts (facial or lingual views), and relative sizes of embrasure spaces (facial, lingual, or occlusal/incisal views).
- Describe and identify the ideal interarch relationship of teeth in class I occlusion, especially the relationship of first molars and canines.
- Identify the number of developmental lobes that form each tooth, and recognize the anatomic landmarks of a tooth that form from these lobes.

Just as you need to learn a new vocabulary before you can speak a foreign language, you need to learn a new vocabulary before you can begin to understand the "foreign language" of dental anatomy. T erefore, you need to understand each new word defined in this introductory chapter (highlighted in **bold**) in order to be able to discuss and appreciate the numerous traits that differentiate each type of tooth that are presented in the next five chapters. Without this understanding, you can neither understand others nor make yourself understood when discussing teeth. Do you comprehend what is meant when someone says "In ideal class I occlusion, the mesiobuccal cusp of the maxillary first molar occludes with the mesiobuccal groove of the mandibular first molar"? If not, study each term in this chapter, carefully analyze each figure when it is referenced, perform all of the learning exercises, and answer each study question. T en you should be able to comprehend and picture exactly what was said in that statement.

SECTION I NaMINg TEETh BaSEd ON LOCaTION wITh IN Th E NOr maL, COmpLETE h u maN d ENTITION

T is section is designed to introduce you to terms used when naming teeth based on their normal location in the mouth. All of the teeth in the mouth together are referred to as our **dentition** [den TISH un]. Humans have two sets of teeth throughout life: one during childhood, called the **primary dentition**, and one that will hopefully last throughout adulthood, called the **permanent** (also known as **secondary**) **dentition**.

T e teeth in the upper jawbones (called the maxillae [mak SIL ee]) collectively form an arch shape known as the **maxillary** [MACK si lair ee] **arch**, and those teeth in the lower jawbone (called the mandible) collectively form the **mandibular** [man DIB yoo ler] **arch**. Each arch can further be divided into the left and right halves, also known as left and right quadrants since each **quadrant** contains one fourth of all teeth in that dentition.

a. COmpLETE pr Imar y d ENTITION

T ere are 20 teeth in the complete primary dentition (shown in Fig. 1-1). T ere are ten in the upper (maxillary) arch and ten in the lower (mandibular) arch. T e complete primary dentition has five teeth in each quadrant. T e primary teeth in each quadrant are further divided into three **classes** based on their unique shape and function during chewing. Incisors [in SI zerz] are shaped to incise and cut off pieces of food, canines are shaped to pierce and hold on to food, and molars are shaped to grind food. Starting on either side of the arch **midline**, that is, the demarcation between the right and left quadrants, the two front teeth in each quadrant of the primary dentition are **incisors**, followed by one **canine**, and then two **molars**.

Two classes of primary teeth, incisors and molars, contain more than one tooth per quadrant and are subdivided into **types** within each class. Each type can be defined by its normal location within the complete quadrant. T e type of primary incisor closest to the arch midline separating the right and left quadrants is called a **central incisor.** T e type of incisor next to, or lateral to, the central incisor is called a **lateral incisor**. Next in each quadrant is a canine, followed by two types of molars: a **first molar** behind the canine and then a **second molar** (Fig. 1-1).

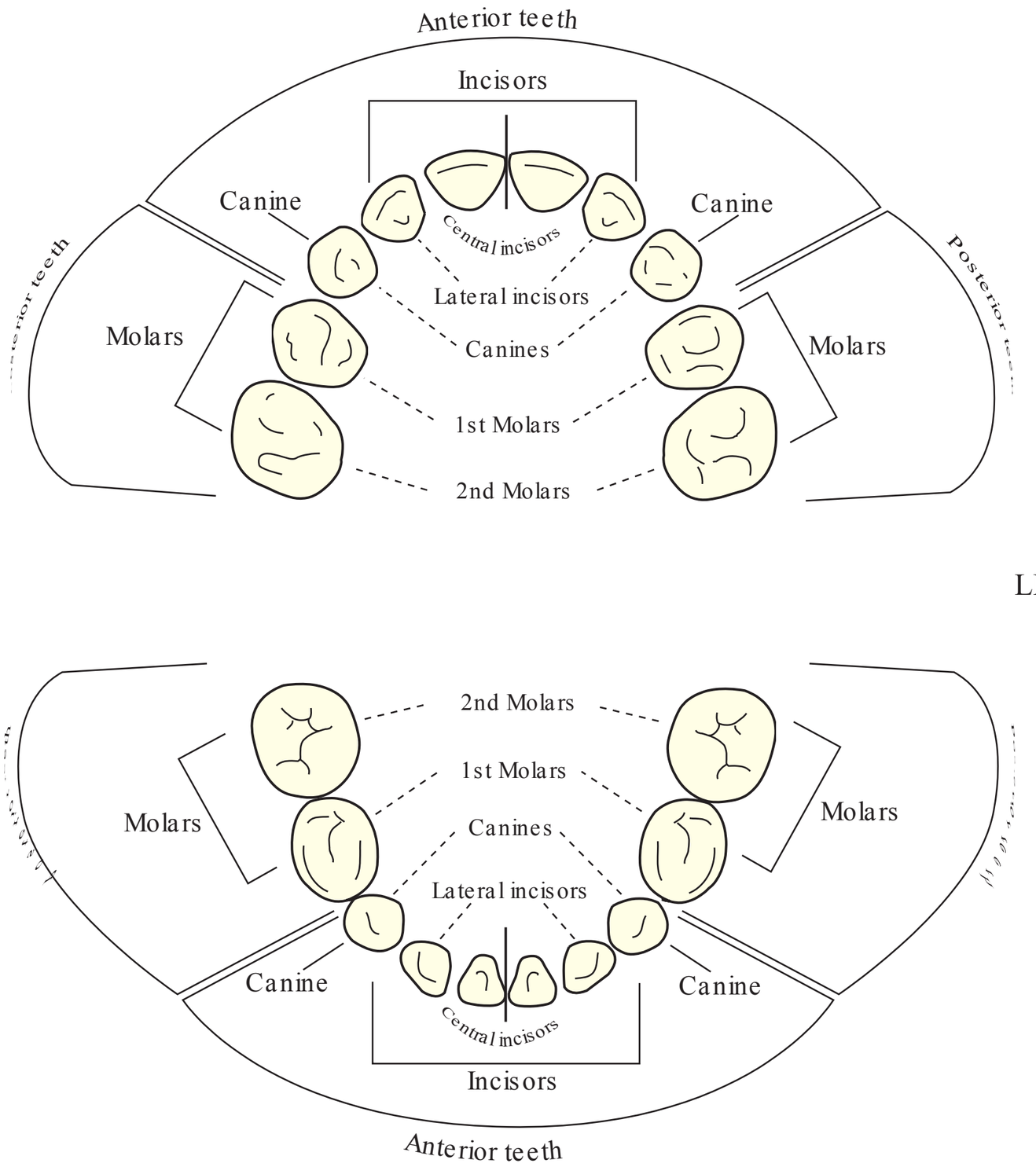

FIgu r E 1-1. Maxillary and mandibular pri**m**ary dentition. The midline of each arch is denoted by a line between the right and left central incisors.

T e primary dentition is also called the **deciduous** [de SIDJ oo us] **dentition**, referring to the fact that all of these teeth are eventually shed (like a deciduous tree loses its leaves), being replaced by teeth of the permanent dentition. T e **mixed dentition** is the term used to describe the dentition where there is a mix of secondary and primary teeth visible in the mouth at the same time, during that time after permanent teeth have begun to replace primary teeth, but before all primary teeth have been lost.



LEARNING EXERCISE

Using either models of the complete primary dentition or Figure 1-1 while covering up the labels, identify each primary tooth based on its location in the arch. Include, in order, the dentiti**o**n (primary), arch (maxillary or mandibular), quadrant (right or left), type (if applicable), and class. For example, the tooth next to the midline in the lower left quadrant would be identified as the primary mandibular left central incisor.

B. COmpLETE pEr maNENT d ENTITION

T e complete permanent (or secondary) dentition is present in the adult. It is composed of 32 teeth: 16 in the upper maxillary arch and 16 in the lower mandibular arch (shown in Fig. 1-2). T e permanent dentition has eight teeth in each quadrant, which are divided into four **classes**: incisors that incise food; canines that pierce and hold food; **premolars**, a new class for permanent teeth shaped to chew food; and molars, also shaped to chew food. Based on location, the two permanent front teeth in each quadrant are incisors, followed by one canine, then two premolars, and finally three molars.

T e classes of permanent teeth containing more than one tooth per quadrant (namely, incisors, premolars, and molars) are subdivided into **types** within each class. Each type can be identified by its normal location within the quadrant. As in the primary dentition, the permanent incisor closest to the midline between the right and the left quadrants is called a central incisor; the incisor next to, or lateral to, the central incisor is called a lateral incisor. Next in the arch is a canine,

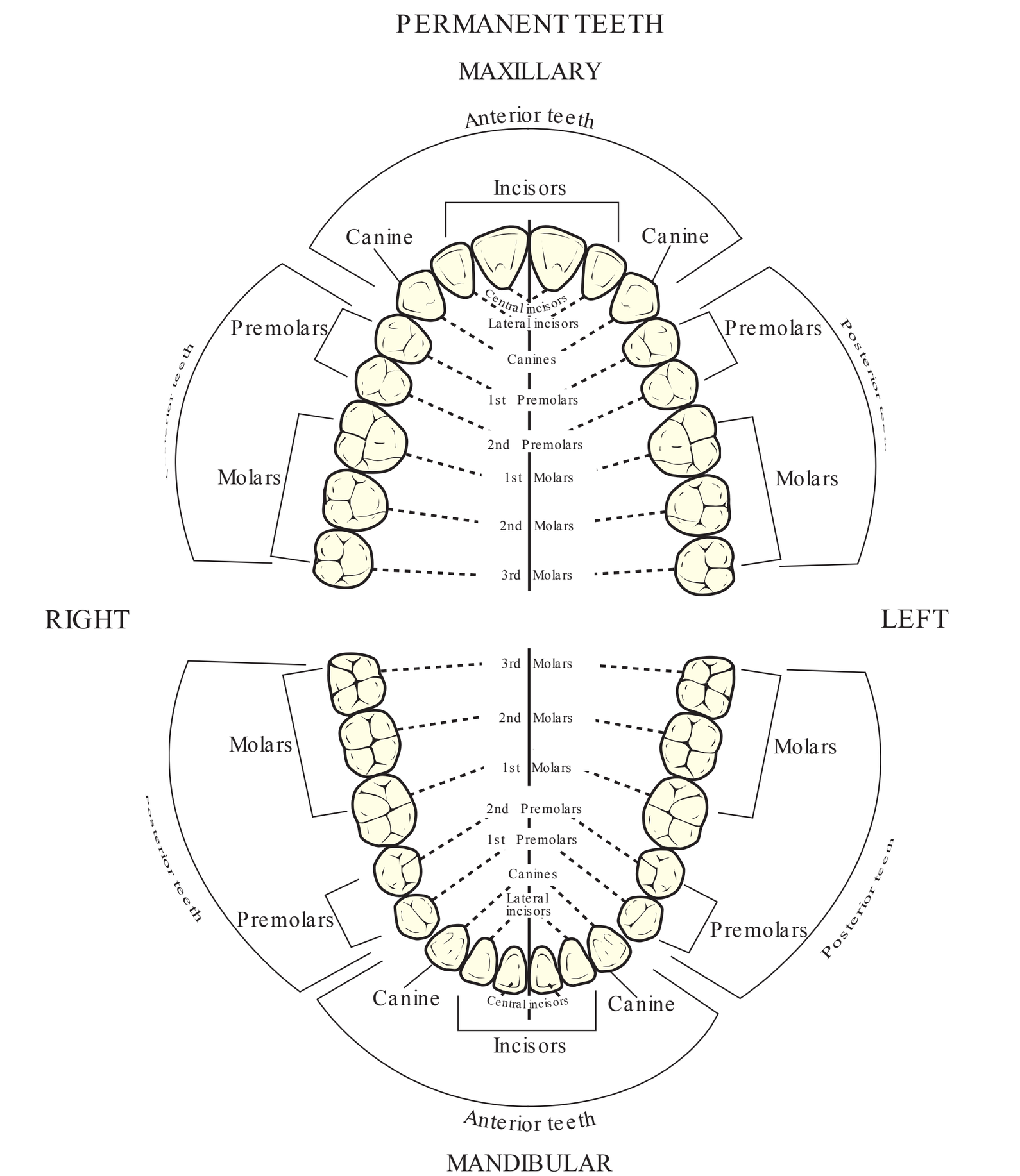

FIgur E 1-2. Maxillary and mandibular permanent dentition. The midline of each arch is denoted by a line between the right and left central incisors.

followed by a **ȧrst premolar**, and then a **second premolar**. Continuing around toward the back in each quadrant are three molars: a first molar, a second molar, and finally a **third molar** (sometimes referred to as a **wisdom tooth**).

In summary, when comparing the teeth in primary and permanent dentitions, be sure to notice the differences. Although central incisors and lateral incisors and canines are similarly positioned in both dentitions, permanent dentitions have a new class of teeth called **premolars**, which are located between permanent canines and permanent molars. Premolars erupt into the spaces left where the primary molars were located earlier in life. Also, there are three permanent molars in each quadrant, whereas there are only two primary molars in each quadrant. T ese three permanent molars erupt behind the premolars where no primary teeth were previously located.

T ere are two other terms used to categorize or distinguish groups of teeth by their location: anterior and posterior teeth. **Anterior teeth** are those teeth in the front of the mouth, specifically, the incisors and the canines. **Posterior teeth** are those in the back of the mouth, specifically, the premolars and the molars.

LEARNING EXERCISE

Using either models of the complete permanent dentition or Figure 1-2 while covering up the labels, identify each permanent tooth based on its location in the arch. To identify each tooth accurately, include, in order, the dentition (permanent), arch (maxillary or mandibular), quadrant (right or left), type (if applicable), and the class. For example, the last adult tooth in the lower right quadrant is correctly identified as the permanent mandibular right third molar.

r EvIEw Questi**o**ns

T ese questions were designed to help you confirm that you understand the terms and concepts presented in this section. Select the one best answer.

1. How many teeth are present in one quadrant of a complete adult (permanent) dentition?
   a. 5
   b. 8
   c. 10
   d. 20
   e. 32

2. What class of teeth is present in the permanent dentition that is NOT present in the primary dentition?
   a. Incisors
   b. Canines
   c. Premolars
   d. Molars

3. In a permanent dentition, the fifth tooth from the midline is a
   a. Canine
   b. Premolar
   c. Molar
   d. Incisor

4. T e posterior teeth in the permanent dentition include which of the following?
   a. Premolars only
   b. Molars only
   c. Premolars and molars only
   d. Canines, premolars, and molars

5. Which permanent tooth erupts into the space previously held by the primary second molar?
   a. First molar
   b. Second molar
   c. First premolar
   d. Second premolar

6. How many teeth are present in one arch of the adult dentition?
   a. 5
   b. 8
   c. 10
   d. 12
   e. 16

7. How many teeth are present in one arch of the primary dentition?
   a. 5
   b. 8
   c. 10
   d. 16
   e. 20

8. How many incisors are present in the complete adult dentition?
   a. 2
   b. 4
   c. 6
   d. 8
   e. 12

9. How many molars are present in the primary dentition?
   a. 2
   b. 4
   c. 8
   d. 10
   e. 1

10. How many molars are present in each arch of the adult dentition?
    a. 2
    b. 3
    c. 6
    d. 8
    e. 12

11. What is the fourth tooth from the midline in the primary dentition?
    a. Canine
    b. First premolar
    c. Second premolar
    d. First molar
    e. Second molar

d–11; c–01; c–9; d–8; c–7; e–6; d–5; c–4; b–3; c–2; b–1: Sr E wS Na

SECTION II TOOTh Id ENTIFICaTION SySTEmS: u NIvEr Sa L, w Or Ld d ENTa L FEd Er aTION (INTEr NaTIONa L), a Nd pa LmEr Nu mBEr INg SySTEmS

Documenting patient treatment with accurate dental records is an important task in any dental practice. To do so expeditiously, it is necessary to adopt a code or numbering system for teeth. Otherwise, for each tooth being charted, one must record the dentition, arch, side, type (if applicable), and class. For example, describing a permanent maxillary right second molar requires five words, but it can be simplified by using the Universal Numbering System, identifying this same tooth with the number 2 (only one number).

T e **Universal Numbering System** was first suggested by Parreidt in 1882 and officially adopted by the American Dental Association in 1975. It is accepted by third-party providers in the United States and is endorsed by the American Society of Forensic Odontology. Basically, the Universal Numbering System uses numbers **1** through **32** for the 32 teeth in the permanent dentition, starting with 1 for the maxillary right third molar, going around the arch to the maxillary left third molar as 16; dropping down on the same side, the left mandibular third molar becomes 17, and then the numbers increase around the lower arch to 32, which is the lower right third molar. T is numbering system is used for each permanent tooth in the illustration in Figure 1-3 and seen in the mouth in Figure 1-4.

For the 20 teeth in the primary dentition, 20 letters of the alphabet are used from **A** through **T**. T e letter A represents the maxillary right second molar, sequentially around the arch and through the alphabet to J for the maxillary left second molar, then dropping down on the same side to K for the mandibular left second molar, and then clockwise around the lower arch to T for the mandibular right second molar. T is system is used to identify each primary tooth in Figure 1-5 and in the mouth in Figure 1-6.

FIgu r E 1-3. The numbers 1 through 32 on the permanent teeth identify each tooth using the Universal Nu**m**bering Syste**m**, which is commonly used for record keeping in the United States and used in this book.



FIgur E 1-4. In the mouth of an adult, the permanent teeth that are visible are numbered using the Universal Numbering System.

There are also two other numbering systems: the World Dental Federation (International) System used in other countries and the Palmer Tooth Notation System. The **World Dental Federation** notation (also known as the **Federation Dentaire Internationale** or **FDI System**) uses two digits for each permanent or primary tooth. The first digit denotes a specific quadrant (right or left), arch (maxillary or mandibular), and dentition (permanent or primary) as follows:

PERMANENT DENTITION
1 = Permanent dentition, maxillary, right quadrant
2 = Permanent dentition, maxillary, left quadrant
3 = Permanent dentition, mandibular, left quadrant
4 = Permanent dentition, mandibular, right quadrant

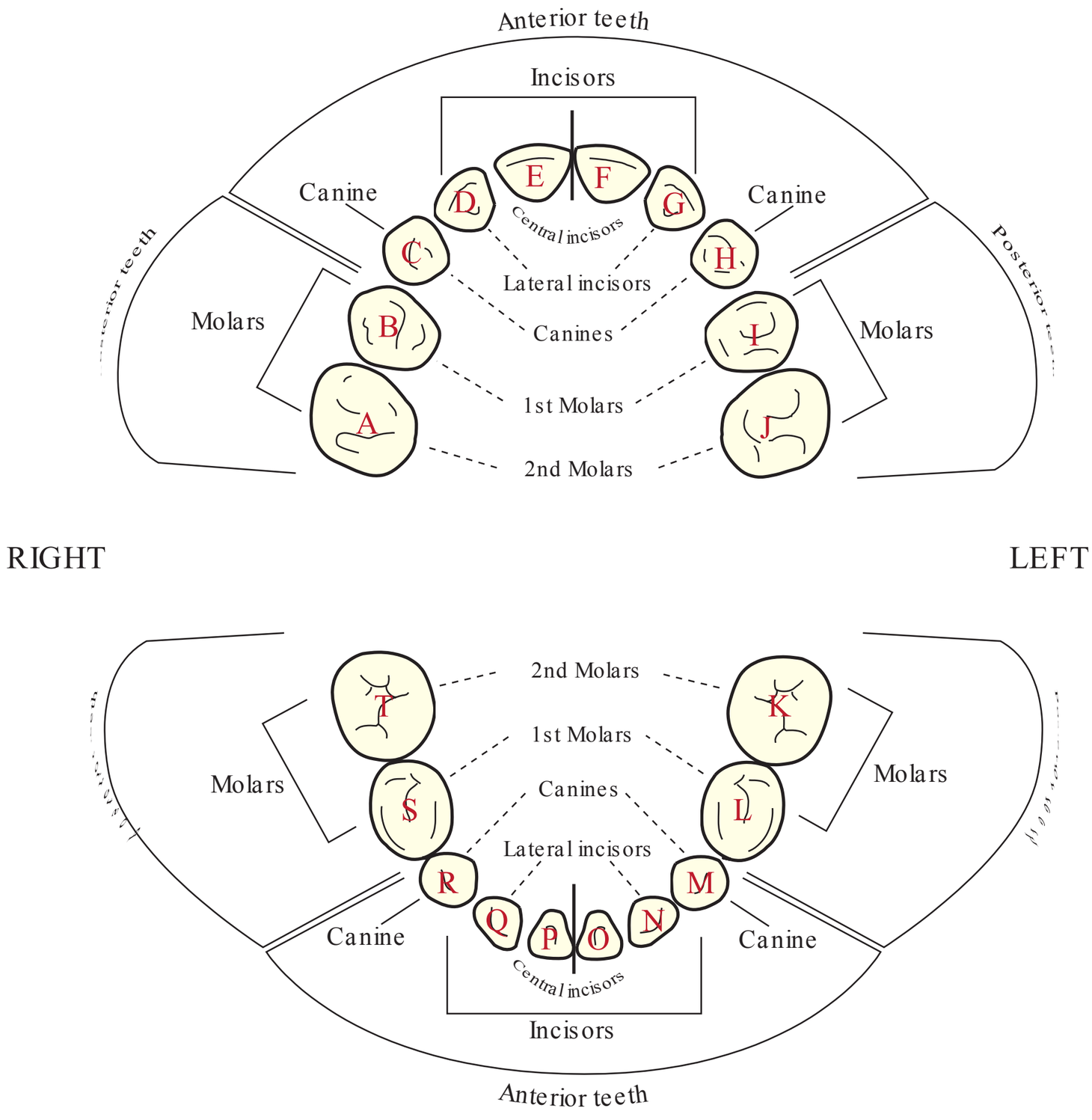

FIgur E 1-5. The letters A to T on the primary teeth identify each tooth using the Universal System, which is commonly used for record keeping in the United States.

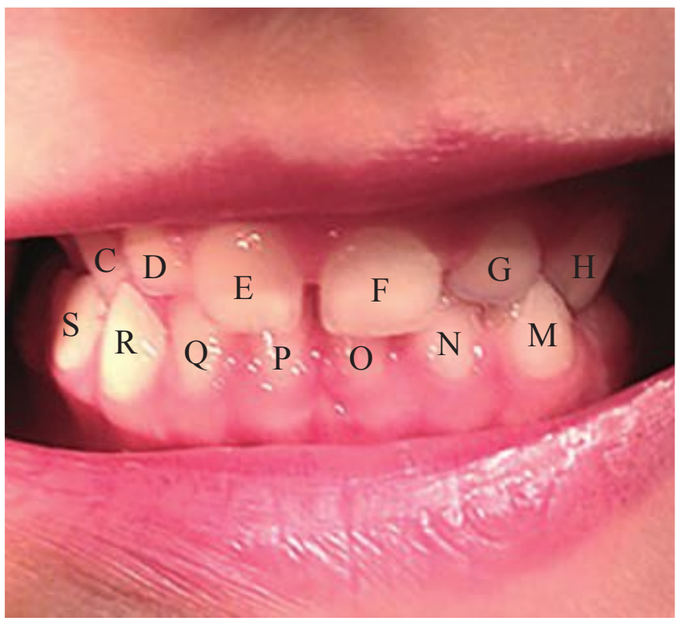

FIgur E 1-6. In the mouth of a child, the primary teeth that are visible are identified using letters as used in the Universal Syste**m**.

PRIMARY DENTITION

5 = Primary dentition, maxillary, right quadrant
6 = Primary dentition, maxillary, left quadrant
7 = Primary dentition, mandibular, left quadrant
8 = Primary dentition, mandibular, right quadrant

T e second digit denotes the tooth position in each quadrant relative to the midline, from closest to the midline to farthest away. T erefore, in the permanent dentition with 8 teeth in each quadrant, 1 is a central incisor closest to the midline, 2 is a lateral incisor, 3 is a canine, and so forth through 8, the permanent third molar, farthest from the midline. In the primary dentition with only 5 teeth in each quadrant, the number 1 represents the tooth closest to the midline or the primary central incisor, and the number 5 represents the tooth farthest from the midline or the primary second molar. In summary, each adult quadrant is numbered 1 through 4 and each adult tooth within that quadrant is numbered 1 to 8 (Fig. 1-7), while

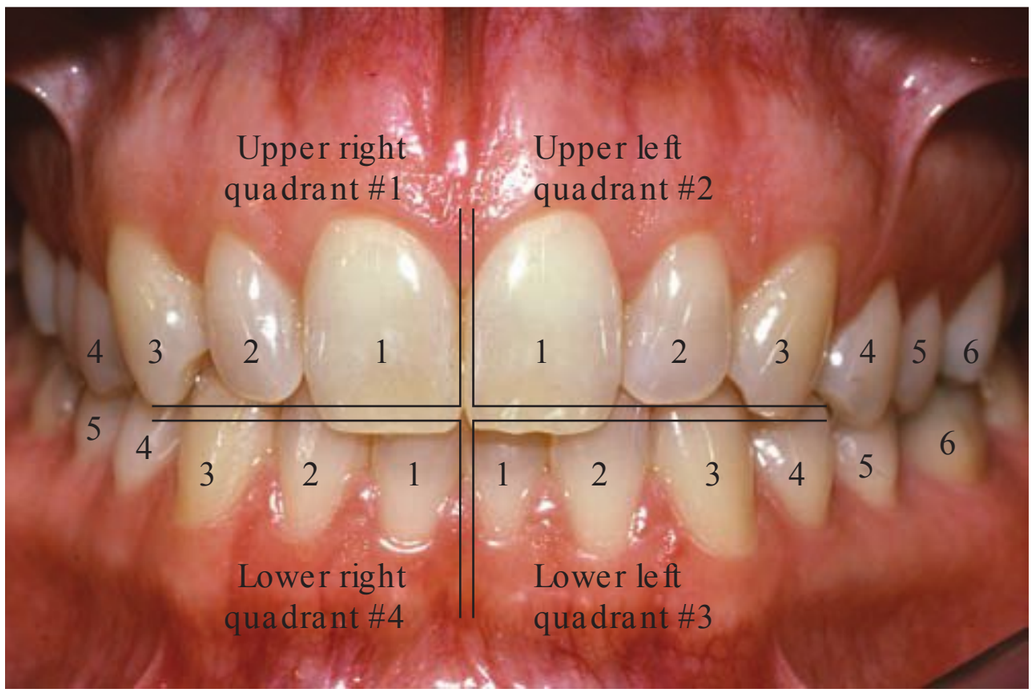

FIgur E 1-7. Two methods are shown for denoting each quadrant in the permanent dentition. The Pal**m**er Syste**m** uses a different "bracket" shape for each quadrant as you face the person, whereas the FDI Internati**o**nal Syste**m** uses the numbers 1 through 4 to denote each adult quadrant. The numbers on each tooth denote the method for identifying teeth within each quadrant beginning at the midline with number 1 for the central incisors, number 2 for lateral incisors, etc.

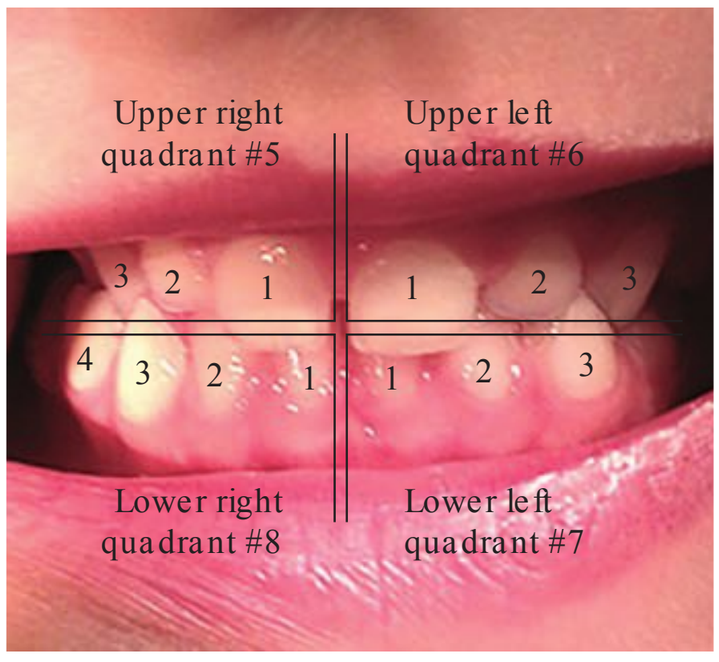

FIgur E 1-8. When identifying each primary tooth using the W**o**rld Dental Federati**o**n or FDI Internati**o**nal Syste**m**, each quadrant is numbered 5 through 8 as indicated, and each tooth within that quadrant is identified using numbers 1 though 5 with number 1 for the central incisors, number 2 for lateral incisors, etc.

each primary quadrant is numbered 5 to 8 and each tooth within that quadrant is numbered 1 to 5 (Fig. 1-8). (Using this system, tooth numbers within the range 11 through 48 represent permanent teeth, whereas tooth numbers within the range 51 through 85 represent primary teeth.) To cite an example, 45 is a permanent mandibular right second premolar since the first digit, 4, indicates the mandibular right quadrant in the permanent dentition, and the second digit, 5, indicates the fifth tooth from the midline in that quadrant, namely, the second premolar. Using this numbering system for the primary dentition, tooth 63 is a primary maxillary left canine since the first digit, 6, indicates maxillary left quadrant in the primary dentition, and the second digit, 3, indicates the third tooth from the midline, namely, the canine. To cite another example, 51 is a primary maxillary right central incisor since the first digit, 5, indicates the maxillary right quadrant for a primary tooth, and the second digit, 1, indicates the first tooth from the midline in that quadrant, namely, the central incisor. Finally, if the Universal number for a tooth was 32, the World Dental Federation number would be 48. If the Universal letter for a primary tooth was A, the World Dental Federation number would be 55. All tooth numbers and letters using both systems are shown in Table 1-1.

T e **Palmer Notation System** is used by many orthodontists and other practitioners especially in the United Kingdom. It utilizes four different bracket shapes (⌟, ⌞, ⌝, and ⌜) to denote each of the four quadrants. T e specific bracket surrounds a number (or letter), which denotes the specific tooth within that quadrant. T e specific brackets are designed to represent each of the four quadrants of the dentition, as if you were facing the patient as seen in Figure 1-7.

⌟ is upper right quadrant.
⌞ is upper left quadrant.
⌝ is lower right quadrant.
⌜ is lower left quadrant.

TABLE 1-1 major Tooth Identification Systems

TOOTH	UNIVERSAL		PALMER NOTATION		INTERNATIONAL (FDI)	
	RIGHT	LEFT	RIGHT	LEFT	RIGHT	LEFT
Central incisor	E	F	A|	|A	51	61
Lateral incisor	D	G	B|	|B	52	62
Canine	C	H	C|	|C	53	63
First molar	B	I	D|	|D	54	64
Second molar	A	J	E|	|E	55	65
Central incisor	P	O	A|	|A	81	71
Lateral incisor	Q	N	B|	|B	82	72
Canine	R	M	C|	|C	83	73
First molar	S	L	D|	|D	84	74
Second molar	T	K	E|	|E	85	75
Central incisor	8	9	1|	|1	11	21
Lateral incisor	7	10	2|	|2	12	22
Canine	6	11	3|	|3	13	23
First premolar	5	12	4|	|4	14	24
Second premolar	4	13	5|	|5	15	25
First molar	3	14	6|	|6	16	26
Second molar	2	15	7|	|7	17	27
Third molar	1	16	8|	|8	18	28
Central incisor	25	24	1|	|1	41	31
Lateral incisor	26	23	2|	|2	42	32
Canine	27	22	3|	|3	43	33
First premolar	28	21	4|	|3	44	34
Second premolar	29	20	5|	|5	45	35
First molar	30	19	6|	|6	46	36
Second molar	31	18	7|	|7	47	37
Third molar	32	17	8|	|8	48	38

The permanent tooth in each quadrant is numbered from 1 (nearest to the arch midline) to 8 (farthest from the midline) as in the International System. To record a specific tooth, place the correct number of the tooth in that quadrant within the bracket shape that identifies the correct quadrant (Fig. 1-7). For example, the lower left central incisor would be ⌋1⌊, the lower left second premolar would be ⌋5⌊, and the upper right canine would be 3|. For primary teeth, the same four brackets are used to denote the quadrants, but five letters of the alphabet, A through E, represent the primary teeth in each quadrant (with A being a central incisor, B a lateral incisor, C a canine, etc.) (Fig. 1-9). For example, the primary upper right first molar would be D|. Comparing the Universal System with the Palmer System, the permanent maxillary right second molar would be tooth 2 using the Universal System, but would be 7| using the Palmer System. If you are confused, study Table 1-1 and the figures that illustrate the quadrant brackets.

Unless otherwise stated, the **Universal System of tooth numbering is used throughout this text.** To master the Universal System, it may be helpful to memorize the number or letters for key teeth, possibly the central incisors (numbers 8, 9, 24, and 25) or the first molars (numbers 3, 14, 19, and 30).

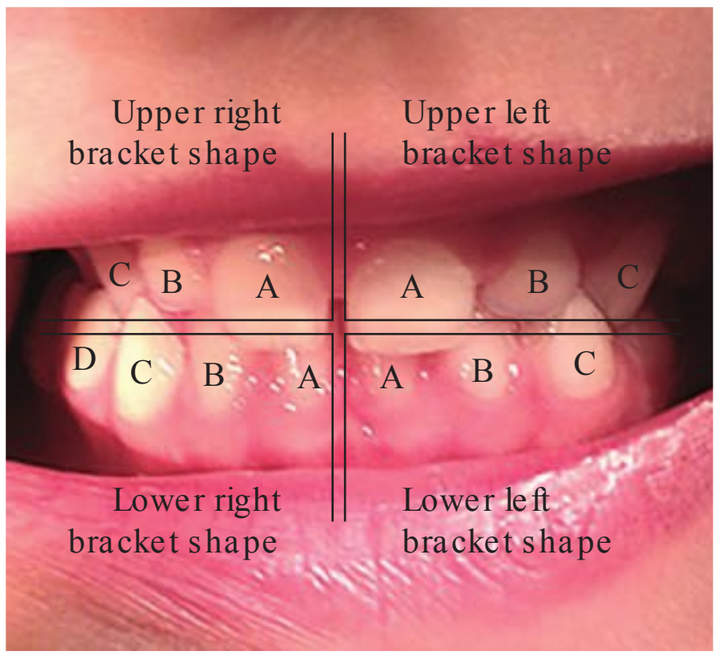

FIGURE 1-9. When identifying each primary tooth using the Palmer System, each quadrant is denoted by bracket shapes as indicated, and each tooth within that quadrant is identified using letters A though B with letter A for the central incisors, letter B for lateral incisors, etc.

r EvIEw Questions about Tooth Notation

T ese questions were designed to help you confirm that you understand the terms and concepts presented in this section. More than one answer may be correct.

1. If you read an article in a British dental journal that refers to tooth number 48, you would suspect that the authors were using the International Numbering System. What Universal number (or letter) would they be talking about?
   a. 25
   b. J
   c. 30
   d. T
   e. 32

2. Using the Universal Numbering System, what numbers are used to identify maxillary canines?
   a. 6
   b. 8
   c. 10
   d. 11
   e. 27

3. If you read an article in a British dental journal that refers to tooth number 55, you would suspect that the authors were using the International Numbering System. What Universal number (or letter) would they be talking about?
   a. A
   b. 5
   c. E
   d. T
   e. 1

4. If an orthodontist wrote about tooth $\underline{|5}$, what would the Universal number be?
   a. 3
   b. 4
   c. 5
   d. 12
   e. 13

5. What are the Universal numbers of the permanent mandibular first molars? _____
   a. 3
   b. 14
   c. 19
   d. 24
   e. 30

6. Fill in the blanks: If you are referring to the Universal tooth 27, what is its position from the midline? _____ What is its arch? _____ In which quadrant is it located? _____

t hgir re wd ,r al ubi dna m, dr 3–6; e, c–5; e–4; a–3; d, a–2; e–1: Sr E wS Na

SECTION III TEr mINOLOg y u SEd TO d ESCr IBE Th E TISSu ES OF a TOOTh (a Nd d EFINITION OF a Na TOm ICa L Cr Ow N a Nd r OOT)

Each tooth is made up of four tissues: enamel, dentin, cementum, and pulp. T e first three of these (enamel, dentin, and cementum) are relatively hard since they contain considerable mineral content, especially calcium (so these tissues can also be described as calcified). Only two of these tissues are normally visible on an intact extracted tooth: enamel and cementum. Enamel covers the portion of the tooth known as the **anatomic crown**, and cementum covers the portion of the tooth known as the **anatomic root**. T e other two tissues (dentin and pulp) are usually not visible on an intact tooth. Refer to Figure 1-10 while reading about each tissue.

Enamel [ee NAM el] is the relatively white, protective external surface layer of the anatomic crown. It is highly calcified or mineralized and is the hardest substance in the body. Its mineral content is 95% calcium hydroxyapatite (which is calcified).

Cementum [se MEN tum] is the dull yellow external layer of the anatomic root. T e cementum is very thin, especially next to the part of the root where the crown joins with the root. Its thickness can be compared to the thickness of a human hair (only 50 to 100 μm thick where 1 μm is one millionth of a meter). Cementum is 65% mineralized. (Another

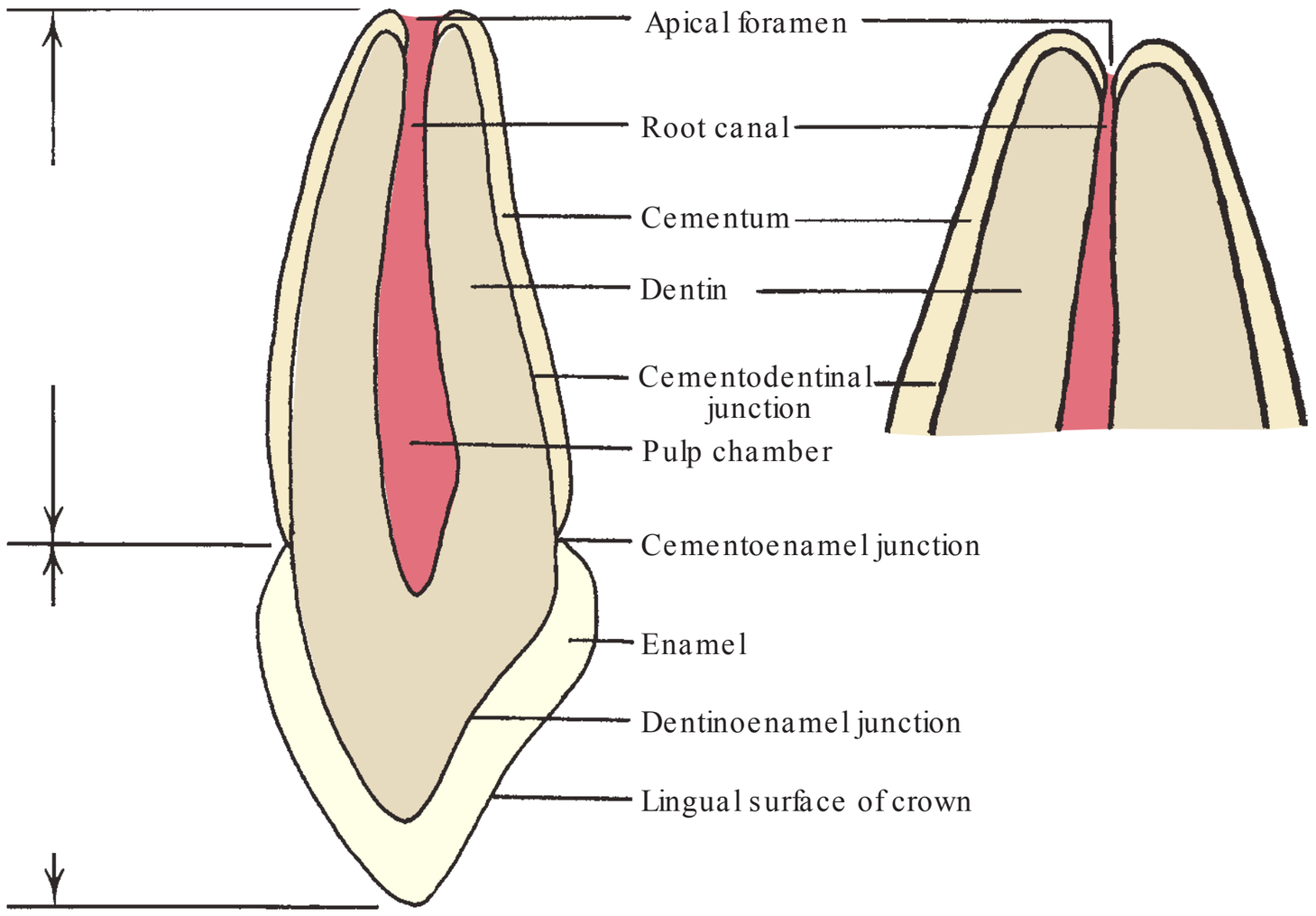

FIgur E 1-10. A maxillary anterior tooth is sectioned faciolingually through the middle to show the distribution of the t**oo**th tissues and the shape of the pulp cavity (made up of pulp chamber and root canal). On the right is a close-up of the root tip depicting the usual expected constriction of the root canal near the apical foramen. The layer of cementum covering the root of an actual tooth is proportionately much thinner than seen in these drawings.

author, Melfi, states that the mineral content of cementum is about 50%.) Cementum is about as hard as bone but considerably less hard than enamel.

T e **cementoenamel** [se MEN toe ehn AM el] **junction** (also called the **CEJ** or **cervical line**) is the junction between the enamel covering the anatomic crown and the cementum covering the anatomic root. T is junction is also known as the **cervical** [SER vi kal] **line**, denoting that it surrounds the neck or **cervix** [SER viks] of the tooth.

Dentin [DEN tin] is the hard yellowish tissue underlying the enamel and cementum, and makes up the bulk of the inner portion of each tooth crown and root. It extends outward from the pulp cavity (located in the center of the tooth) to the inner boundary of the enamel (covering the crown) or cementum (covering the root). Dentin is not normally visible except on a dental radiograph, or when the enamel or cementum has been worn away, or cut away when preparing a tooth with a bur, or destroyed by decay. Mature dentin is composed of about 70% mineralized calcium hydroxyapatite making it less hard (and less brittle) than enamel, but harder than cementum.

T e **dentinoenamel** [DEN tin o ehn AM el] **junction** is the inner surface of the enamel where enamel joins dentin. T is junction can be best seen on a radiograph (Fig. 1-11). T e **cementodentinal** [se MEN toe DEN tin al] (or dentinocemental) **junction** is the inner surface of cementum where cementum joins dentin. Cementum is so thin that it is difficult to identify this junction on a radiograph.

Pulp is soft, nonmineralized connective tissue containing a rich supply of blood vessels and nerves located in the cavity or space in the center of the crown and root called the **pulp cavity**. T e pulp cavity has a coronal portion toward the crown called a **pulp chamber** and a portion within the roots called a **pulp canal** or **root canal**. T e pulp cavity is surrounded by dentin, except at a hole (or holes) near the root tip (apex) called an **apical** [APE i kal] **foramen** [fo RAY men] (plural foramina [fo RAM i na]). Nerves and blood vessels enter the pulp canals through these apical foramina. Like dentin, the pulp is normally not visible, except on a dental radiograph (Fig. 1-11) or on a sectioned tooth. Functions of the dental pulp are as follows:

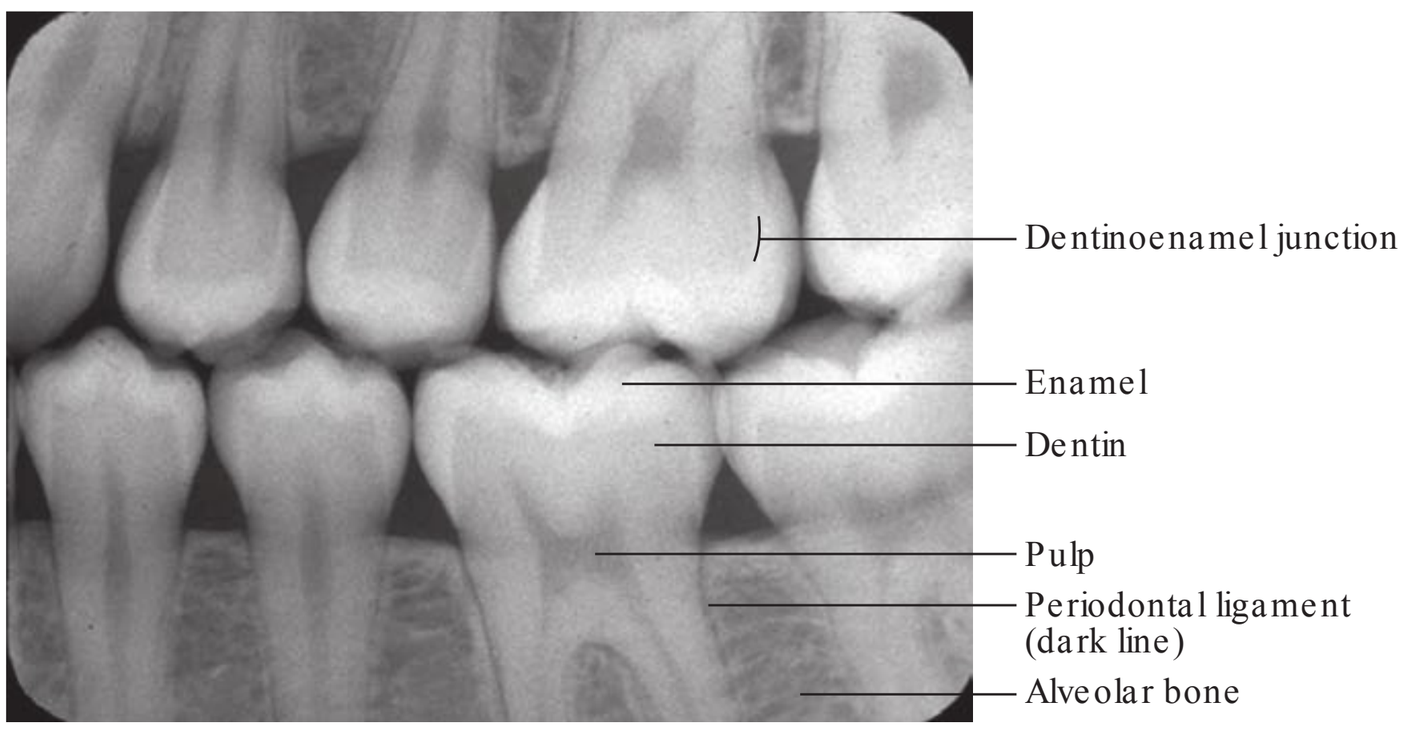

FIgur E 1-11. A radiographs (x-ray) shows tooth crowns covered with enamel, and the tooth roots embedded within the alveolar bone. You can distinguish the whiter outer ena**m**el shape from the darker inner dentin. The pulp cha**m**ber in the middle of the tooth is the darkest. The very thin, dark peri**o**d**o**ntal liga**m**ent can also be seen between the root and the bone, but the cementum is so thin it cannot be seen.

- **Formative**: Dentin-producing cells (**odontoblasts**) produce dentin throughout the life of a tooth. T is normally maturing dentin is called **secondary dentin**.
- **Sensory**: Nerve endings in the pulp relay the sense of pain caused from heat, cold, drilling, sweet foods, decay, trauma, or infection to the brain, so we feel it. However, the nerve fibers in a dental pulp are unable to distinguish the cause of the pain.
- **Nutritive**: Blood vessels transport nutrients from the bloodstream to cells of the pulp and the cells that produce dentin (odontoblasts). Surprisingly, blood being pumped into the tooth pulp had passed through the heart only 6 seconds previously.
- **Defensive or protective**: Pulp responds to injury or decay by forming **reparative dentin** (by the odontoblasts).

Some advanced information on the embryology of tooth tissues that had been included in this chapter in previous editions is now presented at the end of the chapter in a section called "Advanced Topics."

r EvIEw Questions about Tooth Tissues

T ese questions were designed to help you confirm that you understand the terms and concepts presented in this section. More than one answer may be correct.

1. Which tooth junctions are NOT normally visible on a handheld intact tooth?
   a. Cementoenamel junction
   b. Dentinoenamel junction
   c. Dentinocemental junction
   d. Dentinopulpal junction
2. Which mineralized tissue is the hardest?
   a. Cementum
   b. Pulp
   c. Dentin
   d. Enamel
   e. Alveolar bone
3. What tissue forms the outer boundary of almost all of a pulp chamber?
   a. Enamel
   b. Dentin
   c. Cementum
   d. Alveolar bone
   e. Periodontal ligament
4. Which of the following is (are) NOT functions of the pulp?
   a. Taste sweet and sour
   b. Sense pain
   c. Provide nutrition to dentin
   d. Produce new dentin
   e. Produce new enamel

e, a–4; b–3; d–2; d, c, b–1: Sr E wS Na

SECTION Iv INTr Od u CTION TO Th E pEr IOd ONTIu m (a Nd d EFINITION OF CLINICa L Cr Ow N a Nd r OOT)

T e **periodontium** [pair ee o DON she um] is defined as the supporting tissues of the teeth in the mouth, including surrounding alveolar bone, the gingiva, the periodontal ligament, and the outer, cementum layer of the tooth roots (Fig. 1-12). **Alveolar bone** is the portion of the upper (maxillary) or lower (mandibular) bones that surrounds the roots of the teeth. T e **gingiva** is the part of the soft tissue in the mouth that covers the alveolar bone of the jaws and is the only part of the periodontium that is visible in a healthy mouth. Part of it is firmly bound to the underlying alveolar bone and is called **attached gingiva**. T e other part is **free gingiva** (or marginal gingiva), which is a collar of thin gingiva that surrounds each tooth and, in health, adapts to the tooth but provides access into the potential space between the free gingiva and the tooth, which is called a **gingival sulcus** (crevice). T e **gingival margin** (or free gingival margin) is the edge of the gingiva closest to the biting or chewing surfaces of the teeth (Fig. 1-13).

T e gingival sulcus is not seen visually but can be evaluated with a thin probe (**periodontal probe**), since it is actually a space (or potential space) between the tooth surface and the narrow unattached cervical collar of free gingiva. If you insert a periodontal probe into this sulcus, it should extend only 1 to 3 mm deep in a healthy person (Fig. 1-14). T e **interdental (interproximal) papilla** [pah PILL ah] (plural is papillae [pa PILL ee]) is that part of the collar of free gingiva that extends between the teeth. A healthy papilla conforms to the space between two teeth (interproximal space), so it is very thin and easy to damage near where the adjacent teeth contact. T e papilla also has a hidden sulcus where dental f oss can fit once it passes between the teeth (Fig. 1-15). T e f oss must curve around the tooth to avoid cutting into the interdental papilla.

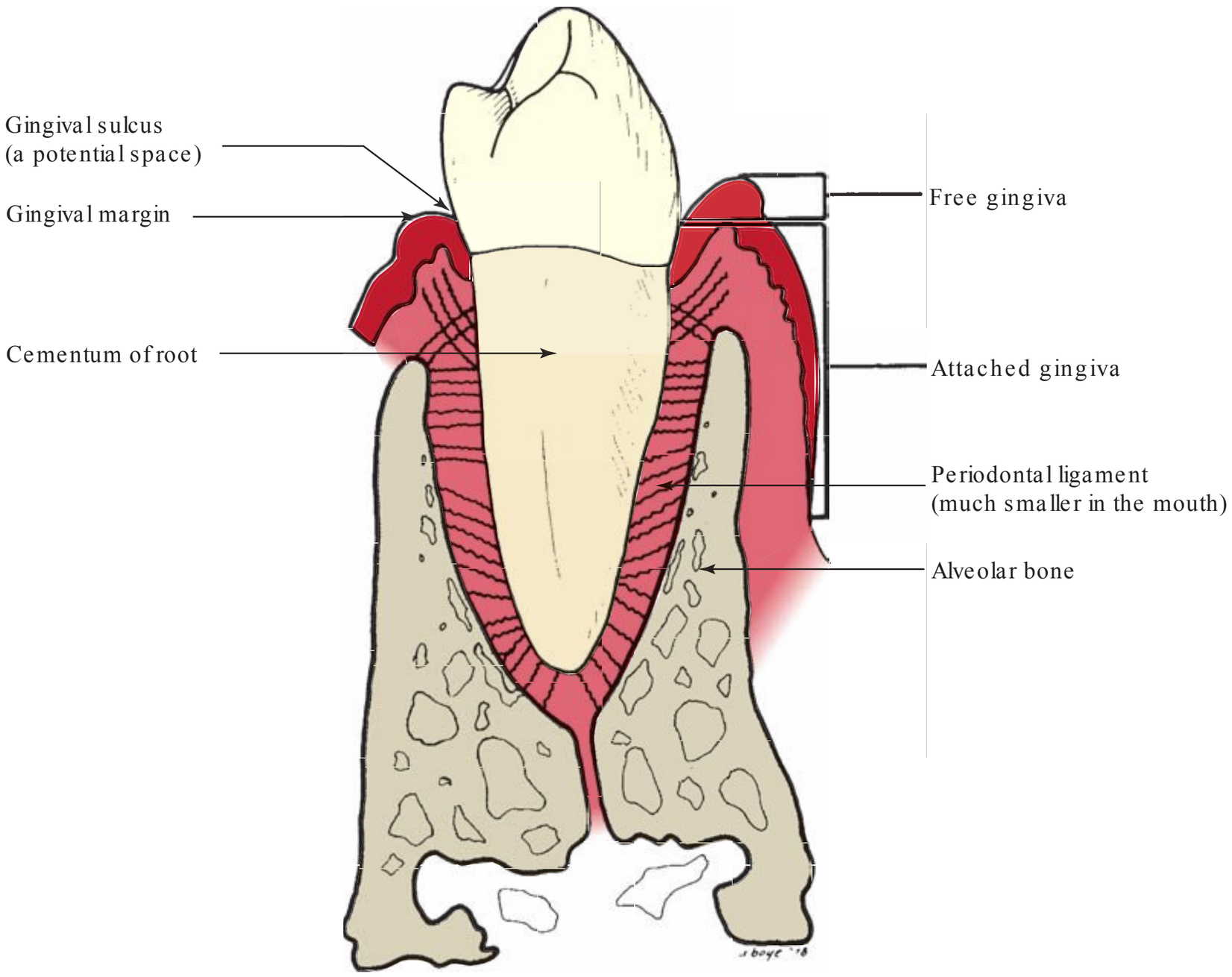

FIgur E 1-12. This diagram is a tooth supported within the peri**o**d**o**ntiu**m**. The periodontium is made up of alve**o**lar b**o**ne, which surrounds the anatomic root; gingiva (gum tissue), which covers the bone; ce**m**entu**m**, which covers the tooth root; and the peri**o**d**o**ntal liga**m**ent, which attaches the cementum of the tooth root to the bone.

Although the term ligament is most often defined as a tough fibrous band of tissue that connects two bones, a **periodontal ligament** (abbreviated **PDL**) is a very thin ligament that connects a tooth to its surrounding bone. It is composed of many microscopic tissue fibers that attach the outer layer of the tooth root (covered with **cementum**) to the thin layer of dense **alveolar bone** surrounding each tooth. T e fibers of the periodontal ligament represented in Figure 1-12 are greatly enlarged. T e average thickness of a healthy periodontal ligament is only about one to four times thicker than the diameter of an average healthy human hair.

CLINICAL CROWN AND ROOT: As mentioned previously, the anatomic crown is that part of the tooth (in the mouth or handheld) normally covered by an enamel layer, and the anatomic root is the part of a tooth covered by cementum (recall Fig. 1-10). However, when the tooth is in the mouth, the amount of the tooth that is visible in the oral cavity (i.e., not covered with gingiva) is called the **clinical**

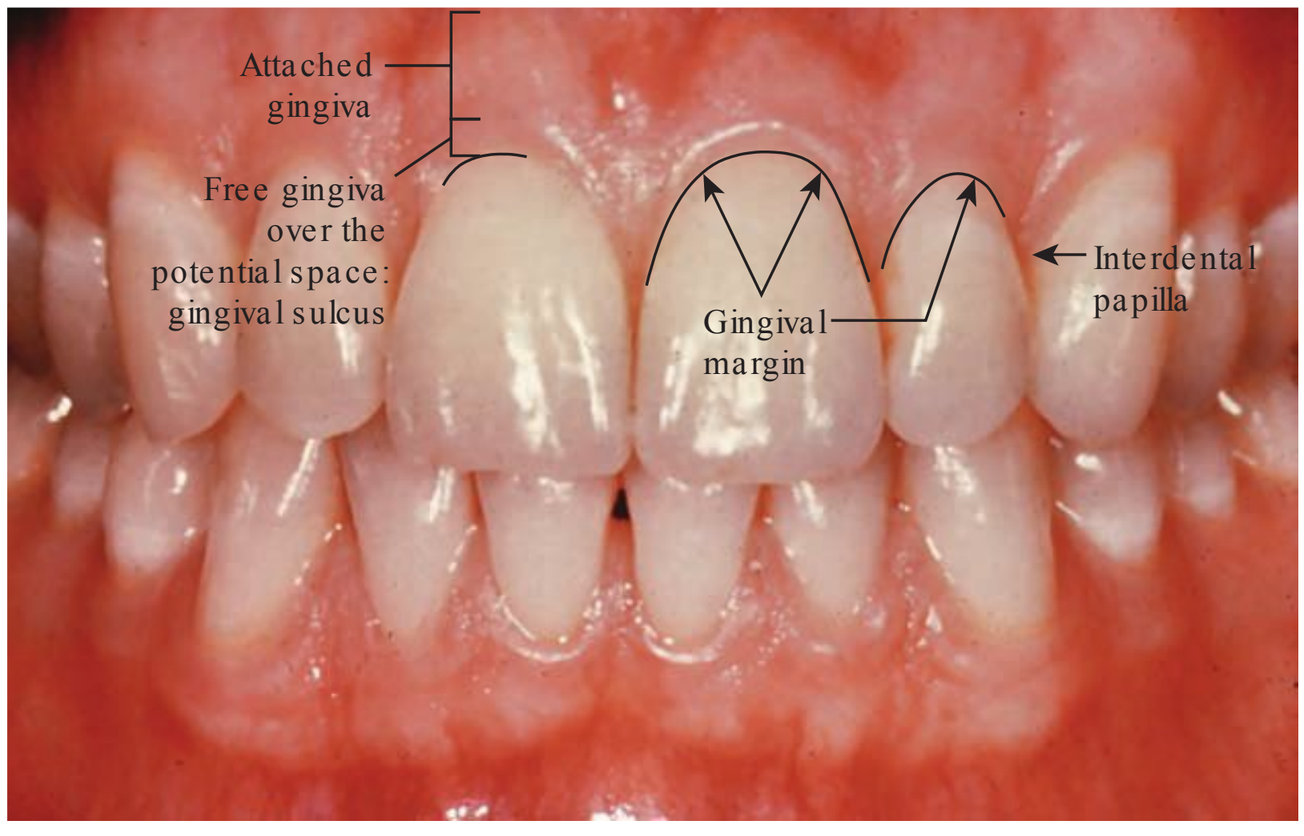

FIgur E 1-13. Healthy gingiva surrounds each tooth forming a characteristic scallop-shaped gingival **m**argin. Interpr**o**xi**m**al papillae fill the spaces between most teeth. The attached gingiva is the gingiva that is firmly attached to the underlying bone.



FIgur E 1-14. A periodontal probe is carefully placed into the gingival sulcus.



FIgur E 1-15. Dental foss must adapt around the curved surface of each tooth when entering the gingival sulcus in order to clean the proximal surface of the tooth and avoid damaging the free gingiva.

crown, and the portion of the tooth that is not visible since it is covered with gingiva is called the **clinical root**. When the gingival margin in a 25-year-old patient with healthy gingiva approximately follows the curvature of the cervical line, the clinical crown is almost the same as the anatomic crown (Fig. 1-16A). However, throughout life, the gingival margin is not always at the level of the cervical line because of the eruption process. For example, the gingiva on a partially erupted tooth of a 10-year-old covers much of the enamel of the anatomic crown of the tooth, resulting in a clinical crown (exposed in the mouth) that is much shorter than the anatomic crown (Fig. 1-16B). T e clinical root (the part of the tooth not visible in the mouth) would be longer than the anatomic root, since it includes all of the anatomic root plus the part of the anatomic crown covered with gingiva.

In contrast, the gingival margin of an older person may exhibit gingival recession, especially after having periodontal disease or periodontal therapy, exposing more of the anatomic root. In this case, the clinical crown is longer than the anatomic crown since the clinical crown in this mouth consists of the entire anatomic crown plus the part of the anatomic root that is exposed (Fig. 1-16C). In this situation, the clinical root is shorter than the anatomic root.

LEARNING EXERCISE

Examine the mouths of several persons of different ages to see if the cervical line of each anatomic tooth is visible or hidden. As the individual grows older, the location of the margin of the gingiva may recede toward the root tip (apically) because of periodontal disease or injury. Of course, the location of the cervical line on the tooth remains the same. In other words, the distinction between the anatomic crown and root does not change over a lifetime.



A

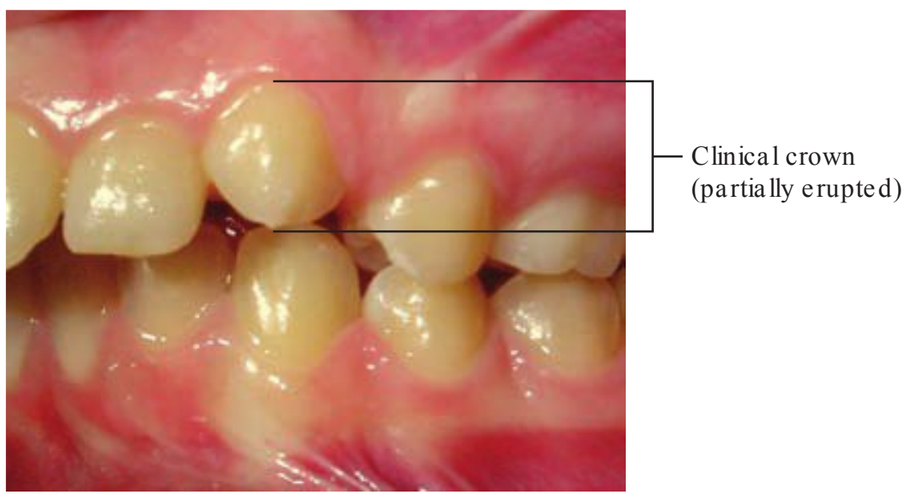

B

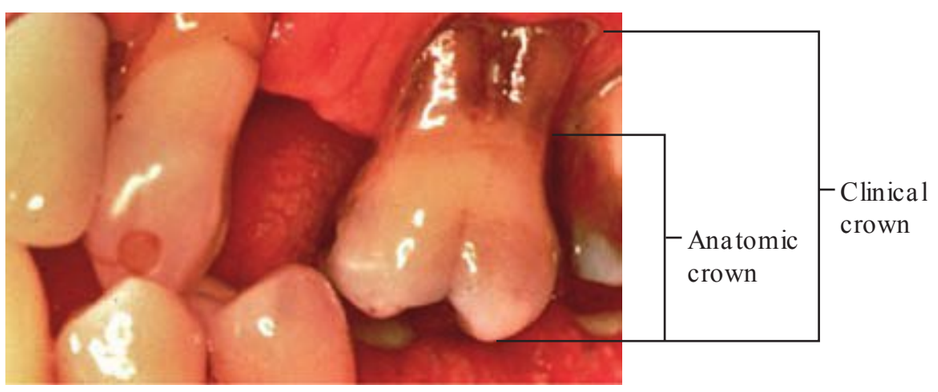

C

FIgur E 1-16. A. On a young adult with healthy gingiva, the entire anatomic crown is all that can be seen, so the clinical cr**o**wn is approximately the same as the anat**om**ic cr**o**wn. B. Since this canine is partially erupted, the anatomic crown is only partially exposed, so there is a sh**o**rt clinical cr**o**wn. C. This maxillary molar has a very l**o**ng clinical cr**o**wn since all of the anatomic crown and much of the anatomic root are exposed due to recession of the gingiva and loss of bone.

? r EvIEw Questions about the Periodontium

T ese questions were designed to help you confirm that you understand the terms and concepts presented in this section. More than one answer may be correct.

1. Which statement(s) is (are) likely to be true on a person with a barely erupted tooth 9?
   a. T e clinical crown is larger than the anatomic crown.
   b. T e clinical crown is smaller than the anatomic crown.
   c. T e clinical root is larger than the anatomic root.
   d. T e clinical root is smaller than the anatomic root.

2. Which statement(s) is (are) true regarding a tooth on a person who has lost most of the bone and gingiva surrounding the tooth?
   a. T e clinical crown is larger than the anatomic crown.
   b. T e clinical crown is smaller than the anatomic crown.
   c. T e clinical root is larger than the anatomic root.
   d. T e clinical root is smaller than the anatomic root.

3. Which of the following structures is (are) NOT part of the periodontium?
   a. Alveolar bone
   b. Periodontal ligament
   c. Gingival margin
   d. Cementodentinal junction
   e. Attached gingiva

4. T e periodontal ligament attaches the alveolar bone to what tooth tissue?
   a. Dentin
   b. Enamel
   c. Cementum
   d. Pulp

c–4; d–3; d, a–2; c, b–1: Sr E wS Na

SECTION v TEr mINOLOg y u SEd TO d EFINE TOOTh Su r Fa CES

All teeth have surfaces that are named according to their normal, ideal alignment within the dental arch. Refer to Figure 1-17 when studying the terms to denote tooth surfaces.

a. TEr mS Th aT Id ENTIFy Ou TEr Su r Fa CES (TOw a r d Th E Ch EEkS Or LIpS) OF a NTEr IOr v Er Su S pOSTEr IOr TEETh

T e **facial surface** of a tooth is the surface toward the face, that is, the surface of a tooth in the mouth resting against or next to the cheeks or lips. Facial may be used to designate this surface of any tooth, anterior or posterior. Another name for the facial surface of posterior teeth is **buccal** [BUCK k'l], located next to the cheek (labeled on tooth 3 in Fig. 1-17). Dental terms that begin with "bucc" refer to a relationship or proximity to the cheek. It is incorrect to use the term buccal when speaking about the incisors or canines because the facial surface of these teeth does not approximate the cheeks. T e facial surface of anterior teeth is properly called a **labial** [LAY bee al] surface, located next to the lips (labeled on tooth 6 in Fig. 1-17). T e term labial should not be used when referring to the premolars or the molars.

B. TEr mS Th aT Id ENTIFy INNEr Su r Fa CES (TOw a r d Th E TONg u E) OF ma xILLa r y v Er Su S ma Nd IBu La r TEETh

T e **lingual** [LIN gwal] **surface** is the surface of a maxillary or mandibular tooth nearest to the tongue (labeled on tooth 5 in Fig. 1-17). In the maxillary arch, this surface can also be called the **palatal surface** due to its proximity with the palate.

C. TEr mS Th aT d IFFEr ENTIa TE BITINg Su r Fa CES OF a NTEr IOr v Er Su S pOSTEr IOr TEETh

T e **occlusal** [ahk KLOO zal] **surface** is the chewing surface of a posterior tooth (labeled on tooth 2 in Fig. 1-17). Anterior teeth (incisors and canines) do not have an occlusal surface but do have a cutting **incisal edge** or **ridge** (labeled on tooth 8 in Fig. 1-17).

d. TEr mS Th aT d IFFEr ENTIa TE a ppr OxIma TINg Su r Fa CES OF TEETh

T e **proximal** [PROCK se mal] **surfaces** are the sides of a tooth next to an adjacent tooth. Depending on whether the proximal tooth surface faces toward the arch midline between the central incisors or away from the midline, it is either a **mesial** [MEE zi al] surface (closer to the midline) or a **distal** [DIS tal] surface (farther from the midline). Mesial and distal surfaces are labeled on tooth 1 in Figure 1-17. Note that the mesial surface of a tooth touches, or is closest to, the distal surface of an adjacent tooth EXCEPT between the central incisors where the mesial surface of the right central incisor faces the mesial surface of the left central incisor. Also, the distal surface of the last (third) molar in each arch does not approximate another tooth.

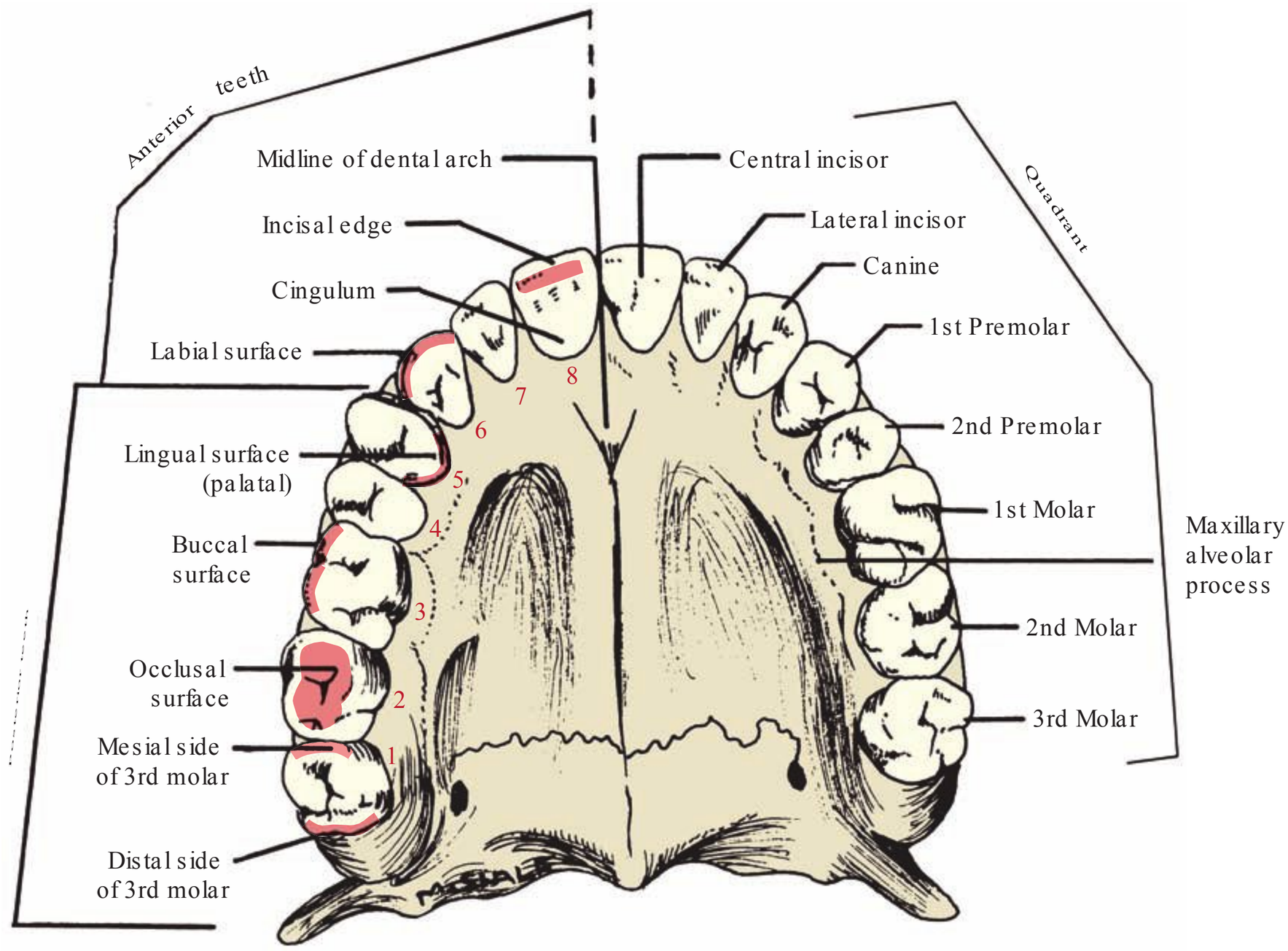

FIgur E 1-17. Maxillary dental arch of teeth with various t**oo**th sur**f**aces labeled. Remember that the labial surface of an anterior tooth and the buccal surface of a posterior tooth are both referred to as facial surfaces. Also, the mesial and distal sides or surfaces are both correctly called proximal surfaces.

Soft debris and food particles on proximal surfaces are not easily cleaned by the action of the cheeks, lips, and tongue when compared to most of the facial or lingual surfaces, which are considered more **self-cleansing**, that is, more easily able to be cleaned by the rubbing action of the cheeks, lips, and tongue.

E. TEr mS TO d ENOTE TOOTh Su r FaCE Ju NCTIONS Or d ImENSIONS

T e junction line where two tooth surfaces meet is called an external **line angle**. To name a line angle, combine the names of the two surfaces, but change the "al" ending of the first surface to an "o." (A guideline has been suggested for the order used when combining terms. Use the following order: mesial is used first; then distal, facial, [buccal or labial] or lingual; and lastly occlusal or incisal. Using this guideline, it is better to say mesio-occlusal than occlusomesial, and it is better to say distolingual than linguodistal.) Examples of external line angles of a molar crown include mesio-occlusal, mesiolingual, mesiofacial, disto-occlusal, distolingual, disto-facial, bucco-occlusal, and linguo-occlusal. **Point angles** are the junctions of three tooth surfaces at a point, such as a mesiobucco-occlusal point angle. Examples of these external line angles and point angles are seen in Figure 1-18.

To describe a **dimension of a tooth**, terms can be combined to denote the direction over which a dimension is taken. For example, the length of an incisor crown from the incisal edge to the cervical line is called the incisocervical dimension or the dimension incisocervically, and the width of the buccal surface of a molar crown from the mesial surface to the distal surface is the mesiodistal dimension (Fig. 1-18). Other examples of terms used to describe a crown dimension include mesiodistal, faciolingual or buccolingual, and occlusocervical. T e length of a root could be described as its cervicoapical dimension.

r EvIEw Questi**o**ns ab**o**ut Di**m**ensi**o**ns

1. What surface(s) of a tooth would you be looking at in order to determine the mesiodistal dimension of a molar?
2. What surface(s) of a tooth would you be looking at when measuring the buccolingual dimension of a molar?

secafr us l as ulcco r o,l atsi d,l aise M-2; secafr us l as ulcco r o,l augril ,l accuB–1: Sr E wS Na

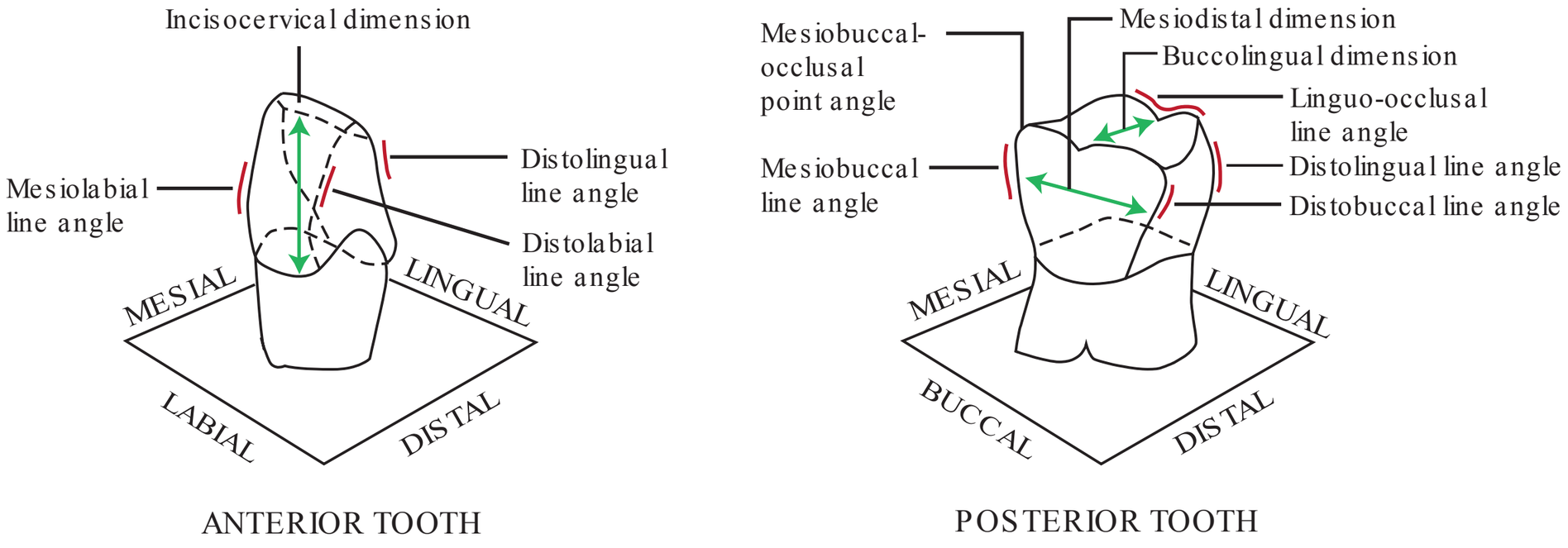

FIgur E 1-18. Diagrammatic representations of an incisor and a molar crown have several examples of line angles and p**o**int angles labeled in red. Three examples describing di**m**ensi**o**ns are labeled in green.

F. d IvISIONS (Th Ir d S) OF Th E Cr Ow N Or r OOT (FOr pu r pOSES OF d ESCr IpTION)

A tooth can be divided into **thirds** in order to define more precisely the location of its specific landmarks such as proximal contacts. When viewing a tooth from the facial, lingual, mesial, or distal surface, horizontal lines can divide the tooth crown into the following thirds: cervical, middle, and occlusal (or incisal) (Fig. 1-19). Similarly, horizontal lines can divide the root into thirds: cervical, middle, and apical (toward the root tip or apex).

When viewing the facial or lingual surfaces of a tooth, vertical lines can be used to divide the crown or root into mesial, middle, and distal thirds. When viewing proximal (mesial or distal) surfaces, vertical lines can be used to divide the crown or root into facial, middle, and lingual thirds. When viewing a tooth from the occlusal (or incisal) surface, lines running mesiodistally can be used to divide the crown into facial, middle, and lingual thirds, and lines running faciolingually can be used to divide the tooth into mesial, middle, and distal thirds.

g. r OOT-TO-Cr Ow N r aTIO

If we know the length of a tooth root from the cervical line to the tip of the root, and the length of the crown (as defined at the end of this chapter in Dr. Woelfel's original research data), we can calculate a root-to-crown ratio. T e **root-to-crown**

FIgur E 1-19. Diagrams of a maxillary canine and mandibular molars show how a crown or root can be divided into thirds from each view.

ratio is the root length divided by crown length. Since almost all tooth roots are longer than their crowns, the root-to-crown ratios for teeth are normally greater than 1.0. For example, the average root length of a maxillary central incisor is only 13.0 mm and the crown length is 11.2 mm. The root-to-crown ratio is 13 divided by 11.2, which equals 1.16. When this number is close to 1, it indicates that the root is not much longer than the crown. Compare this with a maxillary canine, where the average root is much longer, at 16.5 mm, but the crown is only 10.6 mm, for a much larger root-to-crown ratio of 1.56. This larger ratio indicates that the root is over one and a half times (1.56 times) longer than the crown. The obvious difference between the root-to-crown ratio on these two teeth is apparent in Figure 1-20. The ratio can be clinically significant, since a tooth with a small root-to-crown ratio (closer to 1) is not the best choice for attaching and supporting false teeth, because the additional attached teeth would apply even more force on a tooth that already has a short root compared to its crown length. Therefore, the long-term success of attaching false teeth to a tooth like the maxillary canine with a large root-to-crown ratio of 1.56 would be better than attaching it to a tooth like the maxillary central incisor with a small root-to-crown ratio of 1.16.

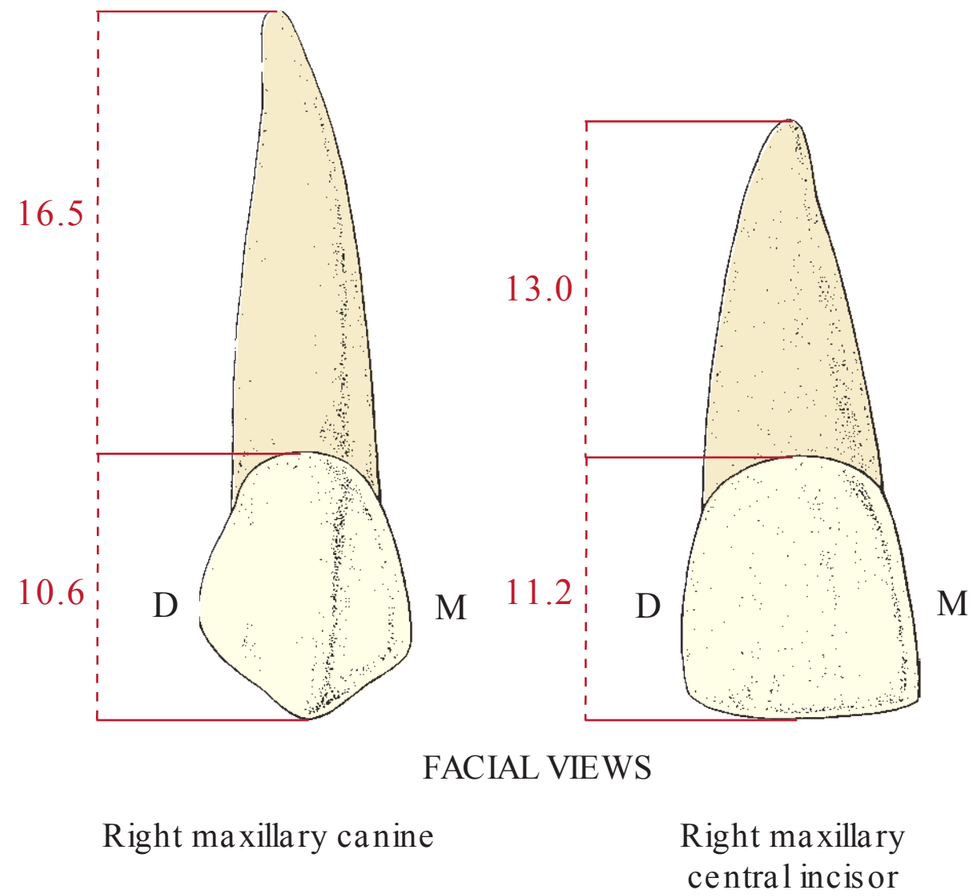

FIGURE 1-20. Compare the root-to-crown ratio of a maxillary central incisor where the root is not much longer than the crown and the ratio is 13 mm of crown length divided by 11.2 mm of root length, or only 1.16, with a maxillary canine where the root is considerably longer than the crown so the ratio is much larger: 16.5 mm crown length divided by 10.6 mm root length, or 1.56.

REVIEW Questions about Tooth Terminology

These questions were designed to help you confirm that you understand the terms and concepts presented in this section. More than one answer may be correct.

1. Which tooth surface(s) face(s) the lips or cheeks?
   a. Facial
   b. Distal
   c. Buccal
   d. Occlusal
   e. Labial

2. Which pairs of teeth have a mesial surface touching a mesial surface?
   a. 25 and 26
   b. 16 and 17
   c. 7 and 8
   d. 1 and 32
   e. 8 and 9

3. Which teeth have a distal surface that does not normally contact another tooth?
   a. 1
   b. 3
   c. 8
   d. 17
   e. 24

4. The term labial refers to association with or proximity to the lips, and the term _____ refers to association with or proximity to the cheeks.
   a. Facial
   b. Buccal
   c. Labial
   d. Proximal
   e. Palatal

5. When viewing tooth 8 from the distal view, it can be divided into thirds from the incisal to the cervical and from the facial to the lingual. Which third is NOT possible to see from the distal view?
   a. Facial
   b. Cervical
   c. Middle
   d. Mesial
   e. Incisal

6. When viewing tooth 19 from this one view, it can be divided into thirds from the buccal to lingual and from the mesial to the distal. From which view is this possible?
   a. Buccal
   b. Lingual
   c. Mesial
   d. Distal
   e. Occlusal

7. If you were observing the faciolingual dimension of a tooth, what surface(s) could you be viewing?
   a. Mesial
   b. Occlusal
   c. Proximal
   d. Labial
   e. Distal

8. If the root-to-crown ratio of a maxillary molar (tooth 14) is 1.72 and that of a maxillary incisal (tooth 8) is 1.16, which tooth has the longest root relative to its shorter crown?
   a. Tooth 14.
   b. Tooth 8.
   c. More information is required in order to answer this question.

9. Which of the following phrases are correct?
   a. Buccal surface of tooth 10
   b. Labial surface of tooth 19
   c. Palatal surface of tooth 29
   d. Occlusal surface of tooth 27
   e. Facial surface of tooth 1

10. Which term does NOT refer to a tooth crown line angle?
    a. Mesio-occlusal
    b. Mesiofacial
    c. Mesiodistal
    d. Distofacial
    e. Linguo-occlusal

c–01; e–9; a–8; e, c, b, a–7; e–6; d–5; b–4; d, a–3; e–2; e, c, a–1: Sr E wS Na

SECTION vI TEr mINOLOg y u SEd TO d ESCr IBE Th E mOr ph OLOg y OF a TOOTh

a. mOr ph OLOg y OF a N a NaTOmIC Cr Ow N

Teeth are made up of many rounded elevations, ridges, depressions, and grooves. Specific tooth structures that occur with some frequency on teeth within a class have been assigned specific names. To identify the following anatomic structures, reference will be made to representative drawings of various teeth seen in figures throughout this book.

1. Elevations: pointed Cusps and Linear r idges

a. Cusps: Cusp Names and Numbers

A **cusp** is a pyramidal elevation with a peak called a **cusp tip**. Cusps are located on the occlusal surfaces of molars and premolars and on the incisal surfaces of canines. Canines have one cusp, premolars normally have two or three cusps, and most molars have from three to five cusps. On teeth with multiple cusps, each cusp is named according to its location on the tooth. For example, on a two-cusped premolar, the two cusps are named after the surface adjacent to each cusp: a buccal cusp and a lingual cusp. T ree-cusped premolars have one buccal and two lingual cusps, and the two lingual cusps are named after the adjacent line angles, that is, mesiolingual cusp and distolingual cusp. A four-cusped molar has four cusps named after the adjacent line angles: mesiobuccal, distobuccal, mesiolingual, and distolingual. A three-cusped maxillary molar has two buccal cusps (mesiobuccal and distobuccal) and one lingual cusp. On a five-cusped molar, the three buccal cusps are called mesiobuccal, distobuccal, and the smallest distal cusp. Refer to Figure 1-21 for examples of cusp names on posterior teeth with two, three, four, and five cusps.

b. Cusp Ridges

Many cusps can be thought of as having four **cusp ridges** (linear prominences of enamel) converging toward the cusp tip. T ese four ridges form the shape of a four-sided pyramid with rounded surfaces. If you draw a line along the greatest linear bulge of each of these four ridges, the lines would intersect at the cusp tip indicated by the “X” on Figure 1-22. On this example of a buccal cusp on a

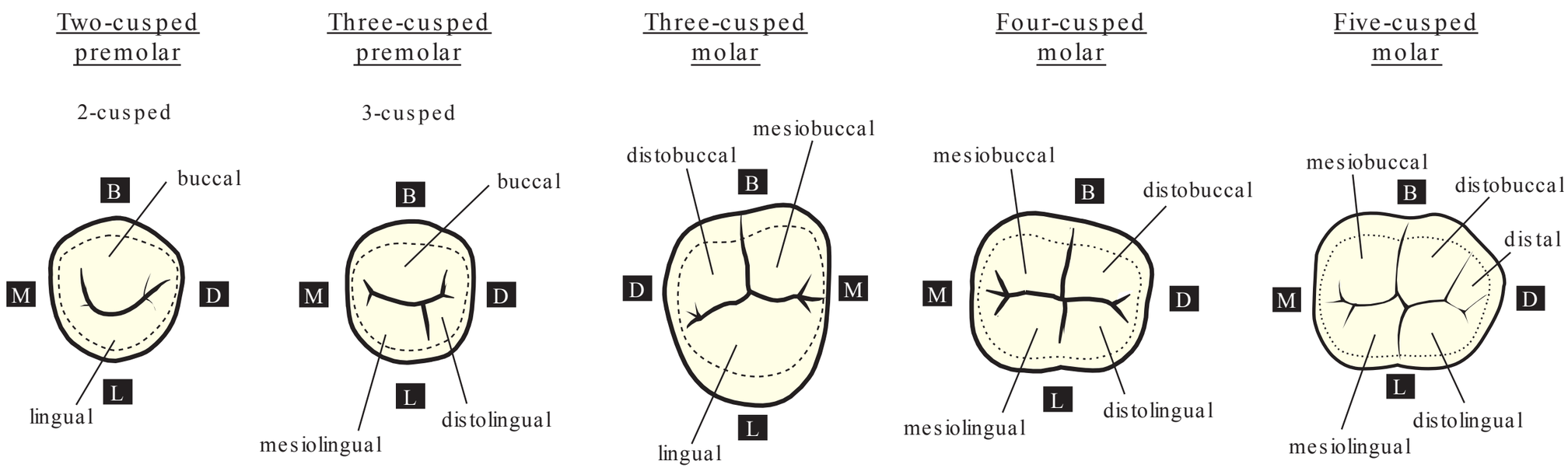

FIgur E 1-21. Cusp na**m**es on teeth having two, three, four, and five cusps, viewed from the occlusal and buccal views. Notice that the cusps are named after the adjacent surface or line angle EXCEPT on five-cusped mandibular first molars with three buccal cusps. On five-cusped molars, the two larger buccal cusps are named **m**esi**o**buccal and dist**o**buccal cusps, as on the four-cusped molar, but the smallest cusp is called the distal cusp.

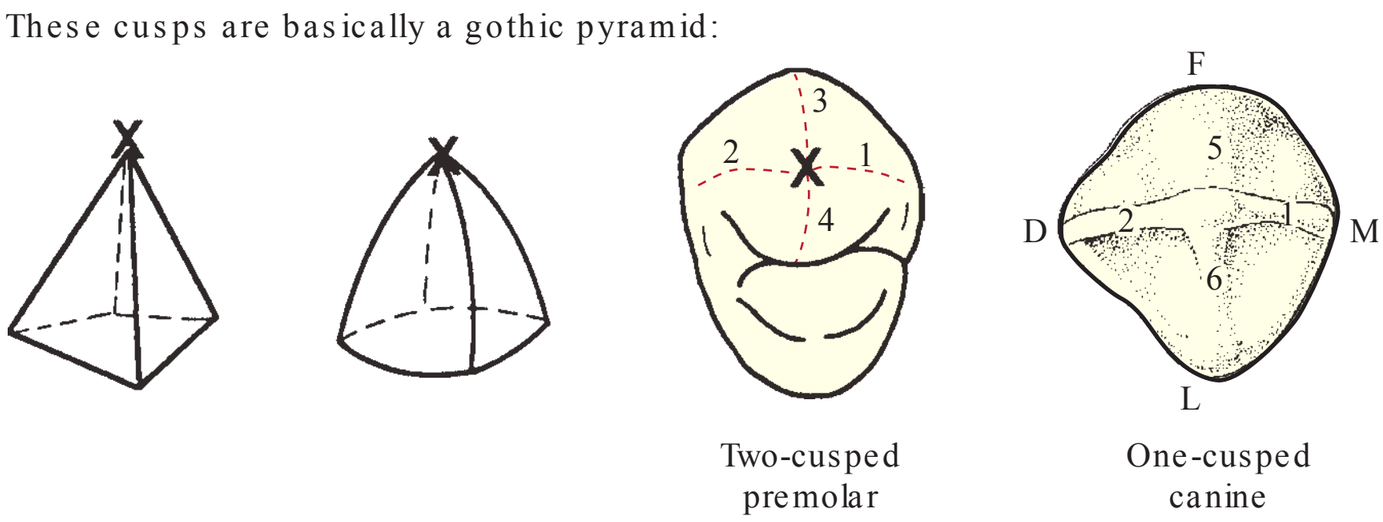

FIgur E 1-22. The **fo**ur-cusped ridges of the buccal cusp of a two-cusped premolar have a somewhat pyramidal design (actually, a pyramid with rounded sides called a gothic pyramid). The cusp ridges are numbered 1 to 4 and converge at the cusp tip (at the "X"). Ridge 1 is the **m**esial cusp ridge of the buccal cusp; ridge 2 is the distal cusp ridge of the buccal cusp; ridge 3 is the more subtle buccal ridge of the buccal cusp; and 4 is the triangular ridge of the buccal cusp. (Courtesy of Drs. Richard W. Huffman and Ruth Paulson.) Cusp ridges on the single cusp of a maxillary canine also have a mesial cusp ridge labeled 1 and distal cusp ridge labeled 2, the same as on the premolar, but 5 is the labial ridge of the canine cusp (similar to a buccal ridge on a premolar), and 6 is the lingual cusp ridge.

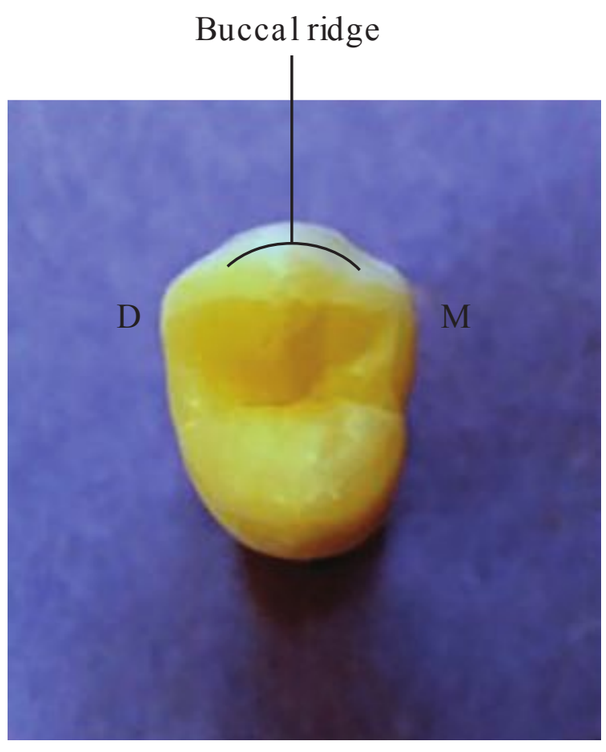

FIgur E 1-23. A rounded buccal ridge can be seen on the buccal surface of many premolars.

premolar, three of the ridges are named after the circumferential tooth surface they extend toward: the more subtle **buccal ridge** extends onto the buccal surface, the **mesial cusp ridge** extends from the cusp tip toward the mesial surface, and the **distal cusp ridge** extends from the cusp tip toward the distal surface. T e fourth ridge extends from the cusp tip toward the faciolingual middle of the tooth and is called a **triangular ridge**.

T e **buccal ridges** that run cervico-occlusally on the buccal surfaces of premolars or molars are often the least distinct of the four ridges that emanate from the cusp tip, although they may be more prominent on some types of teeth (Fig. 1-23). Lingual cusps do not normally have prominent lingual ridges running cervico-occlusally from the cusp tips.

T e **mesial and distal cusp ridges** are also known as **cusp slopes** or **cusp arms**. T ey are most evident when viewing teeth from the facial or lingual aspect where they can be seen as inclined ridges that converge toward the cusp tip to form an angle (seen in green on a buccal cusp of a premolar and on a buccal cusp of a molar in Fig. 1-24). For some teeth, the sharpness or bluntness of a cusp angle can be an defining trait. T ese ridges are more difficult to discern when viewing teeth from the occlusal, denoted in green on the two cusps of a premolar in Figure 1-25.

Triangular ridges are located on the major cusps of posterior teeth. Each triangular ridge extends from a cusp tip toward the depression (sulcus) near the middle of the occlusal surface faciolingually, most easily identified when viewing a proximal surface as on Figure 1-26, but also evident when viewing the occlusal surface as on Figure 1-25. When a triangular ridge from a buccal cusp joins with a triangular ridge from a lingual cusp, these two ridges together form a longer ridge called a **transverse ridge**. A transverse ridge crosses the occlusal surface of posterior teeth in a more or less buccolingual direction, running between the buccal and lingual cusps on a premolar (seen from an occlusal view and a proximal view in Figs. 1-25 and 1-26) or connecting the buccal and lingual cusps that are lined up across from one another on a molar (seen on a mandibular molar in Fig. 1-27 and on the two-cusped premolar). An **oblique ridge** is found only on maxillary molars. It crosses the occlusal surface obliquely (diagonally) and is made up of one ridge on the mesiolingual cusp joining with the triangular ridge of the distobuccal cusp (seen in Fig. 1-27 on the maxillary molar). According to Ash,[1] the ridge of the mesiolingual cusp that forms the lingual half of the oblique ridge is the distal cusp ridge of the mesiolingual cusp.

T e single cusp of many canines may also have four ridges emanating from its cusp tip (Fig. 1-22): a mesial cusp ridge and a distal cusp ridge, a **labial ridge** similar to a buccal ridge running cervicoincisally from the cusp tip, and sometimes a fourth ridge called a **lingual ridge** that extends lingually toward the cervical bulge (cingulum). T ese ridges can be prominent on maxillary canines (Fig. 1-28A and B).

c. *Marginal Ridges and Cingulum*

On the lingual of all anterior teeth, a **cingulum** [SING gyoo lum] (plural **cingula**) is the prominence or bulge in the cervical third of the lingual surface of the crown (incisors and canines) (seen on the lingual view in Fig. 1-29 and seen as a prominence in the cervical third of the crown on the proximal view in Fig. 1-30). On anterior teeth, mesial and distal

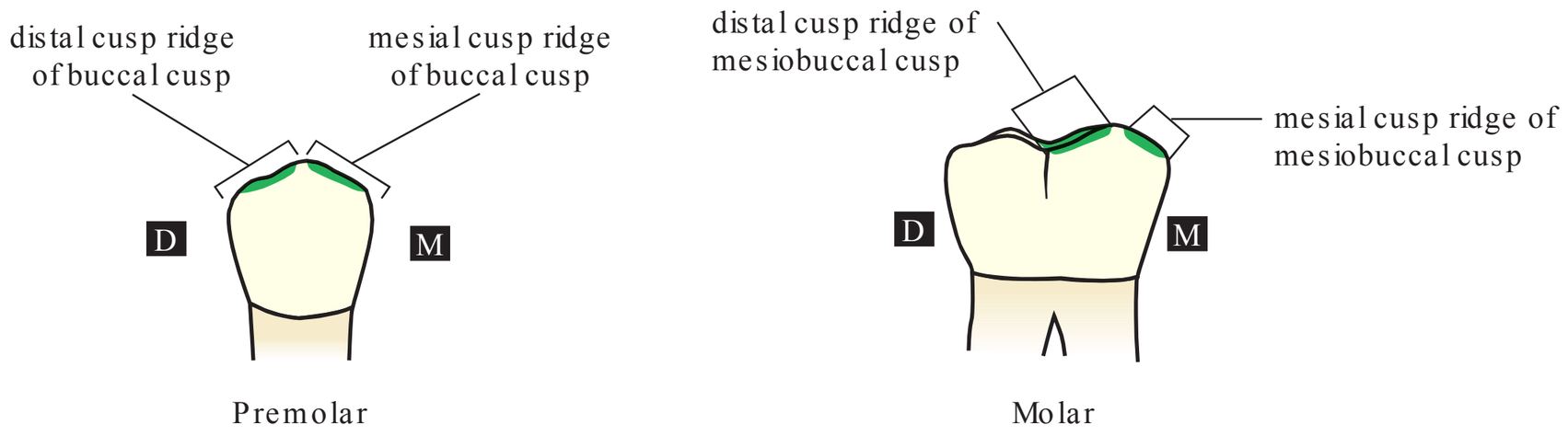

FIgur E 1-24. Cusp ridges (cusp slopes) are labeled on the buccal cusp of a mandibular premolar and on the mesiobuccal cusp of a four-cusped mandibular molar.

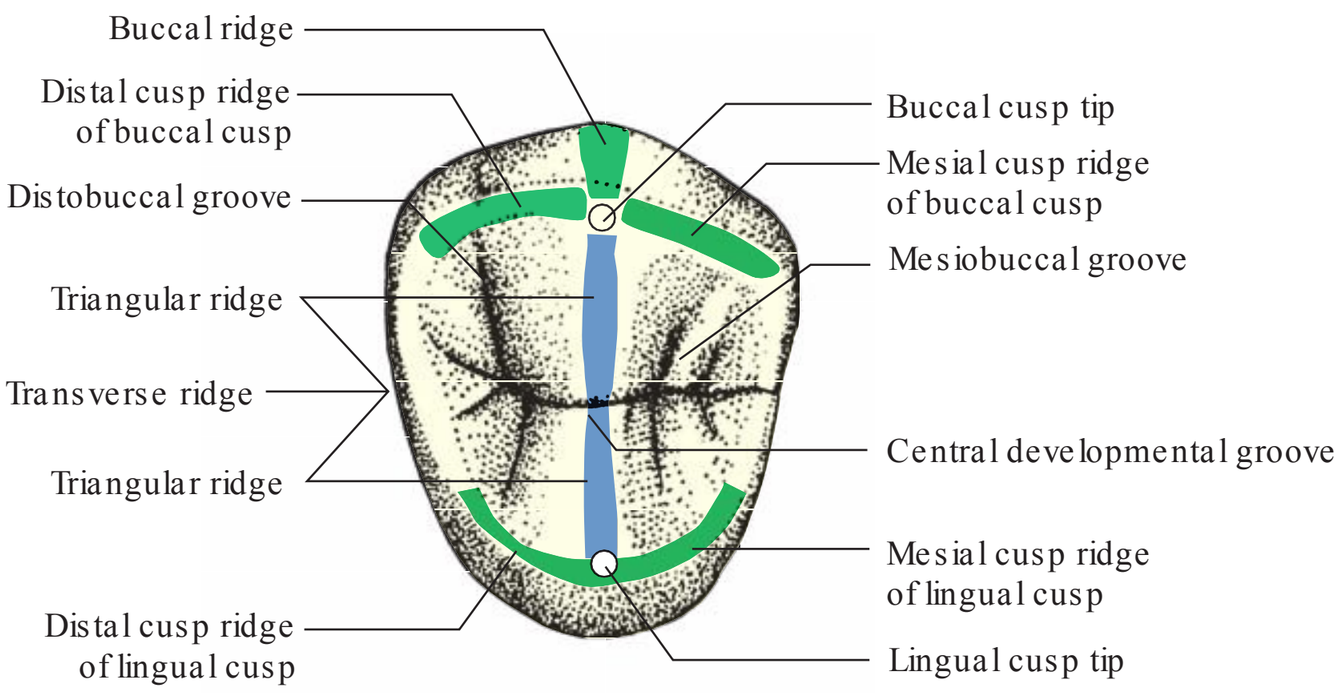

FIgur E 1-25. On this two-cusped maxillary premolar, the **m**esial and distal cusp ridges of the buccal and lingual cusps are shaded green. The triangular ridges of the buccal and lingual cusps are shaded blue and together are called a transverse ridge. The buccal ridge of the buccal cusp is shaded green.

marginal ridges form the mesial and distal borders of the lingual surface, and these ridges converge toward a rounded elevation or bulge in the cervical third called a **cingulum**, as seen on an incisor in Figures 1-29 and 1-30. When distinguishing a mesial from a distal marginal ridge on anterior teeth, it can be useful to remember that the mesial marginal ridge is normally longer than the distal. When determining which marginal ridge is longer, think of the length of a marginal ridge as extending from the incisoproximal line angle to its junction with the cingulum (as on Fig. 1-29 where the mesial marginal ridge appears slightly longer than the distal marginal ridge).

On posterior teeth, marginal ridges form the mesial and distal borders of the occlusal surface. T e mesial marginal ridge on a premolar is shaded red in Figure 1-31.

d. *Occlusal Table Outline versus Crown Outline*

When viewing posterior teeth from the occlusal view, it is important to distinguish the entire crown outline of the tooth from the occlusal table of that tooth. T e **occlusal crown outline** is the outer outline of the entire tooth crown from the occlusal view, whereas the **occlusal table** is the occlusal surface that is bounded by the continuous cusp ridges and marginal ridges. On the premolar in Figure 1-31, the occlusal table is bounded by a mesial marginal ridge joined with the mesial and distal cusp ridges of the buccal cusp, then the distal marginal ridge, and the cusp ridges of the lingual cusp.

T is would be a good time to refer to Figure 1-32 and perform the learning exercise to test your knowledge of cusp ridges.

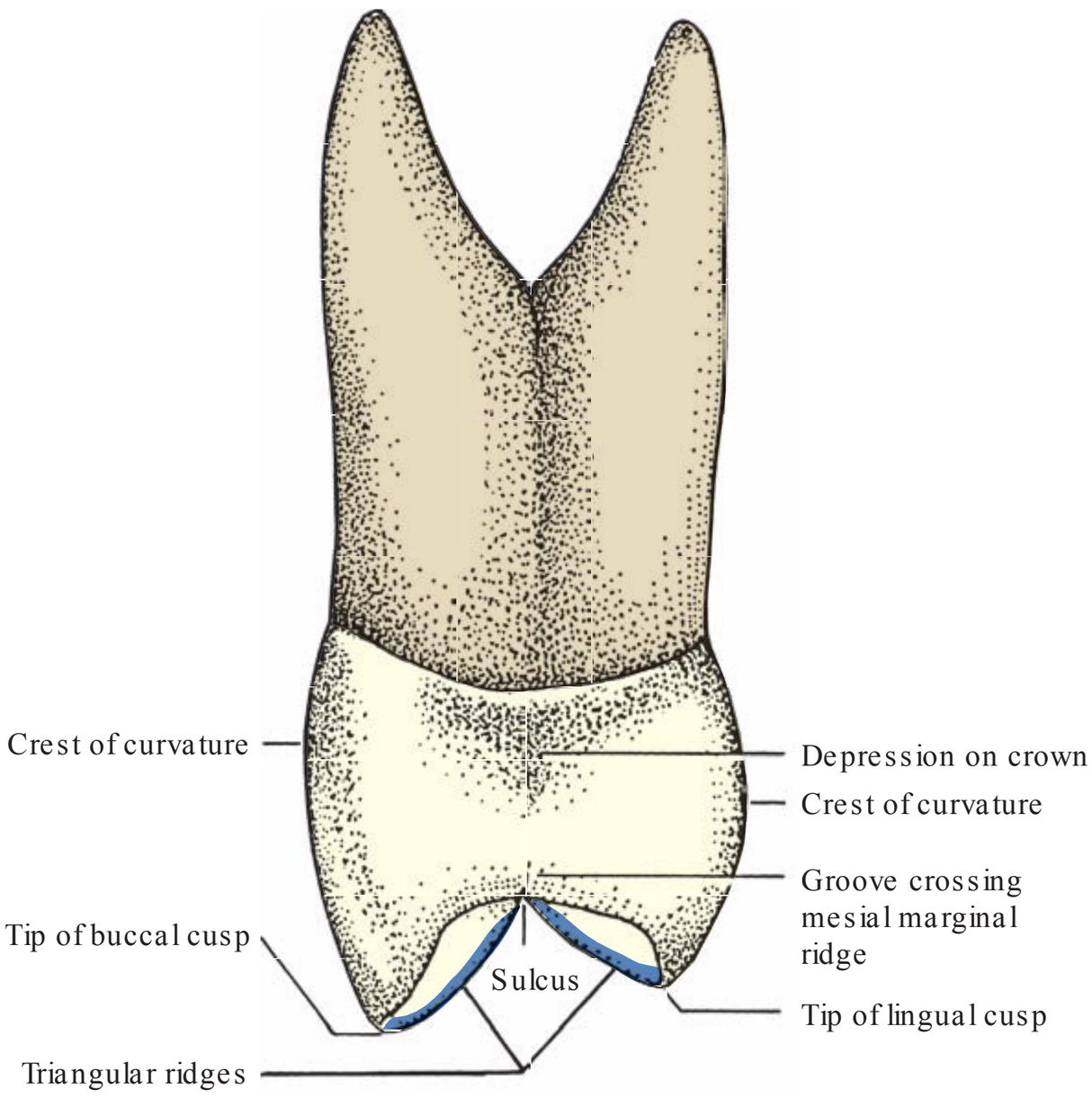

FIgur E 1-26. When seen from the mesial view on this maxillary two-cusped premolar, the outlines of two triangular ridges form a “V” shape and join at the depth of the occlusal sulcus to form one transverse ridge.

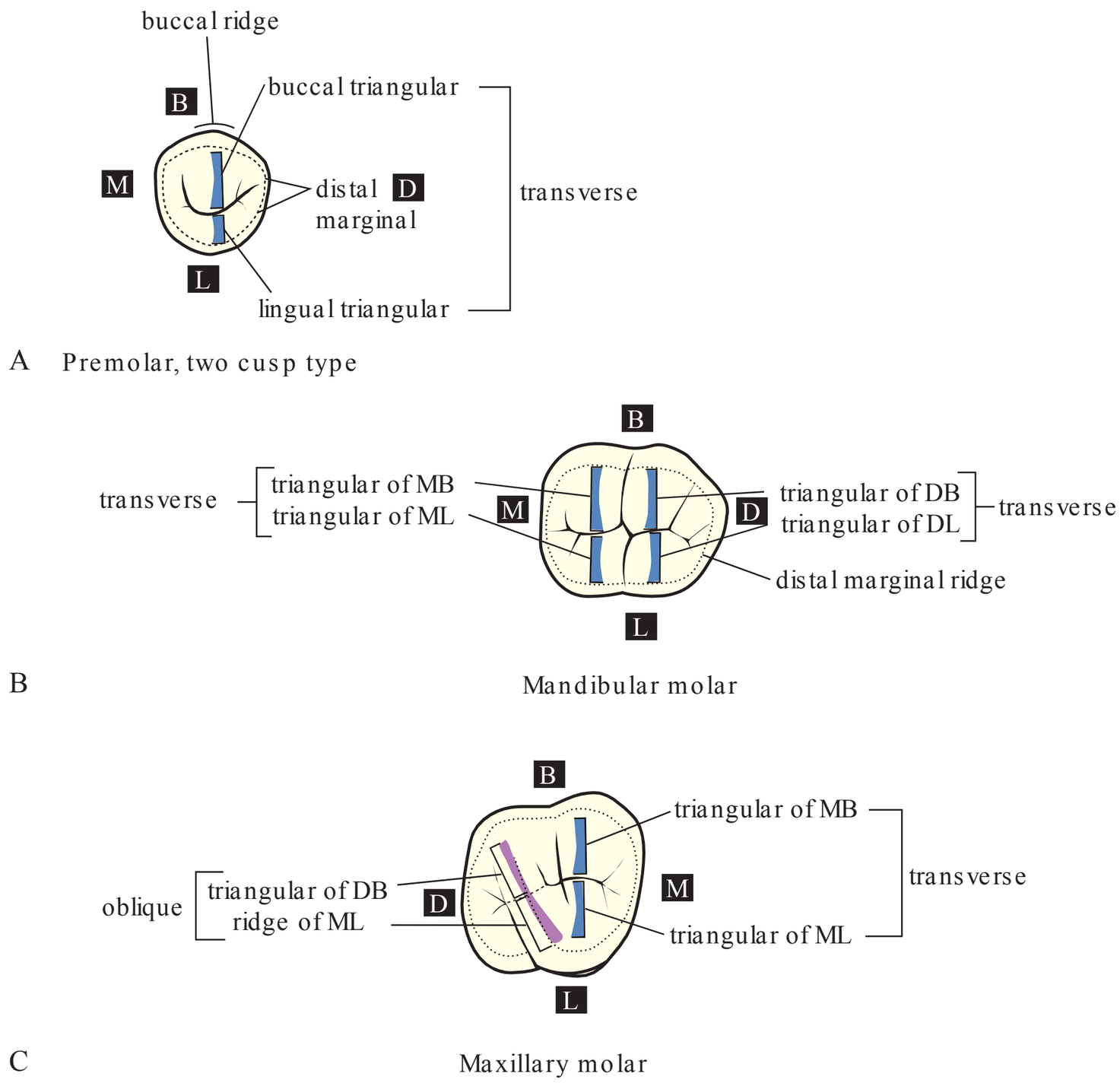

FIgur E 1-27. Three posterior teeth show transverse and **o**blique ridges. A. Two triangular ridges on a two-cusped premolar form one transverse ridge. B. Two pairs of triangular ridges on a mandibular molar join to form two transverse ridges. C. One pair of triangular ridges on a maxillary molar is aligned buccolingually and forms one transverse ridge in blue, and another pair of ridges is aligned obliquely (diagonally) to form an **o**blique ridge in purple.

LEARNING EXERCISE

The diagram in this Figure 1-32 the ridges seen from the occlusal view that bound the occlusal table of a two-cusped premolar. Name each ridge next to its corresponding number. (Note that ridges labeled 1, 3, 4, 5, 6, and 7 form a continuous outline on the occlusal surface. The area inside of this line is called the **o**cclusal table.)

e. *Other Bulges and Ridges*

Other bulges or ridges can be seen on the cervical third of certain teeth facially or lingually. On the facial surface of permanent molars, the ridge or bulge running mesiodistally in the cervical one third of the facial surface of a crown is called the **cervical ridge**. T is ridge forms the greatest bulge on the buccal surface, which is known as the **crest of curvature** (or height of contour) (Fig. 1-33A and B). T is ridge is most evident on mandibular second molars where the

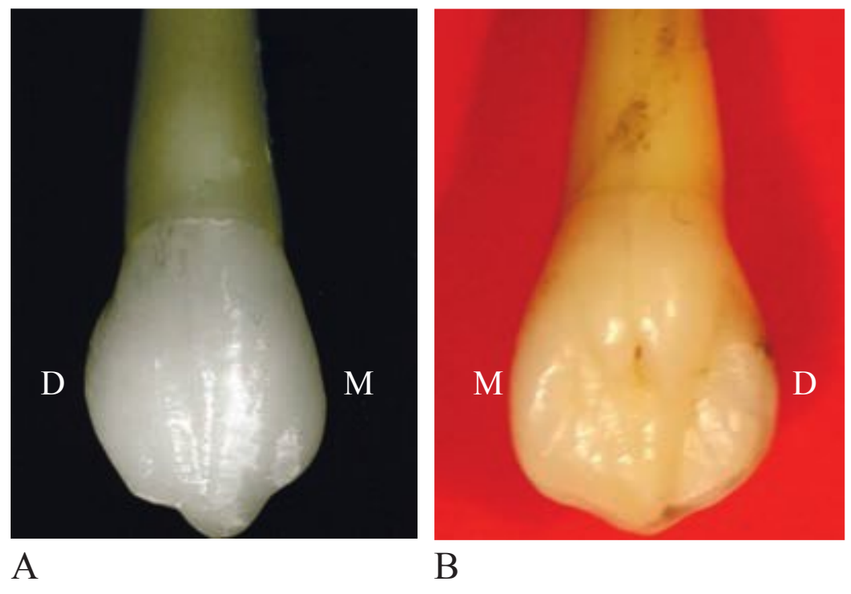

A B

FIgur E 1-28. A. On this maxillary canine, a labial ridge can be seen running from the cusp tip cervically along the labial surface. B. On this maxillary canine, a prominent lingual ridge is visible running from the cusp tip cervically to the cingulum.

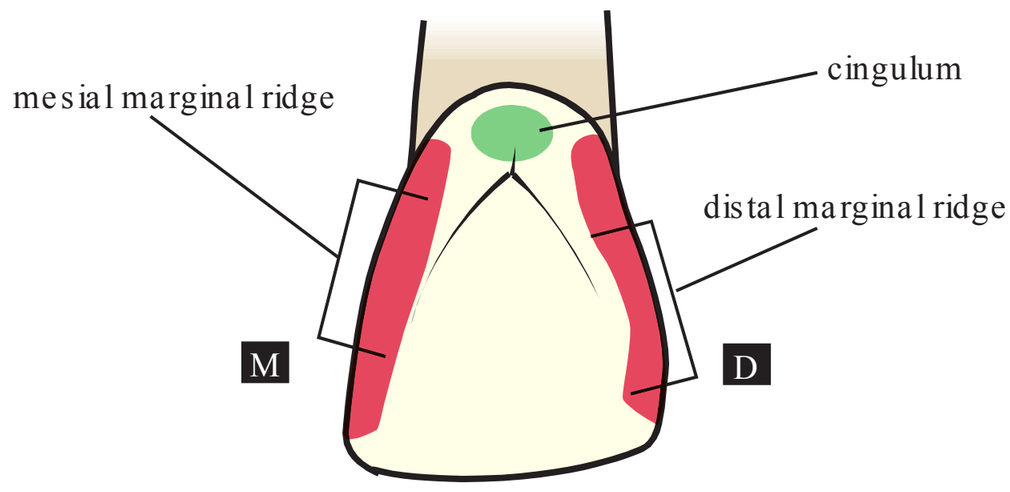

FIgur E 1-29. The mesial and distal **m**arginal ridges are shaded red, and the cingulu**m** is shaded green on the lingual surface of a maxillary incisor. If you think of the length of a marginal ridge as running from the proximal incisal line angles to the cingulum, you can see that this mesial marginal ridge is slightly longer than the distal marginal ridge.

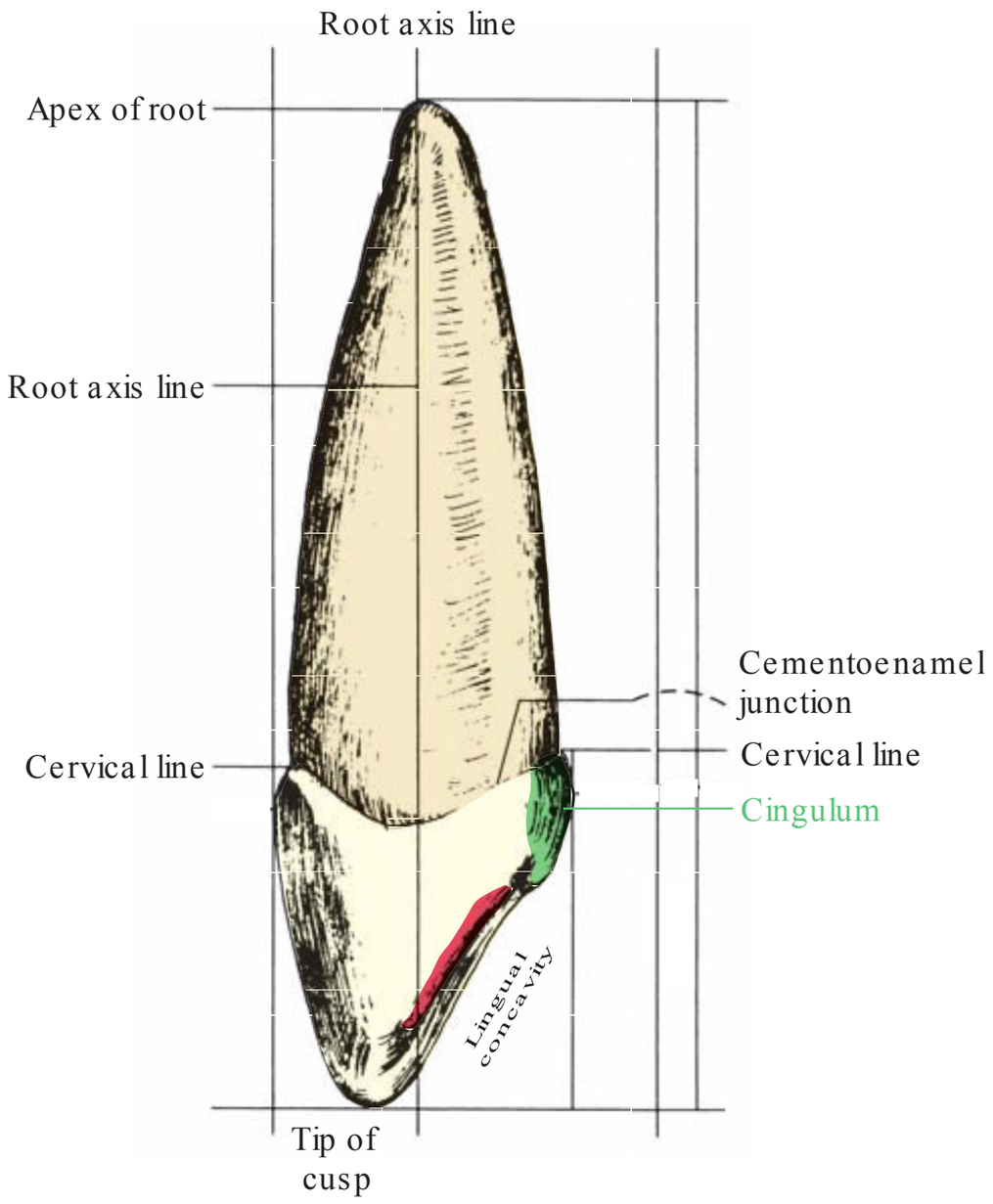

FIgur E 1-30. This maxillary canine demonstrates that the cingulu**m** bulge in green is located in the cervical third of the lingual surface. One visible marginal ridge is shaded red.

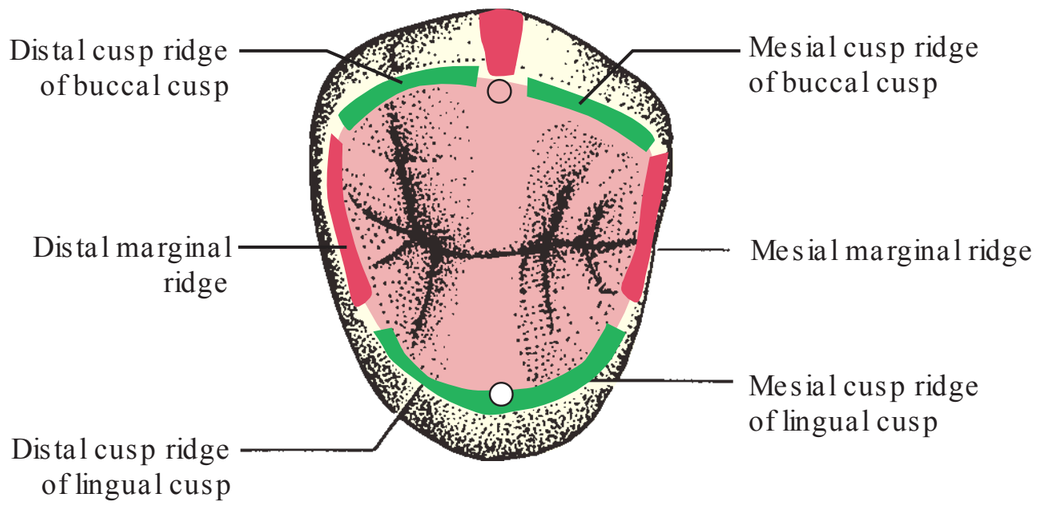

FIgur E 1-31. Occlusal view of a two-cusped premolar shows the difference between the **o**cclusal **o**utline of the tooth (the black outline surrounding the entire tooth from this view) and the smaller red **o**cclusal table (or occlusal chewing surface) bounded by six ridges: the two cusp ridges of the buccal cusp (green), the two cusp ridges of the lingual cusp (green), and the two marginal ridges (red).

occlusal outline of the mesiobuccal cusp appears to bulge (Fig. 1-33C).

Mamelons are three small bulges or tubercles on the incisal edges of newly erupted incisors (Fig. 1-34). Usually, mamelons are not evident on adult dentition since they are worn off after the tooth comes into functional contact with its opposing teeth. If you have the opportunity, observe a 7-year-old smile to see these mamelons on newly erupted permanent incisors. When mamelons remain on the incisors of an adult, it is because maxillary and mandibular anterior teeth do not touch together to wear away the enamel. When a patient desires, the dentist can reduce the mamelons to make the incisal edge more uniformly curved.

Finally, **perikymata** [pear i KY mah tah] are the numerous, minute horizontal ridges on the enamel of newly erupted permanent teeth (Fig. 1-35). T ey form from the overlapping of layers of enamel laid down during tooth formation. T ese lines are closer together in the cervical third of the crown than in the incisal third. Perikymata are more prominent on the teeth of young people than on the teeth of older persons because perikymata, like mamelons, wear away from

1. _____
2. _____
3. _____
4. _____
5. _____
6. _____
7. _____
8. _____
9. _____
10. Transverse

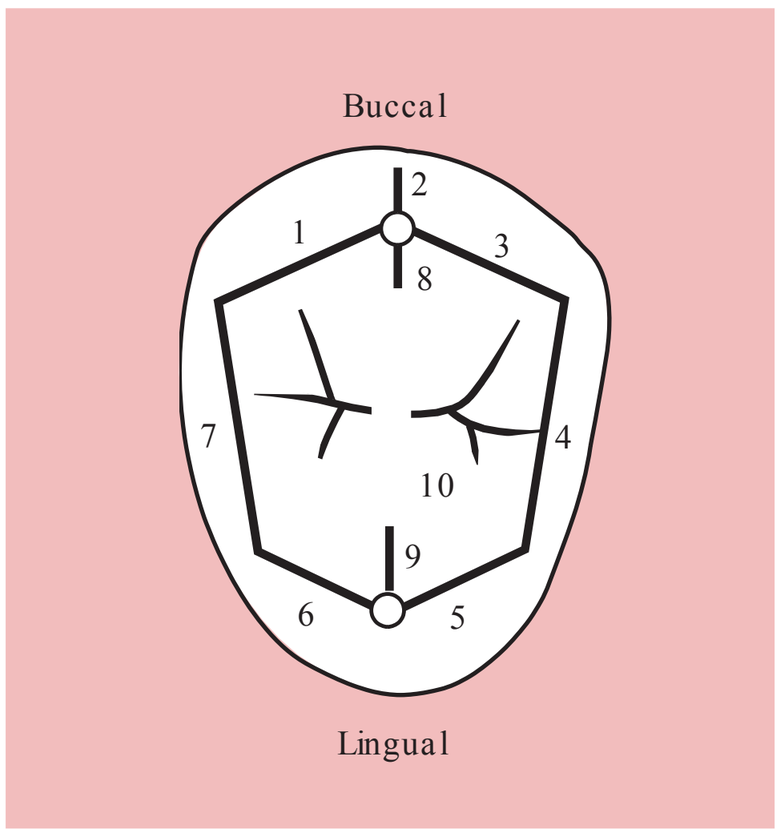

. psucl augril fo egdr ral ugnairt –9; psucl accubfo egdr ral ugnairt –8; egdr lanigra m latsid –7; psucl augril fo egdr psucl atsid –6; psucl augril fo egdr psucl aise m–5; egdr lanigra m laise m–4 ; psucl accubfo egdr psucl aise m–3; egdr) psuc(l accub –2; psucl accubfo egdr psucl atsid –1: Sr E wS Na

FIgur E 1-32. Identify the ridges numbered on this maxillary premolar.

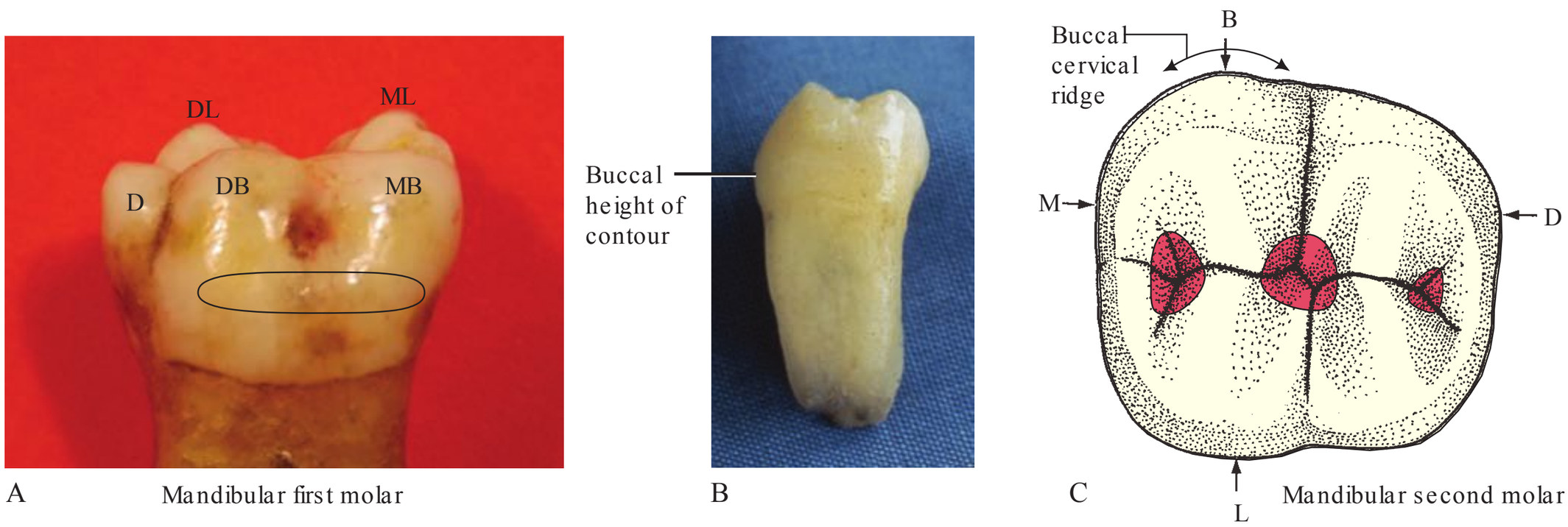

FIgur E 1-33. A. On this mandibular first molar from the buccal view, a buccal cervical ridge is the rounded prominence located in the cervical third of the crown. B. From the proximal view, the buccal cervical ridge forms the greatest bulge or crest of curvature in the cervical third of this molar. C. From the occlusal view on this four-cusped mandibular second molar, the buccal cervical ridge forms a prominent bulge on the mesiobuccal outline.

ongoing abrasion due to eating and even tooth brushing with abrasive toothpastes.

2. depressions and grooves of an anatomic Crown

An occlusal **sulcus** [SUL kuss] (plural sulci [SUL sye]) of a tooth is the broad V-shaped depression or valley on the occlusal surface of each posterior teeth running mesiodistally between the buccal and lingual cusps. T e sulcus is formed by the sloping of the buccal and lingual triangular ridges that converge toward the developmental grooves located in the depth of the sulcus on each posterior tooth (Fig. 1-36). Although a sulcus is a linear depression, there is much variation to the anatomy within the sulcus of each tooth. For example, there are triangular and marginal ridges (discussed previously) and grooves (channels) within the sulcus, as well as multiple depressions, each called a **fossa** [FAH sah] (plural, fossae [FAH see].

GROOVES: A **groove** is a linear channel often found between cusps in the depth of the sulcus and between ridges. T ey serve as important escape ways for food morsels when the teeth of the lower jaw move from side to side and forward against the upper teeth during chewing. Partially chewed food squirts out through grooves toward the tongue and cheeks. Each tooth has major developmental grooves, which are often consistent in location for teeth of the same type, and other minor, supplemental grooves, which can vary greatly from tooth to tooth. **Developmental grooves** separate cusps and other major portions of a tooth formed from the developmental lobes (described later in Section IX of this chapter). On most posterior teeth like the premolar in Figure 1-37A, a **central groove** is a developmental groove that separates the buccal from the lingual cusps and is located near the buccolingual center of the tooth sulcus. Other developmental grooves are named according to their location. For example, on mandibular molars with two buccal cusps, a **buccal groove** separates the mesiobuccal and distobuccal cusps and is likely to extend onto the buccal surface. On mandibular molars with three buccal cusps, there are two grooves separating the three buccal cusps, so they are called a **mesiobuccal groove** that separates the mesiobuccal cusp from the distobuccal cusp, and a **distobuccal groove** that separates the distobuccal cusp from the smallest distal cusp (Fig. 1-37B). Both of these grooves are likely to extend onto the buccal surface. Mandibular molars also have a **lingual groove** between the mesiolingual and distolingual cusp, but these grooves are not likely to extend onto the lingual surface. Most maxillary molars have a **lingual groove** that often extends onto the lingual surface between the mesiolingual and distolingual cusps, and a **buccal groove** between the mesiobuccal and distobuccal cusps that does not normally extend onto the buccal surface (Fig. 1-37).

Additional occlusal grooves that are not developmental grooves are called **supplemental grooves**. T ese small irregular (extra) grooves do not occur at the junction of the lobes or major portions of the tooth and do not occur at the same location on teeth of the same type, so these extra grooves are normally not assigned a specific name.



FIgur E 1-34. Three distinct unworn **ma**a **me**el**o**ns are evident on the incisal edge of this mandibular incisor.

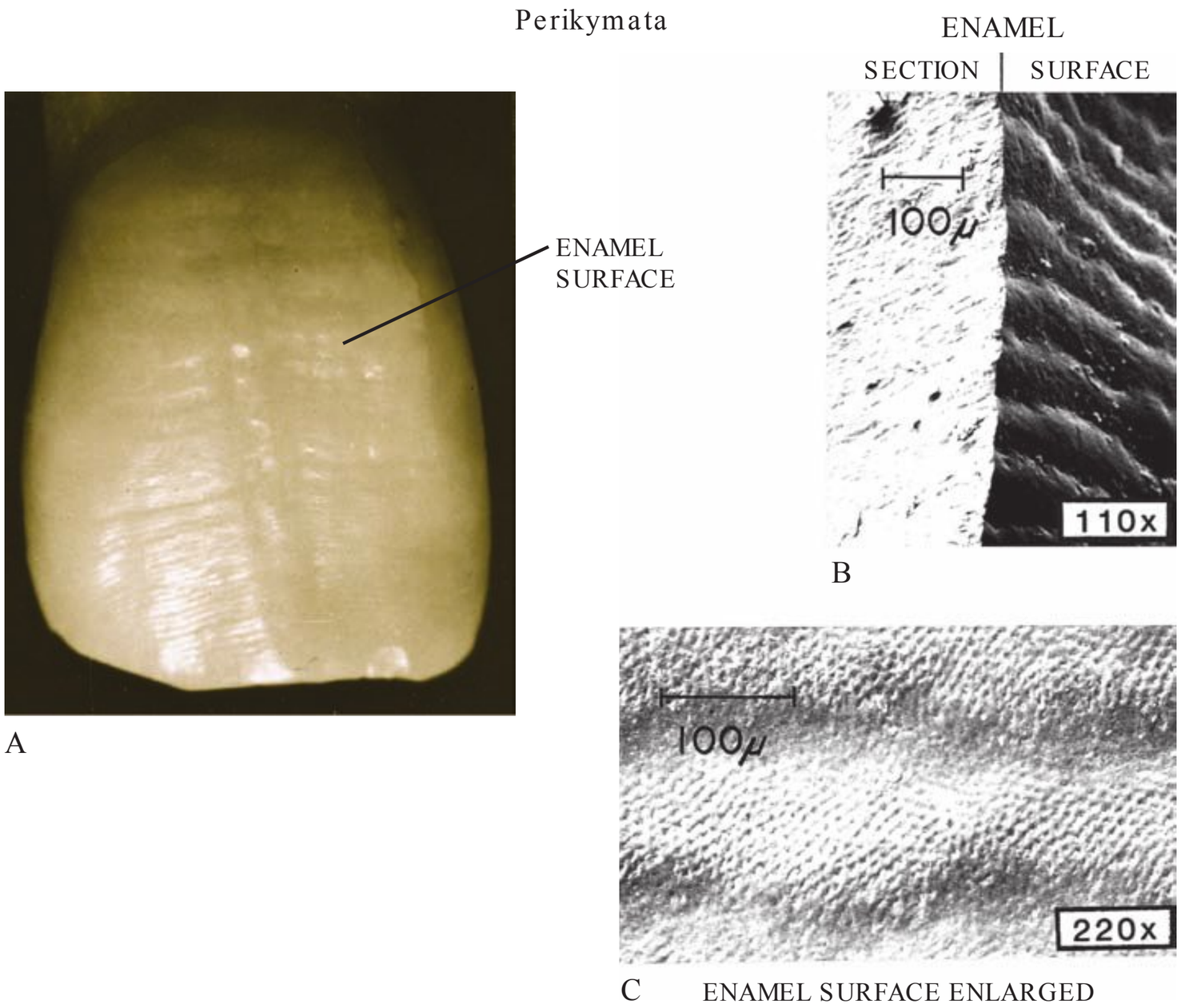

FIgur E 1-35. A. Perikymata are the small ridges visible on the labial surface of this incisor. B. Magnified cross section of enamel shows perikymata ridges on the tooth surface (on the right half). C. Higher magnification (220×) shows the enamel rods that make up enamel ending on the perikymata waves. (These scanning electron micrographs were provided by Dr. Ruth B. Paulson, Associate Professor Emeritus, Division of Oral Biology, the Ohio State University.)

FOSSAE: Located at the mesial and distal ends of the central groove on each posterior tooth within the occlusal table and next to the mesial and distal marginal ridges, there are shallow depressions called a **mesial fossa** and **distal fossa** (sometimes called a **mesial and distal triangular fossa**) (Fig. 1-38). **Fossa grooves** (also called fossa developmental grooves or triangular fossa grooves) may be found within these fossae splitting off of the ends of the central groove directed toward the line angles of the tooth. T ese grooves can be named for the line angles of the tooth toward which they aim, for example, in Figure 1-38, the **distobuccal developmental groove** (more precisely called the distobuccal triangular or fossa groove) runs toward the distobuccal line angle of the tooth. A **pit** may form at the depth of a fossa where central groove joins the fossa grooves. For example, within the distal fossa on a premolar, there is a distal pit at the junction of the central groove with the distobuccal and distolingual fossa grooves (Fig. 1-38). Most molars and three-cusped premolars have an additional **central fossa** seen in Figure 1-39.

Many anterior teeth have a shallow, broad **lingual fossa** that is located on the lingual surface between the mesial and distal marginal ridges and just incisal to the cingulum (particularly on maxillary incisors, Fig. 1-40). T e lingual ridge of some maxillary canines may divide the lingual surface into two fossae: a mesial fossa bounded by the mesial marginal ridge and the lingual ridge and a distal fossa bounded by the distal marginal ridge and the lingual ridge (Fig. 1-41).

Deep, defective **pits and ȧssures** may be found at the depth of fossae and grooves caused by the incomplete fusion of enamel during tooth development (at the white arrow in Fig. 1-42). Because it is very difficult to remove food debris from these inaccessible fissures, tooth decay (also called dental **caries** [CARE eez]) often begins in the deepest part of a fissure or pit (seen spreading out within dentin as the

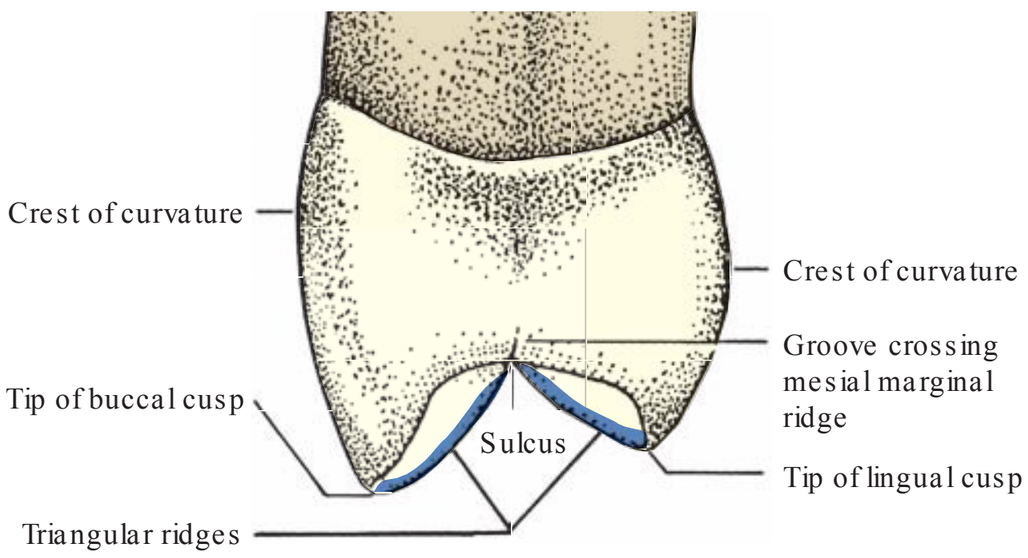

FIgur E 1-36. This two-cusped premolar has a sulcus between the buccal and lingual cusps.

Central developmental groove (C)

Fossa developmental grooves (F)

Supplemental grooves (S)

Marginal ridge groove (M)

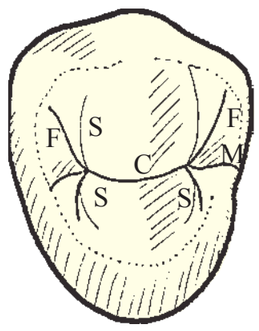

A

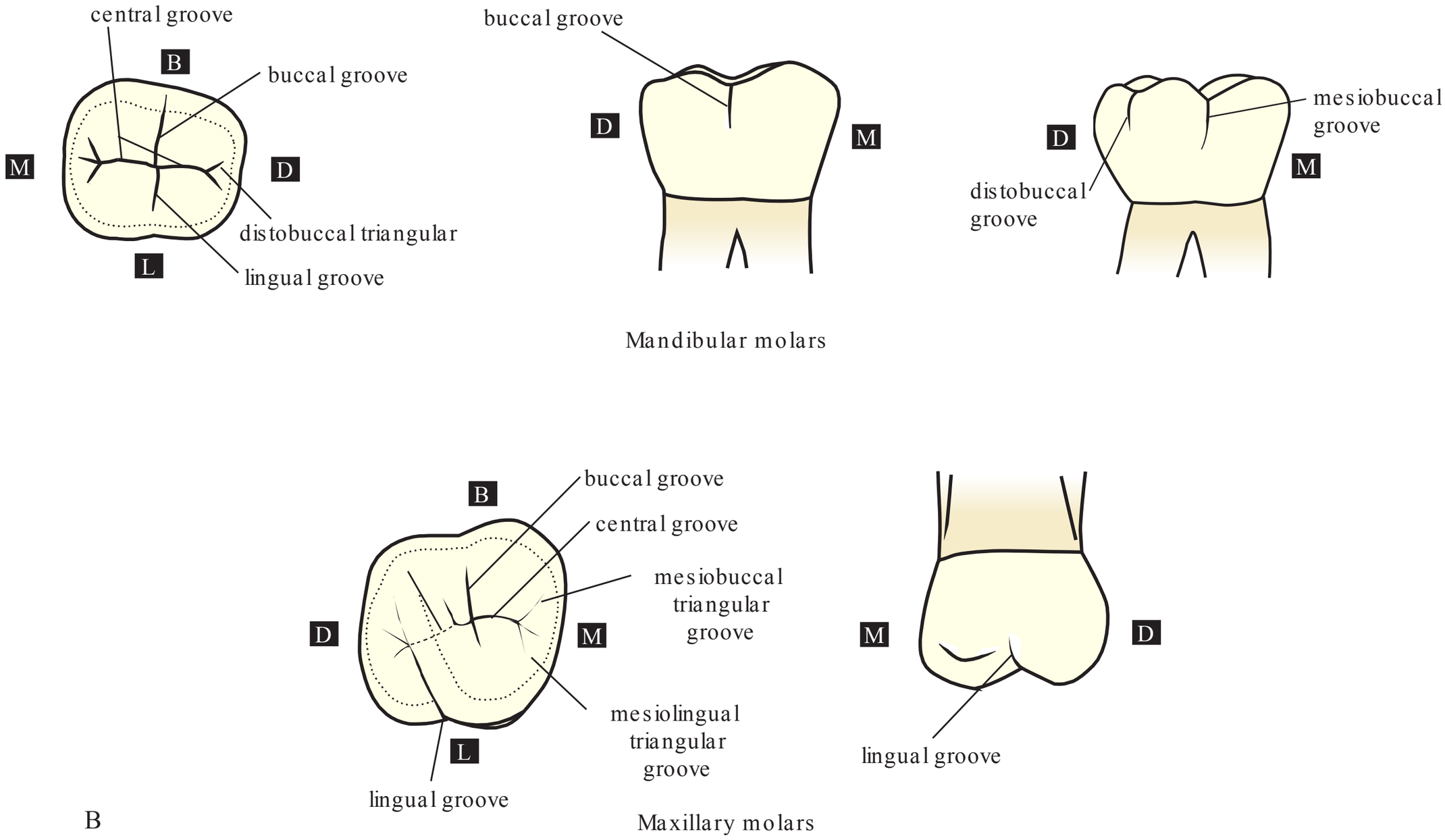

FIgur E 1-37. A. This two-cusped premolar has devel**o**p**m**ental (major) and supple**m**ental (extra) occlusal gr**oo**ves. (Courtesy of Drs. Richard W. Huffman and Ruth Paulson.) B. Grooves are labeled on a mandibular four-cusped molar (upper left and center), a mandibular five-cusped molar (upper right) and a maxillary molar with four major cusps (lower row). The buccal, lingual, and central gr**oo**ves are considered developmental grooves. The buccal gr**oo**ve extends between the two buccal cusps onto the buccal surface on mandibular molars, and the lingual gr**oo**ve extends between the two lingual cusps onto the lingual surface of maxillary molars. Five-cusped mandibular first molars have three buccal cusps, so there are two developmental grooves: a **m**esi**o**buccal gr**oo**ve between the mesiobuccal and distobuccal cusps and a dist**o**buccal gr**oo**ve between the distobuccal and distal cusps.

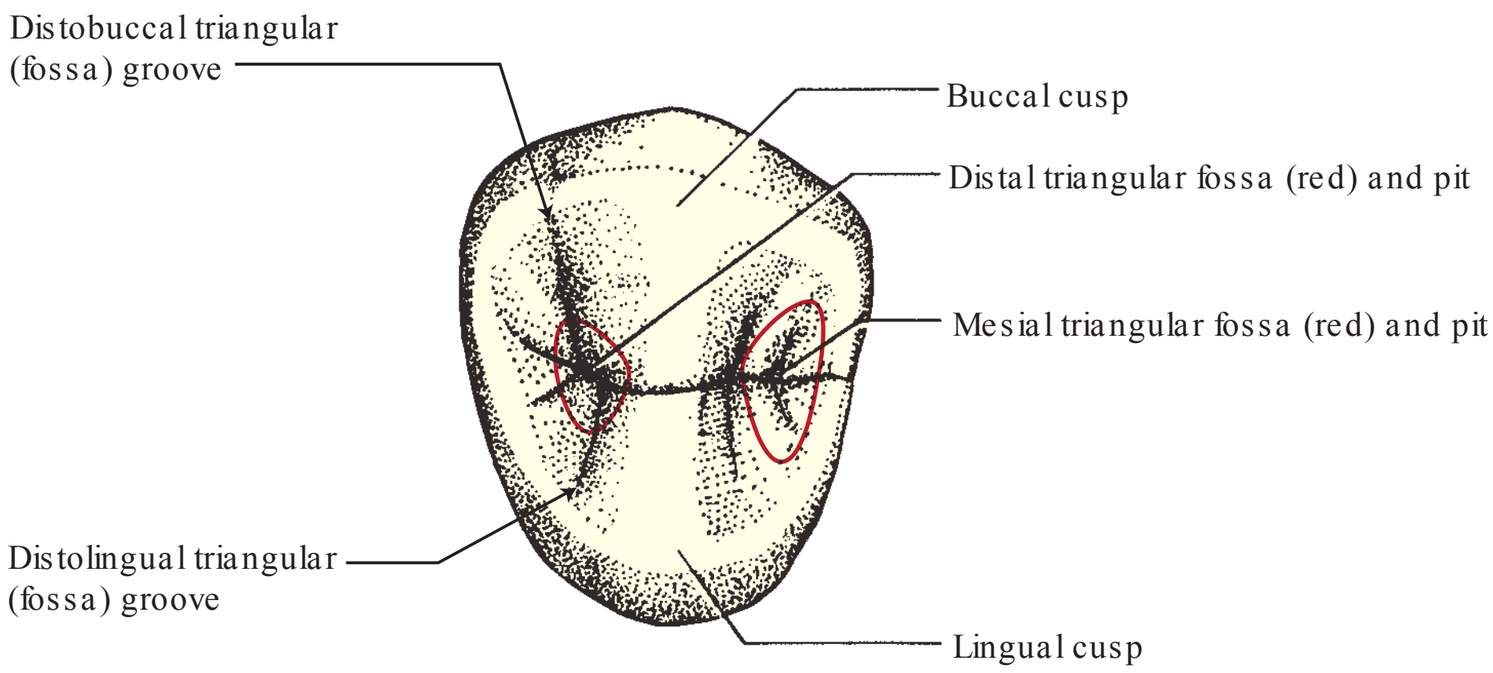

FIgur E 1-38. The **m**esial and distal **fo**ssae are outlined in red on this maxillary two-cusped premolar.

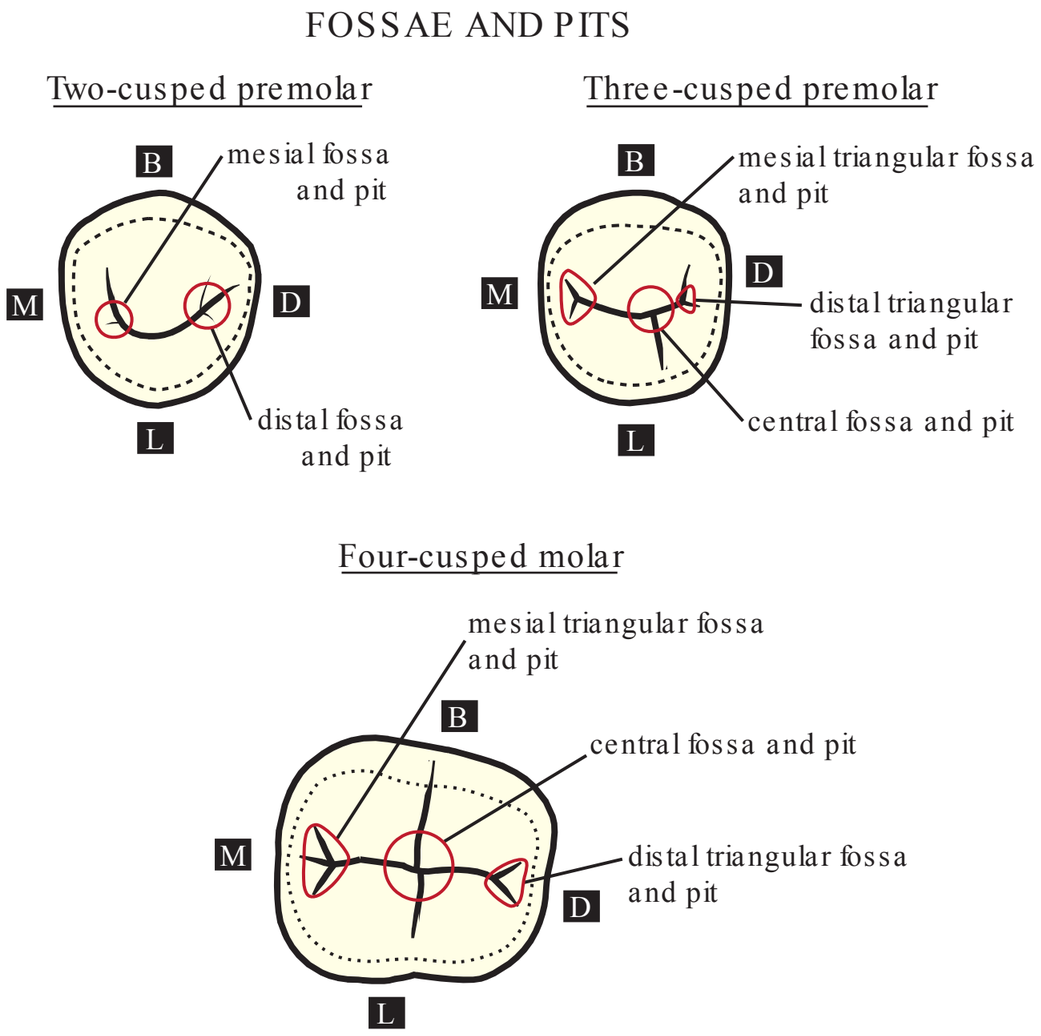

FIgur E 1-39. F**o**ssae and pits are labeled on teeth with two, three, and four cusps. Two-cusped teeth have two fossae (a **m**esial and a distal **fo**ssa), while three- or four-cusped teeth also have a third fossa called a central **fo**ssa.

dark area between the two black arrows) and described in more detail in Chapter 10. T ese carious pits and fissures are most likely to be located in four areas: at the depth of deep grooves and pits on the occlusal surface of posterior teeth, in buccal grooves that extend onto the buccal surface of mandibular molars, in lingual grooves that extend onto the lingual surface of maxillary molars, and on the lingual surface of maxillary incisors where the lingual fossa joins the cingulum (Fig. 1-43).

In summary, if you compare tooth morphology to a mountain range, the mountain peak would be the cusp tip. Ridges emanating from the mountain peak are like the cusp ridges and triangular ridges. T e depression between the mountains is a valley, like the depressions between cusps is a sulcus. T e dried river bed at the bottom of the valley is like a groove at the bottom of the sulcus. If the riverbed is cracked

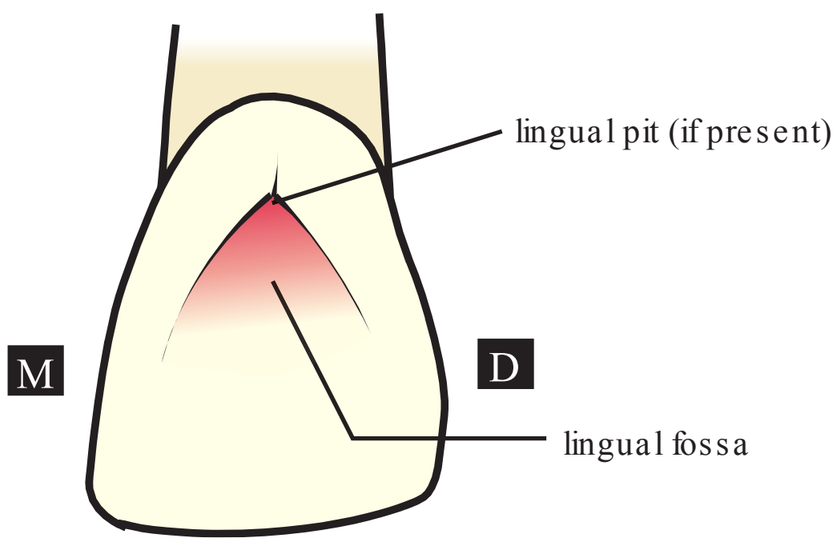

FIgur E 1-40. The lingual surface of this maxillary lateral incisor shows the shallow lingual **fo**ssa and an adjacent lingual pit.

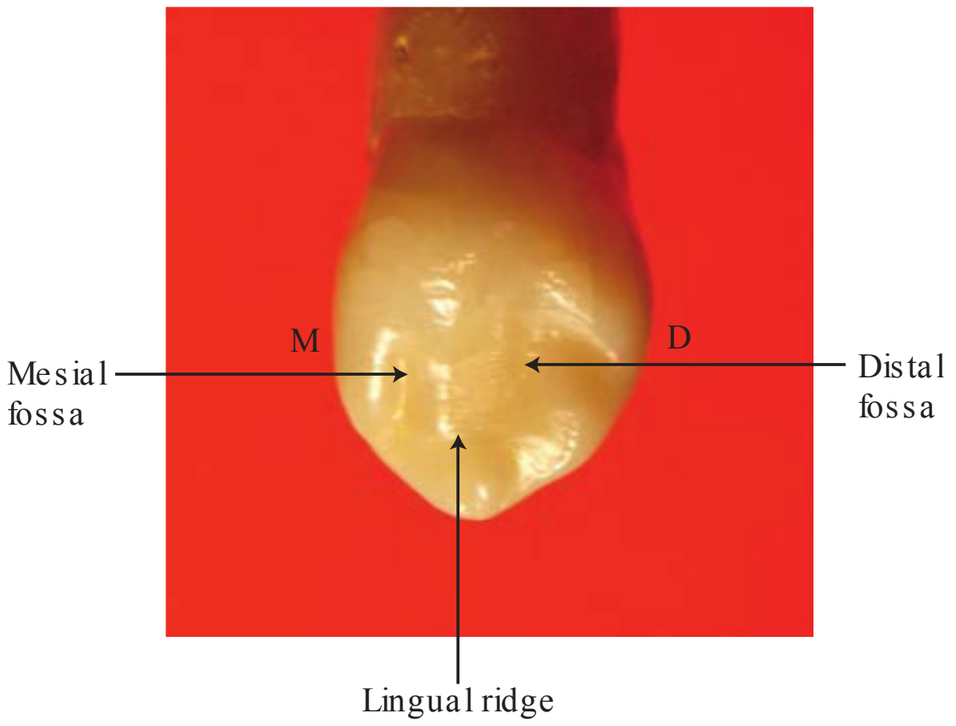

FIgur E 1-41. This maxillary canine has a lingual ridge that divides the lingual surface into a mesial fossa and a distal fossa.

open, it is like a fissured groove. Where two rivers converge (as when grooves or fissures converge), the whirlpools and eddies may have formed a depression, like a fossa, possibly with a pit at its depth. Needless to say, it is difficult to define exactly where a mountain stops and the valley begins, just as it would be difficult to define exactly where a tooth cusp stops and a sulcus or fossa begins. Just realize that these terms are not precise, but that they are helpful when learning how to reproduce tooth form during construction of crowns and placement of fillings or when learning to finish and polish an existing filling.

B. ExTEr Na L mOr ph OLOg y OF Th E a NaTOmIC r OOT

Recall that the anatomic root is the part of a tooth that is covered with cementum. T e **apex** of the root is the tip or peak at the end of the root, often with visible openings called

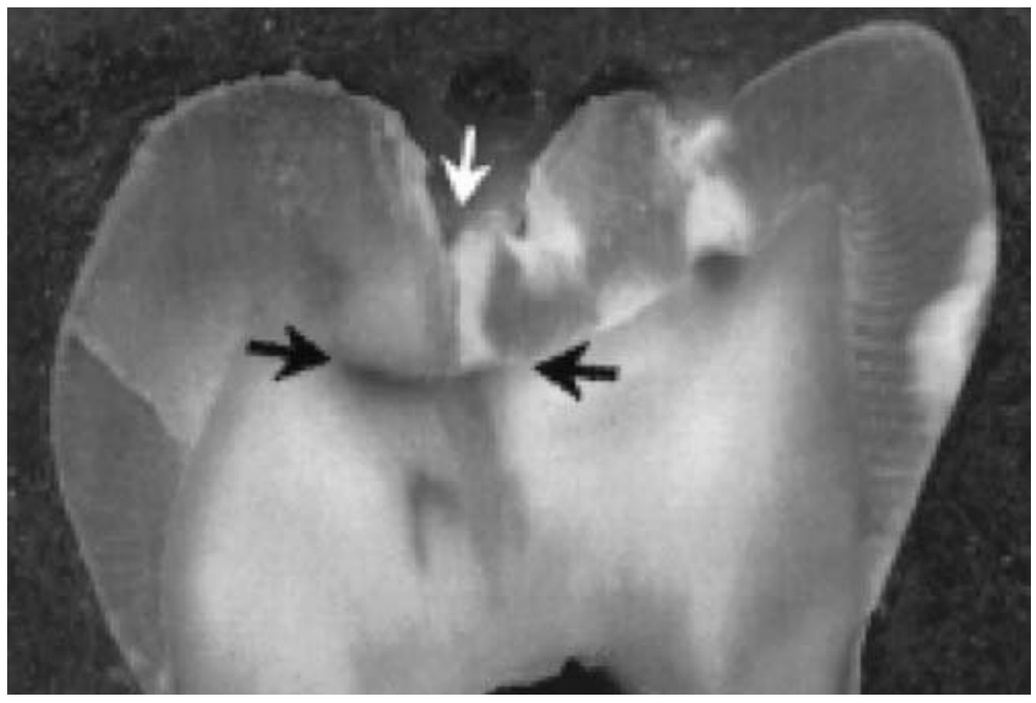

FIgur E 1-42. A cross section of a mandibular molar shows an occlusal groove (white arrow), which actually has a f ssure (crack-like fault) extending through the outer enamel and into the dentin. The black arrows show how the dental decay spreads out once it reaches softer dentin at the depth of this fissure.

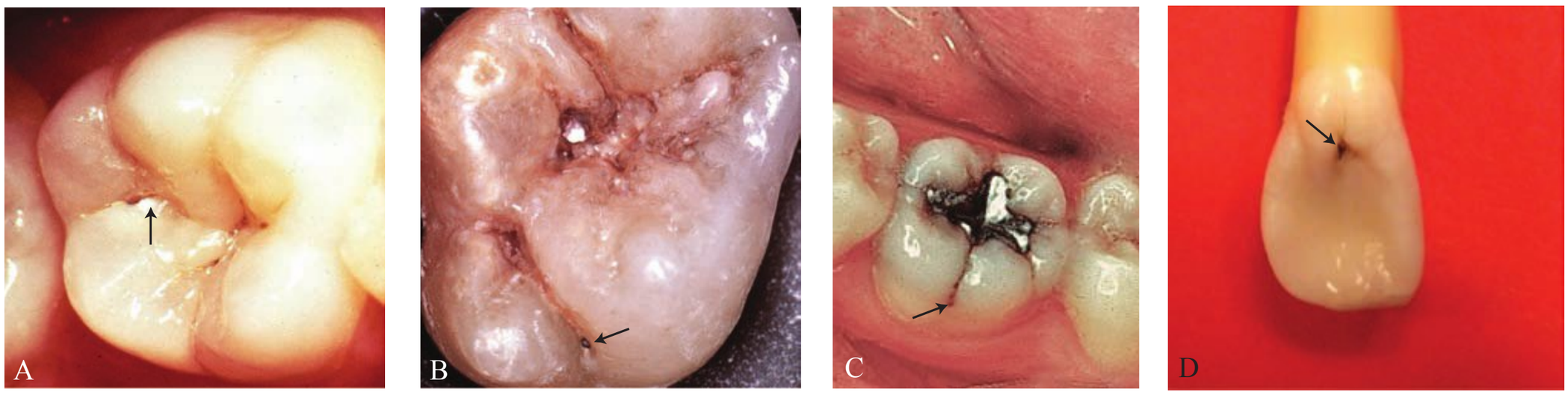

FIgur E 1-43. Caries-prone pits and fissures are located in four places (arrows). A. The occlusal surfaces of posterior teeth. B. The lingual surfaces of maxillary molars. C. The buccal surfaces of mandibular molars. D. The lingual surfaces of maxillary incisors.

apical foramina, where the nerves and blood vessels enter into the tooth pulp canals. T e **cervix** [SUR viks] or neck of the tooth is the slightly constricted region surrounding the junction of the crown and the root (Fig. 1-44B).

Some new terms apply to multirooted teeth (Fig. 1-44B). T e **root trunk** or trunk base is the part of the root of a multirooted molar or two-rooted premolar next to the cementoenamel junction that has not yet split (like a stubby tree trunk before it gives off branches). T e **furcation** [fur CAY shun] is the place on multirooted teeth where the root trunk divides into separate roots (called a **bifurcation** on two-rooted teeth and a **trifurcation** on three-rooted teeth). T e **furcal region** or interradicular space is the region or space between two or more roots, apical to the furcation where the roots divide from the root trunk.

C. CEr vICa L LINE (CEmENTOENa mEL Ju NCTION Or CEJ) Cu r va Tu r E

When viewed from the mesial or distal aspect, the cervical line of a tooth curves (is convex) toward the incisal or occlusal surface (Fig. 1-44). In general, the amount of curvature is greater on the mesial surface than on the distal surface of

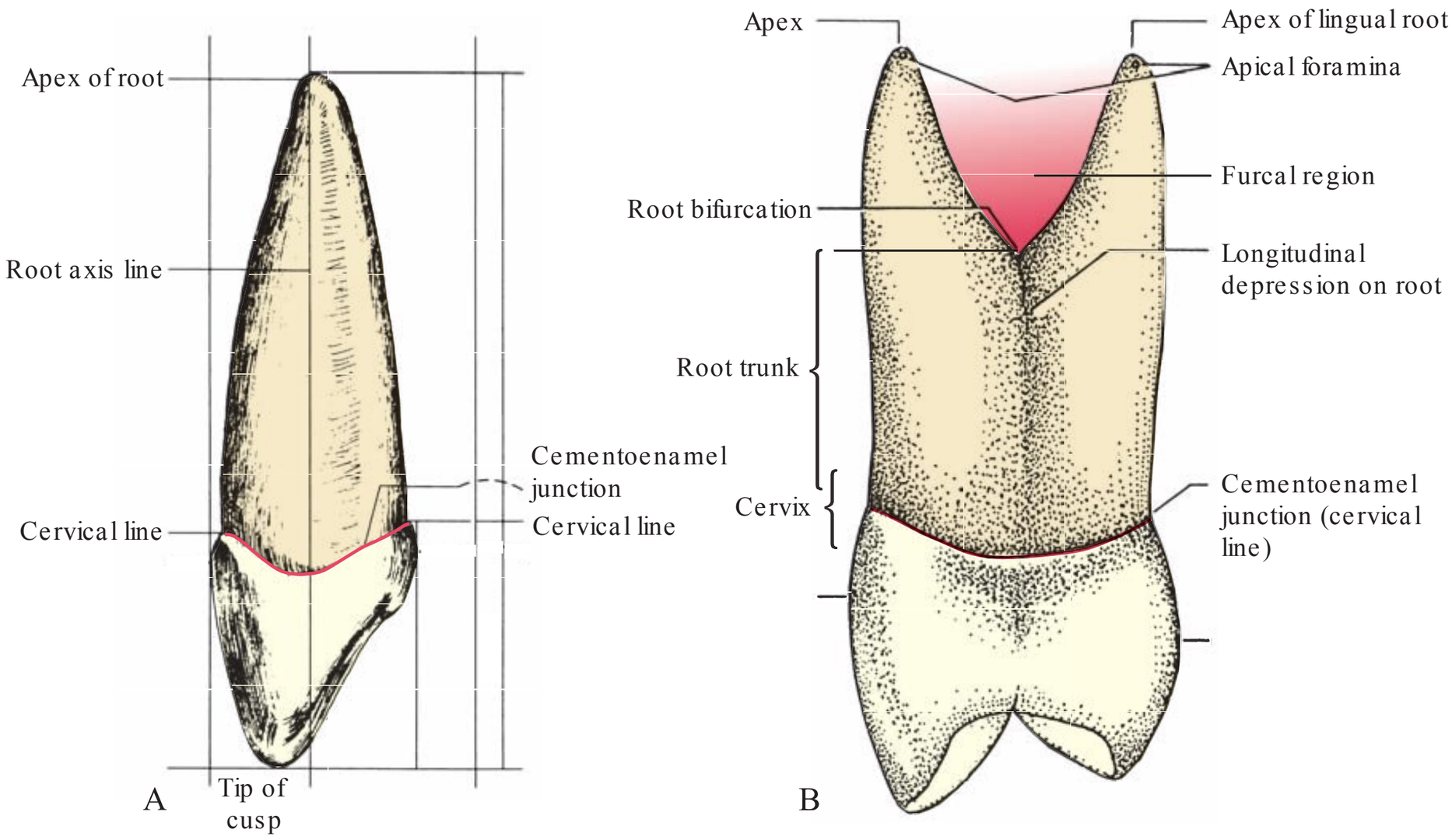

FIgur E 1-44. A. R**oo**t anat**om**y on a single-rooted canine. B. R**oo**t anat**om**y of a bi*f*urcated (split) root on a maxillary first premolar.

TABLE 1-2 Summary of Curvatures of the Cementoenamel Junction

Proximal surfaces: mesial curvature vs. distal curvature	Generally, teeth have a greater proximal cervical line curvature on the mesial than the distal.
Proximal surfaces: anterior teeth vs. posterior teeth	Proximal cervical line curvatures are greatest on the mesial surfaces of central incisors and, for most teeth, tend to get smaller when moving from the anterior teeth toward the last molar where there may be no curvature at all.
Posterior teeth: facial vs. lingual surface	On many posterior teeth, the cervical line is in a more occlusal position on the lingual than on the facial.

the same tooth, and the amount of curvature is greatest for central incisors and diminishes in size for each tooth when moving distally around each quadrant (Table 1-2).

d. Relative Size

In order to document the relative sizes of tooth crowns and roots, Dr. Woelfel studied a convenient sample of 4572 extracted teeth. His findings are presented in Table 1-7 at the end of this chapter. This table should not be memorized, but it can be useful when comparing the average dimensions of each tooth and in order to appreciate the wide range of dimensions for each tooth. A summary of the most important highlights of that data is presented in Table 1-3.

TABLE 1-3 Important Tooth dimensions to memorize

Tooth with longest crown	Mandibular canine (Woelfel research: maxillary incisor)
Longest tooth overall	Maxillary canine
Longest root	Maxillary canine
Widest crown mesiodistally	Mandibular first molar
Widest crown buccolingually	Maxillary first molar
Narrowest crown mesiodistally	Mandibular central incisor
Greatest cervical line curve	Mesial of maxillary incisor

SECTION VII Terminology Related To The Ideal Tooth Alignment Of Teeth In Dental Arches

When viewed from the occlusal aspect, the alignment of teeth within each dental arch is somewhat U shaped or parabolic like the famous landmark in Missouri, the St. Louis Arch (Fig. 1-45). The incisal edges and the buccal cusp tips follow a curved line around the outer edge of the dental arch; the lingual cusp tips of the posterior teeth follow a curved line nearly parallel to the buccal cusp tips. Between the buccal and lingual cusps of posterior teeth is the **sulcular groove (occlusal sulcus)**, a V-shaped depression that extends anteroposteriorly through all of the posterior teeth in each quadrant. This sulcular groove is made up of the occlusal sulcuses of adjacent posterior teeth in each quadrant (Fig. 1-45).

a. Midroot Axis Line and Tooth Alignment

The **midroot axis line** (or root axis line) is an imaginary line through the center of the tooth root. When viewing the facial or lingual surface, it can be visualized as a line that divides

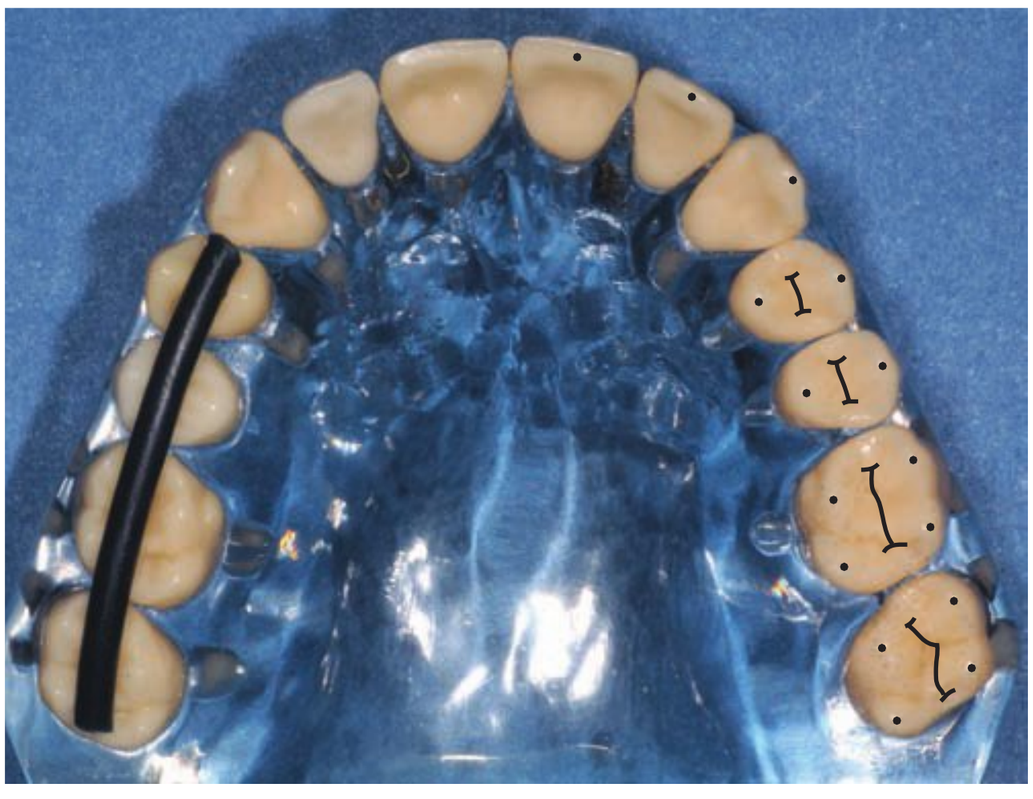

FIGURE 1-45. This model of the maxillary dentition with ideal alignment form an arch shape and the rope of blue wax on the left half falls within the **o**cclusal sulcus.

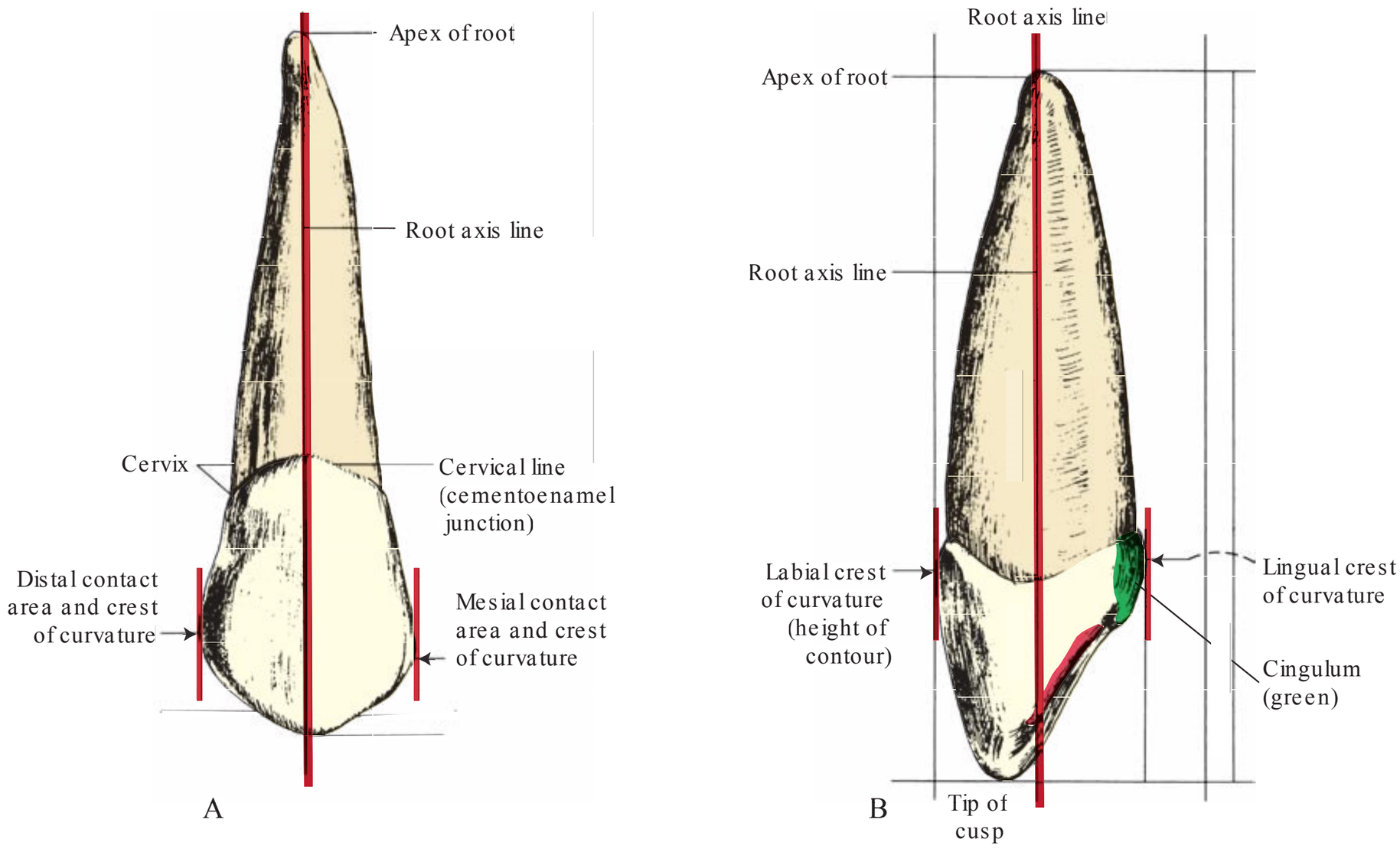

FIgur E 1-46. The **m**idr**oo**t axis line is drawn on two views of a canine. A. When viewed from the facial (or lingual), the greatest bulges on the mesial and distal sur*f*aces (crests **of** curvature) on this canine are the widest points on the crown that touch lines parallel to the midroot axis line. These crests of curvature are essentially the same as the c**o**ntact areas of teeth when they are aligned ideally in the mouth. Notice that these contact areas are positioned more incisally on the mesial surface than on the distal. B. When viewed from the proximal, the greatest bulges on the *f*acial and lingual surfaces (crests **of** curvature) are the points on the facial and lingual crown outline that touch lines that are parallel to the midroot axis line. They are located in the cervical third on both the facial surface and on the lingual surface (on the cingulum shaded green) for all anterior teeth.

the bulk of the root into mesial and distal halves (Fig. 1-46A). When viewing the mesial or distal surface, it divides the bulk of the root into facial and lingual halves (Fig. 1-46B). It is an important reference line for describing the location of tooth landmarks. For example, you will learn that the incisal ridge (or cusp tip) of a maxillary canine is more likely to be labial to the midroot axis line (as seen in Fig. 1-46B).

When the posterior teeth in each arch are viewed from the buccal aspect as in Figure 1-47, notice that posterior teeth are not aligned exactly parallel to one another and all cusp

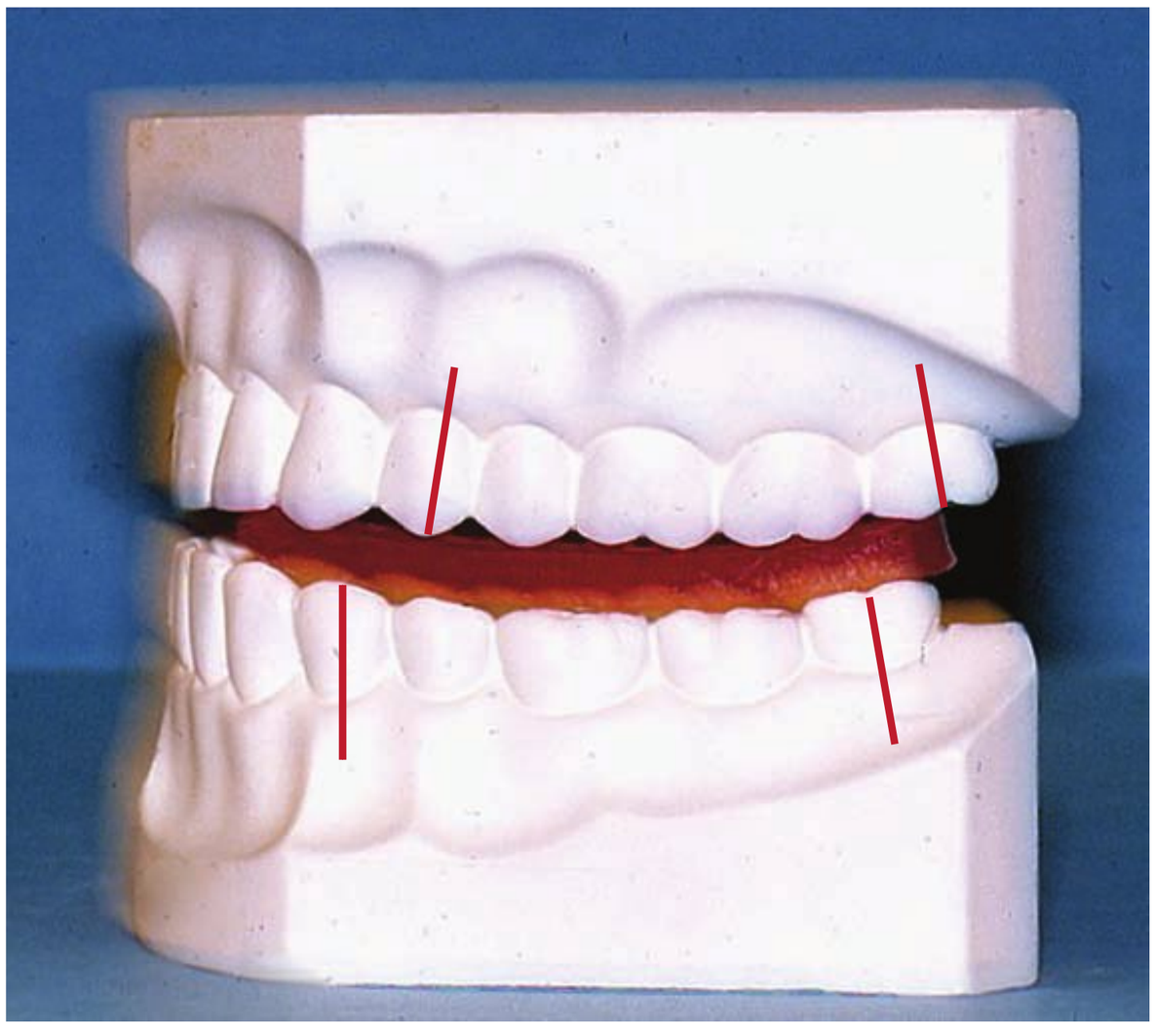

FIgur E 1-47. A wax strip placed between stone models of the maxillary and mandibular teeth demonstrates the anter**o**p**o**steri**o**r curve (curve of Spee), which is concave in the mandibular arch but convex in the maxillary arch. Note the difference in the axial alignment of the teeth within each arch demonstrated by the axial lines placed on the third molars and on the first premolars.

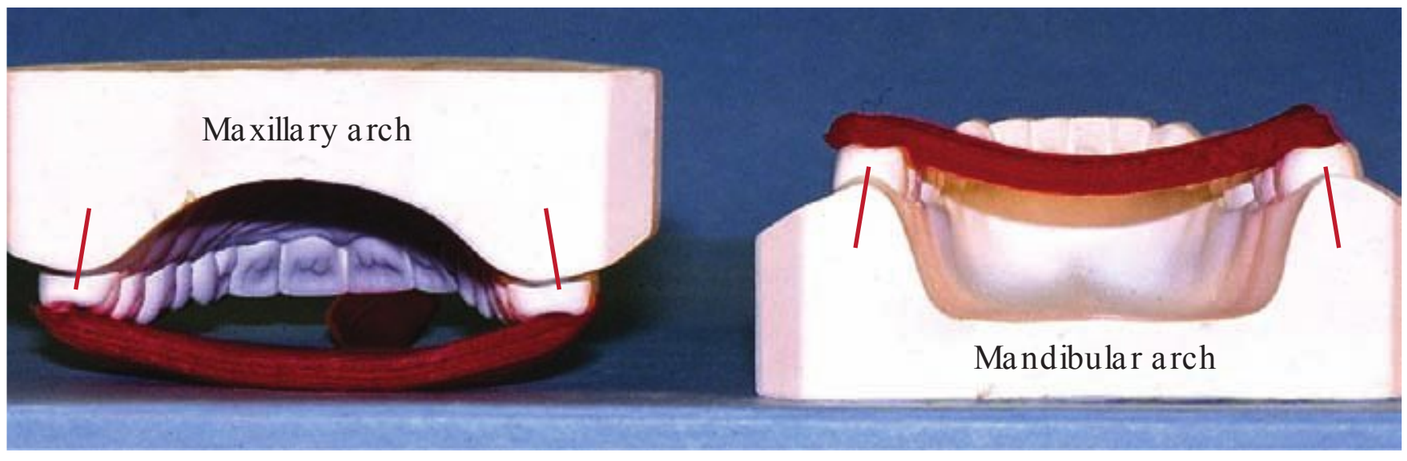

FIgur E 1-48. Dental stone casts viewed from the distal with a wax strip used to demonstrate the **m**edi**o**lateral curve (of Wilson). It is convex in the maxillary arch, but concave in the mandibular arch. Note the red lines that denote posterior tooth alignment within each arch: maxillary molar crowns tilt toward the *f*acial, and mandibular molar crowns tilt toward the lingual.

tips in a quadrant do not normally fall along a ruler-straight line. T e axial alignment changes gradually from posterior to anterior teeth, which is evident when you compare the alignment of the mandibular third molar (tipped noticeably more to the mesial) than on the first premolar. Subsequently, if you were to connect the buccal cusp tips with a line, a gradual **anteroposterior curve** (curve of Spee) is evident (see Fig. 1-47). T is curve is convex in the maxillary arch, while the curve is concave in the mandibular arch.

When viewed from the distal, maxillary posterior teeth are axially tilted facially within the maxillary arch, whereas mandibular posterior teeth are tilted lingually within the mandibular arch (Fig. 1-48). T erefore, in the mouth, lingual cusps of maxillary posterior teeth appear longer than the buccal cusps, while the lingual cusps of mandibular posterior teeth appear shorter than the buccal cusps due to the lingual tilting within the mandible. However, to avoid confusion, you need to realize that later in the book, you will learn that when you hold a mandibular molar in your hand with the midroot axis aligned vertically, the lingual cusps of mandibular molars are actually slightly longer than buccal cusps (Fig. 1-49). When a line connects the buccal and lingual cusps of the same type of molars and premolars on opposite sides of the arch, this side-to-side curve is the **mediolateral curve** (of Wilson). T e mediolateral curve of the maxillary arch is convex, whereas that of the mandibular arch is concave (Fig. 1-48).

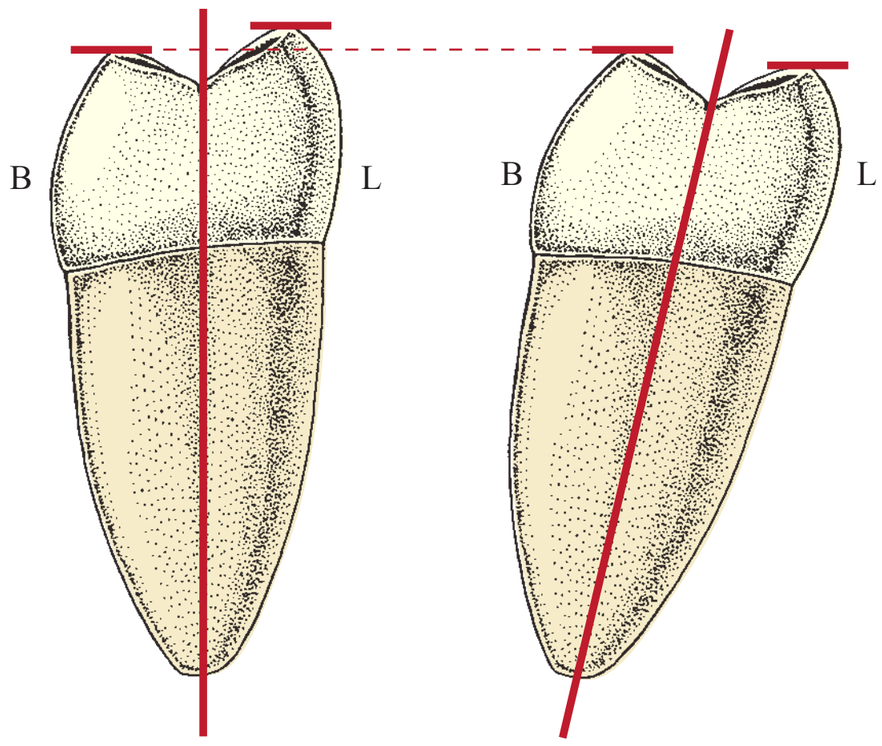

FIgur E 1-49. This mandibular second molar with its mid-root axis aligned vertically (left drawing) has lingual roots that appear longer, whereas the same tooth with the midroot axis tipped lingually, as it would be in the mandible, has lingual cusps that appear shorter.

B. Cr EST OF Cu r va Tu r E (h EIg h T OF CONTOu r) ON Th E Fa CIa L a Nd LINg u a L Su r Fa CE

T e shape and extent of the greatest bulge on the facial and lingual crown surfaces help determine the direction that food particles are def ected as they are crushed between tooth surfaces when chewing. When we chew food, these natural tooth convexities divert food away from the thin free gingiva and gingiva sulcus surrounding the cervix of the tooth and toward the firmer tissues of the mouth, thus minimizing trauma to the gingiva. If teeth were f at facially and lingually, food could more likely damage the gingiva (Fig. 1-50). Needless to say, it is best for the dentist, dental hygienist, and/or dental technician to reproduce and maintain these natural convexities when restoring a tooth, when finishing and polishing fillings near the gum line, or when contouring a replacement tooth crown.

T e facial **or lingual crest of curvature** (**height of contour**) is the point on a crown outline where a line drawn parallel to the midroot axis line touches the greatest bulge on the crown (Fig. 1-51). It is usually located in either the cervical third or the middle third, normally not in the occlusal or incisal third. When viewed from the proximal, the location of the crest of curvature on the facial surface on both anterior and posterior tooth crowns is normally located in the cervical third. T e location of the lingual crest of curvature depends on whether the tooth is anterior or posterior. T e lingual crest of curvature on anterior teeth is in the cervical third, on the cingulum (Fig. 1-46B). T e lingual crest of curvature on posterior teeth is most often located in the middle third (Fig. 1-51). Refer to Table 1-4 for a summary of the location of the facial and lingual heights of contour for anterior teeth compared to posterior teeth.

C. CONTa CT a r Ea S (Or pr OxIma L Cr ESTS OF Cu r va Tu r E)

When the teeth are in normal, ideal alignment within an arch and viewed directly toward the facial or lingual surfaces, the location of the mesial or distal greatest bulges or crests

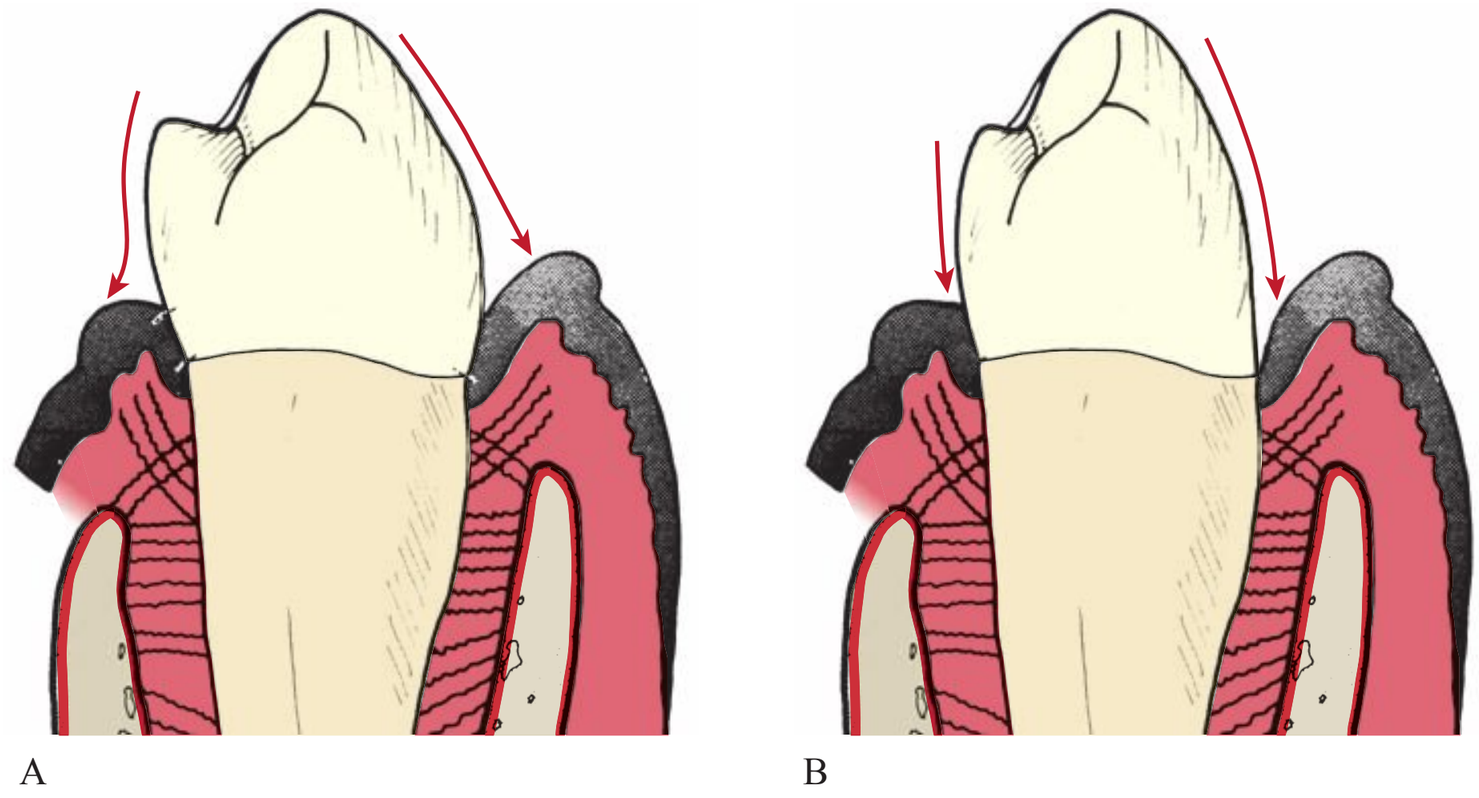

FIgur E 1-50. A. Normal *f*acial and lingual crests of curvature help divert food away from the gingival sulcus. B. When crests of curvature are not adequate, food can more readily damage the gingival sulcus.

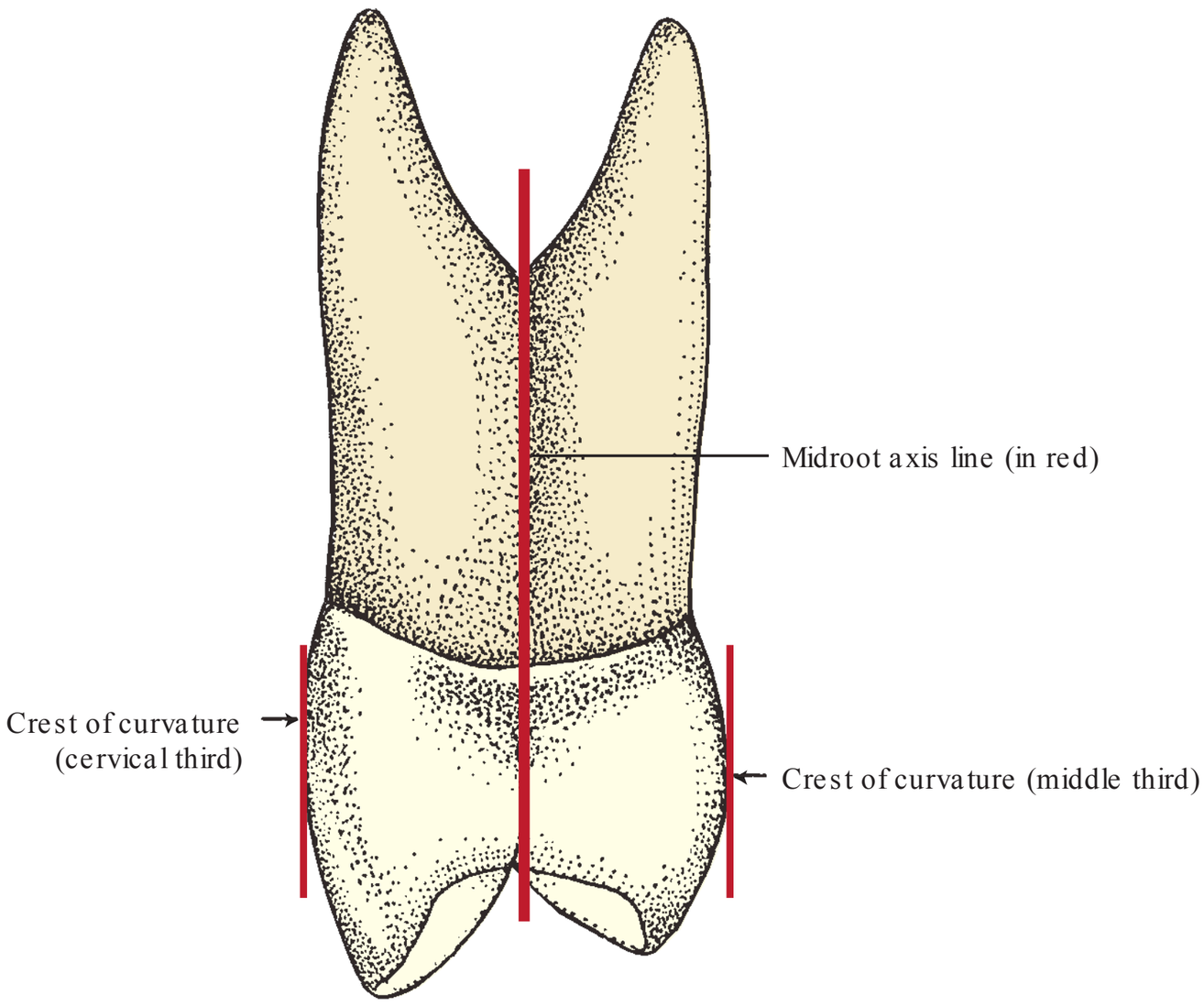

FIgur E 1-51. On the proximal view of this premolar, the buccal crest **of** curvature (height of contour) is located in the cervical third, while the lingual height of contour is located more occlusally, in the middle third. This is typical of most posterior teeth.

TABLE 1-4 Summary of the Location of Facial and Lingual Heights of Contour (Greatest Bulge) of the Crown (Best Seen from the proximal view)

	FACIAL (HEIGHT OF CONTOUR)	LINGUAL (HEIGHT OF CONTOUR)
Anterior teeth (incisors and canines)	Cervical third	Cervical third (on cingulum)
Posterior teeth (premolars and molars)	Cervical third	In or near middle third

General learning guidelines:
1. Facial crest of curvature for all teeth is in cervical third.
2. Lingual crest of curvature for all anteri**o**r teeth is in the cervical third (on the cingulum).
3. Lingual crest of curvature for p**o**steri**o**r teeth is in the **m**iddle third (slightly more occlusal in mandibular teeth due to the lingual tilt of the crown).

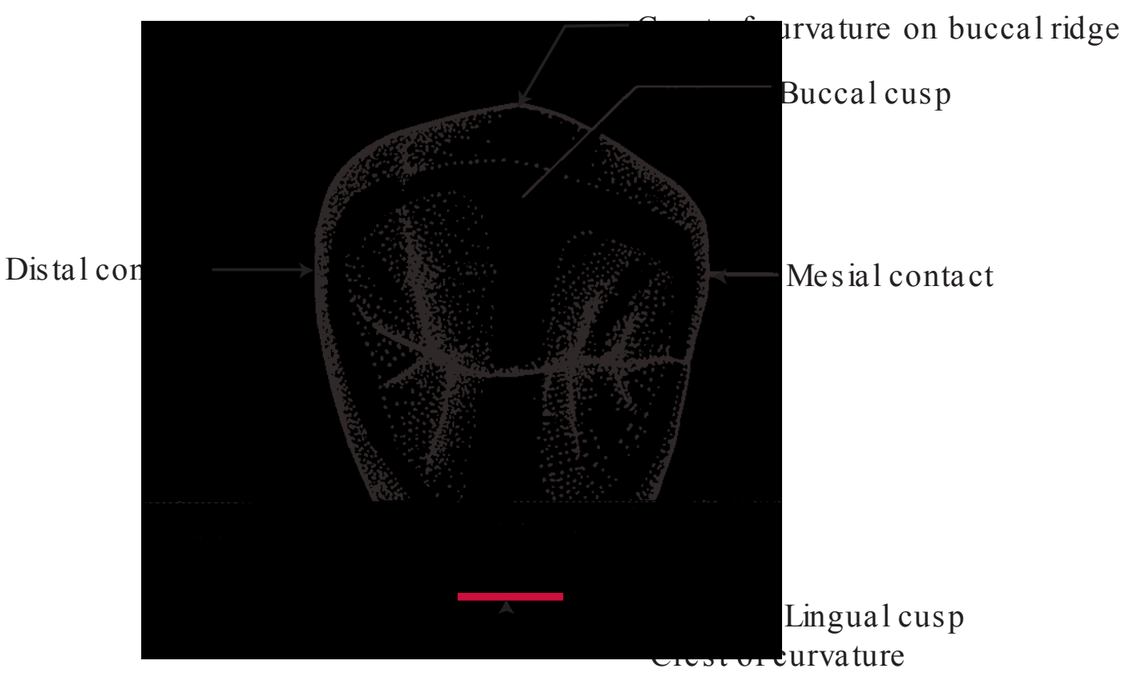

FIgur E 1-52. The mesial and distal contact areas seen on the occlusal view of this two-cusped maxillary premolar are located buccal to the center of the tooth buccolingually, which is typical of most posterior teeth.

of curvature is essentially the same location as **contact areas** where two adjacent teeth touch (labeled on a canine from the facial view in Fig. 1-46A and on a premolar from the occlusal view in Fig. 1-52).

In a young person, contacts between teeth start off between recently erupted teeth as contact points. T en, as the teeth rub together during function, these points become somewhat f attened and truly become **contact areas**. (It has been shown by careful measurements that by age 40 in a healthy mouth with a complete dentition, a total of 10 mm of enamel has been worn off the contact areas of all teeth in an entire arch. T is averages 0.38 mm per contact area on each tooth and certainly emphasizes the amount of proximal wear that occurs. T erefore, we would expect contact areas on teeth of older people to be large and somewhat f attened.)

T e proximal contact of each tooth with the adjacent teeth has several important functions:

- T e positive contact of all teeth within each dental arch stabilizes the position of teeth within each arch.
- When chewing, tooth contacts help prevent food from being forced between the teeth where it could contribute to decay and gum and bone disease (periodontal disease). Further, you must be able to pass f oss through each contact area in order to clean the proximal surfaces, which are otherwise inaccessible to the toothbrush.
- Contact protects the thin interdental papillae of the gingiva by diverting food buccally and lingually.

A **diastema** [di ah STEE mah] is a space that exists between two adjacent teeth in the same arch that is not the result of a missing tooth. It is most commonly seen between the maxillary right and left central incisors, but can occur between any teeth (Fig. 1-53A and B).

When learning the normal location of the **proximal contacts** for each type of tooth, it will be helpful to learn the following general guidelines that apply to most permanent teeth. Exceptions to these general rules will be presented in later chapters.

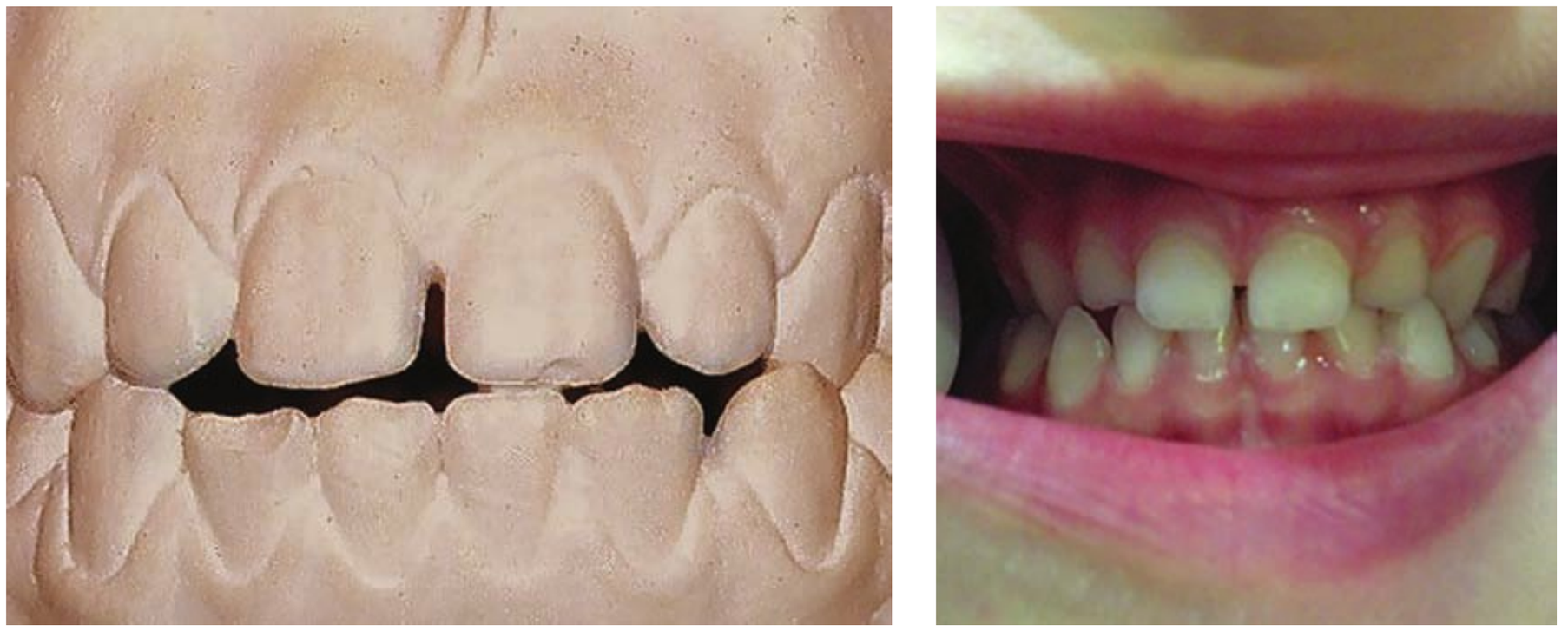

A B

FIgur E 1-53. A. This stone model has a space between maxillary central incisors called a diastema. B. On these primary teeth, there is an obvious diastema between the maxillary central incisors.

SECTION VI Importance of Forensic Dentistry to Practicing Dentists

Forensic dentistry is a large area of special interest. This short chapter could only provide a brief overview of the importance of dental anatomy as a foundation for the effective practice of the specialty. All dental professionals must maintain accurate and comprehensive dental records for legal, standard-of-care, and forensic purposes. This includes written records, radiographs, and models that accurately describe or reproduce the oral anatomic and anthropologic forms in detail. The weakest link in the dental identification process (subsequent to locating the antemortem dentist of record) is the quality of the dental written and radiographic record. These records are the first step in the practice of forensic dentistry by every dental professional.

Even if the average dentist does not intend to be involved in forensic dentistry, the probability is that eventually he or she will be contacted regarding questions about quality of care or observed injuries (such as suspected child or spousal abuse) or from law enforcement agencies requesting help. A valuable contribution can be made by understanding the role of dentistry in forensic science, by recognizing dental evidence or a bite mark, and by helping to properly preserve crucial evidence for later analysis.

The dental professional must understand how dental anatomy knowledge is valuable in forensic procedures. Other chapters of this text describe in more detail some of these anatomic features. The presence of a cusp of Carabelli on a maxillary first molar will identify a person as Caucasian heritage. Shovel-shaped incisors will identify a person of Mongoloid or Asian origin. Tooth root apex development is an age indicator. Cusp contours of lower premolars assist in the orientation of bites in a bite mark case when one understands cusp anatomy of lower versus upper premolars. Root dilacerations, pulp stones, pulpal recession in the elderly or bruxing patient, maxillary sinus morphology, and virtually all aspects of dental anatomy are useful in the forensic identification of an individual or for assessing standard-of-care issues. In some cases, as in the World Trade Center disaster, the ability to identify a single tooth as a maxillary versus mandibular premolar was the key to the ability to search the database of antemortem records and confirm identification.

You will find dental anatomy the foundation or basis for any forensic dentistry investigation. The references offered within this chapter were selected to give the novice a practical and representative introduction to the field and techniques of forensic dentistry.

GENERAL REFERENCES

Seven concise articles with an overview introduction on bite marks, crime investigation, child abuse, photographic computers, and mass disasters are presented in the May 1996 Journal of the California Dental Association.

American Board of Forensic Odontology. Guidelines for bite mark analysis. J Am Dent Assoc 1986;112(3):383–386. Available at: http://www.abfo.org

American Society of Forensic Odontology's information source via the Internet: http://www.asfo.org

Bowers CM. Forensic dental evidence. Boston, MA: Elsevier Academic Press, 2004

Bowers CM, Bell GL, eds. Manual of forensic odontology. 3rd rev. ed. Saratoga Springs, NY: American Society of Forensic Odontology, 1997. This manual can be obtained from the American Society of Forensic Odontology at http://www.asfo.org

Clark DH, ed. Practical forensic odontology. Boston, MA: Wright (Butterworth-Heinemann Ltd), 1992.

Cottone JA, Standish SM. Outline of forensic dentistry. Chicago, IL: Year Book Medical Publishers, Inc., 1982.

deVilliers CJ, Phillips VM. Person identification by means of a single unique dental feature. J Forensic Odontostomatol 1998;16(1): 17–19.

Dorion RB. Bitemark evidence. New York, NY: Marcel Dekker, 2005.

Gill GW, Rhine S. Symposium ed: Skeletal attribution of race—methods for forensic anthropology. Albuquerque, NM: Manual available from Maxwell Museum of Anthropology at the University of New Mexico, 1990.

Guidelines for bite mark analysis by the American Board of Forensic Odontology. J Am Dent Assoc 1986;112:383–386.

Gupta P, Harsaminder K, Shankari M, et al. Human age estimation from tooth cementum and dentin. J Clin Diagn Res 2014;8(4): 7–10.

Harvey W. Dental identification and forensic odontology. London, UK: Henry Kimpton Publishing, 1976.

Krogman W. The human skeleton in forensic medicine. Springfield, IL: Charles C. Thomas Publishers, 1973.

Lampe H, Roetzcher K. Age determination from adult human teeth. Med Law 1994;13(7–8):623–628.

Luntz L, Luntz P. Handbook for dental identification. Philadelphia, PA: J.B. Lippincott, 1973.

Melia E, Carr M. Forensic odontology and the role of the dental hygienist. Access 2005;19(3):15–23.

Nuckles DB, Herschaft EE, Whatmough LN. Forensic odontology in solving crimes: dental techniques and bite mark evidence. Gen Dent 1994;42(3):210–214.

Rothwell BR. Bite marks in forensic dentistry: a review of legal, scientific issues. J Am Dent Assoc 1995;126(2):223–232.

Senn DR, Weems RA, eds. Manual of forensic odontology. 5th ed. American Society of Forensic Odontology, 2013. This is manual can be obtained from the American Society of Forensic Odontology at http://www.asfo.org and from www.amazon.com

Sopher M. Forensic dentistry. Springfield, IL: Charles C. Thomas, 1976.

Standish SM, Stimson PG. Symposium on forensic dentistry: legal obligations and methods of identification for the practitioner. Dent Clin North Am 1977;21(1):145–158.

Committee on Identifying the Needs of the Forensic Sciences Community; Committee on Applied and T eoretical Statistics, National Research Council. Strengthening Forensic Science in the United States: A Path Forward. 2009 (ISBN: 0-309-13131-6, 24 pages).

Stimson PG, Mertz CA. Forensic dentistry. Vol. 21(1). Boca Raton, FL: CRC Press, 1997.

Wood JD, Gould G. Mass fatality incidents: are California dentists ready to respond. J Calif Dent Assoc 2004;32(8):681–688.

Wright FD. Integrating new technologies in bite mark analysis. Am Soc Forensic Odontol News 1999; Winter.

Wright FD. Forensic dentistry: an introduction. Columbus, OH: Ohio Dental Association, 2005.

13 Guidelines for Drawing, Sketching, and Carving Teeth

I. Drawing teeth
   - A. Materials needed
   - B. How to accurately reproduce a tooth outline
   - C. Example: accurately reproduce the shape of a mandibular canine (copying an actual tooth or tooth model)

II. Sketch teeth recognizably from memory

III. Carving teeth
   - A. Materials needed
   - B. How to carve a tooth
   - C. Example: how to carve a maxillary central incisor from a block of wax
   - D. Advice

Objectives

This chapter is designed to prepare the learner to perform the following:

- Carefully draw a tooth to reproduce its contours precisely from various views.
- From memory, sketch (quickly) teeth from various views so that the sketch is recognizable as the tooth is being sketched.
- Reproduce the contours of a tooth in wax.

SECTION I Drawing Teeth

A. Materials Needed

- Graph paper ruled eight squares to the inch
- Drawing pencil, sharpened to a fine point
- Eraser
- Ruler with millimeter scale
- Boley gauge
- Teeth or tooth model
- Chart with dimensions of tooth to be drawn (such as Table 1-7)

B. How to Accurately Reproduce a Tooth Outline

To accurately reproduce the outline of any object, not only must you look at the object but you must also study and visualize it. Rarely is there a person, however, lacking in artistic skill, who cannot make a reasonably good drawing of a human tooth. Those who are not skilled in accurate drawing (extensive art training does not necessarily result in accuracy of outline) may find a solution in using graph paper ruled

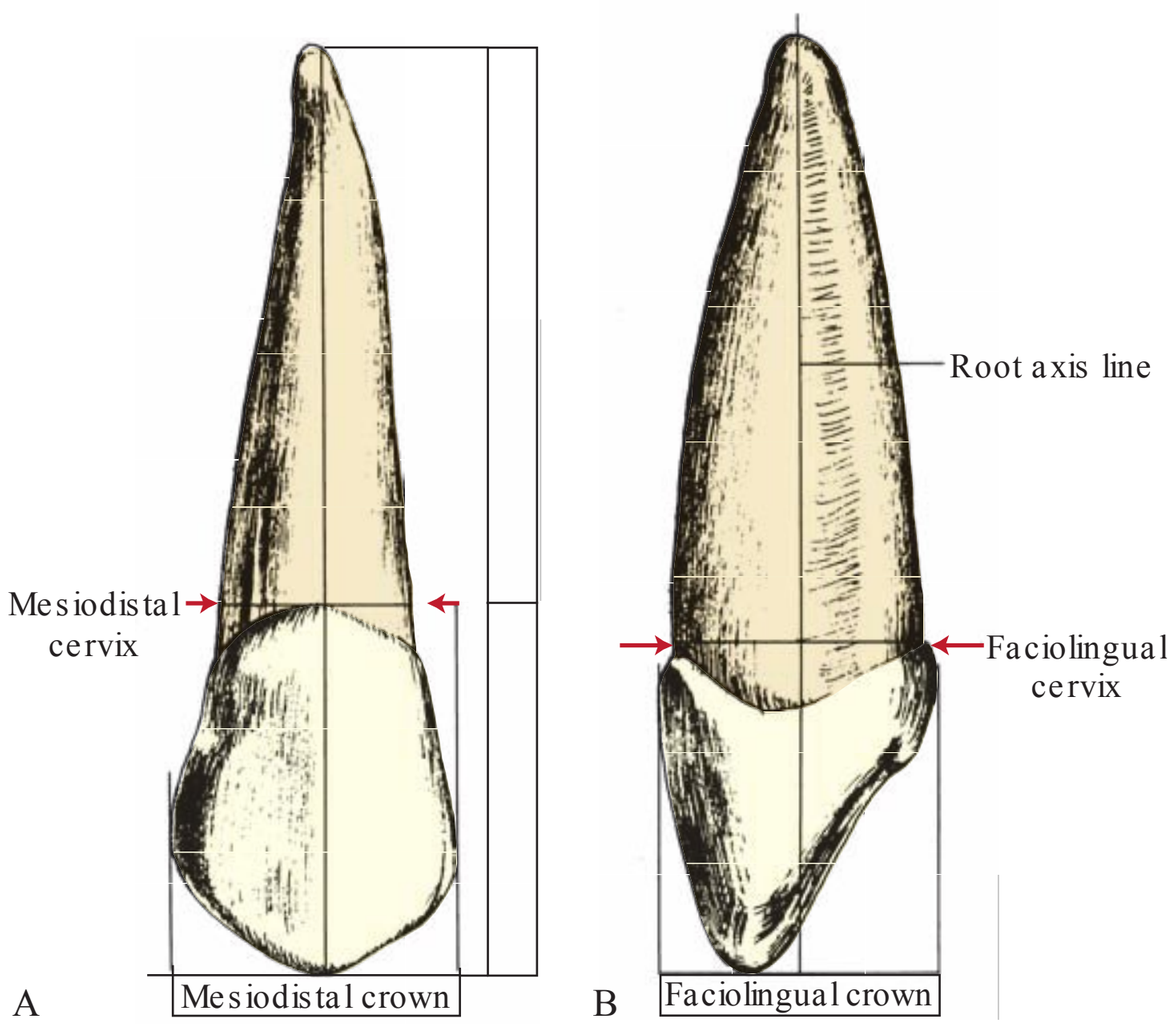

fIgur E 13-1. A. Facial side of a maxillary right canine tooth model showing how measurements of a tooth may be made to assist in drawing and carving. B. Mesial side of the same maxillary canine showing how tooth measurements can be made and how the incisal portion is positioned relative to the root axis line.

eight squares to the inch. The tooth specimen is measured in millimeters with a Boley gauge, and the measurements are transferred to the graph paper, allowing one square to equal 1 mm. Drawings may be made to scale of each type of tooth: maxillary and mandibular incisors, canines, premolars, and molars. All drawings should depict maxillary teeth with crowns down and mandibular teeth with crowns up, the same orientation they have in the mouth.

Using an undamaged extracted tooth or a tooth model for a specimen, make the following six measurements with the Boley gauge (Fig. 13-1A and B):

- Root length
- Mesiodistal crown width
- Faciolingual crown width
- Mesiodistal cervix
- Faciolingual cervix

Using a consistent method of measurement avoids confusion. On anterior teeth, measure the crown length on the facial side from the cervical line to the incisal edge. On premolars, measure the crown length on the facial side from the cervical line to the tip of the buccal cusp. On molars, which have more than one buccal cusp, crown length is always to the mesiobuccal cusp tip. Make the other cusps their proper length relative to the measured cusp, that is, either longer or shorter. With more than one root, the overall tooth length is measured from the mesial or mesiobuccal root apex to the mesiobuccal cusp (refer to Table 1-7).

Plan how you want to place your drawings on the graph paper. One convenient arrangement is facial aspect, upper left corner; lingual aspect, upper right; mesial aspect, lower left; distal aspect, lower right; and incisal aspect, center (Figs. 13-2 and 13-3). These views will be centered nicely if you allow a four square border on all sides of the paper, as shown in the same illustrations.

C. ExaMplE: aCCuraTEly rEprODuCE ThE ShapE Of a *Mandibular Canine* (COpyINg aN aCTual TOOTh Or TOOTh MODEl)

1. facial Views

Use the measurements you have made of the tooth specimen you intend to draw. Begin with the outlines for the facial view of the tooth in the upper left corner of the page and count down from the upper four square border the number of squares and fraction thereof equal to the crown length in millimeters and draw a horizontal line. From this line, count down the number of squares equal to the root length in millimeters and draw a second horizontal line. From the inside of the left four square border, count to the right the number of squares equal to the mesiodistal crown measurement and draw a vertical line. You will draw the facial aspect of the tooth inside the box. Make your lines very light at first so that corrections can be made easily. Remember to begin from the four square margin (top and side), as seen in Figure 13-2.

Before you start to draw the crown from the facial view, make a light mark at the locations of the mesial and distal contact areas of the crown. (A pencil or straight edge held vertically against the side of the tooth parallel to the root axis line will help you determine where to put these light marks.) Then, mark the location of the apex of the root. Also, mark the mesiodistal width of the cervix of the tooth on the horizontal line that separates the crown from the root. When you fit the crown into the box, if you remember to keep the root vertical, the midroot axis will not always be an equal distance from the mesial and distal sides because the crowns of some teeth are tilted distally. Mark off the mesiodistal cervical measurement very lightly.

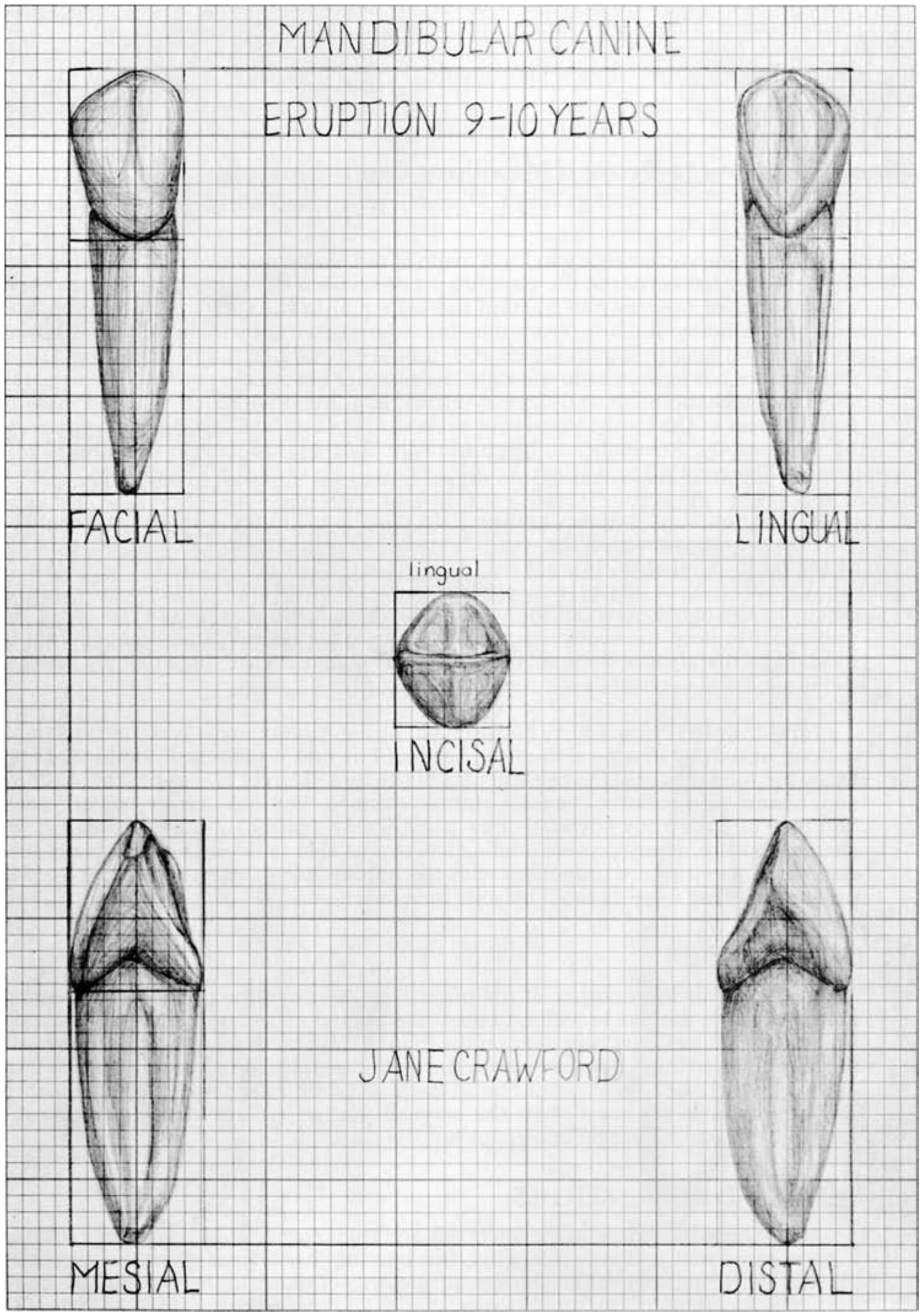

fIgur E 13-2. A precise drawing on graph paper of a model of a mandibular right canine by a frst-year dental hygiene student.

Now, draw in the curvature of the crown at the contact areas (you marked the location) and draw in a portion of the cervical line and the incisal cusp ridges. Draw the root apex and the cervical part of the root. Correct any errors in location or shape, and then, connect the lines you have drawn. You have a drawing of a tooth. You may be pleasantly surprised how natural and morphologically correct this first sketch appears. Many professional artists are unable to depict natural teeth accurately because they are unfamiliar with tooth morphology, and they do not have the proportions that were dictated by your measurements.

2. lingual Views

In the upper right corner of the page (Fig. 13-2), use the same set of measurements to make the box in which to draw the lingual aspect of the tooth. Remember that almost all teeth taper toward the narrower lingual surface, but the overall outline from the lingual is the same width as from the facial view. The cingulum is narrower than the cervical portion on the labial sketch, and it should be drawn centered or a little toward the distal.

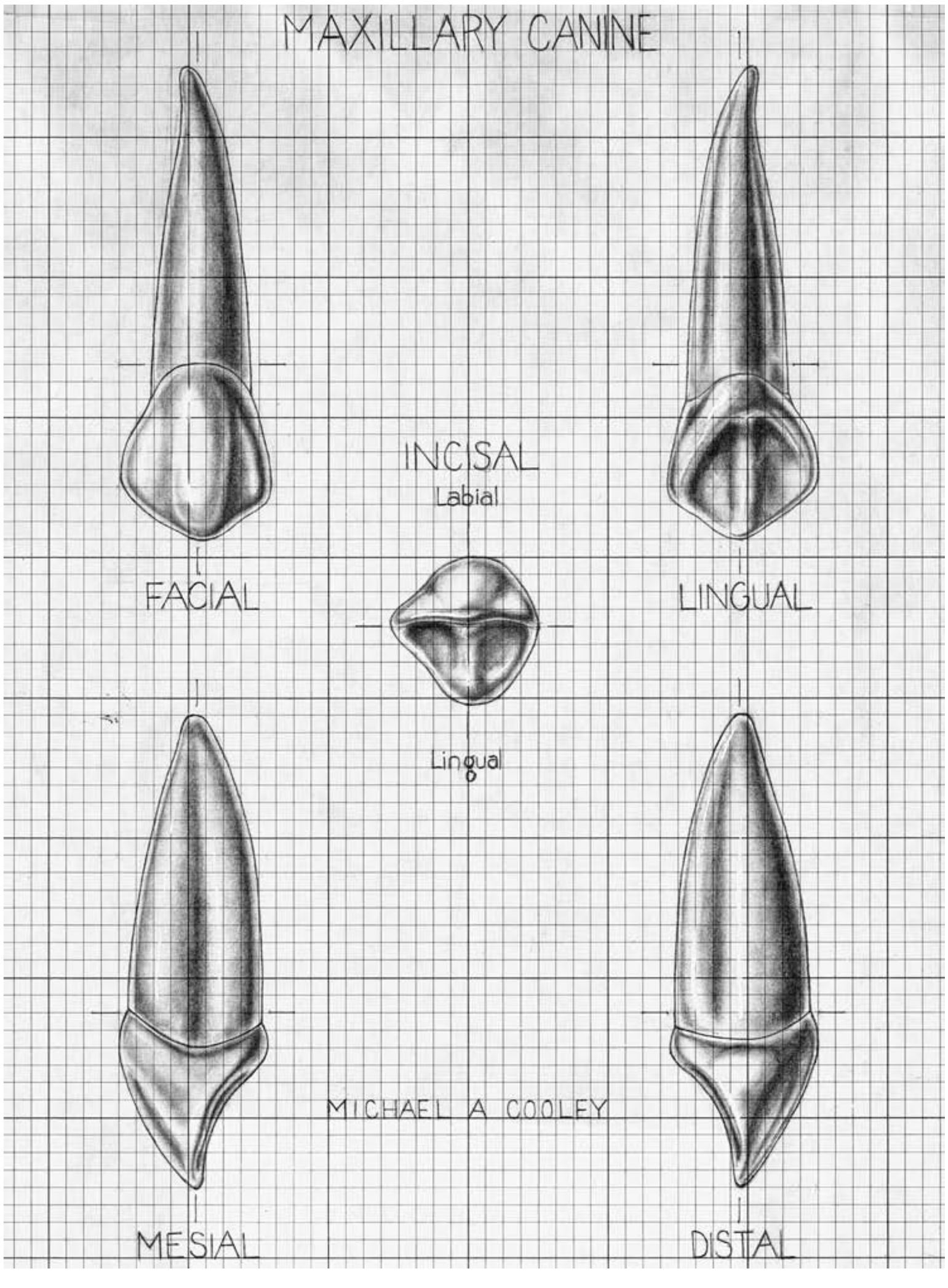

fIgur E 13-3. Professional drawing (by medical artist) of a model of a maxillary canine based on dimensions given in Table 1-7.

3. Mesial and Distal Views

Draw these two boxes in the lower left and right corner of the page (Fig. 13-2) using the same root and crown lengths. However, use the faciolingual crown measurement instead of the mesiodistal measurement. Before you start to draw the tooth, lightly mark the locations of the incisal edge, the labial crest of curvature (i.e., where the curve or greatest convexity of the labial surface will touch the line of the box), and the crest of curvature on the cingulum (Fig. 13-1B) and the root tip. Mark the faciolingual width of the cervix. Then, draw the tooth. Remember to leave the four square border at each side and below these views.

4. Incisal View

Near the center of the page, draw a box with the distance between the upper and lower horizontal lines the exact number of squares for the faciolingual measurement of the crown in millimeters. The distance between right and left vertical lines of this box should equal the number of the squares of the mesiodistal crown measurement in millimeters. Hold the tooth facial side down and in such a position that you are looking exactly in line with the root axis line. Be sure that the tooth crown is not tilted up or down. On the sides of the box, mark the places where you are going to locate the mesial and distal contact points of the crown. The

incisal edge of the tooth will normally have a slight lingual twist of the distoincisal corner (not evident in Fig. 13-2) and will lie either in the center of the box faciolingually or slightly lingual to the center (in the same position it is shown on your drawings of the mesial and distal aspects). The cingulum is normally centered on, or slightly distal to, the root axis line.

Do you find any straight lines (as on a straight ruler) on any tooth other than those lines that have been produced by attrition? This would be most unusual.

Using the same approach, you will be able to draw other types of teeth. Labeling the grooves, the fossae, and the ridges on the occlusal surfaces of the posterior teeth will help to fix the morphology in your mind.

SECTION II SkETCh TEETh rECOgNIzaBly frOM MEMOry

The extremely precise and accurate drawings described in Section I of this chapter have the value of developing skills to accurately visualize and reproduce the subtle outlines and exact grooves of a specific tooth from various views. However, this time-consuming method of copying teeth may have limited value in helping the student to quickly sketch a tooth from memory for a specified view as might be expected during a conversation with an instructor or a patient. Therefore, this section includes guidelines that can be useful for dental and dental hygiene students when learning how to quickly sketch a specific tooth and view from memory.

In order to sketch a facial view of a recognizable tooth from memory, the drawer must have knowledge of the following characteristics related to the tooth being drawn: (a) approximate crown-to-root ratio (i.e., how much longer is the root compared to the crown), (b) approximate crown proportions (i.e., which is wider: the crown width or its length), (c) location of the crown heights of contour (crests of curvature), (d) crown shape (taper, incisal edge shape or number and relative size of cusps, and cementoenamel junction [CEJ] shape), and (e) root shape (taper and number of roots) when drawing the entire tooth. If one considers each of these tooth characteristics in the appropriate order, sketching a tooth becomes a relatively easy task and is an excellent exercise to apply all of the knowledge of dental morphology that was presented in Section I of this text: Comparative Tooth Anatomy.

As an example, consider a sketch of a right maxillary central incisor from the facial view. Follow along with Figure 13-4 as you read about each step.

Step A: Consider the root-to-crown ratio. It is not expected that a student will remember the exact ratio of this tooth (1.16 to 1), but rather he or she should recall that all roots are normally longer than the crown. On maxillary central incisors, the root is only slightly longer than the crown. Based on this fact, three parallel horizontal lines can be drawn to denote the distance of the crown length from incisal edge to the cervical line relative to the root length from cervical line to root apex (only slightly longer). Position the smaller crown length on top for the mandibular teeth and on the bottom for maxillary teeth. For this maxillary central incisor, the crown length is on the bottom.

Step B: Consider the proportions of the crown, that is, the crown height (incisocervically) compared to its width (mesiodistally). Again, you do not need to memorize that the average crown width for this tooth is 8.6 mm and its average length is 11.2 mm, but you should recall that the maxillary central incisor crown is slightly longer than it is wide. Using this knowledge, two parallel vertical lines can be placed perpendicular to the horizontal lines to establish the proportion for the tooth crown. Extending these vertical lines along the entire tooth length results in the formation of two boxes: a crown box that will surround the crown and a root box that will enclose the root. At this time, label the mesial (M) and distal (D) surfaces of the crown box that is dependent on whether you are viewing a right or left incisor. For this right incisor, the mesial surface is on the right side of the box, and the distal is on the left side, as if you were facing the patient.

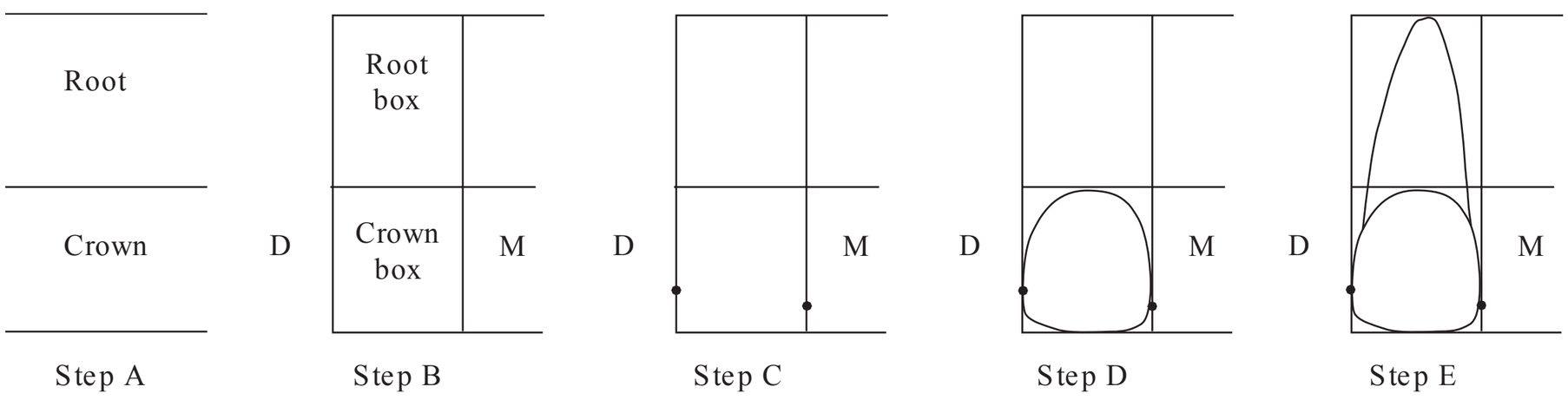

fIgur E 13-4. Five steps involved in sketching the facial view of a tooth (in this case, a right maxillary central incisor).

Step C: Consider the heights of contour (crests of curvature) on the mesial and distal surfaces. Since these two points are the widest parts of the tooth crown where the mesial and distal surfaces bulge out the most, they are therefore the points where the crown outline touches the crown box established in the previous step. When the teeth are in ideal alignment, they are the location of the proximal contacts. On all incisors, the proximal heights of contour (contacts) occur in the incisal one third (EXCEPT on the distal of a maxillary lateral incisor, which is in the middle third) and are located more incisally on the mesial surface than on the distal surface (EXCEPT on the symmetrical mandibular central incisor). With this knowledge, a dot can be placed on the mesial and distal crown box outline at the appropriate levels. It is not until this step is complete that you actually begin sketching the tooth crown shape (outline).

Step D: Begin sketching the crown outline. Use as many of the criteria presented in the Appendix as you can recall in order to sketch a recognizable tooth. For example, on a maxillary central incisor, we know that the areas immediately surrounding all contact areas are convex, mesial and distal crown walls taper slightly toward the root, and the incisal edge is almost flat or slightly convex and is a little shorter toward the distal. We also know that the cervical line from the facial view is broad and curves toward the apex. Based on this knowledge, begin sketching the crown outline by placing subtle convexities that touch the crown box at the heights of contact points (dots). These convexities blend apically to become the mesial and distal crown walls, and these walls converge (just slightly) toward the cervical line. The proximal convexities also curve incisally to blend with the relatively straight incisal edge that touches the incisal line of the crown box in the mesial half and tapers shorter (farther from the box outline) toward the distal. Finally, the cervical line appears as a continuation of the mesial and distal walls and curves toward the apex, just touching the cervical line of the crown box. If a sketch of the crown were all that you are reproducing, you would be finished. If, however, you wish to add the root, proceed to the final step.

Step E: Sketch the root. We know that the apex of the root is near the center of the tooth root axis (a vertical line in the center of the root at the cervix). We also know that roots are broadest in the cervical third (but not very much narrower than the width of the crown), may be nearly parallel in the cervical third, and taper toward the rounded apex. Based on this knowledge, you can finish the sketch. Be aware that part of the root outline where it joins the CEJ is actually visible within the crown box, and the rounded apex just touches the apical line of the root box.

When sketching other teeth from the facial views, use steps A through C as described earlier for developing the "boxes" and crests of curvature, and refer to the appendix pages for tooth traits when sketching the actual tooth outlines. With practice, teeth can be sketched without the boxes in less than a minute while still maintaining the approximate proportions and heights of contour. See the student sketch of a recognizable mandibular second molar from the buccal view in Figure 13-5A.

The steps used to sketch the lingual view of all teeth are the same as for the facial view EXCEPT the outline is a mirror image of the facial view. Also, on this surface of anterior teeth, there is normally evidence of a narrower crown cingulum, marginal ridges, a lingual fossa, and a cervical line that often

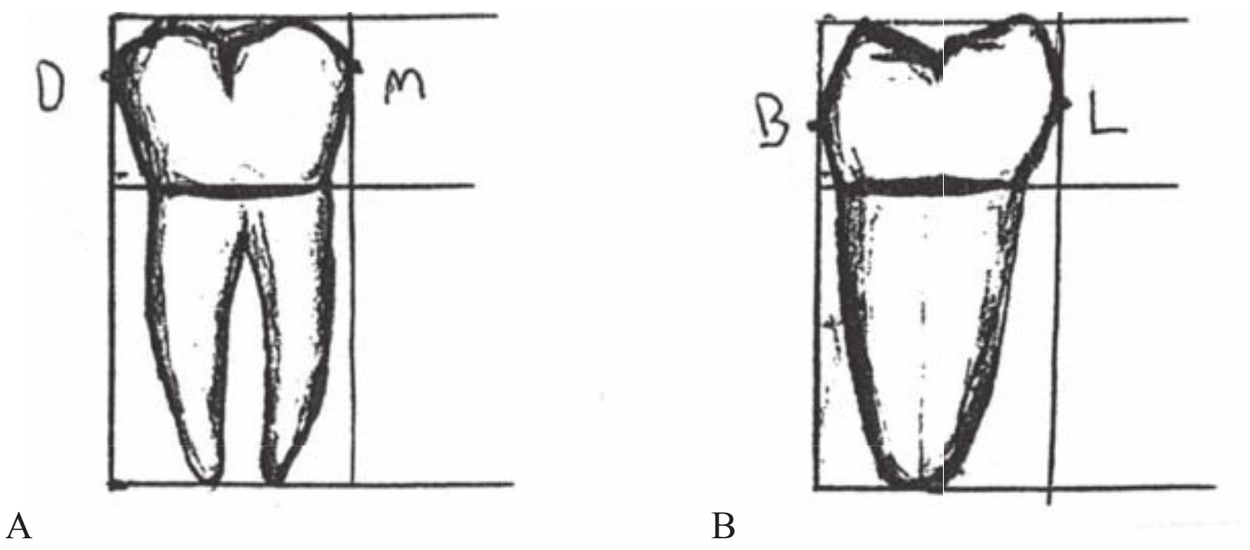

fIgur E 13-5. Four sketches of teeth by frst-quarter dental and dental hygiene students: although not perfectly drawn, each sketch is recognizable as the tooth being drawn. A. Right mandibular second molar, facial (buccal) view. B. Right mandibular frst molar, mesial view. C. A right mandibular frst molar, occlusal view. D. A right maxillary frst molar, occlusal view. Sketches (A) and (B) would look nicer if the lines were not so wide and dark.

includes a partial view of the proximal CEJ due to the taper of teeth toward the lingual (as seen in Fig. 13-2, lingual view). On maxillary molars, the lingual root is now in the foreground.

When sketching the proximal view of teeth, the first two steps are similar to steps A and B above except that the crown outline box is developed for this view by using the faciolingual and inciso- or occlusocervical crown proportions. The facial crest of curvature is similar for all teeth: in the cervical third. Lingually, the crest of curvature is in the cervical third on the cingulum for anterior teeth but in the middle third for most posterior teeth. Develop a crown and root shape according to guidelines in the Appendix. See the student sketch of a mandibular second molar from the mesial view in Figure 13-5B.

Posterior teeth from the occlusal view are viewed looking directly down along the axis of the root. Crown-to-root ratios do not apply from this view. The crown outline box is developed for this view by using the mesiodistal and faciolingual crown proportions. On mandibular premolars, the crown proportions are slightly longer buccolingually than mesiodistally, but close to square. Maxillary premolars from the occlusal view are similar to mandibular premolars except crown proportions are less square, more rectangular: proportionally wider buccolingually than mesiodistally. Mandibular molars from the occlusal view are wider mesiodistally than buccolingually, whereas maxillary molars are slightly wider buccolingually than mesiodistally. The crests of curvature on molars and premolars on the mesial and distal surfaces are located in the center or slightly to the buccal of the buccolingual midline. The buccal and lingual crests of curvature for molars are located mesial to the middle, except on the buccal of the mandibular first molar where it is close to the middle. After the outline "box" is sketched and crests of curvature have been noted, sketch the crown outlines using descriptions from the appendix pages.

An additional challenge on these views involves reproducing the location of the cusp tips, grooves, and pits (as must be accomplished by dental personnel every time a restoration is placed on an occlusal surface, finished and polished, or constructed or carved in wax in the laboratory).

Cusp tips can be identified by placing small dots (or small circles) on the sketches at these locations. It may be helpful to remember these basic guidelines regarding pits and grooves. Most premolars have a mesial and distal pit connected by a groove running mesiodistally between buccal and lingual cusps. Most molars (and three-cusped mandibular second premolars) have three pits (mesial, central, and distal) that are also connected by a groove passing mesiodistally between buccal and lingual cusps. Molars also have one or two buccal grooves that separate the two or three buccal cusps, respectively. On mandibular molars, the lingual groove comes off near the central pit, but on maxillary molars, a lingual (distolingual) groove comes off of the distal pit and parallels the oblique ridge. Developmental triangular or fossa grooves or supplemental grooves may angle off from the mesial and distal pits of most posterior teeth, directed toward the "corners" of the tooth. See the student sketches of the occlusal views of two recognizable molars in Figure 13-5C and D.

SECTION III Carving Teeth

A. Materials Needed

- Blocks of carving wax (34 mm × 17 mm × 17 mm for molars or 32 mm × 12 mm × 12 mm for other teeth)
- Boley gauge (Vernier caliper)
- Millimeter ruler
- Office knife and sharpening stone
- Roach carver, No. 7 wax spatula, and PKT-1 (for melting and adding wax)
- No. 3, No. 5 to 6, 6C, and PKT-4 carvers
- Sharpened drawing pencil
- Large or small tooth model and its measurements

B. How To Carve a Tooth

Carving a tooth helps you to see the tooth in three dimensions and also to develop considerable manual skill and dexterity. Examples of carvings by dental hygiene students are shown in Figure 13-6. While eventually you may be able to carve a tooth from a block of wax without preliminary measurement, the beginner can only do well by approaching the carving systematically in the same way you approached the drawings: first, by drawing a box on the wax block; second, by sketching an outline of the tooth in the box; and third, by carving around the sketch or outline, one view or aspect at a time (sequence is shown in Fig. 13-7).

When approaching the task of carving a tooth, consider Michelangelo who conceived of his task of producing a marble statue by "liberating the figure from the marble that imprisons it." And remember that he, too, sometimes made mistakes and had to discard a half-finished statue. The same can happen to your tooth carving. To minimize this, as you cut away wax, repeatedly examine your carving from all sides; turn it around and around and compare it with your specimen from each view. Where it is too bulbous, the fault is easily correctable by further reductions. Where too much wax has been removed, you have one of three choices: add molten wax to the deficient region, make the entire carving proportionally smaller, or start with a new block of wax.



fIgur E 13-6. Maxillary central incisor wax carvings by first-year dental hygiene students as seen from the mesial (M), lingual (L), incisal (I), facial (F), and mesial–facial (M, F) aspects. The crown and half of the root were carved to specifc dimensions that were proportional to the tooth model they viewed during the carving. These excellent carvings were each done in less than 3 hours as a required skill test.

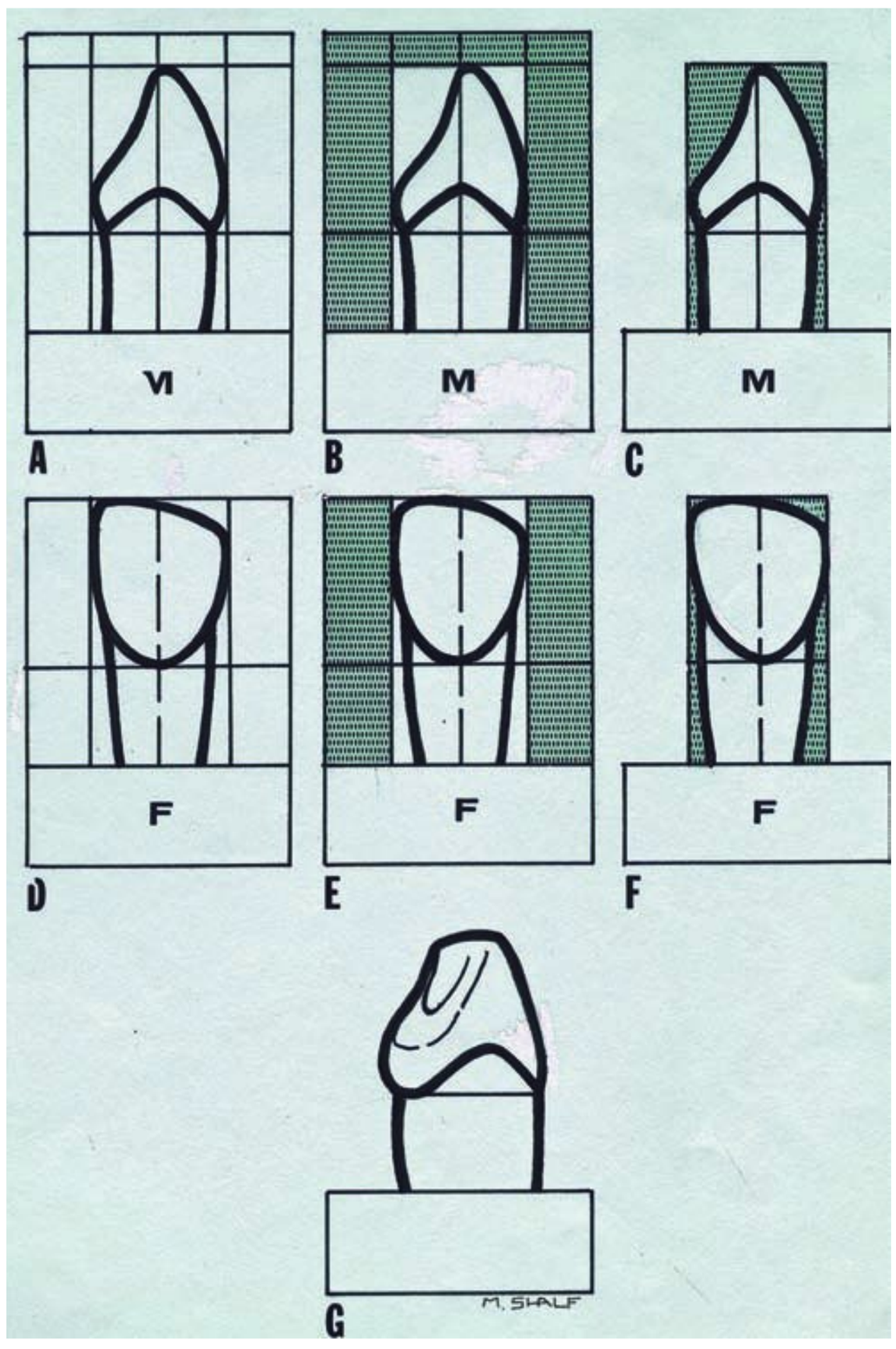

fIgur E 13-7. The sequential method described in this chapter for carving a tooth from a block of wax. The final product should look like those shown in Figure 13-6. The large letter M denotes the mesial aspect of the carving. Likewise, F indicates the facial side of the block.

C. ExaMplE: hOw TO CarVE a MaxIllary CENTral INCISOr frOM a BlOCk Of wax

Use the measurements you used for drawing. (Again, use the measurement of the buccal cusp on premolars for the crown length and of the mesiobuccal cusp and mesiobuccal or mesial root on molars for the root length.) This consistency of method prevents confusion. Allowance is made for the greater length of some lingual cusps, which are longer than the measured buccal cusp. Refer to Figure 13-7 as you follow the following guidelines:

Step 1: Shave the sides of the block flat and make all angles right angles.

Step 2: Measure 2 mm from one end of the block, and **draw** a line at this level, encircling the block (on all four sides). (This end of the block will be the incisal or occlusal end of the tooth, and the 2-mm allowance here is to provide for the extra length of the lingual cups on molars that are longer than the mesiobuccal cusp that established crown length. Although it is convenient to allow the 2 mm on all carvings, it is essential only for molars.)

Step 3: From the 2-mm line, measure the crown length and **draw** a second line around the block at this level. This line is the location of the cervical line on the facial, mesial, distal, and lingual sides of the tooth (Fig. 13-7A).

Step 4: From this cervical line, measure one-half of the length of the root and **draw** a third line around the block. (The end of the block beyond this line will be referred to now as the base.)

Step 5: On the base of the block, **carve**, on appropriate sides, F (facial), L (lingual), M (mesial), and D (distal). Be sure to put M and D in the proper relation to F and L so that you will carve a right or a left tooth, whichever you intend.

Step 6: Using a very sharp pencil, **draw** a shallow line lengthwise on the block in the center of the mesial surface. Do the same on the distal surface and be sure that these lines are exactly opposite.

Step 7: Add 0.5 mm to the faciolingual measurement of the crown. Divide this number by 2. Using this measurement, **draw** a line this distance on either side of the center line on the mesial and distal sides of the block (Fig. 13-7A). These two outer lines should be parallel to the center line and extend from the top of the block to the base. These two lines form a box whose dimension faciolingually is equal to the crown dimension plus 0.5 mm. The extra 0.5 mm is an allowance for safety in carving. Do not make trouble for yourself by allowing more than this extra 0.5 mm.

Step 8: On the mesial side of the block marked M, **draw**, within the box, an outline of the mesial side of the tooth as you drew it on the graph paper. Be careful to place the incisal edge and the labial and lingual crests of curvature accurately. Your carving will probably be no better than this drawing.

Step 9: **Draw** a similar outline on the distal side of the block. Be sure that on both sides, the drawings are oriented so that the facial surface of the tooth is toward the side of the block you have marked F (facial). (It is easy to make a mistake here.) These drawings of the crown may appear slightly fat due to the extra 0.5-mm-width allowance confining the crown size faciolingually.

Step 10: **Carve** away the shaded portions of wax in Figure 13-7B from the facial, lingual, and incisal sides of the block so that it is now shaped like Figure 13-7C. At this time, do not carve around the outline of the tooth, but rather carve up to the straight vertical lines that form the box in which the tooth picture is drawn.

Step 11: Check the distance between the two opposite carved surfaces carefully with your Boley gauge. Be sure they are perfectly flat and smooth. Be sure the thickness of the column of wax between these parallel surfaces exactly equals the given faciolingual crown dimension plus 0.5 mm.

Step 12: Now, **carve** away the shaded regions seen in Figure 13-7C around and down to the facial and lingual outlines of the tooth. Follow the drawing carefully, making the tooth shape the same all the way through the block. Keep the carving surface smooth; if it becomes chopped up, it will be impossible to smooth it without losing both the shape and the size of the carving.

Step 13: With a sharp pencil, very lightly **draw** center lines on the curved facial and lingual sides of the carving as in Figure 13-7D. Be sure they are exactly opposite.

Step 14: Add 0.5 mm to the mesiodistal crown measurement, and **draw** two lines one-half this distance on either side of the center line. This makes a box on the curved surface as wide as the greatest mesiodistal crown measurement plus 0.5 mm (Fig. 13-7D).

Step 15: **Redraw** a horizontal line the exact crown length distance from the incisal edge on the facial and lingual sides (since the original line was carved away). Then, **draw** the facial outline of the crown and half of the root on the curved facial side of the block (Fig. 13-7D).

Step 16: On the lingual surface of the block, **draw** an outline the same shape as the one on the facial surface except, of course, that it is a mirror image; the distal side of the tooth must be toward the same side of the block in each case. Check the crown length on the lingual surface too, so the crown will not be too long.

Step 17: **Carve** away all the wax outside the drawing box, removing all the shaded portions as shown in Figure 13-7E. On some first molars, their spreading roots may extend beyond the box lines, and these roots should be carved accordingly. Check your measurements again.

Step 18: Shape the tooth by carefully **carving** the mesial and distal contours by removing the shaded portions of Figure 13-7F so that it resembles your tooth specimen outline from the facial and lingual sides.

Step 19: Now, it is time to round off the corners, narrow the lingual surface, shape the cingulum (it is distal to the center line, and the mesial marginal ridge is longer than the distal), and **carve** out the lingual fossa. Be sure to look at all aspects of the tooth as you are finishing the carving. Include, of course, the incisal view (seen in Fig. 13-6) or the occlusal view. Four nice carvings of maxillary canines, made by dental hygiene students at the Ohio State University, are shown in Figure 13-8. Five aspects of another very fine carving by a dental student are seen in Figure 13-9.



fIgur E 13-8. Maxillary canine wax carvings viewed from the distal (D), lingual (L), incisal (I), and facial (F) aspects. First-year dental hygiene students carved these during a skill test (2 hours, 50 minutes time limit).

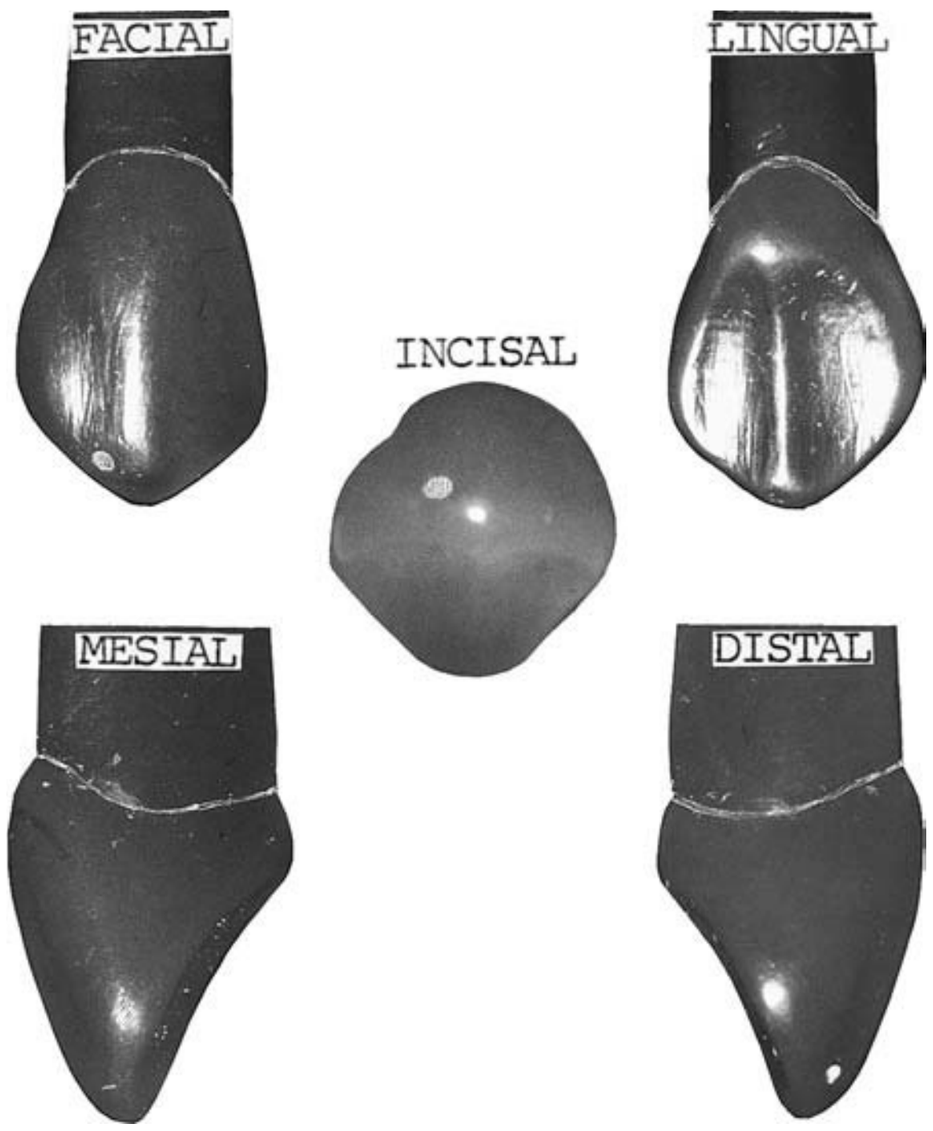

fIgur E 13-9. Maxillary right canine carving done by senior dental student Keith Schmidt: observe the nearly perfect contours from all aspects and that the root is not becoming narrower as it joins the crown (a very common carving error in attempting to refne the cervical line).

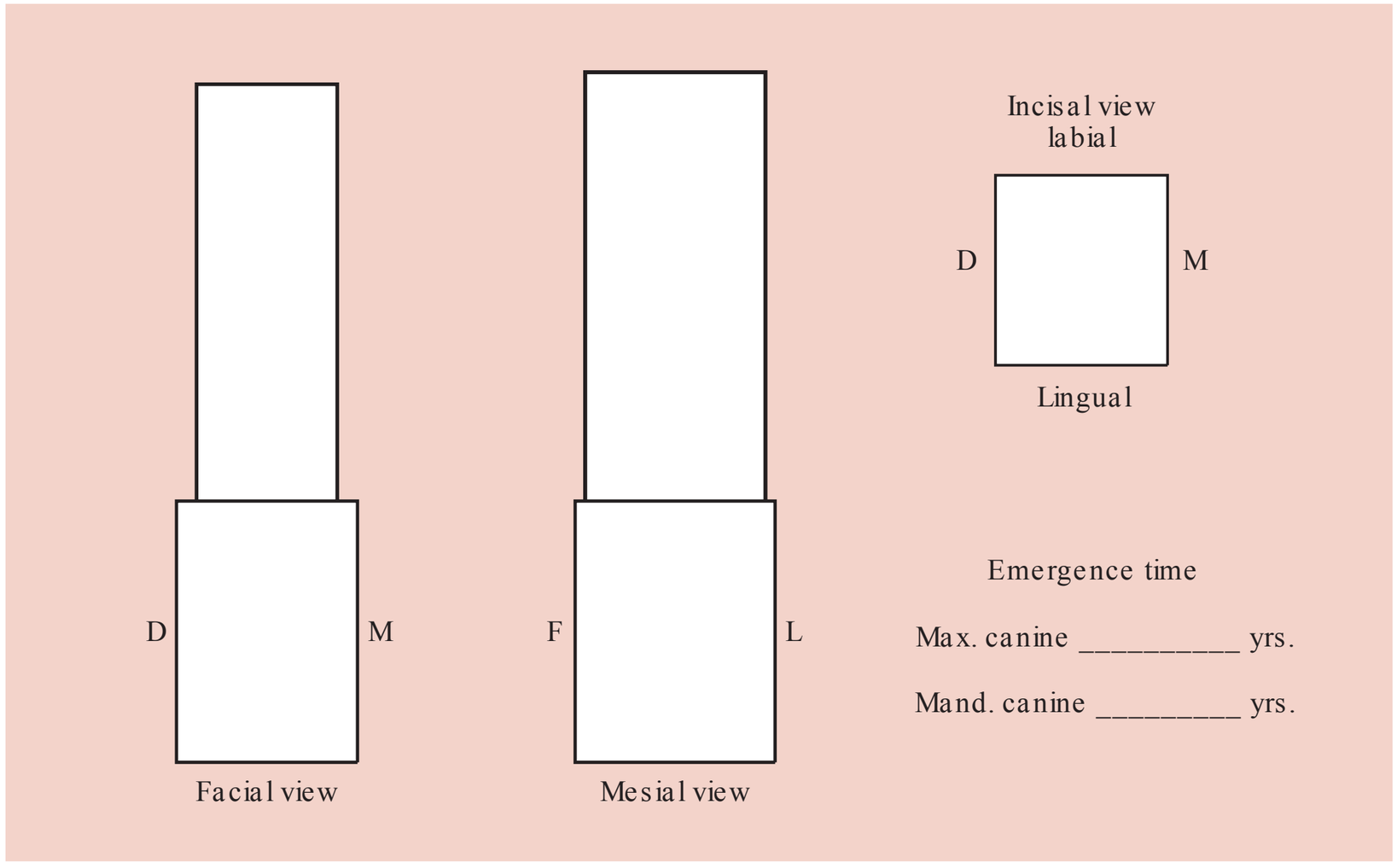

fIgur E 13-10. Outlines within which you may draw three views of a maxillary canine: the boxes are proportional to the natural tooth average measurements in Table 3-2. The widest portions of the crown (mesial and distal contacts) should touch the sides of the wider lower box. Only the widest part of the root should touch the sides of the narrower box above with the root apex touching the top of this box. On the incisal view, be sure to position the incisal ridge just labial to the faciolingual middle of this box. Drawing these three views will be helpful to you when you outline similar contours on a block of wax for carving a maxillary canine.

Step 20: **Carve** your initials on the bottom of the base of the block. Be an honest critic of your work, constantly looking for regions where the carving could be improved.

You can work toward becoming proficient in drawing teeth by sketching outlines (lightly at first) in the blank boxes that are proportionally the correct size for the view and tooth listed in Figures 13-10 and 13-11. You should have a tooth model or extracted tooth specimen to view as you make these sketches. An example of how to sketch teeth into the blank boxes of Figure 13-12 is shown in Figure 13-13.

D. a DVICE

Practice makes perfect, or at least you will see pronounced improvement in your later carvings. Therefore, do not discard your first ones, but keep them for future comparisons. The most difficult task is to begin for the very first time. We have found from many years of experience, however, that the inexperienced people who follow these or similar directions and proceed step-by-step often end up with some of the best carvings in the class. Do not be afraid to begin. When you become skillful at carving teeth, it may surprise you that it is possible to carve the contours of a tooth from memory, possibly aided only by several important dimensions. Average measurements from 4572 extracted teeth are given in Table 1-7. Should you draw or carve a tooth to these average dimensions, it might surprise you how normal it looks. You may find the General References helpful in perfecting your carving techniques.

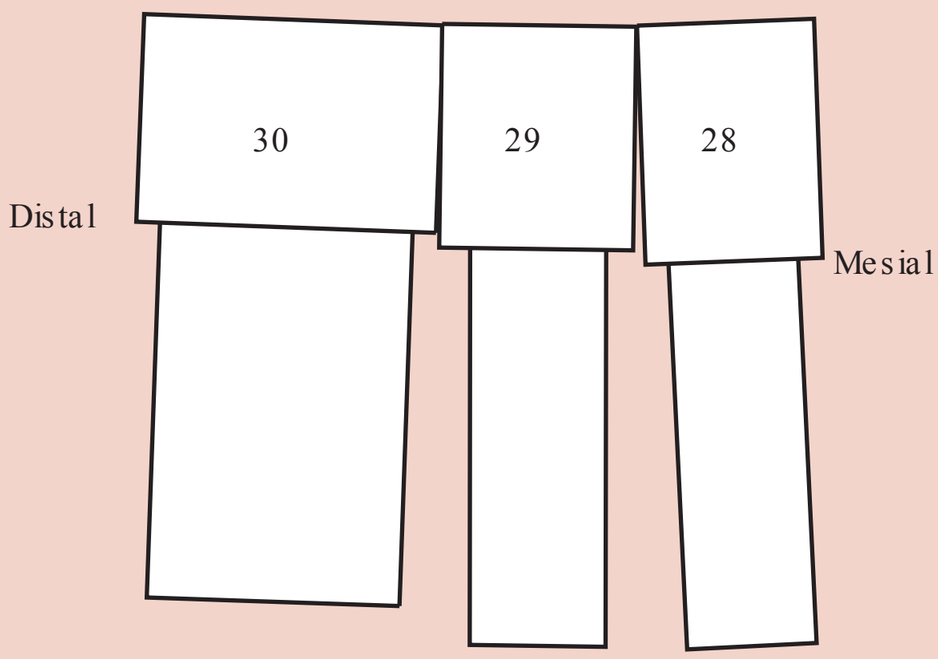

FIGURE 13-11. Proportionally outlined boxes for drawing the lower right first and second premolars and first molar in their usual relationship to one another: select three nice tooth specimens or tooth models and go to work.

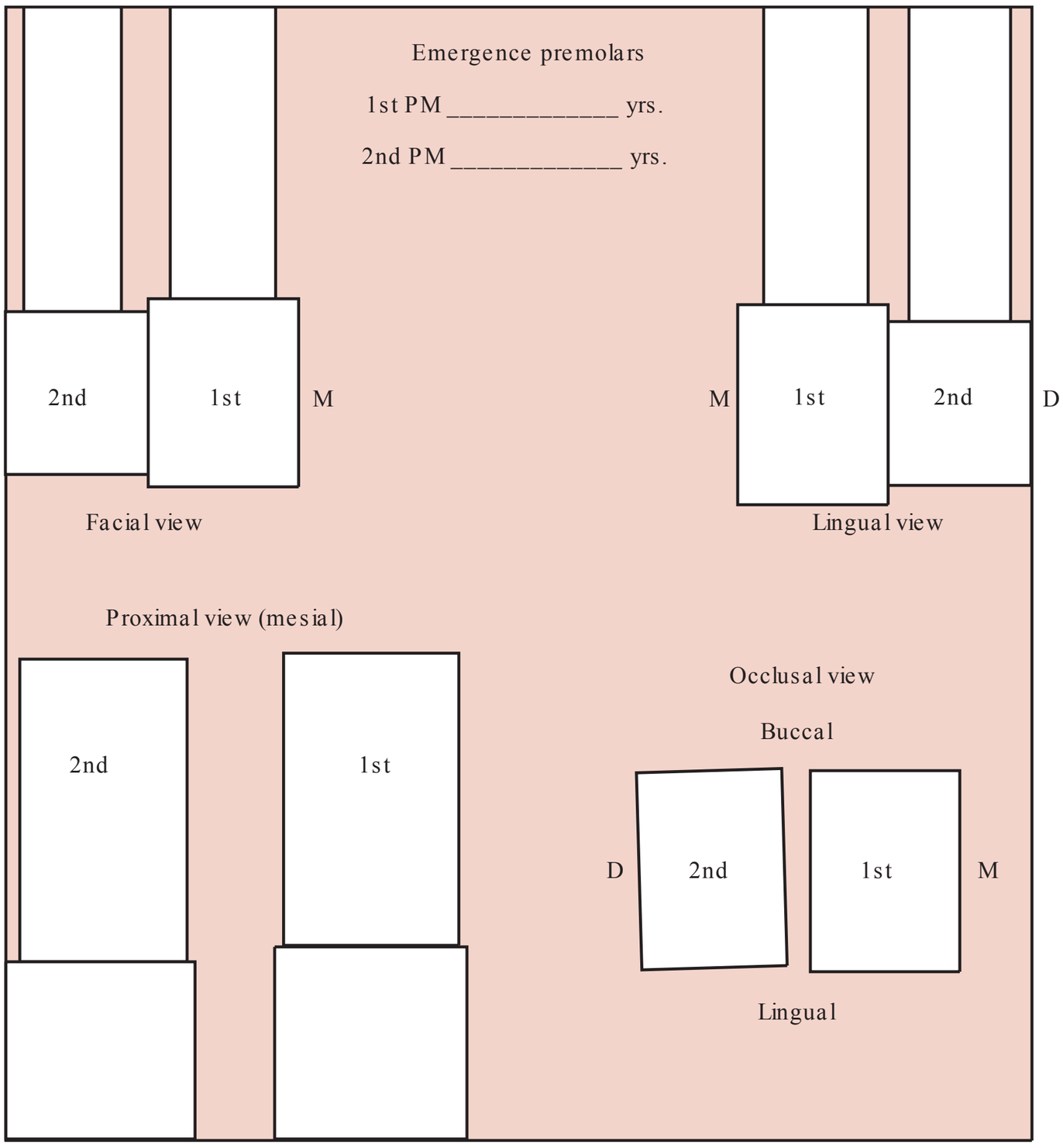

fIgur E 13-12. Outlined proportional boxes for drawing several views of the maxillary first and second premolars in their usual relationship to each other. Use the same guidelines given in the legend for Figure 13-10. A dental hygiene student's drawing of these two teeth within the outlined boxes is seen in Figure 13-13.

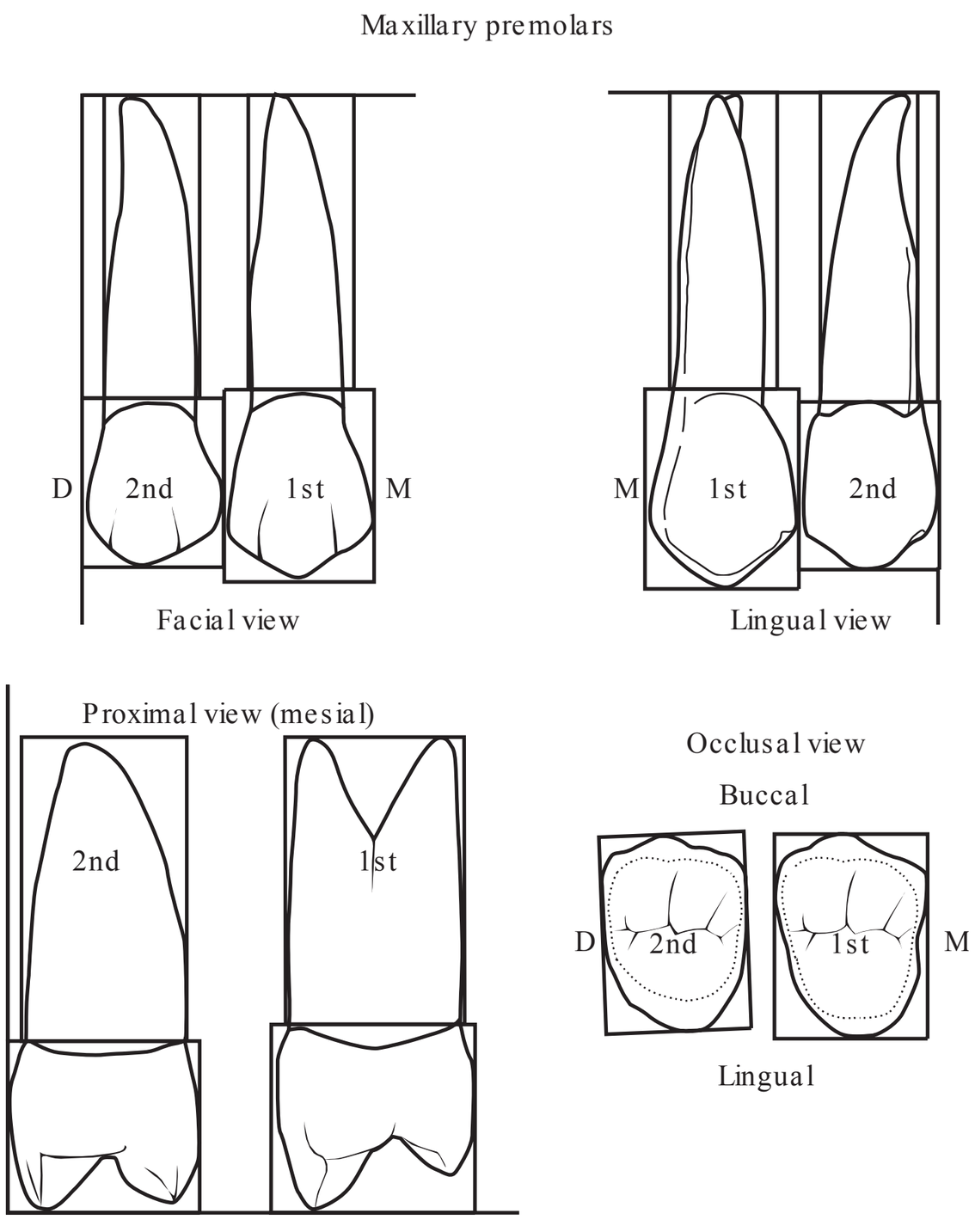

fIgur E 13-13. These drawings within the outlined boxes are examples to help you with your drawings in the blank boxes in Figure 13-12. Study these and perhaps you can make even better drawings. For example, in the lingual view, the maxillary first premolar's lingual cusp is too long. It is the correct length in the drawing of the mesial aspect.

GEn ERAl REFEREn CES

Ash MM Jr. Wheeler's atlas of tooth form. Philadelphia, PA: W.B. Saunders, 1984.

Beaudreau DE. Tooth form and contour. J Am Soc Prev Dent 1973;3:36–37.

Burch JG. Coronal tooth contours: didactic, clinical and laboratory. 3rd ed. Worthington, OH: James G. Burch, 1980.

Grundler H. The study of tooth shapes: a systematic procedure. Berlin, Germany: Buch- und Zeitschriften-Verlag "Die Quintessenz", 1976.

Linek HA. Tooth carving manual. Pasadena, CA: Wood and Jones Printers, 1948.

PART

3

Anatomic Structures of the Oral Cavity

14 Structures That Form the Foundation for Tooth Function

Topics covered within the six sections of this chapter include the following:

I. Bones of the Human Skull (with Emphasis on the Sphenoid, Temporal, Maxilla, and Mandible Bones)
   A. Bones that Cover the Superior Portion of the Braincase
   B. Bones that Form the Floor of the Braincase
   C. Large Bones of the Face and Temporomandibular Joint (TMJ)
   D. Small Bones of the Face
   E. Hyoid Bone

II. The Temporomandibular Joint (TMJ)
   A. Anatomy of the Temporomandibular Joint
   B. Ligaments that Support the Joint and Limit Joint Movement
   C. Development of the Temporomandibular Joint
   D. Advanced Topics: Dimensions Related to the TMJ

III. Muscles of the Mouth
   A. Muscles Involved in Mastication (Chewing)
   B. Other Muscles Affecting Mandibular Movement
   C. Other Factors Affecting Tooth Position or Movement
   D. Summary of Muscles that Move and Control the Mandible
   E. Advanced Topics

IV. Nerves of the Oral Cavity
   A. Trigeminal Nerve (Fifth CN)
   B. Facial Nerve (Seventh CN)
   C. Glossopharyngeal Nerve (Ninth CN)
   D. Hypoglossal Nerve (12th CN)
   E. Summary of Nerve Supply to the Tongue, Salivary Glands, Facial Skin, and Facial Muscles

V. Vessels Associated with the Oral Cavity (Arteries, Veins, and Lymph Vessels)
   A. Arteries
   B. Veins
   C. Lymph Vessels

VI. Structures Visible on a Panoramic Radiograph

This chapter introduces the reader to the structures that form the foundation for the functions of the oral cavity. Emphasis is placed on structures that relate to the functioning of the jaws and teeth. The chapter begins with the gross anatomy of the bones of the skull including the identification of important foramen where nerves pass from the brain and blood vessels pass from the heart to the oral structures of the mouth, the location for attachments of the muscles and tendons that support and move the mandible, and the anatomy of the temporomandibular joint (TMJ). Next, the attachments and functions of the major chewing muscles are described, followed by a description of the passageway and function of the nerves, blood supply, and lymph vessels that supply the face and mouth.

SECTION I BONES Of Th E h u ma N Sku l l (wITh Emph a SIS ON Th E Sph ENOId, TEmpOr a l, ma xIl l a, a Nd ma Nd IBl E BONES)

Objectives Of this sectiOn

This section is designed to prepare the learner to perform the following:

- Describe and identify each bone seen on an intact human skull.
- Describe and identify each bony structure highlighted in bold in this chapter. (Emphasis is placed on structures of the mandible, maxillae, temporal, and sphenoid bones.)
- Describe and identify the location of the attachment of chewing muscles and ligaments that are attached to the bones of the skull.
- Describe and identify the foramen of the nerves and arteries that supply the teeth and oral cavity.

T ere are 206 distinct bones in our skeleton, 28 of which are in the skull if we count the malleus, stapes, and incus bones of each ear. To obtain a clear understanding of the bones of the skull and their relationship to one another and to the teeth, it is best to have a skull or skull model at hand to examine while reading this chapter. If you touch and trace each bone with your fingers as you read, you are not likely to forget its characteristics. Also, as you study this section, you should relate the location of each bony structure on the skull to its location on your own head, that is, where it is located under the skin of the face or under the mucosa of the mouth. T is is important in order to fully appreciate where muscles attach and how they can move the lower jaw (mandible) in all directions and to figure out where to apply local anesthetic along the path of the nerves to the teeth and oral cavity, as described in more detail in Chapter 15.

When reading the description of each bone, there are many descriptive terms that are used to describe the bumps, depressions, holes, and relative location of important landmarks. Many terms have similar definitions, so they are defined here in groups to facilitate learning. Since anatomy terms are often similar to common familiar words, the new terms are compared to familiar words whenever possible.

BUMPS—TERMS USED TO DESCRIBE CONVEXITIES ON BONES AND/OR TEETH

Crest: a projecting ridge along a bone
Eminence: a prominence or elevation of bone
Process: a projection or outgrowth from a bone
Protuberance [pro TU ber ahns]: a prominence of bone
Ridge: linear, narrow, elevated portion of bone or tooth
Tubercle [TOO ber k'l]: a small rounded projection on a bone or tooth

DEPRESSIONS—TERMS USED TO DESCRIBE CONCAVITIES IN BONES AND/OR TEETH

Alveolus [al VEE o lus] (plural: alveoli [al VEE o lie]): small hollow space or socket where the tooth root fits within the jaw bones
Cavity: a hollow place within the body of bone (or within a tooth)
Fissure [FISH er]: a cleft or groove (crack) between parts
Fossa [FOS ah] (plural: fossae [FOS ee]): a small hollow or depressed area
Fovea [FO ve ah]: small pit or depression
Groove: linear depression or furrow
Sinus: hollow, air-filled cavity or space within skull bones, or a channel for venous blood

OPENINGS—TERMS USED TO DESCRIBE HOLES IN BONES AND/OR TEETH

Aperture: an opening; compare a camera lens aperture
Foramen [fo RAY men] (plural: foramina [fo RAM i nah]): a small hole through bone or tooth for passage of nerves and vessels
Foramen ovale [o VAL ee]: a specific oval or egg-shaped foramen
Foramen rotundum: a specific round foramen; recall the Capitol's rotundum or dome is round when viewed from above
Meatus [me A tus]: a natural passage or opening in the body

TERMS USED TO DESCRIBE RELATIVE LOCATION—

Figure 14-1 will be helpful in understanding terms with an asterisk (*).

Anterior*: toward the front of the body
Buccal [BUCK al]: related to or near the cheek; the buccal nerve innervates the cheek; the buccinator muscle is within the cheek; the buccal surface of a tooth is the side toward the cheek.
Cervix: of the neck or neck-like; compare cervical vertebrae in the neck
External: toward the outside of the body; seen from the outside
Facial*: toward the face; seen when viewing the face side
Inferior* or the prefix **infra**: located below or beneath; lower than

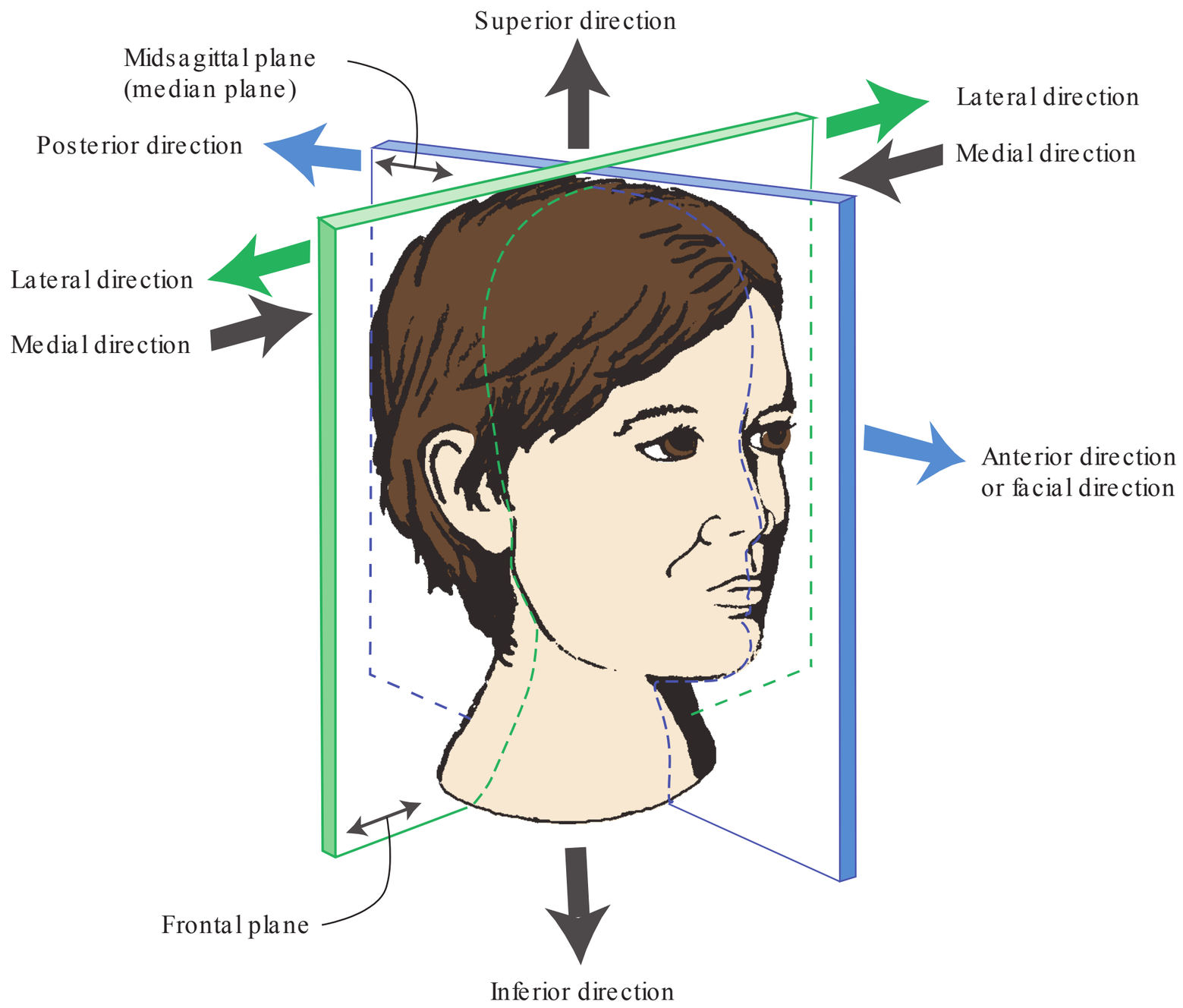

fIGu r E 14-1. Planes of the head and directions used to identify relative location of structures or surfaces of the head.

Lateral*: pertaining to, or situated at, the side
Medial*: the surface toward, or closest to, the midline (median) plane of the body; do not confuse medial with mesial.
Median plane*: a longitudinal plane that divides the body into relatively equal right and left halves
Midsagittal plane* [mid SAJ i t'l]: same as median plane
Posterior*: toward the rear of the mouth or body
Retro (prefix): back or behind
Sub (prefix): under or beneath; compare to infra
Superficial: closer to the surface
Superior* or the prefix **supra**: located above or over; higher or upper

GENERAL TERMS RELATED TO BONES

Acoustic [ah KOOS tik]: referring to sounds or hearing; near the ear
Cervical [SER vi kal]: related to the neck; like cervical vertebrae
Condyle [KON dile]: an articular prominence of a bone resembling a knuckle
Coronoid: where the king's coronation crown fits or the shape of a crown (compare coronation); for example, the coronoid process of the mandible is shaped like the point of a coronation crown; or a coronoid suture is where the crown fits.
Dura: hard, not soft (compare durable)
Glenoid [GLE noyd]: socket-like
Glosso: a prefix referring to the tongue
Labial [LAY bee al]: related to the lips; toward the lips
Lacrimal [LAK ri mal] (also spelled lachrymal): referring to the tears (compare lacrimosa)
Lamina: a thin layer (compare laminated wood)
Lingula [LING gyoo la]: tongue-shaped structure (compare to the word "lingual")
Malar [MAY lar]: referring to the cheek or cheek bone (not to be confused with molar)
Meatus [mee A tus]: a pathway or opening
Palpebral [PAL pe bral]: referring to the eyelid
Piriform [PEER i form]: pear shaped
Septum: a partition (compare separate)
Suture [SOO chur] line: the line of union of adjoining bones of the skull
Symphysis [SIM fi sis]: fibrocartilaginous joint or connection where opposed bony surfaces are joined (a suture line may not be evident)
Trochlea [TROK lee ah]: pulley shaped

The skull bones can be divided into two broad categories: the bones of the **neurocranium** [NOOR o CRAY ne um] surrounding the brain and the **facial bones** that make up the face and mouth and are involved in respiration and eating. The **neurocranium** is the portion of the skull that supports, encloses, and protects the brain. The eight bones of the neurocranium are four single bones (sphenoid, occipital, ethmoid, and frontal) and two paired bones (one on each side): temporal and parietal.

a. BONES THAT COVER THE SUPERIOR PORTION OF THE BRAINCASE

Study Figure 14-2 while reading about the frontal and temporal bones. The **frontal bone** is a single, large midline bone that forms the "forehead" and eyebrow region. It contains two **frontal sinuses** just above the eyes (seen later in Fig. 14-13). Two **parietal bones** are large, paired bones that protect the brain superiorly, laterally, and posteriorly. A small portion of these bones make up a part of the large and shallow **temporal fossa** region (outlined in Fig. 14-2), which serves as part of the attachment for the superior end of one of the major muscles of chewing called the temporalis muscle.

Suture lines are lines of fibrous connective tissue that join two bones of the skull immovably together as seen in Figure 14-2. The **coronal suture** is located between the frontal and two parietal bones. The **sagittal suture** (best seen on the superior surface of the skull) joins the right and left parietal bones along the midsagittal plane of the skull.

B. BONES THAT FORM THE FLOOR OF THE BRAINCASE

The occipital bone, sphenoid bone, ethmoid bone, and two temporal bones support the base of the brain. They all have holes (foramen) for the passage of nerves to the face and mouth. However, the **temporal bones** play a most important part in the functioning of the jaw, so they will be discussed separately when discussing the TMJ.

The floor of the braincase can be divided into three large depressions or fossae, anterior, middle, and posterior (seen later in Fig. 14-4B), which house various portions of the brain. The shallowest **anterior cranial fossa** extends anteriorly from the lesser wing of the sphenoid bone (and houses the frontal lobes of the brain). The deeper **middle cranial fossa** extends from the lesser wing of the sphenoid bone posteriorly to the petrous portion of the temporal bone (and houses the temporal lobes of the brain and the pituitary gland). The largest and deepest **posterior cranial fossa** extends posteriorly from the petrous portion of the temporal bone (and houses the cerebellum).

1. Occipital Bone

The **occipital bone** provides the articulating surface between the skull and vertebral column at the **occipital condyles** [ahk SIP eh tal KON diles] (seen on the inferior surface in Fig. 14-3). The large **foramen magnum** serves as the passageway for the spinal cord that connects the peripheral nervous system with the brain. The **hypoglossal canals** are located on the right and left lateral walls of the foramen magnum. These canals are the passageways of the hypoglossal

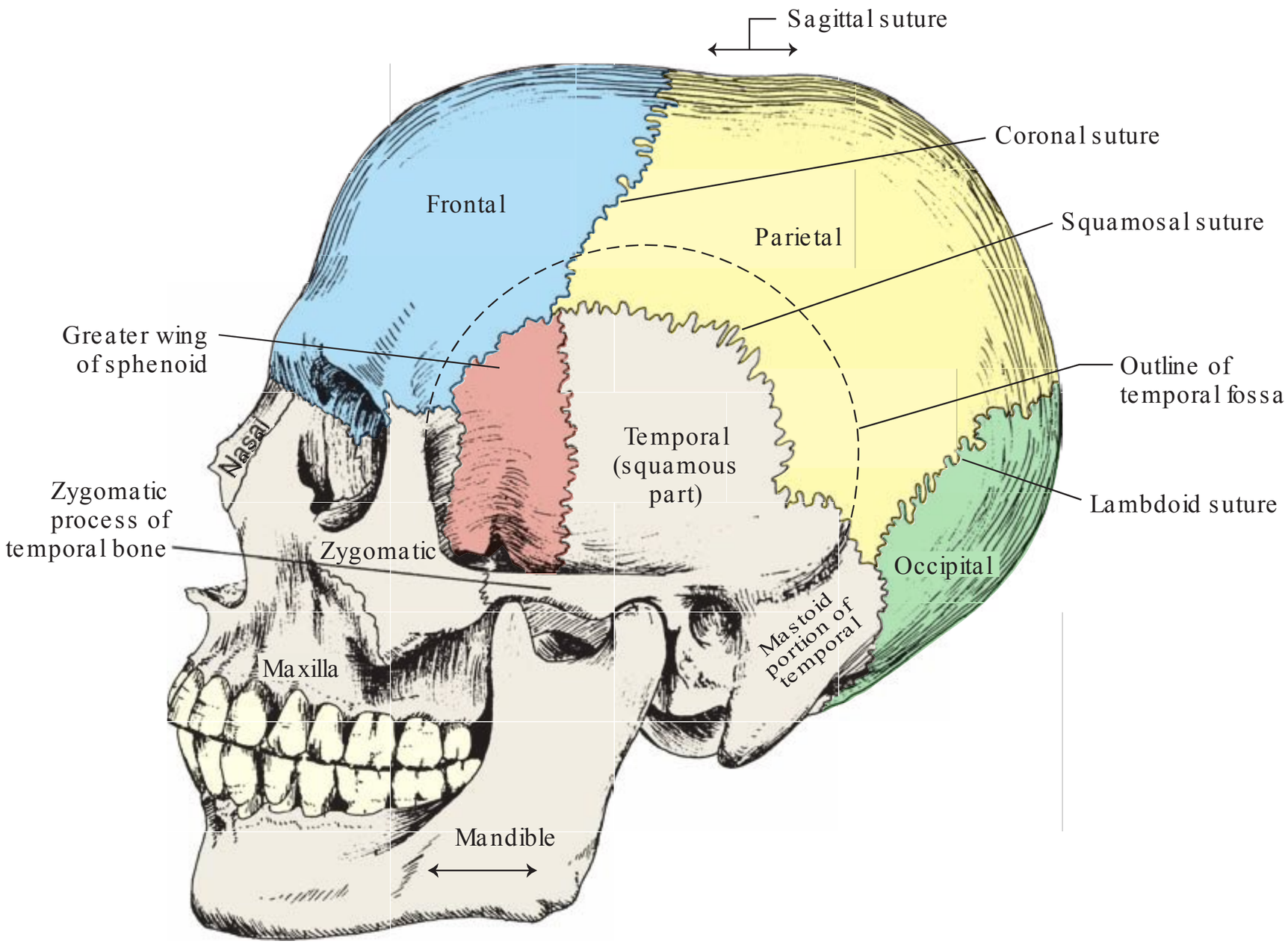

FIGURE 14-2. **Human skull, left side.** The following are large bones of the neurocranium: the single **frontal** bone (blue) forms the anterior superior portion, the parietal bones (yellow) form the lateral and superior surfaces, the occipital bone (light green) forms the posterior inferior portion, and the greater wing of the sphenoid bone (light red) forms part of the temporal fossa. Note the outline of the shallow temporal fossa, which includes portions of temporal, parietal, sphenoid, and frontal bones.

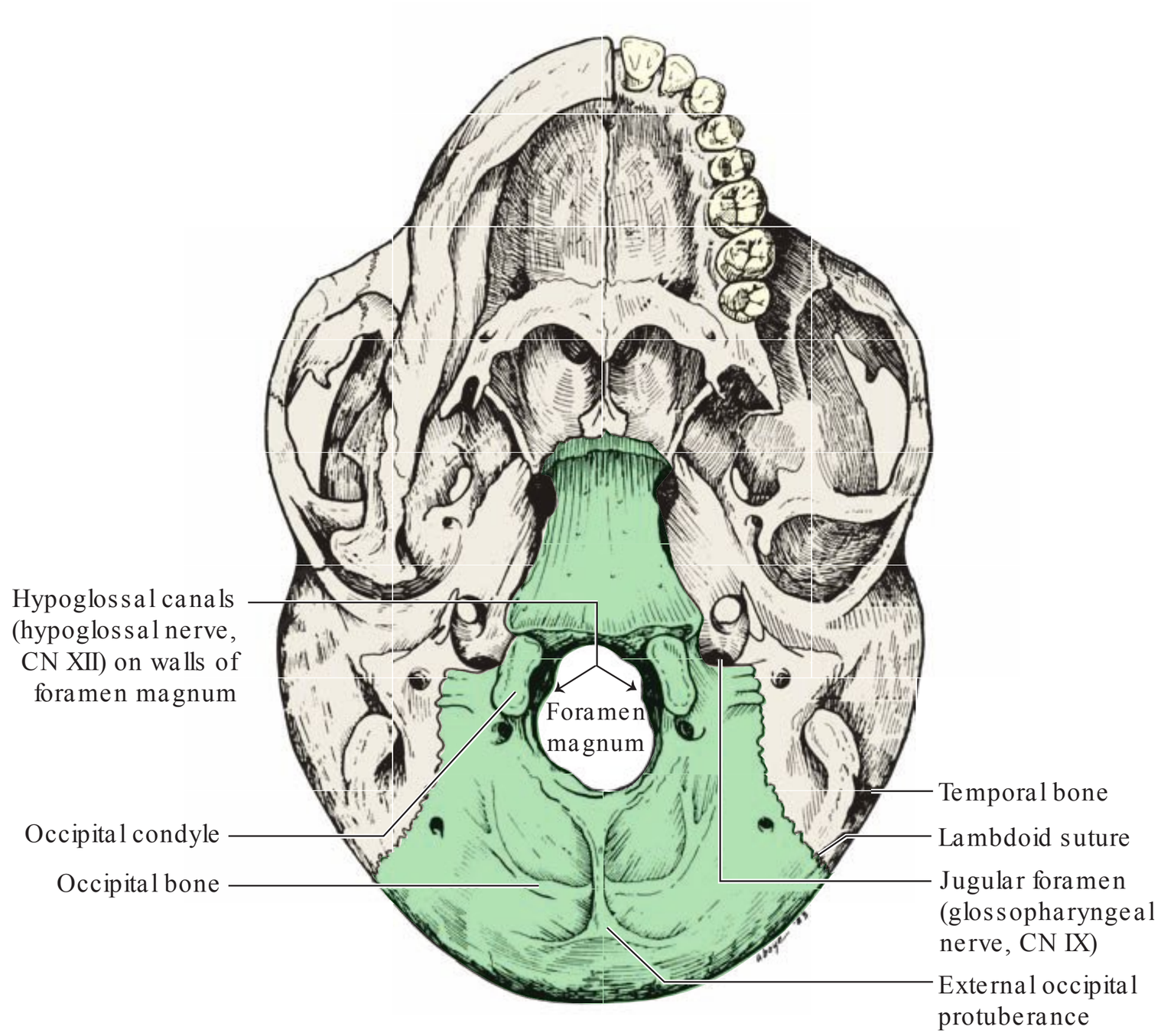

fIGu r E 14-3. Human skull: inferior surface with half of the mandible removed on the ri**g**ht side of the drawing. The occipital bone is highlighted light green. Note the location of the h**y**po**g**lossal canals (in the lateral walls of the foramen magnum) and the j**ugu**lar **f**oramen just adjacent to the occipital bone.

nerves (CN XII). Lateral to the foramen magnum (between the occipital and temporal bones) are the large **jugular** [JUG you lar] **foramen** (Fig. 14-3), the passageway of blood draining from the brain to the internal jugular vein, and the passageway of the glossopharyngeal nerve (CN IX).

T e **lambdoid** [LAM doid] **suture** joins the occipital bone with the parietal bones (Fig. 14-2). Its shape from the posterior view resembles an upside-down "V" and can be compared to the shape of the Greek letter lambda (λ).

2. Ethmoid Bone

T e **ethmoid bone** is a single, hollow bone that is located on the midline inferior to the anterior part of the brain and contains **ethmoidal sinuses** (also called **air sacs**) located between the eye orbits (seen later in Fig. 14-13). T e superior aspect of this bone is visible within the braincase as the sieve-like **cribriform** [KRIB ri form] **plate** (Fig. 14-4A) surrounding the triangular projection called the **crista galli** [KRIS ta GAL li, meaning rooster comb]. T e cribriform plate is full of holes providing the passage from the brain into the nasal cavity for the fibers of CN I, the olfactory nerve (the nerve for smell).

Inferior to the cribriform plate, the hollow ethmoid bone balloons out around its ethmoid sinuses to form part of the medial aspect of each eye orbit (the orbital lamina of the ethmoid bone is visible in Fig. 14-5 and later in Fig. 14-7). It also has scrolled processes extending into the nasal cavity similar in appearance to the inferior nasal concha described later in this section. Finally, a vertical midline plate of the ethmoid bone extends downward into the nasal cavity (along with the separate single **vomer bone**) to form the **nasal septum** (seen later in Fig. 14-7), which separates the right and left nasal cavities. T e scrolled portions and midline plate of the ethmoid bone are visible through the piriform opening (anterior opening of the nasal passageways).

3. Sphenoid Bone

T e **sphenoid** [SFE noid] **bone** is a single, irregularly shaped, midline bone that cradles the base of the brain (and forms the posterior part of the orbit or eye socket as seen later in Fig. 14-7). T e complex shape of the sphenoid bone can only be appreciated by looking at it from several different views (seen from above in Fig. 14-4A, from below in Fig. 14-6, and seen later in the lateral surface of the orbit in Fig. 14-7). T e sphenoid bone is important to dental professionals because it has processes that serve as part of the attachment for three of the four pairs of major chewing muscles. T e sphenoid bone also has foramina (holes)

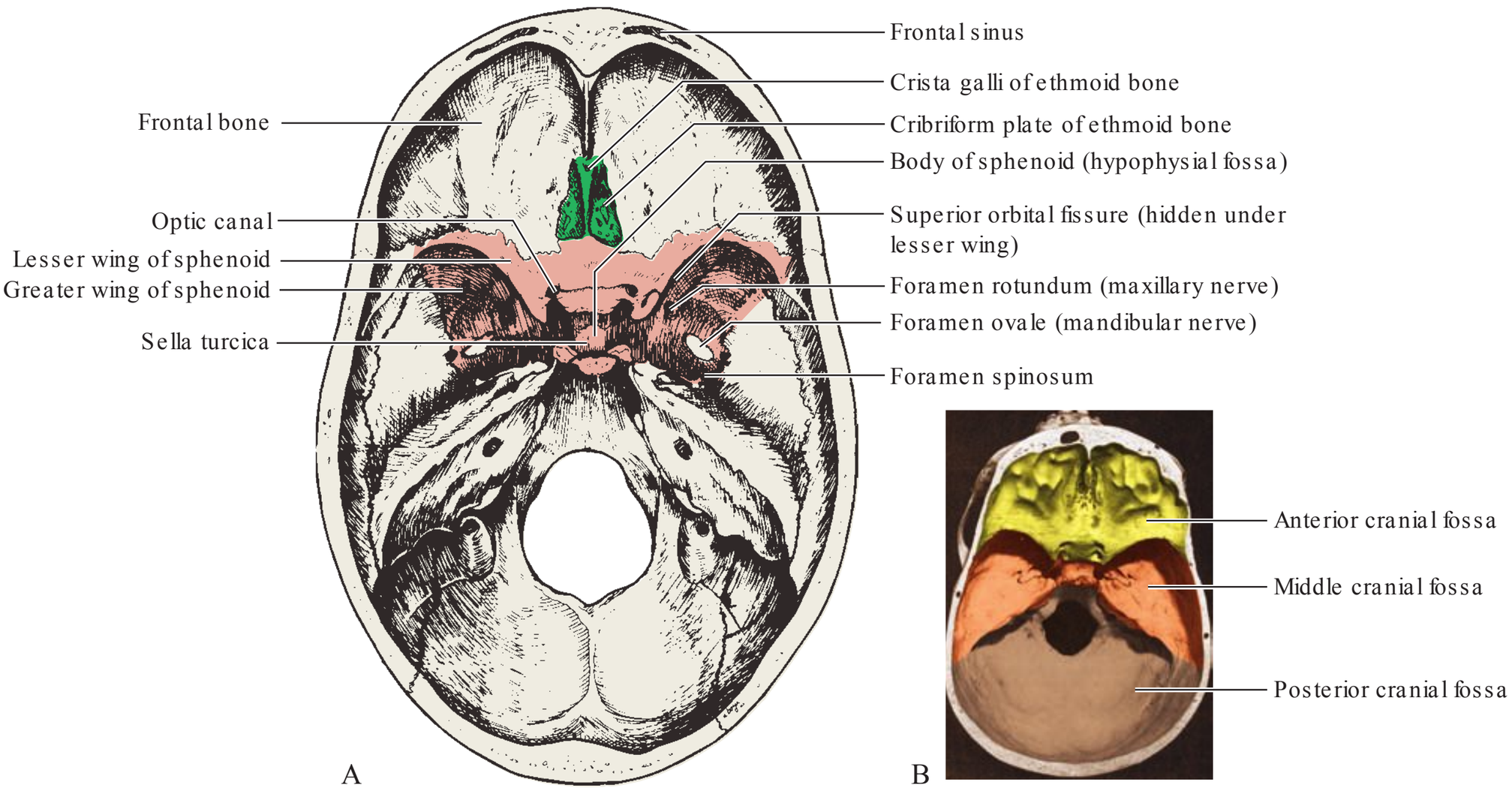

fIGur E 14-4. Human skull: bones lining the inside of the neurocranium, superior view. A. The sphenoid bone is shaded light red in this figure. Also, notice the portion of the midline ethmoid bone (green) that is visible in the anterior braincase. B. The foor of the neurocranium is divided into three large fossae: anterior cranial **f**ossa, middle cranial **f**ossa, and posterior cranial **f**ossa.

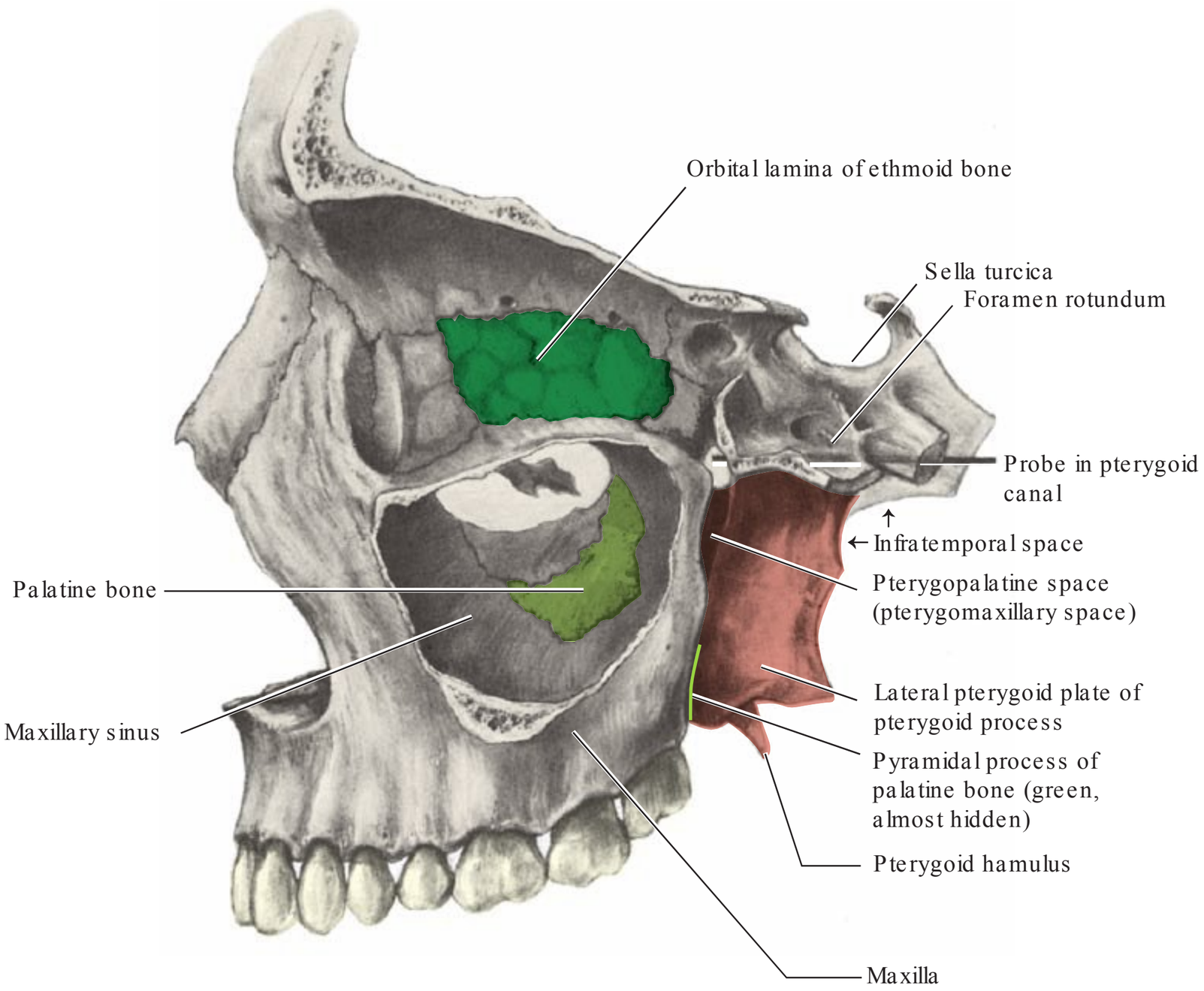

fIGur E 14-5. Part of human skull, lateral view, with the lateral wall of the left maxilla removed, exposing the large ma**x**illar**y** sin**u**s. Note the lateral surface of the lateral pter**yg**oid plate of the sphenoid bone (shaded light red) just behind the maxilla. The pter**yg**oid ham**u**l**u**s of the medial pterygoid plate is also visible and is just posterior (and slightly medial) to the third molars. Also, note the part of the midline ethmoid bone (green) that balloons out between the right and left eye orbits to form part of their medial walls and the part of the palatine bone (light green) that extends superiorly from the palate to form part of the maxillary sinus (and part of the pterygopalatine space). (Reproduced from Clemente CD, ed. Gray's anatomy of the human body. 30th ed. Philadelphia, PA: Lea & Febiger, 1985:166, with permission.)

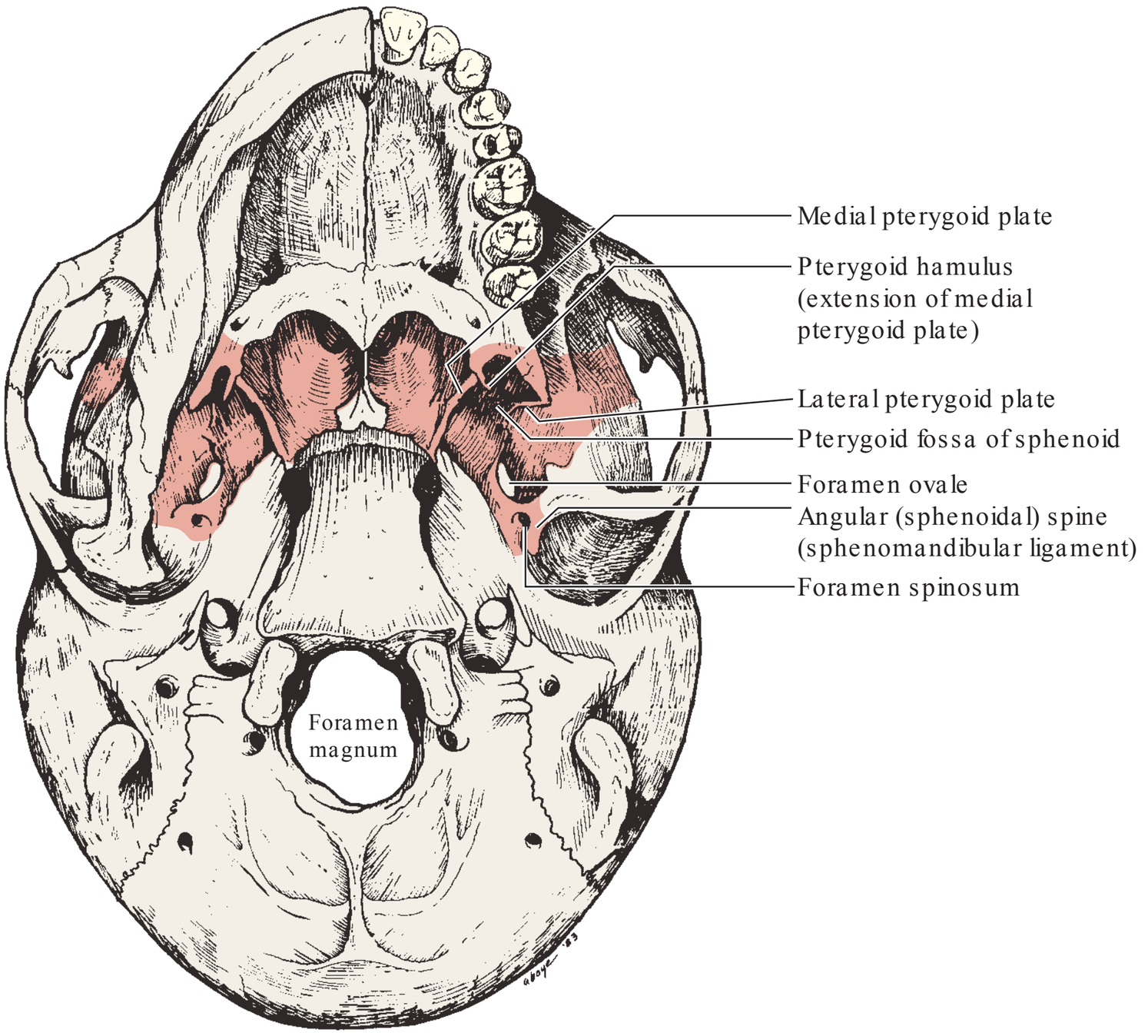

fIGur E 14-6. **Hu**man sk**u**ll: in**f**erior s**ur**face with half of the mandible removed on the ri**g**ht side of the drawing to permit easier viewing of the sphenoid bone, which is shaded light red. Notice the relative location of the medial and lateral pter**yg**oid plates and **f**ossae just posterior to the bones of the hard palate.

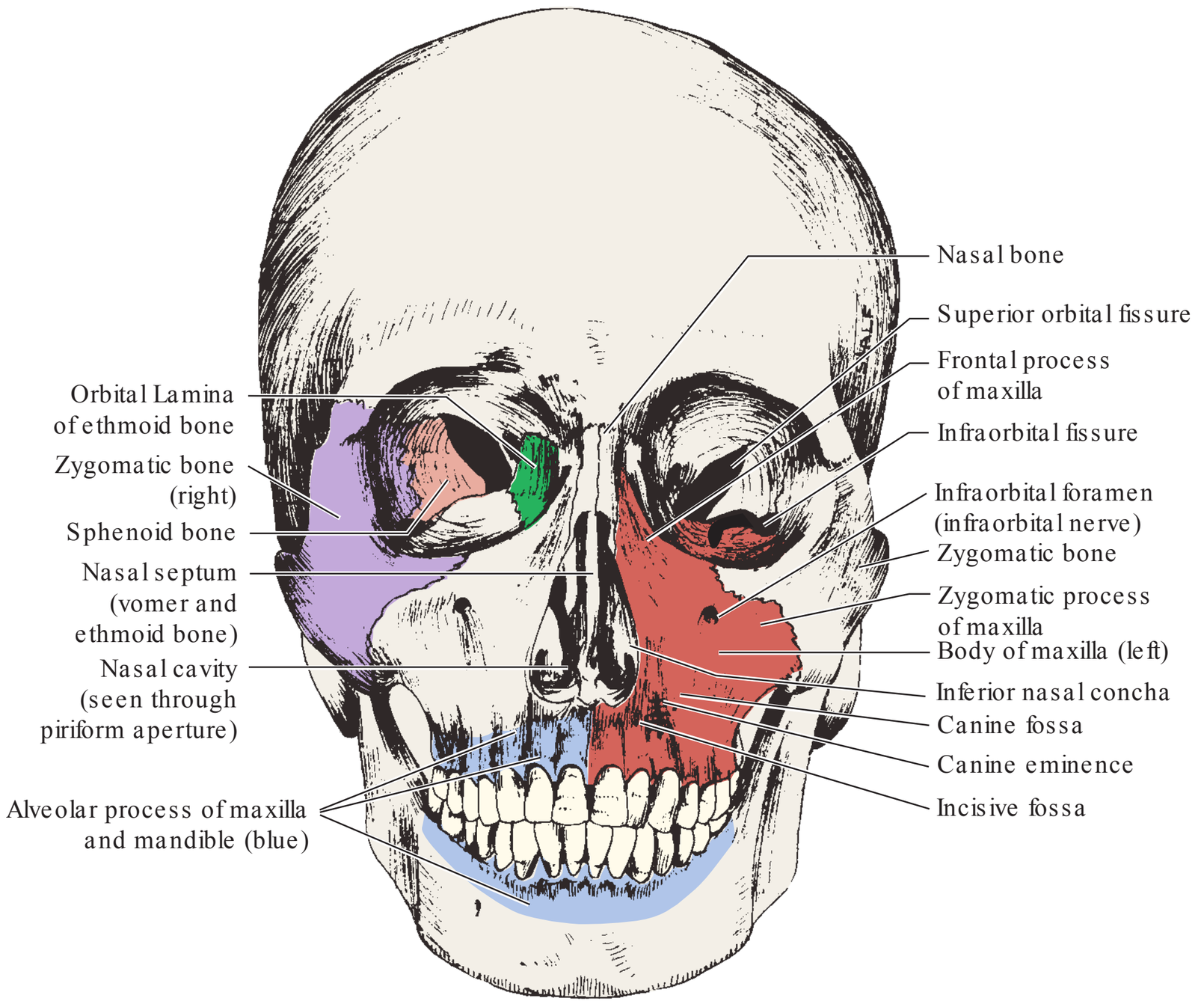

fIGur E 14-7. **Hu**man sk**u**ll, **f**rontal aspect. The left maxilla is shaded red (on the ri**g**ht side of the drawing), and the right z**yg**omatic bone is shaded purple (on the le**f**t side of the drawing). Also, the facial surfaces of the arch-shaped alveolar process o**f** the le**f**t ma**x**illa (process that surrounds the tooth roots) and the alveolar process o**f** the entire mandible are shaded blue. Also, forming part of the right eye orbit, the orbital lamina of the ethmoid bone is shaded green on the medial surface, and part of the sphenoid bone is shaded light red in the right eye orbit (le**f**t side of drawing).

that are the passageway for branches of the important fifth CN (trigeminal nerve) that supply all teeth and surrounding structures.

The hollow, midline **body** of the sphenoid bone contains **sphenoidal sinuses** located posterior to the ethmoidal sinuses (seen later in Fig. 14-13). It has a depression on the superior surface called the **hypophyseal fossa** or **sella turcica** [SELL a TER si ka] (meaning Turkish chair or saddle) that cradles the pituitary gland (Fig. 14-4A). This gland secretes hormones, which regulate many body functions. There are two pairs of processes or wings (greater and lesser wings) that project off of the body laterally and superiorly. The **greater wings** are visible internally in Figure 14-4A but are best viewed externally in Figure 14-2. If you put your thumb on the external surface of the greater wing, you can place your forefinger opposite to your thumb on the inner surface to confirm the location of the greater wing on the inner surface of the braincase. These wings extend superiorly from the body, posterior to the upper jawbones (maxillae), and medial to the lower jawbone and cheekbones. The external surface of the greater wing (along with part of the temporal, frontal, and parietal bones) forms part of each **temporal fossa** (outlined in Fig. 14-2), where a muscle of mastication, the temporalis muscle, attaches to the neurocranium. The **lesser wings** are located superior to a fissure in the posterior surface of the eye socket (seen in the braincase in Fig. 14-4A and on the posterior surface of the eye sockets seen in Fig. 14-7). The fissure between the greater wing and the lesser wing is called the **superior orbital ȧssure**, which is the passageway of the ophthalmic nerve (one part of the trigeminal nerve). Look at this fissure on the inside of the braincase, and then, look at the front of the skull to see this fissure on the posterior superior surface of the eye socket.

The sphenoid bone also has two important processes that project inferiorly from the base of the skull adjacent to the posterior surface of the upper jawbones (maxillae). These are called **pterygoid** [TER i goid] **processes** and are best seen in the lateral view of Figure 14-5. (Hint: To remember the name of this process, note that each has a scalloped border somewhat resembling the wings of a pterodactyl flying dinosaur.) When each pterygoid process is viewed from below (or posteriorly), you can see that it is made up of two thin plates of bone (a **lateral pterygoid plate** or lamina and a **medial pterygoid plate** or lamina) that surround a concavity about the size of your little finger called the **pterygoid fossa** (Fig. 14-6). This fossa is where one end of another major muscle of mastication, the medial pterygoid muscle, attaches. The lateral surface of the lateral pterygoid plate (visible in Fig. 14-5) is where one end of yet another muscle of mastication (the lateral pterygoid muscle) attaches. The medial plate has a hook-like projection just posterior and medial to the third molars and behind the palate, called the **pterygoid hamulus** (Figs. 14-5 and 14-6). The space just lateral to and posterior to the lateral plate and inferior to the temporal bone is called the **infratemporal space** (Fig. 14-5), and it is filled with muscles, ligaments, vessels, and nerves, which will be described later. Note that all of the terms presented here that contain "ptery" relate to the pterygoid process of the sphenoid bone, and the closest you can come to touching this process on your own head is by placing a clean finger in the mouth and sliding it posterior, superior, and medial to the maxillary third molars. Confirm this by looking at a skull.

Two pairs of foramina in the sphenoid bone are important to dental professionals: the foramen rotundum and the foramen ovale. The oval, more posterior **foramen ovale** is the passage of the important mandibular nerve (part of the trigeminal nerve) that passes from the brain to the mandibular teeth and jaw and the muscles of mastication. The foramen ovale is best seen internally in Figure 14-4 and externally in Figure 14-6. On a skull, if you carefully pass a pipe cleaner through this foramen, you will see that it drops inferiorly through the **infratemporal space** (beneath part of the temporal bone) toward the lower jaw (mandible). The foramen ovale can be easily identified by its proximity to the much smaller **foramen spinosum** [spy NO sum] that is located just posterior to it. Just posterior to the foramen spinosum on the inferior surface is a thorn-shaped bony prominence called the **sphenoidal** [SFE noid al] **spine** (or **angular spine**) (Fig. 14-6). This spine is the superior attachment of the sphenomandibular ligament, which extends inferiorly from the spine toward the medial surface of the lower jaw (mandible).

The **foramen rotundum** [ro TUN dum] is visible only internally in Figure 14-4 and is round, anterior, and just slightly medial to the foramen ovale. It is the opening for the passage of another important branch of the trigeminal nerve called the maxillary nerve that supplies all maxillary teeth. If you are able to carefully pass a pipe cleaner from the braincase through this foramen, it will be somewhat hidden in a space between the pterygoid process and upper jawbone (maxilla). This is space between the pterygoid process and the posterior wall of the maxilla (which is covered in part by vertical projections of the palatine bones) is known as the **pterygopalatine** [TER i go PAL eh tine] **space** (also called the **pterygomaxillary space**) labeled in Figure 14-5. The maxillary nerve that exits the skull through the foramen rotundum proceeds through this pterygopalatine space as it gives off branches to the upper jaw (maxillae) and teeth.

At this time, look inside the braincase to review the location for the openings of the three branches of the trigeminal nerve on each half of the skull (Fig. 14-4). The **trigeminal nerve** begins within the braincase as one cranial nerve (CN) but splits to exit the neurocranium in three nerve branches through three openings. The most anterior opening is the superior orbital fissure for the ophthalmic branch. Posterior to it is the **foramen rotundum** for the maxillary branch, and the more posterior (and slightly lateral) **foramen ovale** is for the mandibular branch. Recall that the much smaller foramen spinosum is just posterior to the foramen ovale.

C. l a r GE BONES Of Th E fa CE a Nd TEmp Or Oma Nd IBu l a r JOINT (TmJ)

T e form of 14 facial bones gives us our appearance. T ey function in both respiration and digestion. T e facial bones are located inferior to the forehead and make up most of the anterior part of the skull. Five large bones of the face are the mandible, two maxillae, and two zygomatic (cheek) bones. T e smaller bones of the face are the vomer, two palatines, two nasals, two lacrimal bones, and two inferior nasal conchae [KONG kee] (also called turbinates). T e mandible and maxillae are most important when considering the foundation for teeth and tooth function, so they will be discussed in most detail. Although the temporal bones are not considered facial bones, they are being discussed here due to their importance in our understanding of the TMJ.

1. maxilla

One maxilla is shaded red in Figure 14-7. Each **maxilla** [mak SILL a] (right or left) consists of one large, hollow, central mass called the body and four projecting processes or extensions of bone. T e plural of maxilla is maxillae [mack SILL ee]. T e two maxillae contain all of the maxillary teeth.

a. Body of the Maxilla (Structures Seen in Fig. 14-7)

T e **body** of the maxilla is shaped like a four-sided, hollow pyramid with its base oriented vertically next to the nasal cavity and the apex or peak extending laterally to join the zygomatic bone, part of the cheekbone. T e superior portion of the maxilla forms the floor of the orbit of the eye where an **infraorbital ȧssure** is located. T is fissure disappears anteriorly to become the **infraorbital canal** (hidden within the bone in Fig. 14-7). Important branches of the fifth CN and vessels enter this fissure and canal and give off branches within the canal, which supply some of the maxillary teeth and surrounding tissue. T e infraorbital nerves and vessels exit the infraorbital canal onto the face through the **infraorbital foramen**. T is foramen is on the anterior surface of the body of the maxilla, inferior to the eye orbit and superior to the canine fossa, which is a shallow depression superior and lateral to the canine.

b. Maxillary Sinus or Antrum (and Other Paranasal Sinuses)

T ere are four pairs of **paranasal sinuses** (hollow spaces) located within bones surrounding the **nasal cavity** (nasal passages), and they all connect with the nasal cavity. T ree pairs have been mentioned already: the sphenoidal, ethmoidal, and frontal sinuses (within the bones of the same names). T e fourth pair are the maxillary sinuses, one located in each maxilla. T e relative location of these paranasal sinuses are shown later in Figure 14-13. T e **maxillary sinuses** are the largest of these sinuses and, together with the other paranasal sinuses, they function to (a) lighten the skull, (b) give resonance to the voice, (c) warm the air we breathe, and (d) moisten the nasal cavity. (T e average capacity of each maxillary sinus in an adult is about 15 mL or about 1 tablespoon.[1])

Refer to Figure 14-8 while reading about the maxillary sinus. T is large, four-sided, pyramid-shaped cavity located within the body of each maxilla is important to dental health professionals because of the close relationship it has to the teeth. T e sinus cavity floor extends inferiorly onto the superior portion of the maxillary alveolar process where projections of the apices of the molar roots, and sometimes premolar roots, may be found. T is intimate relationship between the teeth and maxillary sinus space can be appreciated in Figure 14-9A and B. Only very thin bone lies between the floor of the sinus and the apices of the roots of the maxillary molars. In rare cases, no bone separates the root apices from the sinus, but there is always soft tissue between the root and the space of the cavity, made up of the periodontal ligament on the tooth root and the mucous membrane lining the sinus cavity. Sometimes, when a dentist extracts a molar and the root breaks off, he or she is unjustly accused of pushing the root into the sinus. It may have been located in the maxillary sinus prior to the extraction. T e other three walls of the pyramid-shaped sinus are toward the orbit of the eye, toward the face, and, posteriorly and laterally, next to the infratemporal space.

T e nerves to the maxillary molars (posterior superior alveolar [PSA] nerves) enter the maxilla and sinus lining through very small foramina called the **alveolar** [al VEE o lar] **canals** located posterior and superior to the maxillary third molars (Fig. 14-8). T ese nerves pass just beneath the membrane lining of the sinus or through bony canals within the walls of the sinus. An infection in either the sinus or these teeth can spread to the other. Pain caused by a maxillary sinus infection can be mistaken for pain originating in any one or all of the molars or premolars on that side. Unfortunately, healthy teeth are sometimes extracted in a futile attempt to alleviate pain that was caused by a chronic maxillary sinus infection.

All of the paranasal sinuses drain directly or indirectly into the nasal cavity, so an infection into the nose may spread into these sinuses. T e **opening from each maxillary sinus** to the nasal cavity is located on its anterosuperior wall (Fig. 14-8). T e maxillary sinus is lined with specialized cells (ciliated columnar epithelium) similar to those found in the respiratory tract. T e lining secretes mucous that moves spirally and upward (against gravity) across the membrane toward the opening of the sinus, which is located on the anterosuperior wall (Fig. 14-8), where secretions can drains into the nasal cavity. If humans walked on all fours with the head forward like many animals, this opening for drainage would be on the floor of the sinus, not near the roof, and humans would have fewer sinus problems. Persons with a congested maxillary sinus may get pain relief by placing their head with the face downward for several minutes to permit more rapid drainage of the maxillary sinuses.

c. Bony Processes of Each Maxilla

T ere are four processes extending out from the body of the maxillae. T e first three described below are best viewed in Figure 14-7.

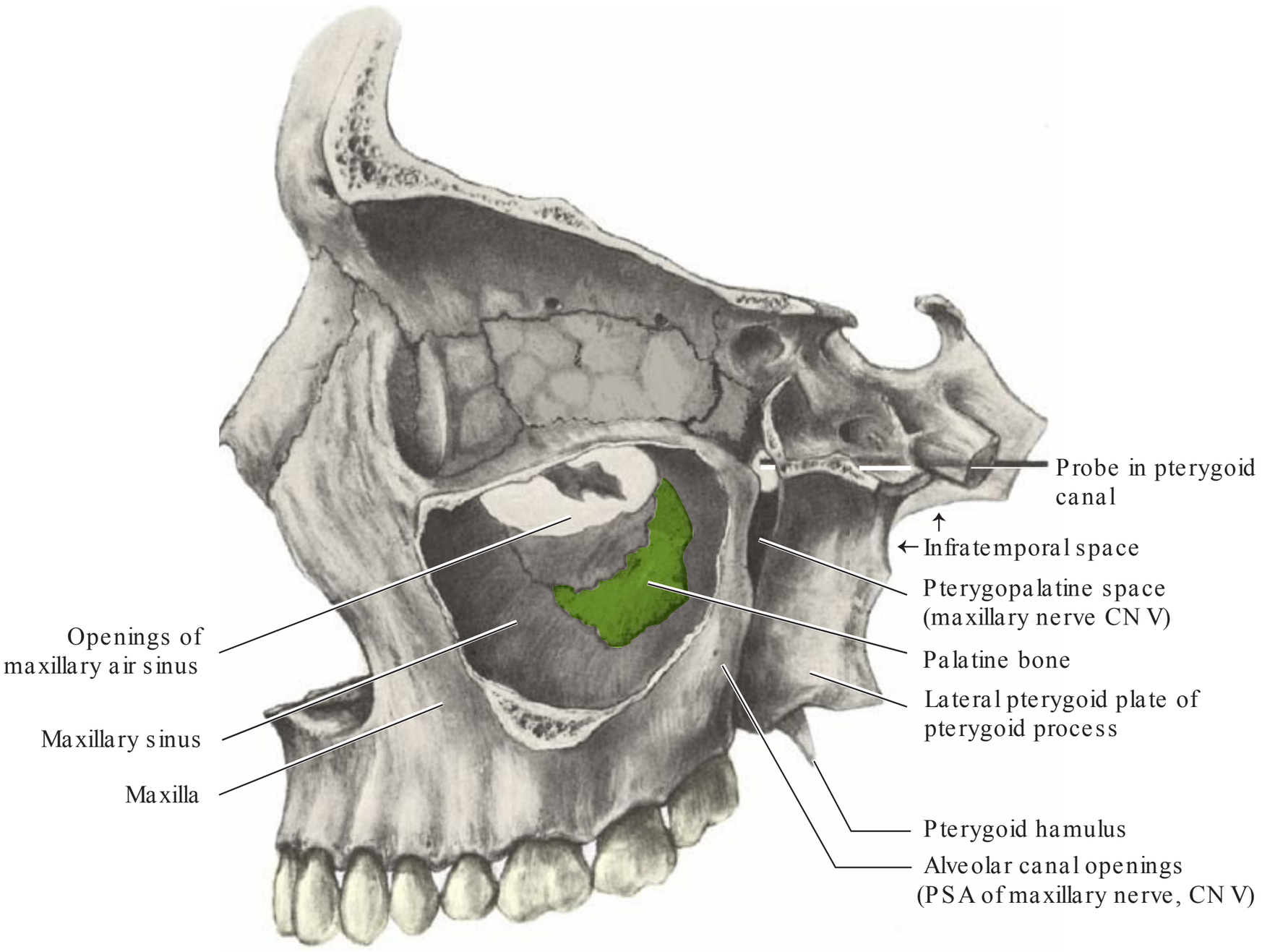

FIGURE 14-8. Part of human skull, lateral view, with the lateral wall of the left maxilla removed, exposing the large maxillary sinus. Note that the foor of this sinus is in proximity to the maxillary posterior teeth but does not extend forward as far as the maxillary anterior teeth. The opening of this sinus (into the nasal chamber) is located superiorly on the medial wall of the sinus. A portion of the palatine bone on the posterior wall of the sinus (shaded light green) is the vertical process of the palatine bone located adjacent to the pterygopalatine space. (Reproduced from Clemente CD, ed. Gray's anatomy of the human body. 30th ed. Philadelphia, PA: Lea & Febiger, 1985:166, with permission.)

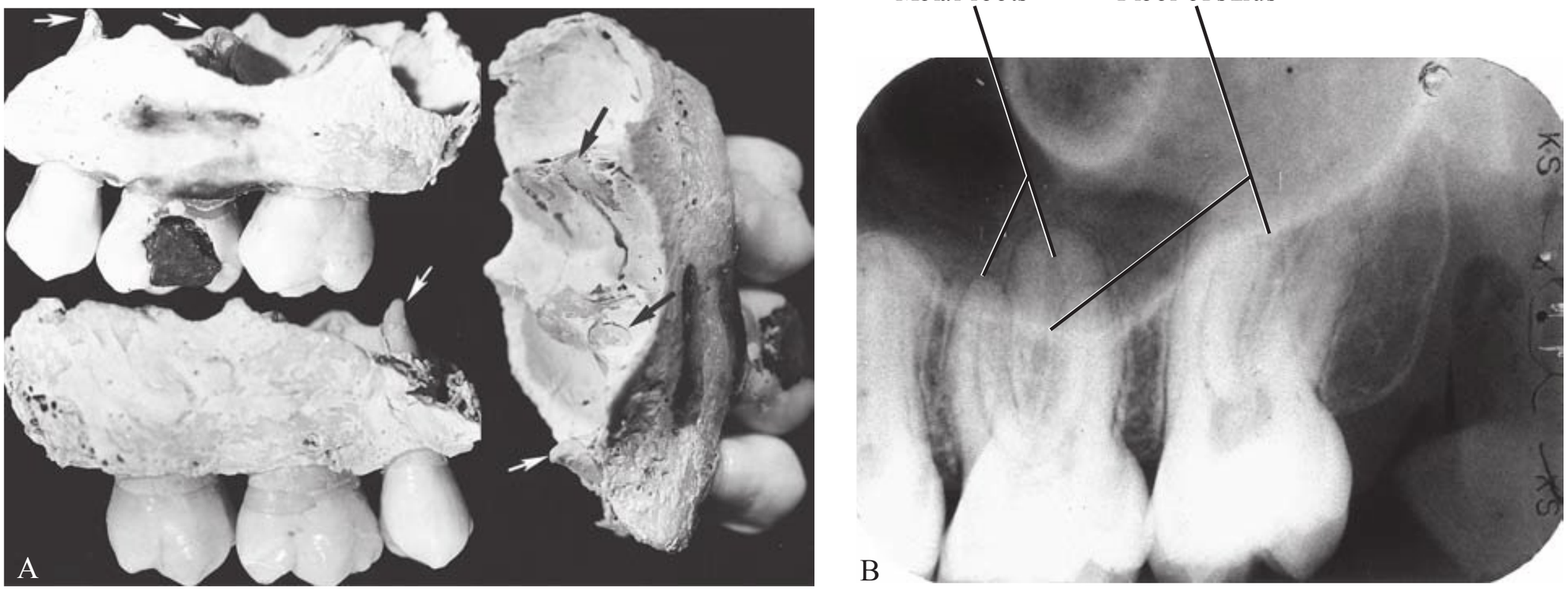

FIGURE 14-9. A. Three views of part of the left alveolar process of the maxilla surrounding the roots of the maxillary first and second molar and second premolar. Note the root tips (apices) shown by arrows extending out of the maxilla into what would have been the foor of the maxillary sinus space in an intact skull. B. Radiograph of the maxillary molar region showing the roots of the first molar several millimeters deep into the maxillary sinus (dark area surrounded by white border). Parts of the roots of the second molar are also within the sinus cavity. The root tip of the second premolar root is in the sinus as well. This is a common relationship.

Frontal (or nasoFrontal) Process

The **frontal** (or **nasofrontal**) **process** derives its name from the fact that its medial edge joins with the nasal bone, extending superiorly to also articulate with the frontal bone. The medial surface forms part of the lateral wall of the nasal cavity and half of the opening of the nasal cavity (called the **piriform aperture** because of its pear shape).

Zygomatic Process

The bulky **zygomatic process** forms part of the anterior or facial surface of each maxilla. It extends laterally to join with the maxillary process of the zygomatic bone.

alveolar Process

The horseshoe-shaped **alveolar** [al VEE o lar] **processes** of the right and left maxillae (also found on the mandible, described later) extend from the body of the maxillae to surround the roots of all maxillary teeth. The extension of these process from the body of each maxilla is best appreciated by viewing the maxillary from below since, when viewed laterally, the alveolar process appears to be continuous with the body of the maxilla (seen shaded on the right maxilla and the entire lower jaw or mandible in Fig. 14-7 and identified in cross-section in Fig. 14-10). Within each alveolar process, the roots of each tooth are embedded in an individual **alveoli** (or tooth sockets) that are visible in the mouth after a recent tooth extraction. The shape of each alveolus or thin bony socket naturally corresponds closely with the shape of the roots of the tooth it surrounds. **Alveolar eminences** are raised ridges of bone externally overlying prominent tooth root convexities. The alveolar eminence over the canine tooth on each side is called the **canine eminence** (Fig. 14-7). Medial to the canine eminence is a shallow fossa over the root of the maxillary lateral incisor called the **incisive** [in SI siv] **fossa**. Lateral and superior to the canine eminence is a fossa over the roots of maxillary premolars named the **canine fossa**.

The alveolar process is made up of several bony layers (seen in cross-section of the mandible in Fig. 14-10). The mandibular bone is made up of the thickened inner (lingual) and outer (facial) dense **cortical plate** with less dense **trabecular** [trah BEK u lar] **bone** sandwiched in between. Trabecular bone is composed of many plate-like bone partitions that separate the irregularly shaped marrow spaces located within this bone. Synonyms for trabecular bone include cancellous or spongy bone. Small nerve branches and vessels actually pass through this spongy bone to enter all teeth through their apical foramen. A thin, compact bony layer called **alveolar bone proper** or bundle bone lines the wall of each tooth socket (or alveolus) and shows up on radiographs as a white line called the **lamina dura**. Other

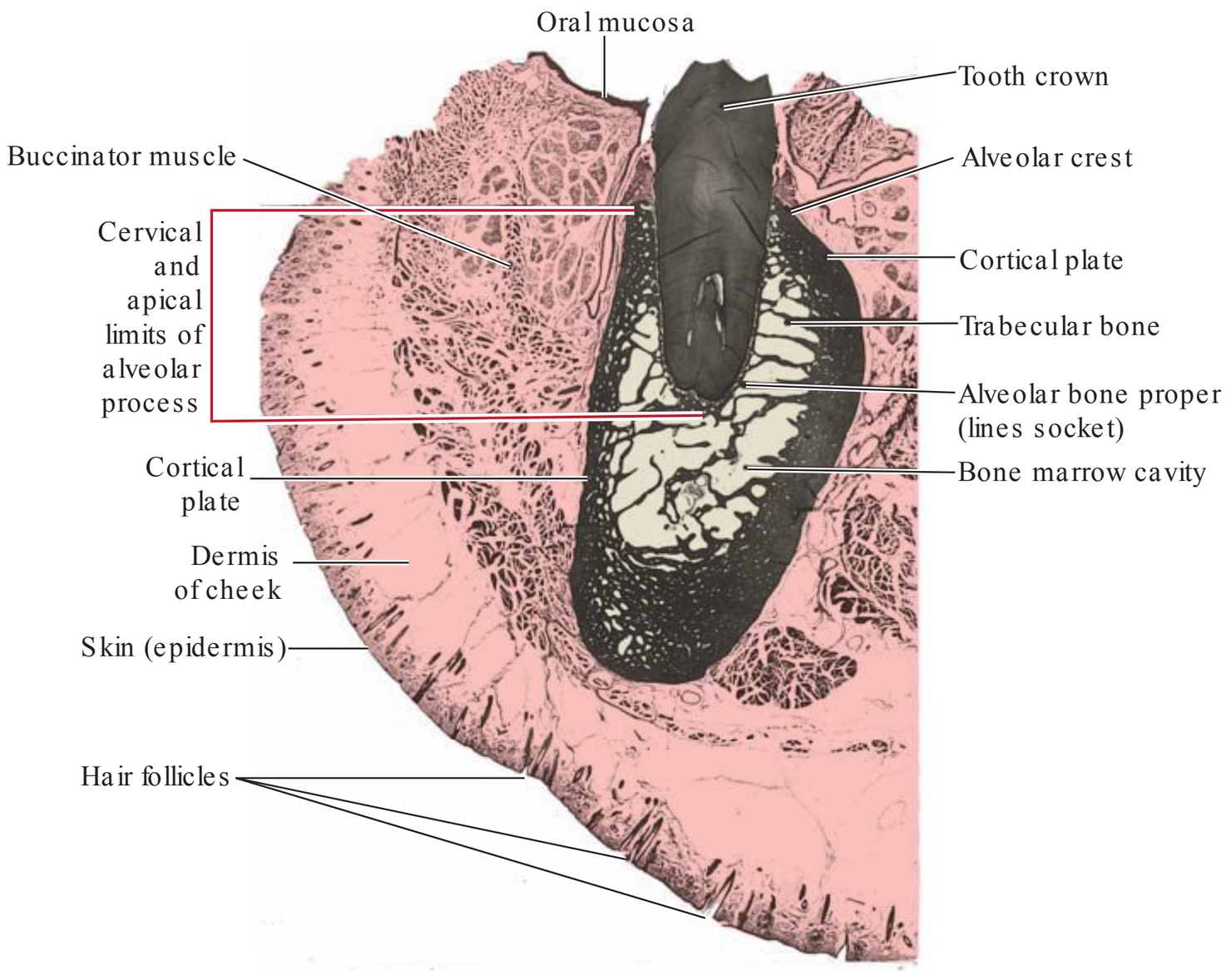

fIGur E 14-10. A buccolingual cross-section (about 30 µm thick) of a human mandible and a molar. To the left of the mandible is the soft facial tissue of the cheek. Note the extent of the alveolar process (denoted by a red bracket)—the part of the mandible that surrounds the teeth roots. The thick cortical plate surrounds the entire facial (left) and medial (right, inner) surfaces of the mandible, while the very thin layer of bone lines the socket that surrounds the tooth root called alveolar bone proper. A very thin periodontal ligament extends between the alveolar bone proper that lines the socket and outer layer of tooth root. It supports the tooth within its socket. Note that much of this mandible has the texture of a sponge with many hollow spaces (bone marrow cavities), allowing nerves and blood vessels, after entering the bone through foramen, to pass through this trabecular (spongy) bone on their way to each tooth and adjacent bony structures. (Tooth enamel was destroyed by the decalcification of the specimen with nitric acid preparatory to embedding and sectioning.) For further information on the histology of these structures, refer to references.[2–8]

terms used to describe this bony layer include bundle bone, alveolar bony socket, true alveolar bone, and cribriform plate of the alveolar process. The only space between the outer layer of tooth root (which is covered with cementum) and this alveolar bone is occupied by a periodontal ligament that suspends each tooth within its alveolus by attaching the circumference of each tooth root to the surrounding alveolar bony socket. The **periodontal ligament** is very thin (less than a third of a millimeter).

Palatine Process of the Maxilla

The right and left **palatine** [PAL a tine] **processes** (Fig. 14-11) join to form the anterior three quarters of the bony roof of the mouth called the **hard palate**. The separate paired palatine bones, discussed later in this chapter, form the posterior one quarter of the hard palate. The palatine process of each maxilla is a thin, bony shelf that projects horizontally to join the process from the opposite side. The entire hard palate separates the nasal passageways from the oral cavity. That is, the hard palate forms the roof the mouth and the floor of the nasal passageways. The shape and relative location of these processes can be best appreciated by viewing them posteriorly between the two pterygoid processes of the sphenoid bone.

The anteroposterior line of fusion between the right and left palatine processes of the maxillae (and the horizontal plates of the palatine bones) is the **intermaxillary** (or **midpalatine**) **suture**. It is located on the midline running posteriorly from the incisive foramen (Fig. 14-11). The **incisive foramen** is a centrally located opening at the most anterior part of this suture, just posterior to the central incisors. It transmits branches of the nasopalatine nerve and artery that supply adjacent palatal mucosa. Just posterior to the maxillary alveolar process of the most posterior maxillary molar is a bulge of bone called the **maxillary tuberosity**. A notch that separates the maxillary tuberosity of each maxilla from the adjacent pterygoid process of the sphenoid bone is called the **hamular notch**. Recall that the **pterygoid hamulus**, the hook-like projection of the medial plate of the pterygoid process, is located just posterior to the hamular notch. In your mouth, the pterygoid hamulus might be felt with your tongue (or clean fingers) under the mucosa of the soft palate posterior to the hard palate and slightly medial to the maxillary tuberosity.

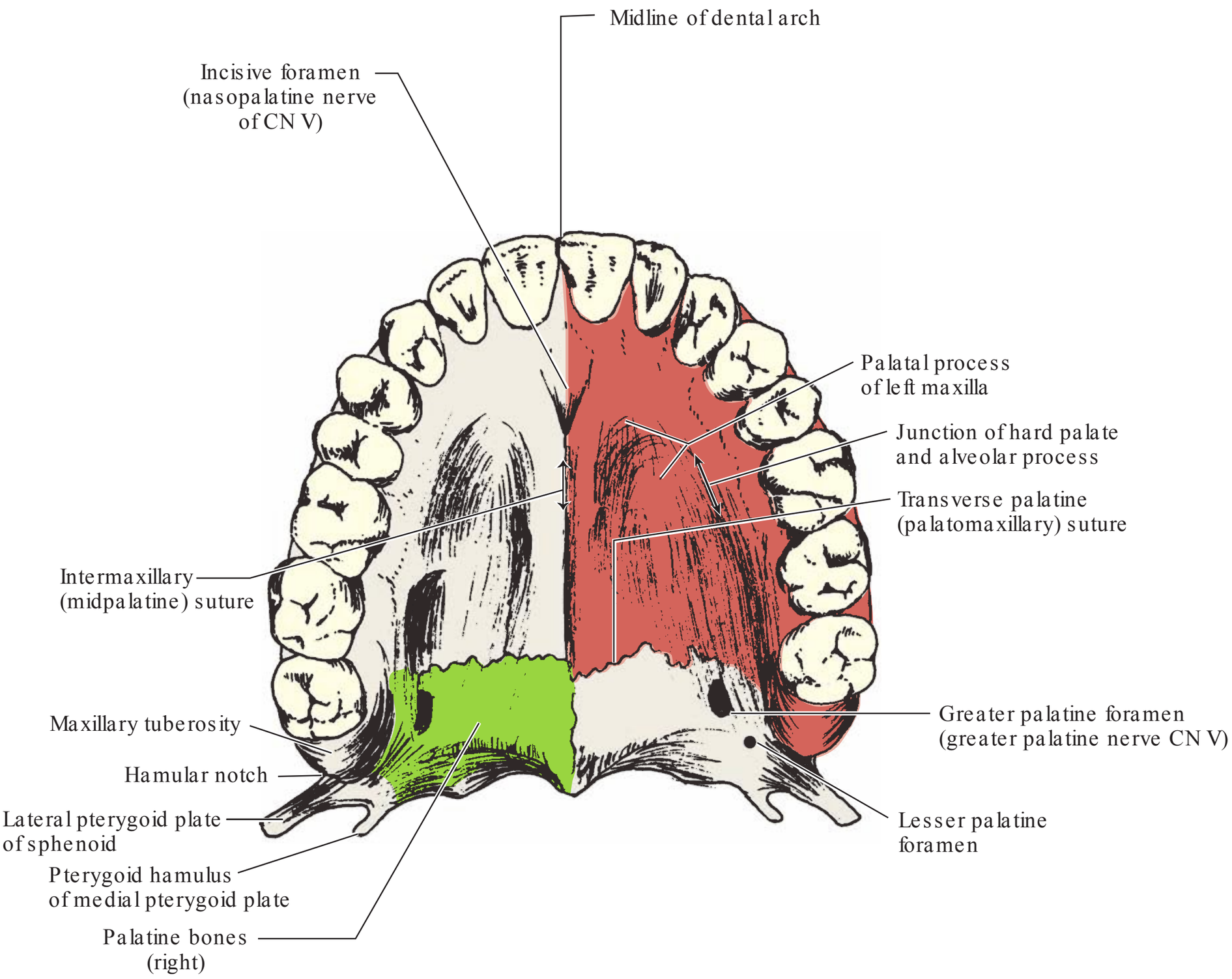

FIGURE 14-11. Inferior view of the hard palate with maxillary teeth. The palatine process of the left maxilla is shaded red (on the right side of the drawing), and the horizontal process of the right palatine bone is shaded light green on the left side of the drawing. Note the important foramen where nerves and vessels can pass through to supply the palatal tissue: the greater palatine foramen in the palatine bones and the incisive foramen anteriorly between the palatine processes of the two maxillae. Also, notice the location of the junction of the hard palate and alveolar process.

An embryonic **premaxilla** cannot normally be distinguished in the adult skull. It is the anterior part of the maxillary bone, which contains the incisors. When visible, a suture line separates the premaxilla from the palatine processes of the two maxillae.

2. palatine Bones

Refer to Figure 14-11 while reading about the **palatine bone**. T e horizontal processes of the paired palatine bones form the posterior one fourth of the **hard palate**. T e entire hard palate is made up of these palatine bones, along with the right and left palatine processes of the maxillae. A **palatomaxillary** [PAL ah toe MACK si lar ee] **(transverse palatine) suture,** at right angles to the intermaxillary suture, is the junction between the palatine processes of the maxillae and the horizontal processes of the palatine bones. T e shape of the palate and the shape of the maxillary arch vary in length, width, and height. T e hard palate blends smoothly with the palatal portion of the maxillary alveolar process. Part or all of the palatine processes are absent in a person who was born with a cleft palate.

T e **greater palatine** [PAL ah tine] **foramina** (Fig. 14-11) are located posteriorly on each side near the angle where the right and left palatine bones meet the alveolar processes of the hard palate. T ey transmit the descending palatine vessels and greater (anterior) palatine nerves to the palate. T e **lesser palatine foramina** are located on the palatine bone just behind and lateral to the greater palatine foramen. T ey transmit the middle and posterior palatine nerves.

T e palatine bones also have vertical processes that are practically hidden from view on the intact skull. T ese vertical processes form part of the posterior wall of the maxillary sinus in Figure 14-8. T ese vertical processes of the palatine bones are separated from the pterygoid process of the sphenoid bone by a space called the **pterygopalatine** [TER i go PAL ah tine] **space**, mentioned earlier when discussing the maxillae. Recall that this space is an important passageway of the maxillary nerve branches of CN V that exited from the cranium via the foramen rotundum on their way to the maxillary teeth and surrounding structures.

3. Zygomatic Bones

T e **zygomatic bones** (also called **malar bones**) form the prominence of each cheek (one on each side of the face, shaded purple in Fig. 14-12). T e temporal process of the zygomatic bone forms an arch along with the adjoining

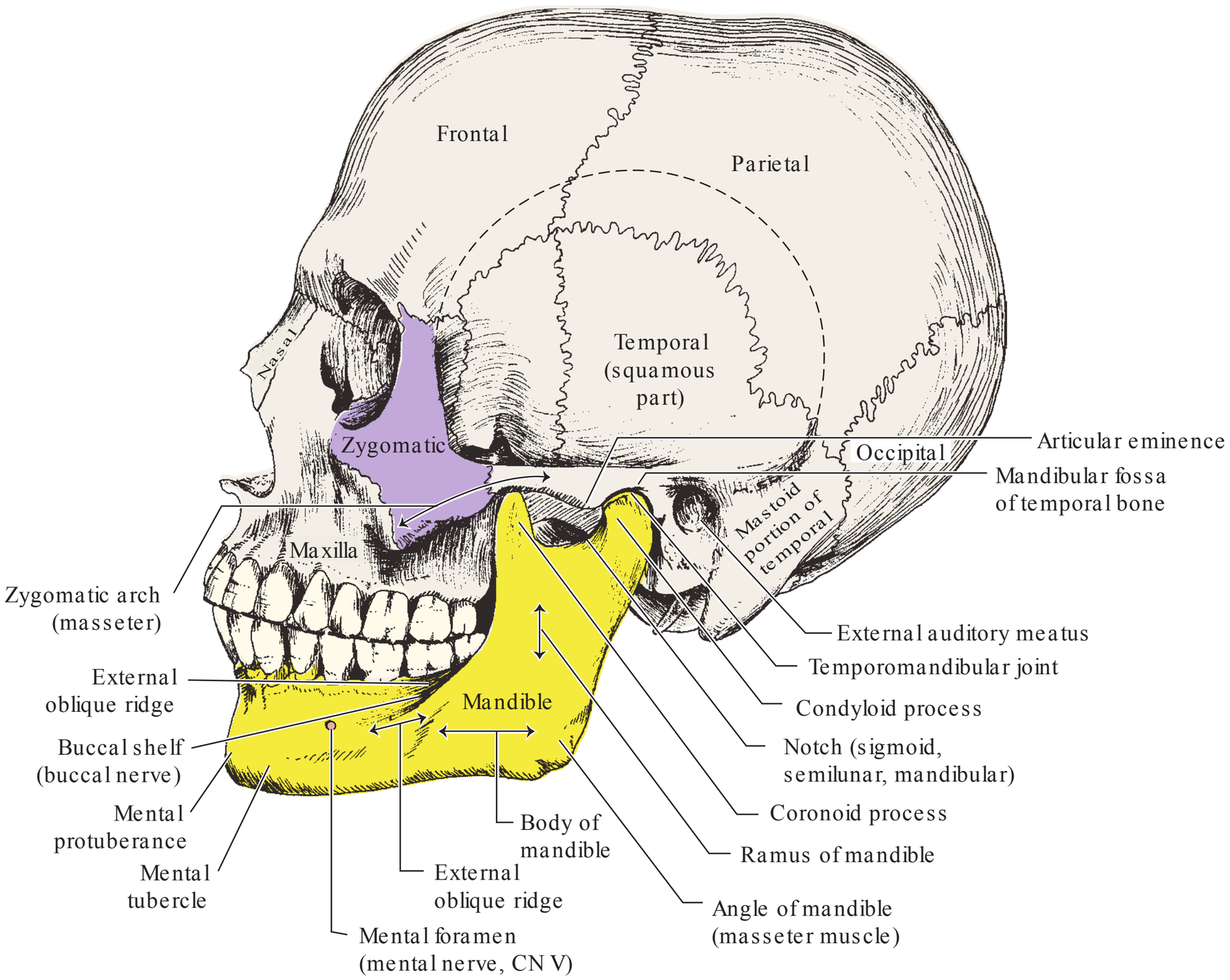

fIGu r E 14-12. H**u**man sk**u**ll, le**f**t side. The lateral view of the mandible is shaded yellow, and the left zygomatic bone (of the cheek) is shaded purple. In this view, the vertical ram**u**s and its two processes (condylar and coronoid processes) are evident. Also, the zygoma bone, the zygomatic process of the temporal bone, and the zygomatic process of the maxilla form the z**yg**omatic arch.

zygomatic process of the temporal bone. T is **zygomatic arch** is where another muscle of mastication (the masseter muscle) attaches to the skull.

4. mandible: forming the Inferior portion of the Temporomandibular Joint

T e single horseshoe-shaped **mandible** [MAN de b'l], seen anteriorly in Figure 14-13, is the largest and strongest bone of the face. Generally speaking, it is bilaterally symmetrical, and it contains all of the mandibular teeth. It is attached by ligaments and muscles to the relatively immovable bones of the temporal bone. T e **temporomandibular joint (TMJ)** between the mandible and the temporal bones are movable articulations, the only visible movable articulations in the head. T erefore, the mandible is the only bone of the skull that can move. T e other bones of the skull move only when the whole head is moved, and then, they move in unison.

T e mandible has three parts: one horizontal, horseshoe-shaped **body** and two vertical **rami** [RAY mee] (singular, ramus [RAY mus]) (see Fig. 14-13). T e landmarks of the mandible will be discussed according to their location: first those seen on the external surface of the body, then those on each ramus, and then those seen on the internal surface.

a. Body of the Mandible: External Surface

As with the maxillae, a horseshoe-shaped **alveolar** [al VEE o lar] **process** surrounds the tooth roots (shaded in Fig. 14-7), and **alveolar eminences** are visible as vertical elevations over tooth roots on the facial surface. T e prominent elevations overlying the roots of the canines are called the **canine eminences**.

T e **symphysis** [SIM fi sis] is the line of fusion of the right and left sides at the midline where the two halves of the mandible fused (joined together) during the first year after birth. It is therefore usually not visible. Near the symphysis, two mental tubercles and one mental protuberance make up the human chin (Fig. 14-13). No other mammal has a chin. Two **mental tubercles** lie on either side of the midline near the inferior border of the mandible. T e **mental protuberance** is centered on the midline between the two

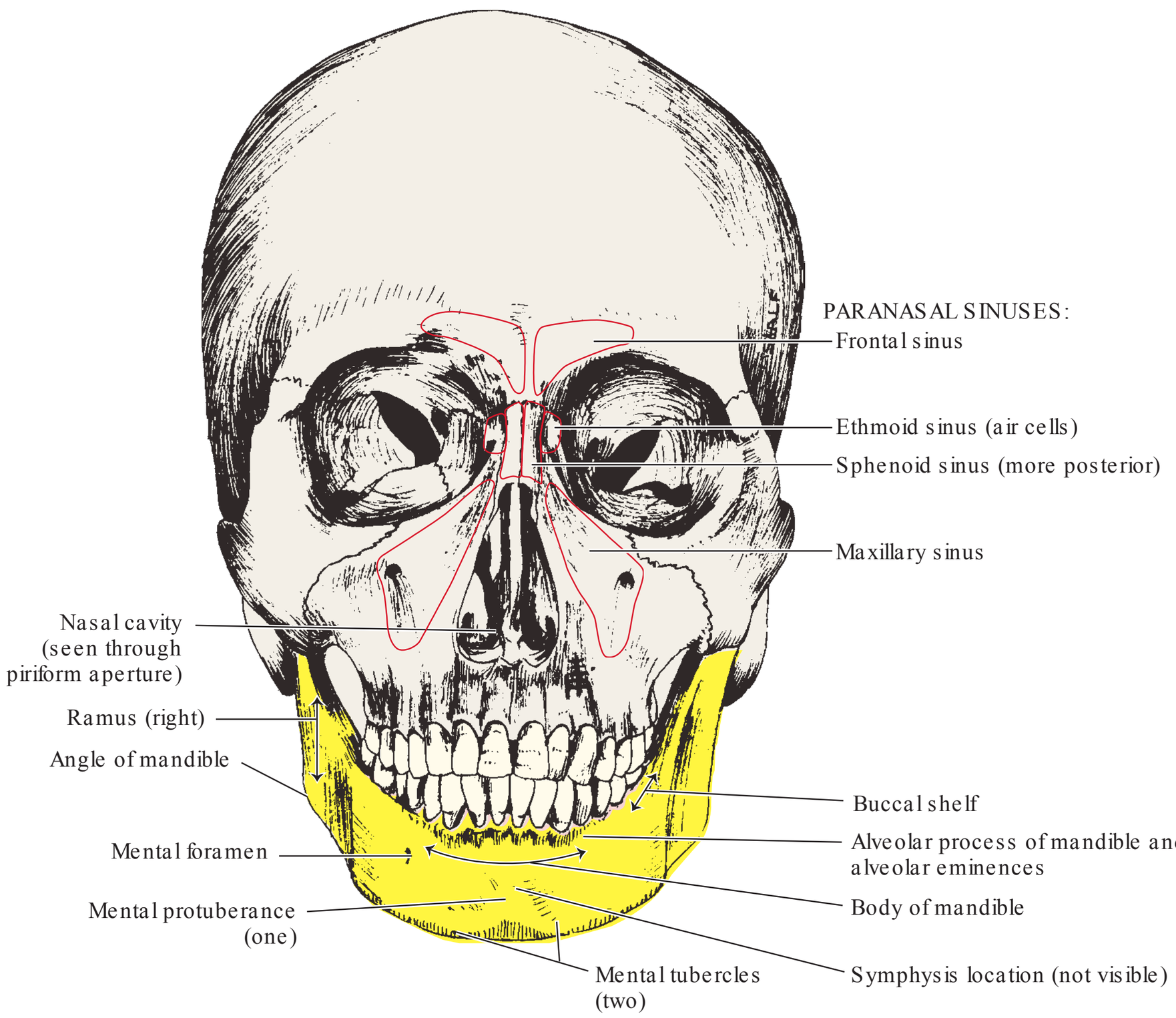

fIGu r E 14-13. H**u**man sk**u**ll, **f**rontal aspect. The mandible is shaded yellow. The bulky bod**y** of the mandible is the horizontal portion including the alveolar process that surrounds the mandibular teeth, and the two vertical processes extending to the base of the neurocranium (to the temporal bones) are called the rami (single is ram**u**s). Also, the relative locations of the four pairs of paranasal sin**u**ses are outlined: frontal, ethmoid (also called air cells), sphenoid (more posterior than ethmoid), and maxillary.

mental tubercles but is about 10 mm superior. The protuberance and the tubercles are more prominent on men than on women.

An **external oblique** [ob LEEK] **ridge** (Fig. 14-12) extends from the anterior border of the ramus toward the canine region. The nearly horizontal ledge of bone in the molar region between the external oblique ridge and alveolar process is named the **buccal shelf**. The buccal (or buccinator) nerve is located in the cheek just superior to this shelf.

The **mental foramen** is located near the root end (apex) of the second premolar (Fig. 14-12). The nerve within the mandible (inferior alveolar nerve) gives off a branch (mental branch of the inferior alveolar nerve) that exits through this mental foramen to supply skin on that side of the chin. The mental nerve exits the mandible in an outward, upward, and posterior direction before it spreads anteriorly. Place a flexible probe carefully into this canal of the mandible to confirm the direction of this canal. The mental foramen is located at practically the same level on most humans: 13 to 15 mm superior to the inferior border of the mandible. (In a study of 40 skulls,[9] the mental foramen was found most often to be directly under the second premolar (42.5% of the time) or between the apices of the first and second premolars (40%). Infrequently, it was located distal to the apex of the second premolar (17.5%) and was never found under the apex of the first premolar.) On dental radiographs (x-rays), this foramen appears as a small dark circle next to the premolar root and must be distinguished from a periapical abscess (infection destroying bone near the root apex), which may appear very similar to the normal mental foramen.

The bulky, curved, horizontal body and each flattened vertical ramus join at the angle of the mandible on either side. The **angle of the mandible** is where the inferior border of the body joins the posterior border of the ramus (Fig. 14-12). The roughened portion of the lateral surface near the angle of the mandible is where the inferior end of the powerful masseter muscle attaches. The posterior border of the ramus is the location of the attachment of one end of the stylomandibular ligament (whose other end attaches to the styloid process of the temporal bone).

b. *Ramus of the Mandible: Lateral Surfaces*

Refer to Figure 14-12 while reading about this surface. There are two processes on the superior end of each ramus. The **coronoid** [KOR o noyd] **process** is the more pointed, anterior process on the upper border. The second more rounded and posterior process of the ramus is the **condyloid** [KON di loyd] **process** (also called the **mandibular condyle**). This process is composed of a bulky condyle head and a narrow neck that attaches the head to the ramus. The **sigmoid notch** (also called the mandibular or semilunar notch) is located between the coronoid process and the condyloid process. An important muscle of mastication, the lateral pterygoid, attaches to the front of the neck of the condyloid process in a depression called the **pterygoid fovea** (Fig. 14-14). The head of the mandibular condyle fits into and functions beneath the articular (glenoid) fossa of the temporal bone (which is discussed in more detail later in this chapter).

c. *Internal or Medial Surface of Mandible*

Refer to Figure 14-14 while reading about this surface of the mandible. The **mandibular foramen** is a prominent opening located on the medial surface of the ramus inferior to the sigmoid notch near the middle of the ramus anteroposteriorly. It is the entrance into the mandibular canal where the inferior alveolar vessels and nerves pass from the infratemporal space into the mandible. The mandibular **lingula** [LING gu lah] is a tongue-shaped projection of bone just anterior and slightly superior to the mandibular foramen. This is where the inferior end of the sphenomandibular ligament attaches to the mandible. The superior end attaches to the angular (sphenoidal) spine on the sphenoid bone. The **mylohyoid groove** is a small groove running inferior and anterior from the mandibular foramen. The mylohyoid nerve rests in this groove.

The **temporal crest** is a ridge of bone extending from the tip of the coronoid process onto the medial surface of the ramus and terminating near the third molar. The tendon from the fibers of the wide, flat, fan-shaped temporalis muscle attaches here. The inferior one fourth of the temporal crest

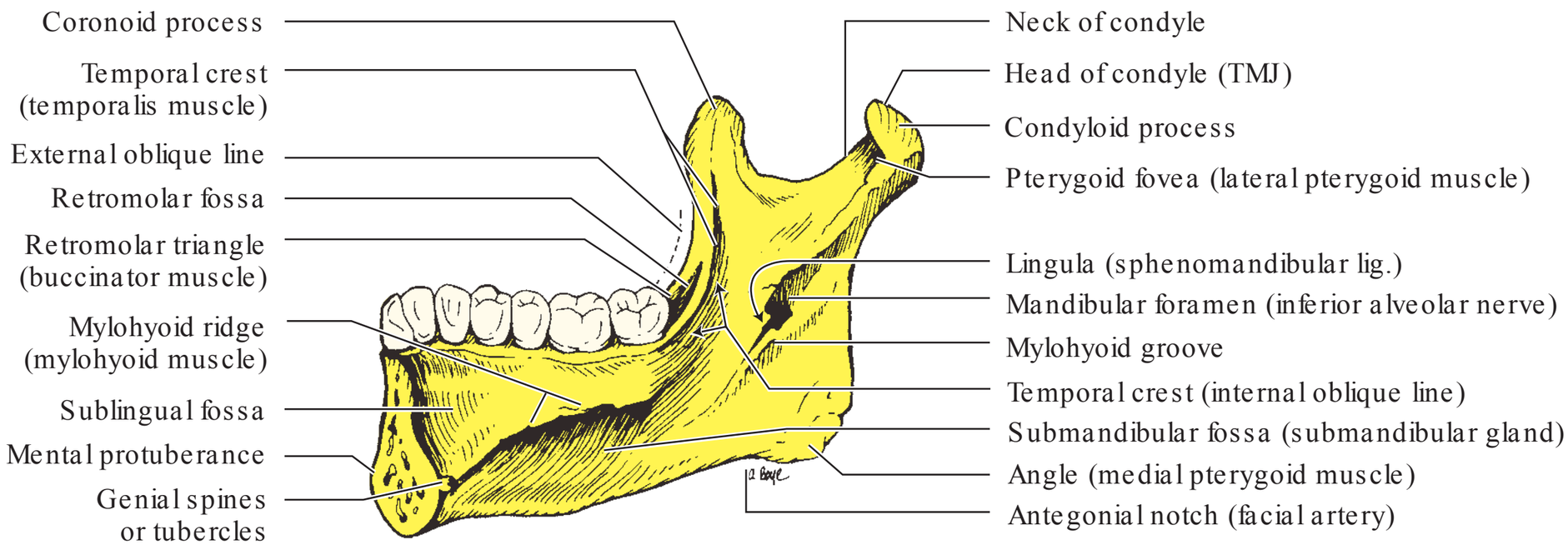

FIGURE 14-14. Mandible, medial surface. Notice the important mandibular foramen, as well as ridges, fossa, and processes.

is called the **internal oblique line**. It is most important as a radiographic, rather than an anatomic, landmark. It appears on radiographs as a short, curved line somewhat inferior to the image of the external oblique line.

T e **retromolar fossa** is a roughened shallow fossa distal to the last molar and bounded medially by the lowest portion of the temporal crest and laterally by the external oblique ridge. T e **retromolar triangle** is in the lowest most anterior, and only horizontal, portion of the retromolar fossa. T e most posterior fibers of the buccinator muscle (a pouch-shaped cheek muscle) attach within this retromolar triangle on a slight ridge of bone called the buccinator crest.

Genial [JEE ne al] and **mental spines** or **tubercles** are located on either side of the midline on the internal surface of the mandible. Two large muscles (the genioglossus and the geniohyoid) attach to these spines and the elevated, roughened bone near them.

T e **mylohyoid ridge** extends downward and forward from the molar region to the genial tubercles. It is not synonymous with the internal oblique line as incorrectly stated in some radiographic textbooks. T e mylohyoid muscle, which forms part of the floor of the mouth, attaches from the mylohyoid ridge on the right medial side of the mandible to the ridge on the left medial side (somewhat like a hammock). T e mylohyoid ridge separates two fossae, one above and one below. A very broad, shallow **sublingual** [sub LING gwal] **fossa** is found just superior to the mylohyoid ridge and lateral to the genial tubercles on each side. T e sublingual salivary gland rests in this fossa. A shallow **submandibular fossa** is found just inferior to the mylohyoid ridge in the premolar and molar regions. T is is where the large submandibular salivary gland rests. On the inferior border of the mandible, a shallow notch (called the **antegonial** [an te GO nee al] **notch** seen in Fig. 14-14) is located anterior to the angle of the mandible and is where the facial arteries and veins pass from the neck to the face. You should be able to feel a pulse at this location of your own lower jaw.

5. Temporal Bones: forming the Superior part of the Temporomandibular Joint

T e **temporal bones** are a pair of complex bones that form part of the sides and base of the neurocranium (braincase) (best seen laterally in Fig. 14-15 where one is shaded blue). Laterally, the **temporal fossa** (outlined in Fig. 14-15) is a large, very shallow depression in the temple region of the face formed primarily by the lateral part of the temporal bone (also called the **squamous** part because it is shaped like a large fish scale) and also by the greater wing of the sphenoid bone and parts of the parietal and frontal bones that were discussed earlier. T e temporal fossa is where the superior end of the major muscle of mastication (the temporalis muscle) attaches. **Squamosal** [skwa MO sal] **sutures** join the temporal bones to the parietal bones.

T e paired temporal bones are especially important to dental professionals since each has a **mandibular fossa** (one is labeled on the right side of Fig. 14-16) located on the inferior aspect of the temporal bones. It is within these fossae that the mandibular condyles articulate with the temporal bones on the base of the neurocranium. T is jaw joint (actually a joint

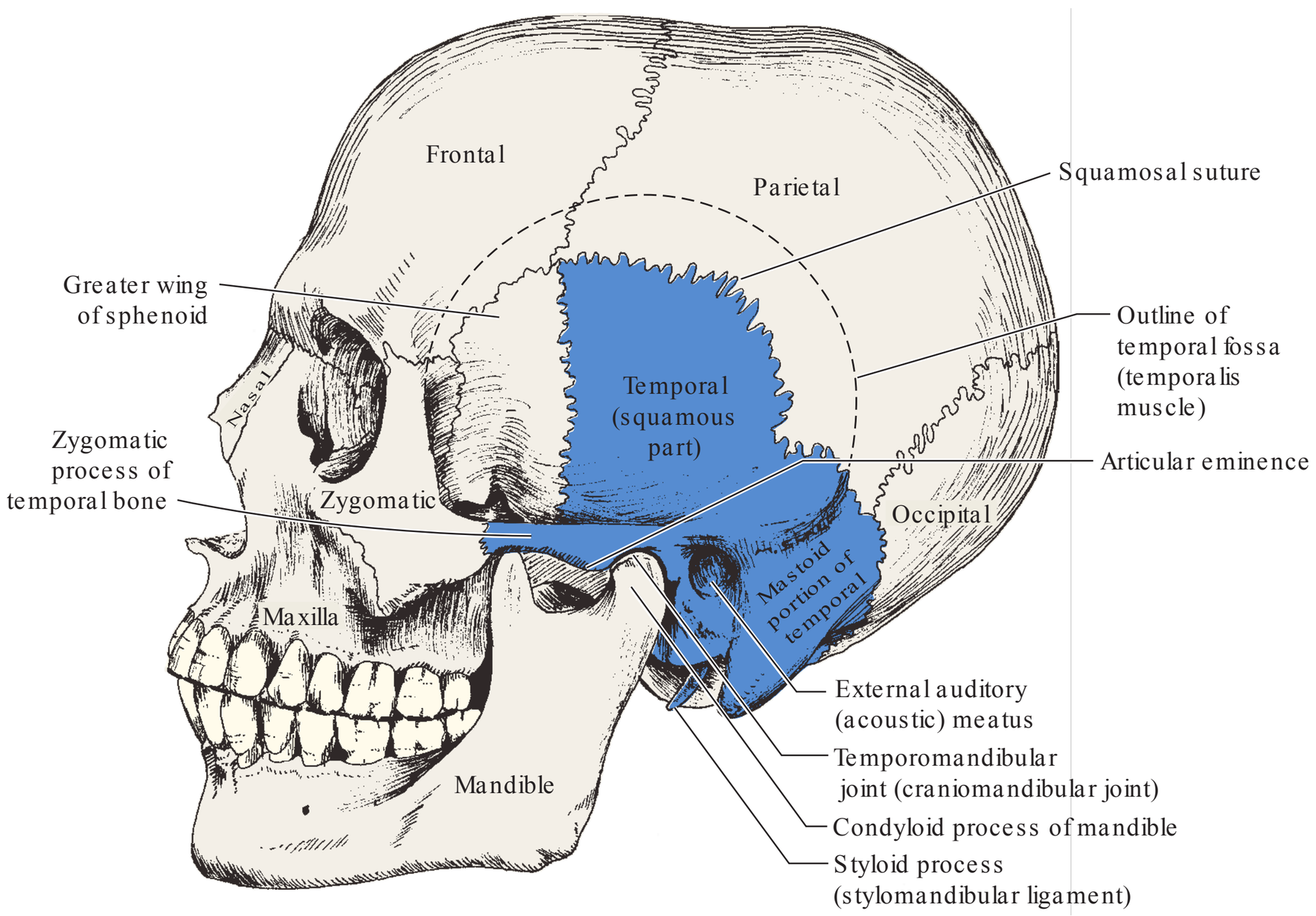

fIGur E 14-15. H**u**man sk**u**ll, le**f**t side. The lateral surface of the left temporal bone is shaded blue. Note its squamous part, as well as its processes: mastoid, styloid, and zygomatic.

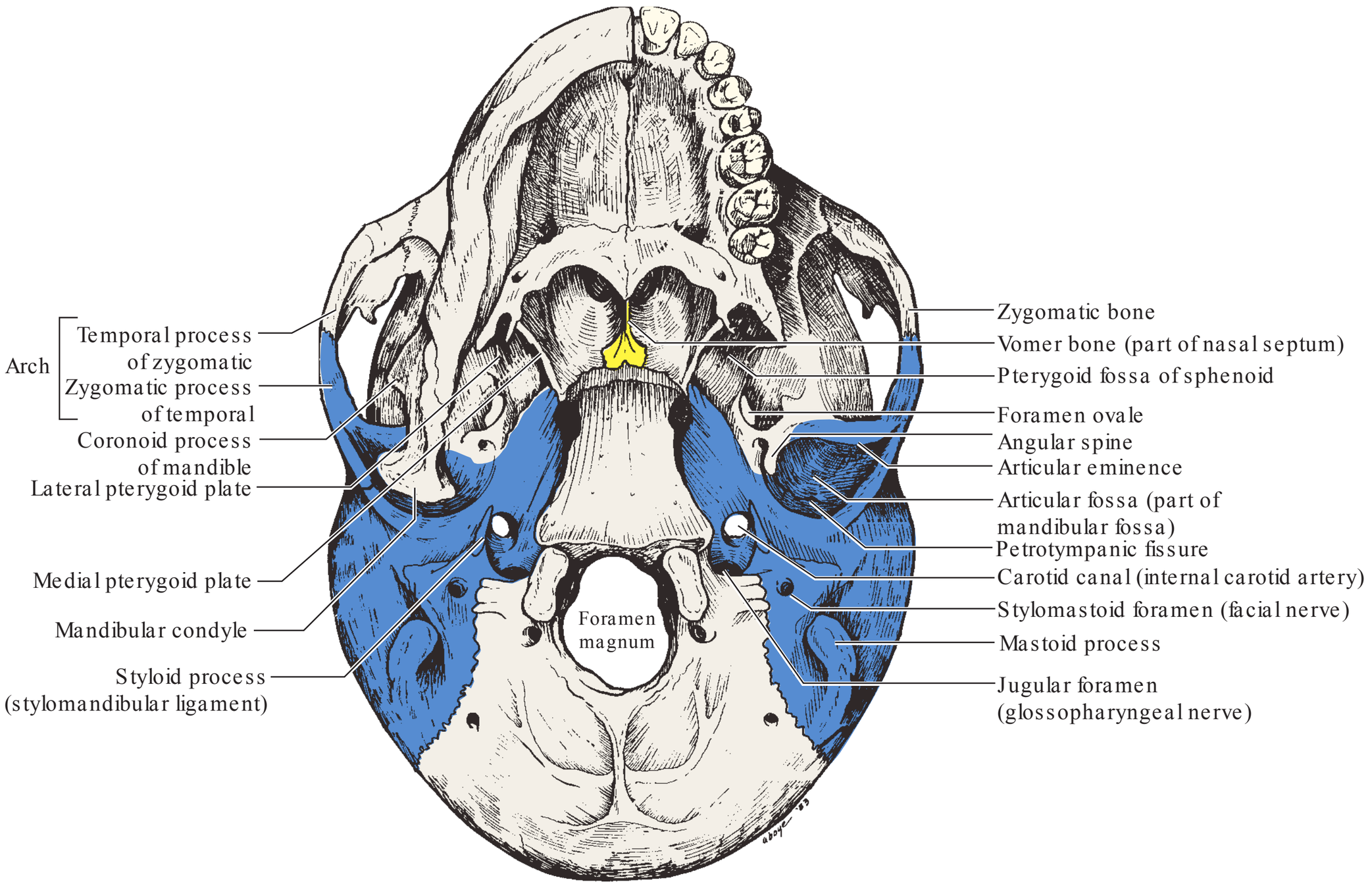

fIGur E 14-16. H**u**man sk**u**ll, in**f**erior s**u**r**f**ace, with half of the mandible removed on the ri**g**ht side of the drawing. The right and left temporal bones are shaded blue. Note the zygomatic process forming part of the zygomatic arch and the mandib**u**lar and artic**u**lar **f**ossa and artic**u**lar eminence. The small portion of the midline vomer bone (shaded yellow) is seen separating the right and left halves of the nasal passageways.

on each side) is called the **temporomandibular joint** (commonly abbreviated **TMJ**) where the temporal bone and mandible articulate. Each mandibular fossa can be divided into two parts by the **petrotympanic ȧssure** (Fig. 14-16). T e anterior two thirds of each mandibular fossa (that portion anterior to the petrotympanic fissure) is the important **articular fossa** (or **glenoid fossa**). Each articular fossa has a ridge of bone forming its anterior border, which is called the **articular eminence**.

Each temporal bone has several processes. T e **zygomatic** [zy go MAT ik] **process** (Fig. 14-15) is the finger of bone extending anterior and lateral to the mandibular fossa of the TMJ. It joins with the temporal process of the zygomatic bone (and the zygomatic process of the maxillae) to form an arch called the **zygomatic arch**. T is arch shape of bones, seen from beneath in Figure 14-16, is the attachment of one end of the large muscle of mastication (masseter muscle). T e prominent **mastoid process** or portion (Fig. 14-15), seen inferiorly and posteriorly to the mandibular fossa, is the attachment for one end of a major neck muscle, the sternocleidomastoid muscle. You can feel the bump of the mastoid process behind your earlobe. Also, on the inferior surface of the temporal bones but more medial is the **styloid process** (Fig. 14-15), shaped like a small skinny pencil (or stylus). It is the attachment for one end of a ligament (stylomandibular ligament) that extends to the mandible.

Several paired foramina are of importance on this bone. Laterally, the large **external acoustic meatus** [a KOO stik me A tus] or **auditory meatus** is the entrance into the ear canal (Fig. 14-15). Note the proximity of the TMJ to the ear canal opening. T is **petrous portion** of the temporal bone contains the auditory canal with the minute bones of hearing known as the malleus, incus, and stapes. T e facial nerve (CN VII) exits the braincase by entering this petrous portion of the temporal bone through the **internal acoustic meatus** (Fig. 14-17) and exits the temporal bone into the infratemporal space through the **stylomastoid foramen** (Fig. 14-16), which is located between the styloid and mastoid processes. T e **carotid canal** is the passageway of the internal carotid artery into the braincase, and the **jugular foramen** (between the temporal and occipital bones) is where the glossopharyngeal nerve (CN IX) passes out of the braincase (seen externally in Fig. 14-16 and internally in Fig. 14-17).

d. Sma l l BONES Of Th E fa CE

T e **vomer bone** is a midline bone that, along with the vertical projection of the ethmoid bone, forms the **nasal septum.** T e vomer is visible posteriorly between the two halves of the nasal passageways in Figure 14-16, and the nasal septum is visible anteriorly in Figure 14-18. T e nasal septum separates

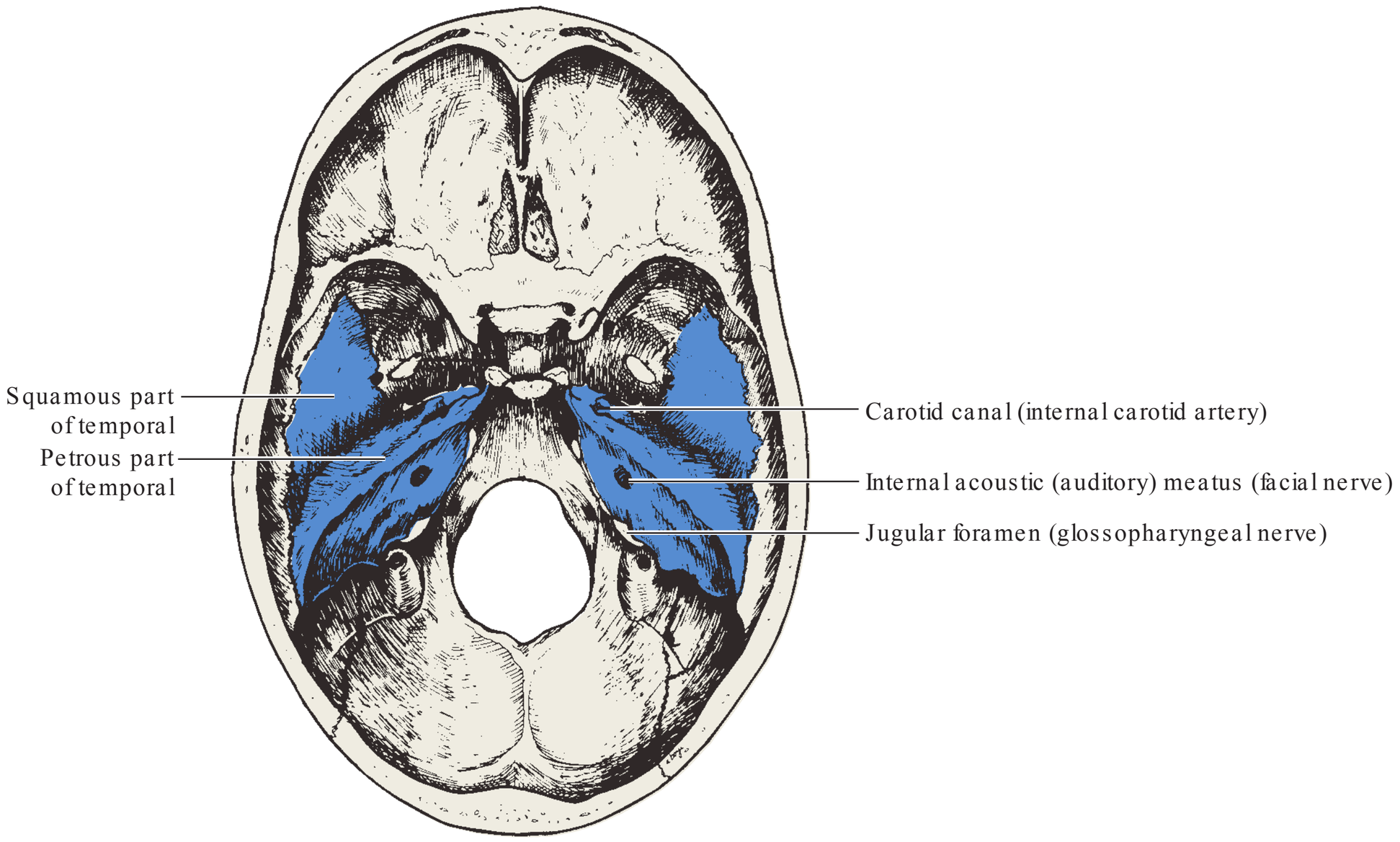

FIGURE 14-17. Part of human skull: bones lining the inside of the neurocranium with the temporal bones in blue. The thick petrous portion of these bones contains the very small bones of the inner ear (incus, stapes, and malleus). Important nerves and vessels pass through the foramen labeled on this diagram. (Reproduced from Clemente CD, ed. Gray's anatomy of the human body. 30th ed. Philadelphia, PA: Lea & Febiger, 1985:166, with permission.)

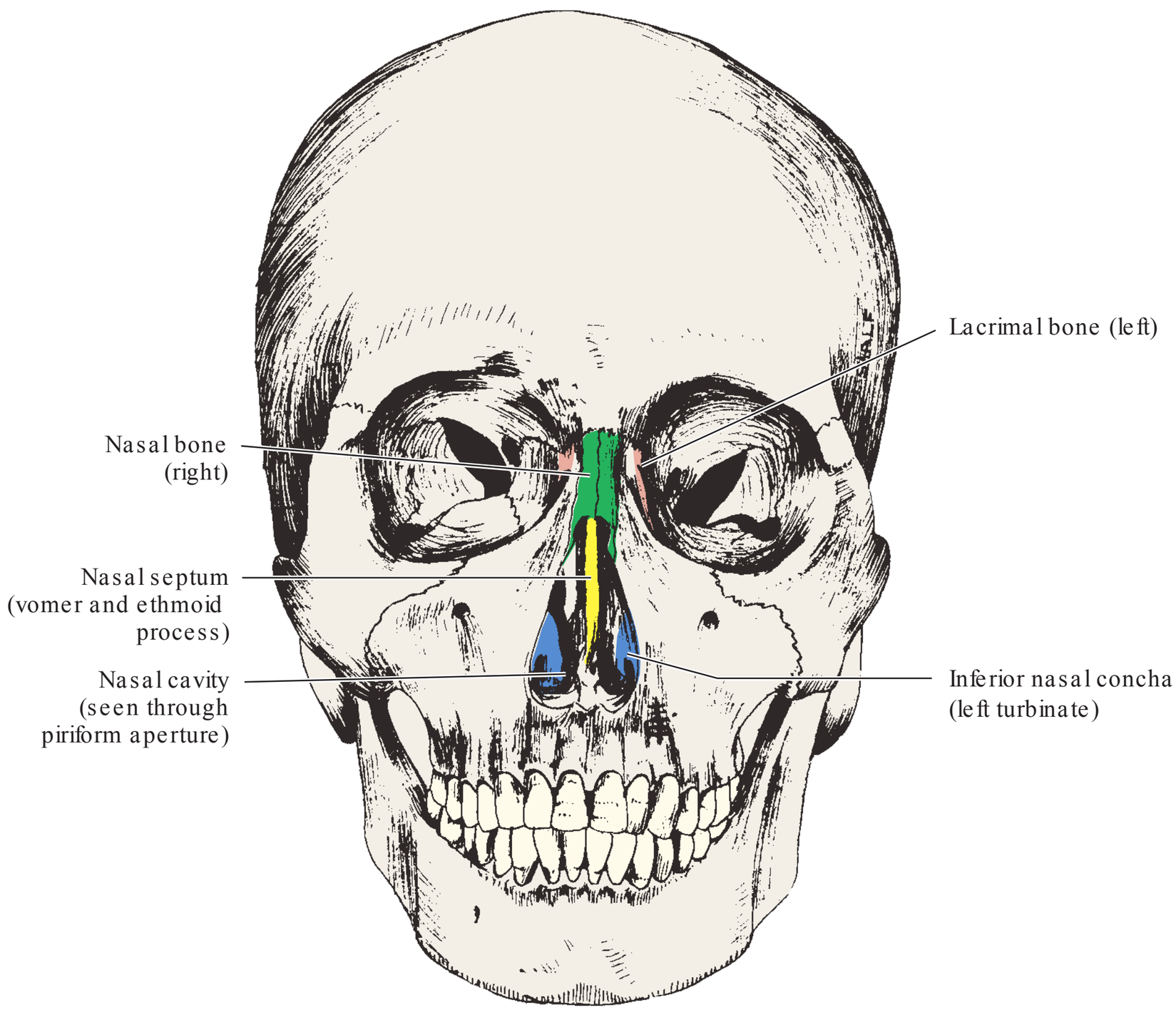

FIGURE 14-18. Human skull, frontal aspect. Several small bones of the face and nose are shaded: the nasal bones forming the bridge of the nose are shaded green, the lacrimal bones on the medial surfaces of the eye socket are shaded light red, the inferior nasal conchae or turbinate bones on the lateral sides of the nasal passageway are shaded blue, and the midline nasal septum is shaded yellow. The septum is made up of two bones: the vomer bone and the midline plate of the ethmoid bone.

the right and left halves of the nasal cavity. A deviated septum may limit breathing and require surgery.

The two **nasal bones** form the bony bridge of the nose (Fig. 14-18). These nasal bones along with the two maxilla bones, surround the opening (**piriform aperture**) to the **nasal cavity**, also known as the nasal passages.

The **lacrimal** [LAK ri mal] **bones** (also spelled lachrymal) are small rectangular bones at the medial corner of each orbit that contain a depression for tear glands (Fig. 14-18).

The **inferior nasal conchae** [CONG kee] or singular concha [KONG kah] (or **turbinates**) are scrolled bones (like the cross-section scroll shape of a conch shell) in the nasal cavity forming part of the maxillary sinus wall. These are best seen through the piriform aperture (Fig. 14-18). Along with other scrolled processes of the ethmoid bone described earlier, they increase the area of mucous membrane inside the nasal cavity to warm and moisten air that we breathe.

E. hyOId BONE

The **hyoid** [HI oid] **bone** (see later in Fig. 14-35) is not really a bone of the skull but is located in the neck above the laryngeal prominence of the thyroid cartilage (known to many as the Adam's apple or voice box). The hyoid bone is not connected to the bones of the skull except via soft tissue. A group of muscles that extend from the hyoid bone superiorly to attach to the mandible are called suprahyoid muscles (such as the geniohyoid muscles that also attach to the genial tubercles), and another group that extend inferiorly from the hyoid bone to attach to the sternum (breastbone) or clavicle (collar bone) are called infrahyoid muscles.

r EvIEw Questions

Select the one best answer.

1. Which of the following bones does not form part of the temporal fossa?
   a. Parietal
   b. Frontal
   c. Sphenoid
   d. Temporal
   e. Occipital

2. The mental foramen is located where?
   a. On the external surface of the mandible
   b. On the internal surface of the mandible
   c. On the palatal surface of the maxilla
   d. On the external surface of the maxillae
   e. On the sphenoid bone

3. What space does the maxillary nerve pass through immediately after exiting the foramen rotundum?
   a. Nasopalatine canal
   b. Mandibular canal
   c. Maxillary sinus
   d. Infraorbital canal
   e. Pterygopalatine space

4. What bony process of the maxilla surrounds tooth roots?
   a. Nasofrontal process
   b. Frontal process
   c. Alveolar process
   d. Zygomatic process
   e. Palatine process

5. Which structure is not located on the sphenoid bone?
   a. Foramen ovale
   b. Foramen rotundum
   c. Greater wing
   d. Pterygoid process
   e. Articular fossa

6. Which teeth are most likely to have the roots in proximity with the maxillary sinus?
   a. Maxillary molars and premolars
   b. Maxillary canines
   c. Maxillary incisors
   d. Mandibular posterior teeth

7. The suture line joining the two parietal bones is called the
   a. Squamosal suture.
   b. Coronoid suture.
   c. Sagittal suture.
   d. Intermaxillary suture.
   e. Lambdoid suture.

8. Which of the following is **not** a bone that contains paranasal sinuses?
   a. Zygomatic
   b. Sphenoid
   c. Ethmoid
   d. Maxilla
   e. Frontal

a–8; c–7; a–6; e–5; c–4; e–3; a–2; e–1: Sr E wS Na

LEARNINg ExERCISES

Each of the following bony landmarks can be seen or felt underneath the soft tissue on the face or in the mouth and could be used to describe the location of abnormalities during a clinical examination. First, describe the location; then, identify each of the following landmarks on your own face and on an actual skull (or figures within this text). Use the referenced figures to confirm that you have correctly located each landmark. Use clean fingers when palpating structures within the mouth.

- Canine eminence of the mandible and maxillae—Figure 14-7
- Mental protuberance—Figure 14-13
- Maxillary tuberosity—Figure 14-11
- External auditory meatus—Figure 14-12

Each of the following landmarks is the attachment of a major muscle or ligament of importance to the dental professional. First, describe the location; then, identify each of the following landmarks on an actual skull (or figures within this text). Use the referenced figures to confirm that you have correctly described the location of the attachment on the skull. When possible, also feel or point to the landmark's location on your own head or within your mouth (using clean fingers).

- Angle of the mandible, lateral surface (lower end of masseter muscle)—Figure 14-12
- Zygomatic arch (upper end of masseter muscle)—Figure 14-12
- Angle of the mandible, medial surface (lower end of medial pterygoid muscle)—Figure 14-14
- Medial surface of the lateral pterygoid plate and adjacent pterygoid fossa of the sphenoid bone (upper end of medial pterygoid muscle)—Figure 14-6
- Temporal fossa (upper end of temporalis muscle)—Figure 14-15
- Coronoid process and temporal crest of mandible (lower end of temporalis muscle)—Figure 14-14
- Lateral surface of the lateral pterygoid plate of the sphenoid bone (anterior end of lateral pterygoid muscle)—Figure 14-5

lEa r NING ExEr CISE (continued)

- Pterygoid fovea: anterior neck of mandibular condyle (posterior end of lateral pterygoid muscle)—Figure 14-14
- Angular spine of the sphenoid (upper end of sphenomandibular ligament)—Figure 14-6
- Lingula of the mandible (lower end of sphenomandibular ligament)—Figure 14-14
- Styloid process of the temporal bone (upper end of stylomandibular ligament)—Figure 14-15
- Mastoid process of the temporal bone (upper end of sternocleidomastoid muscle)—Figure 14-15
- Mylohyoid ridge of the mandible (mylohyoid muscle)—Figure 14-14
- Genial spines of the mandible (upper end of some suprahyoid muscles)—Figure 14-14

Each of the following foramen or spaces is the passageway for nerves and blood vessels of importance to the dental professional. First, describe the location; then, identify each of the following foramina or spaces on an actual skull (or figures within this text). Use the referenced figures to confirm that you have correctly located the foramen, canal, or space on the skull. Then, try to place your finger as close as possible to that opening, realizing that sometimes you cannot get very close with your finger but might get closer with the needle of a hypodermic syringe.

- Foramina rotundum in the sphenoid bone (for the maxillary division of trigeminal nerve)—Figure 14-4
- Pterygopalatine space (for the maxillary division of trigeminal nerve)—Figure 14-5
- Foramina ovale in the sphenoid bone (for the mandibular division of trigeminal nerve)—Figures 14-4 and 14-6
- Mandibular foramina in the mandible (for the inferior alveolar nerve)—Figure 14-14
- Mental foramina in the mandible (for the mental nerve)—Figure 14-12
- Greater palatine foramina in the palatine bones (for the greater palatine nerve)—Figure 14-11
- Incisive foramen between the maxillary bones (for the nasopalatine nerve)—Figure 14-11
- Infraorbital foramina in the maxillae (for the infraorbital nerve)—Figure 14-7

SECTION II Th E TEmpOr OmaNd IBu l a r JOINT (TmJ)

Objectives

The objectives for this section are to prepare the reader to perform the following:

- Describe and locate (on a skull) the articulating parts of the TMJ.
- Describe the location and functions of the articular disc.
- Palpate the lateral and posterior surfaces of the condyle of the mandible during movement of the jaws.
- On a skull, describe and locate the attachments of the ligaments of the TMJ.

An introduction to the TMJ was presented in Chapter 9 on Occlusion, but this chapter goes into more detail regarding the anatomy of this joint. A joint, or articulation, is a connection between two separate bones of the skeleton. T e TMJ is the articulation between the two condyles of the mandible and the two temporal bones. For that reason, some authors state that we have two TMJs, but since it is a bilateral articulation where the right and left sides work as one unit, the authors of this book will refer to the joint as one TMJ. T is articulation may also correctly be termed the craniomandibular articulation since it is the articulation between the movable mandible and the stationary cranium or skull.[10] It is the only visible free-moving articulation in the head; all others are sutures and are immovable.[11]

T e coordinated movements of the right and left joints are complex and usually controlled by reflexes. Within some limit or range, the great adaptability of the joints permits the freedom of movement of the mandible required during speech and mastication (chewing). One can learn, however, to move the mandible voluntarily into specific, well-defined positions or pathways.[12–16] Both the maxillae and mandible support teeth whose shape and position greatly influence mandibular movements.[10] Proper functioning of the TMJs has a profound effect on the occlusal contacts of teeth, which involve nearly all phases of dentistry.

a. aNaTOmy Of Th E TEmpOr OmaNd IBu l a r JOINT

T ere are three articulating parts to each side of the TMJ: the mandibular condyle, the articular fossa of the temporal bone (with its adjacent eminence), and the articular disc interposed between the bony parts (Figs. 14-19 and 14-20). T ese parts are enclosed by a fibrous connective tissue capsule.[1,11,14]

1. mandibular Condyle

Each **mandibular condyle** [KON dile] is about the size and shape of a large date pit with the greater dimension mediolaterally than anteroposteriorly, evident when comparing the width of the condyle mediolaterally in Figure 14-20 to the narrower width anteroposteriorly seen from the side in Figure 14-19. From the posterior (or anterior) aspect, it is wide mediolaterally with a narrow neck. The superior surface of the mandibular condyle is strongly convex anteroposteriorly and mildly convex mediolaterally.

Carefully examine the photomicrograph of a human TMJ seen in Figure 14-21. T e condyle is in the position it would occupy when the teeth fit together as tightly as possible (maximum intercuspal position). T e functioning regions are covered with fibrous connective tissue. T e fibrous layers of the condyle are avascular (devoid of blood vessels and nerves).[2] T is fibrous, avascular type of connective tissue is adapted to resist pressure. It is particularly thick on the superior and anterior surfaces of the condyle (seen as the red-shaded structure in Fig. 14-21) over the region where most function occurs when the condyle is forward from its resting position, as when we bring our incisors together. (Notice in Fig. 14-21 that this same type of fibrous covering also lines the posterior articulating surfaces of the articular eminence and adjacent fossa, as well as the center portion of the disc.)

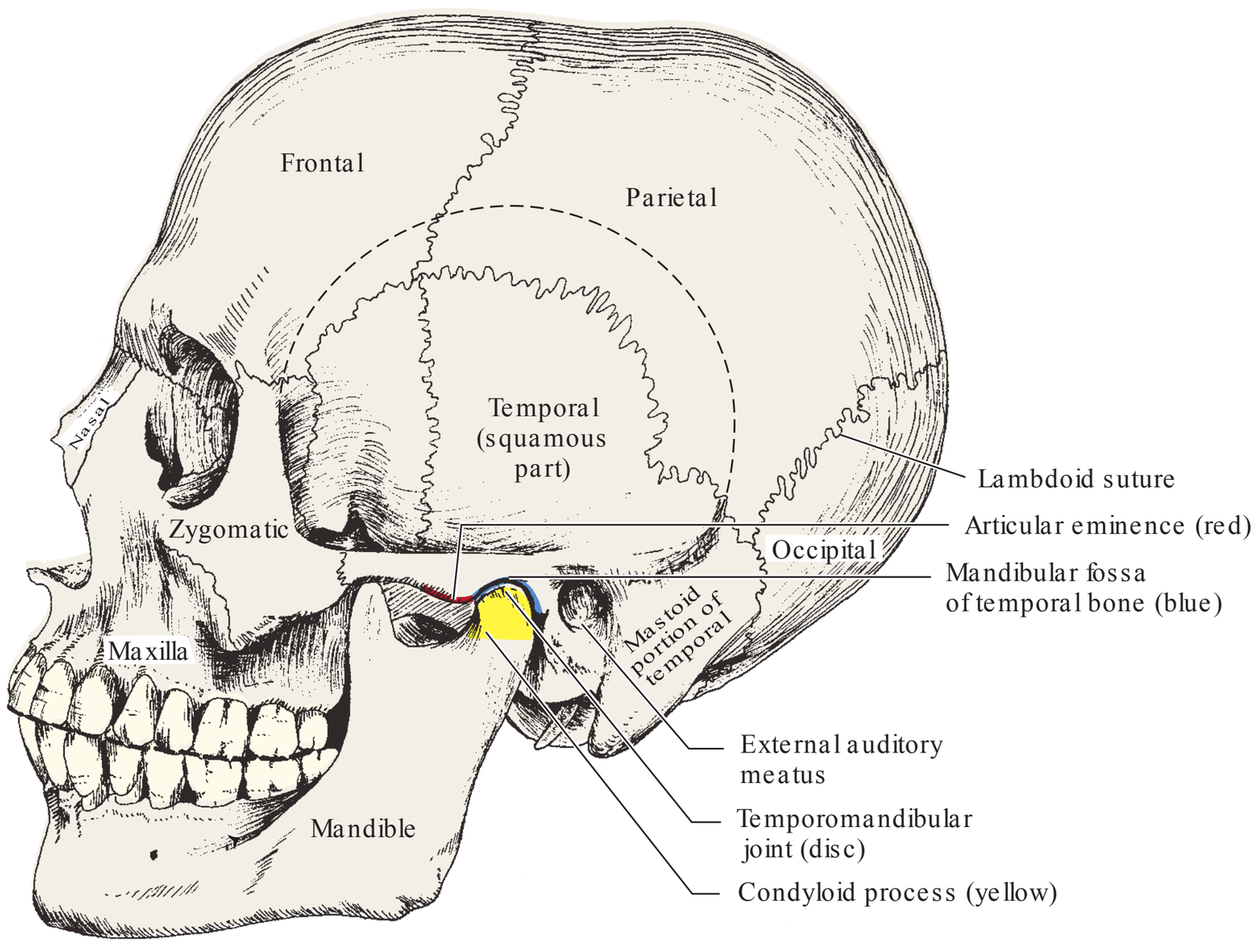

fIGu r E 14-19. **Hu**man sk**u**ll, le**f**t side. This lateral view shows the articulation of the bones of the temporomandib**u**lar joint, namely, the temporal bones and the mandible. The head of the condyle of the mandible is shaded yellow, and the blue line on the inferior border of the zygomatic process of the temporal bone outlines the concave mandib**u**lar (with its artic**u**lar) fossa. A red line just anterior to it outlines the convex artic**u**lar eminence. For the mandibular to move forward, the condyles guide the mandible down onto the articular eminence, so the mandible is depressed and the mouth opens.

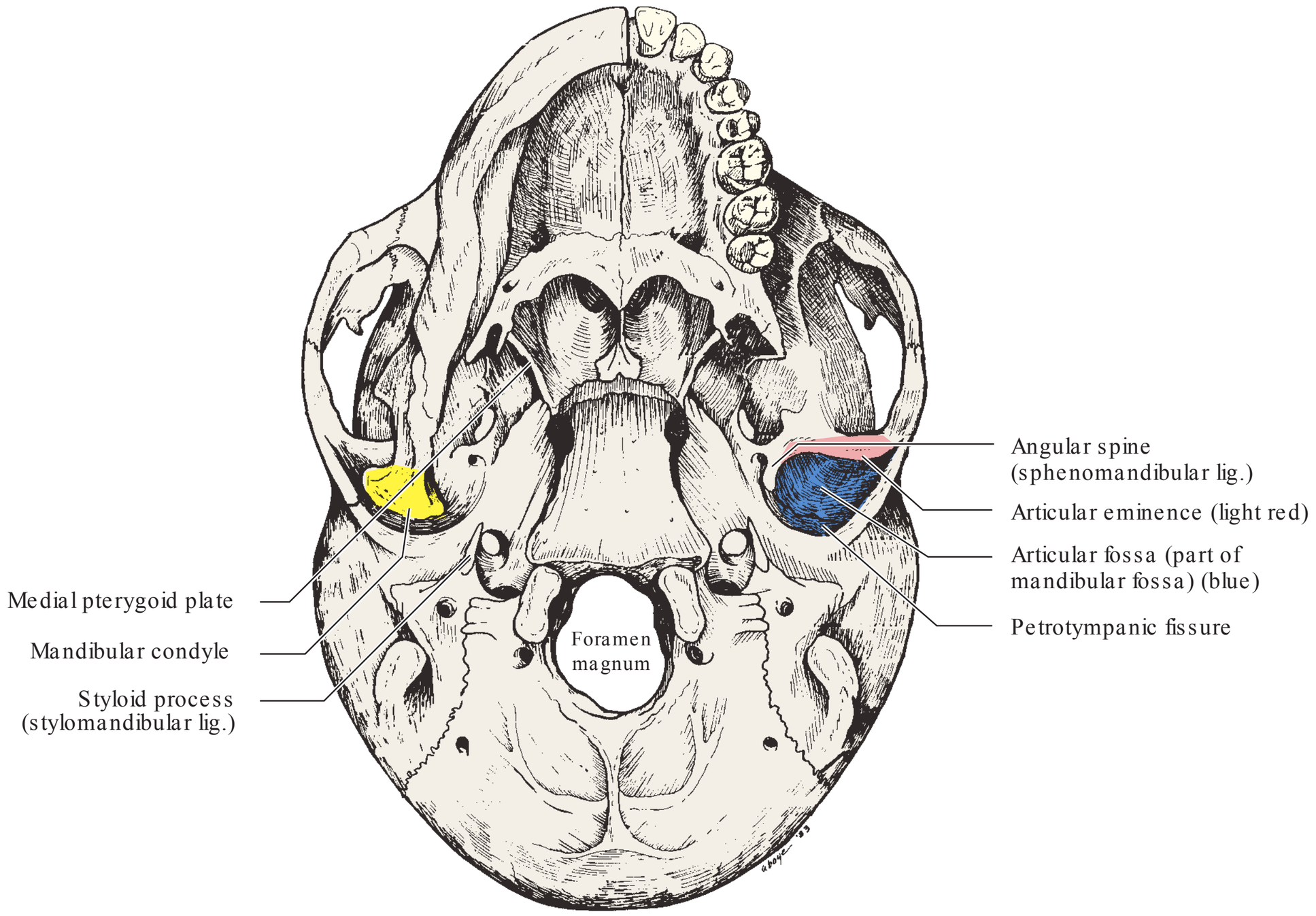

fIGur E 14-20. H**u**man sk**u**ll: inferior surface with half of the mandible removed on the ri**g**ht side of the drawing. On the le**f**t side of the drawing, the cond**y**lar process of the mandible is shaded yellow, and on the ri**g**ht side with the mandible removed, the mandib**u**lar (and artic**u**lar) **f**ossa of the temporal bone is shaded blue, and the more anterior artic**u**lar eminence is shaded light red.

2. a rticular fossa (Nonfunctioning portion) and a rticular Eminence (functioning portion)

Study the right side of Figure 14-20 where half of the mandible has been removed, exposing the maxillary teeth and articular fossa and eminence of the temporal bone. T e **articular (glenoid) fossa** is the portion of the **mandibular fossa** that is anterior to the **petrotympanic ȧssure**. It is considered to be a nonfunctioning portion of the joint because, when the teeth are in tight occlusion, there is no tight contact from the head of the condyle through the disc to the concave part of the articular fossa.

T e **articular eminence** or transverse bony ridge is located just anterior and inferior to the articular fossa (Fig. 14-19). As stated previously, its posterior inferior surface is padded or lined with a thickened layer of fibrous connective tissue, more than the rest of the articular fossa (Fig. 14-21), indicating that this is the functional portion of the joint that take the force when we are chewing food with the mandible in a slightly protruded and/or lateral position. T is is where the anterior superior portion of the mandibular condyle rubs against the eminence, but only indirectly since the articular disc is normally interposed between the two functioning bony elements.

3. a rticular d isc

Examine a skull with the posterior teeth fitting together (in tight occlusion) and study how the mandibular condyle fits loosely into the articular fossa. T e disc is not present in a prepared dry skull because the disc is not bone. T ere should be a visible space between the mandibular condyle and the articular fossa that, in life, was occupied by the disc.

T e **articular disc** (Figs. 14-21 and 14-22) is a tough oval pad of dense fibrous connective tissue acting as a shock absorber between the mandibular condyle and the articular fossa and articular eminence. T e disc surfaces are very smooth. Each disc is thinner in the center than around the edges. T is shape provides one natural wedge anterior to the condyle head and a second wedge posterior to the condyle. Rarely, it may become perforated. T e center of the disc has no blood supply[2]; however, it is richly supplied elsewhere. T e upper surface of the disc is concave anteriorly to conform to the convex articular eminence, and it is convex posteriorly, conforming to the concave shape of the articular fossa that it loosely rests against. T e lower surface of the disc is concave anterior to posterior, thus adapting to the upper surface of the convex mandibular condyle.

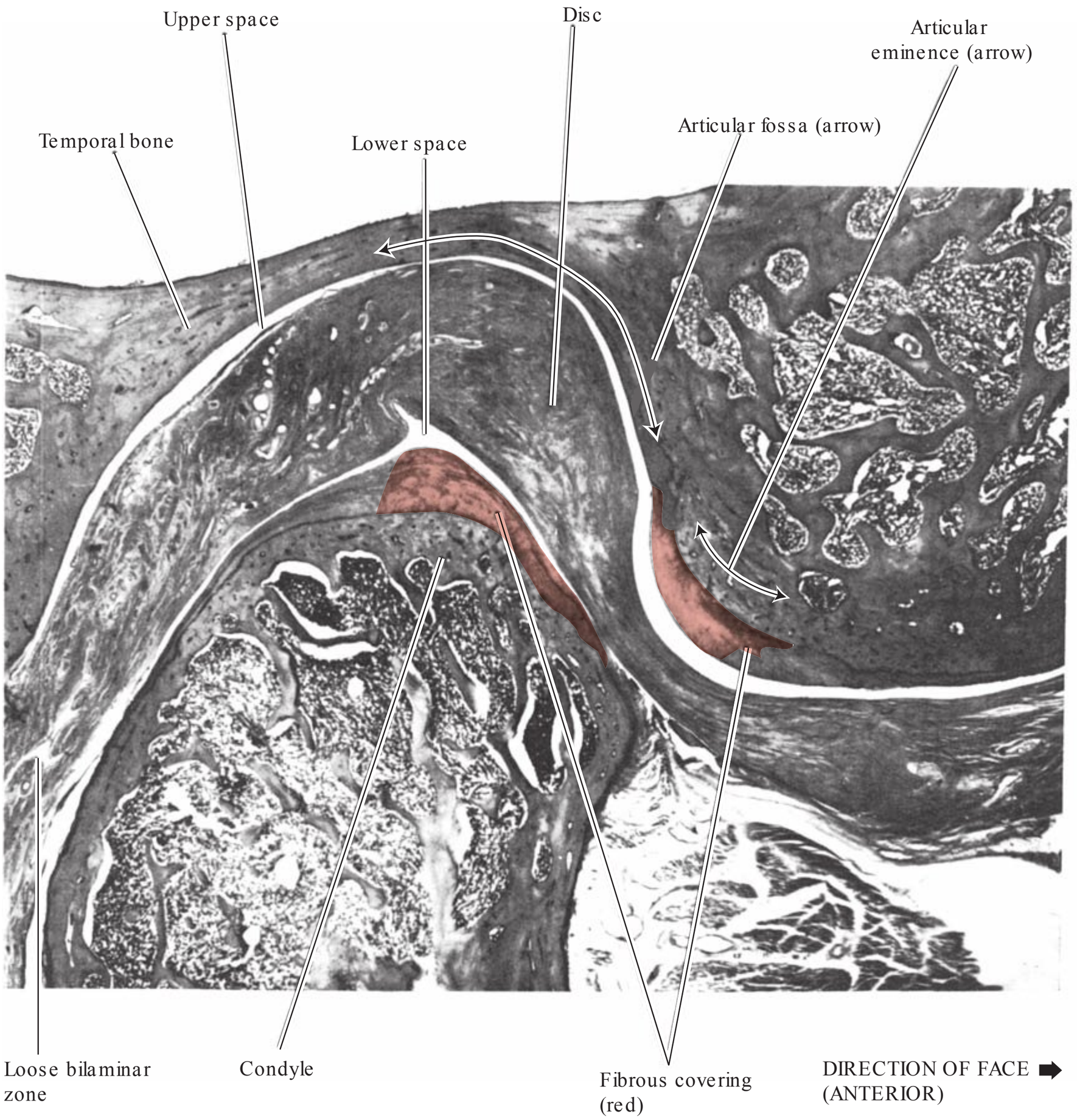

fIGur E 14-21. Temporomandib**u**lar joint, photomicrograph of the lateral aspect. The anterior of the skull (the face) is toward the right of the picture. The white area across the top is the space of the braincase. Notice the thicker **fi**bro**u**s covering (shaded red) and underlying compact bone on the **fu**nctional part of the posterior inferior articular eminence and superior anterior part of the mandibular condyle. Also, notice the arrows indicating the contours of the concave articular fossa, and convex articular eminence, of the temporal bone. (Courtesy of Professor Rudy Melfi.)

As the mandible moves forward, the discs move forward with the mandible due, in part, to the thickened borders of each disc, which conforms to the shape of the condyles, and because the muscles that pull the mandible forward (lateral pterygoids) are attached to the neck of each condyle (in the pterygoid fovea) as well as to the discs. When the thicker peripheral portions of the discs become flattened or the center of the disc thickens, the disc fails to move synchronously with the condyle, resulting in a popping or grating noise (**crepitus**), which is quite an annoying yet a fairly common occurrence. T e frequency of this occurrence is presented in Table 14-1. With an elastic posterior attachment, the disc can move with the head of the condyle during function.

T e articular disc has many functions.[17,18] It divides the space between the head of the condyle and the articulating fossa into upper and lower spaces (**synovial cavities** seen in Fig. 14-22), which permits complex functional movements of the mandible.[18] T e anterior and posterior portions of the disc contain specialized nerve fibers called **proprioceptive** [PRO pri o SEP tiv] **ȧbers**, which help to unconsciously determine the position of the mandible and therefore help regulate movements of the condyle. It stabilizes the condyle by filling the space between incongruous articulating surfaces of the convex condyle and concave–convex articular fossa and articular eminence.[18] T e disc cushions the articulating bones of the joint at the areas of contact (like a shock absorber). T e cushioning and lubrication reduce physical wear and strain on joint surfaces.

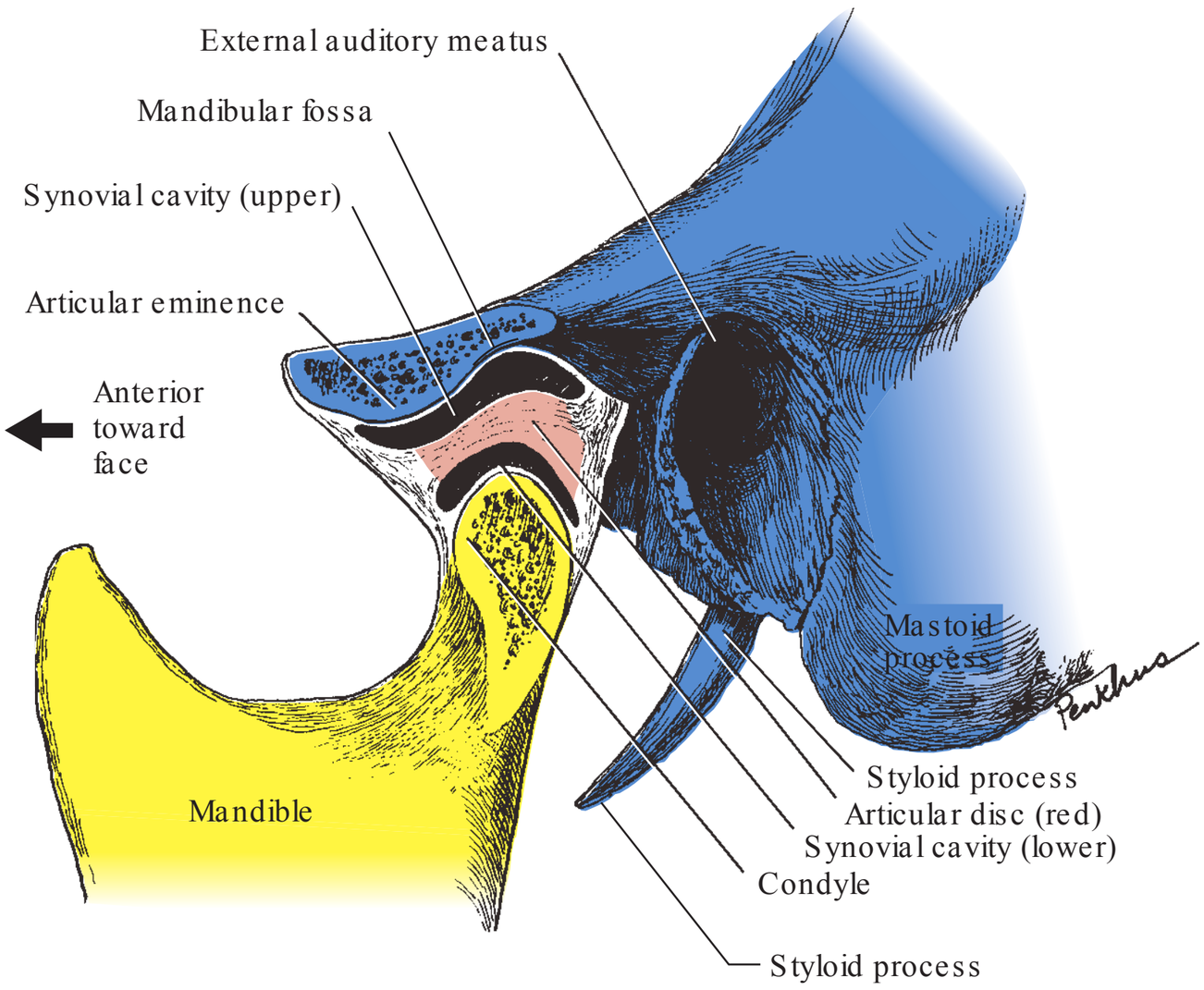

FIGURE 14-22. Temporomandibular joint, sagittal section. The anterior surface of the skull (face) is to the left. The sectioned (blue) temporal bone (with mandibular fossa and articular eminence) forms the superior part of the joint, and the sectioned head of the mandibular condyle (yellow) forms the inferior part. The articular disc is shaded light red. The upper and lower synovial spaces surround the disc. (Reproduced from Clemente CD, ed. Gray's anatomy of the human body. 30th ed. Philadelphia, PA: Lea & Febiger, 1985:340, with permission.)

B. LIGAMENTS THAT SUPPORT THE JOINT AND LIMIT JOINT MOVEMENT

Ligaments are slightly elastic bands of tissue. They do not move the joint; muscles move the joint. They do support and confine the movement of the mandible to protect muscles from being stretched beyond their capabilities.

1. Fibrous Capsule (Capsular Ligament)

The **fibrous** (or **articular**) **capsule** is a fibrous tube of tissue that encloses the joint, best seen laterally in Figure 14-23 and medially in Figure 14-24. It is fairly thin, except laterally, where the thicker **lateral** (formerly temporomandibular) **ligament** is located.[19] The upper border of the capsule is attached to the temporal bone around the circumference of the articular fossa and the articular eminence. The lower border is attached around the neck of the condyloid process, thus enclosing the condyle and completing the tube.

The internal surface of the fibrous capsule is lined with a **synovial membrane** that surrounds the bones and their articulating surfaces. It is thin membrane secretes a fluid, **synovial fluid**, which lubricates the joint. It is fluid is three times more slippery than ice. The synovial fluid both lubricates and nourishes the fibrous covering of the articulating surfaces and center of the disc that lack a blood supply. In a normal joint space, there is only a small amount of fluid (one or two drops).

The articular disc is attached anteriorly to the fibrous capsule, and posteriorly, it is connected by a thick pad of loose elastic, vascular connective tissue called the **bilaminar zone** (Fig. 14-21). Laterally and medially, each disc is tightly attached to the lateral and medial sides of the mandibular condyle but not to the capsule. Therefore, the discs can follow the movement of each condyle when the muscles (lateral pterygoid muscles attached to the necks of the condyles and the discs) move the mandible and discs forward. This design of attachments gives each disc freedom to move anteriorly but limits it from excessive forward movement that could result in its displacement anterior to the head of the condyle.[20] The anterior part of this fibrous capsule prevents excessive movement of the condyle of the mandible on wide openings as it becomes taut.

TABLE 14-1 Prevalence of Crepitus during Maximum Opening[a]

	NONE (%)	BOTH SIDES (%)	RIGHT SIDE (%)	LEFT SIDE (%)	ONE SIDE (R OR L) (%)
594 Dental hygiene students	52.0	13.3	18.2	16.8	35.0
505 Dental students	72.0	4.2	15.9	7.9	23.8
Percentage of all 1099 students	61.2	9.1	17.1	12.7	29.8

[a]Determinations by Dr. Woelfel, 1970–1986. More than 20% of these professional students had or were undergoing orthodontic treatment.

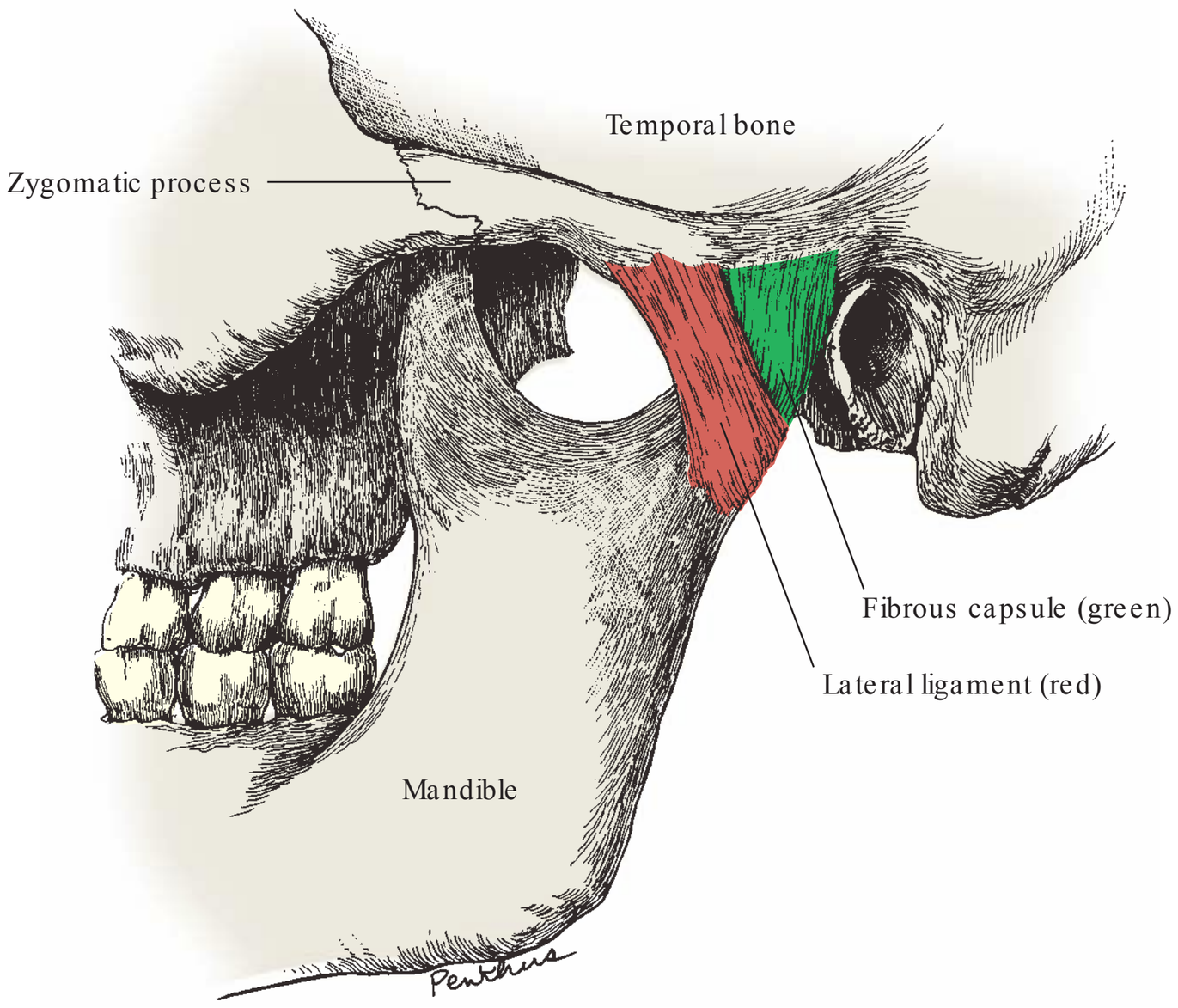

FIGURE 14-23. Fibrous capsule surrounding the TMJ is shaded green, and the thickened outer lateral ligament is shaded red. (Reproduced from Clemente CD, ed. Gray's anatomy of the human body. 30th ed. Philadelphia, PA: Lea & Febiger, 1985:339, with permission.)

2. Lateral ligament (formerly TMJ ligament)

The outer layer of the fibrous capsule is a thicker layer of fibrous tissue that is reinforced by accessory ligaments, which strengthen it. The **lateral ligament** of this joint is the strong reinforcement of the anterior lateral wall of the capsule (Fig. 14-23). It attaches to the zygomatic arch and is directed obliquely down and posterior to the lateral and posterior neck of the condyle. This ligament keeps the condyle close to the fossa and helps to prevent excessive lateral and posterior displacement of the mandible. It has no counterpart medially, and seemingly, none is needed since the right and left temporomandibular articulations work together as a unit. The lateral ligament on the opposite side, by failing to stretch, prevents excess medial displacement on the side moving medially.

3. Stylomandibular ligament

The **stylomandibular** [STY lo man DIB yoo lar] **ligament** is posterior to the joint but also gives support to the mandible (Fig. 14-24). It is relaxed when the mouth is closed but becomes tense on extreme protrusion of the mandible.[19] It is attached above to the styloid process of the temporal bone and below to the posterior border and angle of the mandible.

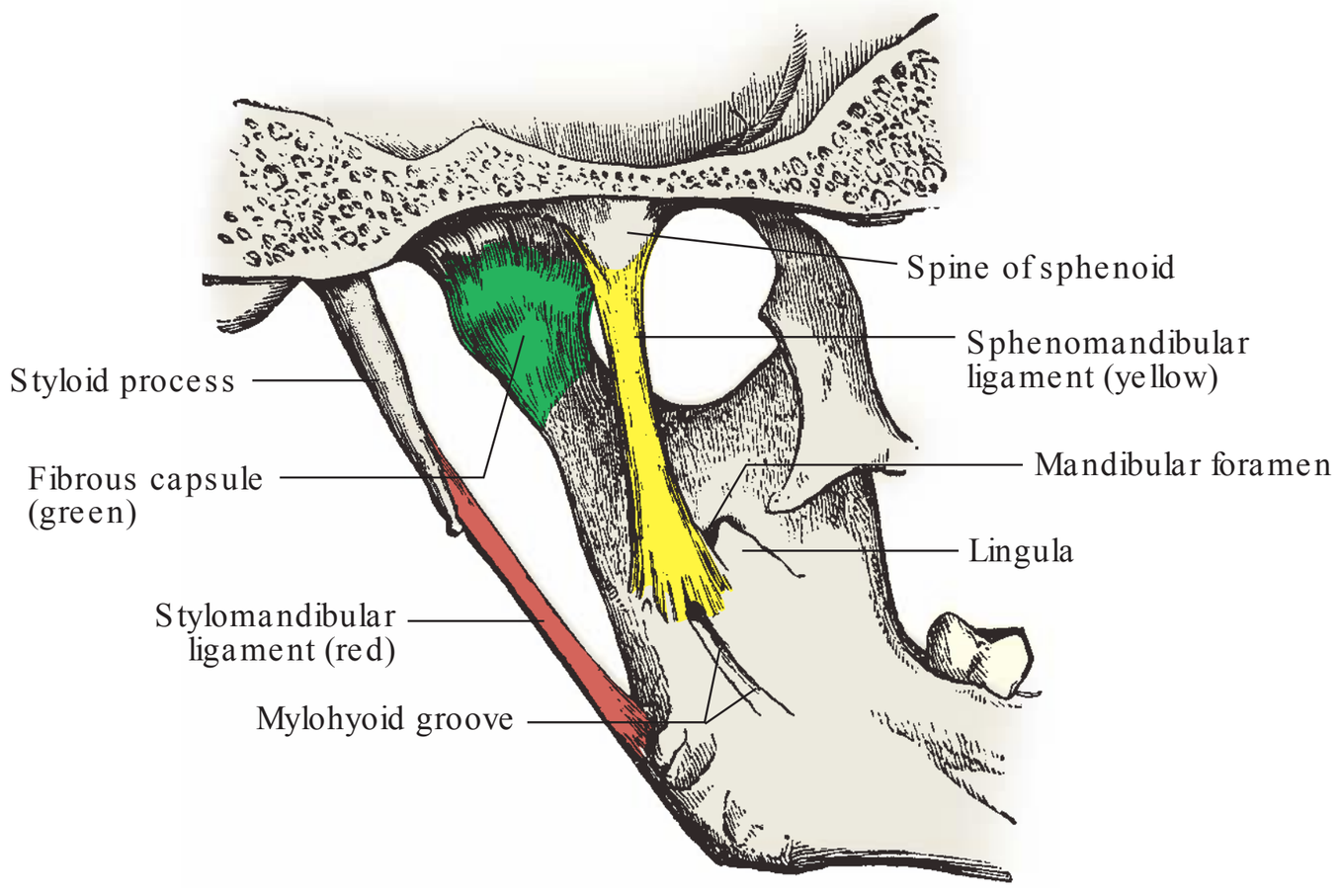

FIGURE 14-24. Ligaments of the temporomandibular joint limit mandibular movement. The fibrous capsule (capsular ligament) shaded green surrounds the joint, the stylomandibular ligament (red) connects the styloid process of the temporal bone to the posterior surface of the mandible near the angle, and the sphenomandibular (or spinomandibular) ligament (yellow) connects the spine of the sphenoid bone with the medial surface of the mandible near the lingula (tongue shaped process) adjacent to the mandibular foramen. (Reproduced from Clemente CD, ed. Gray's anatomy of the human body. 30th ed. Philadelphia, PA: Lea & Febiger, 1985:339, with permission.)

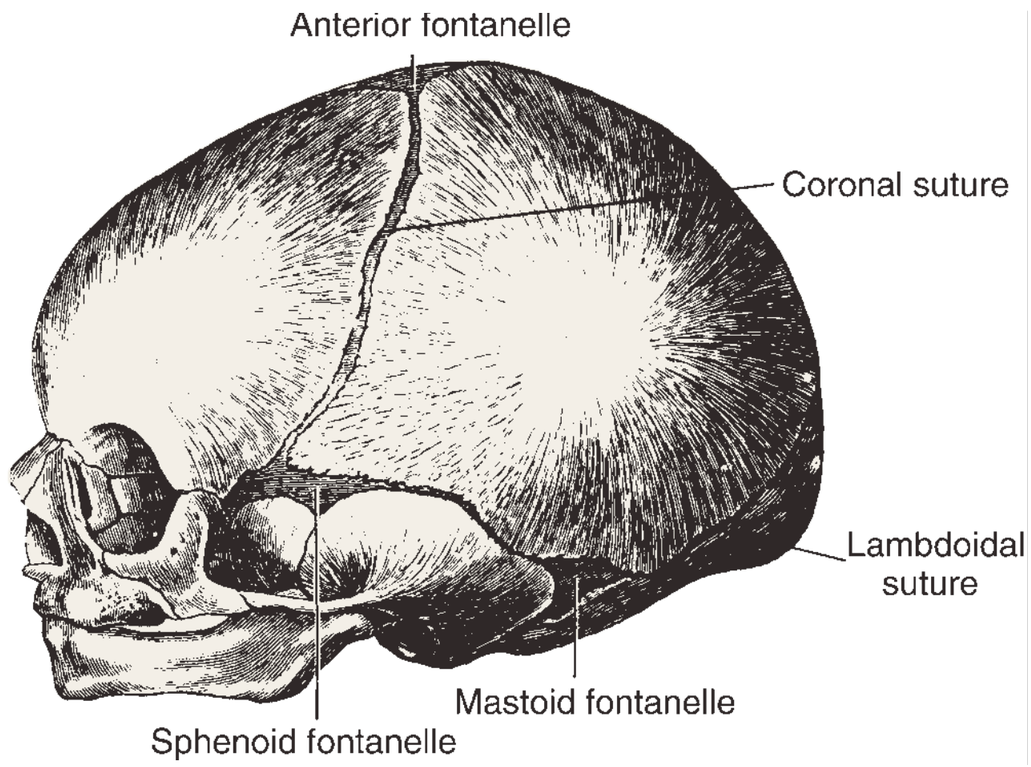

FIGURE 14-25. Skull at birth shows fontanelles (membrane-covered openings between bones). Notice that the mandibular condyle is barely higher than the crest of the mandibular ridge.

4. Sphenomandibular ligament

The **sphenomandibular** [SFE no man DIB yoo lar] **ligament** is medial to the joint (Fig. 14-24). It gives some support to the mandible and may help limit maximum opening of the jaw. It is attached superiorly to the angular (sphenoidal) spine of the sphenoid bone and fans out inferiorly to attach on the lingula of the mandible near the mandibular foramen.

C. Development of the Temporomandibular Joint

In infants, the articular fossa, the articular eminence, and the condyle are rather flat. This flatness allows for a wide range of sliding motions in the TMJ. Also, this joint is at about the same level as the occlusal plane at birth with relatively no ramus height (Fig. 14-25). During growth, the articular fossa deepens, the articular eminence becomes prominent, the condyle becomes rounded, and the shape of the disc changes to conform to the change in shape of the fossa and condyle. There is also a lengthening of the ramus. The condyle contains cartilage beneath its surface, and the condyloid process and ramus lengthen until a person is 20 to 25 years old. As a result of growth in the condyle area, the body of the mandible is lowered from the skull, and the occlusal plane is located about 1 in. below the level of the condyles in an adult.

d. Advanced Topics: Dimensions Related to the TMJ

The average width of the condyle and its depth beneath the skin is illustrated in Figure 14-26. The condyle is a large solid structure, about 10 mm thick anteroposteriorly and 20.4 mm wide mediolaterally. Although the average depth of the outer surface of the condyle is 15 mm beneath the skin, it is readily palpated, and its movements are visible (seemingly just

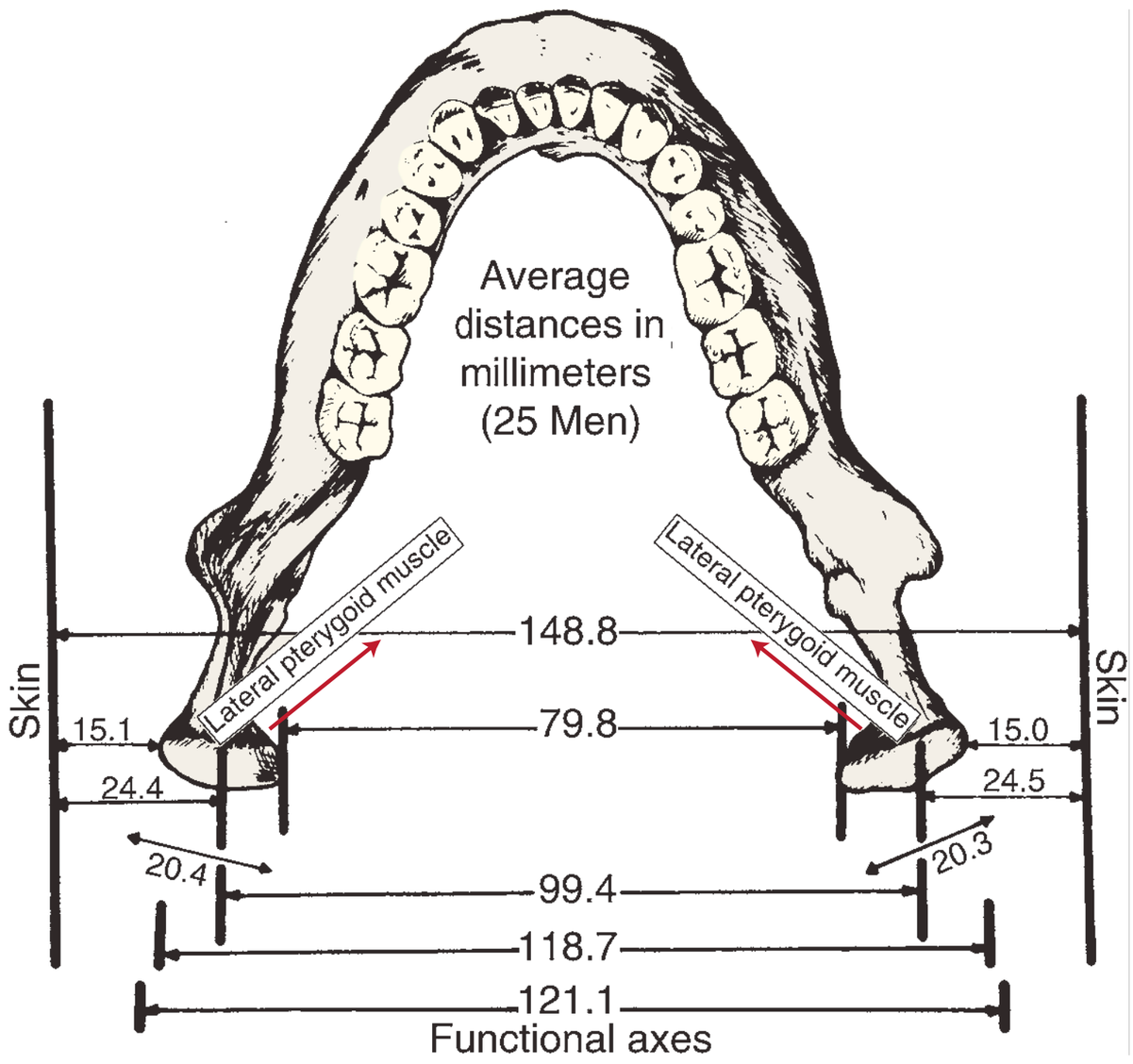

FIGURE 14-26. Depth (beneath the skin) of the landmarks of the head of the mandibular condyle and relative direction of the lateral pterygoid muscle fibers (red arrows) from the insertion on the neck of the condyle toward the origin (not seen, but on the lateral surface of the lateral plate of the sphenoid bone). (To obtain these measurements, metal markers were placed on the skin and some teeth on 25 men prior to taking submental vertex cephalometric radiographs for analysis, tracing, and measuring. The location of the center of rotational opening of the mandible [the hinge axis] was found to pass through or near the center of the heads of the condyles. The functional axes were determined from pantographic recordings. Resultant articular settings were found to be wider than the outer poles of the condyles. This means that lateral and protrusive excursions are controlled by ligaments and muscles, rather than by bone, as previously reported. This research was conducted by Drs. Woelfel and Igarashi and supported by the Ohio State University College of Dentistry and Nihon University School of Dentistry in Tokyo.)

beneath the skin) when eating. Research by Drs. Woelfel and Igarashi on 25 men found the average depth of the outer surface of the mandibular condyle on each side to be 15.0 mm; the range was 10.3 to 21.4 mm beneath skin.

T e size of the mandibular fossa averages about 23 mm mediolaterally and extends 15 mm posteriorly from the eminence. T e intracapsular surface area is two to three times greater than on the very mobile mandibular condyle. T e anterior part of the capsule that surrounds the entire mandibular fossa and articular eminence attaches 10 mm in front of the crest of the articulating eminence.[17]

LEARNINg ExERCISE

1. Study a skull and see how the mandibular condyle fits into the mandibular fossa. When you examine the fit, notice the space between the mandibular condyles and the articular fossae when the posterior teeth are in tight occlusion. This space is where the disc would have been in life.

   On yourself, palpate the TMJ and feel the movement of the mandibular condyle. First, put your index fingers immediately in front of either ear opening and open and close your mouth. Notice that when you open and close the mandible just a little, you feel little movement of the condyles, whereas when you open the mandible wide, you feel more movement. This happens because during minimal opening, the condyles only rotate within the articular fossa, but when we open wide, the entire mandible moves bodily (translates) forward and downward as the condyles are pulled forward over the articular eminence. Next, move your jaw to the right and left sides. You are feeling the movement of the outer (lateral) surface of each mandibular condyle. Finally, place your little finger gently inside either ear opening, and then, open and close your mouth and pull your jaw back or posteriorly. You are feeling the upper and posterior portion of the mandibular condyle, especially when you close or retrude (pull back) your mandible.
2. Search on your computer for a video on "TMJ Examination" that is less than 5 minutes long. Observe the techniques used to identify problems with the joint.
3. Search on your computer for a video on "Normal TMJ and disc function" that is less than 5 minutes long. As you watch, identify all terms that you learned in this chapter.

r EvIEw Qu estions

Select the one best answer.

1. What two structures articulate with the disc in the TMJ?
   a. T e coronoid process of the mandible and the mandibular fossa of the temporal bone
   b. T e condyloid process of the mandible and the mandibular fossa of the temporal bone
   c. T e coronoid process of the mandible and the mandibular fossa of the sphenoid bone
   d. T e condyloid process of the mandible and the mandibular fossa of the sphenoid bone
   e. T e condyloid process of the mandible and the mandibular fossa of the maxillae
2. T e ligament that limits the amount of movement of the mandible and attaches from the inferior surface of the neurocranium to the lingula of the mandible is the
   a. Lateral (TMJ) ligament.
   b. Stylomandibular ligament.
   c. Sphenomandibular ligament.
   d. Sternocleidomastoid ligament.
3. Where on the temporal bone does the mandible function?
   a. In the anterior three quarters of the mandibular fossa called the articular fossa
   b. In the posterior quarter of the mandibular fossa called the articular fossa
   c. On the posterior inferior portion of the articular eminence
   d. On the anterior inferior position of the articular eminence

c–3; c–2; b–1: Sr E wS Na

SECTION III muSCl ES Of Th E mOu Th

Objectives

The objectives for this section are to prepare the reader to perform the following:

- Identify the four pairs of major muscles of mastication.
- Describe and identify the origin and insertion of each of these muscles of mastication on a skull and be able to palpate each (if possible) on yourself or a partner.
- Describe and demonstrate the function of each of these muscles.
- List other factors that contribute to the position of teeth and movement of the mandible.
- Describe the location and list the functions of the groups of muscles that contribute to facial expression.

T e following general terms relate to muscles and will be helpful to know as you read this section:

Anguli [AN gyoo lie]: triangular area or angle of a structure
Depressor: acts to depress or make lower
Insertion (of a muscle of mastication): place of attachment of muscles to the bone that moves, such as muscle attachments on the movable mandible
Labial [LAY bee al]: related to, or toward, the lips; like the labial surface of a tooth
Levator [le VA tor]: acts to raise (compare elevator)
Lingual [LIN gwal]: related to the tongue; for example, the lingual nerve innervates the tongue; the lingual muscle is within the tongue; and the lingual surface of a tooth is the side toward the tongue.
Mental: referring to the chin; the mental foramen is the hole in the mandible where the mental nerve passes out of the mandible to the chin; the mentalis muscle inserts into the chin.[1]
Orbicularis [or BIK u lar is]: round; compare an orbit
Origin (of a m uscle of mastication): is the source, beginning, or fixed proximal end attachment of a muscle as compared to its insertion, which is a muscle's more movable attachment or distal end.[1]
Oris: referring to the edge of the mouth; compare oral
Procerus [pro SE rus]: long and slender

a. muSCl ES INvOlvEd IN maSTICaTION (Ch EwING)

Muscles of mastication or chewing move the mandible. T ey include four pairs of muscles (right and left): masseter, temporalis, medial pterygoid, and lateral pterygoid muscles. T ese muscles have the major control over the movements of the mandible. Each of these muscles has one end identified as its origin and the other end identified as its insertion. T e **origin end** of each of the muscles of mastication is the source, beginning, or fixed proximal attachment located, in this case, on the bones of the neurocranium that are relatively immovable. T e **insertion end** is the attachment on the movable bone that for each of these muscles is attached to, and moves, the mandible.

T ere are five different ways in which the mandible moves. We can **elevate** the mandible (closing the mouth), **depress** it (opening the mouth), **retrude** it (retracting or pulling back the mandible), **protrude** it (protracting or moving the mandible anteriorly), and move it into **lateral excursions** (moving the mandible sideways, as when chewing).

1. masseter muscle

T e **masseter** [ma SEE ter] **muscle** (Fig. 14-27) is the most superficial, bulky, and powerful of the muscles of mastication. It is four sided in shape.

Origin: T e masseter arises from the inferior and medial surfaces of the zygomatic arch that is made up of the zygomatic bone, the zygomatic process of the maxillae, and the temporal process of zygomatic bone (seen in Fig. 14-28). From here, it extends inferiorly and posteriorly toward its insertion.
Insertion: T e masseter inserts on the inferior lateral surface of the ramus and angle of the mandible (Fig. 14-28).
Action: It **elevates** the mandible (closes the mouth) and applies great power in crushing food.[13,15,16]

LEARNINg ExERCISE

As you clench your teeth several times, feel the contraction of the masseter by placing a finger on the outside of your cheek posterior to the third molar region. The muscle will produce a noticeable bulge beneath your finger each time. The part felt just inferior to the cheekbone (anterior to the earlobe) is near the origin, and the bulge felt over the angle of the mandible is near the insertion.

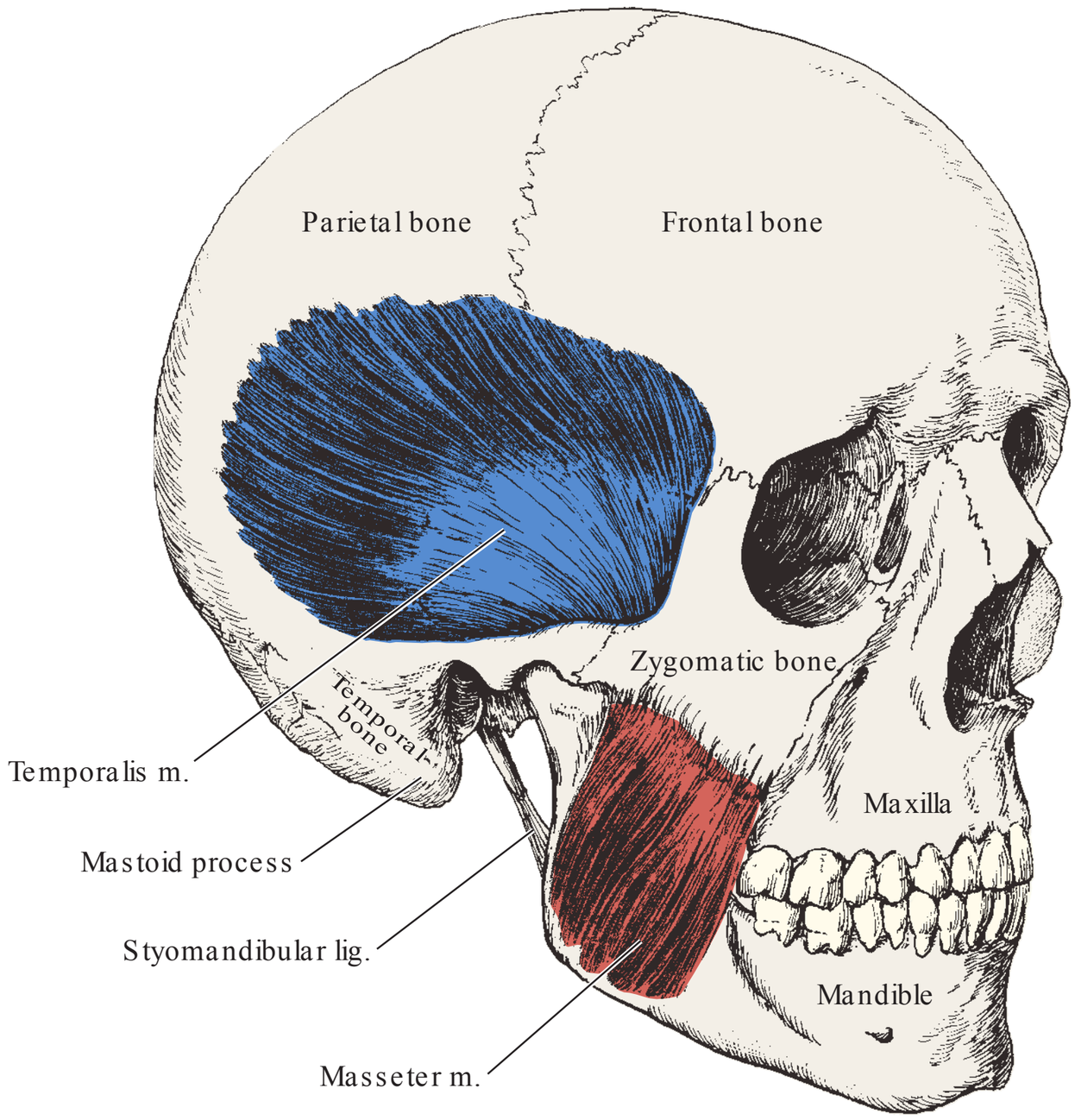

fIGur E 14-27. Masseter m**u**scle (shaded red) and fan-shaped temporalis m**u**scle (shaded blue). (Reproduced from Clemente CD, ed. Gray's anatomy of the human body. 30th ed. Philadelphia, PA: Lea & Febiger, 1985:450, with permission.)

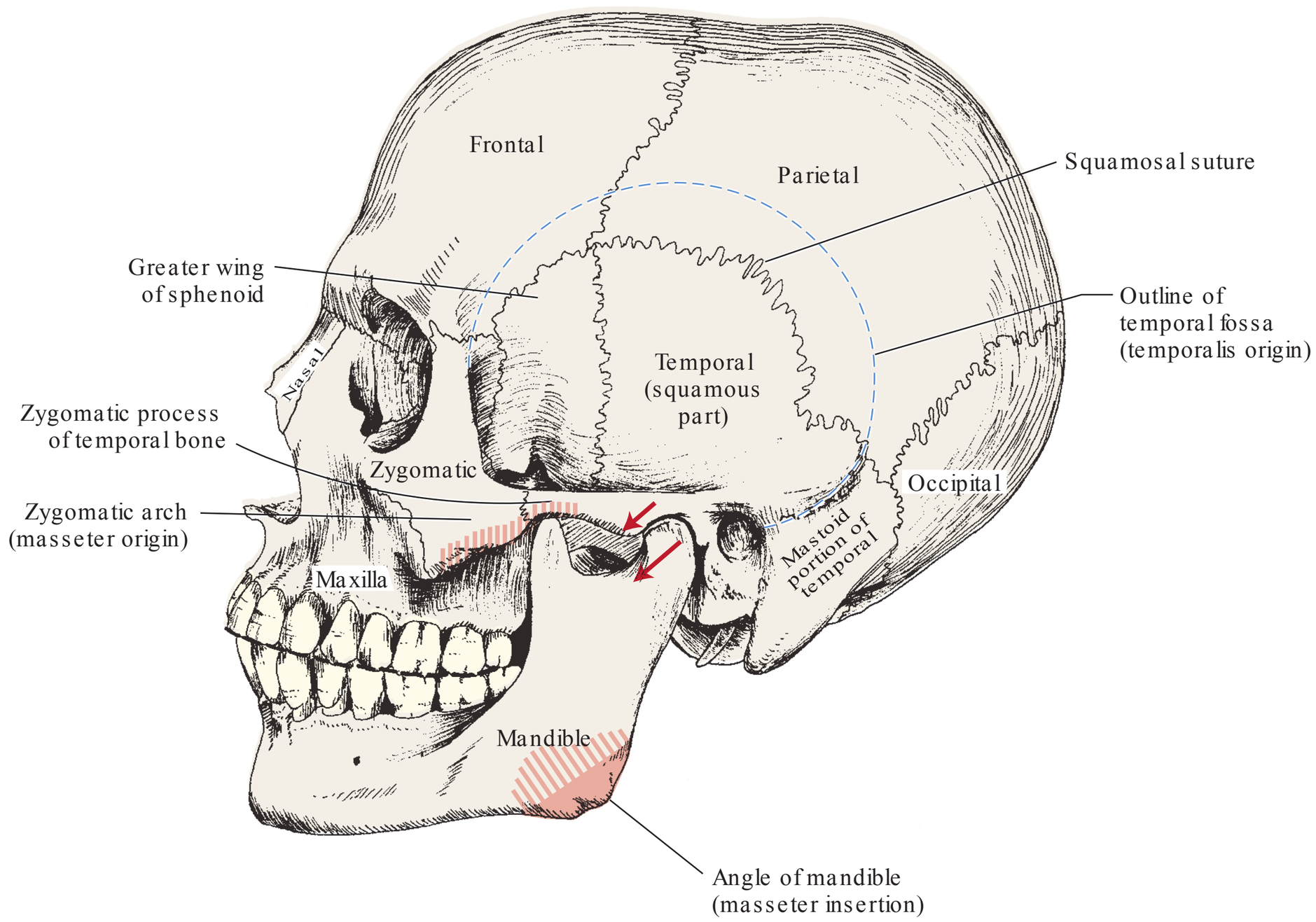

fIGur E 14-28. H**u**man sk**u**ll, le**f**t side, showing m**u**scle attachments. This lateral view shows the ori**g**in of the fan-shaped temporalis m**u**scle (within the shallow temporal fossa outlined with a blue dotted line) and the ori**g**in of the masseter (light red area on the zygomatic arch) as well as the insertion of the masseter muscle (light red area on the lateral surface of the angle of the mandible). The red arrows indicate the slope of the posterior surface of the articular eminence and the subsequent downward (opening) movement of the mandible when it is pulled forward by both lateral pterygoid muscles.

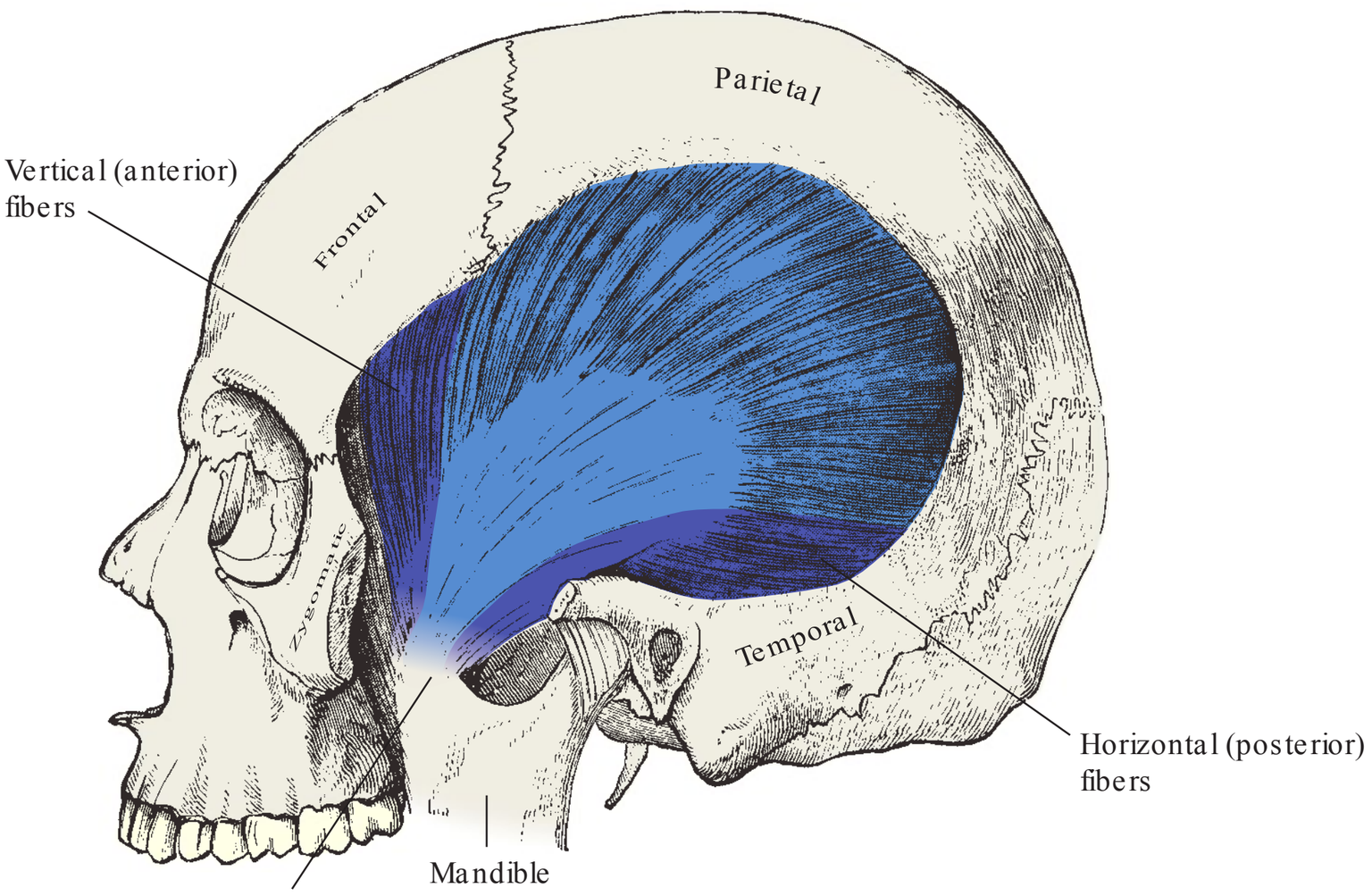

fIGur E 14-29. Temporalis m**u**scle (blue and purple). The zygomatic process of the temporal bone and temporal process of the zygomatic bone have been removed. When studying this drawing, you should understand why the contraction of the anterior vertical **fi**bers (purple) of the temporal muscle acts to close the jaw while contraction of the posteriorl**y** horizontal **fi**bers (purple) acts to pull the jaw back or to retract (retrude) the mandible. (Reproduced from Clemente CD, ed. Gray's anatomy of the human body. 30th ed. Philadelphia, PA: Lea & Febiger, 1985:449, with permission.)

2. Temporalis muscle

T e **temporalis** [tem po RA lis] **muscle** is a fan-shaped, large but flat muscle with both vertical anterior (and middle) fibers and more horizontal posterior fibers. Vertical and horizontal fibers are shaded darker in Figure 14-29.

Origin: T e temporalis arises from the entire temporal fossa (Fig. 14-28) (composed of the squamous part of temporal bone, the greater wing of the sphenoid bone, and the adjacent portions of the frontal and parietal bones). From here, its **anterior** (and middle) **ȧbers** are directed vertically downward while its **posterior ȧbers** are directed more horizontally, mostly anteriorly and somewhat inferiorly, passing medial to the zygomatic arch.

Insertion: T e temporalis inserts on the coronoid process of the mandible, the medial surface of the anterior border of the ramus, and the temporal crest of the mandible (Fig. 14-30) via one common tendon.

Action: T e anterior (and middle) vertical fibers contract to act to **elevate** the mandible (close the jaw) especially when great power is not required, and the

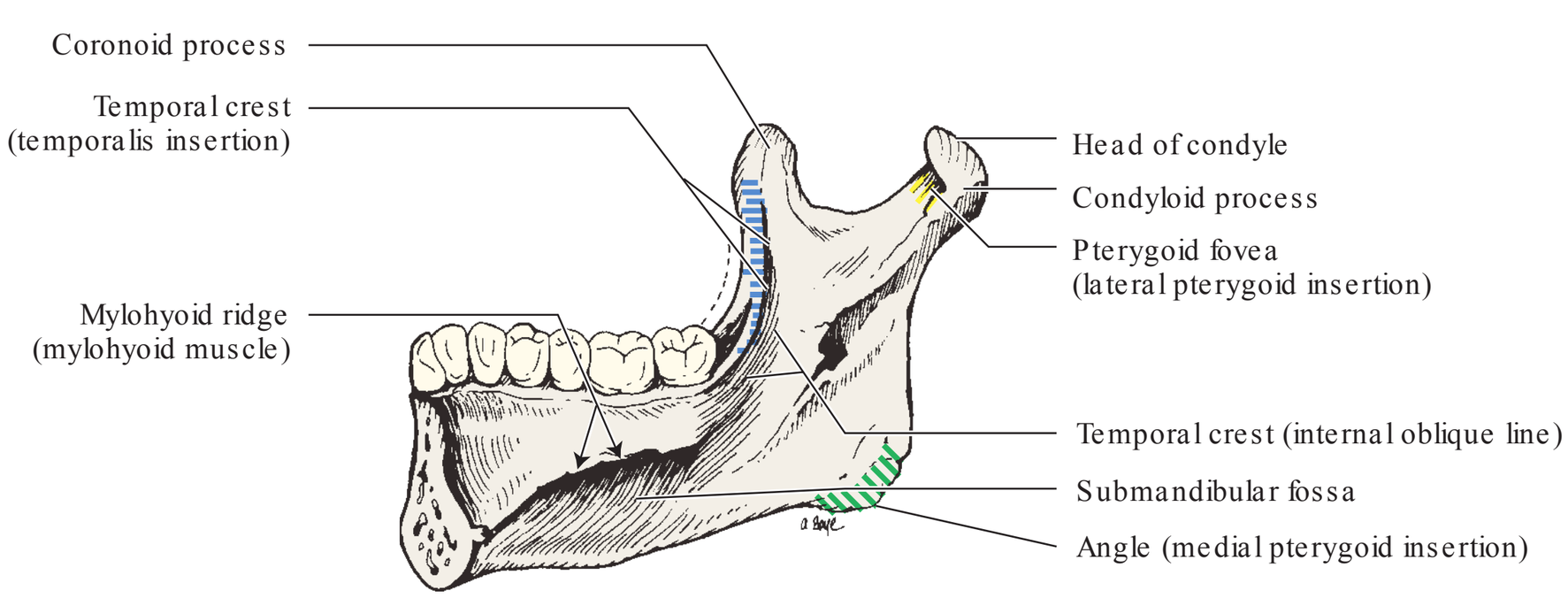

fIGur E 14-30. Mandible, medial surface, with the location of the m**u**scle insertions of the temporalis, medial pterygoid, and lateral pterygoid muscles. The insertion of the temporalis m**u**scle (blue) is located on the anterior medial ridge (temporal crest) of the mandibular ramus. The insertion of the medial pter**yg**oid m**u**scle (green) is on the internal surface of the angle of the mandible. The insertion of the lateral pter**yg**oid m**u**scle (yellow) is on the anterior surface of the neck of the condyle in the pterygoid fovea (as well as the articular disc, which is not shown).

posterior horizontal fibers **retrude** or pull the mandible posteriorly.[13,15,16] T is muscle can position the mandible slightly more anteriorly or more posteriorly while also closing the teeth together.

LEARNINg ExERCISE

Feel contraction of the origin of the temporalis by placing several fingers above and in front of your ear to feel the vertical fibers contract as you firmly close your teeth together several times. Then, feel the nearly horizontal fibers just above and behind your ears contract as you retrude or pull your mandible posteriorly. This may be more difficult to feel since the bulge is less evident.

3. medial pterygoid muscle

T e **medial pterygoid** [TER i goid] **muscle** is located on the medial surface of the ramus (Figs. 14-31 and 14-32).

Origin: T e medial pterygoid muscle arises mainly from the medial surface of the lateral pterygoid plate and the pterygoid fossa between the medial and lateral pterygoid plates (Fig. 14-33) of the sphenoid bone. (Also, there are fibers attached to the posterior surface of the maxilla and to the adjacent vertical processes of the palatine bones and to the maxillary tuberosity.[10]) Similar to the masseter, the fibers pass from their origin inferiorly and posteriorly (but laterally) toward their insertion.

Insertion: T e medial pterygoid muscle inserts on the medial surface of the mandible in a triangular region at the angle and on the adjacent portions of the ramus just above the angle (Fig. 14-30). Along with the masseter located on the lateral surface, these two muscles serve as a sling with the medial pterygoid attached on the medial side and the masseter attached on the lateral side of the angle of the mandible. T ey have similar actions.

Action: It **elevates** the mandible (closes jaw) like the masseter and the anterior (and middle) fibers of the temporalis muscles. Although not as large or powerful, it works together with the larger masseter muscle in helping to apply the power or great force upon closing the teeth together.

LEARNINg ExERCISE

Attempt to palpate the insertion of the medial pterygoid muscle in your mouth by bending the head forward to relax the skin on the neck and placing the forefinger medial to the internal angle of the mandible while gently pressing your finger upward and outward. When the teeth are squeezed together, you should feel the bulge of this muscle.

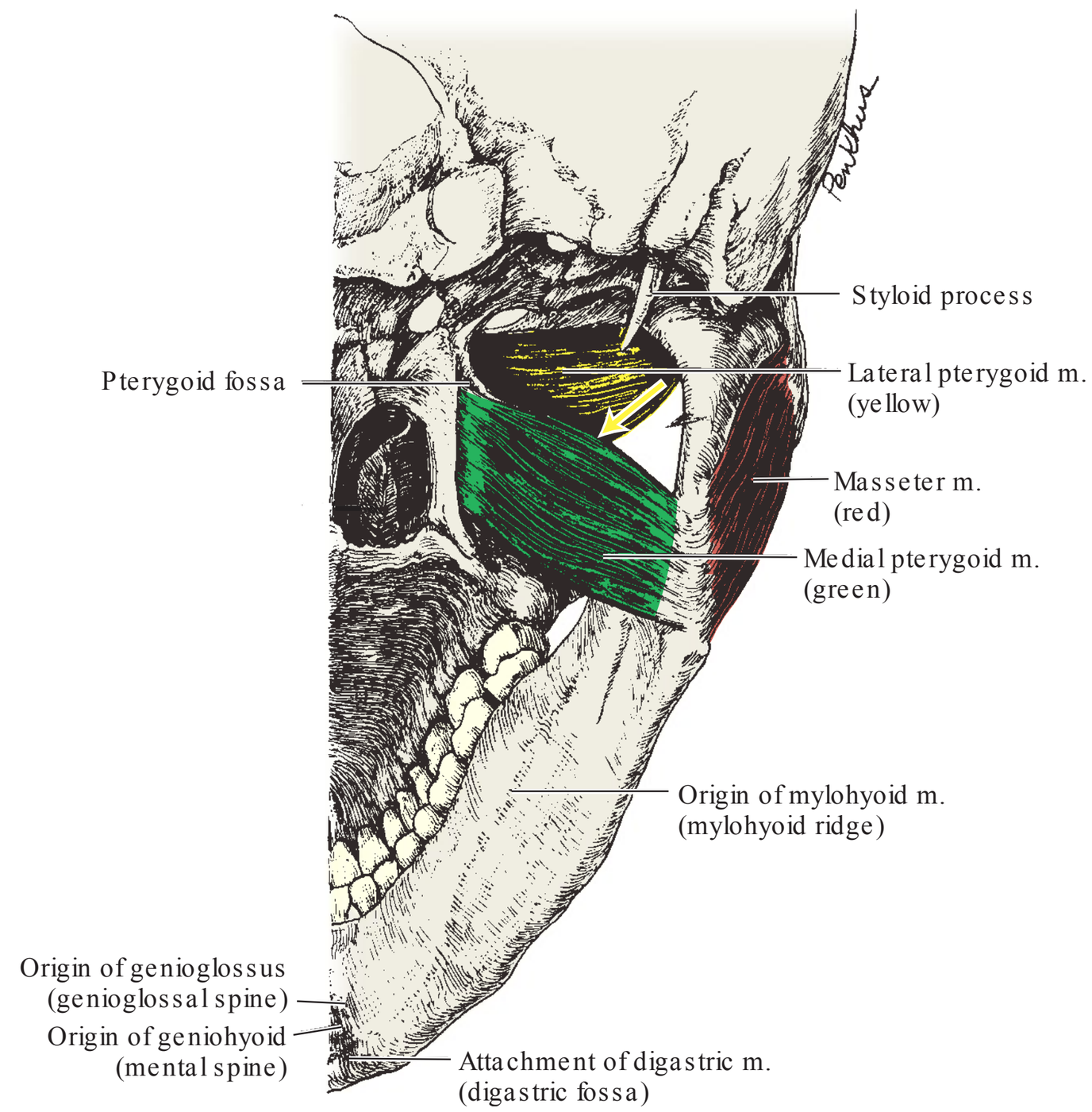

fIGur E 14-31. The sk**u**ll **f**rom the in**f**erior view. The medial pter**yg**oid m**u**scle (shaded green) and masseter m**u**scles (red) form a sling that supports the mandible. Also, from this view, it is clear that the lateral pter**yg**oid m**u**scle (yellow) has its origin (on the base of the cranium) more medial than its insertion (on the anterior portion of the neck of the condyle and the articular disc). If this muscle contracts only on the right side as shown by the arrow, that condyle of the mandible moves toward its origin, thus bodily moving the mandible toward the left or opposite side. (Reproduced from Clemente CD, ed. Gray's anatomy of the human body. 30th ed. Philadelphia, PA: Lea & Febiger, 1985:452, with permission.)

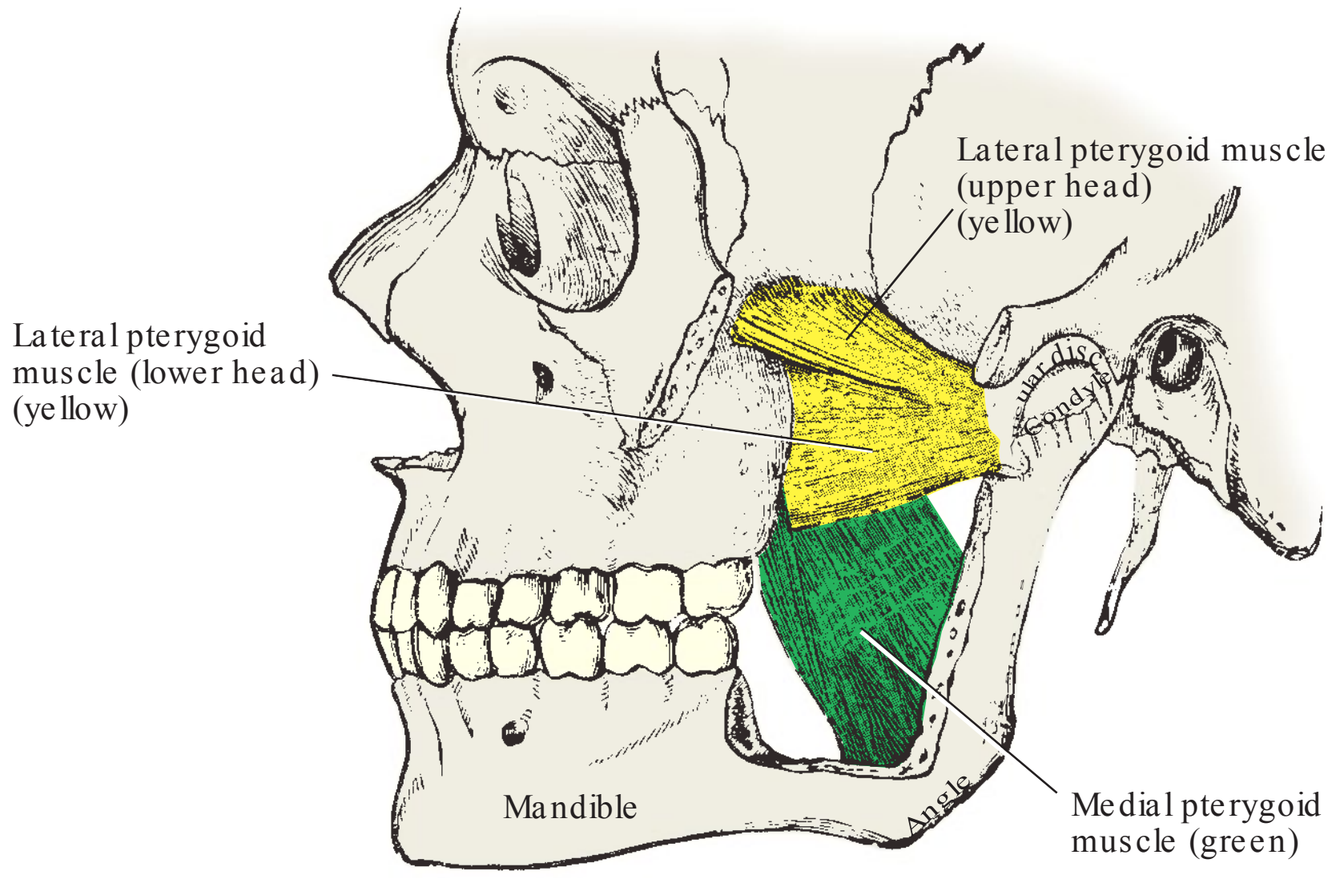

FIGURE 14-32. A lateral view of two heads of the lateral pterygoid muscle (shaded yellow) and the medial pterygoid muscle (shaded green) with the zygomatic arch and the anterior part of the ramus removed. The upper head of the lateral pterygoid muscle has its origin on the infratemporal surface of the sphenoid bone, and the lower head has its origin on the lateral surface of the lateral pterygoid plate of the sphenoid bone (covered by the muscle in this drawing). The insertion of both heads of the lateral pterygoid muscle is on the fovea of the neck of the condyle of the mandible and on the articular disc. Notice the horizontal orientation of the lateral pterygoid fibers in direct contrast to the vertical direction of the medial pterygoid fibers. Simultaneous contraction of both lateral pterygoid muscles guides the condyles (and discs) forward, which causes the mandible to protrude and the mouth to open. Contraction of the medial pterygoid muscle in harmony with the masseter elevates the mandible (closes the mouth). (Reproduced from Clemente CD, ed. Gray's anatomy of the human body. 30th ed. Philadelphia, PA: Lea & Febiger, 1985:451, with permission.)

4. Lateral pterygoid muscle

The **lateral pterygoid muscle**, unlike the other three pairs of muscles where most fibers are oriented mostly vertically, has its fibers aligned mostly horizontally (Fig. 14-32). The lateral pterygoid muscle is a short, thick, somewhat conical muscle located deep in the infratemporal fossa (inferior to the temporal bone and posterior to the maxillae) and is the prime mover of the mandible except for closing the jaw.

Origin: The lateral pterygoid muscle has two parts (two heads), both attached to the sphenoid bone. The smaller superior head is attached to the infratemporal surface of the greater wing of the sphenoid bone; the larger inferior head is attached to the adjacent lateral surface of the lateral pterygoid plate on the sphenoid bone (Figs. 14-32 and 14-34). Fibers pass posteriorly and laterally in a horizontal direction toward their insertion. When viewed from below, the direction of these fibers from their insertion on the anterior surfaces of the mandibular condyles is represented by the arrow in Figure 14-33.

Insertion: The lateral pterygoid muscle inserts on the depression on the front of the neck of the condyloid process called the pterygoid fovea (Figs. 14-30 and 14-32) and into the anterior margin of the articular disc. Contractions of the upper head pull the disc forward working in concert with the stretching of the elastic band of tissues behind the disc (retrodiscal tissues) and permit the disc to accompany the mandible as it moves forward, preventing posterior displacement of the disc.[20]

Actions: When both lateral pterygoids contract simultaneously, the action is:

- To **protrude** the mandible. No other muscle or groups of muscles are capable of doing this but can only assist in this action as stabilizers or by controlling the degree of jaw opening during the protrusion.[12,13,15,16,21]
- To **depress** the mandible. The lateral pterygoids do this by pulling the articular discs and the condyles forward and down onto the articular eminences, which moves the mandible inferiorly and helps rotate it, thereby opening the mouth (illustrated by arrows in Figure 14-28 that indicate the incline of the articular eminence and the same downward direction that condyles and the mandible take when pulled forward under the bump of the eminence). The lateral pterygoids are assisted somewhat in this task by two groups of muscles in the neck: the suprahyoid muscles and the infrahyoid muscles.

When only one lateral pterygoid contracts, it pulls the condyle on that side toward the midline (medially) and anteriorly, moving the body of the mandible and its teeth toward the opposite side (since the origin of the lateral pterygoid muscle is medial to its insertion as seen by the arrow in Fig. 14-33). For example, contraction of the right lateral pterygoid muscle draws the right condyle medially (to the left) and forward, causing the mandible to move toward the left side (into **left lateral excursion**). Conversely, the contraction of the left lateral pterygoid muscle causes the mandible to move to the right side (**right lateral excursion**).[15] No other muscle is capable of moving the mandible sideways, although synergistic (in harmony with) unilateral contraction of the posterior fibers of the temporalis muscle occurs on the side toward which the jaw moves.[15]

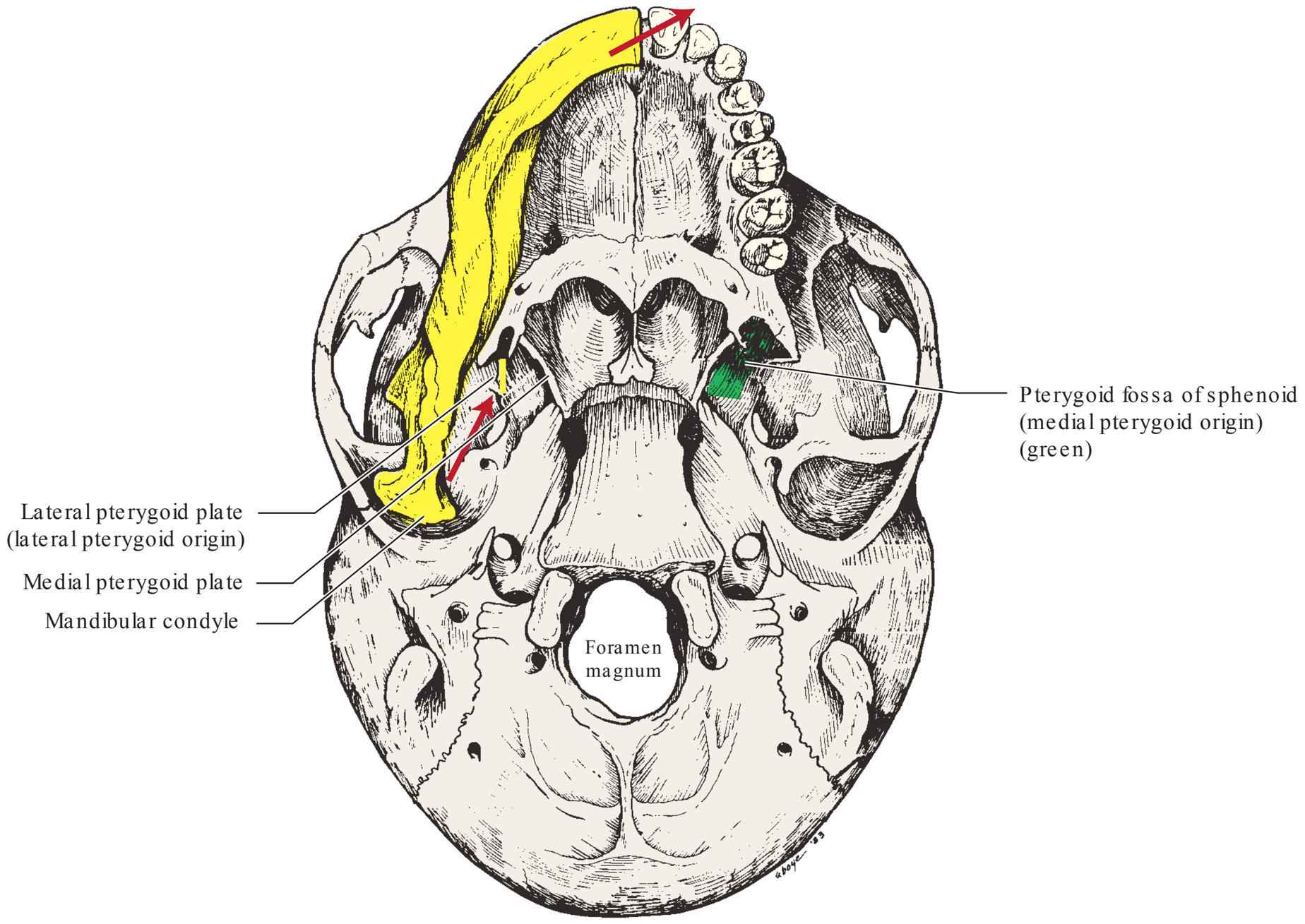

fIGur E 14-33. H**u**man sk**u**ll, in**f**erior s**ur**face. As you study this drawing, notice the arrow that connects the insertion of the lateral pterygoid muscle (on the anterior neck o**f** the cond**y**le o**f** the mandible) with its origin (on the lateral s**ur**face o**f** the lateral pter**yg**oid plate denoted by a yellow line). When only one lateral pterygoid muscle contracts and pulls the insertion end toward its origin, the mandible moves medially, toward the opposite side, as shown by the second arrow near the anterior part of the mandible. The location of the origin of the medial pter**yg**oid m**u**scle is shaded green on the right side of the drawing in the pterygoid fossa.

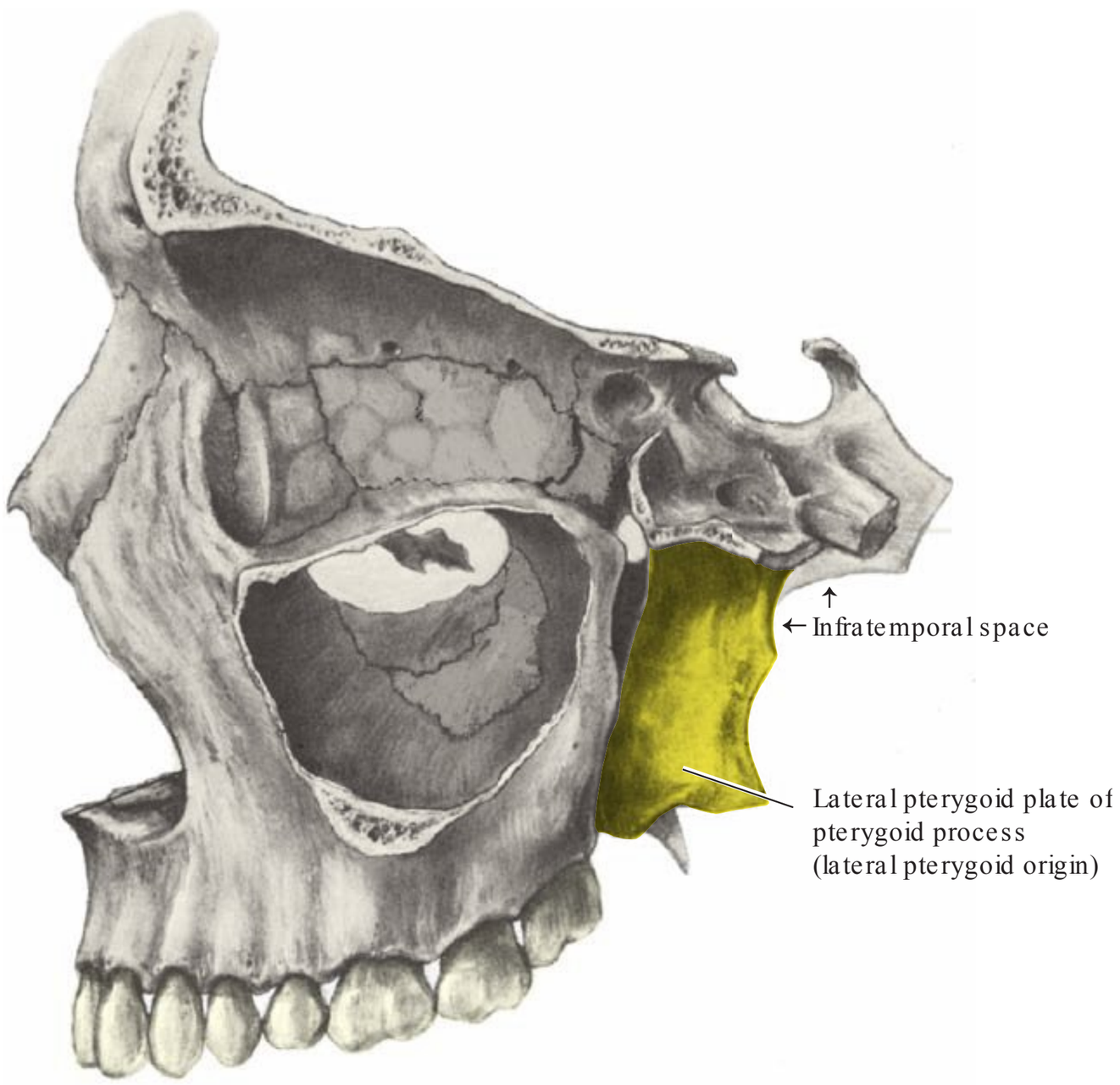

fIGur E 14-34. Part o**f** h**u**man sk**u**ll, lateral view, has the lateral wall of the maxilla removed to expose the maxillary sinus. Posterior to the maxilla, note the location of the origin of the two heads of the lateral pter**yg**oid m**u**scle: the lateral surface of the lateral pter**yg**oid plate (shaded yellow) just posterior to the maxilla and the roof of the in**f**ratemporal space on the base of the cranium. (Reproduced from Clemente CD, ed. Gray's anatomy of the human body. 30th ed. Philadelphia, PA: Lea & Febiger, 1985:166, with permission.)

LEARNINg ExERCISE

Viewing the inferior surface of a skull with a movable mandible, imagine elastic bands attached from the location of the origins to the insertions of the lateral pterygoid muscles, right and left sides. Since the origin on the base of the skull stays stationary, but the mandible at the insertion attachment can move, confirm that the mandible moves anterior and inferior if both elastic bands were contracted (shortened). Next, see what would happen if only one band was shortened (contracted). If only the right side is shortened, the right condyle moves medially (to the left), closer to its origin on the lateral pterygoid plate, so the body of the mandible and its teeth also move toward the left side. Practice this until you understand why the jaw moves the way it does when one lateral pterygoid muscle works. Next, attempt to palpate the origin of the lateral pterygoid muscle in your mouth. Slip a clean little finger into your mouth along the lateral surface of the maxillary alveolar process. Then, gently move the finger posteriorly and medially, around to the posterior surface of the maxilla, and superiorly toward the lateral surface of the lateral pterygoid plate where the lateral pterygoid muscle attaches. Moving the mandible toward the side you are palpating will give your finger more room to reach the muscle. This palpation may be slightly uncomfortable.

B. OTh Er muSCl ES affECTING maNdIBul ar mOvEmENT

Other muscles affecting mandibular movement include the suprahyoid and infrahyoid group of muscles. T e **suprahyoid** [SOO prah HI oid] **muscle group** extends superiorly from the hyoid bone to the mandible, whereas the infrahyoid muscle group extends inferiorly from the hyoid bone to the clavicle (collarbone) and sternum (breastbone) and adjacent structures (Fig. 14-35). T e **infrahyoid muscle group** must stabilize the hyoid bone and keep it from rising, so when the suprahyoid muscles contract, they can move the mandible and not just move the hyoid bone. T ese muscle groups act together with both lateral pterygoid muscles to help depress the mandible (open the mouth) and act with the posterior (horizontal) fibers of the temporalis muscles to retrude (pull back) the mandible.

T e suprahyoid muscles include the **stylohyoid** [STY lo HI oid] (which arise on the styloid process), **digastric** [di GAS trik] (the anterior belly of the digastric attaches in the digastric fossa near the genial spines or tubercles), **mylohyoid** (arising from the mylohyoid ridges on each half of the medial surface of the mandible and found in the tissue that forms the floor of the mouth), and **geniohyoid**

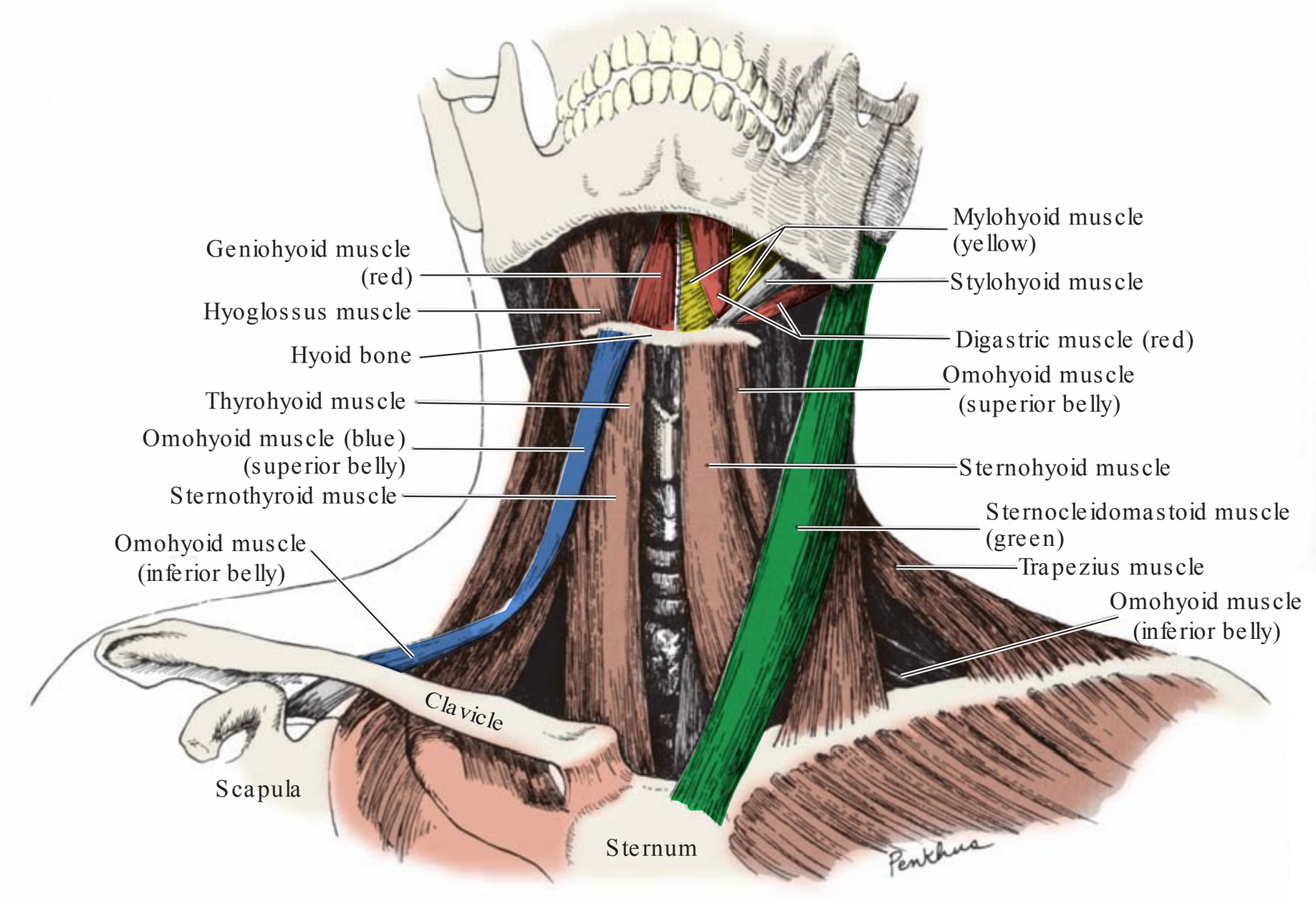

fIGur E 14-35. M**u**scles o**f** the neck, anterior view, with the superficial, thin platysma muscle and some other muscles removed. Note the h**y**oid bone with a group of muscles superior to the hyoid (called the s**u**prah**y**oid m**u**scle **g**ro**u**p) and another group of muscles inferior to the hyoid bone (called the in**f**rah**y**oid m**u**scle **g**ro**u**p). The suprahyoids generally attach the hyoid bone to the mandible and include the di**g**astric muscles (one is shaded red over the m**y**loh**y**oid muscle, which is shaded yellow) and the **g**eniohyoid muscle (one is shaded red). The infrahyoids generally attach the hyoid bone to the clavicle (collarbone) and sternum (breastbone) and include the omoh**y**oid muscle (shaded blue). When both muscle groups work together, they can help open and retrude the mandible. The sternocleidomastoid m**u**scle is shaded green. (Reproduced from Clemente CD, ed. Gray's anatomy of the human body. 30th ed. Philadelphia, PA: Lea & Febiger, 1985:451, with permission.)

[JEE ni o HI oid] muscles (arising from the genial tubercles). T e infrahyoid muscles include the **omohyoid**, **sternohyoid**, **sternothyroid**, and **thyrohyoid**.

Another neck muscle, the **sternocleidomastoid**, attaches from the mastoid process of the temporal bone to the sternum (breastbone) and clavicle (collarbone). T e area around this muscle is palpated during a cancer-screening exam since the chain of cervical (neck) lymph nodes surrounds this muscle (Fig. 14-35).

C. OTh Er fa CTOr S a f f ECTING TOOTh pOSITION Or mOv EmENT

Other factors affecting relative tooth positions and movements include the ligaments, fascia, and, to a certain extent, the muscles of facial expression. T e **ligaments**, including the capsular, temporomandibular, stylomandibular, and sphenomandibular ligaments (recall Figs. 14-23 and 14-24), provide some limits to protrusive, lateral, and opening movements of the mandible.

Fascia [FASH e ah] is also thought to limit movement of the mandible to some extent. Fascia is a connective tissue that forms sheets or bands between anatomic structures. It attaches to bones and surrounds muscles, glands, vessels, nerves, and fat.

Some muscles of facial expression (especially in the lips and cheeks) and the tongue muscles are thought to influence development, position, and shape of the dental arches. T e muscles of facial expression are shown in Figure 14-36 and include the following:

- **Orbicularis oris** [or BIK u LAR is O ris] is located within the lips around the opening of the mouth and acts to close or purse the lips (as around a straw or around a saliva ejector within the dental of ce).
- **Buccinator** [BUCK si na tor] attaches on the buccinator crest (posterior to the mandibular third molar) and

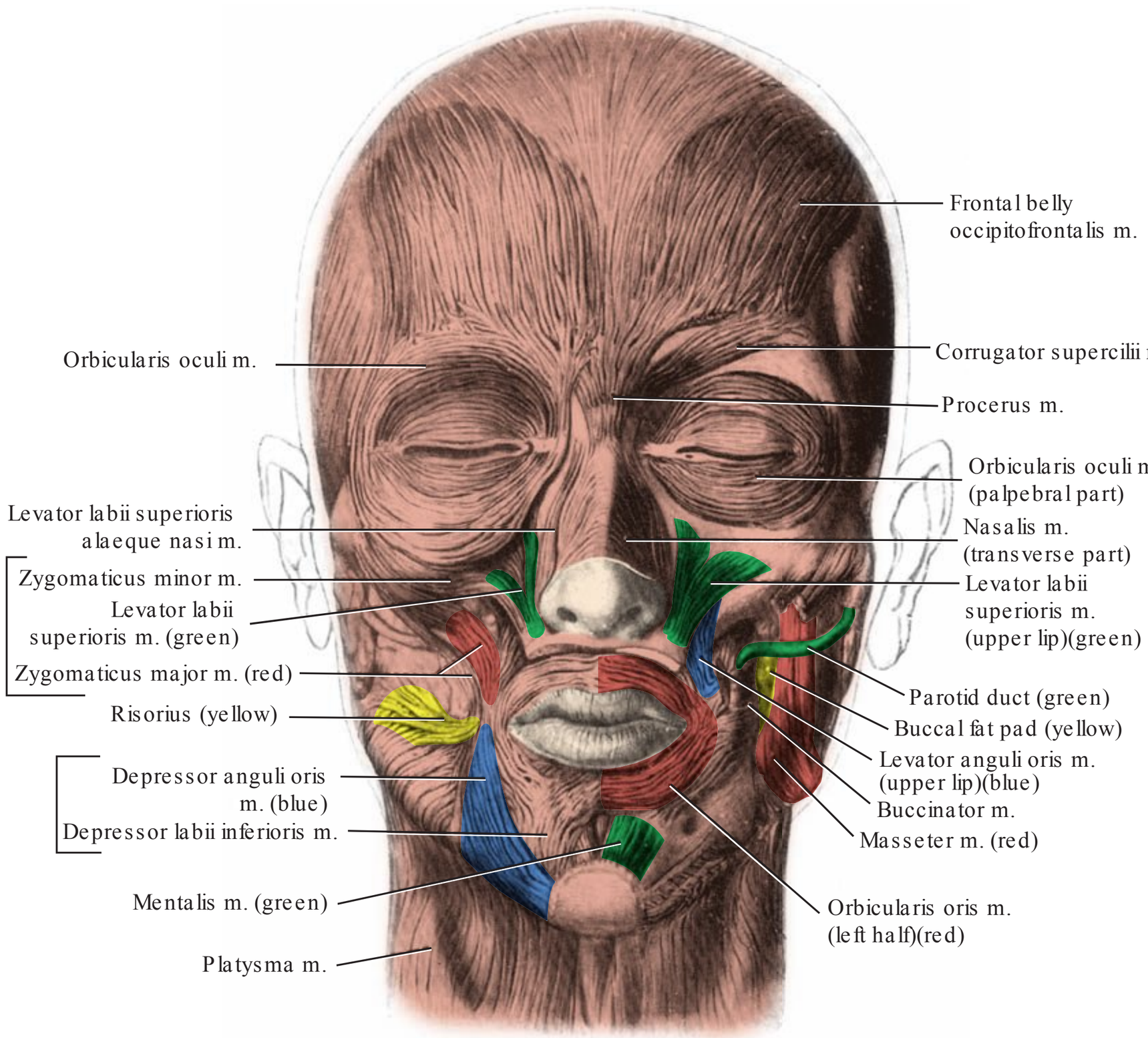

fIGur E 14-36. The m**u**scles o**f** **f**acial e**x**pression. Note the shaded muscles superior to the upper lip, which help raise the lip or help us smile: the z**yg**omatic**u**s major (red) and minor, levator labii s**u**perioris (green), and levator an**gu**li oris (blue) and the muscles inferior to the lower lip, which help lower the lip or frown: depressor an**gu**li oris (blue) and the depressor labii in**f**erioris (not shaded). The risori**u**s (yellow) helps to widen the mouth, the mentalis (green) is in the chin, the b**u**ccinator (yellow) is in the cheek, and the orbic**u**laris oris (red) surrounds the lips for puckering. The plat**y**sma is a thin layer of muscle covering deeper neck muscles. (Reproduced from Clemente CD, ed. Gray's anatomy of the human body. 30th ed. Philadelphia, PA: Lea & Febiger, 1985:444, with permission.)

adjacent soft tissue, forming a pouch in the cheeks. When contracting, it pulls the cheek inward to keep food on the chewing surfaces of teeth during chewing.

- Upper oral group includes the **zygomaticus** [ZI go MAT i kus] **major and minor, levator labii** [LAB e e] **superioris**, and **levator anguli oris**. All contribute to raising the upper lip and/or angle, as in smiling. T e **risorius** [ri SO ri us] retracts (spreads) the angle of the mouth. (T e levator labii superioris alaeque [a LY kwe] nasi dilates the nostrils, as in contempt.)
- Lower oral group (including the **depressor labii inferior** and **depressor anguli oris**) contracts to lower the lower lip or angle, as in a frown. T e **mentalis** [men TA lis] is located in the chin and raises or protrudes the chin as in a pout.

Other muscles that influence facial expression include the following:

- Nose muscles include the **nasalis** [na SA lis], which flares the nostrils; the **depressor septi nasi** (not shown in figure), which pulls the nares down, thereby constricting the opening of the nose (nares); and the **procerus** [pro SE rus] superior from the bridge of the nose, which lowers the medial eyebrow and wrinkles the nose.
- Eye muscles include the **orbicularis oculi** [or BIK u lar is AHK u li], which surrounds the eye and acts to squint the eye, and the **corrugator supercilii** [COR u gay tor su per SIL e e], which draws the medial end of the eyebrow down, as in a frown.
- Ear muscles include the **posterior**, **superior**, and **anterior auricular** [aw RIK u lar] muscles (not shown), which act to move the ears and/or scalp. Can you wiggle your ears by contracting these muscles? Give it a try.
- T e broad **occipitofrontalis** [ahk SIP i toe fron TAL is] (or epicranial) **muscle** draws back the scalp, wrinkling the forehead and raising the eyebrows, as in surprise.
- T e **platysma** [plah TIZ mah] muscle is a broad muscle that extends from the mouth to the anterior and lateral surfaces of the neck and contracts during a grimace.

T e posterior and deep muscles of the neck, as well as the overlying fascia and skin, all have a slight postural influence on the physiologic resting position of the mandible. Other than this, the numerous facial muscles, including the buccinator, do not influence any movements of the mandible. However, a person's posture, state of mind, stress, health, and physical and mental fatigue each have a decided effect on the resting posture of the mandible at any given time.[22]

d. Su mmar y Of mu SCl ES Th aT mOvE a Nd CONTr Ol Th E ma Nd IBl E

T ere are five specifically different ways that we can voluntarily move our mandible. T ere are limitless combinations of these movements that occur throughout any 24 hours. In review, here are the muscles that contribute to each movement:

1. Elevation of the mandible

Elevation (elevates the mandible and closes the mouth) results from the bilateral contraction of three pairs of muscles. T e **temporalis** muscles (vertical fibers) bring the mandible upward into position for crushing food. T e temporalis muscles are primarily the positioning muscles as they elevate the mandible upward until it is in position to have the real force applied by the other two pairs of closing muscles. T e **masseter** muscles and the **medial pterygoid muscles** act together to apply the power for forceful jaw closures, as in crushing food, such as biting through a carrot.

2. d epression of the mandible

Depression (depresses the mandible and opens the mouth) results primarily from the bilateral contraction of **both lateral pterygoid muscles**, assisted by **suprahyoid and infrahyoid muscles**, especially the anterior bellies of the digastric muscles, and the omohyoid (infrahyoid) muscles, which help fix or hold the hyoid bone.

3. r etrusion

Retrusion (retracts the mandible) results from the bilateral contraction of the **posterior ȧbers of the temporalis** muscles assisted by the **suprahyoids**, especially the **digastric** muscles (anterior and posterior bellies seen in Fig. 14-35).

4. protrusion

Protrusion (or protraction, protrudes the mandible) results from the simultaneous contraction of **both lateral pterygoid muscles**.

5. l ateral Excursion

Lateral excursion (moves sideways) results from the contraction of **one lateral pterygoid** muscle. T e mandible is moved bodily to the left by the contraction of the right lateral pterygoid muscle.[15,23]

E. a d va NCEd TOp ICS

1. h ow muscles work

T e muscles of the body contribute 40% to 50% of the total body weight.[24] Muscles produce the desired action by pulling or by shortening, never by pushing or by lengthening. Skeletal or voluntary muscles are made up of specialized cells that contract. Skeletal muscles are very active metabolically and therefore require a rich blood supply.[24] T ere are two other kinds of muscles we are unable to control or direct: cardiac and smooth (involuntary) muscles.

Individual muscle cells are small, elongated contractile fibers, each enclosed in a delicate envelope of loose connective tissue. Many individual parallel muscle fibers make up a

bundle, and various numbers of bundles comprise a muscle. T e longest muscle fibers are 300 mm (11.4 inch) long. Each contractile bundle of cells can contract about 57% of its fully stretched length.[25] T e all-or-none law states that any single muscle fiber always contracts to its fullest extent.[17] When a weak effort or contraction is required of the whole muscle, then only a few fibers contract (each to the fullest extent). Many fibers contracting produce greater power as needed. Further, no single muscle acts alone to produce a movement or to maintain posture. Many muscles must work in perfect coordination to produce a steady, well-directed motion of a body part.

When a muscle becomes shorter as it moves a structure, the movement is called an **isotonic** contraction. When a muscle maintains its length as it contracts to stabilize a part, this movement is called **isometric** contraction. As you close your jaw until all teeth contact, the closing muscles work isotonically because they become shorter as the mandible moves superiorly. If you maintain contact of all of your teeth but squeeze them together hard, these same muscles are contracting isometrically because they cannot shorten any more once your teeth are together.

A few or more individual muscle fibers of all of our voluntary muscles are continually or alternately contracting during consciousness. T is minimal amount of contraction needed to maintain posture is called **muscle tone** or tonus, and the muscles involved are named "antigravity" muscles. As you read this, the muscles of mastication are probably in a state of minimal tonic contraction or balance with each other, with the neck muscles, and with gravity, enabling a restful position for your mandible with the teeth apart. T is normal resting jaw position varies slightly according to whether you are sitting, lying on your back, or standing up and depending on how tense or stressed you are. When you fall asleep at your desk, antigravity muscles relax and, as you may have seen on others, the mouth drops open.

2. Size of the masseter muscle

T e average volume of the masseter muscle is over twice that of the medial pterygoid muscle (on 25 males is 30.4 ± 4.1 cm^3, which is 2.6 times larger than the medial pterygoid muscle at 11.5 ± 2.1 cm^3).[26]

r EvIEw Questions

1. Which muscle has its origin in the pterygoid fossa?
   a. Medial pterygoid muscle
   b. Lateral pterygoid muscle
   c. Masseter muscle
   d. Temporalis muscle

2. T e masseter muscle elevates the mandible. Which other muscles are involved in elevating the mandible?
   a. Temporalis (anterior fibers) and lateral pterygoid muscles
   b. Lateral pterygoid muscles and medial perygoid muscles
   c. Temporalis (posterior and anterior fibers) and medial pterygoid muscles
   d. Medial pterygoid muscles and temporalis (anterior fibers)
   e. Lateral pterygoid muscles and temporalis (posterior fibers)

3. In which direction do the fibers of the lateral pterygoid muscles travel from their origin to their insertion?
   a. Medial and posterior
   b. Medial and anterior
   c. Lateral and anterior
   d. Lateral and posterior

4. Which of the following muscles of facial expression does not contribute to moving the lips?
   a. Orbicularis oris
   b. Risorius
   c. Levator labii superioris
   d. Depressor labii inferioris
   e. Orbicularis oculi

5. Which of the following would you palpate anterior and 1 to 2 inches superior to the ear?
   a. Masseter, the origin
   b. Masseter, the insertion
   c. Temporalis, posterior fibers
   d. Temporalis, anterior fibers
   e. Temporalis, the insertion

6. Which muscle, when contracting, moves the mandible to the right?
   a. T e left medial pterygoid muscle
   b. T e right medial pterygoid muscle
   c. T e left temporalis muscle, horizontal fibers
   d. T e right lateral pterygoid muscle
   e. T e left lateral pterygoid muscle

e–6; d–5; e–4; d–3; d–2; a–1: Sr E wS Na

SECTION Iv NEr vES Of Th E Or a l CavITy

Objectives

The objectives for this section are to prepare the reader to perform the following:

- List the 12 CNs and briefy describe their function.
- Describe the important branches of the trigeminal nerve and trace the route of each important branch from the brain to the structures that they innervate in the oral cavity.
- Describe the pathway to the oral cavity of the facial nerve and identify the oral structure(s) it innervates.
- Describe the pathway to the oral cavity of the glossopharyngeal nerve and identify the oral structure(s) it innervates.
- Describe the pathway to the oral cavity of the hypoglossal nerve and identify the oral structure(s) it innervates.

T ere are three types of nerve fibers based on their function: afferent, efferent, and secretory. **Af erent** [AF er ent] (or **sensory**) fibers convey impulses (such as feeling, touch, pain, taste) from peripheral organs (like the skin or surface of the tongue) to the central nervous system. (Hint: Afferent: where "a" (as in approach) means sending impulses toward the brain, i.e., from an organ receiving sensory input, so the brain can "feel" it; therefore, these impulses are sensory, related to the senses of feeling, touch, pain, taste, etc.)

Ef erent [EF er ent] (or **motor**) nerve fibers convey impulses from the central nervous system to the peripheral organs, such as to muscle fibers to initiate contraction. T ey supply the four pairs of muscles of mastication and other muscles in the region of the mouth. (Hint: Efferent: where "e" (as in exit) means sending an impulse from the brain, which could contract a muscle and move a bone in the intended direction (or could increase force on that bone without movement); therefore, these impulses are motor.)

Secretory fibers are specialized efferent nerve fibers that, upon stimulation, can send messages to glands, such as the salivary and lacrimal (tear) glands to produce and secrete saliva or tears.

T ere are 12 cranial nerves (CNs) that all supply the area of the head. Table 14-2 lists the 12 CNs (indicated by Roman numerals I to XII) that are responsible for the specific functions.[1,3,11,27–30]

a. Tr IGEmINa l NEr vE (f If Th CN)

When discussing the function of the oral cavity, probably the most important nerve is the trigeminal. T e **trigeminal nerve** or **fifth CN** is the largest of the CNs and is the major sensory nerve of the face and scalp. It originates in the large semilunar or trigeminal ganglion, a group of nerve cell bodies located on the superior surface of the petrous portion of the temporal bone in a small depression (the semilunar fossa) medial to the foramen ovale. T e trigeminal nerve divides into **three major divisions** (or three nerve branches). (Hint: "tri" in trigeminal refers to the nerve's three divisions.) **Division I** (the **ophthalmic** [ahf THAL mik] **nerve**) and **Division II** (the **maxillary nerve**) are only afferent (sensory). **Division III** (the **mandibular nerve**) is both afferent (sensory) and efferent (motor). Its efferent fibers supply the muscles of mastication. T is is the only CN with sensory (touch and pain) innervation to the skin of the face, and the divisions or branches are distributed to the face as shown in Figure 14-37.

T e maxillary and mandibular divisions of the trigeminal nerve also supply afferent or sensory neurons that provide the brain with information about the position of the teeth and jaws at all times. T e interpretation of postural information by the brain (sense of position) is called **proprioception**. Proprioceptive nerve receptors are located in muscles and ligaments, including the periodontal ligaments, and in the lateral aspects of the TMJ. T e periodontal ligament around each tooth is well supplied with proprioceptive neurons from the maxillary and mandibular divisions of the trigeminal nerve. T ese branches send messages to the brain as to the relative position of the mandibular to maxillary teeth. T is has a tremendous influence on relative jaw position, movement, and occlusion (the fitting together) of the teeth. Canines are reported to have the richest supply of proprioceptive nerve endings.

T e TMJ also has proprioceptive neurons in the capsule and disc that are innervated by a branch of the mandibular division of the trigeminal nerve. To a great extent, proprioceptive information, especially from the teeth, determines the subconscious but well-coordinated function of the two complex TMJ.[28,29] Otherwise, we could experience many unpleasant tooth interferences or frequent joint pain.

Each of the three divisions is divided into many branches. T e branches of the maxillary nerve and the mandibular nerve are those that innervate the region of, and around, the oral cavity and will be discussed in the most depth in this section.

TABLE 14-2 The Twelve Cranial Nerves

NERVE NO.	CRANIAL NERVE	FUNCTION
I	Olfactory [ol FAK toe ree]	Smell
II	Optic	Sight
III	Oculomotor [AHK u lo MO tor]	Orbital muscles for eye movement
IV	Trochlear [TROK le ar]	Orbital muscles for eye movement
V	*Tri**g**eminal [tri JEM i nal]	Motor: movement o**f** the jaws and m**u**scles o**f** mastication Sensor**y**: sensation o**f** **f**eelin**g** **f**or the **f**ace, teeth, and periodontal li**g**aments and anterior two thirds o**f** the ton**gu**e
VI	Abducens [ab DOO senz]	Orbital muscles for eye movement
VII	***F**acial	Motor: to the m**u**scles o**f** **f**acial e**x**pression Sensor**y**: taste to anterior two thirds o**f** ton**gu**e Secretor**y**: to s**u**bmandib**u**lar and s**u**blin**gu**al **g**lands
VIII	Auditory (or acoustic)	Sense of hearing, position, and balance
Ix	*g lossophar**y**n**g**eal [g LOSS o **f**eh rin JI al]	Secretor**y**: to parotid **g**land and phar**y**n**g**eal movements Sensor**y**: **f**eelin**g** to phar**y**n**x** and posterior one third o**f** the ton**gu**e and taste to posterior one third o**f** the ton**gu**e
X	Vagus [VAY gus]	Pharyngeal and laryngeal movements: digestive tract
XI	Spinal accessory	Neck movements: sternocleidomastoid and trapezius muscles
xII	*H**y**po**g**lossal	Motor: ton**gu**e movement (m**u**scles)

*The asterisked nerves in bold are most important when discussing the function of the oral cavity. A detailed discussion of these nerves will include the major branches to structures of the mouth, including teeth, periodontal ligaments and alveolar processes, gingiva (gums), the palate and foor of the mouth, and muscles of mastication, of facial expression, and of the tongue (for both muscular action and our sense of taste). Also, a pneumonic that may help you remember the cranial nerves (where the first letter of each word is the same as the first letter of each cranial nerve) is "On Old Olympus' Towering Top, A Finn and German Viewed Some Hops."

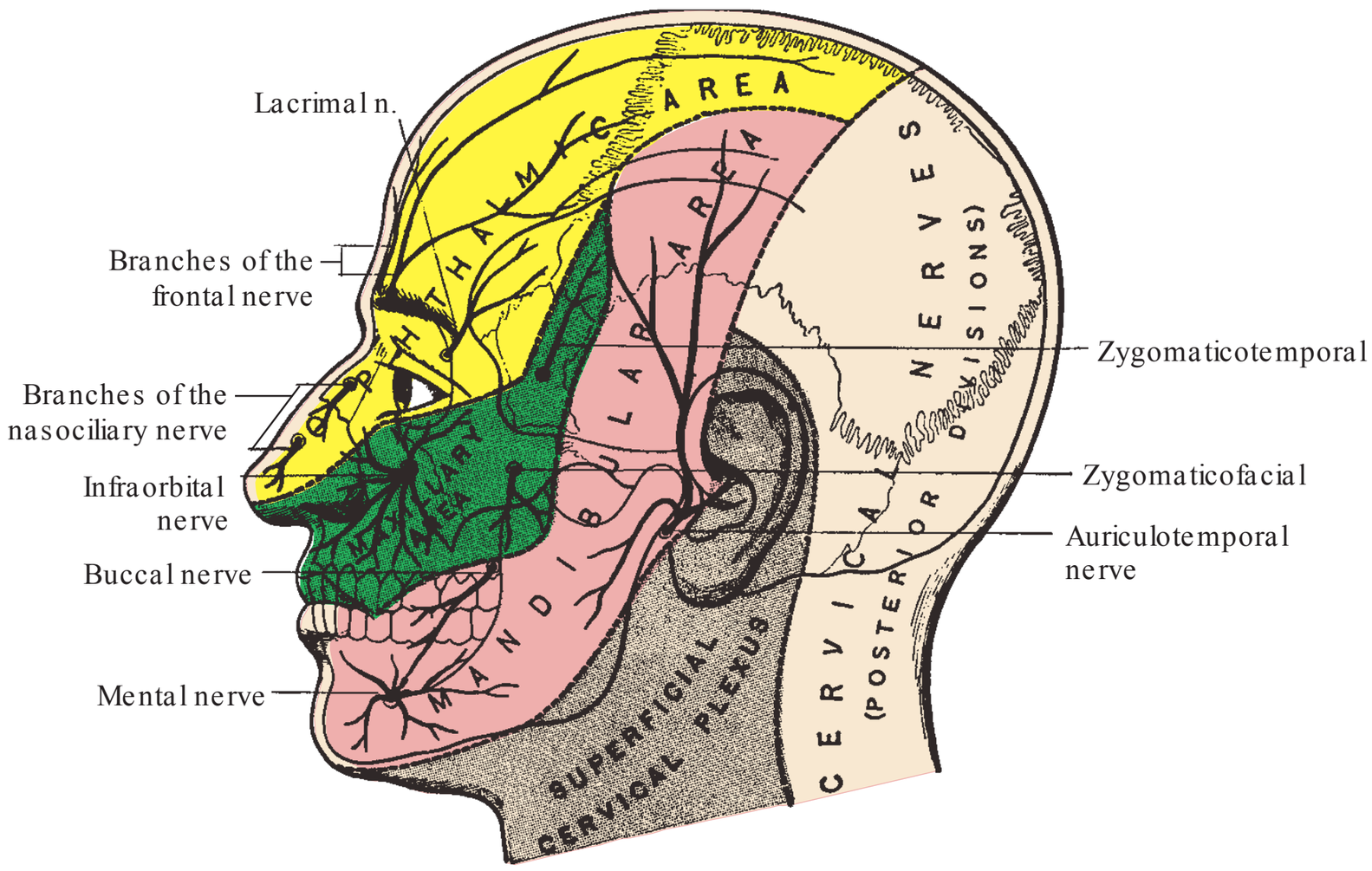

FIGURE 14-37. General distribution to the skin of the three sensor**y** divisions of the tri**g**eminal nerve. Pain in these areas is felt by impulses sent through the ophthalmic (yellow), ma**x**illar**y** (green), and mandib**u**lar branches (red) or divisions of this nerve. These three branches are distributed to the face as indicated in this drawing. (Reproduced from Clemente CD, ed. Gray's anatomy of the human body. 30th ed. Philadelphia, PA: Lea & Febiger, 1985:1164, with permission.)

1. division I (Ophthalmic Nerve) of the Trigeminal Nerve

The **ophthalmic** [of THAL mik] **nerve** exits from the skull by way of the **superior orbital fissure** on the superior surface of the orbit (Fig. 14-38). It has three main branches: the smallest lacrimal nerve, the largest frontal nerve, and the nasociliary nerve. The distribution of these sensory branches that supply the skin of the face is shown in Figure 14-37. The ophthalmic nerve and its branches supply general sensations (of touch, pain, pressure, and temperature) to the skin of the upper third of the face including the skin of the forehead and anterior scalp, and the skin around the eyeballs, upper eyelids, and nose, and part of the nasal mucosa and maxillary sinus. The ophthalmic nerve does not supply the oral cavity. (Hint: "Ophthalmic" is related to the eye; compare ophthalmologist, a physician who specializes in eyes.)

2. division II (maxillary Nerve) of the Trigeminal Nerve

The **maxillary nerve** provides general sensations (of touch, pain, pressure, and temperature) to the skin of the middle third of the face and the palate (Fig. 14-37) plus provides sensory branches to the pulp of all maxillary teeth. It exits the braincase of the skull through the **foramen rotundum** (Fig. 14-38). After passing through the foramen rotundum, the maxillary nerve passes into the pterygopalatine space and eventually splits into four branches: the pterygopalatine, PSA, infraorbital, and zygomatic nerves.

a. First Branch of the Maxillary Nerve: Pterygopalatine Nerve

The first branch of the maxillary nerve, the **pterygopalatine nerve**, splits off closest to the foramen rotundum. A branch of this nerve, called the **descending palatine nerve**, passes through the greater palatine foramen to become the **greater palatine nerve (anterior palatine nerve)**. The greater palatine nerve spreads anteriorly to supply the part of the hard palate and palatal gingiva that is medial to the posterior teeth (molars and premolars) (posterior red lines in Fig. 14-39). Just posterior to the greater palatine foramen, the **middle** and **posterior** (lesser) **palatine nerves** enter the palate through the lesser palatine foramen to spread posteriorly to supply the tonsils and mucosa of the soft palate.

Another long branch of the pterygopalatine nerve, the **nasopalatine nerve**, runs along the roof of the nasal cavity, then diagonally downward and anteriorly along the nasal septum where it enters the bone of the palate to emerge onto the anterior palate through the **incisive foramen**. This branch innervates the soft tissue of the nasal septum and gingiva and palatal soft tissue lingual to the anterior teeth (anterior red lines in Fig 14-39). The right and left nasopalatine nerves combined with the greater palatine nerves innervate the soft tissue of the entire hard palate (shown as all red lines in Fig. 14-39).

b. Second Branch of the Maxillary Nerve: Posterior Superior Alveolar (PSA) Nerve

Just before the maxillary nerve branch enters the infraorbital fissure and canal on the floor of the orbit, it gives off its second branch, the **PSA nerve**. This branch descends to enter

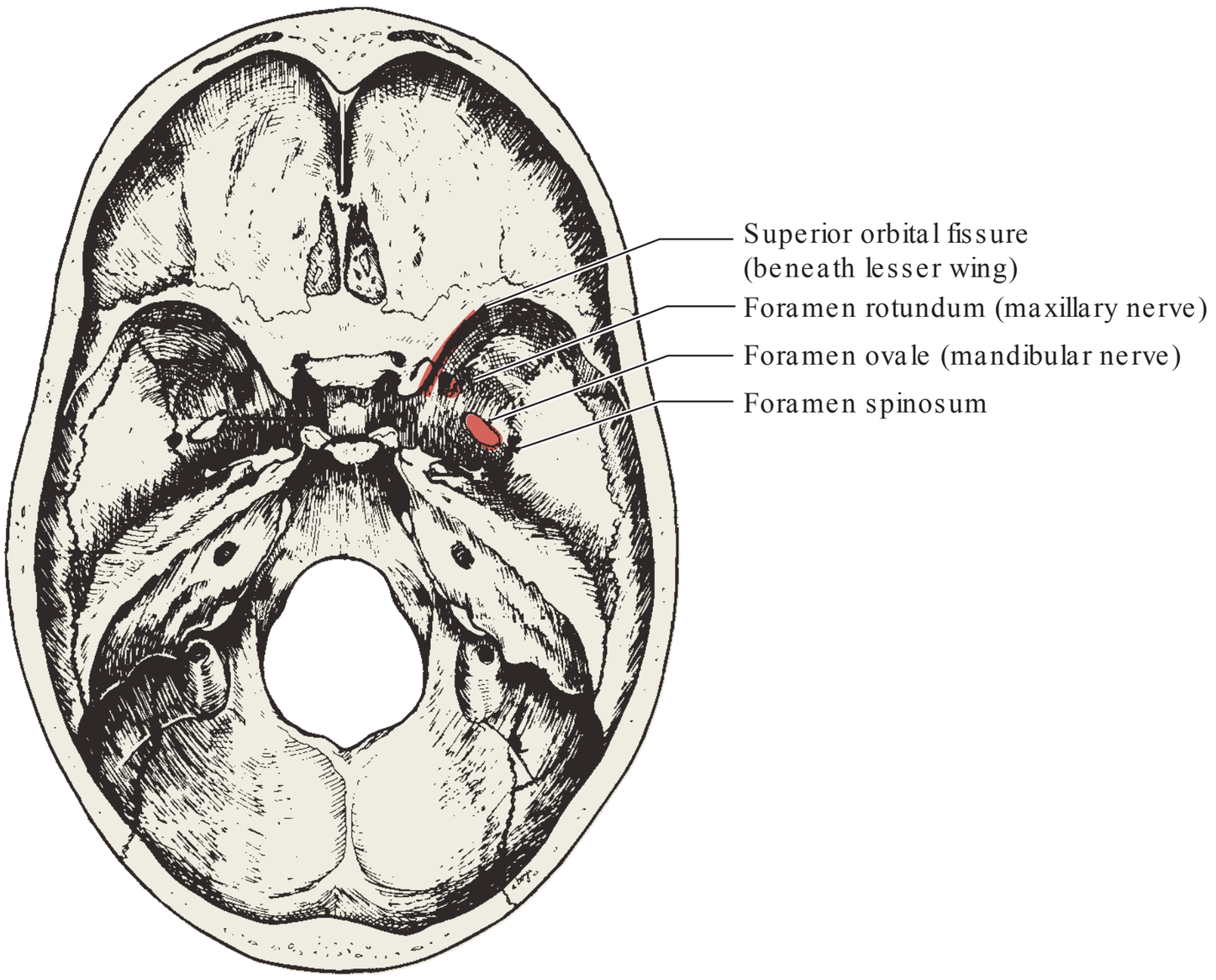

fIGur E 14-38. **Human skull: foramen of the branches of the trigeminal nerve (CN V) (shaded red on right side). The superior orbital fissure for the ophthalmic branch, the foramen rotundum for the maxillary branch, and the foramen ovale for the mandibular branch.**

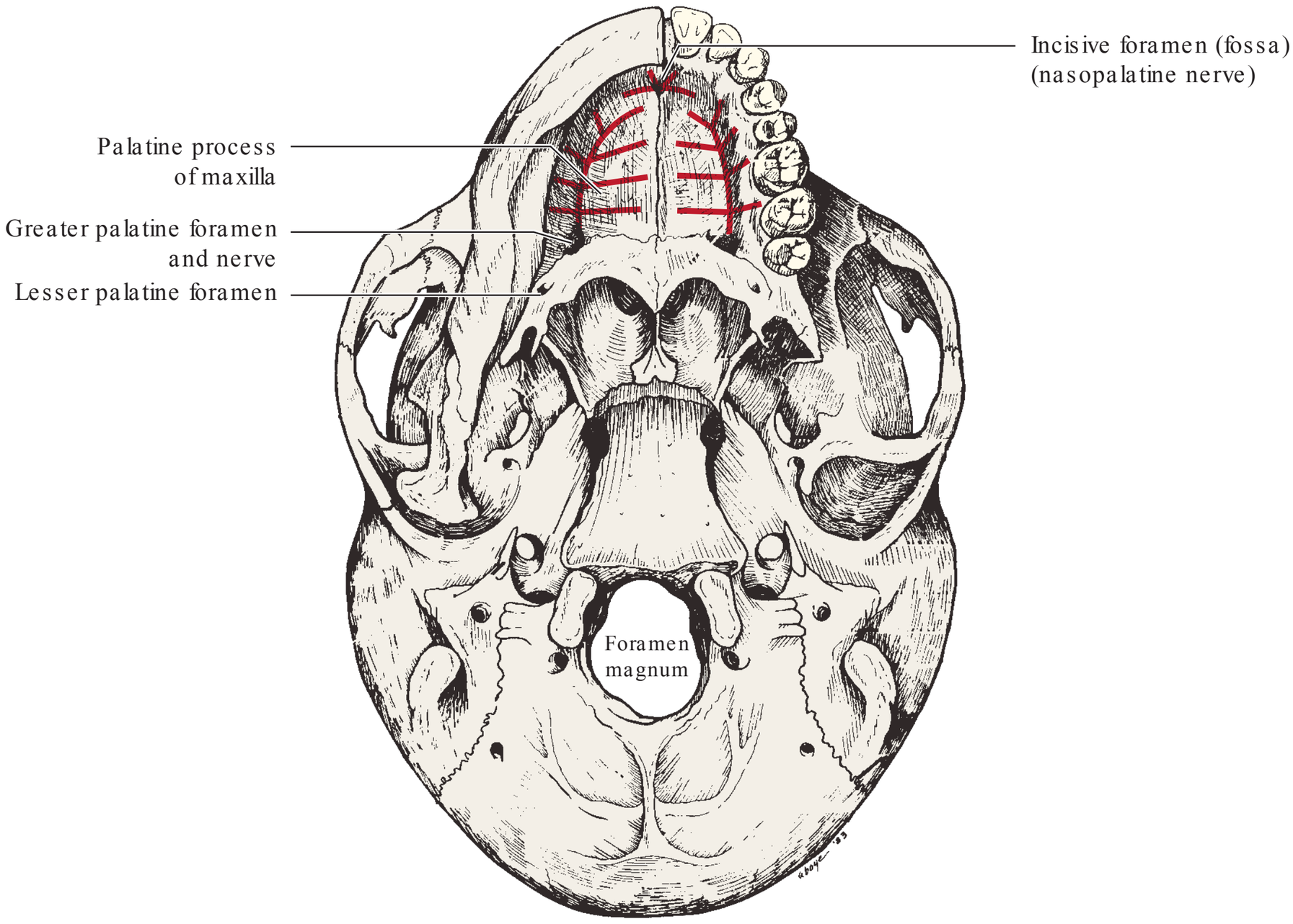

fIGur E 14-39. H**u**man sk**u**ll: in**f**erior s**ur**face including the palate, showing the foramina for branches of the trigeminal nerve that innervates the mucosa of the palate: the **g**reater palatine **f**oramen (for the greater palatine nerve) and the incisive **f**oramen (for the nasopalatine nerve). The more posterior red lines indicate the diagrammatic distribution of the branches of the greater palatine nerves as they spread out along the junction of the alveolar processes with the palatine processes of the maxillae to the tissues (mucosa) of the palate located between the posterior teeth. The more anterior red lines indicate the nasopalatine nerve branches spreading out to the mucosa between the anterior teeth.

the alveolar canals on the infratemporal portion of the maxilla (Fig. 14-40). Once within the trabecular (spongy) bone of the maxilla and the maxillary sinus, its **dental branches** enter small openings in the tooth roots to supply the maxillary molars (except for one root, the mesiobuccal root of the maxillary first molars). It also innervates the supporting alveolar bone, periodontal ligaments, and facial gingiva next to the maxillary molars, the mucosa of part of the maxillary sinus, and cheek mucosa next to maxillary molars.

c. *Third Branch of the Maxillary Nerve: Infraorbital Nerve*

In the pterygopalatine space, a third branch of the maxillary nerve splits off and passes through the inferior orbital fissure on the floor of the orbit and enters the infraorbital canal, where it becomes the **infraorbital nerve** (Fig. 14-40). While within this canal, the infraorbital nerve gives off two branches, the middle superior alveolar (MSA) and the anterior superior alveolar (ASA) nerves (shown in Fig. 14-40).

T e **MSA nerve** passes forward along the lining of the maxillary sinus. It gives off small dental branches that enter premolars through their root openings (apical foramina) to supply the maxillary premolars (and the mesiobuccal root of the maxillary first molar), supporting alveolar bone, periodontal ligaments, and facial gingiva in the maxillary premolar region and part of the maxillary sinus. It is important to realize that the nerve supplying primary teeth is the same as that to the permanent teeth that replace them. T erefore, the nerve branch to the primary molars is the MSA, the same one that supplies their successors, the permanent premolars.

T e second branch given off of the infraorbital nerve while in the infraorbital canal is the **ASA nerve**. Its small dental branches supply the pulp, supporting alveolar bone, periodontal ligaments, and facial gingiva of the maxillary anterior teeth and part of the maxillary sinus.

Notice that three superior alveolar branches of the maxillary nerve of CN V (PSA, MSA, and ASA) innervate all maxillary teeth. A comparison of the descriptions of these three nerves indicates a great lack of uniformity in their distribution. Sometimes, the MSA nerve is missing, and the function is taken over by the anterior and posterior alveolar nerves.

After exiting from the infraorbital foramen, the **infraorbital nerve** splits into its end (terminal) branches innervating the skin and mucosa of the side of the nose (**nasal nerve**), skin and mucosa of the lower eyelids (**palpebral** [PAL pe bral] **nerve**), and skin and mucosa of the upper lip, facial

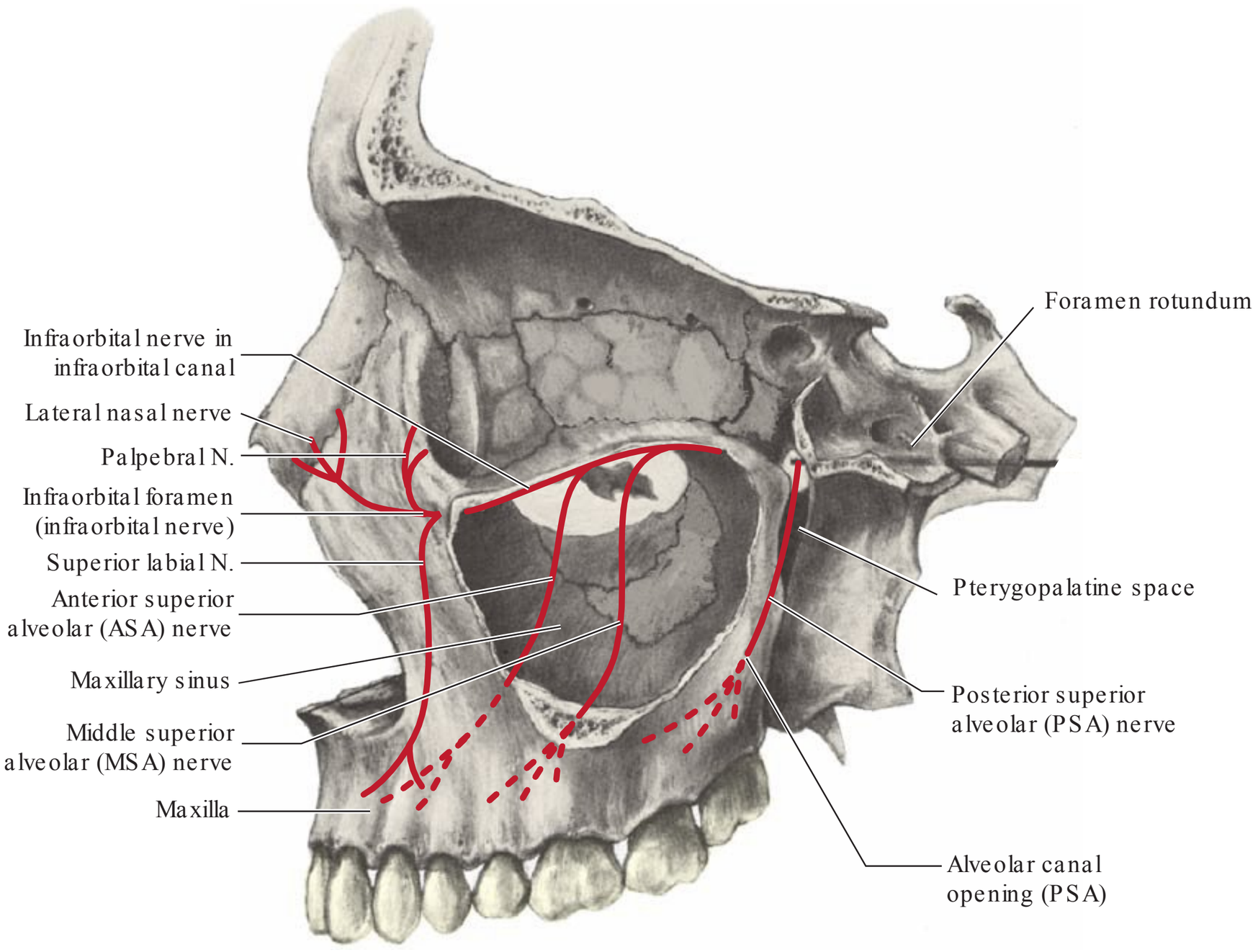

FIGURE 14-40. Maxillary division of the trigeminal nerve: branches seen as red lines (dotted red lines when within the trabecular bone) that innervate the maxillary teeth. The lateral wall of the left maxilla has been removed exposing the large maxillary sinus. One nerve branch (the PSA nerve) exits the pterygopalatine space and goes down the posterior surface of the maxilla before entering the maxilla through the alveolar canals on its way to most maxillary molar roots. Another branch, the infraorbital nerve, passes from the pterygopalatine space to the floor of the eye orbit (which also forms the roof of the maxillary sinus) where it enters the infraorbital canal (not shown). Within the infraorbital canal, two branches split off to pass downward along the walls of the maxillary sinus and into the maxilla. The MSA nerve passes through the spongy bone of the maxilla to the maxillary premolars (and the mesiobuccal root of the first molar on each side), and the ASA passes to the roots of the maxillary anterior teeth. The infraorbital branch continues through the infraorbital canal to exit the maxilla through the infraorbital foramen, which provides feeling to the skin on the side of the nose, the anterior part of the cheek, and the upper lip on that side.

gingiva of maxillary premolars, and facial gingiva of anterior teeth (**labial** [LAY bee al] **nerve**) (Fig. 14-40).

d. Fourth Branch of the Maxillary Nerve: Zygomatic Nerve

The **zygomatic nerve** arises in the pterygopalatine fossa, enters the orbit via the inferior orbital fissure, and then divides into two branches: the upper zygomaticotemporal and lower zygomaticofacial nerves (Fig. 14-37). These branches supply the skin of the temporal region and lower part of the orbit.

3. Division III (Mandibular Nerve) of the Trigeminal Nerve

The **mandibular nerve** is a mixed nerve; that is, it contains both sensory (afferent) and motor (efferent) fibers. It is the only motor portion of the trigeminal nerve. These motor fibers of the mandibular nerve supply the eight muscles of mastication, plus the mylohyoid muscle and the anterior belly of the digastric muscles, which help to retract the mandible (Fig. 14-35). Sensory fibers provide general sensations (of touch, pain, pressure, and temperature) to the skin of the lower third of the face (as seen in Fig. 14-37) and the floor of the mouth and anterior two thirds of the tongue (not taste). Other branches enter all mandibular teeth.

The mandibular nerve exits the neurocranium through the **foramen ovale** (Fig. 14-38). It passes into a space just medial to the zygomatic arch and mandibular ramus and inferior to the temporal bone, called the **infratemporal space**. As it passes inferiorly toward the mandibular foramen in the mandible, it divides into four sensory branches: the auriculotemporal, buccal, lingual, and inferior alveolar nerves.

a. Auriculotemporal Nerve

The first branch of the mandibular division, the **auriculotemporal** [aw RIK u lo TEM po ral] **nerve**, comes off the main trunk immediately below the base of the skull, turning backward to supply pain and proprioception fibers to the TMJ and to supply the skin of the outer ear and the lateral aspect of the skull and cheek (Fig. 14-41).

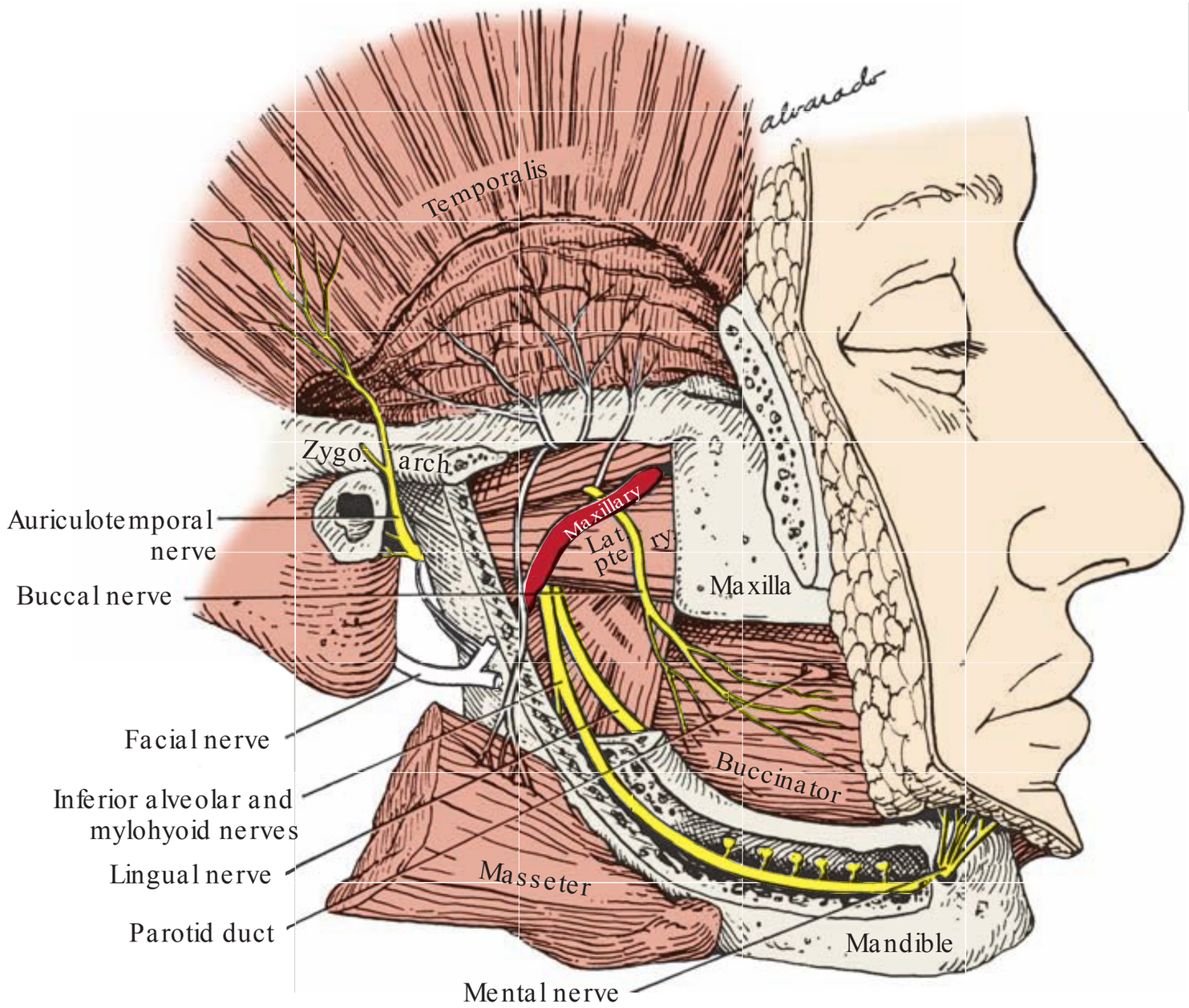

FIGURE 14-41. Mandibular division of the trigeminal nerve branches (yellow). The external wall of the right mandible has been removed to expose the inferior alveolar nerve within the mandible, where it gives off the many small dental branches to each mandibular tooth. (From this view, the buccinator muscle hides the teeth.) Within the mandible near the premolar area, the inferior alveolar nerve splits into two end (terminal) branches. One branch, the mental nerve, exits through the mental foramen to innervate the skin of the chin and lip on that side, while the other branch is really a continuation of the inferior alveolar nerve anteriorly within the mandible where it is called the incisive nerve (not visible here). Also, note the other major branches of the mandibular division: the lingual nerve, which is in close proximity to the inferior alveolar nerve posteriorly but then diverges anteriorly to enter the tongue, and the buccal nerve, which innervates the cheek and tissue next to mandibular molars. Other nerve branches (not shaded) are motor branches of the mandibular nerve supplying the muscles of mastication (shaded light red). The maxillary artery is shaded red. (Motor branches can be seen entering the masseter and temporalis muscles.) (Reproduced from Clemente CD, ed. Gray's anatomy of the human body. 30th ed. Philadelphia, PA: Lea & Febiger, 1985:1166, with permission.)

b. *Buccal (Buccinator) Nerve*

Another branch is the **buccal** (**buccinator** [BUCK sin a tor] **or long buccal**) **nerve**, which comes off just below the foramen ovale and passes through the infratemporal space between the two heads of the lateral pterygoid muscles and then down and forward to the buccinator muscle (Fig. 14-41) where it innervates the mucosa and skin of the cheek up to the corner of the mouth and the buccal gingiva in the area of the mandibular molars and sometimes the second premolars. The best place to anesthetize the tissue supplied by the buccinator nerve is to inject inside the cheek to deposit the anesthetic into the buccinator muscle near the mandibular molars (Fig. 14-42).

c. *Lingual Nerve*

The next branch of the mandibular nerve, given off inferior to the foramen ovale, is the **lingual nerve** branch that goes to the tongue (Figs. 14-41 and 14-42). It passes downward, medial to the ramus but lateral to the medial pterygoid muscle, to the mucous membrane just lingual to the last molar. The lingual nerve provides general sensation (touch, pain, pressure, and temperature, but not taste) to the top (dorsal) and bottom (ventral) surfaces of the anterior two thirds of the tongue and adjacent tissues. The adjacent tissues include the soft tissue (mucosa) on the floor of the mouth and inner surface of the mandible and the lingual gingiva of the entire mandible.

d. *Inferior Alveolar Nerve*

Finally, the **inferior alveolar nerve** comes off the mandibular nerve on the medial side of the lateral pterygoid muscle (Fig. 14-41). This large nerve roughly parallels the direction of the lingual nerve to descend between the sphenomandibular ligament and ramus to the mandibular foramen, where it gives off the **mylohyoid nerve** and then enters the mandible through the **mandibular foramen** (represented on the medial surface of the mandible in Fig. 14-42). The **mylohyoid nerve** (efferent) pierces the sphenomandibular ligament and travels forward in the mylohyoid groove to supply the mylohyoid muscle.

Once the inferior alveolar nerve enters the mandible through the mandibular foramen, it is in the **mandibular canal** within the body of the mandible, where it gives off the

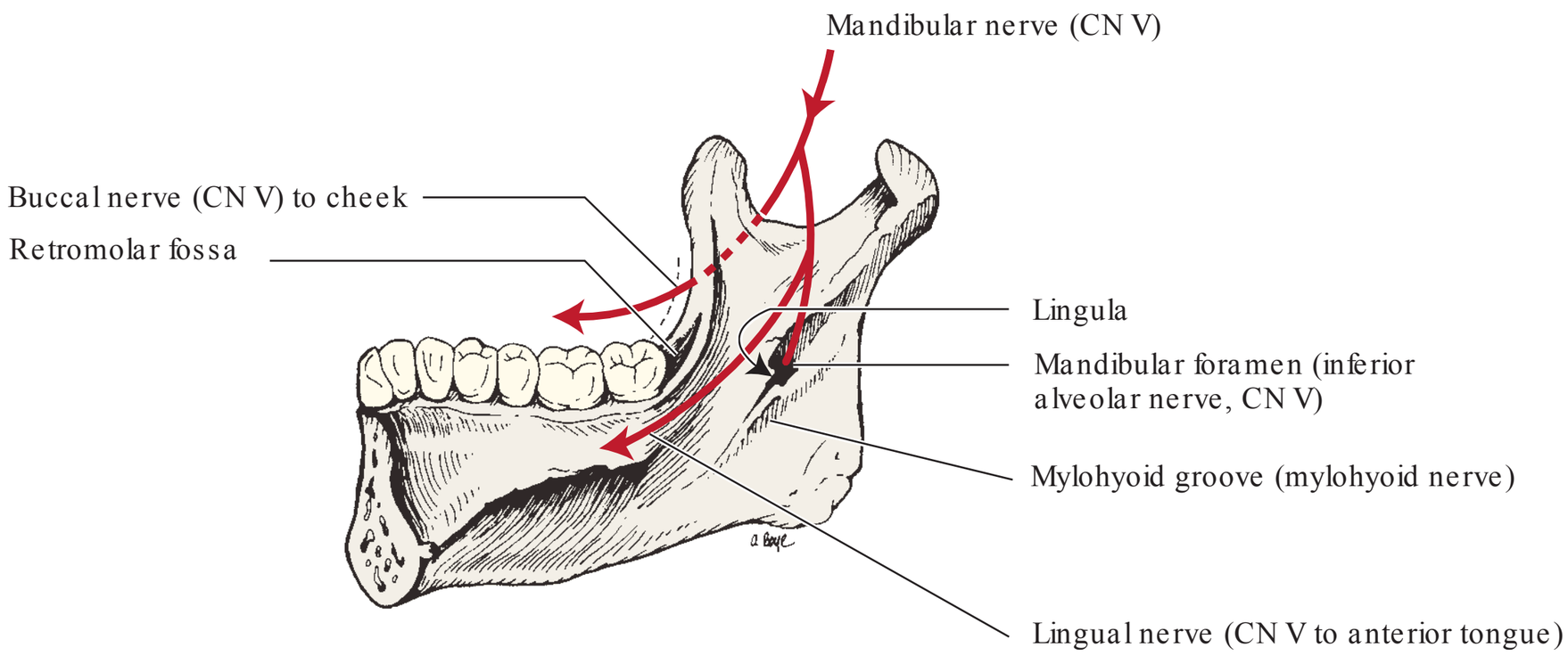

FIGURE 14-42. Location of the branches of the mandibular division of the trigeminal nerve (mandibular nerve) (in red). As the mandibular nerve passes through the infratemporal space, it gives off the buccal nerve to the cheek (lateral to the ramus). Before entering the mandibular foramen, the mandibular nerve (medial to the ramus) gives off a lingual nerve branch that passes to the tongue. The inferior alveolar nerve enters the mandibular foramen (and canal) where it and its terminal incisal branch give off branches through the spongy bone to all mandibular teeth.

many small **dental branches** that spread through trabecular (spongy) bone of the mandible in order to enter the apical foramen of all mandibular molars and premolars. It also innervates the periodontal ligaments and alveolar processes of these teeth. While within the mandibular canal, the inferior alveolar nerve splits near the roots of the premolars to become the mental nerve and the incisive nerve. The **incisive nerve** (Fig. 14-43) branch continues forward within the mandibular canal to supply the mandibular incisor and canine teeth, their periodontal ligaments, and surrounding alveolar process. The **mental nerve** branch of the inferior alveolar nerve exits from the body of the mandible through the **mental foramen** (Fig. 14-41) and supplies the facial gingiva of the mandibular incisors, canines, and premolars and the mucosa and skin of the lower lip and chin on that side up to the midline (Fig. 14-37).

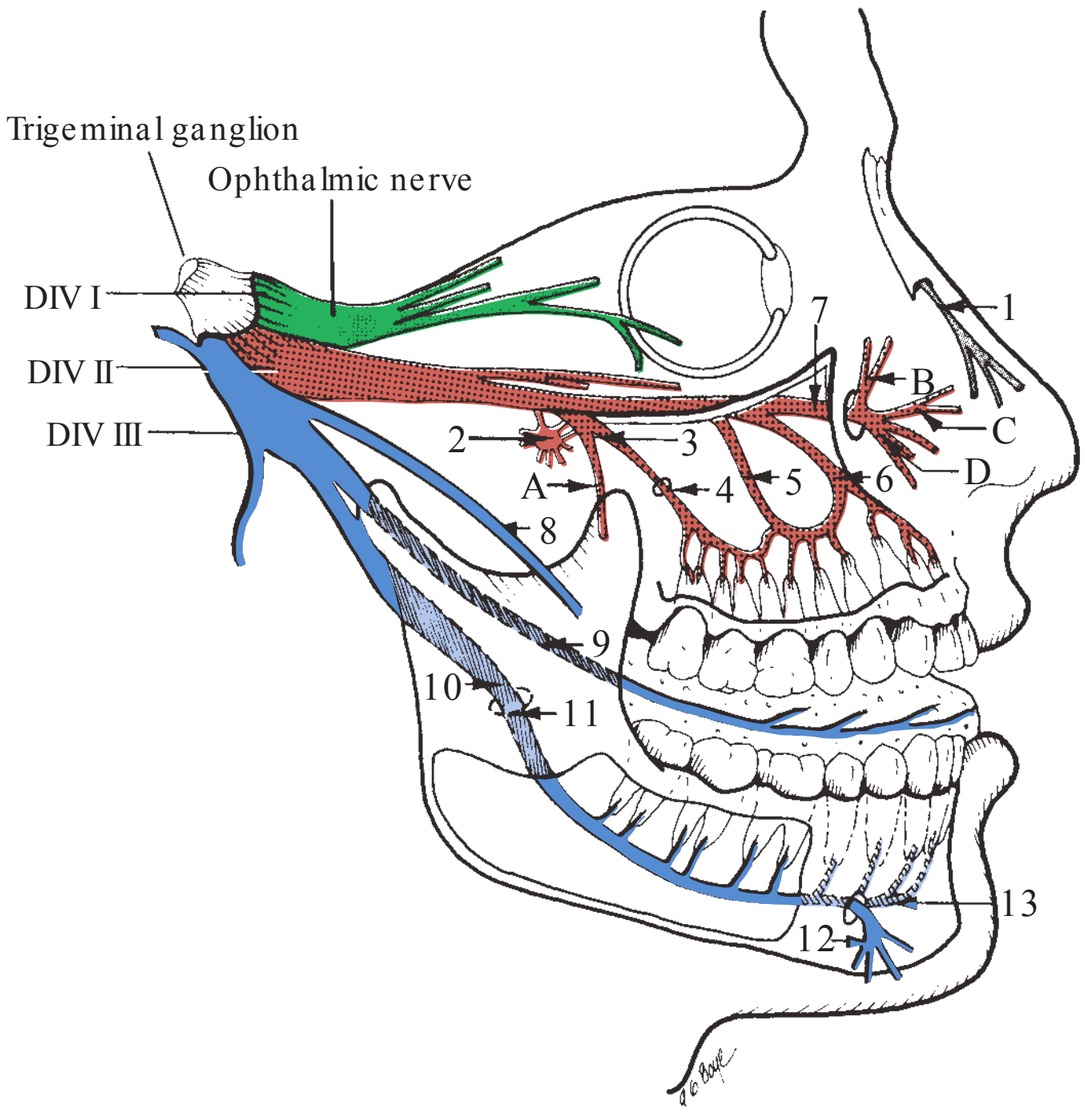

1. External nasal nerve
2. Pterygopalatine ganglion
3. Posterior superior Alveolar nerve
   A. Gingival branch
4. Alveolar canal
5. Middle superior alveolar nerve
6. Anterior superior alveolar nerve
7. Infraorbital nerve
   B. Palpebral branches
   C. Nasal branches
   D. Labial branches
8. Buccinator nerve to cheek (in front of ramus)
9. Lingual nerve (behind ramus)
10. Inferior alveolar nerve (behind ramus)
11. Mandibular foramen
12. Mental nerve (branch of inferior alveolar)
13. Incisive nerve (branch of inferior alveolar)

FIGURE 14-43. Trigeminal nerve distribution of the branches of the maxillary and mandibular divisions. The ophthalmic branches are shaded green, the maxillary nerve and branches are shaded red, and the mandibular nerve and branches are shaded blue. Note that the buccinator (long buccal) branch (labeled No. 8) of the mandibular division passes superficial to the ramus to enter the cheek, whereas the lingual nerve (labeled No. 9) and inferior alveolar nerve (labeled No. 10) pass medial to the ramus as they go to the tongue and mandible, respectively. Also, note that the infraorbital branch of the maxillary division gives off the MSA (labeled No. 5) and ASA branches (labeled No. 6) while in the infraorbital canal on the floor of the eye orbit (roof of the maxillary sinus).

Note that if an anesthetic solution is deposited next to the opening of the mandibular foramen, it could block the passage of sensory nerve signals from all mandibular teeth on that side (by blocking the inferior alveolar and its terminal incisive branch) and also the skin of the chin and lip area (because another terminal branch, the mental nerve, has also been blocked). Further, since the lingual nerve is in close proximity to the mandibular foramen, its fibers may also be blocked, causing that side of the floor of the mouth, lingual gingiva, and anterior two thirds of the tongue to lose feeling. The only part of the mandible that would not be numb would be the tissue buccal to the molars, which requires some additional anesthetic solution in the cheek to block the buccal nerve.

Figures 14-43 and 14-44 and Table 14-3 can be used to help summarize the distribution of the mandibular and maxillary sensory nerve branches to all teeth and surrounding tissues of the mouth.

Motor (efferent) branches of the mandibular nerve supply the muscles of mastication: the **masseteric nerve** to the masseter muscle, as well as to the TMJ, **the posterior and anterior temporal nerves** to the temporalis muscle, the **medial pterygoid nerve** to the medial pterygoid muscle, and the **lateral pterygoid nerve** to the lateral pterygoid muscle.

LEARNING EXERCISE

Referring to Table 14-3, cover one column at a time, and see how many branches of the trigeminal nerve you can recall that innervate the pulps, gingiva, periodontal ligaments and alveolar processes, and hard palate in each area of the mouth. These are the nerves any dental student, dental hygiene student, or graduate of either profession should be most familiar with. You should also be able to determine the location of each nerve.

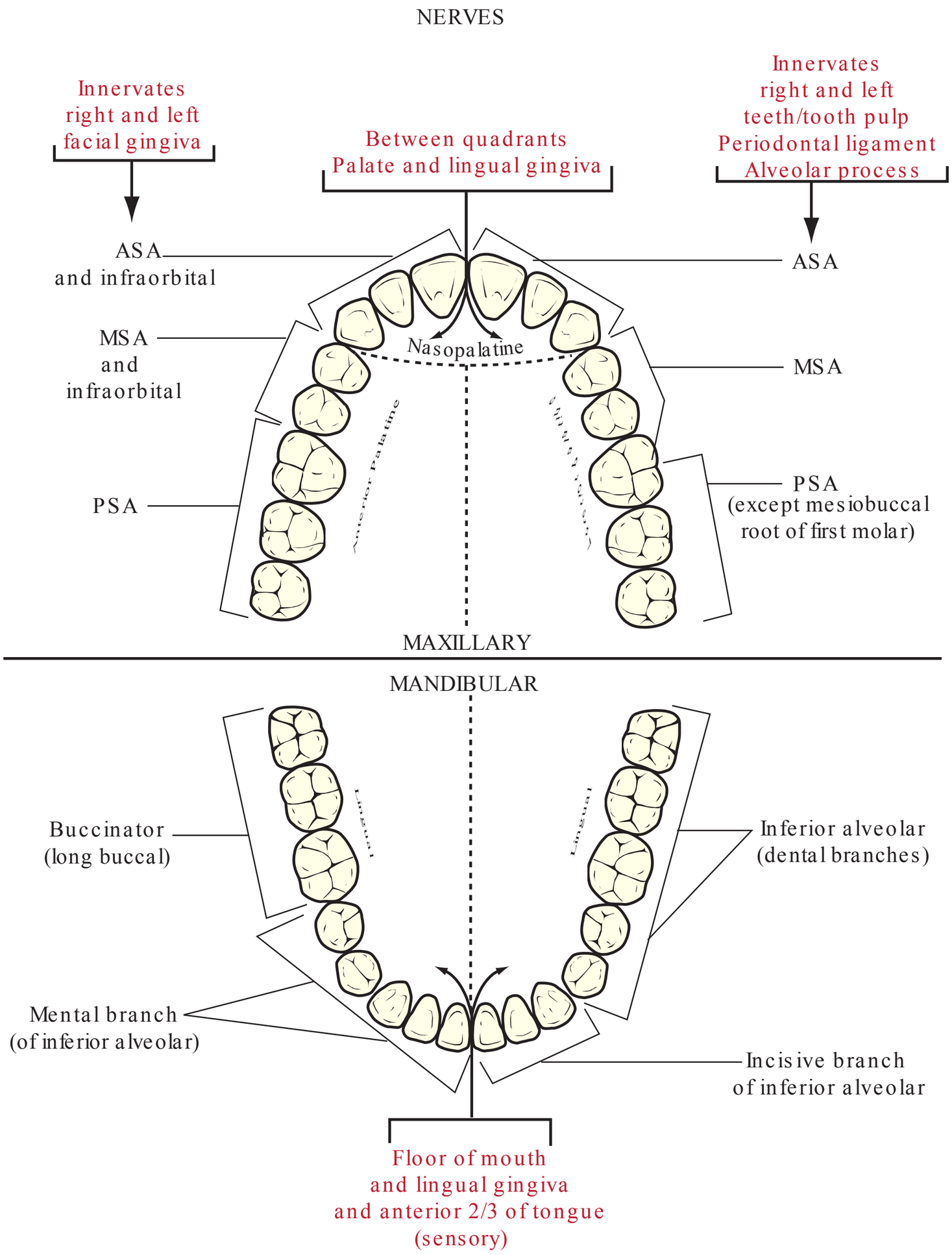

FIGURE 14-44. A summary of the distribution of branches of the trigeminal nerve (CN V) that innervate the tissues of the mouth. Nerves listed on the left side of the diagram supply facial gingiva on both the right and the left side of the face; nerves listed on the right side of the diagram supply the teeth, tooth pulps, periodontal ligaments, and alveolar processes on both sides of the face. Nerves to the lingual and palatal mucosa are identified medial to the teeth.

TABLE 14-3 Distribution of Branches of Trigeminal Nerve to the Teeth and Surrounding Structures

TEETH	TOOTH PULP	GINGIVA	PERIODONTAL LIGAMENT AND ALVEOLAR PROCESS	
		MAXILLARY ARCH		PALATE
Anterior teeth	ASA nerve	Palatal: nasopalatine nerve Labial: infraorbital and ASA nerves	ASA nerve[a]	Nasopalatine nerve
Premolars	MSA nerve	Palatal: anterior palatine nerve Buccal: MSA and infraorbital nerves	MSA nerve[a]	Anterior palatine nerve
Molars	PSA nerve except mesiobuccal root of first (supplied by MSA nerve)	Palatal: anterior palatine nerve Buccal: PSA nerve	PSA nerve[a]	Anterior palatine nerve Soft palate: middle and posterior palatine nerve
		MANDIBULAR ARCH		FLOOR OF MOUTH
Anterior teeth	Incisive branch of the inferior alveolar nerve	Lingual: lingual nerve Labial: mental nerve	Incisive nerve	Lingual nerve
Premolars	Dental branch of inferior alveolar nerve	Lingual: lingual nerve Buccal: mental nerve	Dental branch of inferior alveolar nerve	Lingual nerve
Molars	Dental branch of inferior alveolar nerve	Lingual: lingual nerve Buccal: buccinator nerve (long buccal nerve)	Dental branch of inferior alveolar nerve	Lingual nerve

[a]Also supply the maxillary sinus.

B. FACIAL NERVE (SEVENTH CN)

The **facial nerve** is a mixed nerve (sensory and motor). From the brain, the facial nerve penetrates the petrous portion of the temporal bone through the **internal acoustic meatus** (Fig. 14-45) and exits from the skull between styloid and mastoid processes through the **stylomastoid foramen** (in blue on Fig. 14-46). It passes through the parotid gland. **Efferent motor** [EF er ent] **fibers** innervate muscles of facial expression (including the orbicularis oris) and visual expression of the face and the scalp. Other muscles supplied by the facial nerve include the posterior belly of the digastric muscle and stylohyoid muscle (in blue on Fig. 14-35), the platysma muscle (a broad, thin superficial muscle that covers much of the anterior part of the neck, seen in Fig. 14-36), and the stapedius muscle (in middle ear cavity). None of these muscles has any influence on moving the mandible. Efferent **secretory fibers** stimulate secretions from two pairs of salivary glands: the sublingual glands located just under the mucosa in the floor of the mouth superior to the mylohyoid muscle and the submandibular glands located in the submandibular fossae on the medial surface of the mandible inferior to the mylohyoid muscle.

Afferent sensory [AF er ent] **fibers** of the facial nerve (**chorda tympani branch**) branch off within the petrous portion of the temporal bone (in blue on Fig. 14-46). They course through the tympanic cavity eventually exiting of the skull by way of the **petrotympanic** [PET ro tim PAN ik] **fissure**. These chorda tympani fibers of the facial nerve join with the lingual nerve (branch of the mandibular division of the trigeminal nerve) and supply the sense of taste to the anterior two thirds of the tongue (the body and the tip of the tongue).

Advanced topics about taste buds: There are approximately 8000 to 9000 taste buds in the young adult, more in children, and fewer with advancing age. Originally, four primary tastes were identified: sour (acid), sweet, salty, and bitter.[31] Some authors add alkaline and metallic to the taste senses. (Others are currently citing a unique taste associated with monosodium glutamate [amino acids] called umami.[32]) Early research on taste was interpreted by mapping the tongue for the quality of taste sensed in each area: the tip of the tongue is where one best distinguishes sweet, salty, or alkaline substances, and the sides of the tongue are most sensitive to sour (acidic) substances.[31] However, newer research has shown that cells within each taste bud may respond to multiple tastes, but the sense of taste in each area

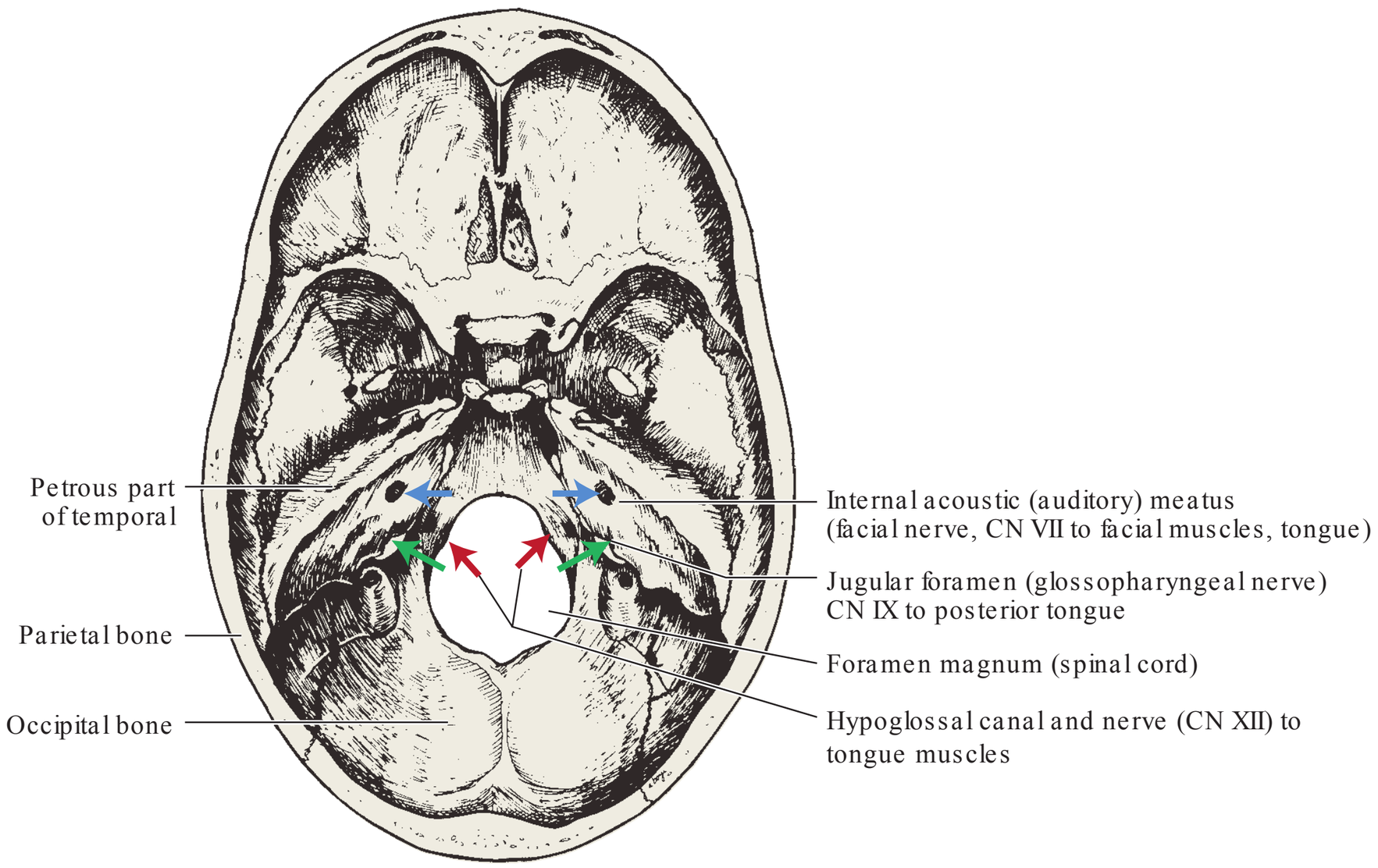

fIGur E 14-45. Foramen for CNs VII (**f**acial), Ix (**g**lossophar**y**n**g**eal), and xII (h**y**po**g**lossal) that exit the braincase through bones lining the neurocranium. Arrows indicate the location of the facial nerve that passes through the internal aco**u**stic **f**oramen (blue), the glossopharyngeal nerve that passes through the j**ugu**lar **f**oramen (green), and the hypoglossal nerve branches that pass through the h**y**po**g**lossal canals (red) (not visible but on the lateral walls of the foramen magnum).

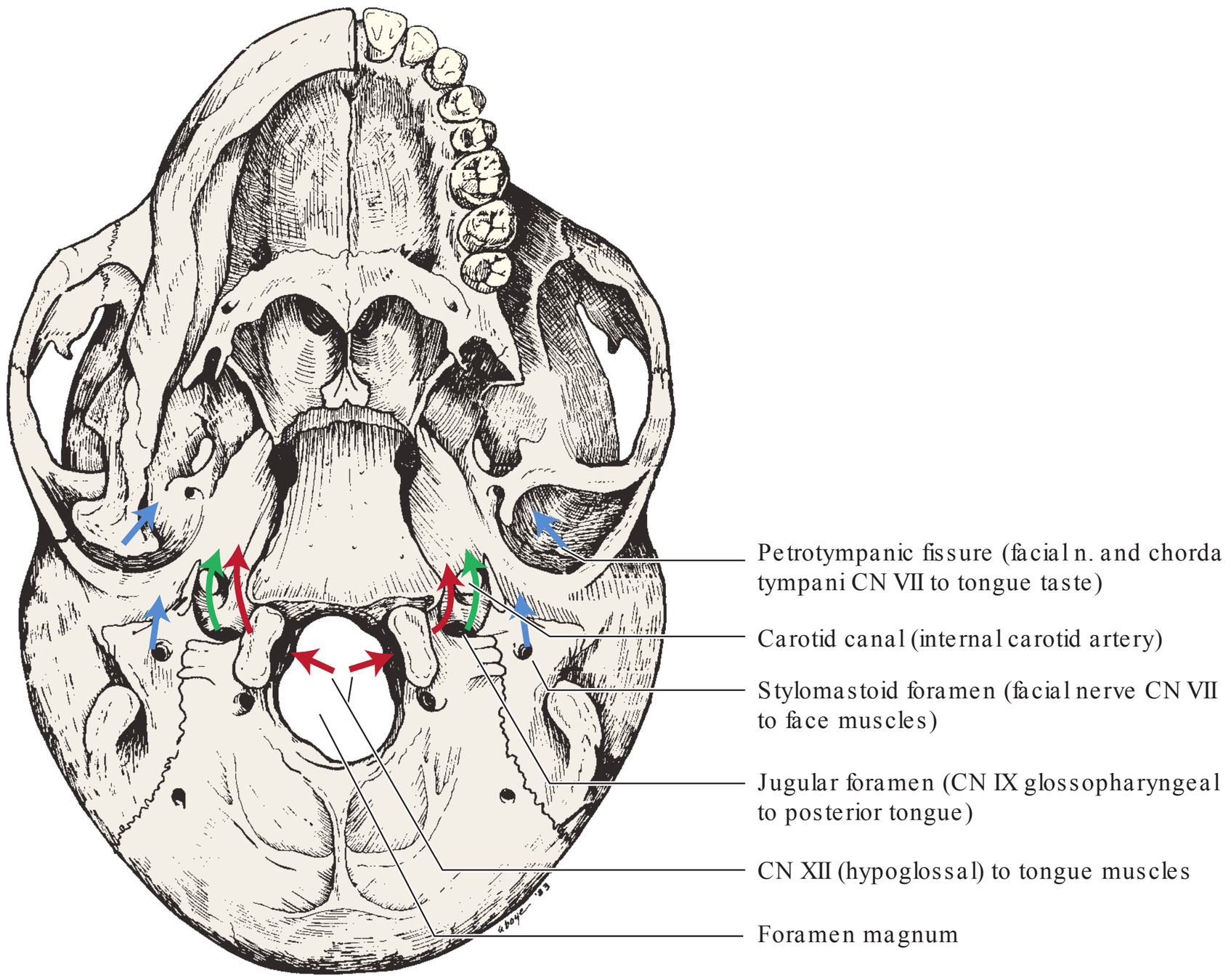

fIGur E 14-46. Foramen for CNs VII (**f**acial), Ix (**g**lossophar**y**n**g**eal), and xII (h**y**po**g**lossal) viewed on the inferior surface of the neurocranium. One part of the facial nerve exits through the st**y**lomastoid **f**oramen (blue) and another small branch exits through the petrot**y**mpanic **fi**ss**u**re (blue) where it joins up with the lingual branch of the trigeminal nerve to provide the anterior two thirds of the tongue with feeling (trigeminal nerve neurons) and taste (facial nerve neurons). The glossopharyngeal nerves exit through the j**ugu**lar **f**oramen (green). The hypoglossal nerves exit through the h**y**po**g**lossal canals (red). Also, note the carotid canal where the internal carotid artery enters the braincase.

of the tongue is dependent upon the intensity of each taste. (An excellent discussion of taste is found in the chapter by Travers and Travers in the text edited by Cummings that is cited at the end of this chapter.)

C. Glossopharyngeal Nerve (Ninth CN)

The **glossopharyngeal** [GLOSS o feh rin JI al] **nerve** exits from the skull via the **jugular** [JUG yoo lar] **foramen** (in green on Figs. 14-45 and 14-46). It then passes down and forward to enter the tongue. It is a mixed nerve (sensory and motor) and supplies parts of the tongue and pharynx.

The **afferent** fibers of this nerve supply the sense of taste and sensation of feeling (touch and pain) to the posterior one third of the tongue and general sensation to the mucosa of the pharynx and tonsils. (Bitter sensations are prominent on the dorsal [top] surface in the region of the circumvallate papillae on the posterior third of the tongue. Additional taste buds can be found in other structures in the back of the mouth, such as the pillars of the fauces, hard and soft palate, epiglottis, and pharynx.[31,33]) The motor fibers of the glossopharyngeal nerve innervate the stylopharyngeus muscle of the pharynx.

Other secretory fibers innervate the parotid gland, influencing secretion. This gland is located in front of each earlobe in the cheek tissues just inferior to the zygomatic arch (seen later in Fig. 14-48). (Hint: Glossopharyngeal means glosso [tongue] + pharyngeal [pharynx or throat]).

D. Hypoglossal Nerve (12th CN)

The **hypoglossal nerves** exit from the skull through the **hypoglossal canals** just above the **occipital condyles** near the anterior border of the large **foramen magnum** visible inside the walls of the foramen magnum (in red on Fig. 14-46). This motor nerve descends steeply to the muscles that move the tongue. (These are genioglossus, styloglossus, hyoglossus, longitudinal, vertical, and transverse.) If this nerve becomes damaged from injury or tumor, the tongue will deviate noticeably toward the affected side. (Hint: Hypoglossal means hypo [beneath; like a hypodermic needle] + glossal [tongue].)

E. Summary Of Nerve Supply TO The TONGue, Salivary GlaNdS, faCIal SkIN, aNd faCIal muSCleS

1. Nerves providing General Sensation (Touch and pain) to the Tongue

- Trigeminal nerve (fifth CN): The lingual nerve branch of the mandibular division provides general sensation of touch and pain to the anterior two thirds (body) of the tongue.
- Glossopharyngeal nerve (ninth CN) is responsible for general sensation (touch, pain) in the posterior one third (or root) of the tongue.

2. Nerves for Taste in the Tongue

- Facial nerves (seventh CN): Chorda tympani branches provide taste sensation to anterior two thirds (body) of tongue.
- Glossopharyngeal nerve (ninth CN) is responsible for taste in the posterior one third (or root) of the tongue.

3. Nerves to the Tongue muscles

- Hypoglossal nerve (twelfth CN) supplies motor fibers to the muscles of the tongue.

4. Nerves to the major muscles of mastication

- Trigeminal nerve (fifth CN): The motor branches of the mandibular division supply the masseter (masseteric nerve), the temporalis (temporalis nerves), and the medial and lateral pterygoid (pterygoid nerve branches).

5. Nerves to most muscles of facial Expression

- Facial nerve (seventh CN) supplies most muscles of facial expression.

6. Secretory fibers to Salivary Glands

- Facial nerves (seventh CN) supply the submandibular and sublingual salivary glands.
- Glossopharyngeal nerve (ninth CN) supplies the parotid salivary glands.

7. Nerves to the Skin of the face

- Trigeminal (fifth CN) supplies all sense of feeling (touch/pain) to the skin of the face through branches of the ophthalmic division (upper face), maxillary division (middle face), and mandibular division (lower face).

LEARNING EXERCISES

- Describe the pathway of the branches of the mandibular division of the fifth CNs as they pass from the brain toward their target organs (especially the teeth and surrounding soft tissue). Name the location where branches split off of the main nerves, and name the foramina through which each branch passes. Then, if it is possible on your study skull, take a pipe cleaner and carefully pass it through the foramina to show the passageway of these nerves. Think about where these nerves might be reached by an anesthetic syringe needle and what structures would be anesthetized if anesthetic deposited in that location blocked nerve impulses from all branches of that nerve that are farther away from the brain.
- Repeat the previous exercise for the branches of the maxillary division.
- Sketch the dorsal view of the tongue and label which nerves innervate the anterior two thirds and posterior one third for general sensation, taste, and movement (muscles).
- List all 12 CNs in order and state their functions.
- Review all words in bold that have phonetic spelling to confirm that your pronunciation is correct.

Review Questions

Select the one best answer.

1. The branches of which nerve cause the masseter muscle fibers to contract, thus squeezing the teeth together?
   a. CN V: maxillary division
   b. CN V: mandibular division
   c. CN V: ophthalmic division
   d. Facial nerve
   e. Lingual nerve

2. Which of the following nerve branches does **not** need to be anesthetized in order to block the sensation of pain to the pulp and all surrounding bone and gingiva of tooth #27 prior to an extraction?
   a. Buccal nerve
   b. Mental nerve
   c. Incisive nerve
   d. Inferior alveolar nerve
   e. Lingual nerve

3. Which two nerves branch off the infraorbital nerve while it is in the infraorbital canal?
   a. MSA and PSA
   b. ASA and MSA
   c. PSA and ASA
   d. MSA and nasopalatine
   e. Nasopalatine and greater palatine

4. Anesthetizing nerve fibers of what nerve results in numbness in half of the anterior two thirds of the tongue?
   a. Hypoglossal nerve
   b. Glossopharyngeal nerve
   c. Lingual nerve branch of the trigeminal nerve
   d. Lingual nerve branch of the facial nerve

5. The nerve branch of the trigeminal that provides pain sensation to the mandibular teeth exits the skull through what foramen?
   a. Foramen ovale
   b. Foramen rotundum
   c. Mandibular foramen
   d. Mental foramen
   e. Infraorbital foramen

a–5; c–4; b–3; a–2; b–1: Sr E wS Na

Critical Thinking

Bell palsy is a condition that causes weakness or paralysis of the seventh cranial nerve (CN VII), which affects the muscles of facial expression on one side of the face. Imagine what might happen to the face with this condition, and then, search the computer for images of "Bell palsy" to observe the effect of damage to the motor part of this nerve.

SECTION v Vessels Associated with the Oral Cavity (Arteries, Veins, and Lymph Vessels)

Objectives

The objectives for this section are to prepare the reader to perform the following:

- Trace blood through the major blood vessels (arteries) from the heart to the teeth and back (through major veins) to the heart.
- Describe the pathway (fossa, spaces, etc.) of the key arteries that supply the teeth and, where possible, feel the pulse.
- Trace the route of infection from teeth and associated oral structures as it passes through the lymph system.
- Palpate the location of lymph nodes associated with the spread of infection of the oral cavity.

Arteries that move blood from the heart to the face and oral cavity meet up with nerves from the brain that innervate the face and oral cavity. Arteries and nerves of the same name begin to parallel one another somewhere in the neck or on the face. They may pass through the same foramen and canals within bones after they meet. Generally, arteries of the face and jaw run a more wiggly or corkscrew course than do veins.

Arteries

Refer to the pathway of blood from the heart to the teeth in Figure 14-47. Blood courses from the left ventricle of the heart through the aorta to the common carotid artery, which ascends in the neck and divides into the **external carotid** [kah ROT id] **artery** (Fig. 14-48) and internal carotid artery. The external carotid artery gives off the **maxillary branches**

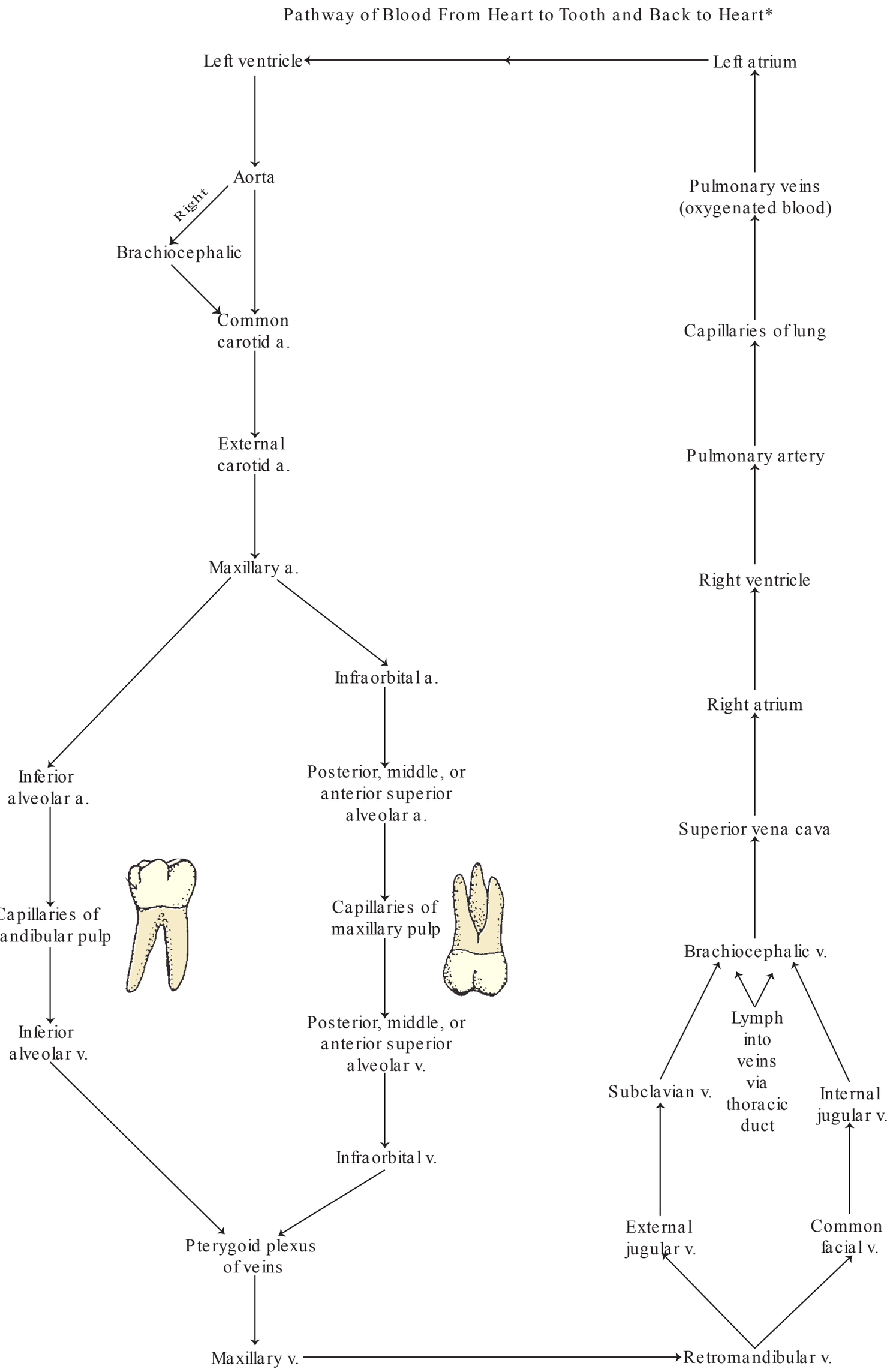

*Think in terms of a drop of blood making this round trip.

FIGURE 14-47. Pathway of blood from the heart to the teeth and back to the heart.

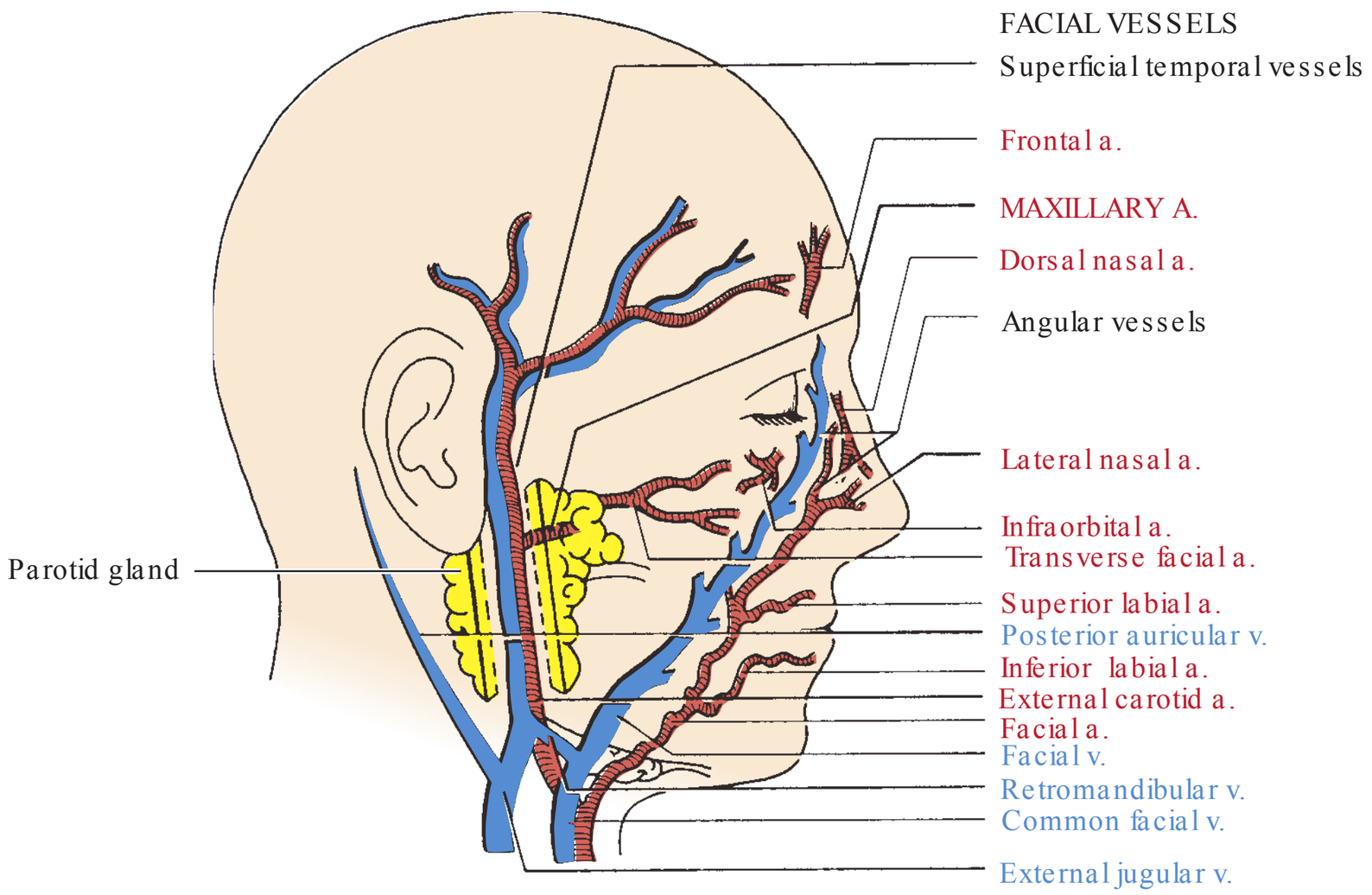

fIGur E 14-48. **F**acial vessels. The parotid gland (yellow) is split apart to show the e**x**ternal carotid arter**y**, with the ma**x**illar**y** arter**y** coming off and passing deep to this gland. Arteries are shaded red; veins are blue.

supplying structures in the mouth (maxillary and mandibular), and the internal carotid artery enters the skull through the carotid canal and does not supply the mouth. You can feel the pulse of the external carotid just in front of the sternocleidomastoid muscle as required during cardiopulmonary resuscitation training.

As the external carotid passes superiorly, it gives off three important branches to the mouth: the lingual, facial, and maxillary arteries. First, the **lingual artery** (not seen on Fig. 14-48) comes off near the hyoid bone and then enters the tongue. Like the lingual nerve, this artery supplies the floor of the mouth, adjacent gingiva, and the sublingual gland.

Second, the **facial artery** (Fig. 14-48) comes off near the lingual artery. It then passes forward obliquely inferior to the submandibular gland and then laterally around the lower border of the mandible. T e facial artery and facial nerve pass together through a shallow notch on the inferior border of the mandible just anterior to the insertion of the masseter muscle. T is notch is called the **antegonial notch** (recall Fig. 14-14). T is is an important landmark to be aware of so that you will be able to stop the flow of blood to the lower part of the face in an emergency. Try to find the facial artery in the antegonial notch with your finger or thumb. You should feel the pulse of the facial artery if you are in the correct spot. From here, the facial artery goes upward over the outer surface of the mandible to the face.

T ere are four branches of the facial artery. Two branches come off before it passes onto the face. First, the **ascending palatine artery** ascends to supply structures adjacent to the pharynx (including the soft palate, the pharyngeal muscles, the mucosa of the pharynx, and the palatine tonsil), and second, the **submental artery** converges with the mylohyoid nerve to supply structures in the floor of the mouth (such as the mylohyoid muscle, anterior belly of the digastric muscle, and lymph nodes inferior to the mylohyoid muscle). After passing onto the face, the **inferior and superior labial arteries** (branches) (Fig. 14-48) surround and supply the lips and the orbicularis oris muscle, and finally, **lateral nasal and angular arteries** are the terminal branches of the facial arteries.

T ere is considerable merging at the midline of the arteries from both sides of the face, rather than the more conventional system whereby an artery terminates with many small capillaries. T is merging of small arteries from opposite sides is called an end-to-end anastomosis [a NAS te MO sis]. One example is where the right and left superior and inferior labial arteries join at the midline. As one might guess, such an anastomosis can cause problems in arresting hemorrhage on the face.

MAXILLARY ARTERY: T e third branch of the external carotid artery is the **maxillary artery**, which is probably the most important artery to the dentist and dental hygienist. It arises from the external carotid within the parotid gland (Fig. 14-48). T e branches of this artery can be considered in three parts as shown in Figure 14-49. T e branches of the mandibular and pterygopalatine part (or first and third parts) are directly involved with the blood supply to the mandibular and maxillary teeth, respectively. T e branches of the pterygoid part (or middle part) provide blood to the four pairs of muscles of mastication. Study Figure 14-49 as you read about the following branches of each part of the maxillary artery. Also, notice the similarity between the names of the vessels and the names of the nerves that supply the same structures.

- **Mandibular Part of the M axillary Artery:** Arteries labeled in red in Figure 14-49

  Branches coming off of the mandibular (or first) part of the maxillary artery supply the mandibular teeth and their periodontal ligaments. You read correctly: branches of the maxillary artery supply the mandible. T e **inferior alveolar artery**, which, like the inferior alveolar nerve, enters the mandible through the mandibular foramen,

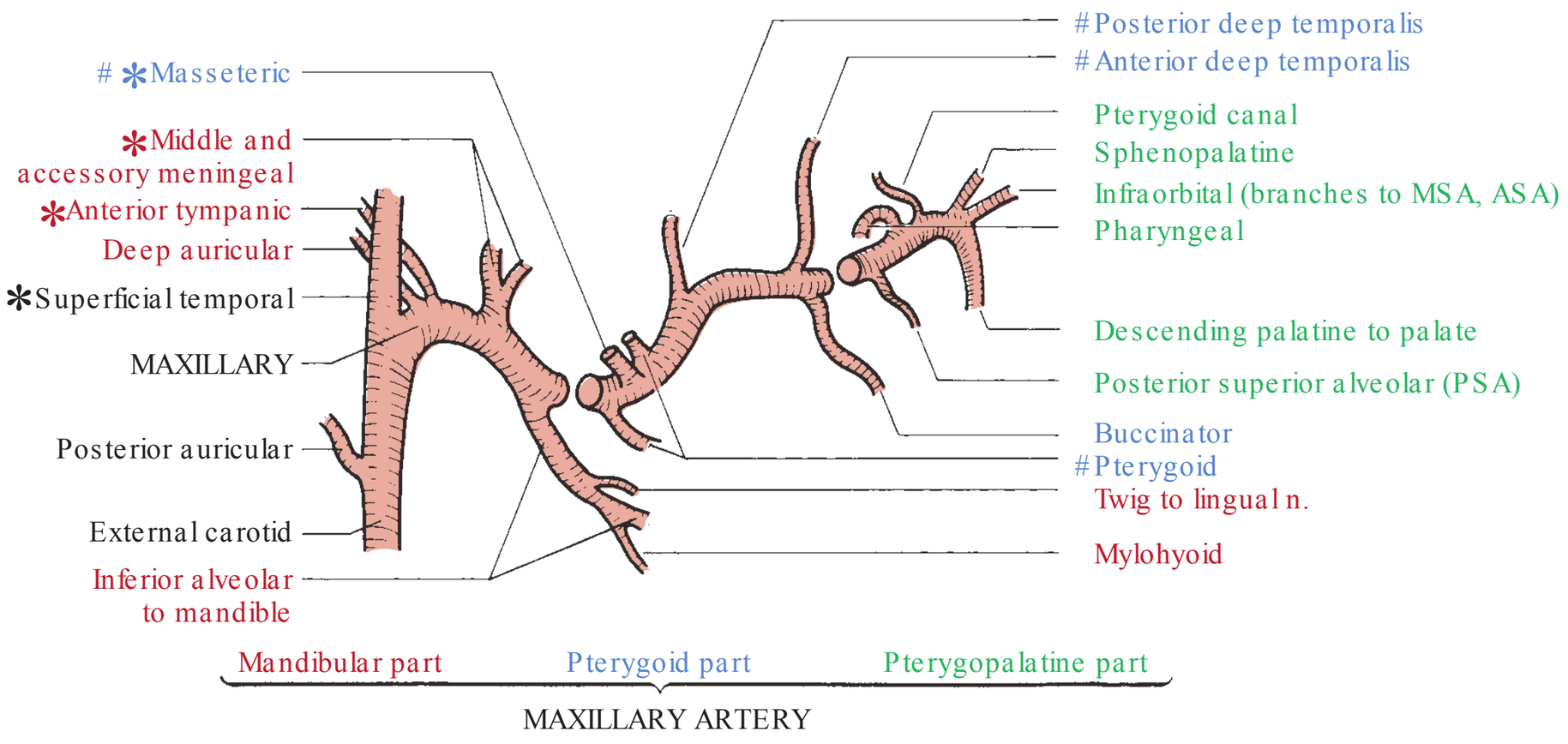

fIGur E 14-49. Ma**x**illar**y** arter**y** and the branches of its three major parts. The branches of the mandib**u**lar part (red print) supply blood to the mandible and teeth, the pter**yg**oid part (blue print) supplies the muscles of mastication, and the pter**yg**opalatine part (green print) supplies the maxillae and teeth. Vessels labeled with (*) are branches to the TMJ. Branches labeled with (#) supply blood to muscles of mastication.

supplies branches to the mandibular molars and premolars. It then divides into two branches: the **mental artery**, which exits from the mental foramen to the lower lip and chin, and the **incisive artery,** which continues forward within the mandible to supply the anterior teeth (similar to the path of nerves of the same name seen in the mandible in Fig. 14-43).

- **Pterygoid Part of the Maxillary Artery**: Arteries to the muscles labeled in blue in Figure 14-49

  Branches coming off of the pterygoid (or second) part of each maxillary artery are not involved directly with the teeth but supply blood to the muscles of mastication (posterior and anterior deep temporalis, masseteric, and pterygoid branches labeled with (#) in Fig. 14-49) and a buccinator branch.

- **Pterygopalatine Part of the Maxillary Artery**: Arteries to the maxillae labeled green in Figure 14-49

  Branches that come off of the pterygopalatine (or third) part of the maxillary artery supply the maxillary teeth and their periodontal ligaments. T e **PSA artery** traverses the maxillary sinus and, like the PSA nerve, supplies the maxillary molars. While within the infraorbital canal, the **infraorbital artery**, like the infraorbital nerve, gives off the **MSA artery** that supplies the premolars and the **ASA artery**, which supplies the anterior teeth. Each **descending palatine** branch of the maxillary artery supplies part of the nasal cavity before it emerges onto the palate through the greater palatine foramen (Fig. 14-39) like the nerves to supply the mucosa of the hard and soft palate and the lingual gingiva. Its terminal part ascends through the incisive canal into the nasal cavity.

T e TMJ is supplied with oxygenated blood from five branches labeled with (*) in Figure 14-49: the ascending pharyngeal (not visible in figure) and superficial temporal branches of the external carotid artery and by the anterior tympanic, masseteric, and middle meningeal branches of the maxillary artery (Fig. 14-49).

B. vEINS

Veins tend to be straighter than arteries.[11,34] In many instances, they travel almost the same course as arteries. Veins that drain blood from the face on its way back to the heart are shown in Figure 14-50.

Numerous deep veins drain blood from the upper part of the face, the tissue of the lips and muscles around the mouth, the posterior part of the nasal cavity, the palate, the maxillary alveolar process, and maxillary teeth into a **pterygoid** [TER i goid] **plexus** of veins. Also, **inferior alveolar veins** carry blood to the pterygoid plexus from the mandible and its teeth, that is, from the area of the oral cavity supplied by the inferior alveolar artery (and the area innervated by the inferior alveolar nerve). T e pterygoid plexus is a network of thin-walled veins medial to the upper part of the ramus of the mandible, located between the temporal and lateral pterygoid muscles or between the lateral and medial pterygoids.[34] T e dense venous plexus that surrounds the maxillary artery helps protect the artery from becoming flattened when the masticatory muscles contract. During muscle contractions, however, blood is driven from the veins.[34]

It was previously thought that an infection in the face could travel through veins in either direction because of the lack of valves in these veins. Now, we know that facial veins do have valves, but infection of the teeth and associated oral structures can spread due to the interconnection of superficial and deep veins of the face into the pterygoid plexus of veins and then to other tissues and organs. Also, the pterygoid plexus of veins connects with another collection of thin-walled veins called the **cavernous sinus** located on the base of the brain. If infection reaches the cavernous sinus, it can spread to the brain with life-threatening effects.

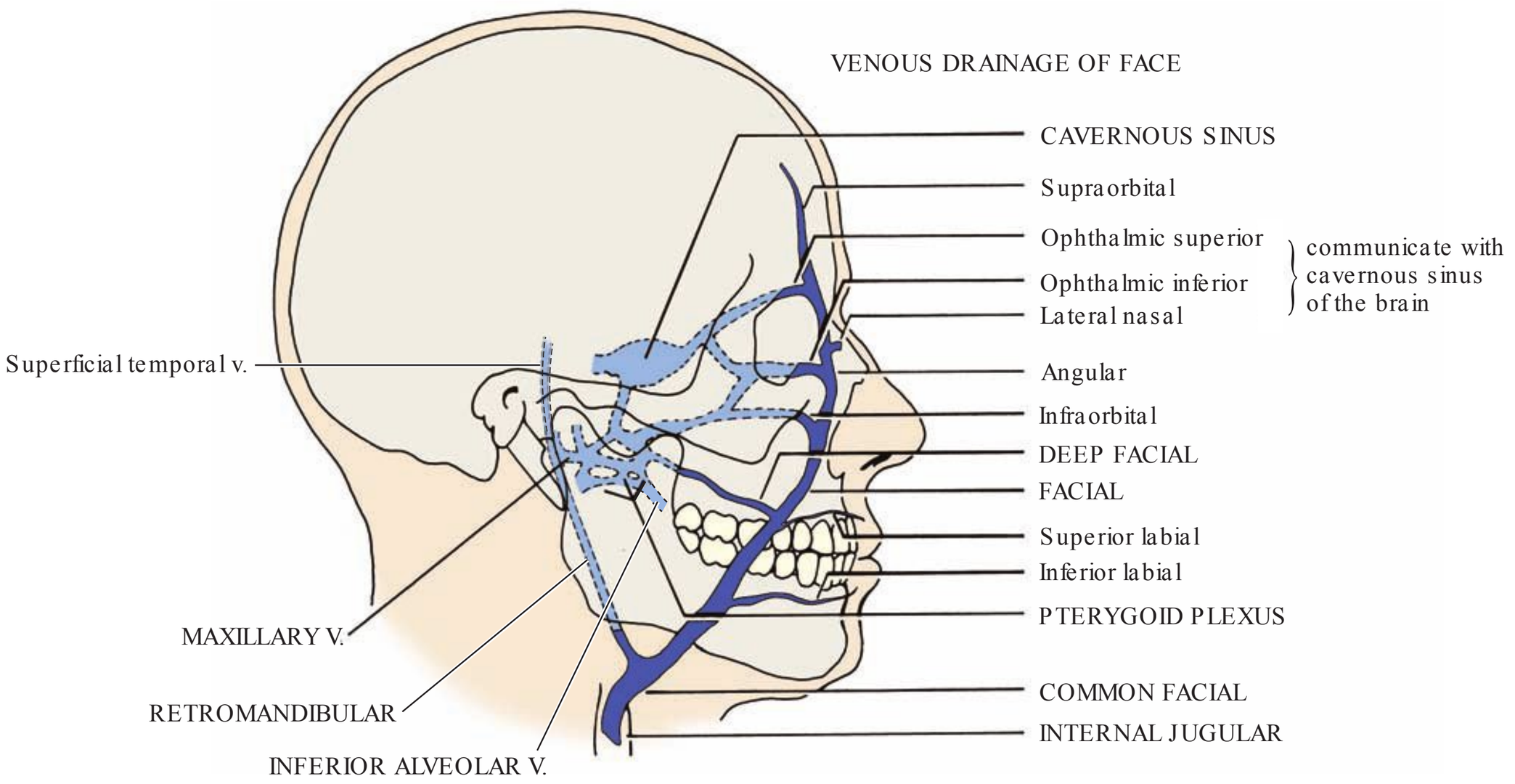

fIGur E 14-50. Venous drainage of the face (blue). The dotted light blue lines represent deeper (less superficial) vessels. Notice how many veins come together in the pterygoid plexus of veins, an area prone to bleeding if the anesthetic syringe cuts any vessel wall within this plexus.

T e veins of the pterygoid plexus empty into the short **maxillary vein.** While within the parotid gland, blood from the maxillary vein (and from the superficial temporal vein) passes into the **retromandibular vein** to drain those areas that had received blood through the maxillary and superficial temporal arteries. T e retromandibular vein drains into the facial vein where it becomes the short **common facial vein** that then empties into the **internal jugular vein**.

An important superficial vein that also drains blood from the face is the **facial vein**, which roughly follows the course of the facial artery but, of course, carries blood in the opposite direction. T e facial vein receives blood from the area around the eyes and nose (via the angular and lateral nasal veins) and receives blood from the lips (via the superior and inferior labial veins). It can also receive blood from the muscles of mastication. Just like the retromandibular vein, the facial vein empties through the common facial vein into the internal jugular vein. Blood from the tongue drains through **lingual veins** (not visible on Fig. 14-50) that also empty into the internal jugular vein (possibly via the common facial vein).

Venous drainage of the face becomes even more complex when you consider that there is a **deep facial vein,** which connects the deeper pterygoid plexus with the more superficial facial vein. T erefore, blood from the head can make its way down to the internal jugular vein either through the pterygoid plexus and retromandibular vein or through the facial vein and its branches.

Once blood reaches the internal jugular vein, it passes into the brachiocephalic vein to the superior vena cava and then through the heart and lungs to become oxygenated before being pumped back to the mouth (Fig. 14-47).

LEARNINg ExERCISES

Draw the route of a drop of blood from the heart to both maxillary and mandibular teeth and then back to the heart as shown in Figure 14-47. Name each vessel along the way. Try to visualize this interesting round trip, which takes place about every 10 to 15 seconds. Remember, the maxillary artery and its branches are probably the most important to the dentist or dental hygienist.

C. lymph vESSEl S

T e lymph system is somewhat more complex[35] since it serves to collect tissue fluid that got outside of blood capillary beds and then return this fluid to the vascular system. In the arterial side of a capillary bed, blood pressure exceeds osmotic pressure, so fluid escapes into the tissue spaces. On the venous side of each capillary bed, the blood pressure is lower, and the osmotic pressure becomes higher, forcing 90% of the tissue fluid back into the venous capillary bed.[36] T e major bulk of the remaining 10% of the fluid is the lymph, which passes into the lumen of lymph capillaries and is then collected in the nodes (shown in Fig. 14-51) and returned to the blood vascular system.

During times of infection, trauma, or cancerous growth, abnormal amounts of fluids escape (along with specialized cells to fight infection, etc.), and this results in swollen lymph glands. Since lymph nodes form chains that are then connected by lymph vessels, infection spreads predictably from the site of infection to a specific lymph node, which then drains to another until the lymph system empties back into the veins. Refer to Figure 14-51 while studying the spread pattern described here.

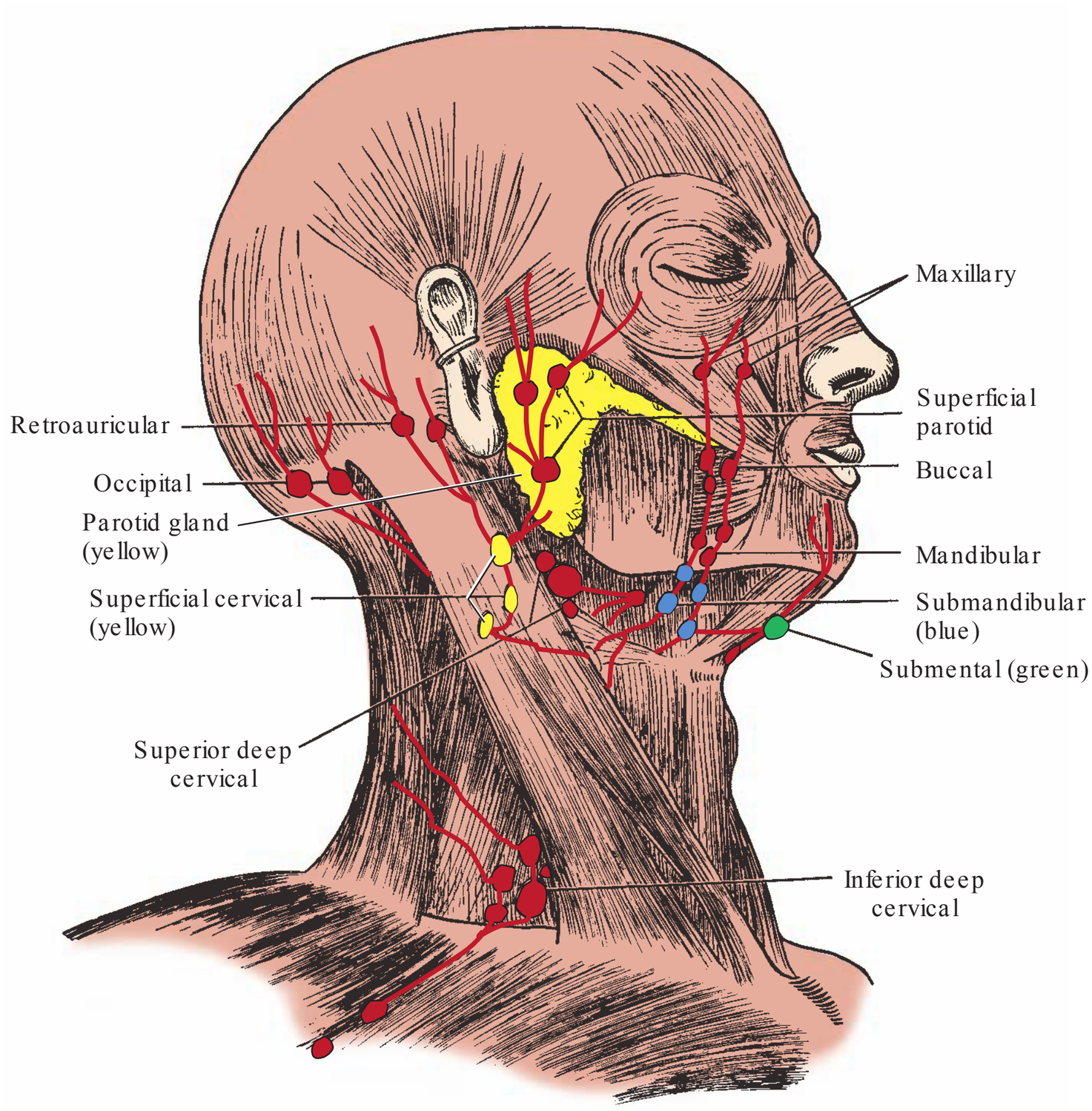

fIGur E 14-51. L**y**mph nodes o**f** the head and neck. These areas should be palpated during a head and neck examination. S**u**bmental nodes are green, s**u**bmandib**u**lar nodes are blue, and s**u**perf**i**cial cervical nodes are yellow. (Reproduced from Clemente CD, ed. Gray's anatomy of the human body. 30th ed. Philadelphia, PA: Lea & Febiger, 1985:880, with permission.)

Infection in the area of the chin and adjacent structures including the tip of the tongue and tissues surrounding the mandibular incisors—anterior floor of the mouth, lower lip, and adjacent gingiva (gum tissue)—all drain into the **submental nodes** just lingual to the mandibular symphysis area. When enlarged, these nodes can be palpated just posterior to the symphysis area of the mandible.

T e **submandibular chain of nodes** is located over the surface of the submandibular salivary gland and can be palpated medial but anterior to the angle of the mandible, with the most prominent node in this chain located over the facial artery medial to the antegonial notch. T e **submental nodes** drain into the submandibular nodes. Also, the submandibular nodes collect fluid from most other intraoral structures, including all maxillary and mandibular teeth, facial and palatal gingiva or gum tissue (except around the mandibular anterior teeth), posterior floor of the mouth, sides of the tongue anteriorly (but not the tip), cheek and side of the nose, and upper lip and lateral lower lip; the maxillary sinus drains into the **submandibular nodes**.

Parotid [pa ROT id] (or preauricular) **nodes**, located over the parotid gland in front of the ear, receive lymph from the area around the parotid gland, including the adjacent scalp, ear, prominence of the cheek, and eyelids. T e parotid and submandibular nodes, as well as excess lymph resulting from a sore throat (inflamed tonsils and pharynx), drain into the **deep and superȧcial cervical chain of nodes**. T ese are located along the large sternocleidomastoid neck muscles. To cite an example of the spread of infection, if an infection like a pimple or aphthous ulcer formed on the lower lip, it would drain into the mental nodes, which would in turn drain into the submandibular nodes, which in turn, along with parotid nodes from the side of the face, would drain into the cervical nodes. An enlarged cervical node could be the result of the lower lip infection.

From here, the lymph returns via the venous drainage of the cardiovascular system. On the left side, drainage is through the **thoracic** [tho RAS ik] **duct**, which empties into veins at the junction of the **left subclavian** [sub CLAY vi an] **and internal jugular veins**, which ultimately form the **brachiocephalic** [BRAY ki o se FAL ik] **vein**. On the right side, lymph empties into the junction of the **right subclavian** and **internal jugular veins**.

LEARNINg Ex ERCISES

- Describe the pathway by which an infection (or cancer cells) might spread from a maxillary tooth to the neck through the lymph system and then through the venous system.
- Describe the pathway by which an infection might spread from a mandibular anterior tooth to the neck through the lymph system and then through the venous system.

Review Questions

Select the one best answer.

1. Which node would first show enlargement from an infection of a mandibular incisor?
   a. Submental
   b. Submandibular
   c. Parotid
   d. Cervical
   e. Preauricular

2. At what location would you palpate the cervical lymph node chain?
   a. Around the sternocleidomastoid muscle
   b. Near the symphysis of the mandible
   c. Over the submandibular gland
   d. Behind the ear
   e. Over the parotid gland

3. Branches of what artery supply blood to the mandibular teeth?
   a. Maxillary artery
   b. Masseteric artery
   c. Pterygoid artery
   d. Pterygopalatine artery
   e. Superficial temporal artery

4. Branches of what artery supply blood to the maxillary teeth?
   a. Maxillary artery
   b. Masseteric artery
   c. Pterygoid artery
   d. Pterygopalatine artery
   e. Superficial temporal artery

a–4; a–3; a–2; a–1: Sr E wS Na

SECTION VI STRUCTURES VISIBLE ON A PANORAMIC RADIOGRAPH

Objectives

The objective for this section is to prepare the reader to perform the following:

- Based on relative location and shape, identify key structures already discussed in this text as they appear on a panoramic radiograph.

Now that you have learned the location and shape of many bony structures within the head, it is possible to look at a radiograph and identify many of these structures based on their shape and location. In order to do this, you need to know that the denser structures in the head (i.e., the bones and teeth) will appear on the radiograph as whiter (or **radiopaque**). Further, the least dense structures in the head (like foramina passing through bones, sinuses, and nerve canals) will appear on the radiograph as darker structures (called **radiolucent**). A panoramic radiograph can be taken with a device that rotates around the jaws so that the operator can view structures from the right, front, and left on one film. It is as though you could take the horseshoe-shaped mandible with its teeth and rami and flatten it out with its inner surface lying flat on a table and the outer (lateral) surface visible as one flat object.

LEARNINg ExERCISES

With this simple background, and your knowledge of the shape and location of structures in the skull, study the radiograph in Figure 14-52 and see how many of the following structures you can identify without looking at the answers. MATCH the following lettered items with the corresponding number and arrow on the radiograph. use the cl**u**es onl**y** i**f** needed.

A. Mandib**u**lar teeth. Note that each tooth has one or more roots embedded into the bony (opaque) alveolar processes. How many teeth there? If you know that all anterior teeth are present, count the premolars in each quadrant. Are they all there? Can you see the radiolucent, very thin (almost invisible) periodontal ligaments around each root?

B. Ma**x**illar**y** teeth. Note that each tooth has one or more roots embedded into the bony (opaque) alveolar processes. How many are there?

C. Bod**y** o**f** the mandible

D. An**g**le o**f** the mandible
(Clue: It is the inferior posterior corner of the horizontal body of the mandible where it joins the vertical ramus.)

E. Ramus
(Clue: It is the vertical part of the mandible.)

F. Coronoid process
(Clue: It is shaped like the point of a king's crown.)

G. Cond**y**lar process
(Clue: It articulates within the concavity of the temporal bone called the mandibular [articular] fossa).

H. Si**g**moid notch
(Clue: This notch is between the coronoid and condyloid processes.)

I. Mandib**u**lar canal
(Clue: It is a radiolucent canal with its mandibular foramen where the inferior alveolar nerve enters the mandible.)

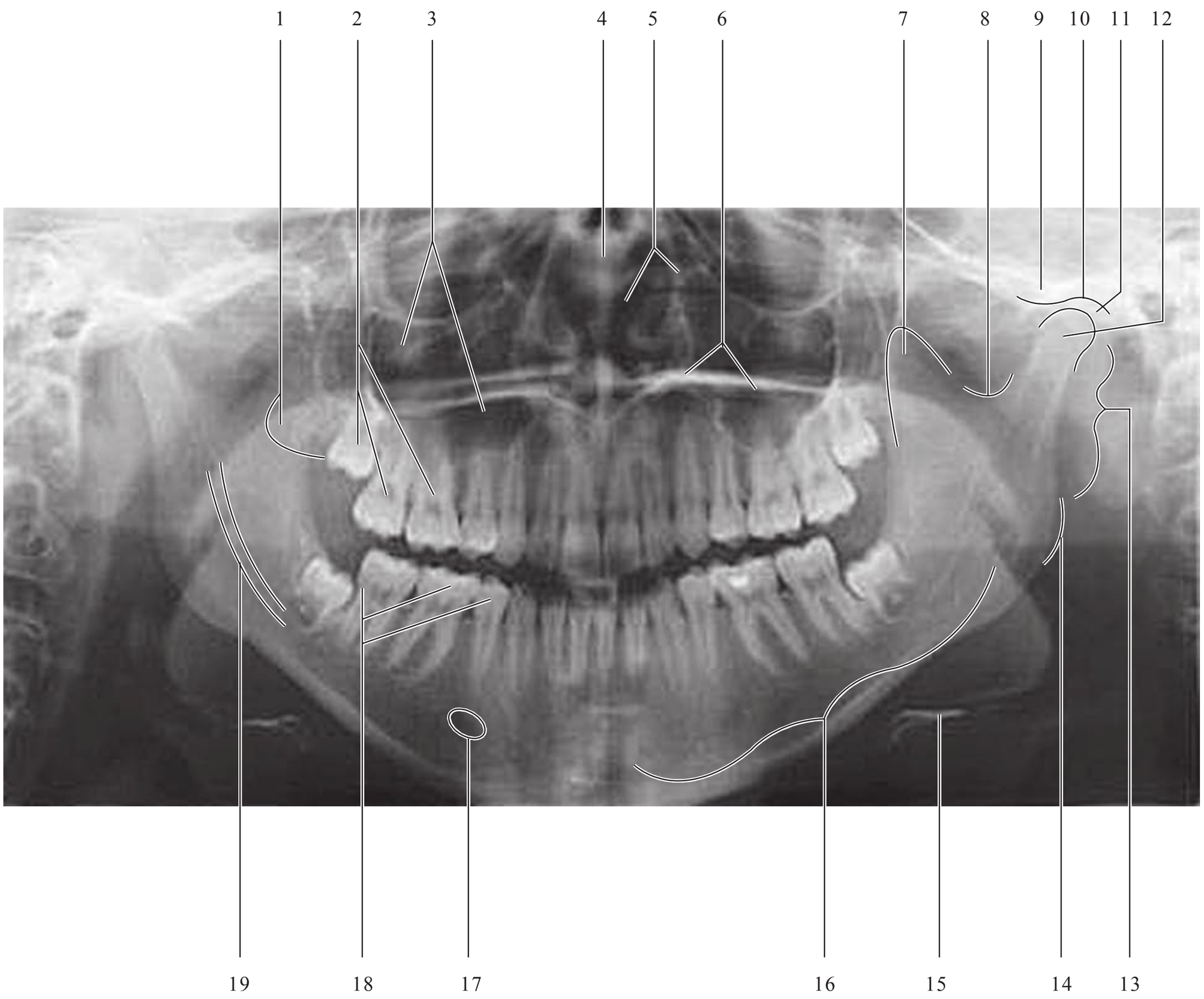

fIGur E 14-52. A panoramic radio**g**raph (Panorex) shows many of the structures of the skull. Test your ability to identify these structure based on their shape and relative location by matching the letter of a description (A–S) with the number of each structure (1–19). (Radiograph courtesy of Dr. R. M. Jaynes, DDS, Assistant Professor at Ohio State University.)

lEarNING ExErCISE (continued)

J. Mental **f**oramen
(Clue: It is a radiolucent circle near the ends of the premolar roots where the mental nerve branch of the inferior alveolar nerve splits off and exits the mandible to innervate the lower lip and chin on that side.)

K. Ma**x**illar**y** t**u**berosit**y**
(Clue: It is the bump of bone behind the last maxillary molar.)

L. Ma**x**illar**y** sin**u**s
(Clue: It is the radiolucent area in proximity to the roots of the maxillary molars and premolars.)

M. Hard palate composed of the palatal processes of maxillae and palatine bones.

N. Mandib**u**lar (artic**u**lar) **f**ossa
(Clue: It is the depression on the base of the cranium in the temporal bone where the condyle of the mandible fits.)

O. Artic**u**lar eminence
(Clue: It is the opaque bump of temporal bone anterior to the mandibular fossa that defects the condyles and the mandible downward [opening the mouth] as it moves forward.)

P. Artic**u**lar disc space
(Clue: It is a radiolucency between the condyle and the fossa.)

Q. Nasal passa**g**ewa**y** (also called nasal fossa)
(Clue: This hollow radiolucent space is located superior to the maxillary anterior teeth.)

R. Nasal sept**u**m: VOMER and vertical plate of ETHMOID bone
(Clue: The septum separates the right and left halves of the nasal passageways.)

S. H**y**oid bone
(Clue: This bone appears to foat below the mandible since the infra- and suprahyoid muscles attached to it are radiolucent and are not visible.)

ANSWERS: A—18 (there are 14 mandibular teeth; two premolars are missing), B—2 (there are 14 maxillary teeth; two premolars are missing), C—16, D—14, E—13, F—7, G—12, H—8, I—19, J—17, K—1, L—3, M—6, N—10, O—9, P—11, Q—5, R—4, S—15

REFERENCES

1. Clemente CD, ed. Gray's anatomy of the human body. 30th ed. Philadelphia, PA: Lea & Febiger, 1985.
2. Melfi RC. Permar's oral embryology and microscopic anatomy. 8th ed. Philadelphia, PA: Lea & Febiger, 1988:247–257.
3. Sicher H, DuBrul EL. Oral anatomy. 6th ed. St. Louis, MO: C.V. Mosby, 1975:344–378.
4. Osborn JW, ed. Dental anatomy and embryology. Oxford, UK: Blackwell Scientific Publications, 1981.
5. Montgomery RL. Head and neck anatomy with clinical correlations. New York, NY: McGraw-Hill, 1981.
6. Brand W, Isselhard B. Anatomy of orofacial structures. 5th ed. St. Louis, MO: C.V. Mosby, 1994.
7. Francis CC. Introduction to human anatomy. 6th ed. St. Louis, MO: C.V. Mosby, 1973.
8. Osborn JW, ed. Anatomy, biochemistry and physiology. Oxford, UK: Blackwell Scientific Publications, 1982.
9. Roman-Ruiz LA. T e mental foramen: a study of its positional relationship to the lower incisor and premolar teeth [Master's T esis]. Columbus, OH: Ohio State University, College of Dentistry, 1970.
10. Sicher H, DuBrul EL. Oral anatomy. 7th ed. St. Louis, MO: C.V. Mosby, 1975:174–209.
11. Edwards LF, Gaughran GRL. Concise anatomy. 3rd ed. New York, NY: McGraw-Hill, 1971.
12. Hickey JC, Allison ML, Woelfel JB, et al. Mandibular movements in three dimensions. J Prosthet Dent 1963;13:72–92.
13. Hickey JC, Woelfel JB, et al. Influence of occlusal schemes on the muscular activity of edentulous patients. J Prosthet Dent 1963;13:444–451.
14. Woelfel JB, Hickey JC, Rinear L. Electromyographic evidence supporting the mandibular hinge axis theory. J Prosthet Dent 1957;7:361–367.
15. Woelfel JB, Hickey JC, Stacy RW. Electromyographic analysis of jaw movements. J Prosthet Dent 1960;10:688–697.
16. Woelfel JB, Hickey JC, Allison ML. Effect of posterior tooth form on jaw and denture movement. J Prosthet Dent 1962;12:922–939.
17. Sharry JJ. Complete denture prosthodontics. New York, NY: McGraw-Hill, 1962:45–86.
18. Ricketts RM. Abnormal function of the temporomandibular joint. Am J Orthod 1955;41:425, 435–441.
19. Burch JG. Activity of the accessory ligaments of the temporomandibular joint. J Prosthet Dent 1970;24:621–628.
20. Turell J, Ruiz HG. Normal and abnormal findings in temporomandibular joints in autopsy specimens. J Craniomandib Disord Facial Oral Pain 1987;1:257–275.
21. Montgomery RL. Head and neck anatomy with clinical correlations. New York, NY: McGraw-Hill, 1981:202–214.
22. Winter CM, Woelfel JB, Igarashi T. Five-year changes in the edentulous mandible as determined on oblique cephalometric radiographs. J Dent Res 1974;53(6):1455–1467.
23. Kraus B, Jordan R, Abrams L. Dental anatomy and occlusion. Baltimore, MD: Williams & Wilkins, 1969:203–222.
24. Osborn JW, ed., Armstrong WG, Speirs RL. Anatomy, biochemistry and physiology. Oxford, UK: Blackwell Scientific Publications, 1982:324–343.
25. Haines RW. On muscles of full and of short action. J Anat 1934;69:20–24.
26. Gionhaku N, Lowe AA. Relationship between jaw muscle volume and craniofacial form. J Dent Res 1989;68:805–809.

27. Basmajian JV. Grant's medical method of anatomy. 9th ed. Baltimore, MD: Williams & Wilkins, 1975.
28. Crum RJ, Loiselle RJ. Oral perception and proprioception. A review of the literature and its significance to prosthodontics. J Prosthet Dent 1972;28:215–230.
29. Jerge CR. Organization and function of the trigeminal mesencephalic nucleus. J Neurophysiol 1963;26:379–392.
30. Renner RP. An introduction to dental anatomy and esthetics. Chicago, IL: Quintessence Publishing, 1985:162.
31. Jenkins GN. The physiology of the mouth. 3rd ed. Revised reprint. Oxford, UK: Blackwell Scientific Publications, 1970:310–328.
32. Kawamura Y, Kare MR. Umami: a basic taste. New York, NY: Marcel-Dekker, 1987.
33. Osborn JW, ed. Anatomy, biochemistry and physiology. Oxford, UK: Blackwell Scientific Publications, 1982:542.
34. Sicher H, DuBrul EL. Oral anatomy. 7th ed. St. Louis, MO: C.V. Mosby, 1980:351–376.
35. Montgomery RL. Head anatomy with clinical correlations. New York, NY: McGraw-Hill, 1981:75–82.
36. Paff GH. Anatomy of the head and neck. Philadelphia, PA: W.B. Saunders, 1973.

GENERAL REFERENCES

Ash MM. Wheeler's dental anatomy, physiology and occlusion. 7th ed. Philadelphia, PA: W.B. Saunders, 1993.
Clemente CD, ed. Gray's anatomy of the human body. 30th ed. Philadelphia, PA: Lea & Febiger, 1994.
Clemente CD. Anatomy: a regional atlas of the human body. 4th ed. Baltimore, MD: Williams & Wilkins, 1997.
Dorland's illustrated medical dictionary. 28th ed. Philadelphia, PA: W.B. Saunders, 1985.
Fehrenbach MJ, Herring SW. Illustrated anatomy of the head and neck. Philadelphia, PA: W.B. Saunders, 1996.
Reed GM, Sheppard VF. Basic structures of the head and neck. Philadelphia, PA: W.B. Saunders, 1976.
Travers JB, Travers SP. Physiology of the oral cavity. In: Cummings CW, ed. Otolaryngology head and neck surgery, vol. 2, 4th ed. Philadelphia, PA: Elsevier Mosby, 2005.
Web site: http://education.yahoo.com/reference/gray/—Bartleby.com edition of Gray's Anatomy of the Human Body

15 Oral Examination: Normal Anatomy of the Oral Cavity

Topics covered within the two sections of this chapter include the following:

I. Extraoral examination: normal structures
   - A. General appearance
   - B. Head
   - C. Skin and underlying muscles of mastication
   - D. Eyes
   - E. Temporomandibular joint
   - F. Neck
   - G. Lymph nodes
   - H. Salivary glands (extraoral)
   - I. Lips

II. Intraoral examination: normal structures as well as landmarks used for placing local anesthetic
   - A. Labial and buccal mucosa: vestibule and cheeks
   - B. The Palate: roof of the mouth
   - C. Oropharynx: fauces, palatine arches, and tonsils
   - D. Tongue
   - E. Floor of the mouth
   - F. Salivary glands (intraoral)
   - G. Alveolar process (of underlying bone)
   - H. Gingiva
   - I. The teeth (count them)

Objectives

This chapter is designed to prepare the learner to perform the following:

- While systematically following all of the steps suggested for a thorough head and neck (cancer screening) examination, identify and describe all normal structures found during an extraoral and intraoral examination.
- Describe the location and palpate (examine by touching), if possible, the major muscles of mastication.
- Describe the location of the temporomandibular joint, and palpate the joint posteriorly and laterally to the condyles.
- Describe the location of the lymph nodes that drain the face and neck and palpate these areas.
- Describe the location of the major salivary glands and palpate these areas.
- Describe the location for injecting anesthetic in order to anesthetize the teeth and surrounding structures.

Note: Specific research data and some of Dr. Woelfel's original research findings related to material covered in this chapter are referenced throughout by using superscript letters (like this[A]) and are then presented at the end of the chapter.

ANATOMIC TERMS: Familiarize yourself with the following anatomic terms before reading this chapter:

Circumvallate [sir kum VAL ate]: circum (around), vallate (valley or trench)

Filiform: shaped like a thread or filament

Fornix: referring to a vault-like space

Frenum [FREE num] (also frenulum; pl. frena): small fold of tissue that limits movement

Fungiform [FUN ji form]: shaped like a fungi or mushroom

Linea alba [LIN e a AL ba]: the white (alba) line (linea)

Mastication [MAS ti KA shen]: chewing food

Vestibule: entrance to the mouth; like an anteroom, known as a vestibule in an old house

During a head and neck (cancer screening) examination, the dental professional should evaluate all oral and surrounding structures for evidence of pathology. T is examination begins with an evaluation of the patient's general health and then involves an assessment of extraoral structures of the head and neck, followed by an intraoral examination that includes an evaluation of all structures from the lips to the throat. T e purpose of a complete and thorough extraoral and intraoral examination is to identify any areas of pathology that might require follow-up or treatment. T e primary purpose of this section is to describe normal structures that can be identified within the mouth so that deviations from normal can be distinguished. It should also help the reader describe the location of abnormal lesions relative to the location of normal adjacent structures, which is necessary when following the progression of changes of a lesion or when referring a patient for a lesion biopsy. A secondary purpose of this chapter is to highlight landmarks that are helpful when injecting local anesthetic prior to dental treatment.

You should try to perform an examination on a partner after studying the description and location of each normal landmark. Keep in mind that soft tissue structures cover the bones of the skull and are supplied by the nerves and blood vessels that were discussed in Chapter 14. As you study this material and examine the mouth, recall the location of the underlying bony landmarks, nerves, and vessels.

Section i extr Ao r Al exAMin At io n: n o r MAl St r Uc t Ur eS

A. Gen er Al AppeAr An c e

T e first thing to notice during an initial meeting with a patient is his or her general appearance. You can obtain clues regarding possible health problems that have not yet been diagnosed, and you can begin to predict how well the patient will tolerate dental treatment. Notice the posture, gait, breathing, and general well-being during your greeting.

B. HeAd

A close look at the head may reveal asymmetry of the head or a discrepancy in the relationship of the upper and lower jawbones. T is could be important to identify swelling that could be a sign of pathology or infection and when determining how to identify and treat problems with the occlusion.

c. Skin An d Un d er lyin G MUSc l eS o f MASt ic At io n

Observe the skin for any unusual lesions and describe each lesion by location (relative to adjacent normal landmarks), size, and the person's knowledge of its history. T e evaluator's knowledge of pathology is necessary when distinguishing benign lesions from those requiring follow-up pathology consult and/or biopsy.

Muscles of the head and neck may be palpated to identify pain or tenderness that could be related to problems with the temporomandibular joint or an imbalance in the occlusion of the teeth (made worse when the person habitually clenches or squeezes the teeth together). For this reason, it is important to be able to locate and palpate these muscles where possible. You can palpate each muscle pair bilaterally by lightly massaging an area with the middle finger of each hand while using the index and fourth finger to palpate surrounding soft tissue to feel for unusual lumps or tenderness. Palpate these muscles on a partner while using Figure 15-1 as a guide.

- **Masseter**: Feel the body of the masseter by palpating the bulge over the lateral surface of the mandible near the angle while your partner clenches the jaws together. Move your finger down toward the angle of the mandible to feel the insertion (labeled No. 4 on Fig. 15-1), and move

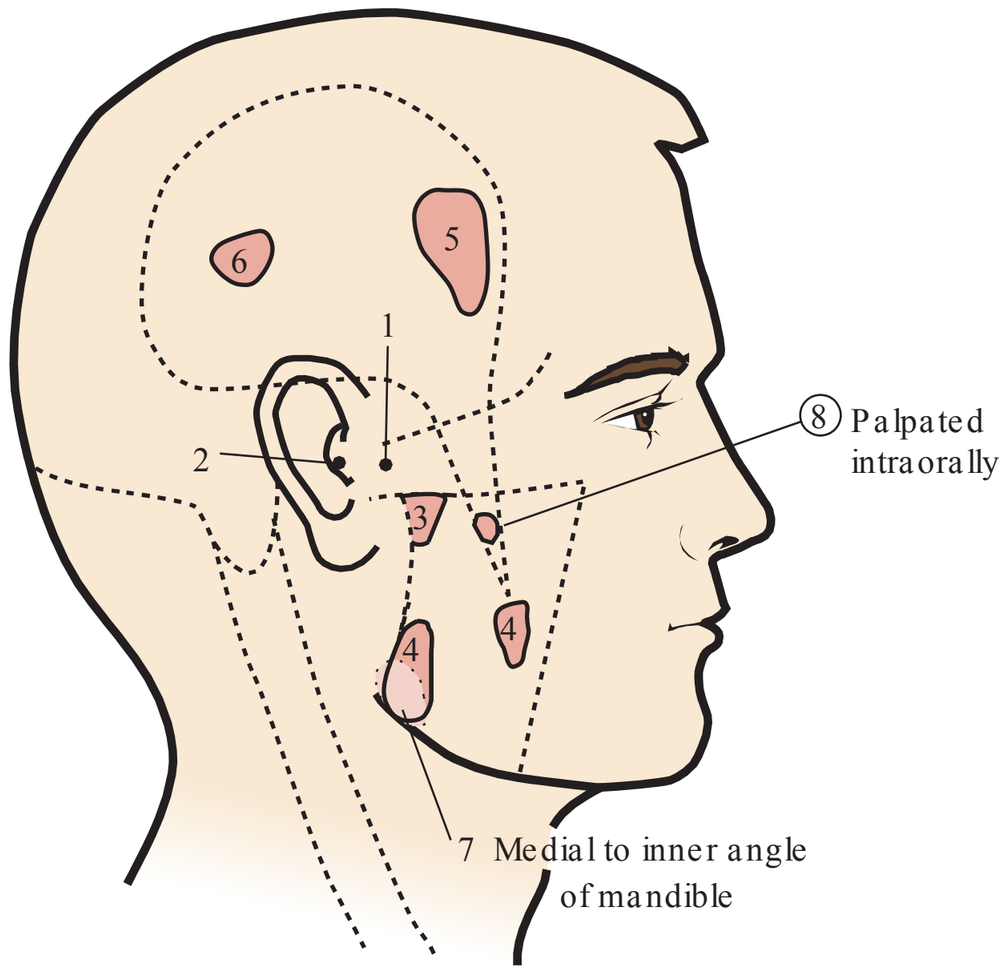

fiGUr e 15-1. Sites **fo**r palpati**on** of temporomandibular joint and muscles of mastication (origin and insertion locations). 1. Lateral surface of mandibular condyle. 2. Posterior surface of mandibular condyle. 3. Masseter (origin). 4. Masseter (insertion). 5. Temporalis (anterior vertical fibers that close mandible). 6. Temporalis (posterior horizontal fibers that retract mandible). 7. Medial pterygoid. 8. Lateral pterygoid (palpated i**n**tra**o**rally).

up toward the zygomatic arch (inferior border of the zygomatic bone and zygomatic process of the temporal bone) to feel the origin (labeled No. 3).

- **Medial pterygoid**: Feel the bulge when your partner clenches while palpating the medial surface of the angle of the mandible at the insertion (labeled No. 7). It may help to have your partner lean the head forward to relax the skin of the neck as you gently palpate upward and outward against the medial surface of the mandible near the angle, using the tips of your middle finger and forefinger. T is may cause some discomfort.
- **Temporalis, anterior ȧbers**: Palpate the origin of the anterior (vertical) fibers on the forehead just above a line between the eyebrow and superior border of the ear (labeled No. 5). Since these muscle fibers help close the mouth, see if you feel the bulge when your partner clenches the teeth.
- **Temporalis, posterior ȧbers**: Palpate the origin of the posterior (horizontal) fibers of the temporalis just above and posterior to the superior border of the ear (labeled No. 6). Since these muscle fibers are involved in retruding the mandible, see if you can feel a bulge when your partner retrudes (pulls back) the mandible.
- **Lateral pterygoid** (intraoral palpation): T e lateral pterygoid can only be palpated intraorally. Feel this muscle by placing your little finger in the vestibule of the mouth behind the maxillary tuberosity (labeled No. 8). (Use a skull to see how to reach the lateral plate of the pterygoid process of the sphenoid bone.) With your partner's mouth slightly open and the mandible moved slightly toward the side being palpated, slide your little finger back toward the lateral pterygoid plate for the origin of the lateral pterygoid muscle. T is may be uncomfortable to a patient even if the muscle is not sore. T e anterior surface of the neck of the condyloid process is the location of part of the insertion of this muscle, but it cannot be palpated.

d. eyeS

T e normally white part of the eyes (sclera) should be white and clear, not bloodshot, and not yellow (a possible indication of jaundice from liver disease). T e thin layer of tissue covering the eyeball and reflected onto the inner surfaces of the eyelids (called the conjunctiva) should appear healthy and not be severely inflamed (red) or irritated (a possible sign of allergy or disease). T e pupil (dark center opening surrounded by the colored iris) should not be severely pinpoint or dilated, both of which may be signs of disease or drug use.

e. t eMpo r o MAn d iBUl Ar Jo in t

Locate and palpate the lateral aspects of both mandibular condyles simultaneously by standing behind your partner and pressing your middle fingers over the skin just anterior to the external opening of the ear and inferior to the zygomatic arch while your partner opens wide and closes (Fig. 15-1, labeled No. 1). Feel the head of the condyle move as your partner opens and closes the mandible and moves the mandible from side to side. Movement of the condyles during minimal opening of the mandible cannot be felt as easily as when the mouth is opened wide since the condyles and mandible only rotate around a line connecting the condyles (like a swing) during minimal opening, but the condyles and mandible move bodily (translate forward and downward over the articular eminences) when opening wide. Also, feel the condyles during lateral movement to see if you discern differences in movement on the right side versus the left side during movement to the right, then movement to the left. Sometimes, you may feel a jerky movement accompanied by a clicking or popping sound. T is is likely due to the head of the condyle slipping off of the articular disc.

Palpate the posterior surface of the mandibular condyle by placing your little fingers into each external auditory meatus (ear canal openings) and press anteriorly forward (Fig. 15-1, labeled No. 2). Feel the posterior surface of the condyles as your partner opens, closes, and moves the mandible laterally from side to side.

f. n e c k

T e neck should be evaluated for symmetry and to confirm that there are no lumps or bumps. T e thyroid gland (a major gland that secretes the thyroid hormone, which is responsible for controlling much of the metabolism of the body) is located in the neck. It is just inferior to the voice box (larynx or laryngeal prominence), and it is shaped somewhat like a butterfly with wings extending laterally on either side of the larynx (Fig. 15-2, labeled No. 17). T is gland should be evaluated visually and palpated (as in Fig. 15-3) to ensure that there is no swelling (a possible goiter), which could be a sign of dysfunction of this gland and its output of thyroid hormone. Also, in the neck, lymph nodes that are located around the sternocleidomastoid muscles are described next.

G. lyMpH n o d eS

T e evaluation of lymph nodes during a dental exam is important since enlarged nodes may indicate infection from sites that drain into them or may be an indicator of the spread of cancer. Healthy nodes are normally not palpable, but infection or malignancies may cause them to become enlarged. When infection drains into a node, it is more likely to be firm, tender, enlarged, and warm, and adjacent skin may be reddened. In this case, look for the site of infection based on your knowledge of the spread pattern within the nodes discussed in the previous chapter. Even after the infection is resolved, the nodes may remain enlarged but would be nontender and rubbery in consistency. If a node becomes enlarged due to the effect of a malignancy, it is more likely to feel firm and nontender, but it also feels like it is attached to the underlying tissue, so it is relatively immovable, and it will continue to get larger.

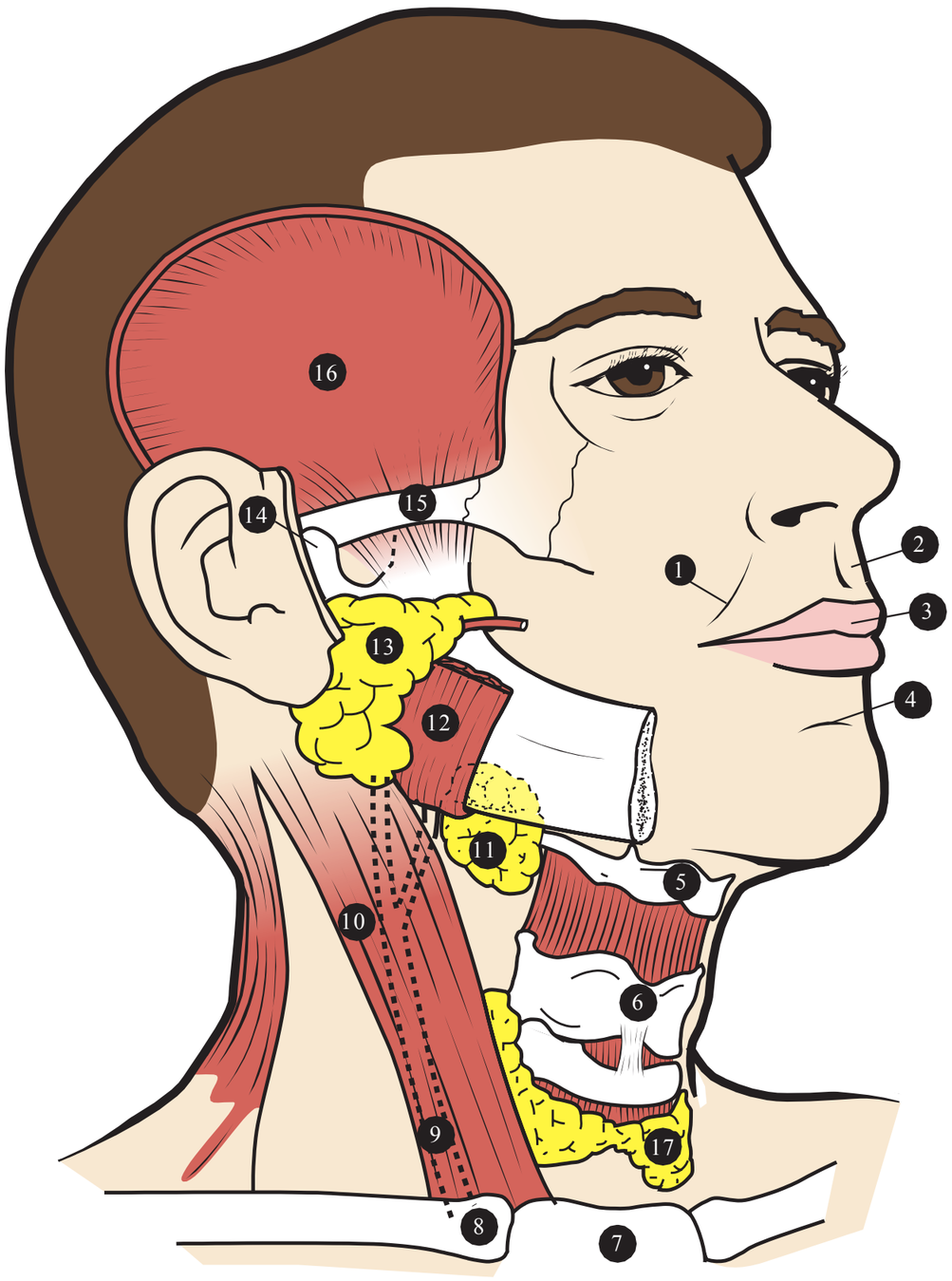

1. Nasolabial groove
2. Philtrum
3. Tubercle (upper lip)
4. Labiomental groove
5. Hyoid bone
6. Laryngeal prominence (Adam's apple)
7. Sternum
8. Clavicle
9. Carotid artery (dotted lines)
10. Sternocleidomastoid muscle
11. Submandibular gland
12. Masseter muscle
13. Parotid gland
14. Head of condyle
15. Zygomatic process
16. Temporalis muscle
17. Thyroid gland

FIGURE 15-2. Structures in the head and neck that can be identified (or palpated) during a head and neck examination.



FIGURE 15-3. Palpation of the tissue in the neck surrounding the thyroid gland and laryngeal prominence, feeling for asymmetry or swelling.

Nodes, when enlarged, can be felt by passing the sensitive fleshy part of the fingertips over the location of each node location. Using Figure 14-51 in the last chapter as your guide, palpate the skin located over the submental nodes (just inferior and posterior to the chin), the submandibular nodes (inside the angle of the mandible and over the submandibular glands), the superficial parotid and the retroauricular nodes (anterior and posterior to the ear, respectively), and the cervical nodes (surrounding the large sternocleidomastoid neck muscle, as demonstrated in Fig. 15-4).

H. Salivary Glands (extraoral)

Two pairs of major salivary glands can be palpated extraorally: the submandibular glands and the parotid glands. The **submandibular glands** are located just medial to the inferior border of the mandible within the shallow submandibular fossae (Fig. 15-2, labeled No. 11). They are positioned just anterior to where the facial artery passes over the inferior surface of the mandibular on its way from the neck to the face. Palpate this vessel on the inferior border of the mandible in the antegonial notch (you may feel its pulse) and move medially in order to locate the submandibular gland. These glands produce almost two thirds of our saliva, mostly the thinner (serous) type but also some thicker (mucous) types.[1]

The large **parotid glands** (labeled No. 13 in Fig. 15-2) are located just anterior and inferior to each ear lobe (lateral to the ramus and extending posteriorly to the sternocleidomastoid



fiGUr e 15-4. Palpation of tissue of the neck that surrounds the ster**no**cleid**om**ast**o**id **mu**scle in order to detect any enlarged cer**v**ical ly**m**ph **no**des that are located around this muscle.

muscle). T ey produce 23% to 33% or our saliva (the serous or thinner type).[1] T ese glands may become enlarged during mumps or a duct blockage.

i. l ip S

Use Figure 15-5 as a guide while studying the lips. T e lips are the two fleshy borders of the mouth (an upper and a lower) that join at the **labial commissure**. T e upper lip is bounded laterally by the cheeks at the nasolabial groove and superiorly by the nose. T e **nasolabial groove** runs diagonally downward and laterally from the side of the nostrils toward an area near the commissure of the mouth. T e lower lip is also bounded laterally by the cheeks and is bounded inferiorly by the chin at a horizontal groove called the **labiomental groove**. Recall that the underlying orbicularis oris muscle is the muscle within the lips surrounding the mouth opening that permits us to close our lips around a straw. T e upper lip has a small rounded nodule of tissue in the center of its lowest part called the **tubercle**, and the skin superior to the tubercle has a broad depression running from the tubercle toward the center of the nose called the a **philtrum** [FIL trum].

T e **vermilion border** (also margin or zone) is the red zone of the lips, which is really a transitional zone between the skin of the face and the mucous membrane or mucosa [mu KO sah] (tissue lining the mouth). It is the area where many women apply lipstick. T e lips are redder in younger persons than in older persons, and in some individuals, the

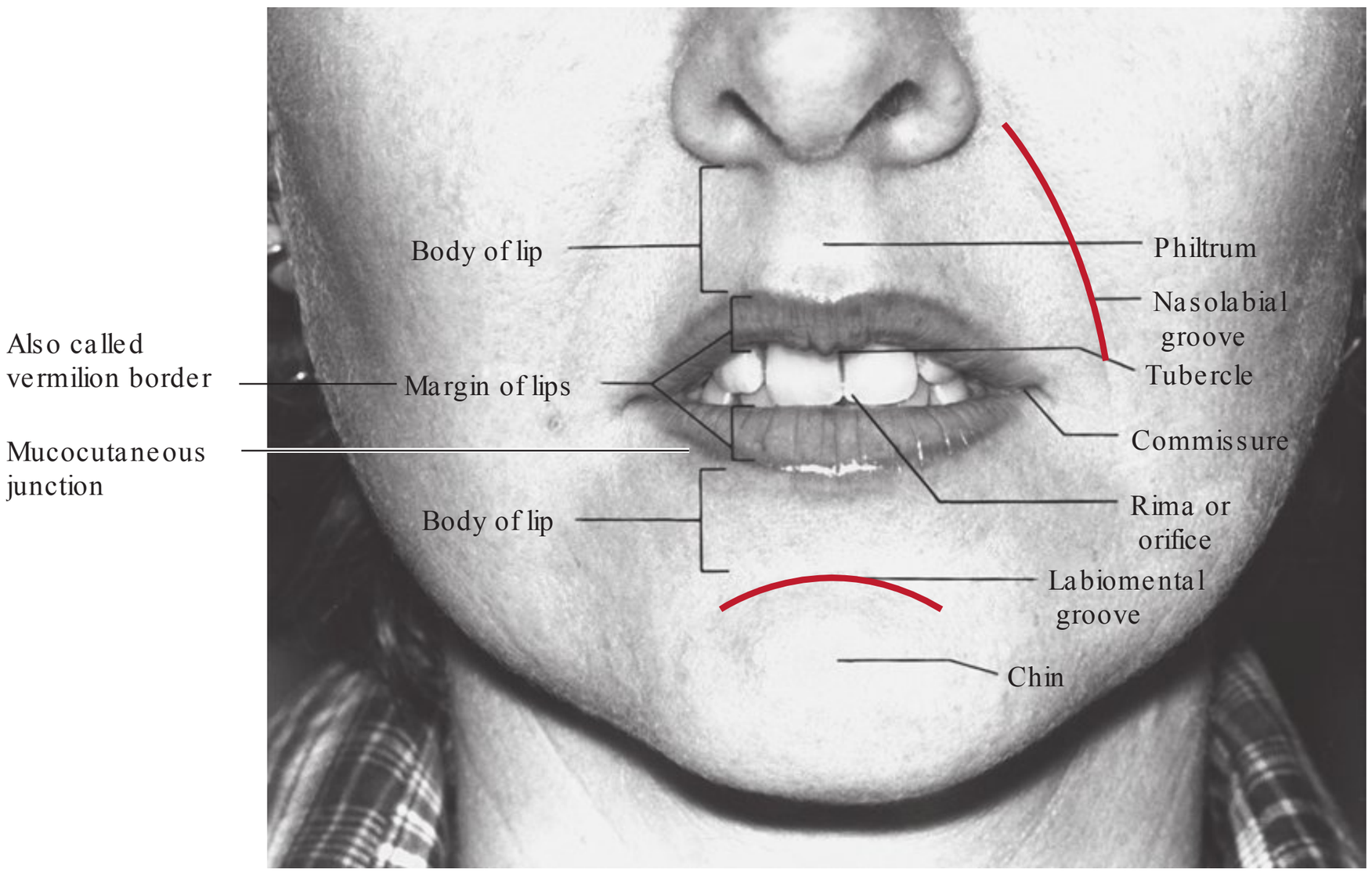

fiGUr e 15-5. Str**uct**u**r**es **of** the lips. The margin of the lips is also called the vermilion zone or border. The **muc**o**cu**ta**n**e**ou**s **junct**i**on** is the junction of the skin of the face with the vermilion zone.



FIGURE 15-6. **L**ower lip: **v**er**m**illi**on** b**o**rder, wet (wet–dry) li**n**e and **muco**cu**ta**n**e**ou**s** **junc**ti**on**.

lip color is reddish brown due to the presence of brown melanin pigment. The vermilion border is bounded externally on the face by the **mucocutaneous** [MYOO koe kyoo TAY nee us] **junction**, the junction between the skin of the face and the vermilion border of the lips. The vermilion border is bounded internally in the mouth by the wet line where labial mucosa begins. The **wet line** (or **wet–dry line**) is the junction between the outer vermilion border, which is usually dry, and the inner smooth and moist mucosa (Fig. 15-6). The wet line is located about 10 mm back from the skin or mucocutaneous junction. The vermilion border and mucocutaneous junction are important in the head and neck examination because changes here may be caused by exposure to the sun and could lead to skin cancer.

Section ii Intraoral Examination: Normal Structures as Well as Landmarks Used for Placing Local Anesthetic

The **oral cavity** is bounded anteriorly by the lips, laterally by the cheeks, superiorly by the palate, and inferiorly by the floor of the mouth. The oral cavity can be divided into two parts: the oral vestibule and the oral cavity proper. The outer **oral vestibule** is the space between the teeth with the supporting alveolar processes and the lips or cheeks. The inner **oral cavity proper** is the space bounded anteriorly and laterally by the teeth and alveolar processes.

Mucous membrane (mucosa) lines any body cavity opening out to where it joins the skin on the outside of the body. **Oral mucous membrane** lines the oral cavity. It resembles the skin covering the outside of the body, except that it is moist. Some areas subjected to the most wear, such as the roof the mouth (over the hard palate) and the gingiva, are covered by a toughened outer tissue called a **keratin** [KER ah tin] layer. As wear occurs, this keratinized tissue may take on a grayish appearance. Other areas of the oral mucous membrane have no keratin layer so are more delicate in structure, such as the cheeks and floor of the mouth. This mucosa lining may be so thin that the blood vessels located in the underlying connective tissue may easily be seen, giving it a reddish or bluish color.

Many of the nerves that innervate the teeth and adjacent oral structures can be reached with the anesthetic syringe needle by penetrating the labial and buccal mucosa. The landmarks that are helpful for locating these injection sites will be described throughout this section.

A. Labial and Buccal Mucosa: Vestibule and Cheeks

The vestibule space between the teeth and the lips or cheeks can be divided into the labial vestibule next to the anterior teeth and the buccal vestibule next to the posterior teeth (premolars and molars). It extends superiorly into a mucosa-lined space next to maxillary teeth and inferiorly next to mandibular teeth. It is covered with dark pink–colored alveolar mucosa and is rich in blood vessels and minor salivary glands. The tip of your tongue can reach into each vestibule to assist in cleaning the facial surfaces of the teeth and, while chewing, to lift food back for additional chewing. The **vestibular fornix** (Fig. 15-7) is the lowest part of the vestibule next to the mandible or the highest part next to the maxillae. The vestibular fornix next to the cheeks is where food may collect in patients especially after nerve damage to the cheek (as with unilateral loss of function of the facial nerve from Bell palsy or from a stroke).

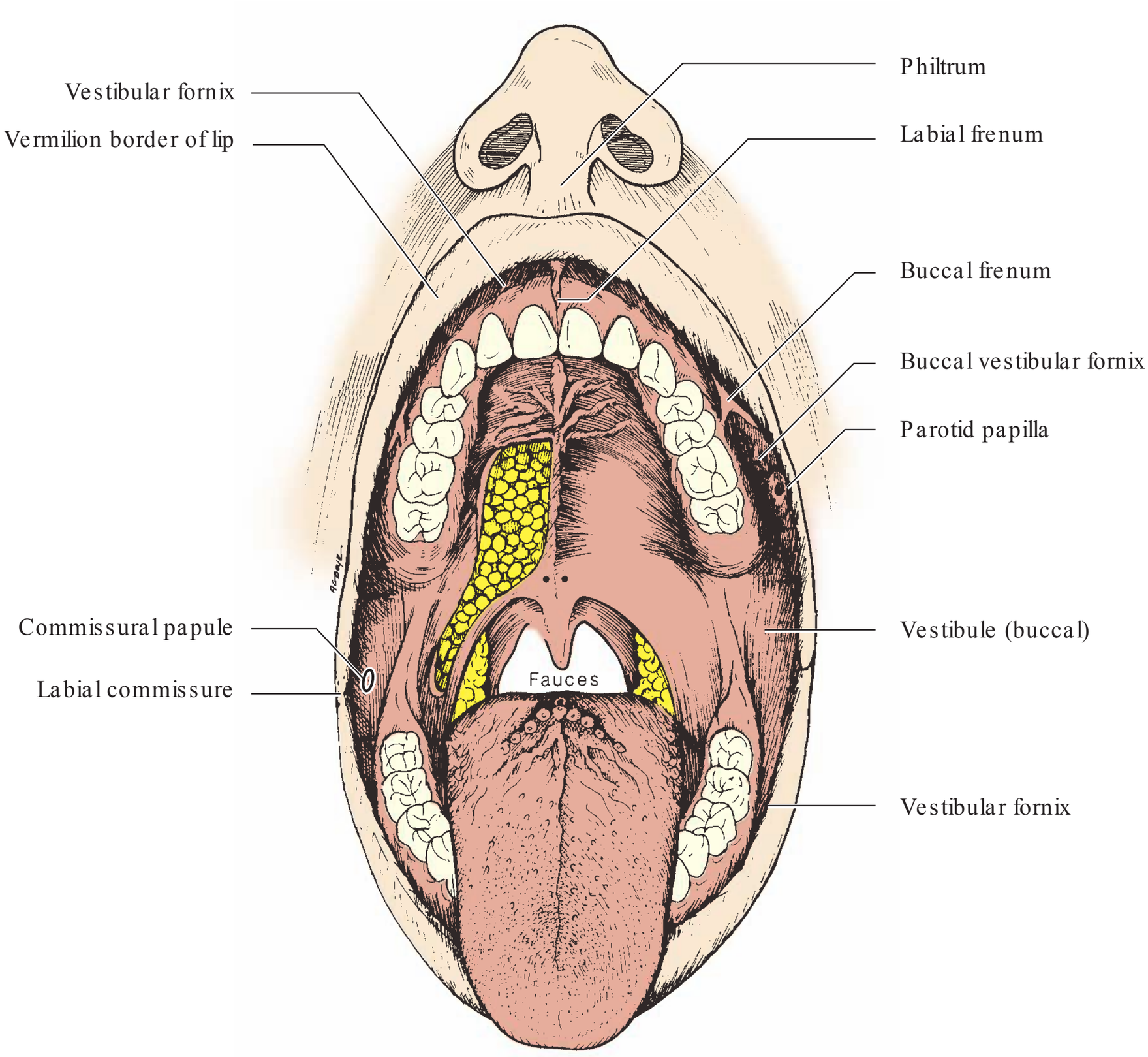

fiGUr e 15-7. Str**uc**t**u**res **of** the **v**estib**u**le a**n**d ad**j**ace**n**t chee**k mu**c**o**sa.

Refer to Figure 15-7 as a guide while studying the following structures. T e **labial frenum** [FREE num] (plural: frena [FREE nah]) is the thin sheet of tissue at the midline that attaches each lip (upper and lower) to the mucosa covering the maxillae or mandible between the central incisors. T e **buccal frenum** loosely attaches the cheek to the mucosa of the jaw in the area of the premolars (maxillary and mandibular). T ese buccal frena can be seen by pulling the lip and cheek out and upward and the lip and cheek out and downward. Facial muscles move the buccal frena forward and backward and upward and downward during eating to help, along with the tongue, place our food back over the chewing surfaces of our teeth while eating. Movement of these frena can dislodge complete dentures if the denture border is designed improperly.

Usually 4 to 6 mm posterior to the commissure of the lips, a slight bulge of mucous membrane called the **commissural papule** is commonly seen and may be palpated (Fig. 15-7). T e **parotid papilla** [pa ROT id pah PILL e] is a rounded flap of tissue on the mucosa of the cheek next to the maxillary first and second molars at or just superior to the occlusal plane (Fig. 15-7). T is papilla covers the opening to the **parotid duct** (**Stensen duct**).[A]

T e lining of the **buccal mucosa** on the inside of the cheeks is shiny, but in spots may be rough. Often, there is a horizontal white line extending anteroposteriorly on each side at the level where the upper and lower teeth come together, called the **linea alba** [LIN e ah AL ba] buccalis (Fig. 15-8). (Hint: "Linea" means line; "alba" means white.) It may extend from the commissural area to the third molar region at a level of the occlusal surfaces of the posterior teeth. T is area may become irritated by trauma from biting the cheek. **Fordyce granules** or spots are small, yellowish irregular areas and may be conspicuous in some persons. T ey are most commonly located on the buccal mucosa inside the cheeks posterior to the corner of the mouth (Fig. 15-8). T ey are really the manifestation of intraoral sebaceous glands—glands normally associated with hair follicles on the skin outside of the mouth. T eir presence here may be the result of fusion of the upper and lower parts of the cheek during embryonic development. Such glands have also been found, however, on other parts of the oral mucosa.

Palpation of the cheeks (or lips) for lumps or bumps can be accomplished by pressing with the thumb on one side against the forefinger on the other side (called **bidigital palpation**), as seen in Figure 15-9.

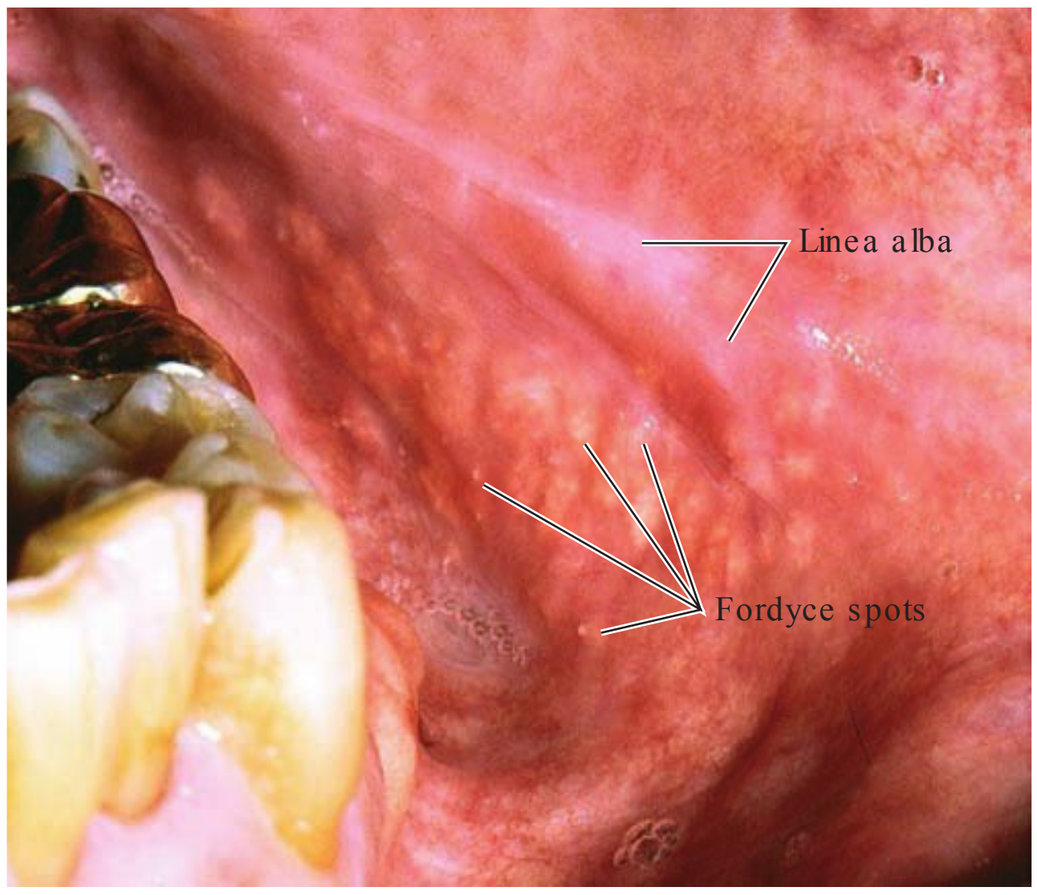

fiGUre 15-8. Buccal mucosa adjacent to posterior teeth showing a linea alba and Fordyce granules (spots). (Courtesy of Carl Allen, D.D.S., M.S.D.)



fiGUre 15-9. Bidigital palpation is used to feel for lumps or bumps within the soft tissue of the cheeks by pressing with the thumb on the one of the cheek and forefinger on the other side.

TECHniqu E Fo R In jECTIn G Lo CAL An ESTHETIC To numB o RAL STRu CTu RES: BACkGRo u n D

In order for you to "feel" pain in a tooth, the tooth or surrounding tissue that is being "hurt" must pass the signal to the brain by way of the branches of the trigeminal nerve. In order for the anesthetic to block the signal of oral pain being sent along these nerve branches that pass from each tooth to the brain, a sufficient concentration of anesthetic must enter the nerve cells along their passageway from the tooth to the brain to block the nerve. In order to accomplish this, anesthetic is applied as close as possible to a nerve before it enters the bone, or, if the bone is porous enough or thin enough, it may be applied outside of the bone where it can pass (infiltrate) through the bone directly to the dental nerve branches in the bone before they enter the tooth root. The maxillae bones are less dense than the mandible, permitting anesthetic to infiltrate more readily from adjacent soft tissue into bone and reach nerve branches that enter the tooth pulps. In the mandible, nerves supplying the pulps can be blocked more effectively by applying the anesthetic near the mandibular nerve before it enters the mandible (the inferior alveolar nerve) or into the mental foramen (which permits the solution to enter the mandible and block only the inferior alveolar nerve branches to the premolars and possibly the anterior teeth but not the molars).

Recall that most nerves parallel arteries and veins. In order to avoid injecting local anesthetic into these vessels where it can produce an exaggerated undesirable effect on the heart (systemic effect), an aspirating syringe is used. This type of syringe permits the operator to pull back on the stopper of the anesthetic cartridge and apply a negative pressure through the solution and needle. Therefore, if the needle tip is in a blood vessel, the negative pressure can aspirate (suck in) blood into the glass anesthetic cartridge where it can be seen. When blood is observed, the operator can reposition the needle prior to injecting the anesthetic and aspirate again to ensure that the anesthetic will not enter the vessel where it would quickly reach the heart, resulting in an increased chance of undesirable side effects.

InjECTIon S Fo R THE PSA, mSA, An D ASA n ERvES

Consider the nerves that must be blocked in order to anesthetize the teeth and surrounding tissues of the upper jaw. These are all branches of the maxillary division of the fifth cranial (trigeminal) nerve. In order to anesthetize the pulp of one or two teeth, or the soft tissue in a specified area, it is necessary to block the appropriate individual branches of the posterior superior alveolar (PSA), middle superior alveolar (MSA), or ASA nerve branches that innervate these tissues.

Injections for the PSA, MSA, and ASA nerves (Continued)

If you want to anesthetize only the maxillary second or third molar and adjacent tissue, you can reach the PSA (Fig. 15-10) before it enters the alveolar canals (Fig. 15-11) by directing the anesthetic toward the posterior surface of the maxilla, just superior, distal, and slightly medial to the apex of the third molar. Entry to this site is through the mucosa at the height of the buccal vestibule (vestibular fornix) superior to the maxillary tuberosity (Fig. 15-12). The cheek can be stretched slightly outward to permit an angle that is directed superiorly and medially. Specific dental branches of the PSA can also be blocked by depositing the anesthetic next to the maxilla as close as possible to the apex of the tooth being anesthetized, and the solution will infiltrate through the maxillary bone to block the dental branches to these molars. When using this technique to anesthetize a maxillary first molar, the anesthetic will reach not only the dental branches of the PSA that enter two of its roots but also the MSA branches that enter the third root.

For all other maxillary teeth and adjacent facial gingiva, you need to block branches of the MSA or ASA. Since you cannot easily reach the MSA and ASA nerves as they pass from the brain through the base of the orbit and maxillary sinus, you can deposit the solution in the soft tissue of the vestibular *f*ornix adjacent to the maxillae, at a level o*f* the tooth root tips of the teeth you want to get numb (Figs. 15-13 for the MSA and Fig. 15-14 for the ASA). The anesthetic can infiltrate through the soft tissue and bone to reach dental nerve branches of the ASA (supplying the pulps of anterior teeth, Fig. 15-15) or MSA (supplying the pulps of premolars and one root [mesiobuccal] of the maxillary first molar, Fig. 15-16) in order to block pain. As stated previously, the anesthetic placed to block the MSA nerve branches may also infiltrate through the bone to block some of the PSA nerve branches, thereby numbing the entire first molar.

End branches of the infraorbital nerve branches that supply the soft tissue facial to premolars and anterior teeth can be anesthetized using the infiltration technique described above. However, blocking all of the terminal branches of the infraorbital nerve may also be helpful. This nerve can be reached by applying the anesthetic near the opening of the in*f*raorbital *f*oramen (Fig. 15-17). This foramen may be palpated with the forefinger through the skin just below the inferior border of the eye socket. Then, using the thumb in the facial vestibule to raise the upper lip, you can pass the needle into tissue at the height (*f*ornix) of the vestibule near the premolars (similar to the MSA injection) and continue to move the tip parallel to the facial surface of the maxilla until reaching the level of the infraorbital foramen (Fig. 15-18).

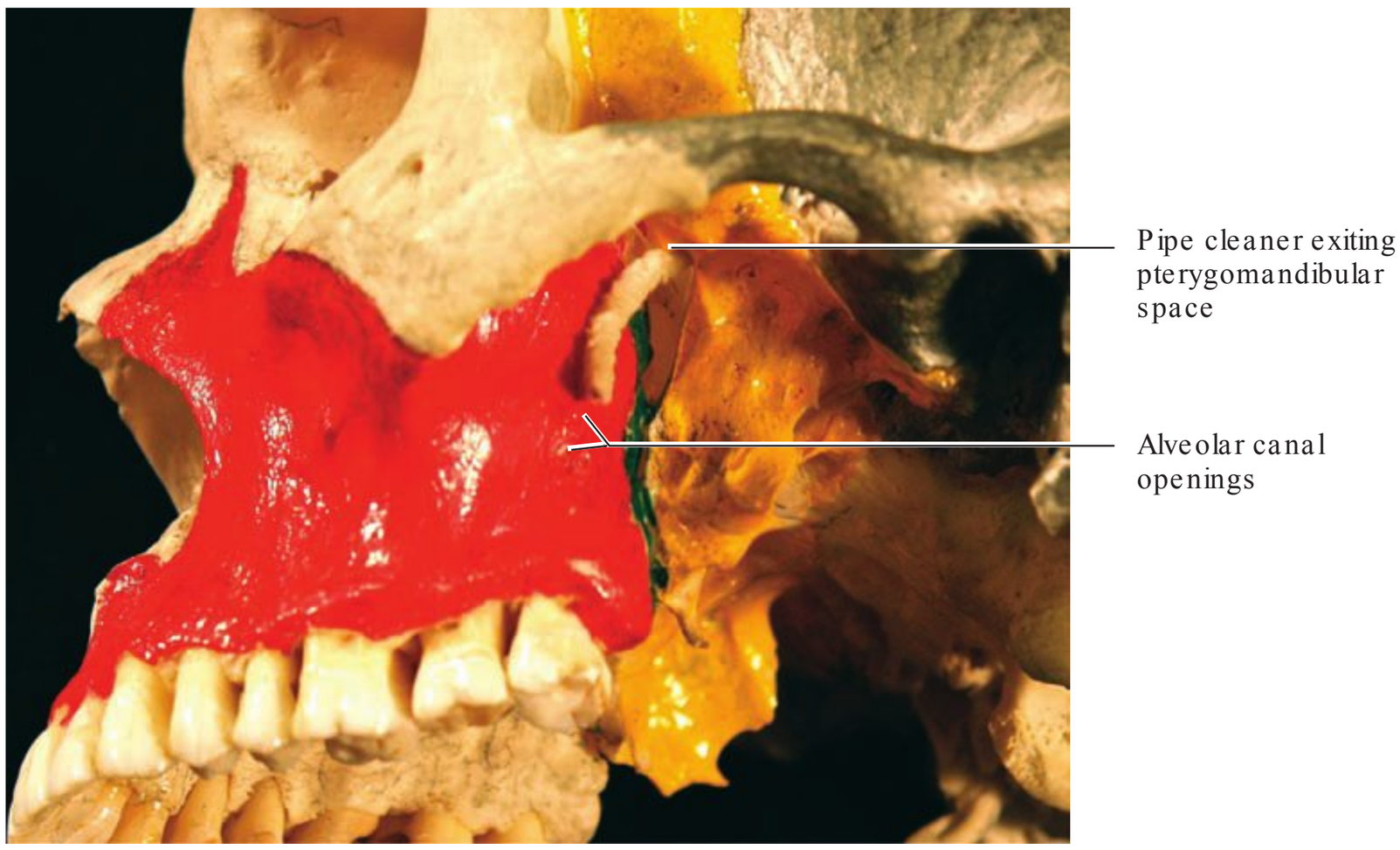

fiGUr e 15-10. PSA **n**er**v**e l**o**cati**on**: human skull with maxilla painted red, the palatine bone (barely visible) is green, and the sphenoid bone is yellow. A pipe cleaner, representing the PSA **n**er**v**e, passes out of the pterygomandibular space and passes inferiorly toward the alveolar canals on the posterior surface of the maxilla.

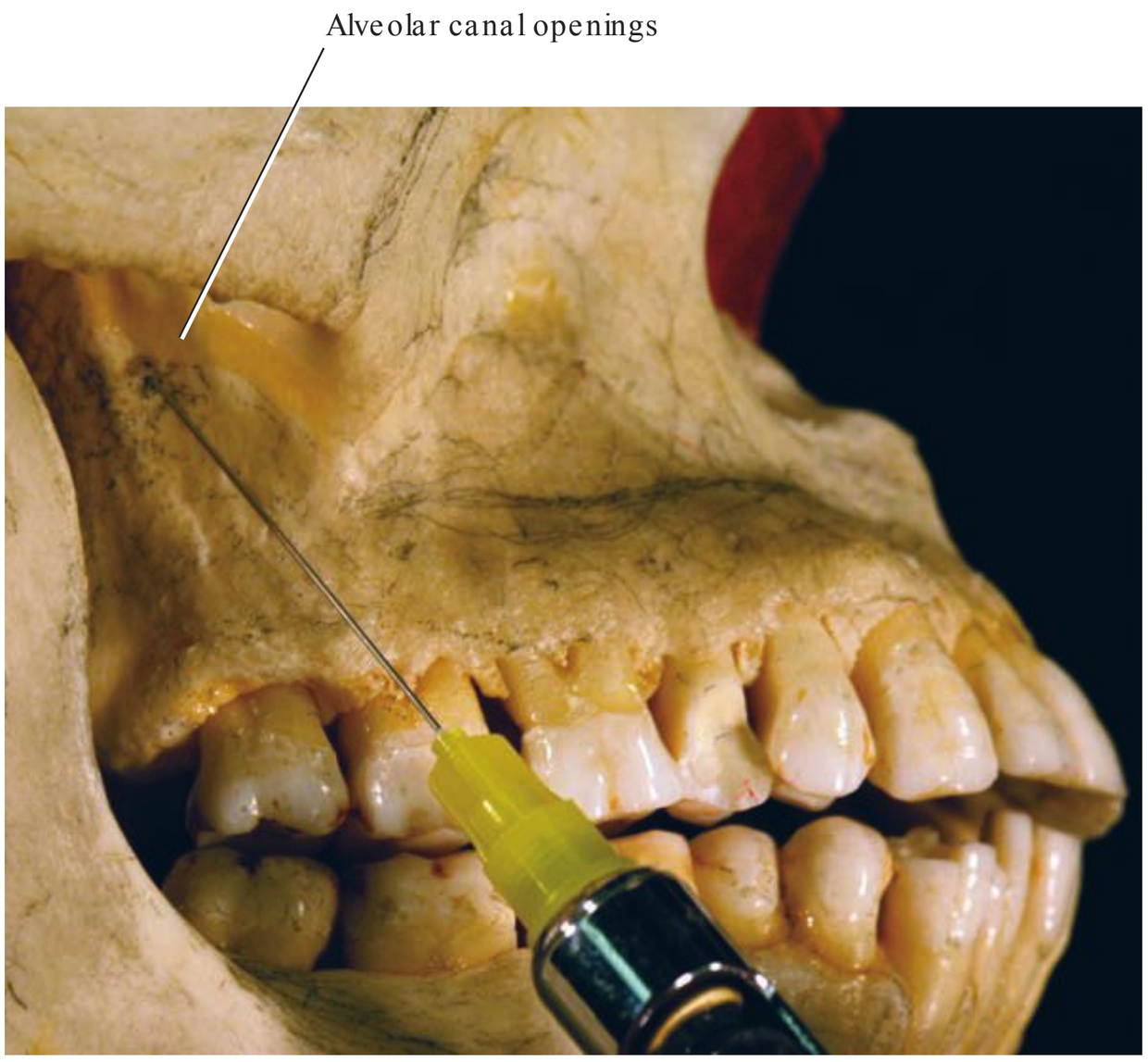

fiGUr e 15-11. PSA **n**er**v**e l**o**cati**on**: anesthetic syringe needle aimed toward the alveolar canals where the PSA **n**er**v**e branch enters the maxilla on its way to the maxillary molar roots.



fiGUr e 15-12. PSA **n**er**v**e i**nj**ecti**on**: penetration of the needle through the oral mucosa at the height of the maxillary vestibular fornix just posterior to the maxillary tuberosity is directed medially and superiorly toward the alveolar canals where the PSA **n**er**v**e enters the maxilla. This injection location should reduce pain sensation to the maxillary molars (except the mesiobuccal root of the maxillary first molar) and adjacent facial soft tissue and gingiva.

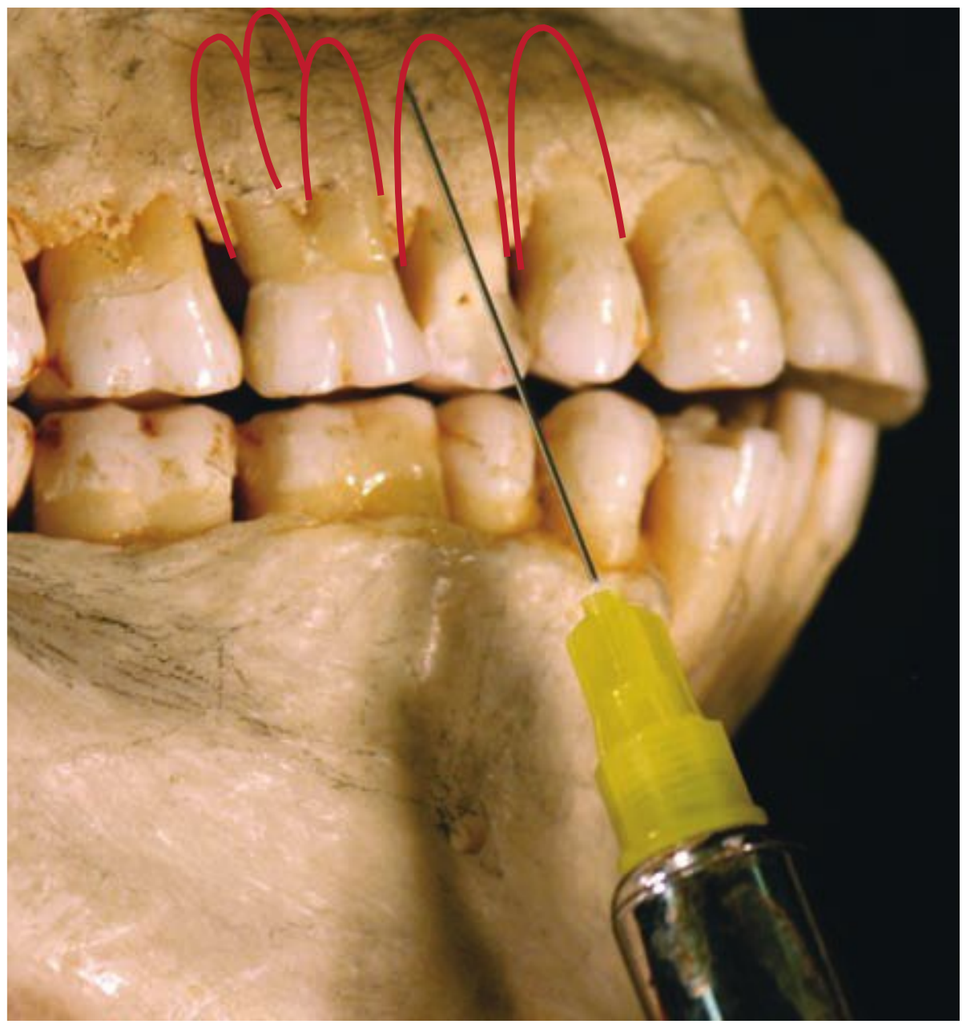

fiGUr e 15-13. mSA (a**n**d ad**j**ace**n**t PSA) **n**er**v**e l**o**cati**on**: human maxilla has the location of the maxillary first molar and premolar roots outlined on the maxilla. The anesthetic syringe needle is aimed parallel to the contour of the maxilla to reach the level of the root ends of the maxillary premolar or molar teeth to be anesthetized. The anesthetic can infltrate through the bone of the maxilla to reduce pain sensation to these teeth (and adjacent facial soft tissue and gingiva) by simultaneously blocking the mSA **n**er**v**e and branches of the adjacent PSA **n**er**v**e.



fiGUre 15-14. ASA **n**er**v**e l**o**cati**on**: human maxilla with a pencil line indicating the approximate level of the end of the maxillary tooth roots. The anesthetic syringe needle is aimed parallel to the contour of the maxilla to reach the level of the root ends of the maxillary anterior teeth in order to block the dental branches of the ASA **n**er**v**e.



fiGUre 15-16. mSA (a**n**d ad**j**ace**n**t PSA) i**nj**ecti**on**: the anesthetic syringe needle penetrates through the oral mucosa at the height of the maxillary vestibular fornix (near the buccal frenum) adjacent to the maxillary premolars until the needle tip reaches the estimated level of the root tips. This injection location should reduce sensation to the maxillary premolars and adjacent first molar by infiltrating through the maxilla to block the mSA **n**er**v**e and the adjacent branches of the PSA **n**er**v**e.



fiGUre 15-15. ASA **n**er**v**e i**nj**ecti**on**: the anesthetic syringe needle penetrates through the oral mucosa at the height of the maxillary vestibular fornix adjacent to the maxillary lateral incisor until the needle tip reaches the estimated level of the root tip. This injection location should reduce sensation to the maxillary incisors by infiltrating through the maxilla to block the ASA **n**er**v**e.

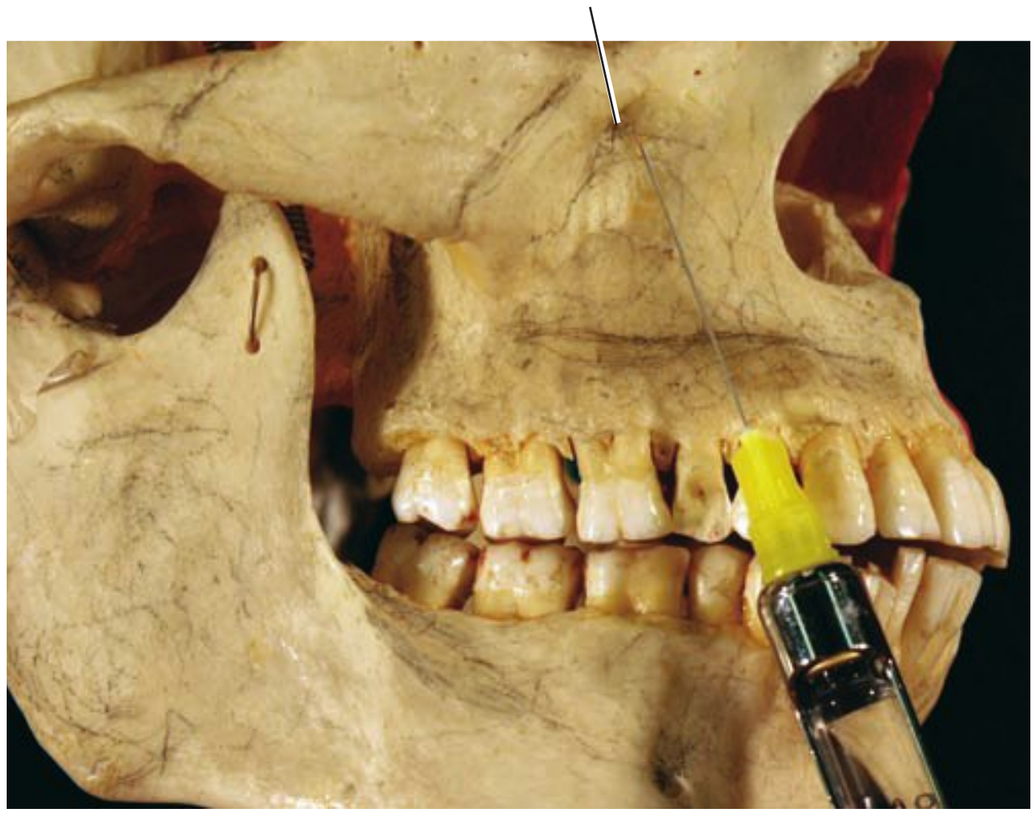

fiGUre 15-17. I**nf**ra**o**rbital **n**er**v**e l**o**cati**on**: the anesthetic syringe needle is aimed parallel to the contour of the maxilla to reach the level of the i**nf**ra**o**rbital **n**er**v**e. Anesthetic can block the infraorbital nerve where it exits the in*f*raorbital *f*oramen to reduce pain sensation in the tissues of the upper lip and facial gingiva (and part of the nose and lower eyelid) that are supplied by the infraorbital nerve branches.



fiGUre 15-18. **Inf**ra**o**rbital **n**er**v**e i**nj**ecti**on**: the anesthetic syringe needle penetrates through the oral mucosa at the height of the maxillary vestibular fornix adjacent to the maxillary canine or first premolar (similar in location and syringe angulation to an MSA or an ASA block), but the needle penetrates farther, beyond the level of the root tips, to the level of the i**nf**ra**o**rbital **n**er**v**e (felt by palpating to find the depression of the infraorbital foramen and marking the level with the finger as in the photograph).

Lo n G Bu CCAL In jECTIo n

The buccinator (long buccal) nerve is a branch of the mandibular nerve that does not pass through the mandibular foramen but is located in the soft tissue of the cheek. The anesthetic can be applied just beneath the buccal mucosa and just superior to the buccal shelf next to the mandibular molars that require facial tissue numbness (Figs. 15-19 and 15-20).



fiGUre 15-19. **Bu**ccal **n**er**v**e l**o**cati**on**: location on the skull for blocking the end branches of the (long) b**u**ccal **n**er**v**e facial to the mandibular molars and superior to the buccal shel*f*.

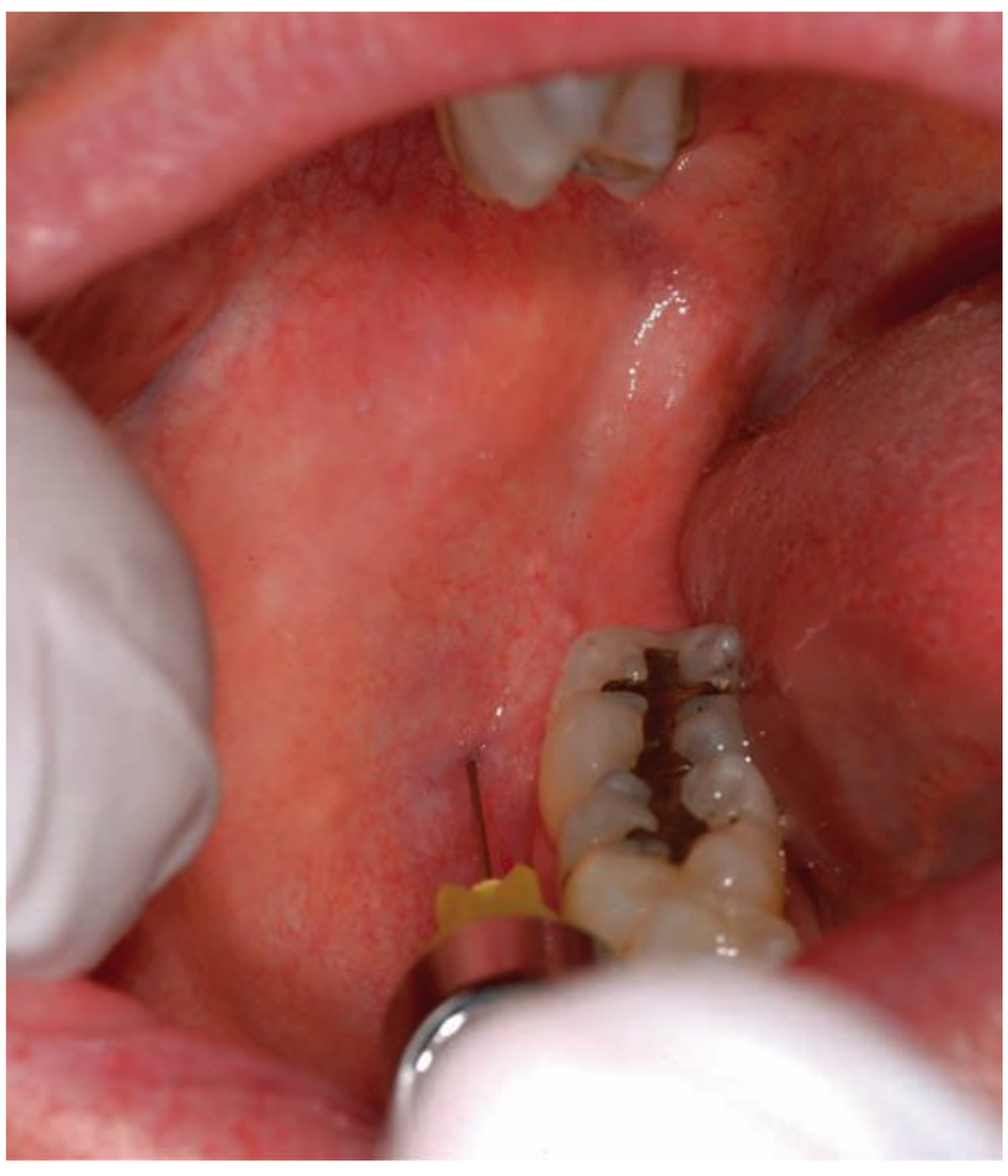

fiGUre 15-20. **Bu**ccal **n**er**v**e i**nj**ecti**on**: anesthetic syringe used to block the (long) b**u**ccal **n**er**v**e by penetrating the mucosa into the cheek just buccal to the maxillary molars. This anesthetic should reduce pain sensation to the facial soft tissue and gingiva of the mandibular molars.

B. The Palate: Roof of the Mouth

The **hard palate** is the firm anterior part of the roof of the mouth with mucosa over the underlying bone (namely, the horizontal plates of the palatine bones and palatine processes of the maxillae). The **soft palate** is the posterior movable part of the roof of the mouth without underlying bony support. The **vibrating line** is the junction between the hard and soft palate (Fig. 15-21).

1. Hard palate Structures

Refer to Figures 15-21 and 15-22 while studying the structures of the hard palate. The hard palate is covered by keratinized, grayish-red to coral pink tissue. The **incisive papilla** is the small rounded elevation of tissue on the midline of the palate just lingual to the central incisors. This papilla is located over the incisive foramen, where the nasopalatine nerve passes from the nasal cavity onto the palate to innervate the anterior portion of the hard palate. It is the location for injecting anesthetic to numb palatal tissue in this area.[B]

The **palatine raphe** [RAY fee] is the slightly elevated ridge of firm tissue running anteroposteriorly along the midline of the hard palate (over the intermaxillary suture attachment between the palatine processes of the right and left maxillae) (Fig. 15-22). The mucosa over the raphe is firmly attached to the underlying bone without intervening fat or gland cells. The rest of the tissue on both sides of the raphe has fat or salivary gland tissue beneath the surface, so it is softer. This spongy tissue at the junction of the hard palate and alveolar process next to premolars and molars is the location of the greater palatine nerve. There are more than 350 very small palatine glands in the posterior third of the hard palate.[2] They secrete thick but slippery saliva.

Palatine rugae [ROO guy] or [ROO jee] are a series of palatal tissue elevations, or wrinkles, located on the palate just posterior to the maxillary anterior teeth (Fig. 15-22). They form a pattern like branches on a tree, coming off of the common midline "trunk," the palatine raphe.[C] Rugae function in two important ways: in tactilely sensing objects or food position and in aiding the tongue's proper placement for the production of certain speech sounds.[3] This part of the palate is often burned by eating pizza when it is too hot or becomes abraded from chewing too much popcorn.

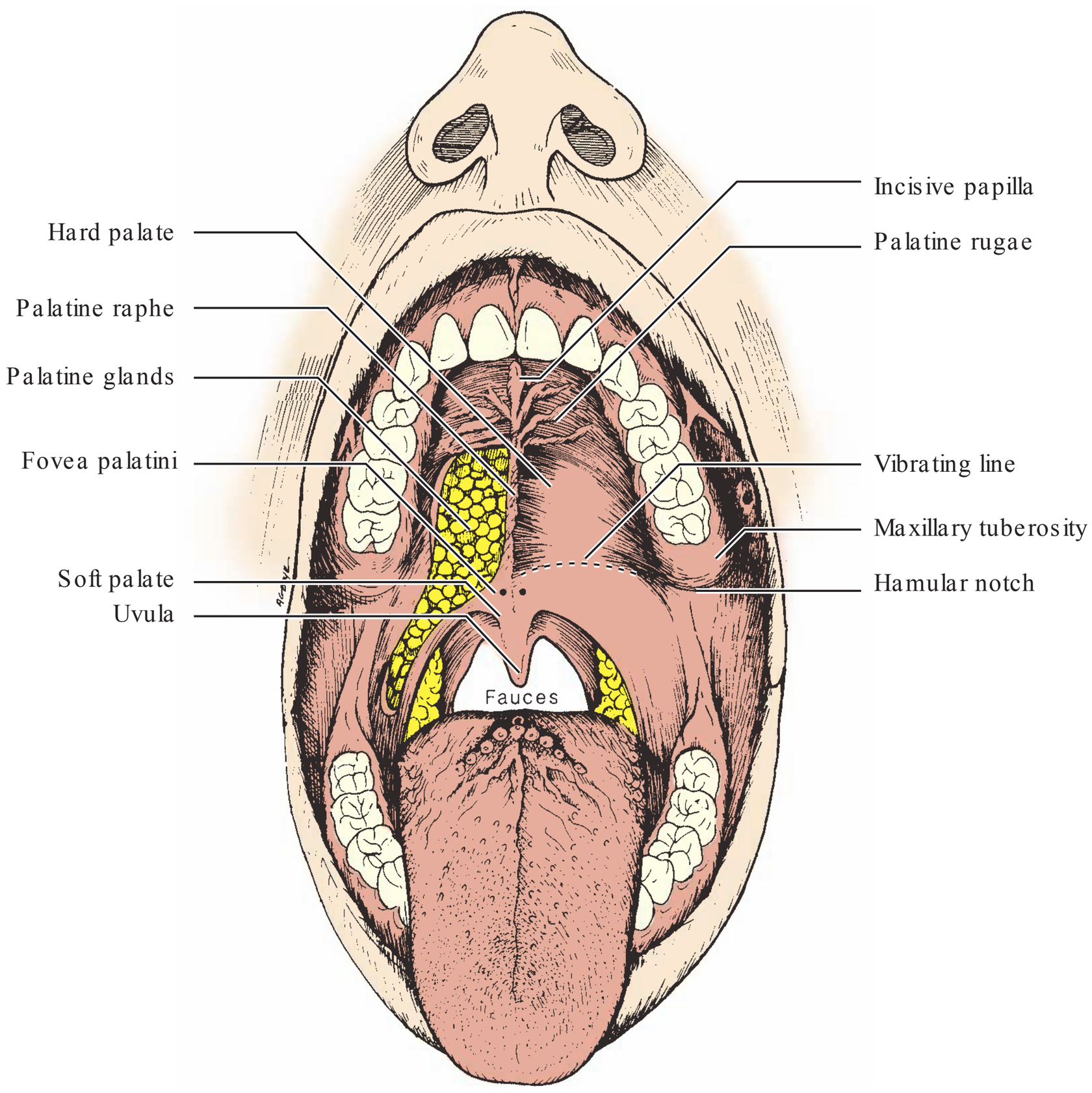

fiGUre 15-21. Structures of the hard and soft palate.

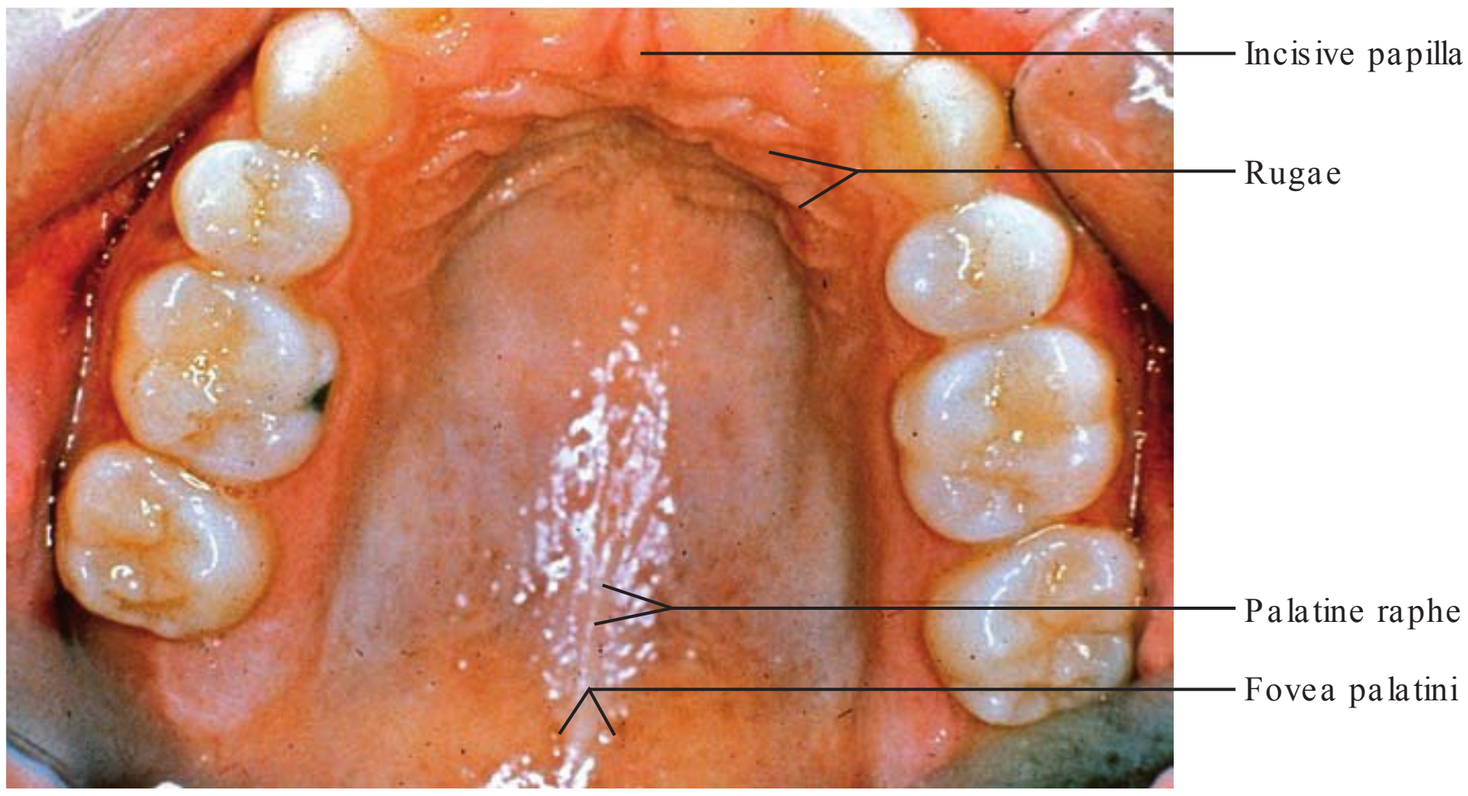

FIGURE 15-22. Structures of the hard palate: note the prominent palatine rugae (ridges) and incisive papilla (anterior midline), and the palatine raphe, which is located over the intermaxillary suture line between the right and left maxillary palatine processes. The two tiny depressions on either side of the posterior portion of the raphe are called fovea palatini.

ANTERIOR PALATINE NERVE INJECTION

In order to anesthetize the tissues of the palate, you need to block one or two nerves. The greater (anterior) palatine nerve innervates most of the palate (all tissue covering the hard palate lingual to molars and premolars) and the nasopalatine nerve for tissue lingual to the anterior teeth. Recall that both of these nerve branches split off of the maxillary nerve while in the pterygopalatine space and then pass through the nasal passageways before entering the palatal tissue. The nasopalatine nerve passes from the pterygopalatine space along the nasal septum in the nasal cavity and into palatal mucosa through the incisive foramen (Fig. 15-23), which is located immediately under the bump of very firm tissue called the incisive papilla (Fig. 15-24). This papilla is located on the palate just lingual to the midline between the maxillary central incisors. Since this tissue is very firm, only a small amount of anesthetic can be applied into this tissue, and this injection can be most painful. Applying pressure over the injection site with the handle of a mirror or with the end of a cotton-tipped applicator for 15 to 20 seconds prior to injecting can minimize this discomfort.

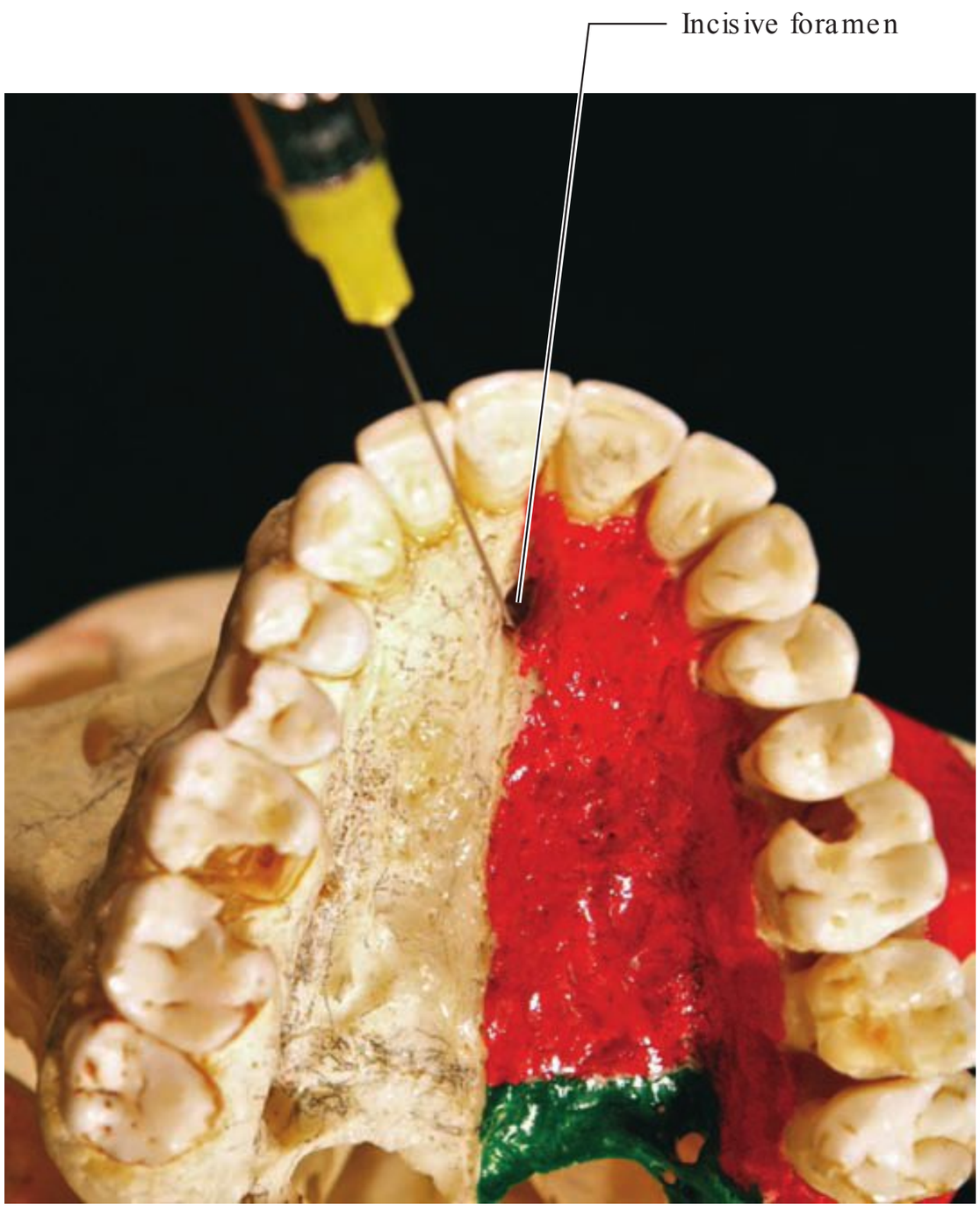

FIGURE 15-23. nasopalatine nerve location: the anesthetic syringe needle is directed toward the nasopalatine canal opening (incisive foramen) where it can block the nasopalatine nerve, which enters the palate at this location. (On this skull, the palatine process of the one maxilla is painted red, and one palatine bone is painted green.)

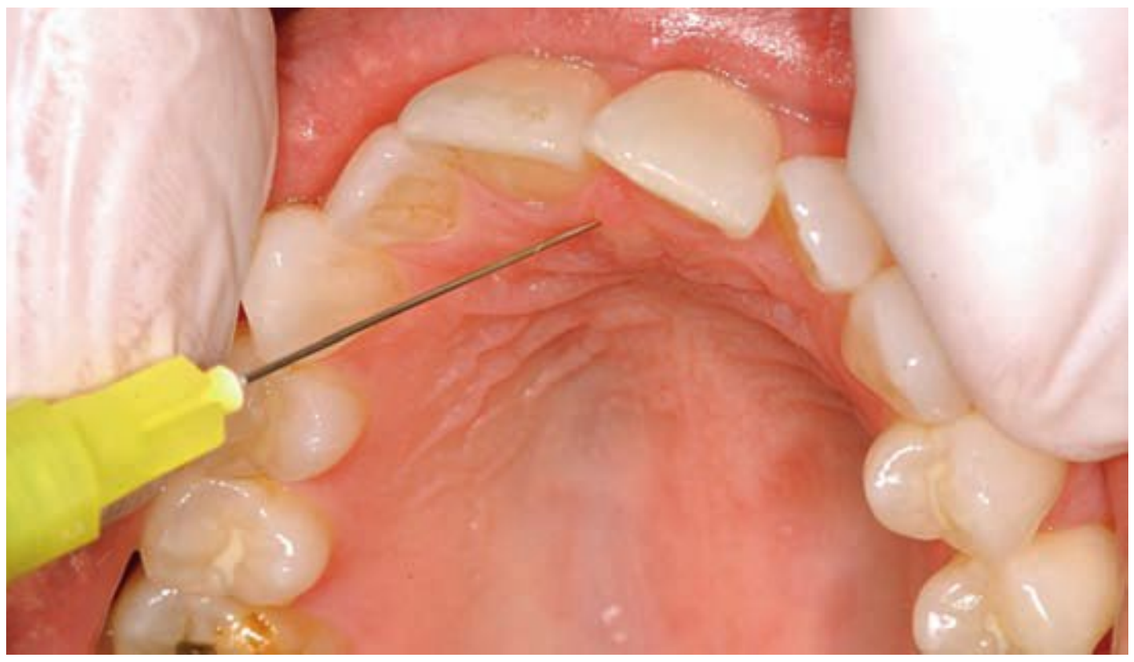

fiGUre 15-24. nasopalatine nerve injection: the anesthetic syringe needle is penetrating the very firm tissue of the incisive papilla overlying the opening to the incisive foramen in order to block the nasopalatine nerve. This should reduce pain sensation to the palatal soft tissues lingual to the anterior teeth. Since this injection site is so sensitive (it has been known to bring tears to the eyes), it is recommended to place pressure over the incisive papilla with a mirror handle or cotton-tipped applicator for a brief time prior to injecting with the needle.

GREATER PALATINE NERVE INJECTION

The greater palatine nerve passes from the nasal cavity to palatal tissue through the greater palatine foramen located just lingual to the third molars at the junction of the most posterior part of the horizontal bone of the hard palate and the more vertical alveolar process surrounding the maxillary posterior teeth (Fig. 15-25). The greater palatine nerve spreads anteriorly toward the tissue lingual to the first premolar along the junction of the alveolar process and palate covered by tissue that is softer and more spongy than the tissue covering the midline of the hard palate. When locating or palpating this location, care must be taken to avoid touching the soft plate (posterior to the underlying bones of the palate) since this may elicit a gag reflex causing the patient to vomit. A small amount of anesthetic may be placed into this spongy tissue, resulting in numbness of tissues adjacent to and anterior to the injection site (Fig. 15-26).

Note: It is also possible to reach the entire maxillary branch of the trigeminal nerve just after it exits the cranium through the foramen rotundum while it is still within the pterygopalatine space and anesthetize all of the maxillary branches (called a second division block). This location is superior to the location of the PSA block already discussed. Anesthetic deposited in this location reduces pain to the structures supplied by the PSA, MSA, ASA, greater palatine, and nasopalatine nerves. Caution must be taken in this area because the pterygoid plexus of vessels is located here, and cutting a vessel wall could result in bleeding under the skin called a hematoma.



fiGUre 15-25. Greater palatine location: the anesthetic syringe needle is directed toward the greater palatine foramen opening where it can block the greater palatine nerve (represented here by yellow wires), which enters the palate at this location. The branches of this nerve supply half of the hard palate tissue located between the posterior teeth.

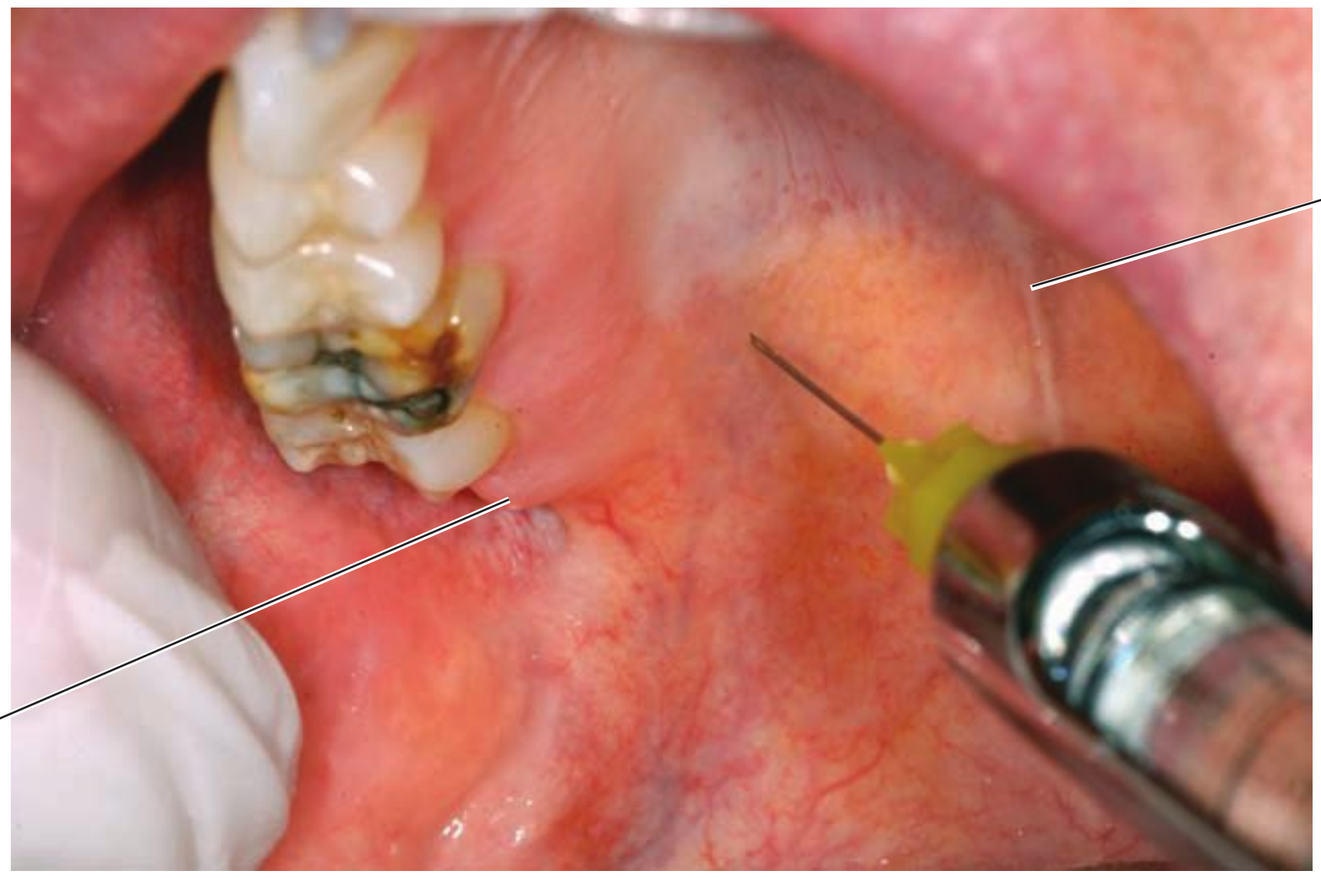

fiGUre 15-26. Greater palatine injection: the anesthetic syringe needle penetrates the relatively spongy palatal mucosa near the junction of the vertical alveolar process and horizontal palatine process of the right maxilla near the third molar to reach the greater palatine nerve where it enters the palate through the greater palatine foramen. This injection should reduce pain sensation on the right side to the palatal soft tissues lingual to the posterior teeth up to the midpalatine suture.

2. the Soft palate

The **soft palate** (Fig. 15-27) is located posterior to the hard palate. Along with the hard palate, it separates the mouth from the nasal passage. It is sometimes redder than the hard palate because of its slightly increased vascularity. Its anterior border extends between the right and left third molars. Unlike the hard palate, there is no bone beneath the surface of the soft palate. If you forcefully say "ah, ah, ah," you can see the soft palate move (or vibrate) up and down whereas the

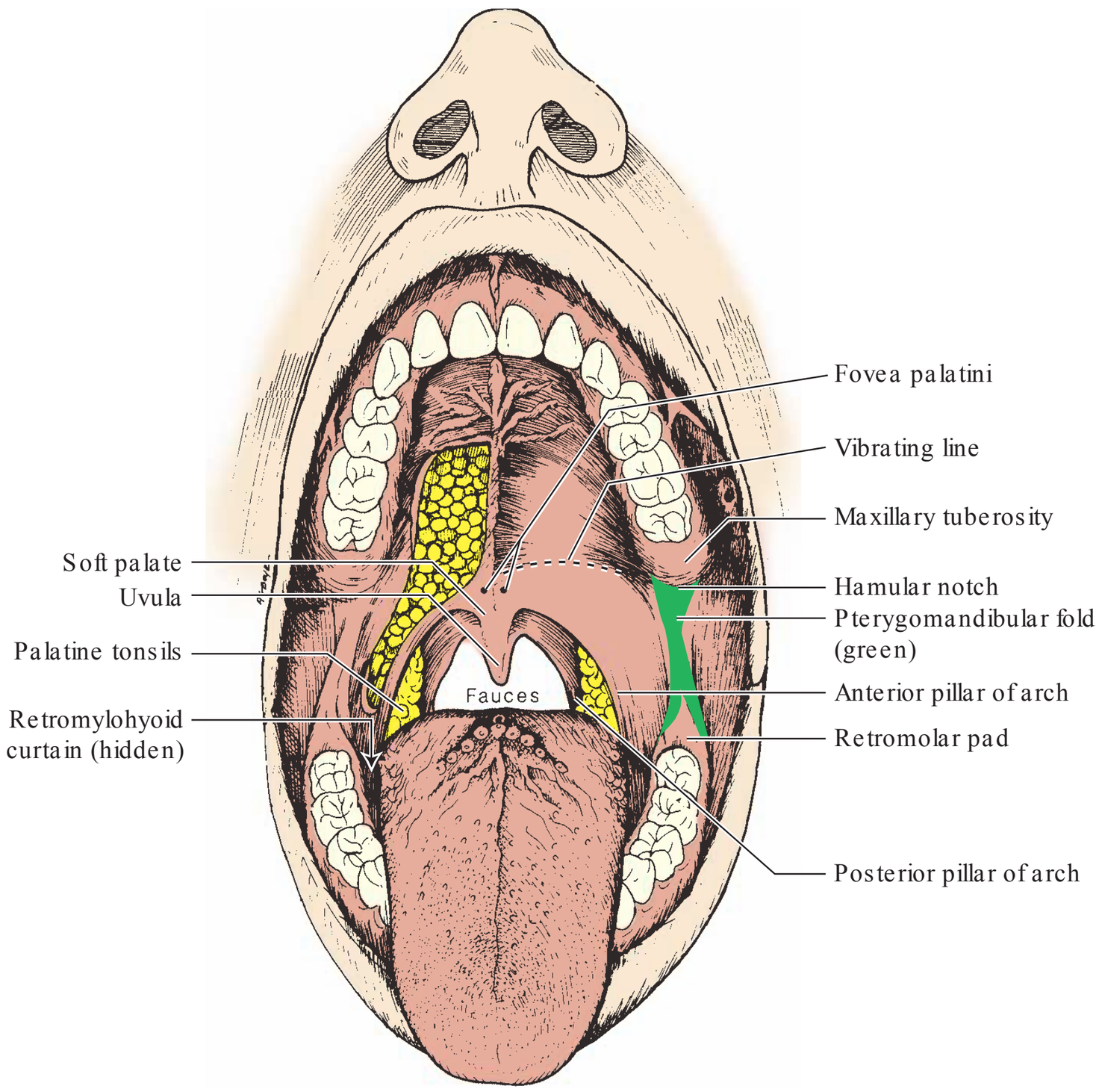

fiGUre 15-27. Structures surrounding the fauces (oropharynx): the pterygomandibular fold is green.

hard plate does not. The place where you observe the beginning movement of the soft palate is the **vibrating line. Fovea palatini** [FO ve ah pal a TEEN ee] are a pair of pits in the soft palate located on either side of the midline, near but just posterior to the vibrating line (Fig. 15-22). They are openings of ducts of minor palatine mucous glands.[3] The **uvula** [YOU view la] is a small fleshy structure hanging from the center of the posterior border of the soft palate (Fig. 15-27).

The soft palate functions during swallowing and speech. The **pharynx** [FAR inks] is the superior part of the digestive tube between the nasal passageways, oral cavity, and esophagus. During swallowing, the soft palate raises to close off the nasal portion of the pharynx from the oral pharynx (oropharynx) to prevent upward movement of food into the nasal cavity. The soft palate is raised to seal the oral cavity from the nasal cavity during blowing or when producing explosive consonants (like "b" and "p").

c. oropHArynx: fAUceS, pAlAtine ArcHeS, And tonSilS

Refer to Figure 15-27 while studying the fauces and surrounding structures. The **fauces** [FAW seez] is the posterior boundary of the oral cavity. It is the opening from the mouth into the oropharynx (throat) for air when breathing through the mouth to reach the lungs and for food since the oropharynx leads to the esophagus and stomach. The fauces is bounded inferiorly by the dorsum (upper surface) of the tongue, laterally by palatal arches or pillars, and superiorly by the soft palate. Examine the fauces and palatine arches by having a partner open wide and say "ahhh…." You may have to gently push the tongue down with a tongue depressor. Be careful: patients may gag.

Two pillars make up each of the two arches. Identify the **anterior palatine arch** (two pillars) that descends from the soft palate. The smaller **posterior palatine arch** is visible behind it (anterior and posterior pillars seen in Fig. 15-27). The **anterior arch** is also named the **glossopalatine** [GLOSS o PAL a tine] **arch,** and the **posterior arch** is also called the **pharyngopalatine** [fah RING go PAL a tine] **arch**, after the muscles beneath them. (Hint to remember these terms: The arch from the tongue [glosso] to the palate [the glossopalatine anterior arch] is more anterior than the arch from the pharynx or throat posterior to it [pharyngopalatine posterior arch].) (See Fig. 15-28.) The **palatine tonsils**, when present, are located between the anterior and posterior pillars. These tonsils may become enlarged and inflamed during infections of the respiratory system. Patients may have had these surgically removed.

Although not part of the oropharynx, there are several landmarks just posterior to the last molars that will be presented here. Immediately posterior to the maxillary last molar is a firm tissue bulge over the bone of the alveolar ridge called the **maxillary tuberosity** (Fig. 15-27). This tuberosity

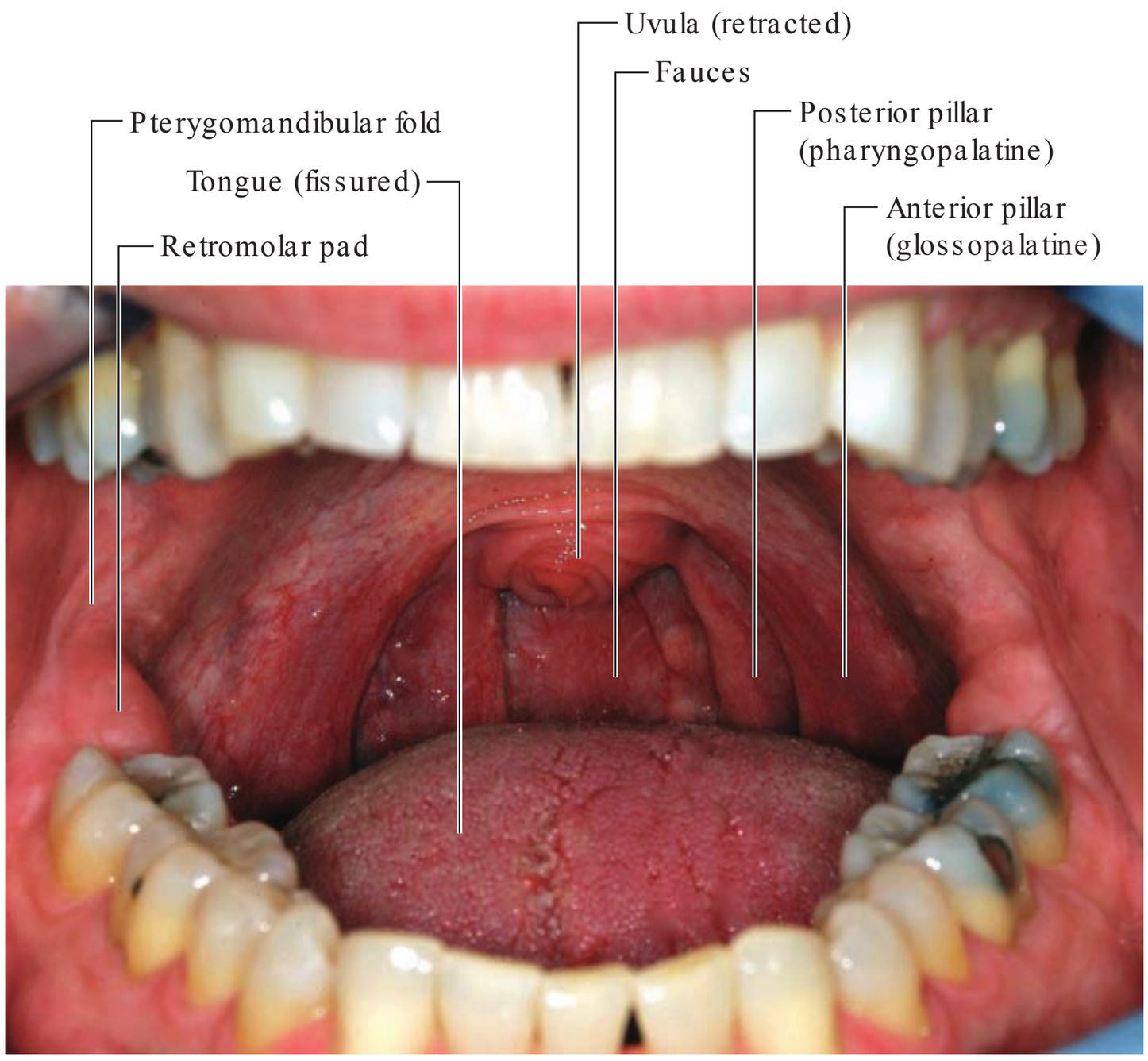

fiGUre 15-28. **oropharynx** showing the retr**omo**lar pad and pterygo**m**a**n**dib**u**lar **fo**ld extending upward from the last mandibular molars as well as structures surrounding the fauces: **uvu**la (retracted), a**n**teri**o**r pillars (making up glossopalatine arch), and p**o**steri**o**r pillars (making up pharyngopalatine arch).

is present even after all of the teeth have been lost and is included in an impression of the upper arch when constructing a maxillary complete denture. A similar, less prominent elevation of movable tissue distal to the mandibular last molar is the **retromolar pad** (Fig. 15-28). (Hint: "Retro" means behind, or distal, to the last molar.) When a person has fully erupted third molars, the maxillary tuberosity and mandibular retromolar pad on each side are small because of the proximity of these adjacent teeth. The **pterygomandibular** [TER i go mand DIB you lar] **fold** gets its name since it is a fold of tissue that connects the retromolar pad of the mandible with the pterygoid process just distal to the maxillary tuberosity. This is easy to see when the mouth is opened wide as this action stretches this fold (Fig. 15-27). This fold is an important landmark for the anesthetic syringe needle to enter when aiming toward the mandibular foramen in order to block the inferior alveolar nerve just before it enters the mandibular canal. The **retromylohyoid** [REH tro my lo HI oid] **curtain** is a curtain of mucous membrane along the medial, posterior portion of the mandible near the floor of the mouth, extending between the anterior pillar of the fauces and the pterygomandibular fold. An arrow points to the location of this curtain (but it is not visible) in Figure 15-27. It is an important limiting structure when forming the lingual border (flange) of a mandibular complete denture.

Inferior Alveolar Injection: Anesthetizing Mandibular Teeth, Surrounding Tissue, and Adjacent Floor of Mouth and Tongue

The nerves being blocked here are branches of the third division or mandibular branch of the fifth cranial (trigeminal) nerve. Since the bone of the mandible is more dense than in the maxillae, to reduce pain for all structures supplied by the entire inferior alveolar nerve, the anesthetic is deposited next to the mandibular nerve before it enters the mandibular foramen. Recall that the mandibular *f*oramen is located on the medial surface of the ramus of the mandible, a little over halfway from the anterior to the posterior border of the ramus (Fig. 15-29). On most adults, the foramen is also located a small distance (on average about 5 mm or 1/4 to 1/2 inch) superior to the level of the occlusal surfaces of the posterior teeth. In order to reach the mandibular foramen, the needle penetrates the mucosa of the pterygomandibular *f*old about 1/2 inch above the occlusal plane (Fig. 15-30). (On an edentulous patient, use the landmark of the retromolar pad and inject just slightly superior to it.) After penetration into the mucosa, continue moving the needle tip parallel to the medial surface of the ramus until you reach the location of the inferior alveolar nerve, that is, slightly beyond halfway from the anterior to the posterior border of the ramus. Recall that the internal surface of each ramus, when viewed from above, diverges wider as it goes posteriorly, so the handle of the syringe must be angled across the premolars on the opposite side in order to parallel the medial surface of the ramus. This angle is evident in Figure 15-31 and can also be seen in the mouth in Figure 15-30. If bone is touched before reaching the estimated depth of the foramen, or if the bone is not reached when you are well beyond the foramen, you need to pull back the needle, reangle the syringe, and try again. If bone is reached at the estimated location of the inferior alveolar nerve, pull back the needle very slightly to avoid damaging the bone, then aspirate to ensure you are not in a vessel, and inject the anesthetic.

Anesthetic can be placed in small amounts at intervals while entering through the mucosa toward the mandibular foramen (reaspirating each time) in order to reach the lingual nerve branch, which is next to the inferior alveolar nerve. Because the lingual nerve is located within the tissue adjacent to the mandibular nerve (Fig. 15-32), the anesthetic can infiltrate through tissue to reach the lingual nerve and result in numbness to the anterior half of the tongue and adjacent lingual mucosa of the foor of the mouth on the side being injected. Blocking the inferior alveolar nerve and lingual nerve should reduce pain in all mandibular teeth and almost all surrounding tissues but should also numb half of the tongue and half of the lip on that side. The only area not numb would be the tissue just buccal to the molars, which is innervated by the buccinator (long buccal) nerve (described earlier).

If only tissue or pulps of mandibular premolars or anterior teeth need to be anesthetized, the anesthetic solution can be applied at the location of the mental *f*oramen (Fig. 15-33). At this location in the mandible, the mental nerve branches off the inferior alveolar nerve and exits the mandible to spread anteriorly and innervate the lower lip and adjacent labial tissue. Just inside of this foramen, the inferior alveolar nerve continues forward within the mandible as incisive branches to innervate the pulps of anterior teeth. This foramen is normally palpable (and evident on radiographs) at a level between or near the root tips of the mandibular premolars. The injection enters mucosa at the depth (fornix) of the buccal vestibule extending to the level of the palpated foramen. Due to the posterior superior direction of the canal inside of the mental foramen, it is best to direct the needle inferiorly and slightly from the distal (Fig. 15-33). An advantage of this injection is that it does not numb any of the tongue, so it does not affect the ability of the person to speak as might occur with an inferior alveolar block that numbs the tongue on the side of the injection.

Note: It may also be possible to anesthetize only mandibular incisors by placing the anesthetic just labial to the alveolar bone facial to the root tips of the mandibular anterior teeth. Even though the mandibular bone is dense, this may be successful if the bone overlying these roots is quite thin. Using this technique, one can numb the mandibular facial tissue and anterior teeth, but neither this mandibular facial infiltration technique nor the mental nerve block will numb the lingual tissue or tongue.

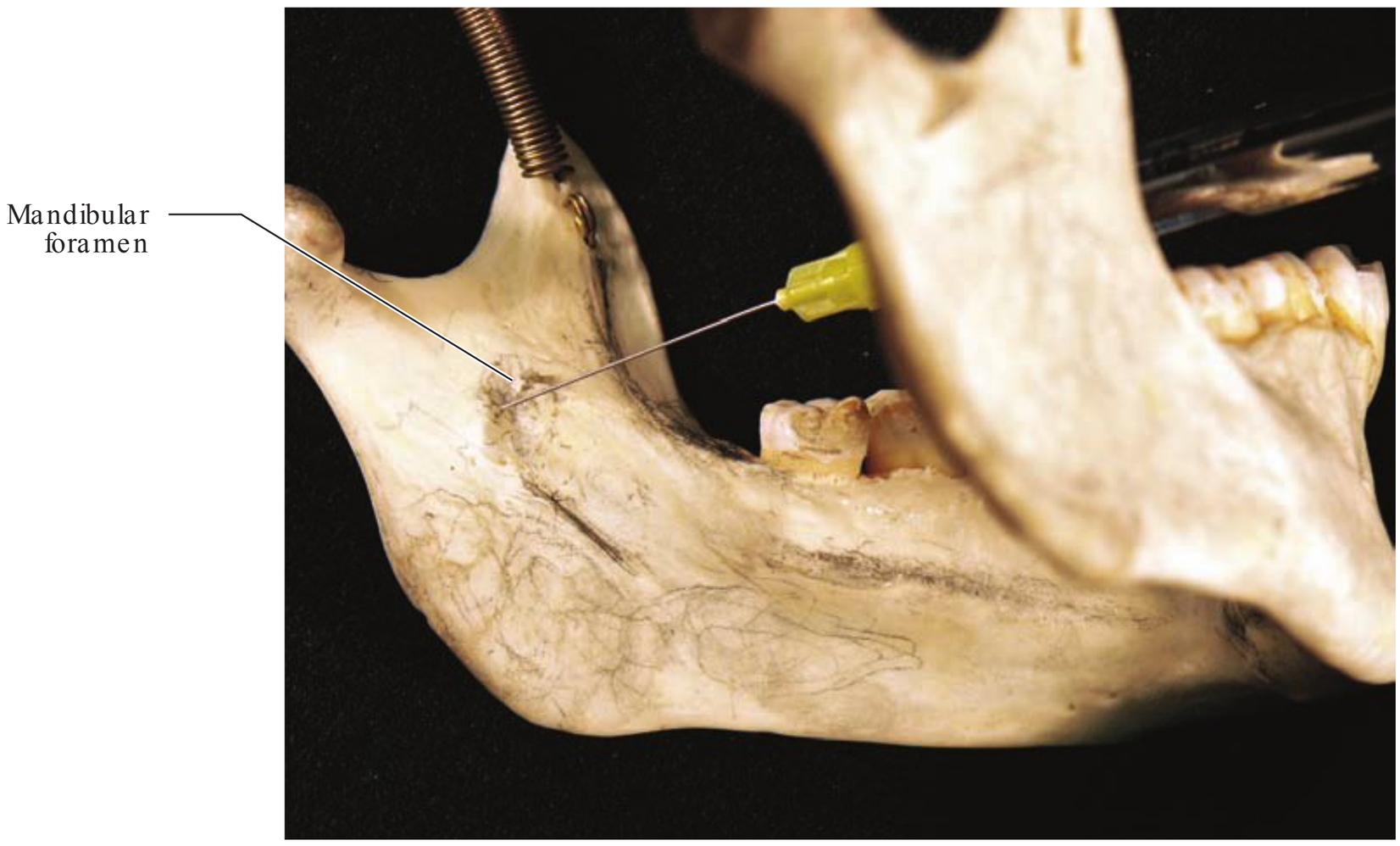

fiGUre 15-29. **Inf**erio**r** a**l**ve**o**lar **n**er**v**e l**o**cati**on**: anesthetic syringe needle tip placed at the location on the mandible for blocking the i**nf**erio**r** a**l**ve**o**lar **n**er**v**e before it enters the mandibular *f*oramen and canal. Note the position of the mandibular foramen about halfway between the anterior and posterior border of the ramus and the foramen location relative to the occlusal plane of the mandibular teeth (which is slightly superior to the plane by about 5 mm).

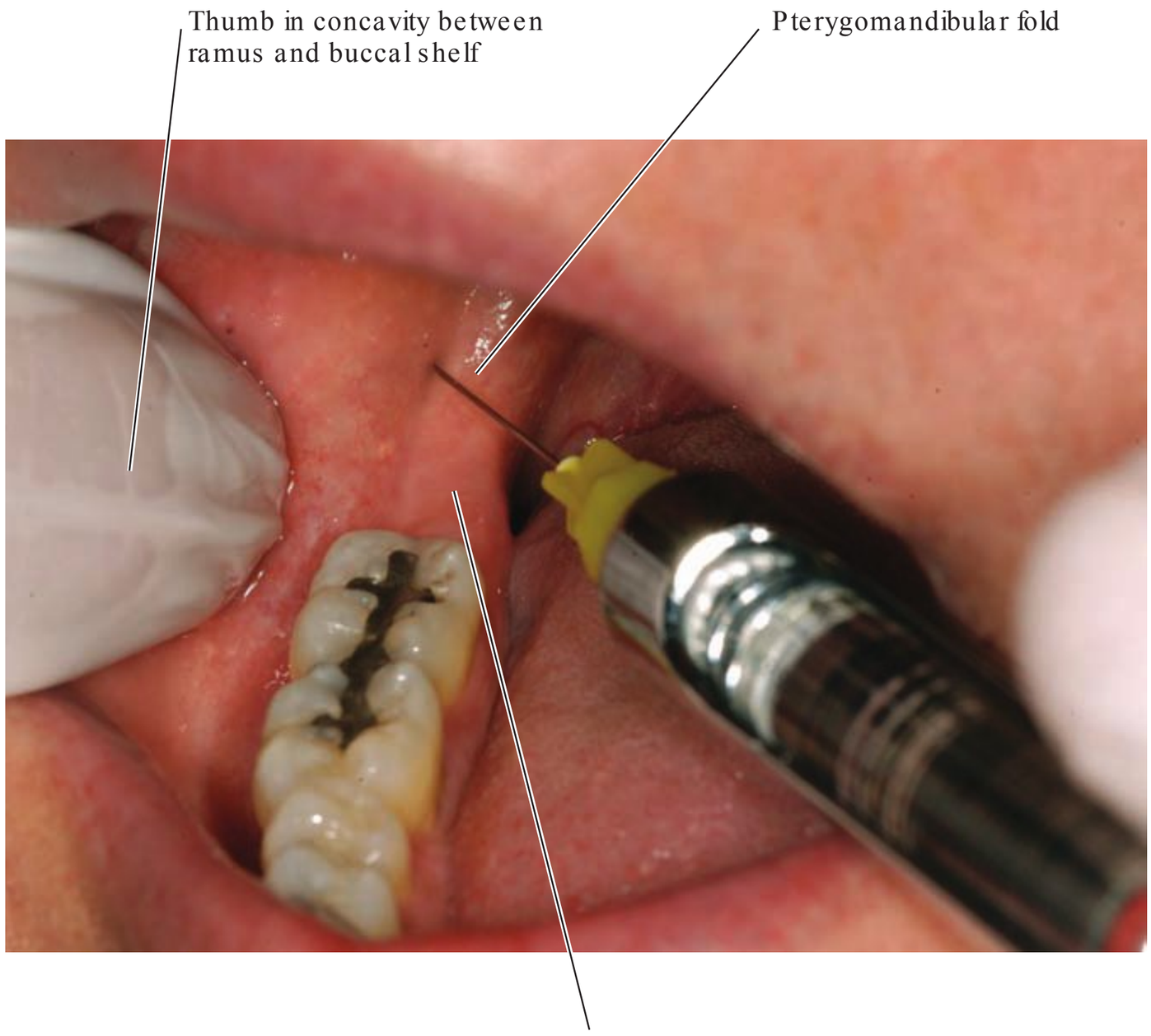

fiGUre 15-30. **Inf**erio**r** a**l**ve**o**lar **n**er**v**e i**nj**ecti**on**: anesthetic syringe needle tip aiming toward the i**nf**erio**r** a**l**ve**o**lar **n**er**v**e by penetrating the oral mucosa at the location of the pterygomandibular *f*old just occlusal to the retromolar pad. By angling the syringe cartridge over the premolars on the opposite side, the needle can be directed toward the inferior alveolar nerve where it enters the mandible through the mandibular canal. For the average-sized person, a long needle penetrates to about half of its total length in order to reach the ramus and foramen, but this depth may be deeper for a very large-boned person or less deep for a very small-boned person.

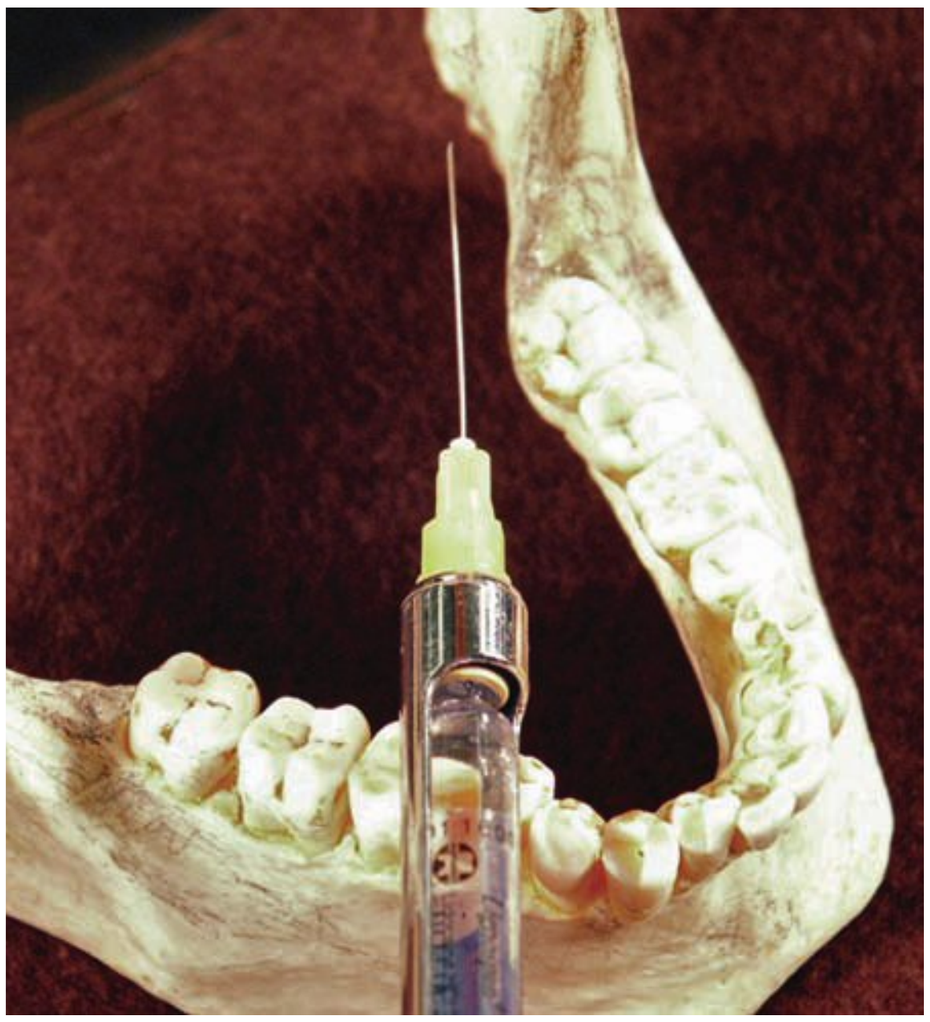

Figure 15-31. **Inferior alveolar nerve location**: a superior view of the **mandible and ramus** showing the angle of the syringe required to reach the opening of the mandibular canal. The syringe cartridge must be directed over the premolars on the opposite side in order to parallel the internal surface of the ramus (which diverges considerably posteriorly).

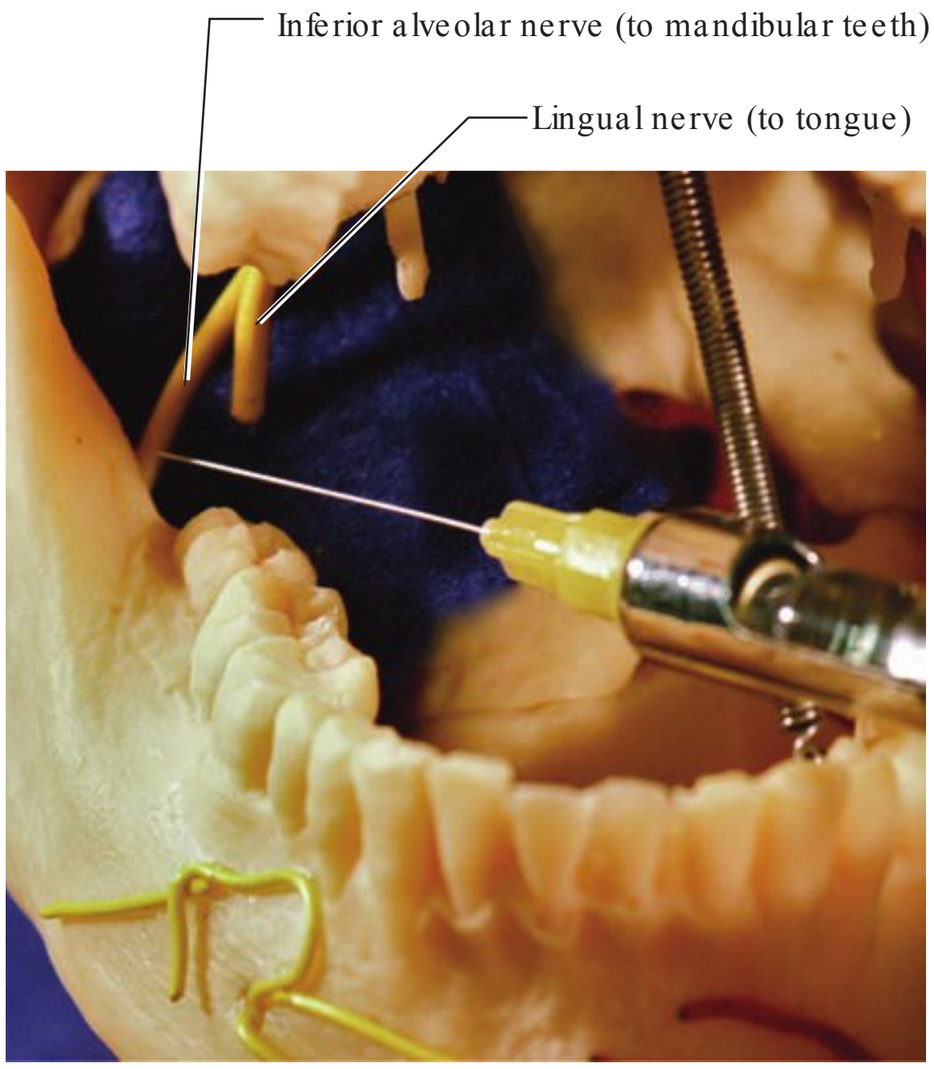

Figure 15-32. **Inferior alveolar nerve and lingual nerve location**: two wires represent the **inferior alveolar nerve** (touched by the needle) and a cut portion of the **lingual nerve** branch (which goes to the tongue). Notice that the lingual nerve would be anesthetized if some anesthetic were applied prior to reaching the inferior alveolar nerve.

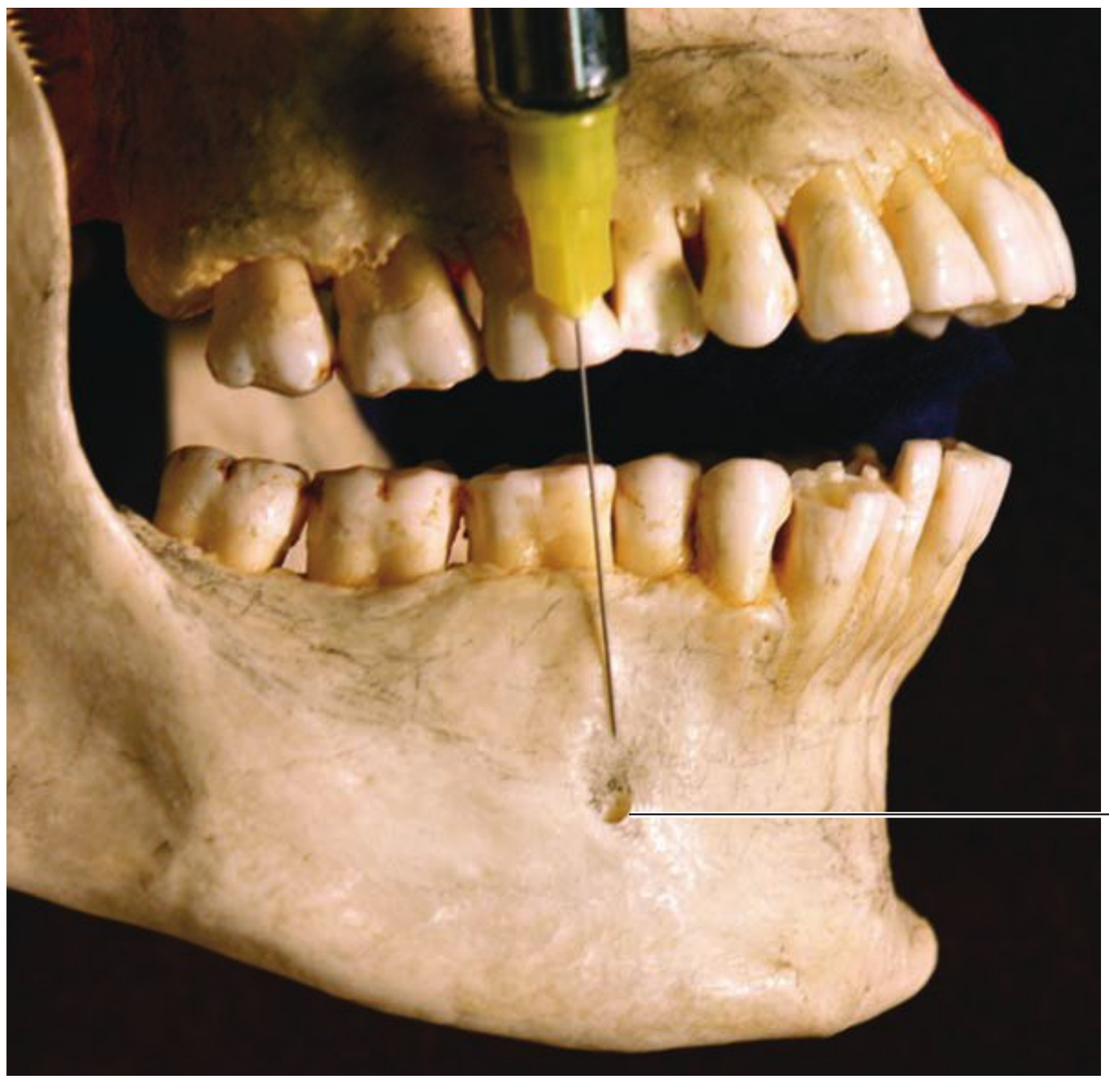

Figure 15-33. **mental nerve location**: the syringe needle tip is located adjacent to the mental *f*oramen. Note its location near the estimated root tips of the mandibular premolars. Applying anesthetic here can reduce pain to the soft tissue of the chin and lower lip on that side by blocking the **mental nerve**, which splits off the inferior alveolar nerve and exits the mandibular at this location. If enough concentration of anesthetic makes its way into the opening of the mental foramen, it can also reduce pain to premolar teeth and adjacent gingiva (and possibly anterior teeth by blocking the **incisive branches** of the inferior alveolar nerve that supply the anterior teeth). This injection would not numb the tongue.

d. tongue

The tongue is the principal organ of taste and is invaluable during speech, mastication (keeping the food between the teeth), and **deglutition** (swallowing). It is a broad, flat organ largely composed of muscle fibers and glands. It rests in the floor of the mouth within the curved body of the mandible. The tongue changes its shape with each functional movement. The anterior two thirds is called the **body** (the part that is most visible during an intraoral examination of the tongue), and the posterior one third is the tongue base or **root** (which is difficult to see in most mouths since it is back so far). Recall that the body of the tongue is innervated for touch and pain by cranial nerve V (the trigeminal nerve) and for taste by cranial nerve VII (chorda tympani branches) of the facial nerve. The base or root of the tongue is innervated for taste and feeling by cranial nerve IX (the glossopharyngeal nerve). The part we see when someone sticks out their tongue is the dorsal (upper) surface. The part we see when someone raises their tongue to touch the palate is called the ventral (lower) surface.

1. dorsum of the tongue

Use Figure 15-34 as a guide for landmarks on the **dorsum** (**dorsal** or superior surface) of the tongue, but realize that most people are unable to stick their tongue as far forward as in this illustration. The dorsum of the tongue is grayish-red and is rough. It is covered by two kinds of papillae [pah PILL e] or projections. The fine hair-like **filiform papillae**, which are quite numerous, cover the anterior two thirds of the dorsal surface of the tongue. The more sparse, scattered, and shorter **fungiform papillae** are easy to identify because of their larger round shape and deep red color (Fig. 15-35). Fungiform papillae get their name because they have a mushroom [fungus] shape when viewed in cross-section from the side. Fungiform papillae are most concentrated near the tip of the tongue.[2]

A third type of papilla is found near the junction of the body and root of the tongue. The **circumvallate** [ser kum VAL ate] **papillae** are 8 to 12 prominent, flat, mushroom-shaped papillae forming a V-shaped row on the dorsum near the posterior third of the tongue (Fig. 15-35). Their walls

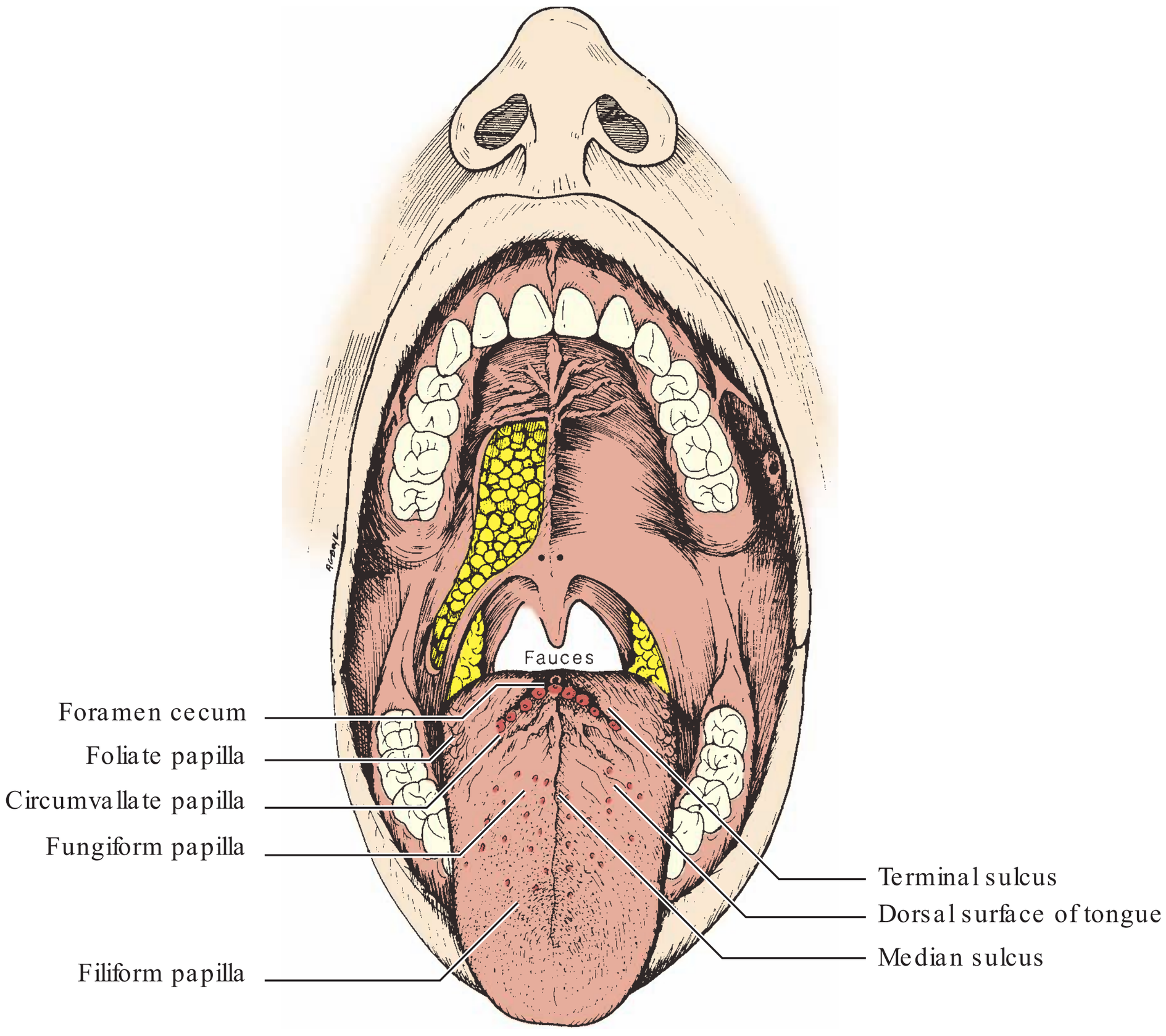

figure 15-34. Structures of the dorsal (top) surface of the tongue.

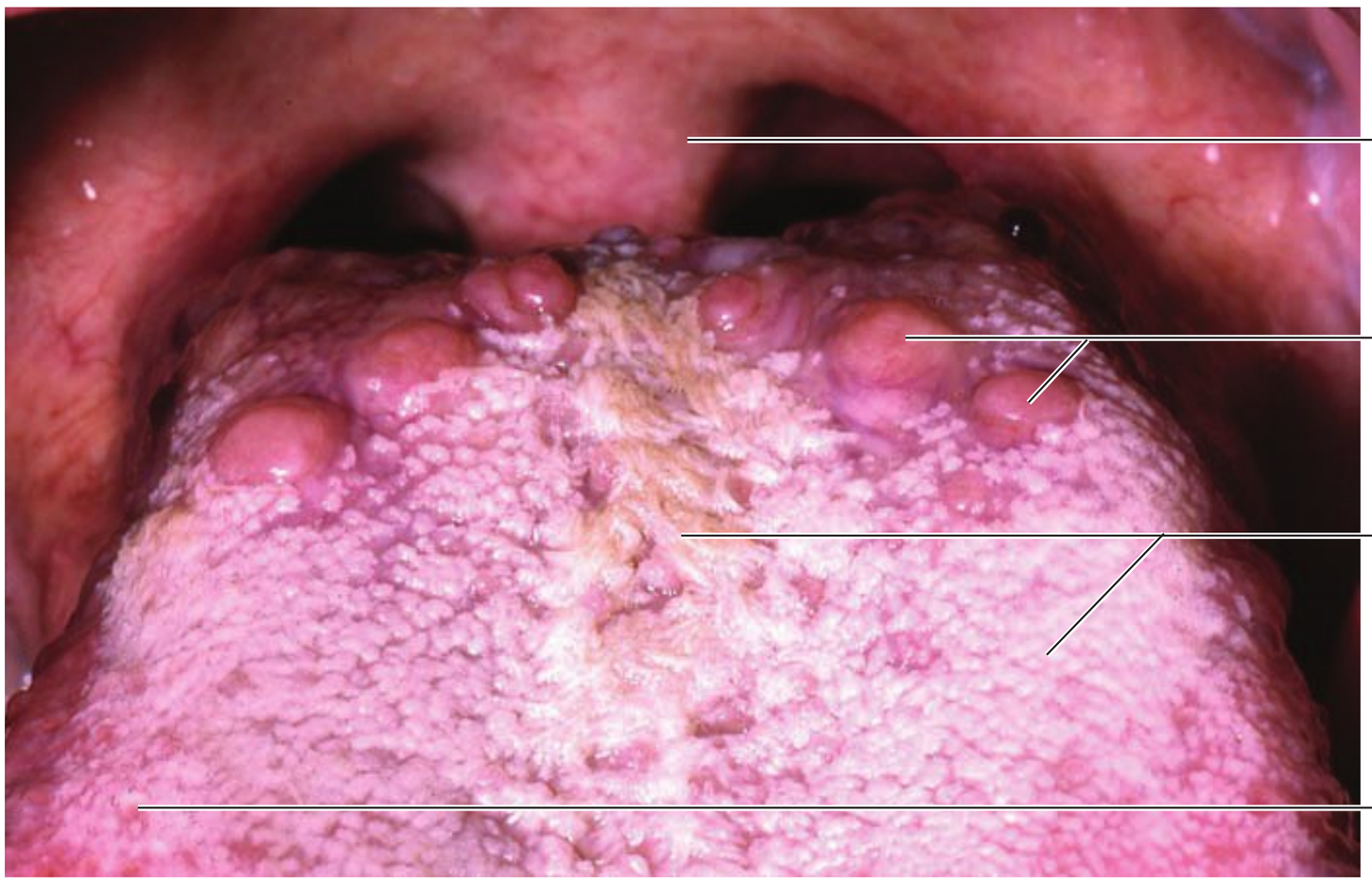

fiGUre 15-35. Dorsal surface of the tongue: structures include the row of prominent circumvallate papillae, numerous hair-like filiform papillae (which are normally not this long), and a few small round, red fungiform papillae. The uvula is above the tongue. (Photo courtesy of Carl Allen, D.D.S., M.S.D.)

contain numerous taste buds. The **terminal sulcus** is a shallow groove located just posterior to the circumvallate papillae, and it separates the body of the tongue from the root of the tongue (Fig. 15-34). The **foramen cecum** [SEE kum] is a small circular opening in the center of the terminal sulcus immediately posterior to the circumvallate papillae. This foramen is the remnant of the thyroglossal duct from which the thyroid gland developed. Posterior to the terminal sulcus, the smoother posterior one third of the dorsum contains numerous mucous-producing glands and lymph follicles (or nodules) referred to as the **lingual tonsil** (not visible on Fig. 15-34). Because of the extremely posterior location of the circumvallate papillae and their neighboring structures, you need to hold the tongue quite firmly with a damp gauze pad and gently pull it forward. The tongue muscles that may fight you in this endeavor are innervated by cranial nerve XII (hypoglossal nerve).

In order to view the lateral surfaces of the tongue, use the damp gauze pad to gently pull the tongue first to one side, then to the other. A fourth type of papillae visible on these lateral surfaces of the tongue are large, red, leaf-like projections known as **foliate** [FO li ate] **papillae** (Fig. 15-36). They contain some taste buds.

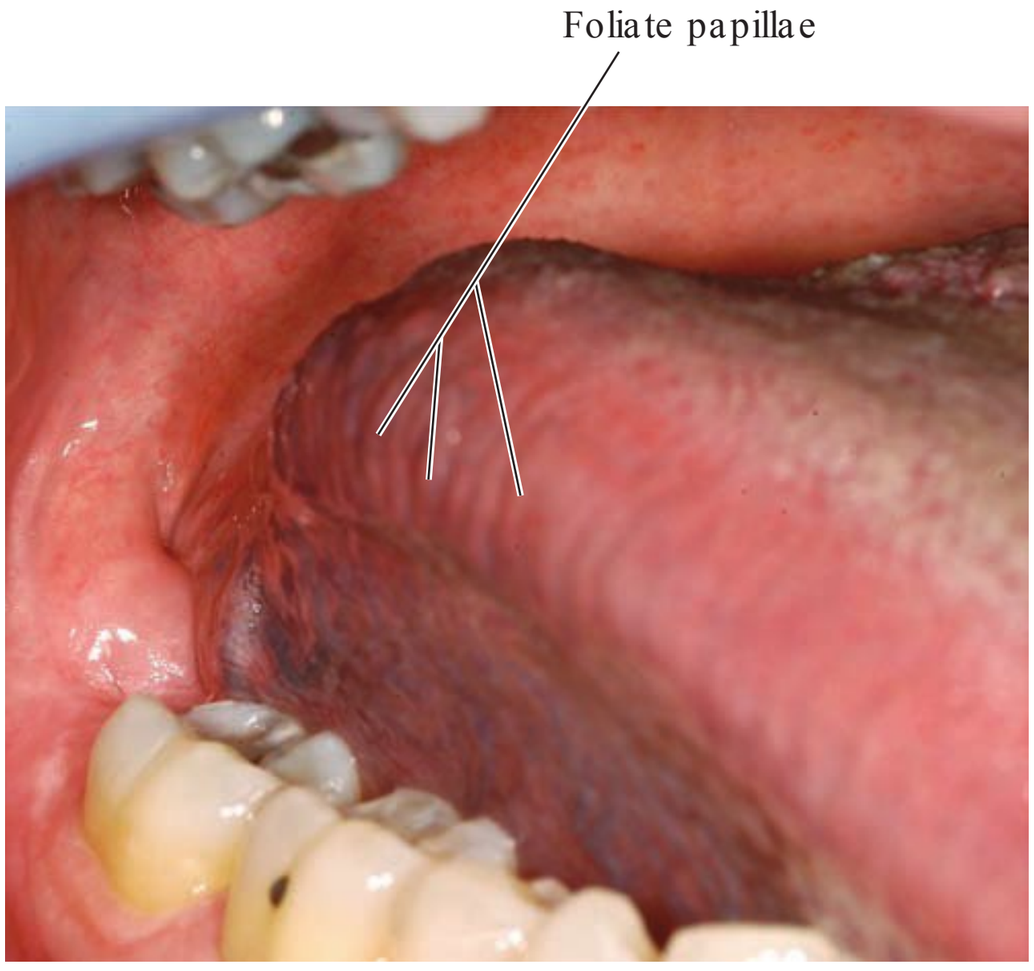

fiGUre 15-36. Lateral surface of the tongue: prominent fold-like foliate papillae must be distinguished from oral cancer that may develop in this area. (Photo courtesy of Carl Allen, D.D.S., M.S.D.)

2. ventral Surface of the tongue

The **ventral** or undersurface of the tongue is shiny, and blood vessels are visible. Refer to Figure 15-37. The **lingual frenum** is a thin sheet of tissue at the midline that attaches the undersurface of the tongue to the floor of the mouth. Look in a mirror and raise your tongue to watch how this tissue fold limits the amount of tongue movement.[D] In a person who is tongue tied, the lingual frenum is attached to mucosa on the lingual surface of the mandible perhaps only 3 or 4 mm inferior to the gingival margins of the central incisors. Further, as the tongue moves, this frenum could pull on the attached gingiva, contributing to loss of attached gingiva and subsequent periodontal problems. A simple surgical procedure can change this area of attachment.

Plica ȧmbriata [PLY kah fim bri AH tah] (also called **ȧmbriated folds**) are delicate fringes of mucous membrane on each side of the frenum on the ventral surface of the tongue. The free edge of this fold may have a series of fringe-like processes. These are very delicate and often dif -

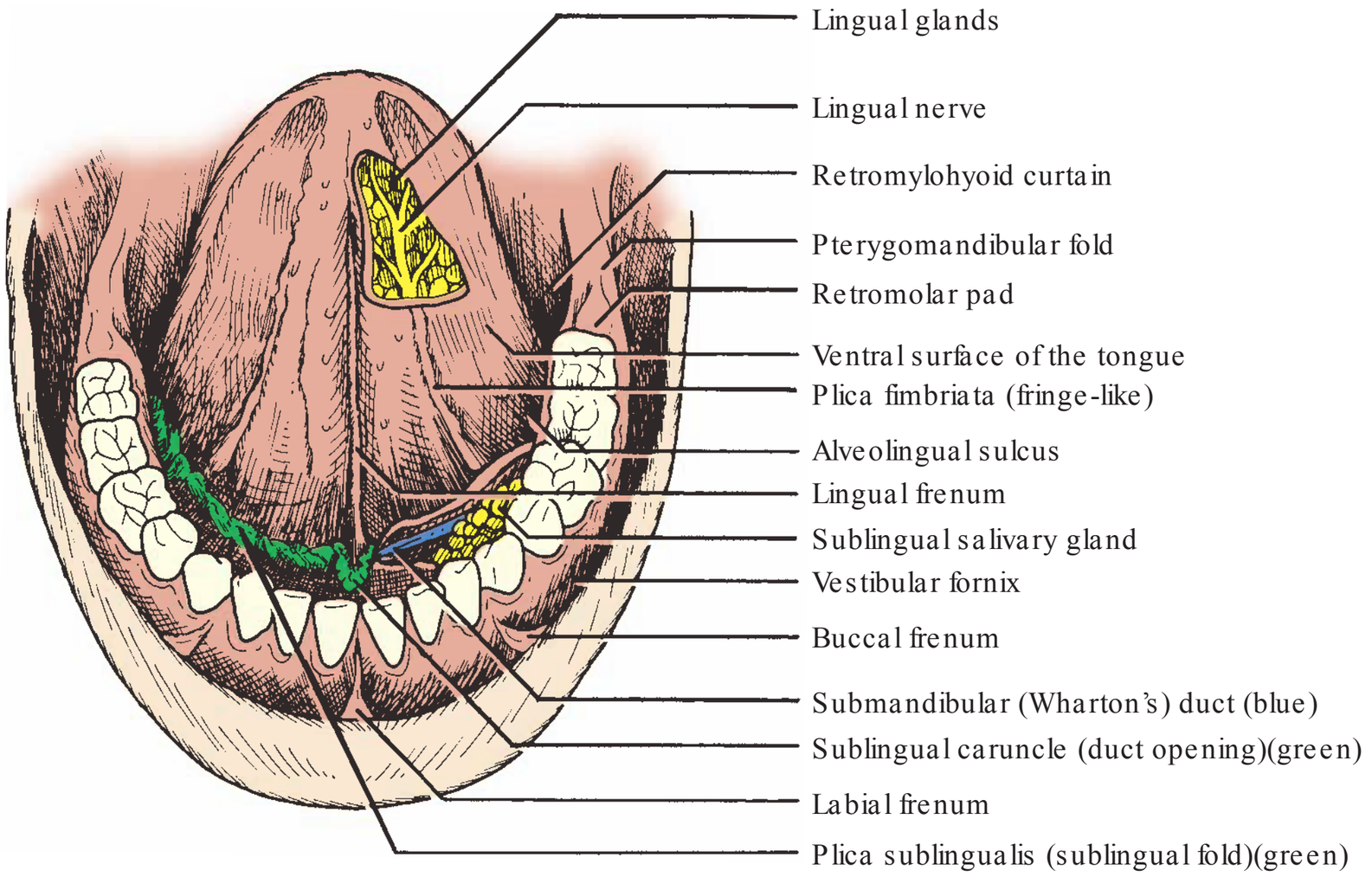

fiGUre 15-37. **Structures of the ventral (under) surface of the tongue and floor of the mouth:** some mucosa was dissected away on one side of the tongue and floor of the mouth to reveal the sublingual salivary gland (seen on the right side of the drawing in yellow), which is located just beneath the sublingual fold (seen intact in green on the left side of the drawing). The submandibular duct (blue) passes from the submandibular gland (not visible) to the openings on the sublingual caruncles (green structures on the midline where the right and left sublingual folds join).

cult to see unless gently moved by a tongue blade or mirror. In some animals, these fringes of tissue serve to keep the teeth clean.

e. floor of the Mouth

Visually examine the floor of the mouth by having a partner raise the tongue. Also, feel for unusual lumps by palpating the floor of the mouth with the forefinger of one hand pressing against the floor and opposed outside of the mouth by a finger of the other hand. This method of palpation is called **bimanual palpation** since it requires two hands (Fig. 15-38).

Like the ventral surface of the tongue, the tissues of the floor of the mouth are shiny, and some large blood vessels may be seen near the surface. The **alveololingual sulcus** (Fig. 15-37) is the broad, valley-shaped space between the mandibular alveolar bone and the tongue. You can gently place your finger in this broad sulcus and press laterally to confirm whether there are any bony ridges on the medial surface of the mandible. A prominent bump in this area might be a relatively common occurrence: a mandibular torus.



fiGUre 15-38. **Bimanual palpation** (using the opposing fingers of two hands) in order to feel for lumps or bumps (like a salivary duct blockage) within the floor of the mouth.

A **mandibular torus** (plural tori) (Fig. 15-39) is a bulbous protuberance of bone beneath a thin mucous membrane covering on the medial side of the mandible that may be found in the premolar region (Fig. 15-40). Mandibular tori may be inherited as a genetic trait and are not uncommon. They usually cause no problems but may be irritated during chewing of coarse foods or when mandibular dental impressions are made. After all lower teeth have been lost and removable dentures are to be made, it may be necessary to surgically remove mandibular tori. A similar torus may also occur in the middle of the palate and is called a **palatine torus** or torus palatinus (Fig. 15-41). **Exostosis** [ek sos TOE sis, plural is **exostoses**] is the general term used to describe any excess bony growth projecting outward from the bone surface, such as a torus palatinus or mandibular torus, but can also be used to describe bony ridges that may form on the facial (cheek) surface of the alveolar processes of the mandible or maxillae.

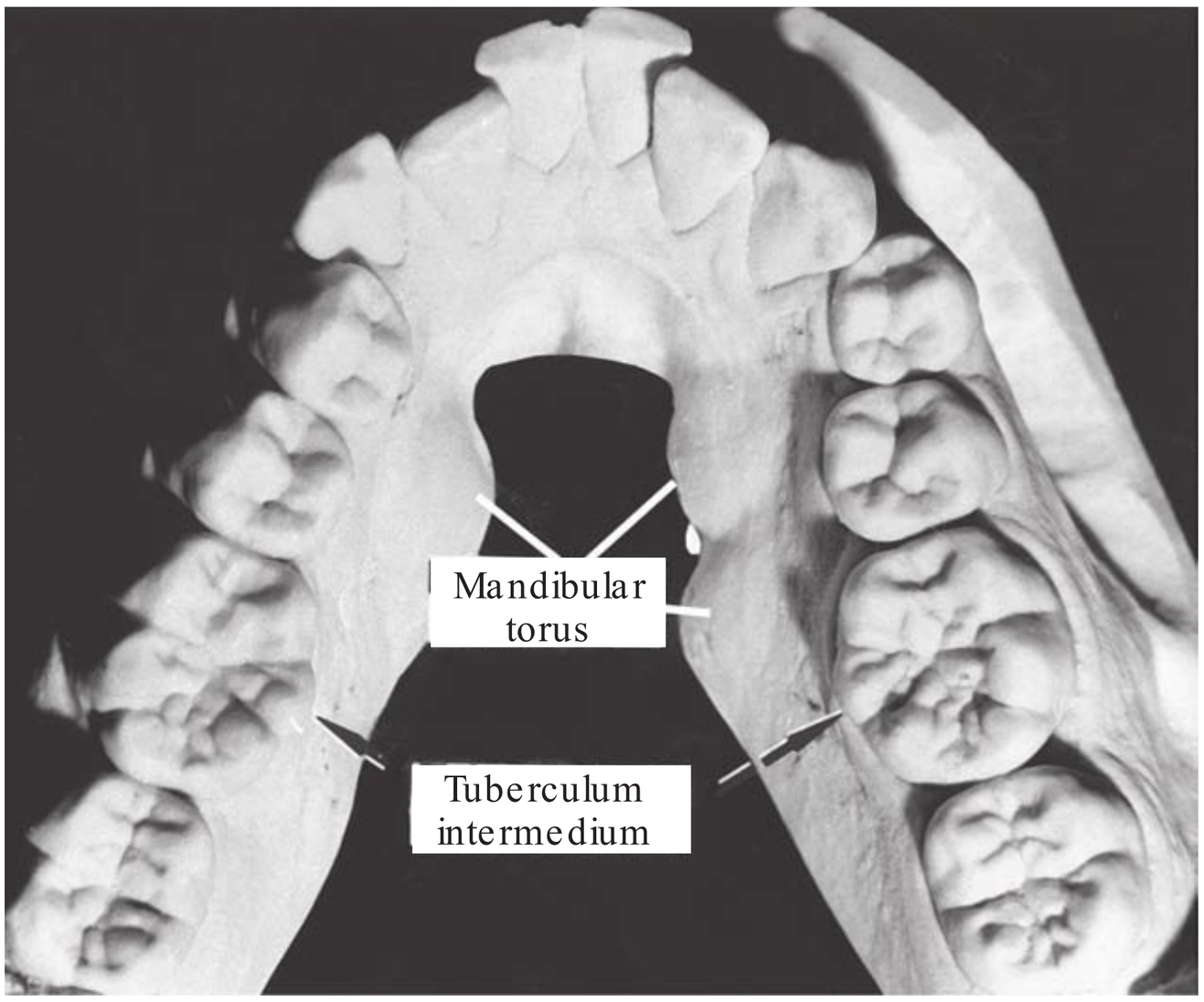

FIGURE 15-39. **MAN**dib**U**lar t**O**ri (bulbous elevations of bone) on the lingual surface of a stone cast of the mandible. (Also, note that the mandibular first molars have six, instead of the usual five, cusps. The extra lingual cusp is called a tuberculum intermedium.)

FIGURE 15-40. **FLOOR OF** the **MOU**th: the s**U**bli**N**g**U**al **FO**lds (plica sublingualis) lie over the sublingual glands. The s**U**bli**N**g**U**al car**UN**cles are located on either side of the li**NGU**al **F**re**NUM** where the submandibular gland ducts empty into the mouth (via Wharton ducts). Also, note the very prominent li**NGU**al t**O**ri under the mucosa projecting off of the lingual surface of the mandible.

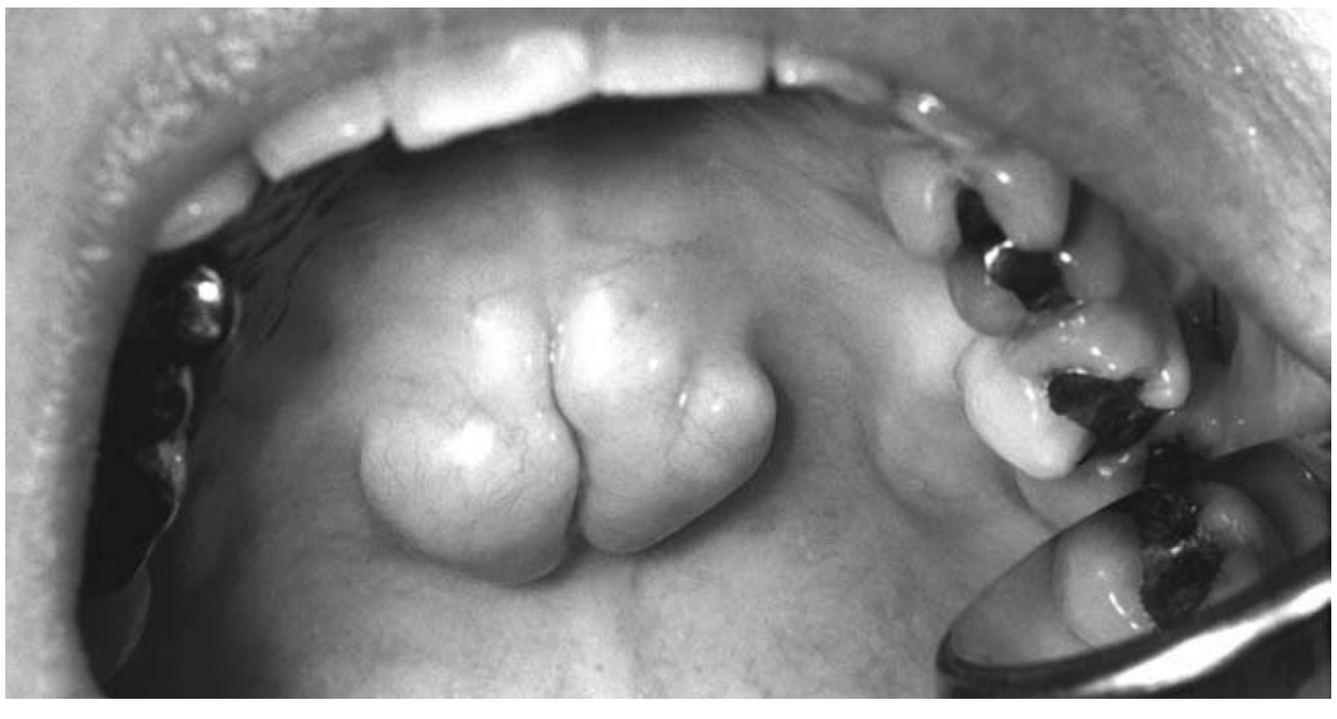

fiGUre 15-41. A maxillary torus palatinus or palatal t**o**r**u**s.

f. SAliv Ar y Gl An d S (in t r Ao r Al)

Refer to Figure 15-37 while studying these landmarks on the floor of the mouth. On the floor, the **sublingual folds** called the **plica sublingualis** [PLY ka sub ling GWAL is] extend anteriorly on each side of the floor of the mouth from the first molar region to the lingual frenum. Along these folds are many small openings of ducts from underlying **sublingual salivary glands** located in this region. T ese sublingual glands secrete purely mucous saliva (ropy type), producing only 5% to 8% of our saliva.[1]

On the midline at the junction between the right and left sublingual folds, on either side of the lingual frenum, is a pair of bulges called **sublingual caruncles** (Fig. 15-40), each with an opening from the **submandibular ducts** (also called **Wharton ducts**). T ese ducts transport saliva into the mouth from the **mandibular salivary glands**, which are located in the submandibular fossae on the internal surface of the mandible. T ese glands produce about two thirds of our saliva.[1] T eir secretions are primarily serous (two-thirds serous cells, one-third mucous cells[4]). A person normally secretes over a pint of saliva during 24 hours.[E] If you use bimanual palpation and gently move one finger in the floor of the mouth (opposing another outside of the mouth) from posterior to anterior over the sublingual folds and the underlying submandibular ducts, saliva may flow out of the gland openings in the caruncles. Saliva may even squirt out of the mouth through the openings in the caruncles when the patient opens wide (like when you yawn during a boring lecture), and the surrounding muscles apply pressure to the duct. It is possible for saliva to calcify within the ducts and block the flow of saliva. T is could cause symptoms that get worse when eating since the saliva cannot make its way out of the ducts. T is calcified blockage (called a **sialolith** [si AL o lith]) may be palpated, confirmed with a radiograph, and surgically removed.

G. Alveol Ar proceSS (of Underlyin G Bone)

T e bone surrounding the roots of the teeth should be palpated for bony growths (exostosis) or lesions.

H. Gin Givi

T e **periodontium** [per e o DON she um] was discussed in detail in Chapter 7 but is reviewed here in order to emphasize the landmarks that can be identified in the mouth of a healthy person (Fig. 15-42). Recall that the periodontium is comprised of the supporting tissues of the teeth, including surrounding alveolar bone, the gingiva, the periodontal ligaments, and the outer layer of the tooth roots (covered with cementum).

T e **gingiva** is the only visible part of the periodontium that is seen in the initial oral examination. It is the part of the **oral mucosa** covered by **keratinized epithelium** that covers the alveolar processes of the jaws and also surrounds the portions of the teeth near where the root and crown join (cervical portion). As discussed in detail in Chapter 7 (Periodontics), healthy gingiva varies in appearance from individual to individual and in different areas of the same mouth. It should be resilient and firm, stippled (i.e., textured with many small depressions, like an orange peel), and coral pink in persons with light skin pigmentation (Fig. 15-43), or in persons with dark coloring of the hair and skin, the gingiva may be brown or spotted with brown (**melanin pigmentation**). T e margins of healthy gingiva are thin in profile and knife edged. T e shape of the facial gingival margin around each tooth somewhat parallels the CEJ, so it is shaped like a parabolic arch (similar in shape to the McDonald arches). T is repeated parabolic arch pattern around each tooth is evident in Figure 15-43. Refer to Table 7-1 in Chapter 7 for a list of all characteristics of healthy gingiva.

Gingiva can be visually divided into zones as shown in Figure 15-44. T e zone closest to the tooth crown is **unattached gingiva**, which includes the free gingiva and the interdental papillae. **Free gingiva** (or marginal gingiva) is the tissue that is not attached to the tooth or alveolar bone. It surrounds each tooth to form a collar of tissue with a potential space or **gingival sulcus** (crevice) hidden between it and the tooth. Free gingiva extends from the **free gingival margin** (the edge of gingiva closest to the chewing or incising surfaces of the teeth) to the **free gingival groove** (visible in about one third of adults) that separates free gingiva from attached gingiva. T e **interdental papilla** (interproximal papilla) [pah PILL ah] (plural is papillae [pa PILL ee]) is

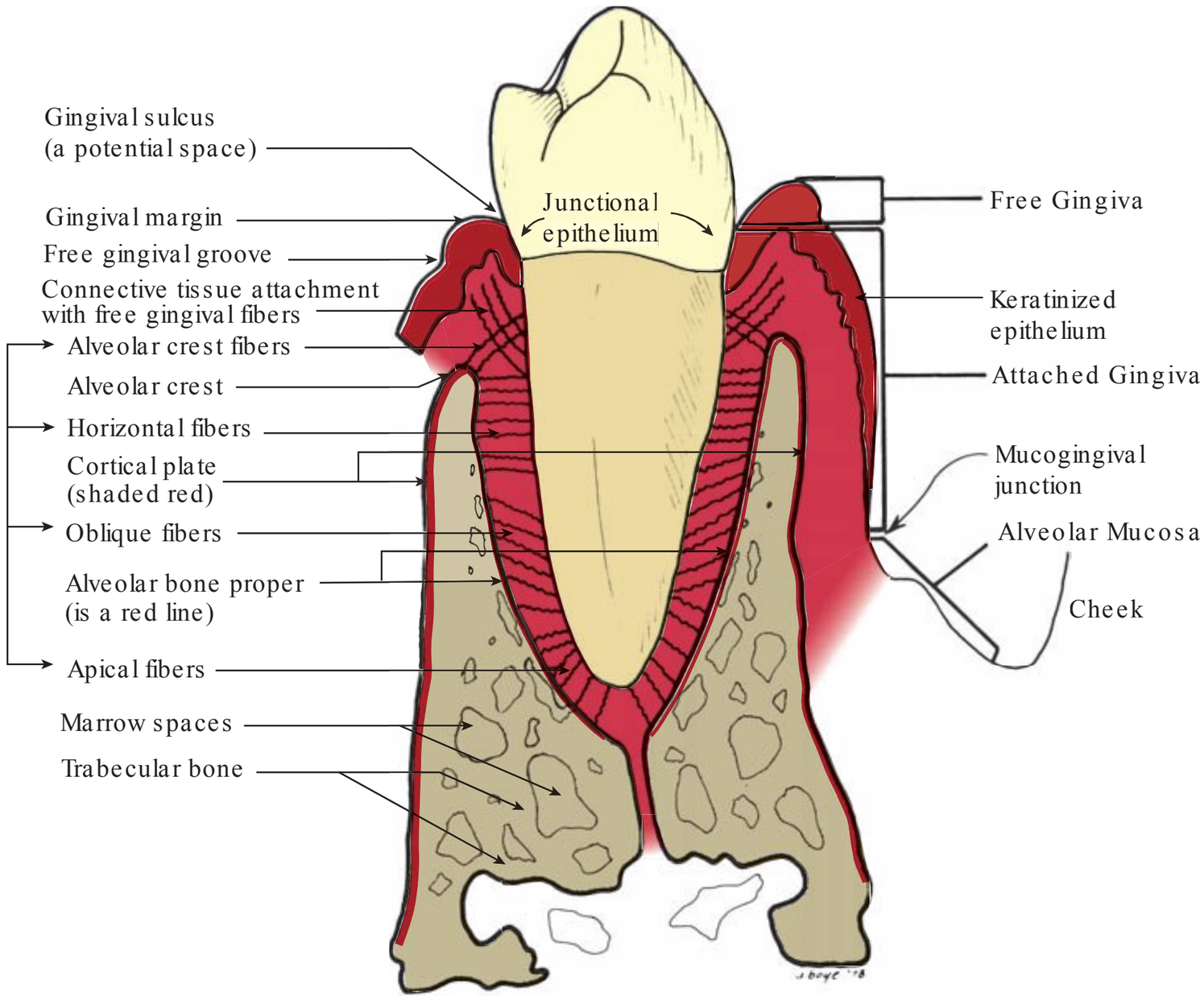

fiGUre 15-42. Periodontium including zones of gingiva and periodontal fiber groups: a mandibular left first premolar is suspended in its alveolus by the five groups of periodontal ligament fibers: apical, oblique, horizontal, alveolar crest, and *free* gingival fbers are visible. A sixth group, called transseptal fbers, not visible in this drawing, attaches from the cementum of one tooth to the cementum of the adjacent tooth at a level between the free gingival and alveolar crest fibers. The fibers of the periodontal ligament are much shorter than depicted here, averaging less than ¼ of a millimeter.

that part of the unattached gingiva between adjacent teeth. A healthy papilla conforms to the space between two teeth (interproximal space), so from the facial view, it comes to a point near where the adjacent teeth contact. T e papilla also has the hidden sulcus (potential space) next to each tooth where dental floss can fit once it passes between the teeth.

Attached gingiva is a band or zone of gray to light or coral pink (possibly with melanin pigmentation) keratinized masticatory mucosa that is firmly bound to the underlying bone (Fig. 15-44). It extends between the free gingiva (at the free gingival groove if present) and the more movable alveolar mucosa. T e amount or width of attached gingiva varies normally from 3 to 12 mm.



fiGUre 15-43. Healthy gingiva, close-up. Note the ideal contours and stippled (orange peel) surface texture that is usually most noticeable on the maxillary labial attached gingiva.

T e **mucogingival line (junction)** (Fig. 15-44) is a scalloped junction between attached gingiva and the looser, redder **alveolar mucosa**. Alveolar mucosa is movable mucosa, dark pink to red, due to increased vascularity and more delicate nonkeratinized tissue just apical to the mucogingival line. It is more delicate and less firmly attached to the underlying bone than the attached gingiva and is more displaceable as well because of the underlying vessels and connective tissue. Palpate these two types of tissues and you will feel the difference in firmness. T is movable alveolar mucosa is found in three places: in the maxillary and mandibular facial vestibule and in the mandibular lingual aspects (alveololingual sulcus) but not on the palate, which has firm, attached keratinized tissue for almost the entire surface. T erefore, the mucogingival line is present on the facial aspects of the maxillary and mandibular gingiva but only on the lingual aspect of mandibular gingiva.

Keratinized gingiva is the general term used to describe both the free and attached gingivae. It is widest on the facial (vestibular) aspect of maxillary anterior teeth and the lingual aspect of mandibular molars. It is narrowest on the facial aspect of mandibular premolars.[5]

T e **gingival sulcus** is not seen visually but can be evaluated with a periodontal probe since it is actually a space (or potential space) between the tooth surface and the narrow

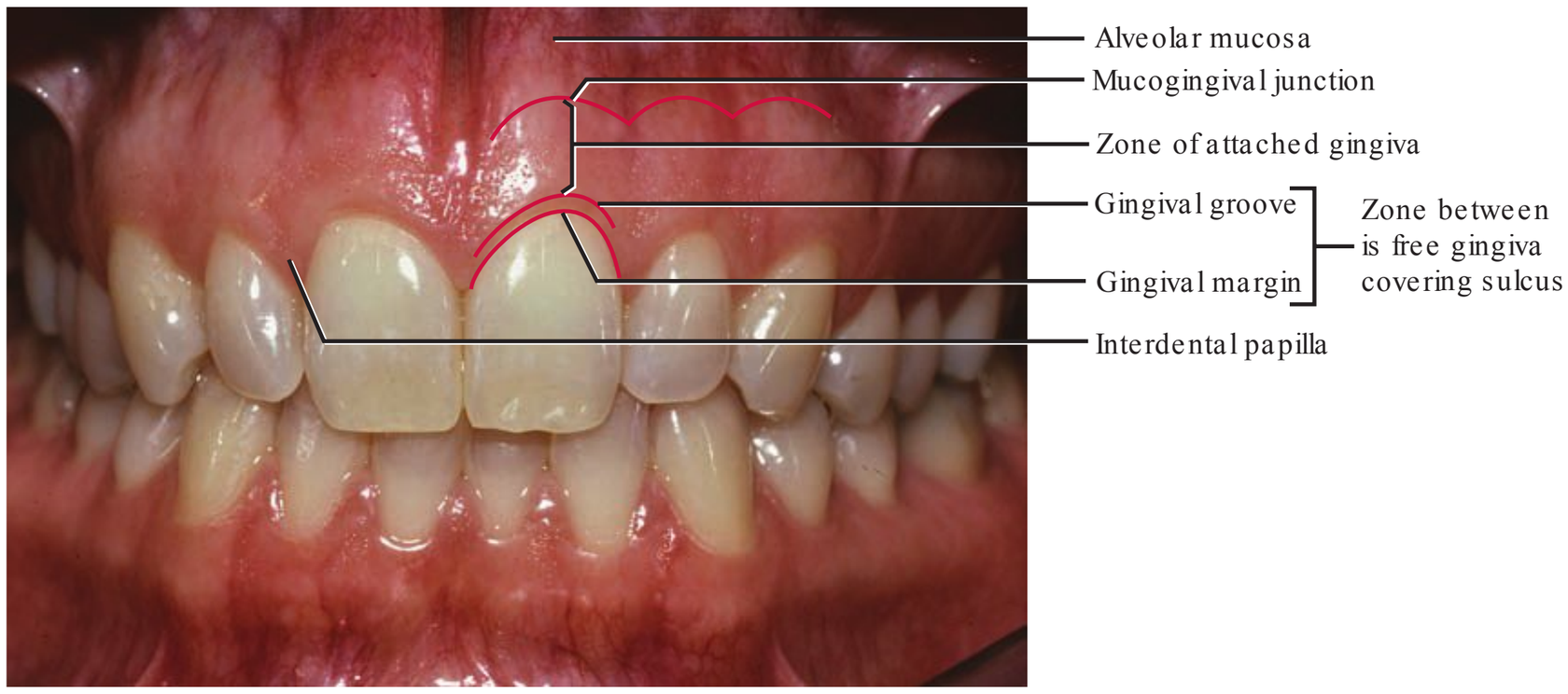

fiGUre 15-44. Clinical zones of the gingival. (Photo courtesy of Lewis J. Claman, D.D.S., M.S.)

unattached cervical collar of free gingiva (Fig. 15-45). The gingival sulcus is lined with the sulcular epithelium. It extends from the free gingival margin to the junctional epithelium. Clinically, the healthy gingival sulcus ranges in probing depth from about 1 to 3 mm and should not bleed when correctly probed. Junctional (or attached) epithelium (seen in cross-section in Fig. 15-42) is a band of tissue at the most apical portion of the gingival sulcus that attaches the gingiva to the tooth. It is about 1 mm in width.[6] There is also a 1- to 1.5-mm connective tissue attachment to the root above the crest of bone. The periodontal probe usually penetrates into the junctional epithelium, hence the difference between the depth determined through clinical probing and the depth seen on a microscopic cross-section.[7, F] Sometimes, during the process of eruption of the mandibular last molar through the mucosa, a flap of tissue may remain over part of the chewing surface called an **operculum** (seen previously in Fig. 7-7). This operculum can easily be irritated during chewing and become infected.



fiGUre 15-45. Periodontal probe in place in the gingival sulcus: the end of the probe can actually be seen here through the thin layer of unattached gingiva.

Evaluation of the thickness of the periodontal ligament and the amount of alveolar bone surrounding each tooth requires appropriate radiographs. Recall that the **periodontal ligament** is a very thin ligament composed of many fibers that connects the outer layer of the tooth root with the thin layer of dense bone called alveolar bone proper (seen on a radiograph as a white line called **lamina dura**) lining each alveolus or tooth socket seen in Figure 15-42. The fibers of the periodontal ligament represented in this figure are greatly enlarged; the actual width of this ligament is less than ¼ mm. The periodontal ligament is made up of four groups of fibers with differing directions and attachments and different names. The **apical**, **oblique**, **horizontal**, and **alveolar crest ȧbers** connect different parts of the tooth root (cementum) to the dense bone lining the tooth socket. The oblique fibers provide the major support to the tooth during function. **Free gingival ȧbers** are directed from tooth root (cementum) into free gingiva. A sixth group, the **transseptal ȧbers**, is not seen on Figure 15-42 since these fibers run directly from the root (cementum) of one tooth to the cementum of the adjacent tooth at a level between the free gingival and alveolar crest fibers.

i. tHe teetH (co Unt tHeM)

An important part of the oral examination is to determine which teeth are erupted in the mouth, identify them by name or universal number, and determine which teeth are missing. When the number of teeth is fewer than expected for a patient, a careful history can confirm tooth loss by disease or accident or teeth removed prior to orthodontic treatment. When history does not confirm such reasons for tooth loss, radiographs are recommended to rule out the possibility of unerupted (impacted) teeth beneath the mucosa or surrounded by bone (impacted teeth) or to confirm that a tooth never formed. It is also possible for the patient to have extra (supernumerary) teeth or unexpected teeth (such as retained primary teeth in a 30-year-old). These factors impact treatment planning decisions and should be documented.

The total number of teeth depends on the age of the individual and the stage of development of the teeth. Recall that the

complete primary dentition consists of 20 teeth. From about 2 years old until almost 6 years old, most children have all 20 primary teeth present in the mouth but no permanent teeth. For the next 6 years, there is normally a mix of some primary and some permanent teeth (called mixed dentition with 24 teeth including the 4 permanent first molars) until about 12 years of age, when all primary teeth have been lost and only permanent teeth are present. At age 12, there would normally be 28 permanent teeth (all but the unerupted third molars). Eventually (by the late teens or early 20s), the complete permanent (or secondary) dentition consists of 32 teeth, including the four third molars that erupt (become visible) into the mouth.



LEARn In G Ex ERCISE

Examine a partner (using infection control procedures) and identify each of the structures listed on this modified Head and Neck examination form. (The order of structures listed on this form is the same order as that encountered within the chapter, so it should be easy to follow the text as you perform the exam.) Use a tongue depressor or a mouth mirror to retract the lips and cheeks. A good light is needed, and a mouth mirror is useful for refecting light into remote areas and for holding the tongue or cheek out of the way during your examination.

n o Rm AL STRu CTu RES Fo u n D Du RIn G THE HEAD An D n ECk Ex Am

(Key: * = not found on all patients)

E**x**tra**o**ral E**x**a**mi**na**t**i**on**:

Ge**n**eral appeara**n**ce: healthy walk and posture; normal breathing

Head: symmetrical (or not); upper and lower jaw midlines lined up (or not)

S**ki**n: evaluate for lesions, palpate underlying muscles: masseter (origin, insertion); temporalis (anterior and posterior fibers: origin); medial pterygoid (insertion)

Eyes: clear sclera; pupil not considerably dilated or constricted

Te**m**p**o**r**om**a**n**dib**u**lar **joi**n**t**: palpate lateral surface of condyle during function; posterior surface of the condyle (in internal auditory meatus)

n ec**k**: palpate thyroid gland; submandibular salivary gland

n **o**des: palpate for submental; Submandibular; parotid (preauricular); postauricular; cervical (around sternocleidomastoid muscle)

Sali**v**ary gla**n**ds: palpate parotid gland and submandibular gland (bimanual for sublingual [intraoral])

Lips: commissure; nasolabial fold; labiomental groove; tubercle; philtrum; vermilion zone; mucocutaneous junction; wet line

I**n**tra**o**ral E**x**a**mi**na**t**i**on**:

m**u**c**o**sa: Labial: labial frenum; fornix
B**u**ccal: buccal frenum; commissural papule; *linea alba; parotid papilla from parotid gland (Stensen duct: press along it for saliva); *Fordyce granules (orange-colored spots)

Palate: Hard palate: incisive papilla; palatine raphe; rugae; *torus palatinus; pterygoid hamulus
S**of**t palate: vibrating line (say "ah"); fovea palatini; uvula

T**on**sils/ **o**r**o**phary**nx**: fauces; glossopalatine (anterior) arch; pharyngopalatine (posterior) arch; *palatine tonsils; pterygomandibular fold; retromylohyoid curtain

T**on**g**u**e: D**o**rs**um**: filiform, fungiform, and circumvallate papillae (way back); foramen cecum and terminal sulcus (probably too far back to see)
Lateral: foliate papillae
ve**n**tral: lingual frenum; plica fimbriata (can "separate" from tongue with mirror handle)

Fl**oo**r **of mou**th: alveololingual sulcus; *mandibular torus, palpate bimanual: sublingual folds over sublingual glands; sublingual caruncles with Wharton ducts of submandibular gland (may squirt)

Sali**v**ary gla**n**ds: buccal mucosa: parotid papilla ("milk" Stensen duct to see saliva drip out) foor of mouth: sublingual folds over sublingual glands with caruncle and opening to submandibular gland (may squirt)

Al**v**e**o**lar pr**o**cess: *exostosis (particularly on buccal aspect); maxillary tuberosity (pterygoid hamulus)

Gi**n**gi**v**a: free gingiva (has sulcus; would confirm with probe); *free gingival groove: interdental papilla; attached (keratinized) gingiva; mucogingival junction; retromolar pad (mandibular), *tissue overlapping last molar = operculum

Teeth: count all erupted teeth; note retained primary teeth: *impacted (on radiographs), malformations, etc.

o ccl**u**si**on** (circle **on**e): class I II III: evaluate first molar and canine relationships

review questions

Test your newly acquired knowledge by matching the forty landmarks with their descriptions. Place the appropriate letter or letters on line on left.

___ 1. Dorsum of tongue
___ 2. Hard palate
___ 3. Pharynx
___ 4. Elevated midline of hard palate
___ 5. Stensen parotid duct
___ 6. Alveolar mucosa
___ 7. Fordyce spots
___ 8. Melanin
___ 9. Gingiva between teeth
___ 10. Palatal tissue bump between teeth Nos. 8 and 9
___ 11. Vibrating line
___ 12. Wharton submandibular duct openings
___ 13. Labial frenum
___ 14. Ventral surface of tongue
___ 15. Oral cavity
___ 16. Retromolar pad
___ 17. Maxillary tuberosity
___ 18. Filiform papillae
___ 19. Torus mandibularis
___ 20. Attached gingiva
___ 21. Fauces
___ 22. Nasolabial groove
___ 23. Labiomental groove
___ 24. Sublingual gland
___ 25. Submandibular gland
___ 26. Plica sublingualis
___ 27. Uvula
___ 28. Plica fimbriata
___ 29. Foliate papilla
___ 30. Circumvallate papillae
___ 31. Alveololingual sulcus
___ 32. Palatine tonsils
___ 33. Retromylohyoid curtain
___ 34. Fungiform papillae
___ 35. Fovea palatini
___ 36. Parotid gland
___ 37. Philtrum
___ 38. Commissure
___ 39. Exostosis

a. Mouth
b. Dark pigment on attached gingiva
c. On the anterior floor of mouth where the plica sublingualis meet
d. Underside of tongue
e. Hair-like papillae covering two thirds of dorsum of tongue
f. Top side of tongue
g. Sebaceous glands on inside of cheek
h. Interdental papillae
i. Opens on inside of cheek near maxillary molars
j. Palatine raphe
k. Attaches lip to mucosa covering jaw (upper and lower)
l. Behind soft palate
m. Incisive papilla
n. Lines floor of vestibule, loosely attached
o. Firm, covered by gingiva, has rugae
p. Ridge of bone lingual to mandibular premolars
q. Elevation of tissue distal to mandibular last molar
r. Elevation of tissue distal to maxillary last molar
s. Junction of hard and soft palate
t. Tightly attached—pink color
u. Mucous salivary glands beneath anterior third of tongue
v. Large serous salivary gland beneath posterior third of tongue
w. At the corners of mouth where lips join
x. Diagonal grooves from nostrils to corner of mouth
y. Horizontal depression below lower lip
z. Vertical depression on upper lip
aa. Opening from oral cavity to pharynx
bb. Serous salivary gland just in front of ear
cc. Located just posterior to vibrating line
dd. Fold in floor of mouth beneath tongue
ee. Delicate fold on each side of ventral surface of tongue
ff. Hangs downward in center of soft palate
gg. On lateral surfaces of tongue near posterior third
hh. Space between mandibular teeth and tongue
ii. 8 to 12 circular papillae arranged in a "V" shape
jj. Mucous membrane between anterior pillar and pterygomandibular fold
kk. Located between anterior and posterior pillars in throat
ll. Bulbous protuberance of bone on facial side of mandible in premolar region
mm. Sparse round mushroom-shaped papillae on dorsum of tongue

ll –93; w–83; z–73; bb–63; cc–53; mm–43; jj –33; kk–23; hh–13; ii –03; gg–92; ee–82; f –72; dd–62; v–52; u–42; y–32; x–22 ; aa–12; t –02; p–91; e–81; r –71; q–61; a–51; d–41; k–31; c–21; s–11; m–01; h–9; b–8; g–7; n–6; i –5; j –4; l –3; o–2; f –1: Sre WSnA

Critical Thinking

1. Mrs. Huay requires the extraction of tooth #31 due to a severe tooth fracture. A. State each nerve branch that needs to be blocked with anesthetic in order for her not to feel any pain in the tooth or surrounding oral tissues during the extraction. B. Describe in as much detail as possible exactly where the anesthetic should be placed. C. Then, trace each nerve branch that supplies this tooth and surrounding structures back to the brain where it exited the brain case.
2. Discuss the **tongue**. A. First, list as many structures on it as possible (describing the locations of each). B. List the nerves that innervate the tongue for movement, feeling (pain), and taste; the artery that supplies blood; and the lymph nodes where infections of the tongue would drain. (This requires knowledge obtained when reading Chapter 14 as well as Chapter 15.)

REFERENCES

1. Jenkins GN. The physiology of the mouth. 3rd ed., Revised reprint. Oxford, UK: Blackwell Scientific, 1970:310–328.
2. Osborn JW, Armstrong WG, Speirs RL, eds. Anatomy, biochemistry and physiology. Oxford, UK: Blackwell Scientific, 1982:535.
3. Renner RP. An introduction to dental anatomy and esthetics. Chicago, IL: Quintessence Publishing, 1985.
4. Brand RW, Isselhard DE. Anatomy of orofacial structures. 5th ed. St. Louis, MO: C.V. Mosby, 1994.
5. Lang N, Loe H. The relationship between the width of keratinized gingiva and gingival health. J Periodontol 1972;43:623.
6. Gargiulo A, Wentz F, Orban B. Dimensions and relationships of the dentogingival junction in humans. J Periodontol 1961;32:261.
7. Polson A, Caton J, Yeaple R, et al. Histological determination of probe tip penetration into gingival sulcus of humans using an electronic pressure-sensitive probe. J Clin Periodontol 1980;7:479.
8. Foley PF, Latta GH. A study of the position of the parotid papillae relative to the occlusal plane. J Prosthet Dent 1985;53:124–126.
9. Simmons JD, Moore RN, Errickson LC. A longitudinal study of anteroposterior growth changes in the palatine rugae. J Dent Res 1987;66:1512–1515.

GENERAL REFERENCES

10. Beck EW. Mosby's atlas of functional human anatomy. St. Louis, MO: C.V. Mosby, 1982.
11. Clemente CD. Anatomy: a regional atlas of the human body. 4th ed. Baltimore, MD: Lippincott Williams & Wilkins, 1997.
12. Clemente CD, ed. Gray's anatomy of the human body. 30th ed. Philadelphia, PA: Lea & Febiger, 1985.
13. DuBrul EL. Sicher and DuBrul's oral anatomy. St. Louis, MO: C.V. Mosby, 1988.
14. Dunn MJ, Shapiro CZ. Dental anatomy/head and neck anatomy. Baltimore, MD: Lippincott Williams & Wilkins, 1975.
15. Montgomery RL. Head and neck anatomy with clinical correlations. New York, NY: McGraw-Hill, 1981:236–240.
16. Web site: http://education.yahoo.com/reference/gray/

Dr. Woelfel's original research Data

Specific research data and some of Dr. Woelfel's original research findings related to material topics in this chapter were referenced throughout by using superscript letters (like this[A]) and are presented here.

A. In 1971 and 1972, Dr. Woelfel and Dr. Igarashi supervised 331 dental students as they recorded the **position of the right and left parotid papilla** on each other. Of 662 parotid papillae, 78% were located between the maxillary first and second molar or by the second molar. Only 22% were by the first molar. In height, 87% of these same papillae were located level with (34%) or above the level (53%) of the occlusal plane. Only 13% were found below the level of the occlusal plane. The widest variation in location among these dental students was in two men, one having his parotid papilla on each side 11 mm above the occlusal plane and the other man with his 8 mm below the level of the occlusal plane. In a similar study of 293 adult men and 114 adult women (258 White, 11 Black, 9 Hispanic), the parotid papilla averaged 3.3 mm above the occlusal plane (right 3.0 mm, left 3.5 mm).[8]

B. There is a relatively constant 8.5-mm distance from the facial surface of the maxillary central incisors to the center of the **incisive papilla**. On 326 casts measured by Dr. Woelfel, the average distance was 8.4 mm, with a range of 5.5 to 12 mm.

C. Among casts from 939 hygiene students, **rugae** "trees" had three, four, or five branches on each side in 87% of the students. The first main branch was aligned lingual to the canine in 72%. The rugae were well elevated in 85% of the students and flattened in only 14%. Rugae are more distinct in young persons than in older persons. However, a longitudinal study of 20 females and 21 males, from age 4 to 22 years, indicated a slight but steady growth in the length of rugae during this period

(average: 1.4 to 2.3 mm). Rugae growth occurred earlier in females, but the males had more branches.[9]

D. Measurements on 333 casts by Dr. Woelfel indicated the **frenum attachment** to be 8.03 ± 1.5 mm below the gingival sulcus of the mandibular central incisors, range 5.4 to 11 mm. Assuming an average-length mandibular central incisor (8.8 mm), the lingual frenum attaches about 17 mm below the incisal edge of these teeth.

E. **(Not Woelfel research) Daily saliva secretion**: A person normally secretes an average of 300 mL of saliva between meals, 300 mL while eating, and only 20 mL while sleeping, based on averages from 600 people.[1]

F. In a survey by Dr. Woelfel, 267 dental hygiene students measured their **gingival sulcus depths** with a calibrated periodontal probe. T e average gingival sulcus depths for mandibular first molars midbuccal were 1.5 ± 0.5 mm; midlingual, 1.7 ± 0.6 mm; and mesiolingual and distolingual, 2.5 ± 0.5 mm. T ese measurements indicate that the gingival sulcus is usually deeper interproximally. Similar measurements made on the mesiofacial aspect of mandibular canines (1.9 ± 0.8 mm), maxillary canines (1.8 mm), maxillary first premolars (1.9 ± 0.7 mm), and maxillary first molars (2.1 ± 0.7 mm) indicate sulci slightly deeper on posterior teeth than those on anterior teeth.

Appendix

T is Appendix includes drawings of permanent and primary teeth, which are labeled (with letters) to highlight features of each tooth. Traits represented by each letter are described on the back of each page following the same letter used on the drawings.

T e authors recommend that you copy each Appendix page (front and back sides) or print out these pages from the online source thePoint® provided for this book, to facilitate study and minimize page turns as you read chapters two through six. For example, while reading about the morphology of incisors in Section I of Chapter 2, when you see the word "Appendix" followed by a number and letter (e.g., Appendix 1a), refer to the appendix page (page 1) and item (letter a). Find that letter on the line drawings, and it will illustrate the concept being described in the text.

Class Traits of Most Incisors
(using the maxillary right lateral incisor #7 as an example)

Facial View

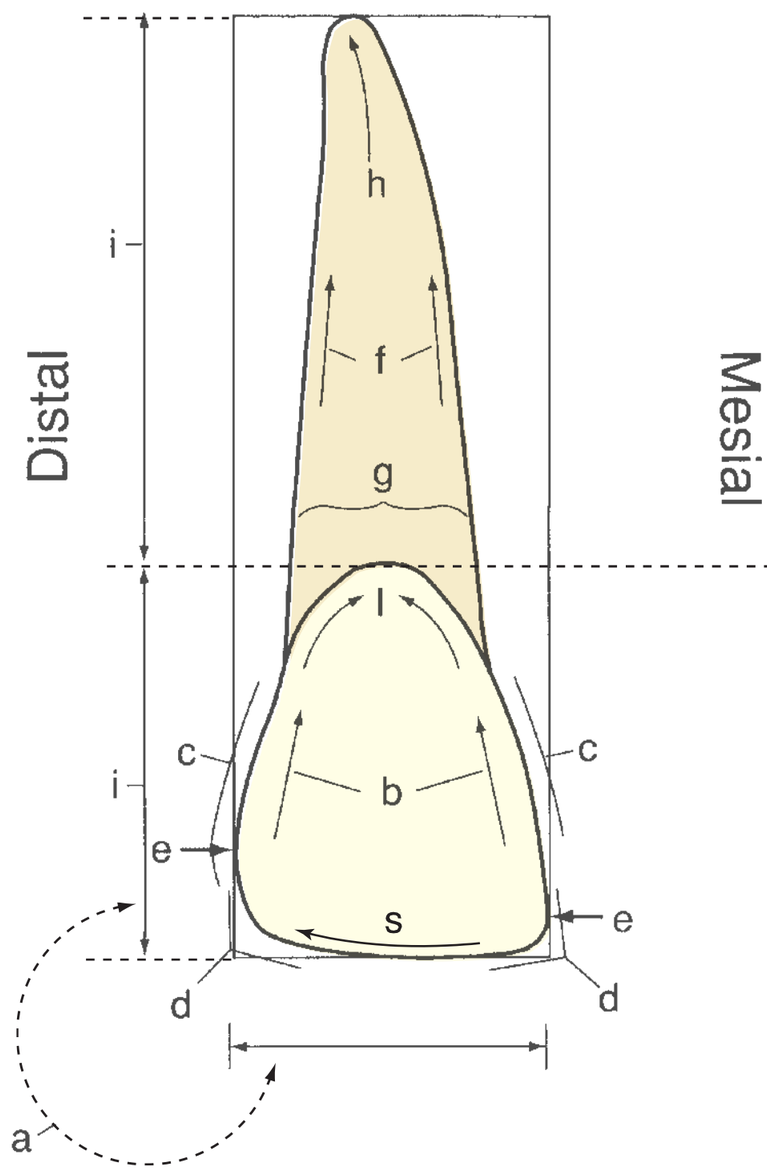

Mesial View

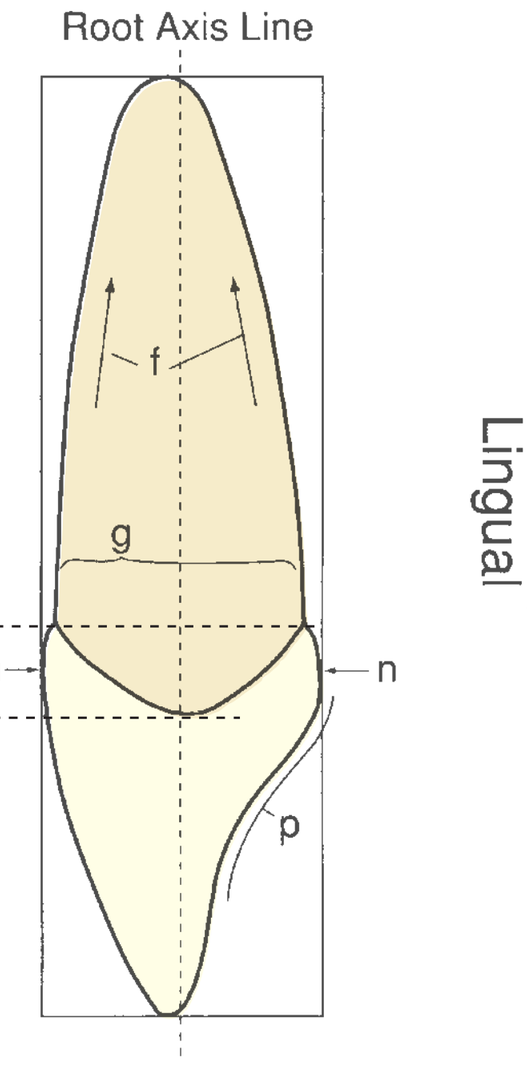

Incisal View

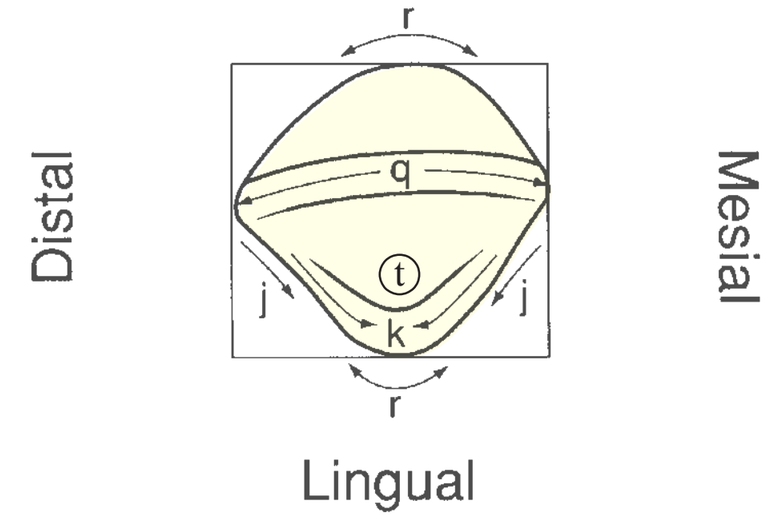

Distal View

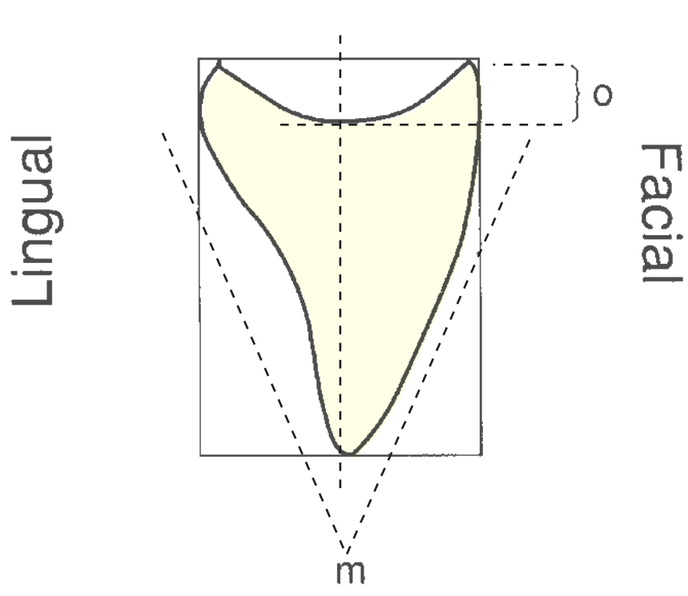

Refer to letters a–t on back, which describe these features.

General Class TraiTs of Mos T Per Manen T in Cisors

a. Crown shapes are rectangular, longer incisogingivally than mesiodistally (facial views).
b. Crowns taper from the contact areas to cervical lines (facial views).
c. Crown outlines on the distal are more convex than on the mesial (facial views) EXCEPT on mandibular central incisors, which are known for their symmetry.
d. T e mesioincisal angles are more square (or acute) than the distoincisal angles, which are more obtuse (facial views) EXCEPT on mandibular central incisors.
e. Mesial contact areas are in the incisal third; distal contact areas are more cervical than the mesial (facial view) EXCEPT on mandibular central incisors, where mesial and distal contacts are at the same height (facial views).
f. Roots taper from the cervical line toward the apex (facial and mesial views) and from the facial toward the lingual (best seen on an actual tooth or model).
g. Roots are wider faciolingually than mesiodistally (comparing proximal to facial view) EXCEPT maxillary central incisors, where dimensions are almost equal.
h. When bent, roots often bend to the distal in the apical third (facial views).
i. Roots are slightly to considerably longer than crowns (facial and proximal views).
j. Crowns taper from proximal contact areas toward the lingual (incisal views).
k. T e mesial and distal marginal ridges converge toward the lingual cingulum (incisal and lingual views).
l. Cervical lines on the facial (and lingual) surfaces are convex (curve) toward the apex (facial and lingual views).
m. Proximal outlines are wedge shaped or triangular (proximal views).
n. Facial and lingual crests of curvature are in the cervical third (proximal views).
o. Proximal cervical lines are convex (curve) toward the incisal AND curve more so on the mesial than on the distal surfaces (compare mesial to distal views).
p. Lingual outlines are S-shaped with a concave lingual fossa and marginal ridges and convex cingulum. T e lingual outlines of the marginal ridges are more vertical than horizontal (proximal views).
q. Incisal edges terminate mesially and distally at the widest portion of the tooth crown (incisal views).
r. Facial outlines are more broadly rounded than lingual outlines due to lingual convergence (incisal views).
s. Incisal edges slope shorter toward the distal EXCEPT on symmetrical mandibular central incisors, which have no slope (facial views).
t. A lingual fossa is located between marginal ridges, more evident on maxillary incisors (incisal views).

Arch and Type Traits of Incisors

Maxillary

Lateral (#7)

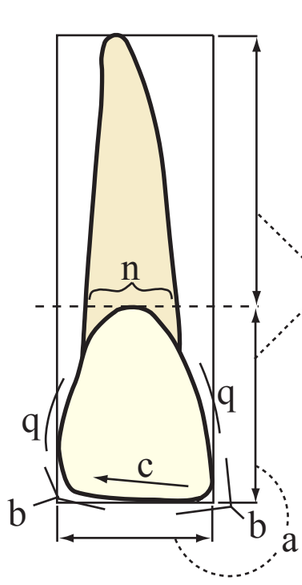

Central (#8)

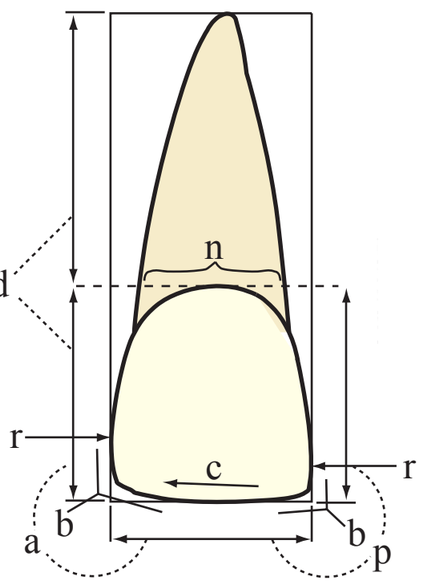

Mandibular

Lateral (#26)

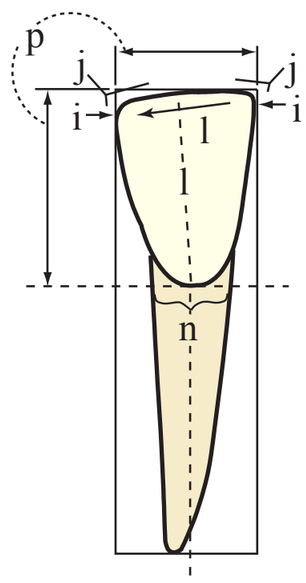

Central (#25)

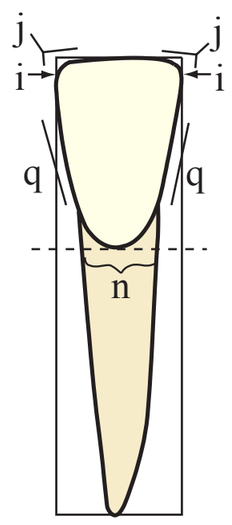

Labial

Lingual

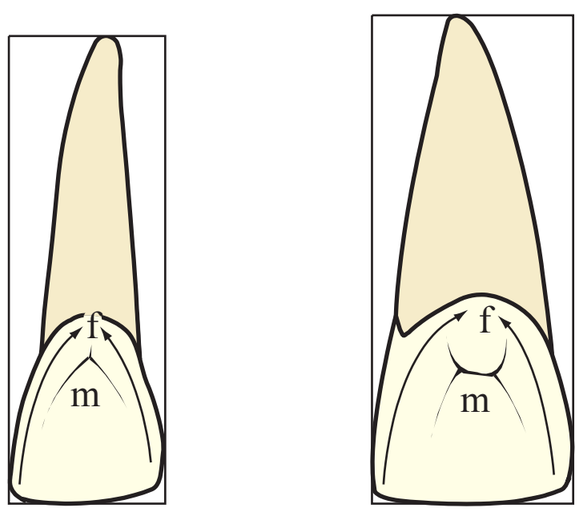

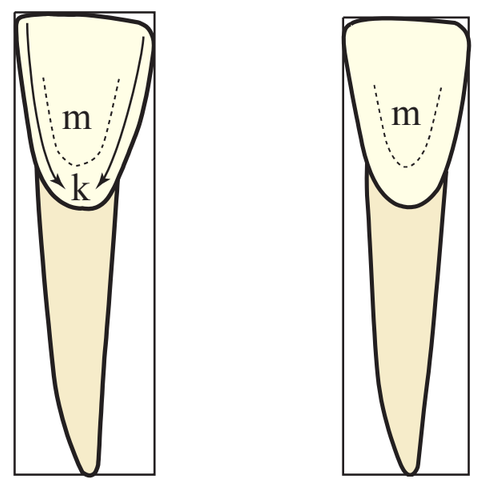

Mesial

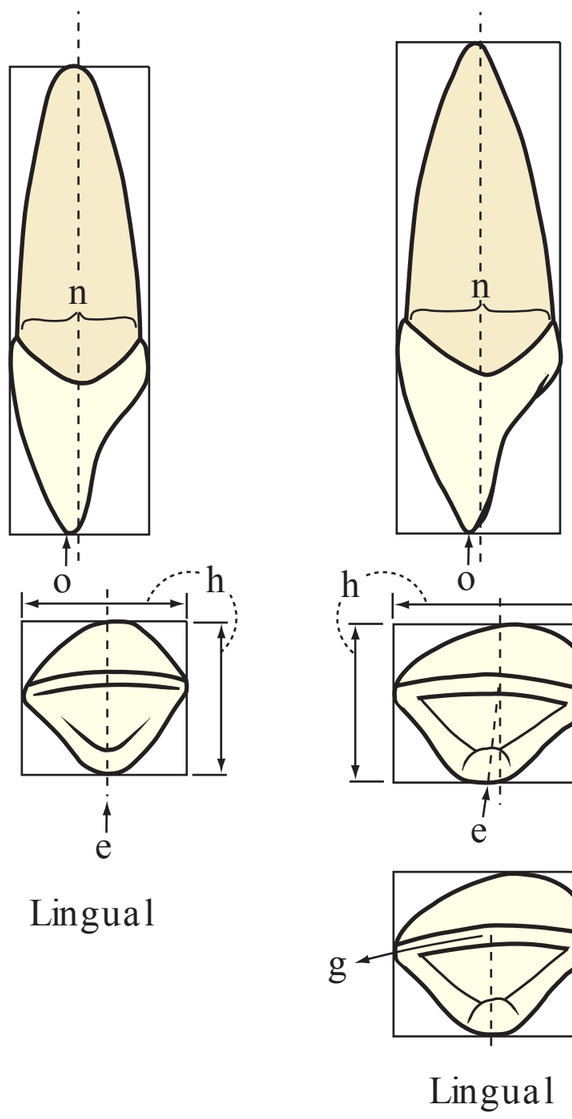

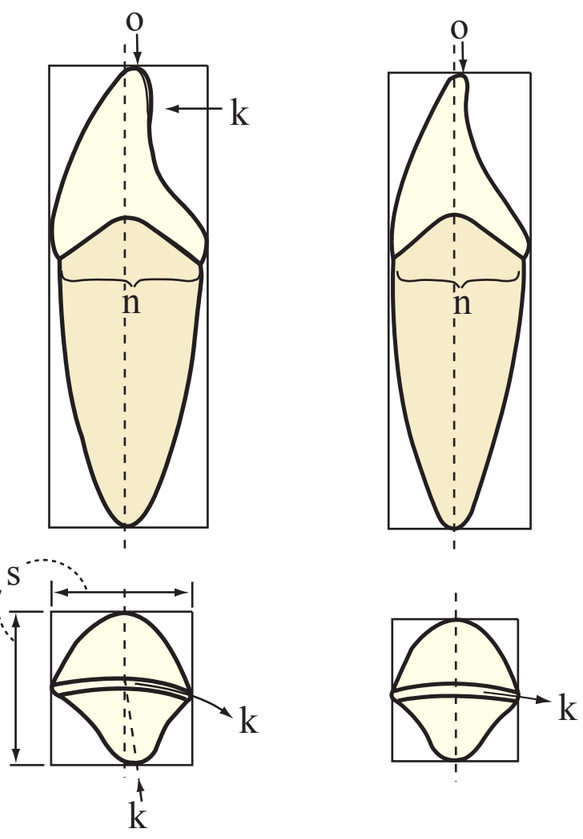

Incisal

(two alignments of same crown)

Lingual

Lingual

Lingual

Lingual

Refer to letters a–s on back, which describe these features.

TyPe TraiTs ThaT DisTinGuish The Maxillary CenTral inCisor froM The Maxillary laTeral inCisor

a. Although the crowns of both types of maxillary incisors are longer cervicoincisally than mesiodistally, maxillary central incisors are closer to square. Lateral incisors are more oblong cervicoincisally (facial views).
b. On both maxillary incisors, the mesioincisal angles are close to 90 degrees; the distoincisal angles are more rounded (facial views), but both angles are more rounded on the lateral compared to the central incisor (facial views).
c. Incisal edges on maxillary incisors slope cervically toward the distal (facial views), more so on lateral incisors (facial views).
d. Maxillary central incisors have crowns and roots closer to the same length. Lateral incisors have proportionately longer roots relative to crowns (facial views).
e. When the incisal edges of maxillary incisors are aligned horizontally, cingula of maxillary central incisors are off-center to the distal versus cingula of lateral incisors, which are centered (incisal views).
f. Mesial marginal ridges of maxillary incisors are longer than the distal marginal ridges (in central incisors due to the distally displaced cingulum and in lateral incisors due to the cervical slope of the incisal edge to the distal) (lingual views).
g. From the incisal view, when the crest of curvature of the cingulum is positioned directly downward, the incisal edge of maxillary central incisors has a slight distolingual twist with the distoincisal corner more lingual than the mesioincisal corner. T e incisal ridges of maxillary lateral incisors run mesiodistally with no twist (incisal and mesial views).
h. Mesiodistal dimensions on maxillary central incisors are considerably wider than faciolingual dimensions (rectangular shaped). On maxillary lateral incisors, these dimensions are more nearly equal (closer to square) (incisal views).

TyPe TraiTs ThaT DisTinGuish The MandibulaR CenTral inCisor froM The MandibulaR laTeral inCisor

Mandibular central incisors are very symmetrical versus lateral incisors, which are not. T e following are examples of the relative lack of symmetry in lateral incisors:

i. Mandibular lateral incisors have the distal proximal contacts more apical than the mesial contacts. Central incisor contacts are at the same level (facial views).
j. Lateral incisors have the distoincisal angles more rounded than the mesioincisal angles. On central incisors, the mesioincisal and distoincisal angles are quite similar (facial views).
k. Incisal edges of mandibular lateral incisors have a slight distolingual twist (relative to a line bisecting the cingulum). Central incisors have their incisal edges at right angles (with no twist) to this bisecting line (incisal and mesial views). T e cingulum is positioned distal to the center (incisal views) and the mesial marginal ridge appears longer than the distal (lingual views).
l. T e crowns of the mandibular lateral incisor tip slightly to the distal relative to the root accentuated by the fact that the incisal edges slope cervically toward the distal (facial views).

arCh TraiTs ThaT DisTinGuish Maxillary froM MandibulaR inCisors

m. Lingual fossae are more pronounced on maxillary incisors (often with a lingual pit, especially on the maxillary lateral incisor). Mandibular incisors have smoother lingual anatomy without grooves and pits (lingual views).
n. Maxillary incisors have roots that are closer to round in cross-section. Mandibular incisors have roots that are more ribbon-like (i.e., are thin mesiodistally and much wider faciolingually). Compare proximal views to facial views.
o. Incisal edges of maxillary incisors are often labial to the root axis line. Mandibular incisal edges are often lingual to the root axis line (proximal views).
p. Mandibular crowns are smaller and narrower mesiodistally relative to the length compared to maxillary incisors, which are relatively wider (facial views).
q. Mandibular crowns have outlines mesially and distally that are flatter than on maxillary incisors (facial views).
r. (r compared to i). Proximal contact points (crests of curvature or heights of contact) are closer to the incisal edge on mandibular incisors (i) than on maxillary incisors (r) (although incisor proximal contacts are in or close to the incisal third of the crowns [EXCEPT distal of maxillary laterals, which are in the middle third], and distal contacts are more cervically positioned than mesial contacts [EXCEPT mandibular centrals]) (facial views).
s. Mandibular incisors are usually wider faciolingually than mesiodistally compared to h where maxillary central incisors are wider mesiodistally and maxillary laterals are about the same dimension (incisal views).

Class Traits of Most Canines
(using the maxillary right canine #6 as an example)

Facial View

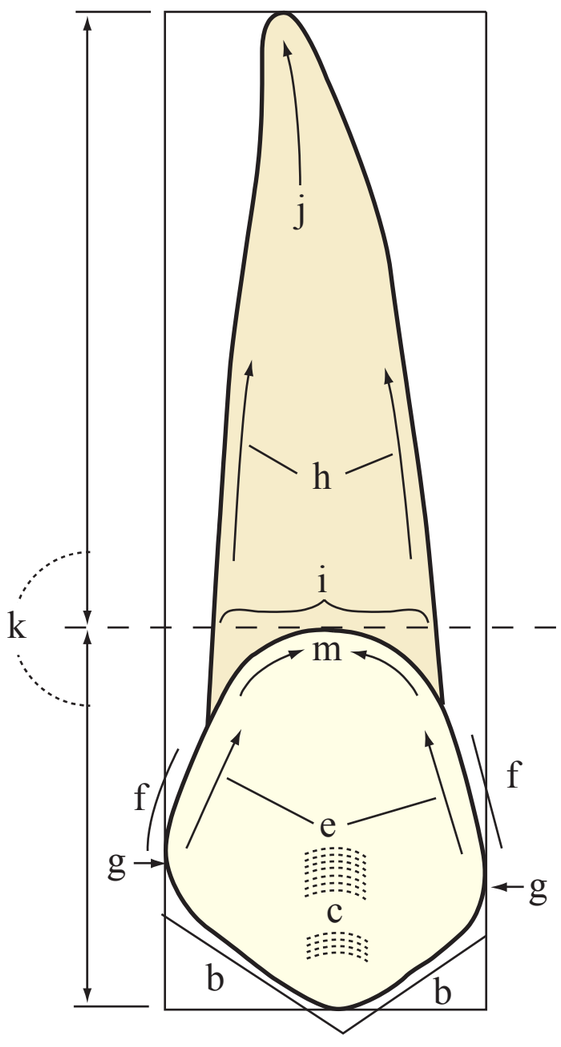

Mesial View

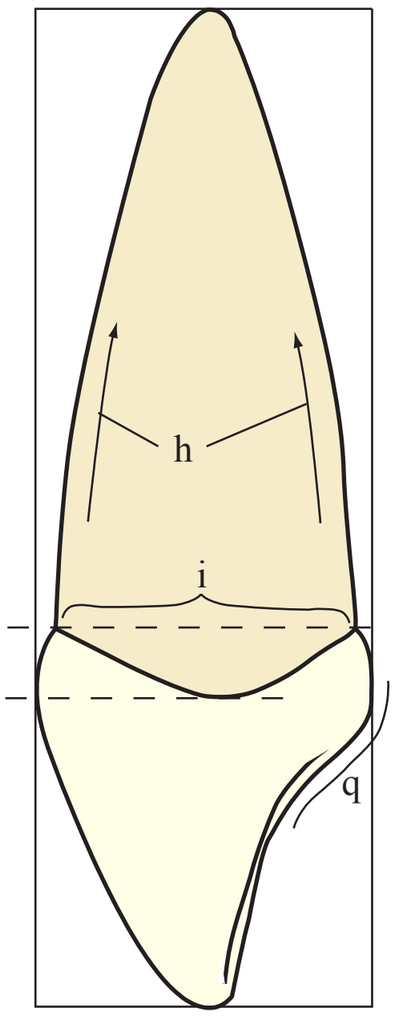

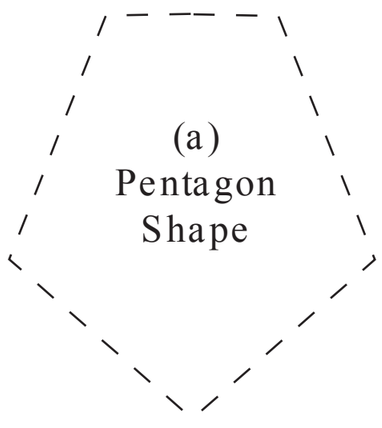

Incisal View

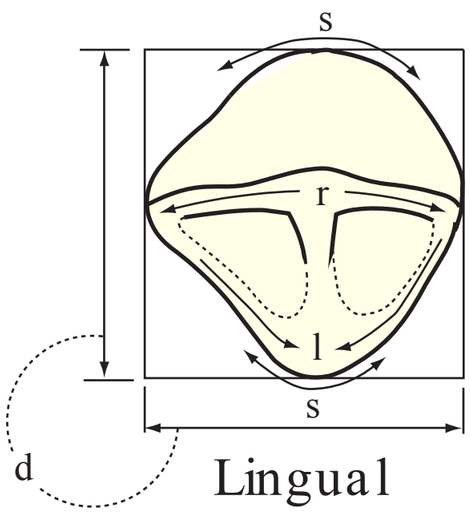

Lingual

Distal View

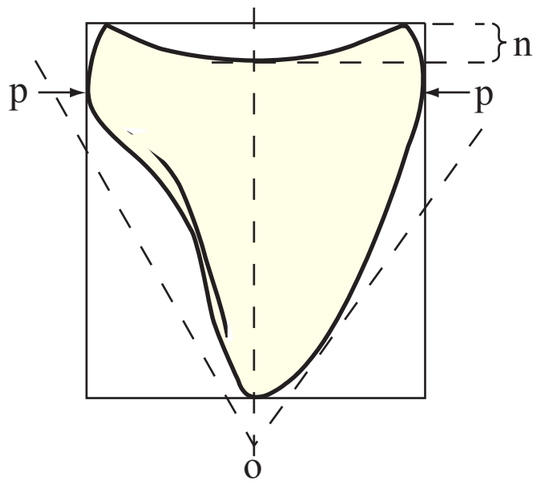

Refer to letters a–s on back, which describe these features.

General Class Traits of Most Canines

a. Crowns are pentagon shaped (facial views).
b. Cusps have mesial cusp ridges shorter than distal cusp ridges (facial views).
c. Vertical labial ridges are prominent (more so on maxillary canines) (facial views).
d. Crowns are wider faciolingually than mesiodistally (similar to mandibular incisors) (incisal views).

General Canine Characteristics similar to incisors

e. Crowns taper from contact areas toward the cervical line (facial views).
f. Crown outlines are more convex on the distal and less convex (flatter) on the mesial (facial views).
g. Mesial contact areas are located in the incisal third of the crown (or at the junction of the incisal and middle thirds); distal contact areas are more cervically positioned (facial views).
h. Roots taper from the cervical line toward the apex (facial and proximal views) and from facial toward lingual (which is best viewed on an actual tooth or model).
i. Roots are wider faciolingually than mesiodistally (compare proximal to facial views).
j. If roots are bent, they more often bend toward the distal in the apical third on maxillary canines (facial views), but mandibular canine roots are more likely to be straight.
k. Roots are considerably longer than crowns (facial views).
l. Crowns taper from the proximal contacts toward the lingual (incisal views), so the mesial and distal marginal ridges converge toward the cingulum (incisal views).
m. Cervical lines on the facial (and lingual) surfaces curve toward the apex (facial and lingual views).
n. Proximal cervical lines curve toward the incisal, more so on the mesial than on the distal surface (compare proximal views).
o. Canines (like incisors) are wedge shaped (triangular) when viewed from the proximal.
p. Facial and lingual crests of curvature are in the cervical third (proximal views).
q. Lingual outlines are S-shaped with a concave lingual fossa and convex cingulum; the marginal ridges are oriented more vertically than horizontally (proximal views).
r. Incisal edges run from the mesial to the distal contact areas (incisal views).
s. Facial outlines are more broadly rounded than lingual outlines due to lingual convergence (incisal views).

Arch Traits of Canines

Maxillary (#6)

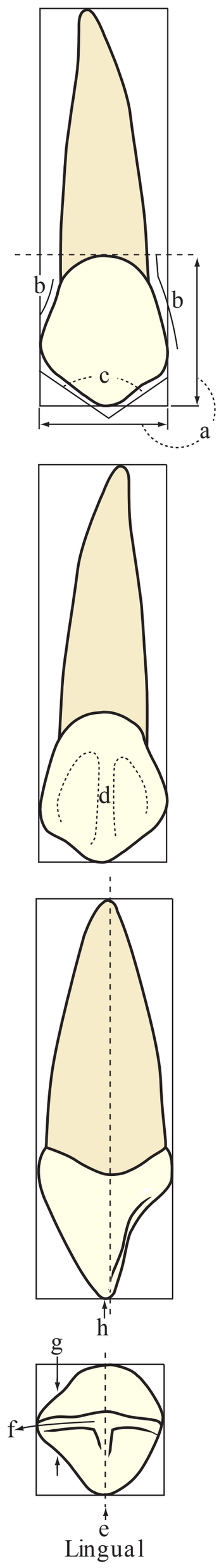

Mandibular (#27)

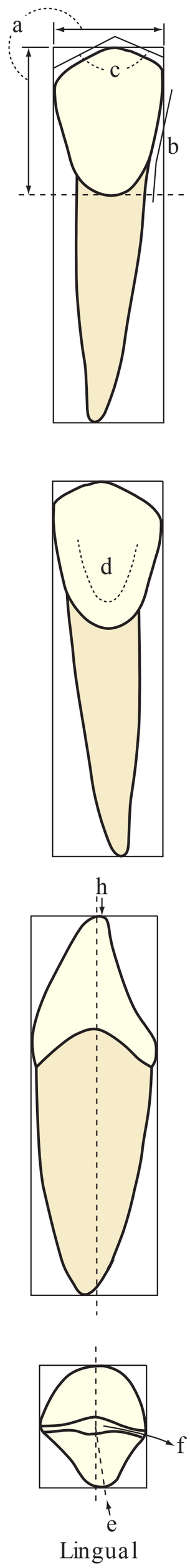

Labial

Lingual

Mesial

Incisal

Refer to letters a–h on back, which describe these features.

ar Ch Tr aiTs Th aT Dis Tin Gu ish Th e Ma xil l ar y Ca n in e fr o M Th e Man Dibu l ar Ca n in e

a. Both maxillary and mandibular canine crowns are oblong (rectangular) with the mesiodistal dimension less than the incisocervical dimension, but the mesiodistal dimension is narrower on mandibular canines than on maxillary canines (facial views).
b. Maxillary canines have a mesial crown outline convex (to nearly flat cervically) versus mandibular canines, which have a mesial crown outline that is less convex and aligned closely with the outline of the root. T e distal outline of maxillary canine crowns is often slightly concave in the cervical third (facial views).
c. T e angle formed by the cusp ridges (slopes) of maxillary canines is more pointed or acute (averaging about 105 degrees), resulting in a sharper cusp, compared to the broader (less pointed or obtuse) angle on the mandibular canine, which averages 120 degrees (facial views). T e mesial cusp ridge of the mandibular canine is often close to horizontal when the tooth is held with the long axis vertically.
d. Lingual ridges that separate mesial and distal fossae are more prominent on maxillary canines than on mandibular canines (lingual views).
e. Cingula on maxillary canines are large and centered mesiodistally. On mandibular canines, they are often slightly to the distal (incisal views).
f. Incisal ridges on maxillary canines are straighter mesiodistally. On mandibular canines, the distal cusp ridge bends distolingually (incisal views).
g. T e distal half of the crown of maxillary canines is compressed (squeezed) faciolingually more than on mandibular canines (incisal views).
h. T e cusp tip of the maxillary canine is most likely on or labial to the root axis line, whereas the mandibular cusp tip is lingual to or on this root axis line (proximal views).

Class Traits of Most Premolars
(using the maxillary right second premolar #4 as an example)

Facial View

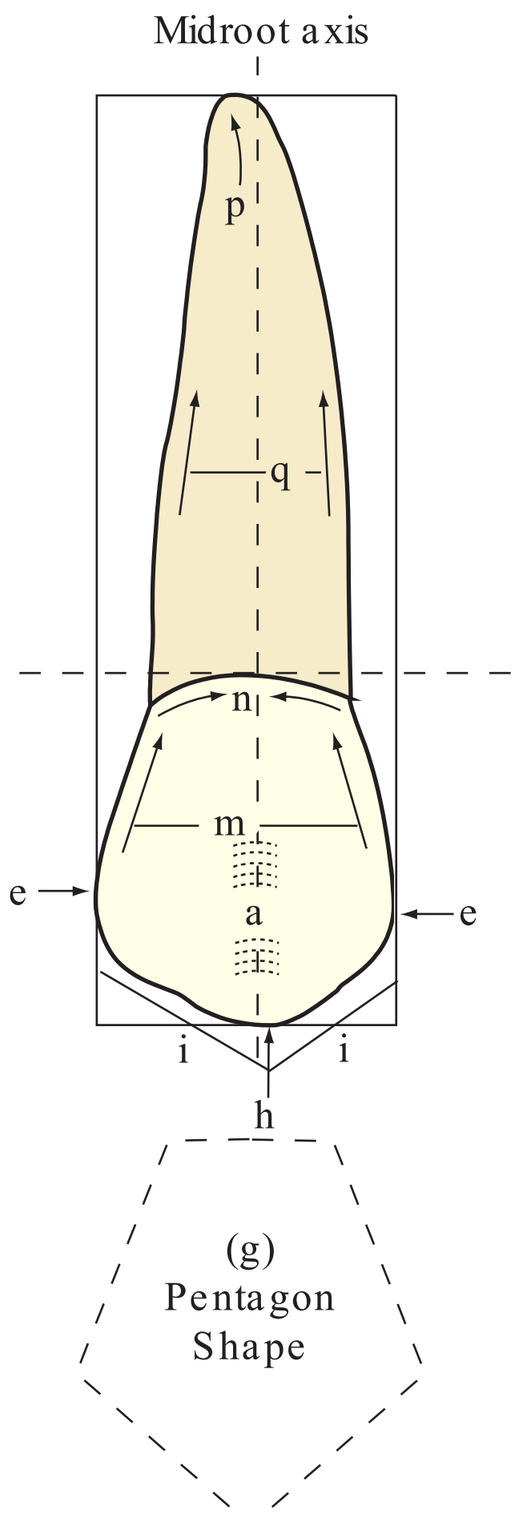

Mesial View

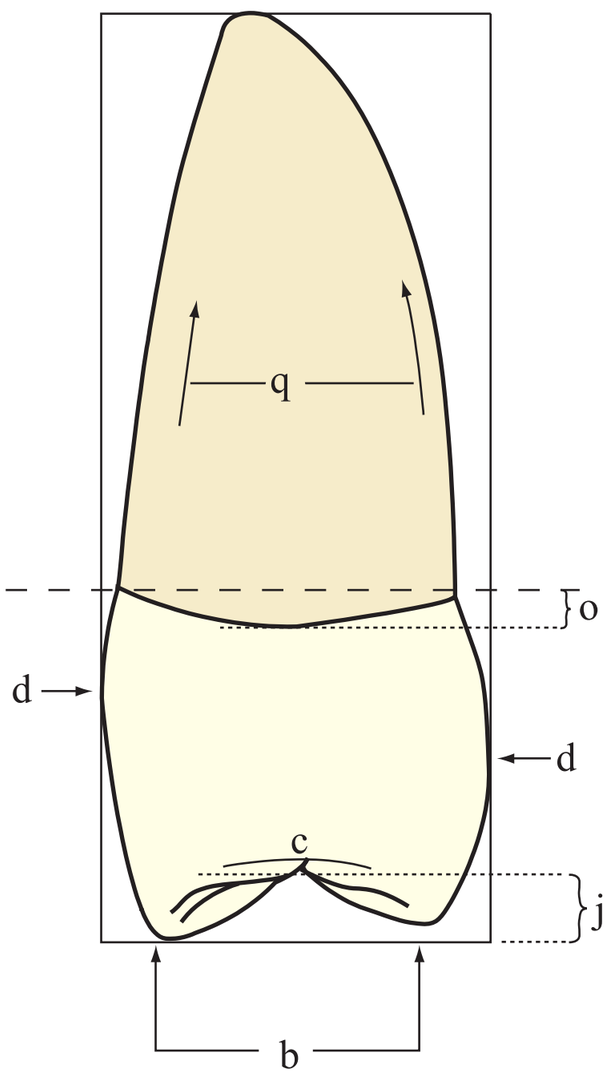

Occlusal View

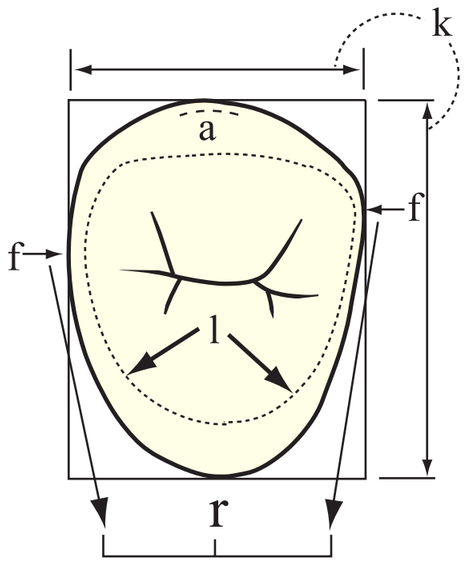

Lingual

Distal View

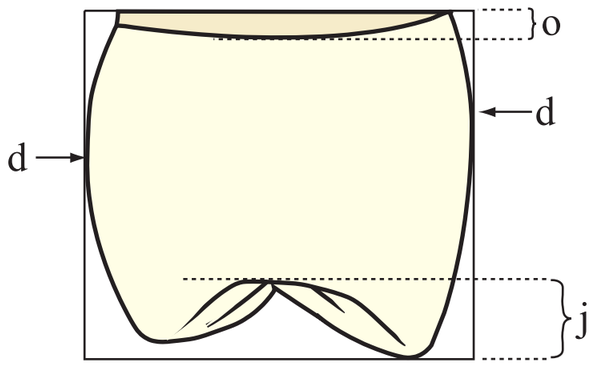

Refer to letters a–r on back, which describe these features.

General Class TraiTs of MosT PreMolars

a. Buccal ridges are present (similar to canine labial ridges) (facial and occlusal views).
b. Usually, premolars have two cusps: one buccal and one lingual (EXCEPTION is the mandibular second premolar, which often has three cusps: one buccal and two lingual) (proximal views).
c. Marginal ridges are aligned relatively horizontally (EXCEPT on mandibular frst premolars, where the mesial marginal ridge is closer to a 45-degree angle from horizontal) (proximal views).
d. Buccal and lingual crests of curvature are more occlusal than on anterior teeth (still in cervical third on the facial but in the middle third on the lingual) (proximal views).
e. Mesial proximal contacts (crests or heights of contour) are near the junction of the occlusal and middle thirds, and the distal contacts are often slightly more cervical in the middle third (EXCEPT on mandibular frst premolars, where mesial contacts are more cervical than the distal contacts) (facial views).
f. Proximal contacts (crests of curvature) from the occlusal view are most often buccal to the center faciolingually (occlusal views).
g. From the facial, premolars are roughly pentagon shaped (similar to canines) (facial view).
h. T e buccal cusp tip is mesial to the midroot axis (EXCEPT on the maxillary frst premolar, where the cusp tip is distal to the midroot axis) (facial views).
i. T e mesial cusp ridge of the buccal cusp is shorter than the distal cusp ridge (EXCEPT on the maxillary frst premolar, where the mesial cusp ridge is longer) (facial views).
j. Mesial marginal ridges are generally more occlusal than distal marginal ridges, which are more cervical (EXCEPT on mandibular frst premolars, where mesial marginal ridges are in a more cervical position) (compare the proximal views).
k. Crowns are oblong from the occlusal view and wider faciolingually than mesiodistally (maxillary premolars are decidedly oblong or rectangular, but mandibular premolars are closer to square [or round] in shape) (occlusal views).
l. Cusp ridges (or slopes) and marginal ridges join to form the boundary of the occlusal surface or occlusal table (occlusal views).
m. Crowns taper from proximal contact areas toward the cervical (facial views).
n. Cervical lines curve apically on the facial and lingual surfaces (facial and lingual views).
o. Cervical lines curve occlusally on the proximal surfaces, with the mesial cervical line more convex than the distal (compare mesial to distal proximal views).
p. T e apical third of roots bend distally more often than mesially (facial views).
q. Roots taper toward the apex (both proximal and facial views).
r. Premolar crowns taper narrower from the contact areas toward the lingual (occlusal views) EXCEPT three-cusp–type mandibular second premolars.

Arch and Type Traits of Premolars

Maxillary

Second (#4)

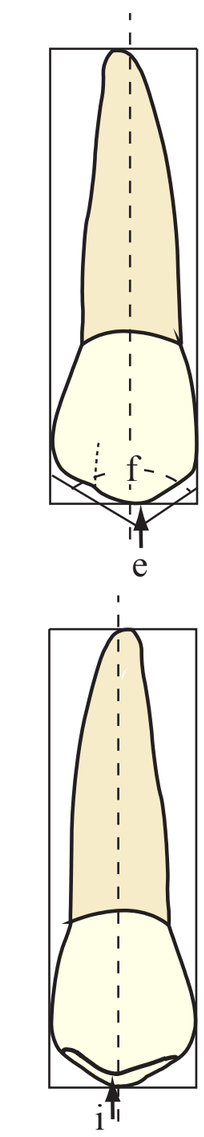

First (#5)

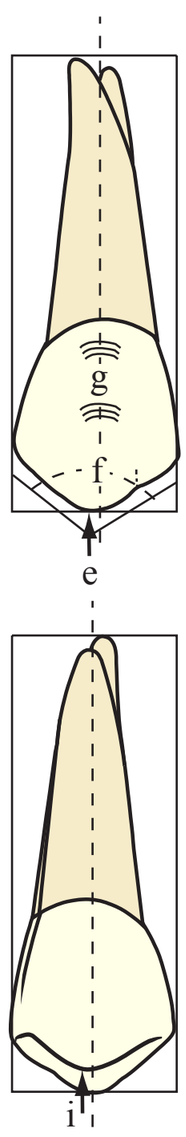

Mandibular

Second (#29)

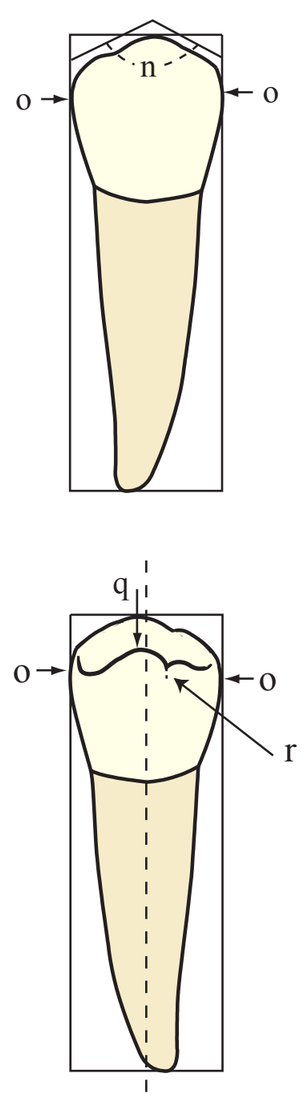

First (#28)

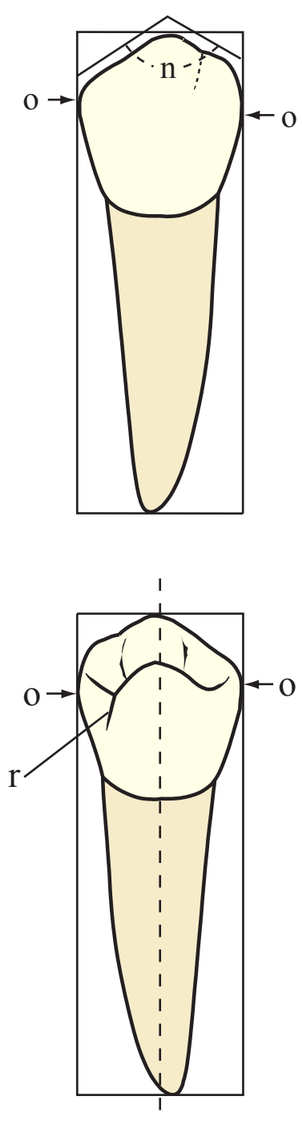

Buccal

Lingual

Mesial

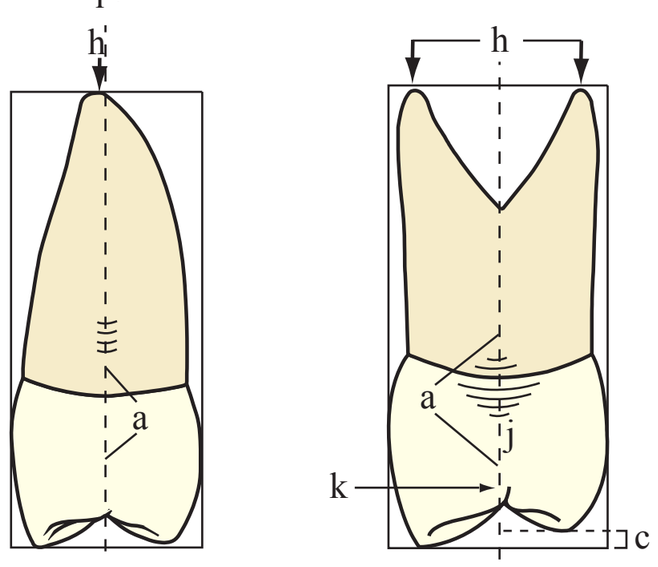

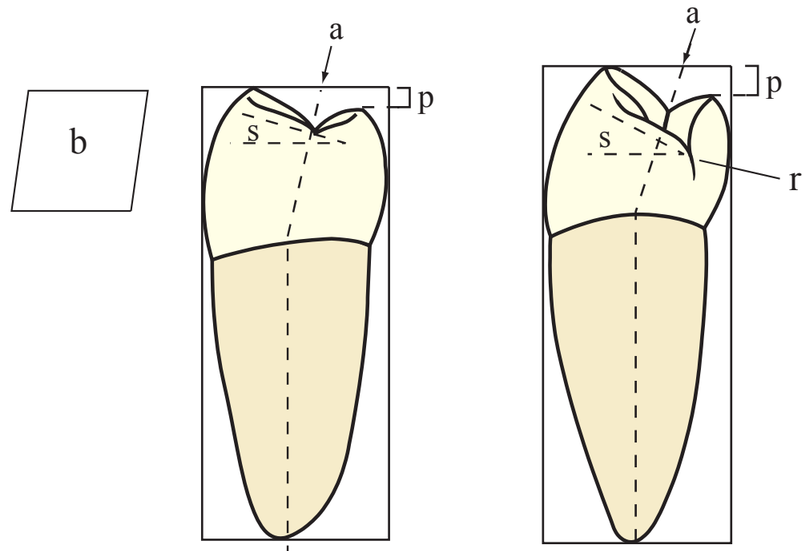

Occlusal

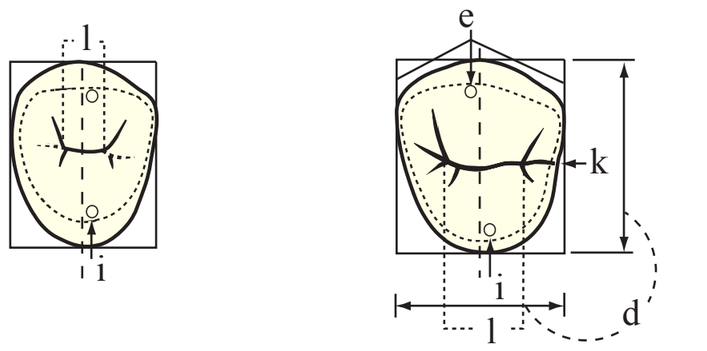

Lingual

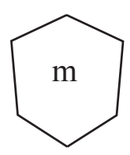

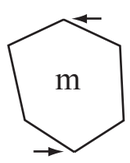

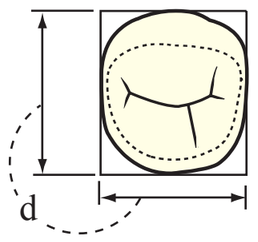

Lingual
(three cusps)

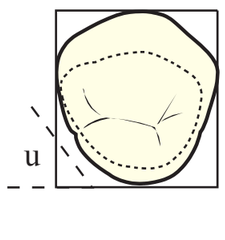

Lingual

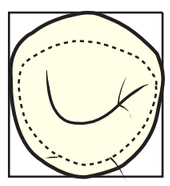

Lingual
(two cusps)

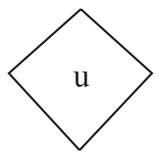

Refer to letters a–u on back, which describe these features (t is not shown).

ar Ch Tr aiTs o f Pr eMo l ar s ThaT Dis Tin Gu ish Maxil l ar y fr o M Man Dibu l ar Pr eMo l ar s

a. Mandibular premolar crowns tilt to the lingual, so mandibular lingual cusp tips may be lingual to the root (proximal views). Maxillary crowns do not tip noticeably.
b. T e outline of the mandibular premolars are rhomboid in shape (four-sided with all opposite sides parallel), and the maxillary premolars are trapezoidal (four-sided with only two opposite walls parallel) (proximal views).
c. (compared to p) Although lingual cusps are shorter than buccal cusps for all premolars, the mandibular lingual cusps are relatively much shorter than buccal cusps (p) compared to maxillary lingual cusps, which are closer to the same length (c) (maxillary second premolar cusps are almost equal in length) (proximal views).
d. Mandibular premolars are slightly wider buccolingually but closer to square or round from the occlusal view; maxillary premolars are more rectangular or oblong (relatively wider buccolingually) (occlusal views).

TyPe Tr aiTs Dis Tin Gu ish in G Maxil l ar y fir sT fr o M Maxil l ar y seCo n D Pr eMo l ar s

e. Buccal cusp tips of maxillary ȧrst premolars are positioned more to the distal, and mesial cusp ridges are longer than distal cusp ridges. T ese are the ONLY type of premolars with this trait (facial and occlusal views).
f. Buccal cusps of maxillary f rst premolars are more pointed (average 105 degrees) than on second premolars, where they are more obtuse (120 to 125 degrees) (facial views).
g. Buccal ridges are more prominent on maxillary f rst premolars (occlusal and facial views).
h. Maxillary f rst premolars are the ONLY type of premolar most likely to have a divided root versus all other types of premolars, which usually have one root (proximal views).
i. Maxillary premolars have their lingual cusp tips positioned more toward the mesial (lingual and occlusal views).
j. Both maxillary premolars have mesial and distal root depressions, but ONLY the maxillary f rst premolars exhibit a mesial crown concavity (mesial views).
k. Mesial marginal ridge grooves are almost always present on maxillary f rst premolars and are less common on second premolars (occlusal and mesial views).
l. T e central developmental grooves on maxillary f rst premolars are longer (from mesial to distal pit) than those of second premolars, where they are only one third or less of the mesiodistal dimension (occlusal views).
m. Occlusal outlines of maxillary f rst premolars are more asymmetrical with the lingual cusp tip positioned more to the mesial and the buccal cusp tip more to the distal, versus second premolars, which are more symmetrical overall (occlusal views).

TyPe Tr aiTs Dis Tin Gu ish in G Man Dibu l ar fir sT fr o M Man Dibu l ar seCo n D Pr eMo l ar s

n. Mandibular f rst premolar buccal cusps are more pointed (110 degrees) versus on second premolar, where they are more obtuse or blunt (130 degrees) (facial views).
o. Mesial proximal contacts (and marginal ridges) of mandibular second premolars are more occlusal than distal contacts (following the general rule), whereas the reverse is true on mandibular f rst premolars (EXCEPTION), where mesial contacts (and marginal ridges) are more cervical (facial views).
p. Lingual cusps of mandibular f rst premolars are very small and nonfunctional. On second premolars, the lingual cusps function and are relatively longer (proximal views).
q. Lingual cusp tips of mandibular second premolars are most often positioned to the mesial (or, if there are two lingual cusps, the mesiolingual is the more prominent) (lingual views).
r. Mandibular f rst premolars have a mesiolingual groove separating the mesial marginal ridge from the lingual cusp. Second premolars (three-cusp type) have a lingual groove separating the two lingual cusps (lingual and mesial views).
s. Mesial marginal ridges of mandibular f rst premolars slope cervically toward the lingual at about 45 degrees from horizontal. On second premolars, they are more horizontal (mesial views).
t. T e mesial root surfaces of mandibular second premolars are the only premolar root surface (maxillary and mandibular, mesial and distal) not likely to have a midroot depression (best seen on models or actual teeth, not labeled in drawings).
u. Mandibular f rst premolars are the only premolars that have the mesiolingual corner, with its mesiolingual groove and low marginal ridge pinched or squeezed in, forming about a 45-degree angle with the lingual surface. T is makes the occlusal outline somewhat diamond shaped (occlusal views).

Class Traits of Most Molars
(using the right second mandibular molar #31 as an example)

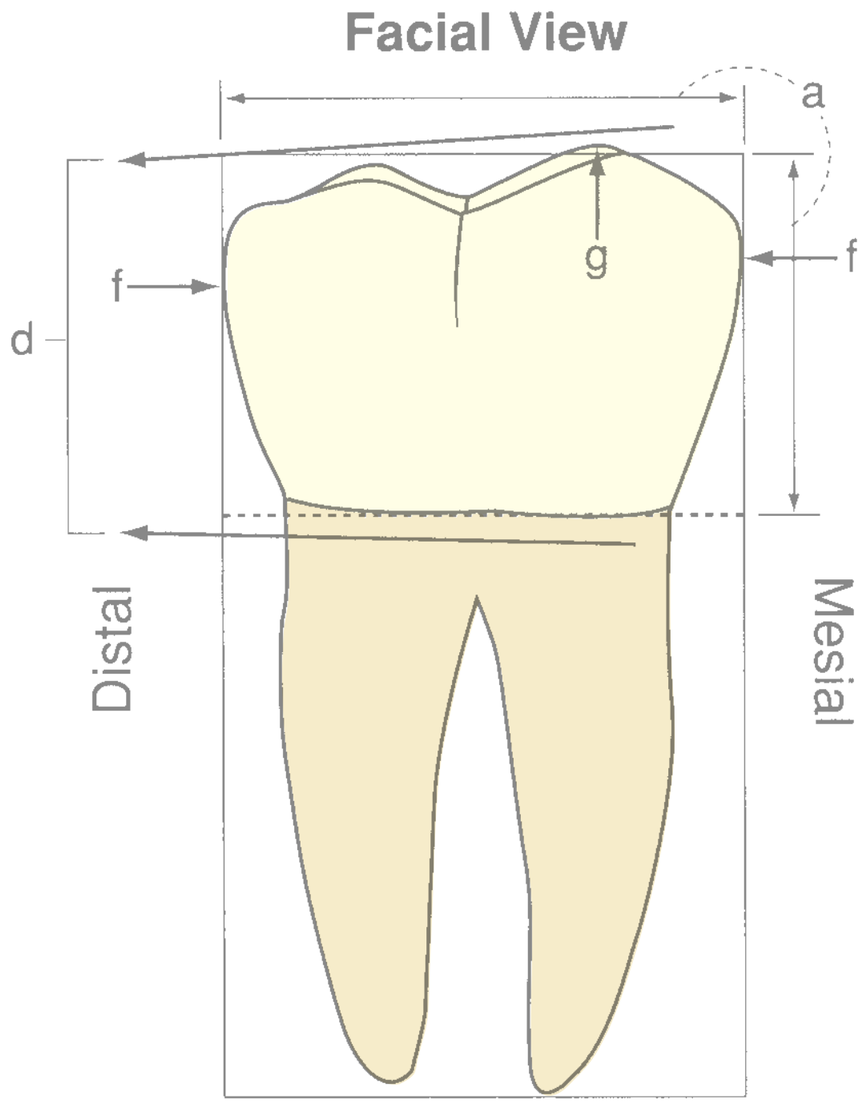

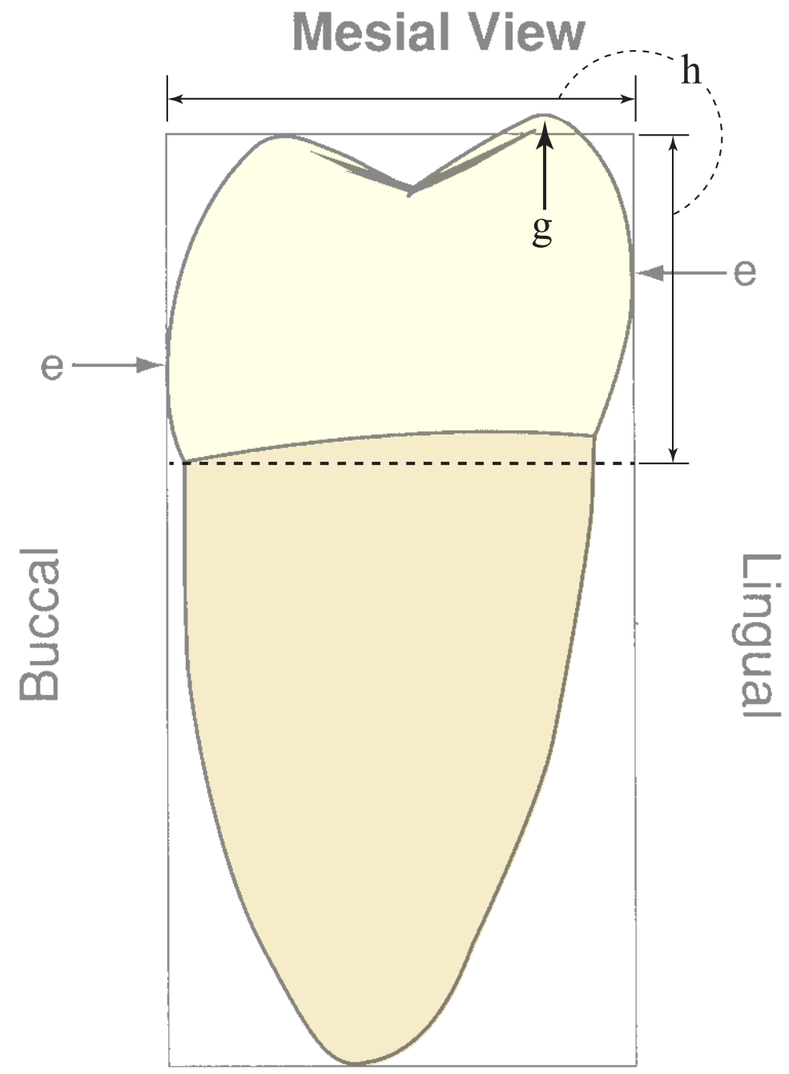

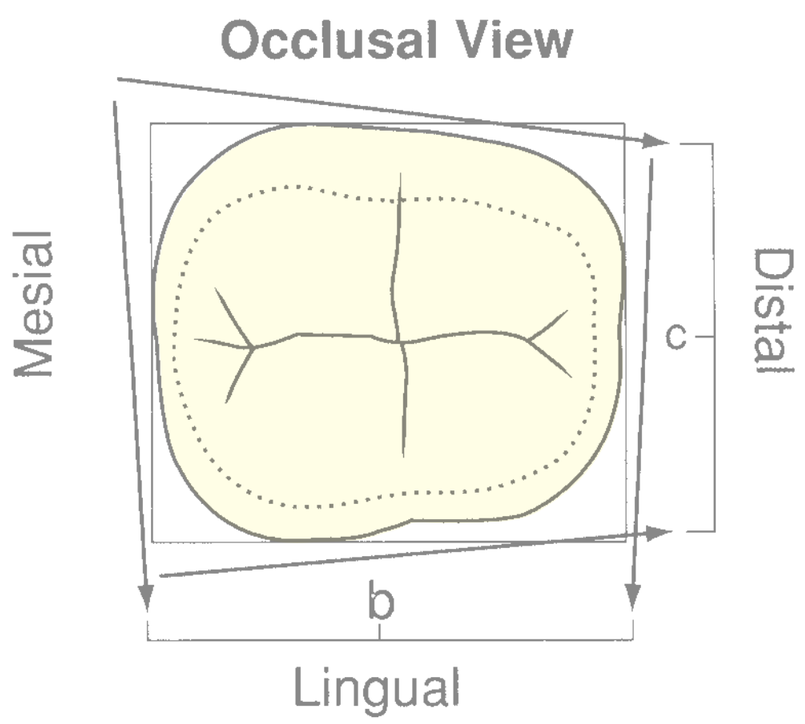

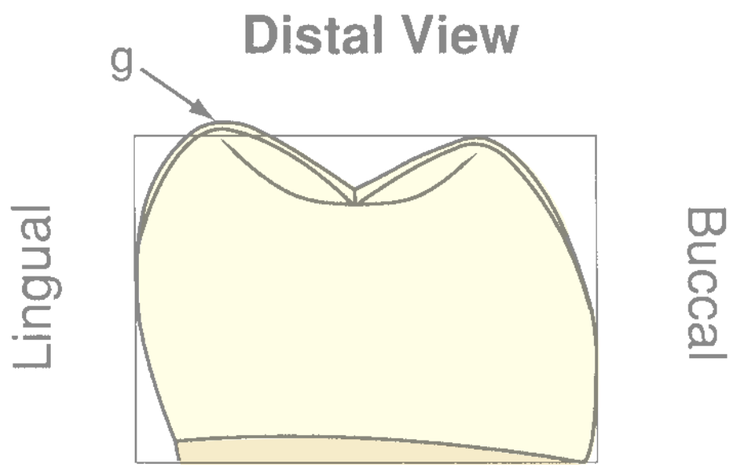

Refer to letters a–h on back, which describe these features.

General Class TraiTs for MosT Molars

a. Molar crowns are wider mesiodistally than cervico-occlusally (facial views).
b. Crowns taper (get narrower) from the buccal to the lingual; that is, the mesiodistal width on the buccal half is wider than on the lingual half (EXCEPT some maxillary frst molars with large distolingual cusps, where crowns taper to the buccal so that the mesiodistal dimension on the lingual is greater than on the buccal) (occlusal view).
c. Crowns taper (get narrower) from the mesial to the distal; that is, the buccolingual width is less on the distal third than on the mesial third (occlusal view).
d. Crowns taper (get shorter) from mesial to distal; that is, the crown height on the distal half is less than on the mesial half (facial view).
e. As with premolars, the buccal crests of curvature (heights of contour) of crowns are in the cervical one third, and the lingual crests of curvature are in the middle third (proximal views).
f. Proximal contacts (heights of contour) on the mesial are at or near the junction of the occlusal and middle thirds, and distal proximal contacts are more cervical, in the middle third near the middle of the tooth (facial views).
g. Lingual cusps on mandibular molars (and mesiolingual cusps on maxillary molars) are longer than buccal cusps when molars are oriented on a vertical axis (facial, mesial, [and distal] views).
h. Molar crowns are wider buccolingually than cervico-occlusally (proximal views).

Arch and Type Traits of Molars

Maxillary

Second (#2)

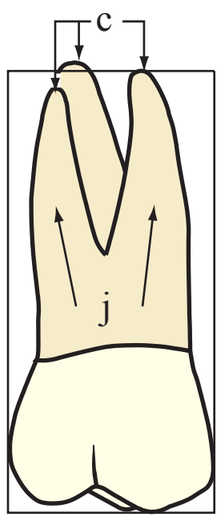

First (#3)

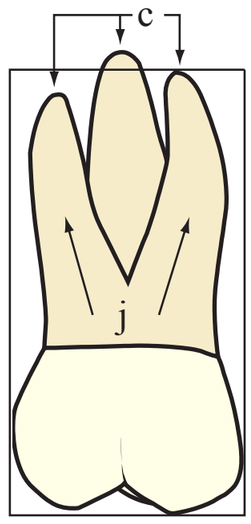

Mandibular

Second (#31)

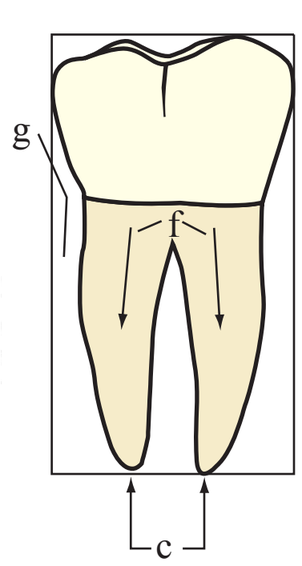

First (#30)

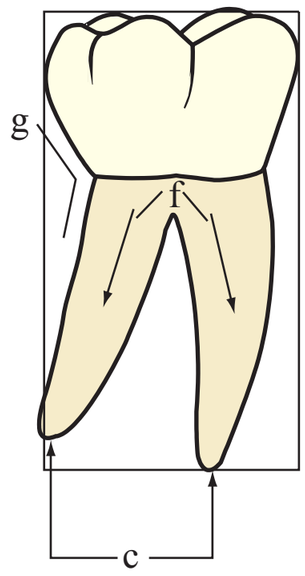

Buccal

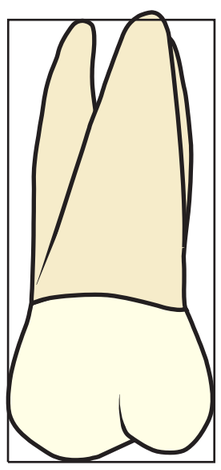

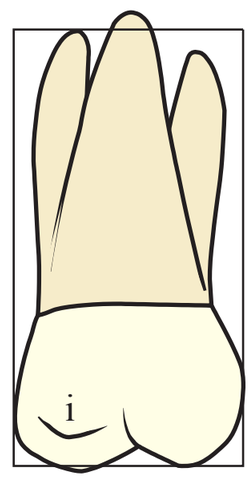

Lingual

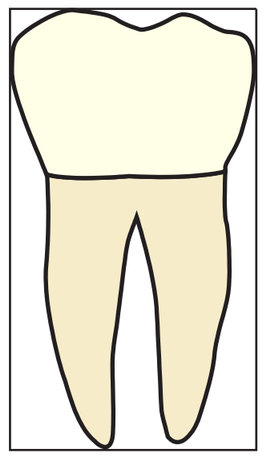

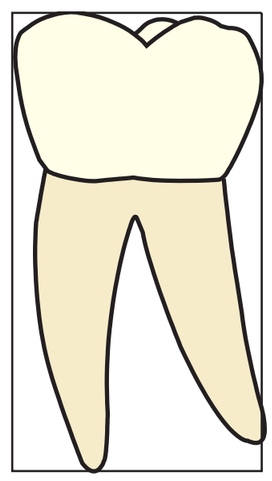

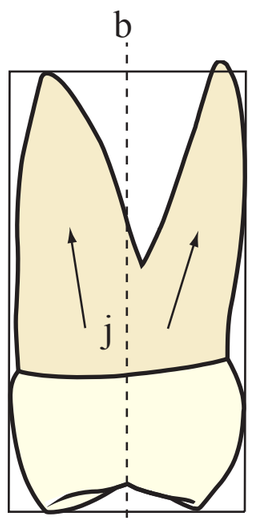

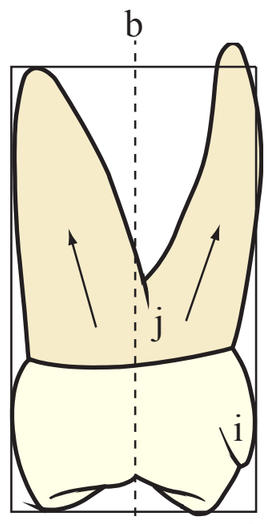

Mesial

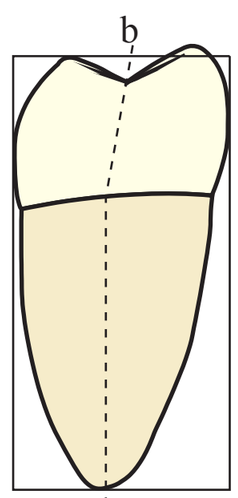

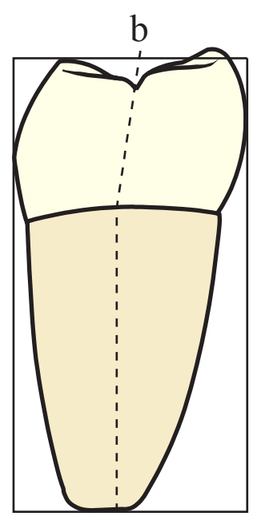

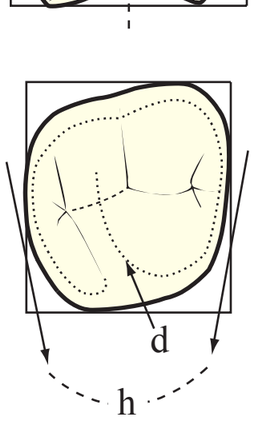

Lingual

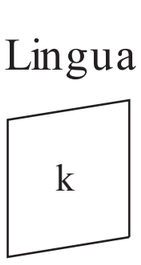

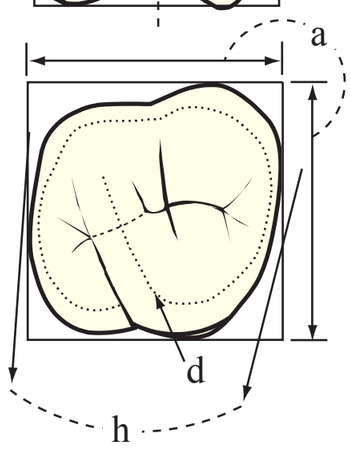

Lingual

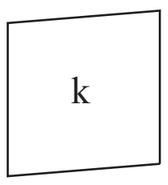

Occlusal

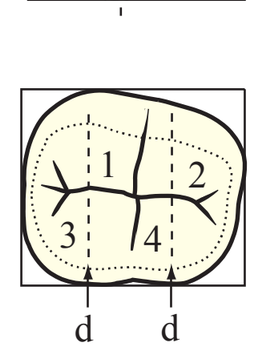

Lingual

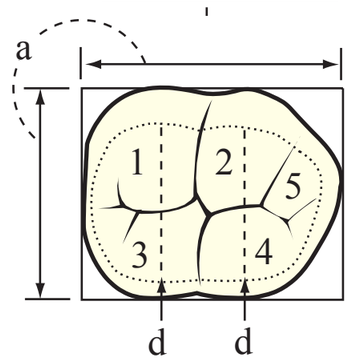

Lingual

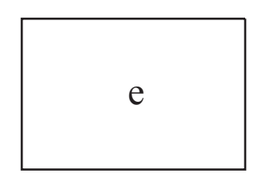

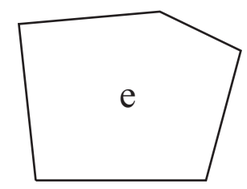

Refer to letters a–k on back, which describe these features.

ar Ch Tr aiTs ThaT DisTin Gu ish Maxillary fr o M Man Dibu l ar Mo l ar s

a. Mandibular crowns are wider mesiodistally than faciolingually, resulting in a more rectangular or pentagon outline (e). Maxillary molar crowns have the faciolingual dimension slightly greater than the mesiodistal dimension and are more square or rhomboid in outline (k) (occlusal views).
b. Mandibular molar crowns tilt lingually at the cervix (like mandibular premolars), whereas maxillary crowns are aligned directly over the roots (proximal views).
c. Mandibular molars usually have two roots (a longer mesial and a shorter distal root) versus maxillary molars, which have three roots (the longest lingual, the shorter mesiobuccal, and the shortest distobuccal root) (facial or lingual views).
d. Maxillary molars have oblique ridges that run diagonally across the tooth from the mesiolingual to the distobuccal cusp, compared to mandibular molars, which primarily have two transverse ridges that run directly buccolingually (occlusal views).

TyPe Tr aiTs ThaT DisTin Gu ish Man Dibu l ar fir sT fr o M Man Dibu l ar seCo n D Mo l ar s

e. Mandibular second molars have four cusps (mesiobuccal = 1, distobuccal = 2, mesiolingual = 3, and distolingual = 4) with a "cross" pattern of occlusal grooves compared to frst molars, which most often have fve cusps (the same four cusps as on the second molar, plus a smaller distal cusp = 5) with a more zigzag central groove pattern (occlusal views; see corresponding numbered cusps, not labeled as "e"). T e occlusal outline of four-cusped mandibular second molars is rectangular and wider mesiodistally than buccolingually, whereas the outline of the fve-cusped mandibular frst molar is often somewhat pentagon shaped due to the prominence of the distobuccal cusp outline (labeled e at bottom of page).
f. First molar roots are more divergent and widely separated compared to second molar roots, which are more parallel and closer together (facial and lingual views).
g. T ere is more taper (narrowing) from the distal proximal contact to the cervical line on frst molars than on second molars due to the presence of the distal cusp on frst molars (facial views).

TyPe Tr aiTs ThaT DisTin Gu ish Maxillary fir sT fr o M Maxillary seCo n D Mo l ar s

h. T ere is more taper (narrowing) from the buccal to lingual on second molars due to their smaller distolingual cusp compared to less taper on maxillary frst molars with their wider, prominent distolingual cusps (occlusal views).
i. First molars are more likely to have a ffth cusp, the cusp of Carabelli (located on the mesiolingual cusp), compared to second molars, which do not normally have a cusp of Carabelli (lingual, mesial, and occlusal views).
j. Roots of frst molars are more spread apart than those of second molars (similar to mandibular molars) (facial and proximal views).
k. T e parallelogram outline shape of maxillary molars (with more acute or sharper mesiobuccal and distolingual angles and more obtuse or less sharp distobuccal and mesiolingual angles) is more twisted on second molars than on frst molars (i.e., acute angles are more acute and obtuse angles are more obtuse on maxillary second molars) (occlusal views).

Primary Anterior Teeth

Maxillary

Canine (C) | Lateral Incisor (D) | Central Incisor (E)

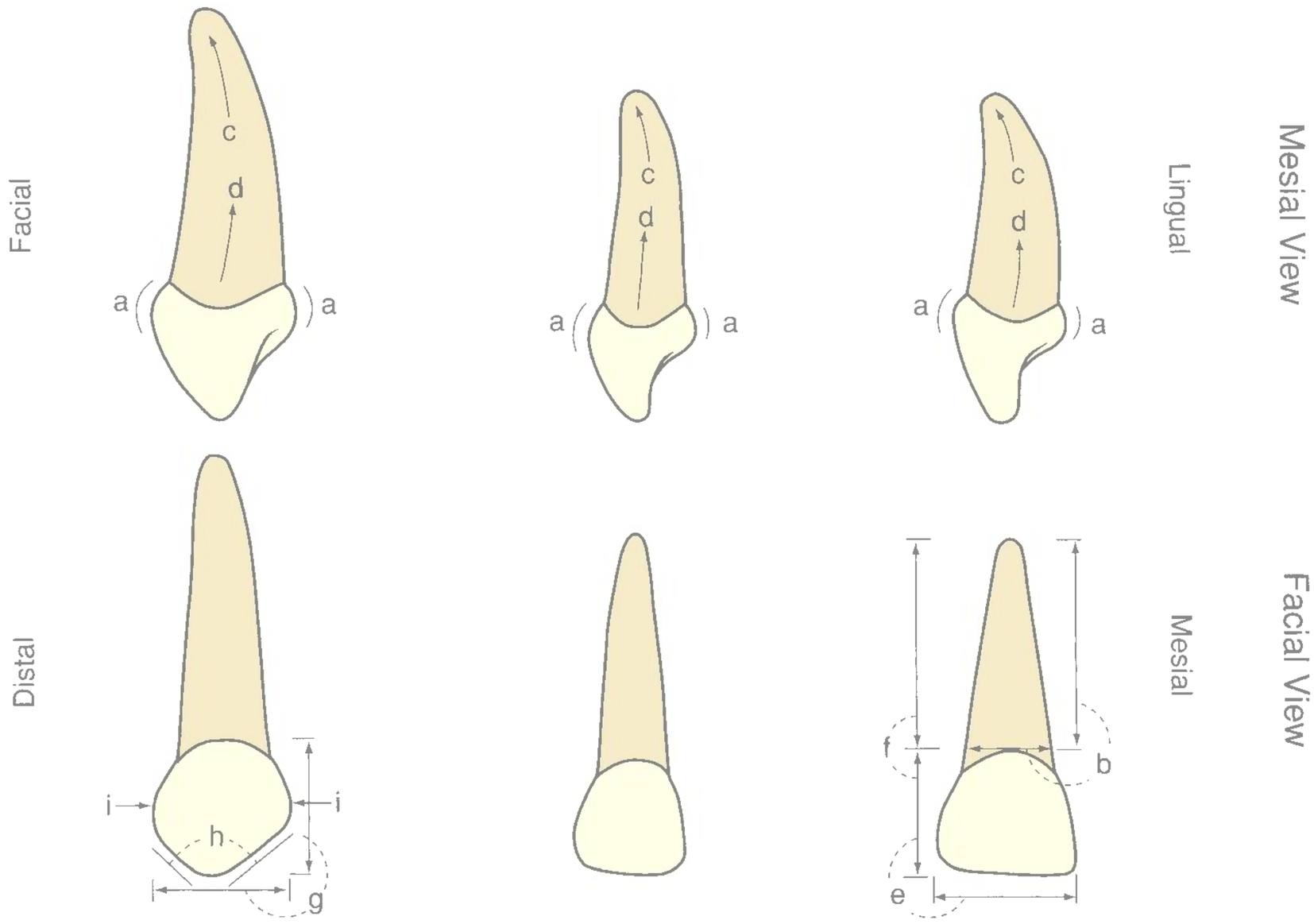

Mandibular

Canine (R) | Lateral Incisor (Q) | Central Incisor (P)

Refer to letters a–i on back, which describe these features.

unique Properties of anterior Primary Teeth

a. Primary anterior tooth crowns have bulges in the cervical third of the labial and lingual surfaces. The lingual bulge is seen as a relatively large cingulum that occupies up to one third of the cervicoincisal crown length, and the labial bulge is seen as a prominent convex cervical ridge (proximal views).
b. Roots are long in proportion to crown length and narrower (thinner) mesiodistally than on permanent anterior teeth (facial view).
c. Roots of maxillary and mandibular primary anterior teeth bend as much as 10 degrees labially in their apical third, less so in mandibular canines (proximal views).
d. Roots of maxillary incisors bend (bow) lingually in the cervical third to half, whereas the mandibular incisors are straighter in their cervical third (proximal views).
e. Primary maxillary central incisors are the ONLY type of incisors, primary or permanent, where the crown is wider mesiodistally than incisocervically (facial views).
f. Primary incisor crowns are shorter relative to the root length compared to permanent teeth (facial views).
g. Primary maxillary canines are about as wide mesiodistally as they are long incisogingivally. Mandibular canines are longer incisocervically and narrower mesiodistally (facial views).
h. Primary mandibular canines have their distal cusp ridges longer than their mesial cusp ridges (as do all permanent canines and premolars EXCEPT permanent maxillary first premolars) (facial views). Primary maxillary canines have their mesial cusp ridges longer than the distal cusp ridges (which is UNIQUE to only this tooth and maxillary first premolars).
i. Primary maxillary canines have mesial proximal contacts more cervical than the distal (which is UNIQUE to this tooth and permanent mandibular first premolars) (facial views). All other primary and permanent teeth have the distal contact area more cervically located than on the mesial.

Primary Molars

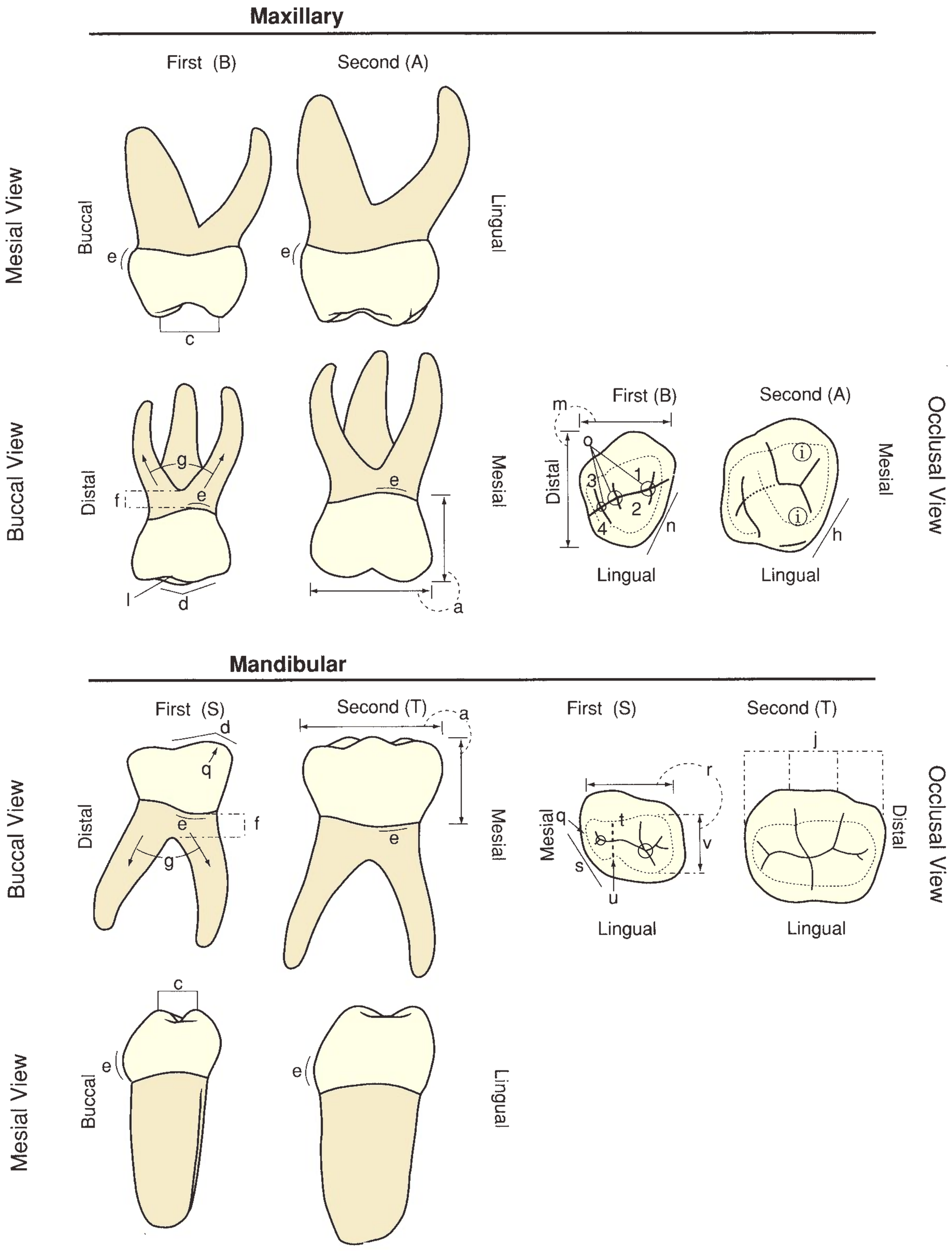

Refer to letters a–v on back, which describe these features.

General Characteristics of all Primary Molars

a. Primary molar crowns are wider mesiodistally and shorter cervico-occlusally, as on permanent molars (buccal views).
b. Primary frst molars are decidedly smaller than primary second molars compared to permanent or secondary molars, where the frst molars are larger (compare all views, not labeled as "b").
c. Primary molar crowns have a narrow chewing surface, or occlusal table, buccolingually compared to the entire tooth width buccolingually (proximal views).
d. Buccal cusps are not sharp; cusp ridges meet at a wide (obtuse) angle (buccal views).
e. Buccal cervical ridges are prominent, especially mesially (proximal views), so the facial cervical lines curve more apically in the mesial half of the buccal surface (buccal views).
f. Root furcations are nearer to the crown with little or no root trunk compared to secondary molars (buccal views).
g. Roots are thin, slender, and widely spread (buccal views).

additional Characteristics unique to Primary Maxillary second Molars (Which Most Closely resemble the Permanent Maxillary first Molars)

h. The mesial surface outline tapers toward the lingual (occlusal views).
i. Primary mesiobuccal cusp is about equal in size to the mesiolingual cusp compared to permanent or secondary teeth, where the mesiolingual cusp is larger than the mesiobuccal cusp (occlusal views).

additional Characteristics unique to Primary Mandibular second Molars (Which Most Closely resemble the Permanent Mandibular first Molars)

j. The three buccal cusps are of nearly equal size versus permanent frst molars, where the distal cusp is usually considerably smaller (occlusal views).

additional Characteristics unique to Primary Maxillary first Molars (Which, from the occlusal View, somewhat resemble Permanent Maxillary Premolars)

k. There are often four cusps: two larger cusps (like a maxillary premolar) (the mesiobuccal cusp (1) widest and longest and the mesiolingual cusp (2) the smaller but sharpest) and two smaller cusps (the distobuccal (3) and the inconspicuous, sometimes absent, distolingual (4)) (occlusal views; see corresponding numbered cusps).
l. A buccal groove (notch) located distal to center divides the large mesiobuccal cusp from the indistinct distobuccal cusp (buccal views).
m. The crown is wider faciolingually than mesiodistally like a maxillary premolar (occlusal views).
n. The mesial surface outline and marginal ridge converge toward the lingual (occlusal views).
o. There are three fossae: a large mesial triangular fossa, a medium central fossa, and a minute distal fossa (occlusal views).
p. The grooves form an "H" pattern (somewhat similar to a maxillary premolar) (not labeled with a letter; seen on occlusal views).

additional unique Characteristics of Primary Mandibular first Molars (resembling no other Tooth)

q. The mesial marginal ridge is overdeveloped, almost resembling a cusp (buccal and occlusal views).
r. The occlusal table is wider mesiodistally than buccolingually like secondary mandibular molars (occlusal views).
s. The mesial surface outline converges to the lingual with an acute and prominent mesiobuccal angle of the occlusal table (occlusal views).
t. The mesiobuccal cusp is the largest and longest cusp, covering nearly two thirds of the buccal surface (occlusal views), but is not wide buccolingually (occlusal views).
u. A pronounced transverse ridge runs between the mesiobuccal and mesiolingual cusp (occlusal views).
v. The occlusal table is larger distal to the transverse ridge with a larger distal fossa and a smaller mesial triangular fossa (no central fossa) (occlusal views).

Glossary for Woelfel's Dental Anatomy

A

Abducens nerve [ab DOO senz]: CN VI, controls eye movement.

Abfraction [ab FRAK shun]: Cervical loss of enamel theoretically thought to be due to tooth bending of the tooth under heavy occlusal forces.

Abrasion [ah BRA zhun]: Wearing away of tooth due the action of abrasive substances (like some toothpastes).

Abutment teeth: Teeth that support the false teeth (called pontics) of a fixed dental prosthesis (or bridge).

Access opening (root canal therapy): T e opening made by the dentist through the crown of a tooth in order to gain access to the diseased pulp.

Accessory canals: Small, extra pulp canals.

Accessory roots: (Anomaly) Development of extra roots.

Acid etching: Roughening of enamel by using an acid thereby permitting mechanical attachment of flowable resin into the remaining tooth irregularities.

Acoustic [ah KOOS tik]: Referring to sounds or hearing or near the ear.

Acoustic meatus [ah KOO stik me A tus]: External acoustic meatus is the passageway into the ear canal of the temporal bone. Internal acoustic meatus is the passage for the facial nerve (CN VII) from the brain into the petrous part of temporal bone.

Adult dentition: All of the teeth of an adult; normally 32 of them.

Aȧerent (sensory) nerves: Type of nerves that convey impulses such as feeling, touch, and pain from peripheral organs like skin or oral mucosa to the brain.

Aggressive periodontitis: Fast progressing, young-adult form of periodontal disease.

Air abrasion system: Abrasive particles are blown forcefully toward tooth to remove decay, forming a modified tooth preparation.

All ceramic restoration: Restoration that completely covers the crown of a tooth and is made entirely of porcelain.

Alveolar [al VEE o lar]: Related to the bone surrounding the roots of teeth.

Alveolar bone: Bone that surrounds the tooth roots.

Alveolar bone proper: T in layer of compact bone lining the tooth socket, seen on an x-ray as the white line called lamina dura. Also called bundle bone.

Alveolar canals: Small passageways in the maxillae located superior and posterior to third molar region; is where the posterior superior alveolar nerves and accompanying vessels pass.

Alveolar eminences: Raised ridges of bone overlying prominent root convexities.

Alveolar mucosa: Loose, nonkeratinized gingiva apical to attached gingiva that is not firmly attached to bone or tooth.

Alveolar process: T e horseshoe-shaped process of the upper or lower jawbones that surrounds all of the roots of healthy teeth.

Alveolingual sulcus [AL vee o LIN gwal]: Broad, valley-shaped space between mandibular alveolar bone and the tongue.

Alveolus [al VEE o lus] (plural alveoli [al VEE o lye])**:** Tooth cavity or socket surrounding each tooth in bone; shape resembles the root it surrounds.

Amalgam, restoration material [ah MAL gam]: Silver-colored restorative filling material used to restore tooth preparations after decay removal.

Ameloblasts [ah MEL o blasts]: Specialized cell that forms enamel.

Amelogenesis imperfecta [ah mel o JEN e sis im per FEC ta]: Hereditary disorder that affects enamel formation; occurs in both dentitions.

Anastomosis [a NAS te MO sis]: Connection between blood vessels, such as between the smallest arteries on the right and left sides of the lips.

Anatomic crown: Portion of the tooth covered with enamel.

Anatomic root: Portion of the tooth covered with cementum.

Angle, Edward H.: Dentist who defined three classes of occlusion in 1887: classes I, II, and III.

Angle of the mandible: Junction of inferior border of the mandible and the posterior border of the ramus; medially is attachment of internal pterygoid chewing muscle; laterally is attachment of masseter muscle.

Angular artery: Along with lateral nasal arteries, are end branches of the facial arteries supplying blood to the side and bridge of the nose.

Angular spine: Pair of thorn-shaped bony prominences on the inferior surface of the sphenoid bones; attachment of sphenomandibular ligament. Also called sphenoidal spine.

Ankylosis [ANG ki LO sis]: Loss of periodontal ligament resulting in fusion of cementum to bone due to trauma or infection; results in infraocclusion**.**

Anodontia [an oh DON she ah]: (Anomaly) Absence of teeth; can be total (**total** congenital absence of the entire primary or secondary dentitions) or partial (**partial** congenital absence of teeth from primary or secondary dentitions).

Anomaly [ah NOM ah lee]: Deviation from normal.

Antegonial notch: Shallow notch located on inferior border of mandible, anterior to mandibular angle; where facial vessels and nerves pass from neck to face.

Antemortem dental records [an te MOR tem]: Dental charts and radiographs recording the condition of the mouth, collected prior to death.

Anterior: Toward the front of the body.

Anterior deprogramming: Process of getting the TMJ into a relaxed neuromuscular position by interrupting signals from proprioceptors in the periodontal ligaments.

Anterior fibers (of temporalis muscle): T e anterior vertical fibers that help to elevate the mandible and close the mouth.

Anterior guidance or anterior protected articulation: T e beneficial overlapping of maxillary over mandibular incisors that causes posterior teeth to separate during forward movements of the mandible.

Anterior superior alveolar nerve abbreviated ASA (and vessels): Branches of maxillary division of CN V that branch off of the infraorbital nerve while within the inferior orbital canal; pass through maxillary sinus toward maxillary anterior teeth and surrounding structures. Accompanied by ASA vessels.

Anterior teeth: Teeth in the front of the mouth, namely, incisors and canines.

Anteroposterior curve: T e curve formed by connecting all buccal cusps in a quadrant; the curve is convex in the upper arch and concave in the lower arch. Also called curve of Spee.

Antrum [AN trum]: Natural cavity within bone such as a sinus.

Aperture [AP er chur]: An opening, as in bone.

Apex: Tip, of a root.
Apical foramen [APE i kal fo RAY men] (plural foramina [fo RAM in na]): Hole(s) near the root tip where nerves and vessels enter the pulp.
Arch (dental): Refers to the arch-shaped alignment of all teeth in either the upper or lower jaw.
Arch traits: Characteristics that apply to classes of teeth in the same arch.
Articular capsule: Fibrous tube of tissue enclosing the condyles, disc, and mandibular fossa on each side of the temporomandibular joint; includes the thickened lateral or TMJ ligament. Also called fibrous capsule.
Articular disc: In the TMJ, a tough, oval pad of connective tissue that is between each mandibular condyle and the articular fossa of a temporal bone; a shock absorber.
Articular eminence: Ridge of bone forming the anterior border for each articular fossa.
Articular fossa: In the TMJ, anterior two thirds of the mandibular fossa in each temporal bone (the portion of the mandibular fossa anterior to the petrotympanic fissure) where the mandibular condyle articulates. Also called glenoid fossa.
Articulation, long centric: Range of mandibular movements where a person can smoothly move the mandible horizontally from centric relation to maximal intercuspal position.
Articulator: Mechanical device that holds casts of teeth in positions that duplicate the patient's relationship between maxillary and mandibular arches, and his or her functional movements.
ASA: Abbreviation for anterior superior alveolar nerves or vessels.
Ascending palatine artery: Branch of facial artery that supplies blood to structures adjacent to the pharynx.
Aspirating syringe: Syringe design that permits the application of negative pressure to pull in (aspirate) blood into the glass cartridge if the needle is within a blood vessel. T e dentist can then move the needle tip before injecting the anesthetic into the vessel, which might cause detrimental side effects.
Attached gingiva: Keratinized gingiva firmly bound to underlying bone; extends from the free gingival groove to the mucogingival junction.
Attachment level, clinical: Measured as the distance from the cementoenamel junction to the apical extent of the periodontal sulcus (or pocket).
Attrition [ah TRISH en]: T e wearing away of tooth structure due to heavy occlusal contacts between maxillary and mandibular teeth.
Auditory nerves: CN VIII for sense of hearing, position, and balance. Also called acoustic nerves.
Auricular muscles [aw RIK yu lar]: Muscles that move the ear and/or adjacent scalp.
Auriculotemporal nerve [aw RIK yu lo TEM po ral]: Branch of mandibular division of CN V to skin of outer ear. Accompanied by associated vessels.

B

Bennett movement: T e lateral movement or shift of the entire mandible during movement to the working side.
Bevels (on preparation): In a tooth prepared for a cast restoration, the angle established by the dentist of the junction between the prepared tooth with the unprepared tooth surfaces designed for improved adaptation of the restoration.
Bidigital palpation: Using two opposing fingers of one hand (thumb and forefinger) to feel for tissue lumps.
Bifurcation [bi fur KAY shun]: A tooth root that has split into two roots.
Bilaminar zone [bi LA min ar]: Posterior attachment of articular disc by loose elastic, vascular connective tissue.
Bimanual palpation: Using opposing fingers from two hands to feel for tissue lumps.
Biofeedback: Using monitors of muscle activity to improve patient awareness of TMJ muscle overuse.
Biofilm: Organized layer mostly of microorganisms that adhere to teeth and contribute to gingival and periodontal diseases as well as tooth decay. Also known as dental plaque.
Biologic width, of gingiva: An area of attachment of gingiva to cementum that includes junctional epithelium plus a band of connective tissue attachment. Also known as dentogingival junction.
Bite guard or bite plane: Removable artificial occlusal surface used to stabilize occlusion, treat pain from TMDs, and prevent tooth wear. Also called occlusal devise or night guard.
Bite mark analysis: Study of the shape of bite marks after a crime in order to identify the biter.
Black, G.V: One of the fathers of modern dentistry who developed classes of tooth preparation.
Bleaching, intracoronal: Temporary placement of bleach within a pulp chamber whose pulp has been removed; in order to lighten a darkened tooth.
Bleeding on probing (abbreviated **BOP**): Condition where bleeding is visible after probing the gingival sulcus due to inflammation of gingival sulcular epithelium.
Body of the t ongue: Anterior two thirds of tongue, the part normally visible during an oral exam.
Bolus [BOW lus]: Small mass of chewed food.
Bonding agents: A flowable dental material designed to adhere to prepared dentin or enamel in order to attach (bond) the subsequent layers of restorative material.
Bone grafting materials: Donor bone or synthetic material that can create a scaffold for inducing new bone regeneration.
BOP: Abbreviation for bleeding on probing; blood is visible upon probing a periodontal sulcus or pocket due to inflammation of the gingival sulcular epithelium.
Bruxism [BRUCKS iz em]: Undesirable, heavy tooth-to-tooth grinding of teeth back and forth other than chewing, may result in tooth wear or TMJ dysfunction.
Buccal [BUCK k'l]: Related to, or in proximity with, the cheeks; also words beginning the preface "bucc."
Buccal cervical ridge: Subtle crown ridge on the buccal surface of some molars located near the cervical line that is the location of the buccal crest of curvature.
Buccal cusp ridge: Subtle ridge on posterior teeth extending from the cusp tip toward the buccal surface.
Buccal cusps: Cusps on multicusped teeth located toward the buccal on the occlusal surface.
Buccal embrasure: T e portion of the space (embrasure) surrounding the proximal contact of two adjacent teeth that is buccal to the contact.
Buccal frenum: Fold of mucous membrane that attaches the cheek to the mucosa of the alveolar ridge near the premolars; separates labial from buccal vestibule.
Buccal groove: A developmental groove on four-cusp mandibular molars located between the two buccal cusps.
Buccal nerve (and vessels): Nerve branch of mandibular division of CN V to buccinator muscle and adjacent cheek mucosa and skin. Also called long buccal or buccinator nerve. Accompanied by associated vessels.
Buccal shelf: Nearly horizontal ledge of bone between the external oblique ridge and the alveolar process of the mandible; buccal nerve to the cheek is located superior to it.
Buccal surface: Surface of posterior teeth closest to the cheeks. Also called facial surface.

Buccinator crest [BUCK sin a tor]: Small elevation of bone within the retromolar triangle; attachment of posterior fibers of the buccinator muscle.

Buccinator muscle [BUCK sin a tor]: Cheek muscle, keeps food on chewing surfaces of teeth during chewing.

Buccinator nerve [BUCK sin a tor]: Buccal nerve branch of the mandibular division of CV V; to the cheek. Also called buccal nerve or long buccal nerve.

Buccoversion [BUCK o VER zhun]: Tooth that is buccally positioned relative to the ideal parabolic arch form of other teeth.

Bulimia [bu LEE mee ah]: Serious eating disorder where persons overeat followed by self-induced vomiting; acids in vomit can destroy tooth structure.

C

Calcification: Process of taking up calcium into the calcified tissue of a tooth.

Calculus [KAL kyoo les]: Calcified mass that forms on teeth due to calcification of dental plaque. Also called tartar.

Canal orifice (root): On multirooted teeth, the opening on the floor of a pulp chamber into the root canals.

Canines [KAY nines]: T e class of teeth located third from the midline in each quadrant.

- **Canine eminence**: Raised ridge of alveolar bone over the prominent canine roots.
- **Canine fossa**: Depression in bone just posterior and superior to canine eminences; over area of premolar roots.
- **Canine guidance**: T e beneficial overlapping of canines that causes posterior teeth to separate during movements of the mandible from right to left. Also called canine-protected articulation.
- **Canine-protected articulation or occlusion**: Desirable occlusal relationship where vertical overlap of opposing canines produces a separation of posterior teeth when the mandible moves laterally. Also called canine guidance.

Capsular ligament: Fibrous tube of tissue enclosing the condyles, disc, and mandibular fossa on each side of the temporomandibular joint; includes the thickened lateral or TMJ ligament. Also called fibrous capsule.

Carabelli cusp [care a BELL ee]: A fifth, relatively small, functionless cusp on many maxillary first molars located on the lingual surface of the mesiolingual cusp. Also called a fifth cusp.

Caries (dental caries) [CARE eez]: Dental decay, literally means "rotten."

Carotid artery: Vessel carrying blood from the aorta to the head; external branches supply the teeth and surrounding structures; internal carotid passes into braincase.

Carotid canal: Passageway of internal carotid artery into braincase.

Cast metal restorations: Restorations made outside of the mouth; are cast in metal.

Cavernous sinus: Collection of thin-walled vessels on the base of brain where infection can spread into the brain.

Cavity preparation: T e procedure for removing diseased hard tooth tissue while developing an acceptable form to place and retain the restoration.

Cavosurface margins [KAY vo SUR fes]: T e junction of a tooth preparation and adjacent uncut tooth; also called the outline of the preparation.

Cement base or liner: Dental materials designed to be placed under restorative filling materials to improve patient comfort and restoration success.

Cementoblasts [se MEN toe blasts]: Specialized cells that produce cementum.

Cementodentinal junction [se MEN toe DEN tin al]: Junction between cementum and dentin, cannot be seen on an intact tooth.

Cementoenamel junction [se MEN toe ehn AM el]: Junction between enamel and cementum; also called cervical line and abbreviated CEJ.

Cementum [se MEN tum]: External layer of calcified tissue that covers the tooth root.

Central: Located in the center.

- **Central incisor**: A type of incisor located next to the midline in each quadrant.
- **Central fossa** [FAH sah]: A shallow depression between cusps near the center of the occlusal surface on most molars and three-cusp premolars.
- **Central groove**: A developmental groove in enamel that separates buccal and lingual cusps.

Centric relation (abbreviated **CR**): Relationship of the mandible to the maxillae where healthy muscles and bony joint contours comfortably guide the mandible into its most posterior position as if there were no teeth to guide the mandible. Also called centric jaw relation.

Ceramic restorations: Restorations made entirely out of ceramic, a type of porcelain, an esthetic material that resembles enamel.

Cervical [SER vi k'l]: Related to the neck (cervix) of the body, or on a tooth, the area surrounding the cementoenamel junction.

- **Cervical chain of lymph nodes**: Deep and superficial cervical lymph nodes are located along the sternocleidomastoid muscle in the neck; they collect lymph from the submental, submandibular and parotid nodes.
- **Cervical curvature**: T e curve taken on by the CEJ: curved apically on the facial and lingual surfaces and curved occlusally or incisally on the proximal surfaces.
- **Cervical line**: Junction between enamel and cementum; also called cementoenamel junction.
- **Cervical ridge**: Subtle ridge on the buccal crown surface of some molars located in the cervical third.

Cervix of tooth [SER viks]: Portion of tooth crown and root adjacent to the cervical line.

Chamfer [SHAM fur]: Rounded finish line of the preparation used for a cast metal crown; finish line is the portion of the preparation where the prepared tooth meets unprepared tooth.

Chronic periodontitis [PAIR ee o don TIE tis]: Slowly progressing, adult form of periodontal disease.

Cingulum [SING gyoo lum]: Bulge in the cervical third of the lingual surface of anterior teeth; forms the lingual height of contour.

Circumvallate papilla [sir kum VAL ate pah PILL ah], plural **papillae** [pah PILL ee]: Eight to twelve prominent, flat, mushroom-shaped projections forming a V-shaped row on the dorsum of the tongue anterior to the terminal sulcus; they contain taste buds.

Civil litigation, forensic dentistry: Court case involving a violation of the standards of care, human abuse and neglect, or malpractice.

Clasps, of removable dental prosthesis: Flexible arms of the framework for a removable prosthesis that engage into undercuts on the tooth to provide retention.

Class of carious lesions (and their tooth preparations): Developed by Dr. GV Black.

- **Class I**: Pit and fissure type of lesion located on the occlusal surfaces of posterior teeth, lingual of maxillary molars, buccal of mandibular molars, and lingual of some incisors.

Class II: Smooth surface decay located on proximal surfaces of posterior teeth.
Class III: Smooth surface decay located on proximal surfaces of anterior teeth.
Class IV: Smooth surface lesions involving proximal surfaces of anterior teeth AND adjacent proximal incisor angles.
Class V: Smooth surface lesions located in the gingival one third of facial or lingual crown surfaces.

Class I occlusion: An ideal occlusal relationship where the mesiobuccal cusp of the maxillary first molar occludes against the mesiobuccal groove of the mandibular first molar. Also called neutroclusion or normal occlusion.

Class II occlusion: Skeletal type of malocclusion where the mandible is too small or the maxillae are too large, or both. T is results in a retruded or retrognathic chin profile. Also called disto-occlusion.

Class III occlusion: Skeletal type of malocclusion where the mandible is too large or the maxillae are too small, or both. T is results in a protruded or prognathic chin profile. Also called mesio-occlusion.

Class (of teeth): Four categories or groups of teeth based on similar shape and function, namely, incisors, canines, premolars, and molars.

Clavicle [KLAV i k'l]: Collar bone.

Clench (teeth): Squeezing together opposing teeth without jaw movement; seen as a bulge of some chewing muscles.

Clinical crown: Portion of a tooth that is visible in the mouth, and in a tooth with bone and tissue loss, this includes part of the exposed anatomic root.

Clinical root: Portion of a tooth that is not visible in the mouth; in a partially erupted tooth, this includes part of the anatomic crown, which is not visible.

Col [KOL]: Notch in the interproximal papilla conforming to the teeth just apical to the adjacent tooth contact.

Commissural papule [COM i SHUR al]: Slight bulge of mucous membrane in the oral cavity 4 to 6 mm posterior to the commissure of the lips.

Commissure, labial [COM i shur]: Junctions of the two fleshy borders of the upper and lower lips, where they come together on the right and left sides.

Common facial vein: Vessels that drain blood from the face and empty into the internal jugular vein.

Complete removable dental prosthesis [pros THEE sis]: A full denture replacing all teeth, which can be removed.

Composite resin: An esthetic tooth-colored restorative material used to place into preparations after removing dental decay.

Conchae [KONG kee]: Paired scroll-shaped bones in the nasal cavities that increase surface area of mucosa for warming and moistening breath. Also called turbinates.

Concrescence [kon KRES ens]: (Anomaly) Superficial fusion of two adjacent tooth roots; fused only by cementum.

Condyloid process [KON di loyd] or **mandibular condyle** [KON dile]: Rounded process on superior posterior border of mandibular ramus; part of temporomandibular joint.

Congenitally absent or missing teeth: Teeth that never developed.

Connective tissue attachment: Band of tissue apical to the junctional epithelium that attaches gingiva to cementum via gingival fibers. Together, the connective tissue attachment and junctional epithelium form the dentogingival junction.

Connective tissue graft: Technique used to cover an exposed root after gingival loss using a piece of donor tissue.

Conservative resin restoration: Restoration requiring a very conservative preparation and restored with resin and sealant.

Contact areas, proximal: T e area on a tooth where it touches an adjacent tooth in the mouth.

Convenience form (of tooth preparation): Design (shape) of preparation that permits access to remove decay and place the filling.

Coronal suture [kor O nal]: Immovable junction between the frontal and parietal bones (near where a coronation crown might fit).

Coronoid process [KOR o noyd]: Pointed (like a crown) anterior border of mandibular ramus.

Corrugator supercilii muscle [SOO per SILL ee eye]: Facial expression muscle that pulls the medial eyebrow down, as in a frown.

Cortical plate: T in layer of bone covering the medial and lateral surfaces of the mandible. Sandwiched in between is trabecular bone.

Cranial fossae [FAH see]: Large depressions along the internal floor of the braincase: Anterior fossa houses the frontal lobes of the brain, middle fossa houses the temporal lobes of brain, and posterior fossa houses the cerebellum.

Cranial nerves (abbreviated **CN**): Twelve pairs of nerves that pass through bony openings in the skull directly from the brain; abbreviated CN I through XII (in Roman numerals).

Crepitation or crepitus [KREP i tes]: Grating or popping sound within temporomandibular jaw joint due to joint irregularities.

Crest of curvature: Greatest bulge of a crown contour where a line drawn parallel to the midroot axis line touches the crown outline. Also called height of contour or crest of contour.

Cribriform plate [CRIB ri form]: Sievelike plate in the ethmoid bone with many holes where the branches of the olfactory nerve (CN I, for smell) pass to the brain.

Crista galli [Kris ta GAL lee]: Triangular, superior projection of the ethmoid bone.

Crossbite: A malocclusion where a tooth has a much more buccal or lingual relationship with its opposing teeth compared to the ideal relationship. Also called reverse articulation.
Anterior crossbite: Mandibular anterior teeth are facial to opposing maxillary anterior teeth.
Posterior crossbite: Mandibular posterior teeth are considerably too far buccal or too far lingual compared to opposing maxillary posterior teeth.

Crown (metal): Gold or semiprecious metal restorations made outside of the mouth and used to cover and protect an entire tooth crown. One example is complete cast metal crown. If metal is partially covered with porcelain, it is a metal ceramic restoration.

Crown lengthening, clinical: Procedure that increases amount of supragingival tooth structure by removing or apically positioning gingival tissue.

Curettes, dental [kyoo RETS]: Dental instruments designed to remove hard deposits from teeth.

Curve of Spee: Curve formed by connecting all buccal cusps in a quadrant; the curve is convex in the upper arch and concave in the lower arch. Also called the anteroposterior curve.

Curve of Wilson: Curve formed by connecting the buccal and lingual cusps of posterior teeth of the same type on the right and left sides of an arch; the curve is convex in the upper arch and concave in the lower arch. Also called the mediolateral curve.

Cusp: Somewhat pyramidal elevation on the occlusal surface (or incising surface on a canine).
Cusp of Carabelli [Care a BELL ee]: Small, functionless fifth cusp located on the lingual surface of the mesiolingual cusp of many maxillary first molars. Also called a fifth cusp.

Cusp ridges or cusp slopes or cusp arms: Linear elevations extending both mesially and distally from a cusp tip; each cusp has a mesial and distal cusp ridge.

Cusp tip: T e peak, or highest point, of a cusp.

Cyst [SIST]: Epithelium-lined sac filled with liquid or semiliquid material.

D

Debridement [di BREED ment]: Removal of inflamed or contaminated tissue and foreign matter.

Deciduous dentition (teeth) [de SIDJ oo us]: T e first set of 20 teeth that erupt between about 6 months and 2 years. Also called primary dentition.

Deep facial vein: Vessels that connect the deeper pterygoid plexus with the more superficial facial vein.

Def ective tooth contacts (occlusal contacts): Tooth contacts of opposing teeth that touch before any others when closing the mandible in a relaxed posterior position causing the mandible to deflect from its relaxed closing path. Also called a prematurity or premature contact.

Deglutition [de gloo TISH un]: Process of swallowing.

Dehiscence, root [dee HISS enss]: Isolated area of exposed tooth root with no bony covering.

Demineralization: Loss of minerals from mineralized tooth structure, as occurs during dental decay.

Dens in dente [denz in DEN tee]: (Anomaly) Invagination of epithelium of the enamel organ before the formation of hard tissue; literally means "tooth within a tooth."

Dentin [DEN tin]: Tooth tissue underlying the enamel and cementum; surrounds the pulp cavity.

Dentin dysplasia [dis PLAY zhah]: Abnormal development of the dentin.

Dentinoenamel junction [DEN tin o ehn AM el]: Junction between enamel and dentin.

Dentinogenesis imperfecta [den tin o JEN e sis im per FEC ta]: Hereditary disorder that affects the dentin formation of both dentitions; may result in gray or brown discoloration of teeth.

Dentistry: Branch of medicine involving study, diagnosis, prevention, and treatment of diseases and disorders of the teeth and adjacent structures in the oral cavity.

Dentition [den TISH un]: All of the teeth in the mouth: primary, permanent or mixed.

Dentogingival junction: Attachment of tooth to gingiva, coronal to the crest of alveolar bone; includes junctional epithelium and connective tissue attachment. Also called biological width.

Depress: Make lower (such as the mandible when opening the mouth).

Depressor anguli oris: Pair of the lower oral group of facial expression muscles that lower the angle of the lips, as in a frown.

Depressor labii inferior: Pair of the lower oral group of facial expression muscles that lower the lower lip.

Depressor septi nasi muscle: Muscle of facial expression that pulls down the nostrils.

Descending palatine nerve: Branch of maxillary division of CN V to nasal cavity and palatal tissues via greater palatine foramen.

Desensitizing agents: Chemicals designed to reduce the sensitivity from exposed dentin.

Developmental grooves: Primary grooves (major grooves) that separate cusps or other major portions of a tooth that were formed by developmental lobes.

Developmental lobes: Primary growth centers of the tooth that form major morphological structures of the crown.

Diastema [die a STEE mah]: Space between adjacent teeth that is not the result of a missing tooth.

Die (dental): Accurate dental stone reproduction of a prepared tooth, used to construct indirect cast restorations.

Digastric muscles [die GAS trik]: Suprahyoid muscles that aid in retruding and depressing the mandible.

Dilaceration [die lass uh RAY shun]: (Anomaly) Severe curvature of a root. Also called flexion.

Disocclusion: Separating of posterior teeth.

Distal (and preface **disto**): Related to the tooth surface farther from the arch midline; on the opposite side from the mesial tooth surface.

Distal cusp: Small, fifth cusp found on most mandibular first molars located near the junction of the buccal and distal surfaces.

Distal oblique groove: Groove on the occlusal surface of four-cusped maxillary molars that extends from the distal pit to between the two lingual cusps. It may continue onto the lingual surface as a lingual groove.

Distobuccal root or cusp: Cusp or root closest to the junction of the distal and buccal surfaces.

Distobuccal (developmental) grooves: Developmental groove on five-cusp molars located between the distobuccal and distal cusps.

Distolingual root or cusp: Cusp or root closest to the junction of the distal and lingual surfaces.

Distolingual twist: Twisting of the incisal edge of some teeth where, when viewed incisally, the distal part is twisted more lingual than the mesial part.

Distomolar: (Anomaly) An extra (fourth) molar forms distal to the third molar. Also called a paramolar or fourth molar.

Disto-occlusion: Skeletal type of malocclusion where the mandible is too small or the maxillae are too large, or both. T is results in a retruded or retrognathic chin profile. Also generally considered the same as Angle's class II occlusion.

Divisions of trigeminal nerve (CN V): T ree divisions: division I is ophthalmic passing from brain via superior orbital fissure to skin of upper face; division II is maxillary via foramen rotundum to palate and upper teeth and surrounding structures; and III is mandibular via foramen ovale to lower teeth and surrounding structures.

DNA analysis: Comparison of DNA found in an unidentified person with DNA from a known person (as obtained from epithelial cells found on their used toothbrush, hair cells, or pulp tissue).

Dorsum of tongue: T e superior surface of the tongue.

Dwarf root: (Anomaly) Tooth root that is much shorter than normal.

Dysplasia [dis PLAY zhah]: Generic term that indicates abnormal tissue development. Can be of the enamel or of the dentin.

E

Eccentric jaw relationships: Any deviation of the mandible from the relaxed centric relation position.

Edge-to-edge occlusion: Maxillary incisal edges line up touching mandibular incisal edges with no vertical overlap when posterior teeth are closed together.

Eἀerent (motor) nerves: Type of nerve fibers that convey impulses from the brain to peripheral organs like muscles, to initiate contraction.

Elevate the mandible: Raise the mandible to close the lower and upper teeth together.

Embrasure spaces [em BRAY zhur]: Continuous space(s) that surrounds the contact areas between adjacent teeth. T is space can be subdivided into four smaller spaces: a facial, lingual, and

occlusal (or incisal) embrasure space and a cervical or gingival embrasure space (also called an interproximal space), which is filled with gingiva in a healthy person.

Enamel [ee NAM el]: Hard, mineralized outer layer of a tooth crown.

Enamel dysplasia [dis PLAY zhah]: Abnormal development of the enamel.

Enamel extension: (Anomaly) A thin projection of enamel that spreads toward the root furcation.

Enamel pearls: (Anomaly) Small, round spheres of enamel with a core of dentin; attached to the tooth.

Endodontics [en doe DON tiks]: Dental specialty concerned with diagnosis and treatment of pathology of dental pulp and associated periapical tissues.

Endodontist [en doe DON tist]: Dentist who specializes in endodontics, especially root canal therapy.

End-to-end occlusion: When maxillary buccal cusps line up over mandibular buccal cusps.

Envelope of motion: Paper record of the outline of the limits of the movement of the lower jaw from different views.

Epithelium [ep I THE lee um]: Cellular layer covering of internal mucosa and external skin surfaces of the body.

Erosion [e RO zhun]: Loss of tooth structure from the action of acidic substances, like citric acid in lemons, stomach acids, and carbonated beverages.

Eruption: Process of a tooth development when the tooth enters the mouth and becomes visible.

Esthetic restorative materials: Filling materials that have a similar color and translucency to the tooth being restored.

Ethmoid bone: Single, sinus-filled bone located at the midline between the eye orbits; contains cribriform plate and part of nasal septum.

Exfoliation [eks fo lee EY shun]: Process of shedding (loss) of the primary teeth.

Exostosis [eck sos TOE sis]: Benign growth (bump) of bone. Also seen as a torus on the palate or tori on the mandible.

External (and preface extra): Toward the outside of the body, or seen from the outside.

- **External acoustic meatus** [a COO stik me A tus]: Pair of openings into the ear canal on the lateral surface of the temporal bones; also called auditory meatus.
- **External carotid artery**: Vessel directing blood from aorta to the head, gives off maxillary branches to all teeth and surrounding structures.
- **External oblique ridge or line** [ob LEEK]: Linear prominence on the external surface of the mandible extending from anterior border of the ramus toward the canine region.
- **Extracoronal restoration**: [EX tra COR o nal]: Dental restoration that fits around the tooth crown; covers cusps and buccal and/or lingual surfaces. Examples include crowns.
- **Extraoral examination**: Exam of structures of the head and neck outside of the oral cavity.

Extrusion of a tooth: Overeruption of a tooth (beyond the occlusal plane): longer than adjacent teeth in the ideal arch. Also called supraeruption.

F

Facet [FAS it] or [fah SET] **(on a tooth)**: Polished, smooth flat area of enamel due to tooth-to-tooth wearing away of enamel.

Facial [FAY shal]: Associated with, or toward, the face.

- **Facial artery**: Branch of external carotid artery with four branches to the face and oral structures: ascending palatine to soft palate, pharynx, and palatine tonsil, submental artery to floor of mouth, labial arteries to lips, and lateral nasal and angular arteries to face near nose and lips.
- **Facial bones**: Bones of the skull that underlie the skin of the face.
- **Facial nerves and vessels**: CN VII has sensory (chorda tympani) branches providing taste to anterior two third of tongue, motor branches to most muscles of facial expression, and secretory fibers to sublingual and submandibular salivary glands. Accompanied by facial vessels via antegonial notch.
- **Facial surface**: Surface of a tooth toward the face, or toward the cheeks (also called buccal) or lips (also called labial surface).
- **Facial view**: View of the facial surface of a tooth.

Fascia [FASH e ah]: Bands of connective tissue between anatomic structures like muscles, glands, and fat.

Fauces [FAW seez]: Opening from the mouth to the oropharynx; posterior boundary of the oral cavity.

Federation Dentaire Internationale (FDI notation system): System used in many countries to identify each tooth: using numbers 1 to 8 to denote each of the eight permanent and primary quadrants, plus 1 to 8 to denote each tooth within the quadrant. Also called World Dental Federation notation.

Fibrous capsule: Tube of connective tissue enclosing the mandibular condyle, disc, and articular fossa, thereby limiting the movement of the TMJ.

Filiform papilla [FIL i form pah PILL a]: Fine hairlike projections found on the dorsal surface of the anterior two thirds of the tongue.

First premolars: Type of premolar located closest to the midline in each quadrant.

First molars: Type of molar located closest to the midline in each quadrant.

Fissure: Cleft at the depth of some tooth grooves, which is a site for future decay.

Fixed dental prosthesis [pros THEE sis]: Tooth restoration that replaces missing teeth and cannot be readily removed from the mouth. Also called a bridge.

Flexion [FLEK shen]: Extreme curvature of a root. Also called dilaceration.

Floor of mouth: Mucosal covered, inferior boundary of the oral cavity.

Flowable resin: Flowable form of resin that mechanically attaches to microscopic irregularities formed after roughening (etching) the enamel with acid.

Fluoride [FLOOR ide]: Mineral that, when taken up into enamel in appropriate concentrations, increases resistance to breakdown of mineralized tooth surfaces by caries-forming acids.

Fluorosis [Floor O sis]: Condition caused by exposure of forming enamel to excessive amounts of fluoride (such as found in some drinking water); results in discolored or pitted enamel surfaces.

Focal hypoplasia [hi poe PLAY zhah]: Incomplete development of enamel in a localized area, possibly due to an infection of the pulp and surrounding tissues of the primary tooth it replaces; results in discolored spot on the enamel. Also called Turner hypoplasia.

Foliate papillae [FO li et pah PILL eye]: Large red, leaflike projections on the lateral surfaces of the tongue; they contain taste buds.

Foramen [fo RAY men]; plural **foramina** [fo RAM in ah]: Opening, hole, or passage, especially through bone, or into the pulp of a tooth.

- **Foramen cecum** [SEE cum]: Pair of small circular openings in the center of the terminal sulcus on the top surface of the tongue; is remnant of thyroglossal duct.

Foramen magnum [MAG num]: Large opening for passage of spinal cord through occipital bone from brain.
Foramen ovale [o VAL ee]: Oval-shaped opening in sphenoid bone for passage of mandibular division branches of CN V.
Foramen rotundum: Round opening for passage of maxillary division branches of CN V.

Fordyce granules [FOR dice]: Small yellowish, irregular spots in some persons on the buccal mucosa posterior to the commissure; are misplaced intraoral sebaceous glands.

Forensic [for EN sik]: Branch of medicine using scientific knowledge for solving crimes.
Forensic anthropology: Involves studying evidence similar to that studied by an anthropologist.
Forensic dentistry: Branch of forensic medicine that deals with oral structures including teeth in the legal or judicial system. Also called forensic odontology.
Forensic engineering: Involves studying vehicles (cars, planes) involved in a crime.
Forensic jurisprudence: Applying medical knowledge to questions of civil and criminal law.
Forensic odontology [o don TOL e jee]: Branch of forensic medicine that deals with oral structures including teeth in the legal or judicial system. Also called forensic dentistry.
Forensic pathology: Using analysis of tissues for solving crimes.
Forensic psychiatry: Using legal opinions obtained from psychiatric experts for solving crimes.

Fornix, vestibular [FOR niks]: Lowest part of the vestibule of the oral cavity that is next to the mandible and the highest part next to the maxillae, where food may collect.

Fossa [FAH sah](plural **fossae** [FAH see]**)**: Small depressions, as seen on the occlusal surfaces of posterior teeth.

Fourth molar: (Anomaly) An extra (fourth) molar forms distal to the third molar. Also called a paramolar or a distomolar.

Fovea palatini [FO ve ah pal a TEEN ee]: Pair of pits in soft palate near the midline, just posterior to vibrating line; are openings of minor palatine mucous glands.

Framework, of removable dental prosthesis [pros THEE sis]: Portion of the prosthesis that adapts to adjacent tooth structure to provide stability and retention. Includes a major connector, clasps and rest seats.

Free gingiva: Collar of tissue that surrounds each tooth with a potential space (sulcus) between it and the tooth; includes free gingiva and interdental papillae. Also called unattached gingiva.

Free gingival fibers: Tissue fibers that are directed from cementum into free gingiva.

Free gingival groove: Subtle groove visible in some persons that separates free gingiva from attached gingiva.

Free gingiva margin: Most coronal crest of the free gingiva; in a healthy mouth, forms a scalloped appearance.

Freeway space: Space normally occurring between opposing upper and lower teeth when a person in an erect posture makes no conscious effort to open or close the mouth. Also called interocclusal rest space.

Fremitus [FREM i tus]: Palpable or visible movement of a tooth during occlusal contact.

Frenum [FREE num] or **frenulum**: Flap of tissue connecting gingival tissues to the tongue (lingual frenum), lips (labial frenum), or cheeks (buccal frenum).

Frontal bone: Skull bone with sinuses that forms the forehead and eyebrow region.

Full mouth rehabilitation: Dental treatment involving restoration of all teeth with new occlusal surfaces (like crowns) to improve occlusion.

Functional occlusion, of the jaws: Tooth contacts during normal function, that is, chewing and swallowing.

Fungiform papilla [FUN ji form pa PILL a]: Scattered, deep red projections on the dorsal surface of the tongue, especially near the tip; appear mushroomlike in cross-section.

Furcal region [FUR cal]: Space (in health filled with bone) between multiple roots**.**

Furcation [fur CAY shun]: Part of a multirooted tooth where the trunk divides into separate roots. Called a bifurcation between two roots and a trifurcation between three roots.

Furcation involvement: Advancement in the depth of gingival pockets that extend into the root furcation, an area extremely dif cult to keep clean. **Grade I** furcation involvement is barely detectable; **grade II** is when a probe can hook the furcation roof; and **grade II** is where the probe can pass through the furcation.

Fusion (of teeth) [FYOO zhen]: (Anomaly) Union of two adjacent forming teeth; tooth crown is doubled in width, but the root has separate pulp chambers and root canals.

G

Gemination [jem e NAY shen]: (Anomaly) Splitting of a single forming tooth; tooth crown is doubled but there is a common root canal. Also called twinning.

Genial spines [JEE ne al]: Pair of small bony spines on either side of the midline on the internal surface of the mandible; is attachment of genioglossus muscle (to tongue) and geniohyoid muscle (to hyoid bone).

Geniohyoid muscle [JEEN I o HI oyd]: Pair of suprahyoid muscles that help depress and retract the mandible. Attach from genial tubercles of mandible to hyoid bone.

Gingiva [JIN ji vah]: Soft tissue overlying the bone that surrounds tooth roots.
Gingival embrasure: Space between teeth, in health filled with the interdental papilla. Also called interproximal space.
Gingival f oor (of tooth preparation): Floor of a proximal box; wall closest to the gingiva.
Gingival margin: Edge of gingiva closest to the biting surface of the tooth, also called free gingival margin.
Gingival recession: Loss of gingival tissue usually with loss of underlying bone resulting in exposure of anatomic root.
Gingival sulcus [SUL kuss]: Potential space between free gingiva and the tooth.

Gingivectomy [jin ni VEK tah me]: Removal of gingiva using a scalpel or laser.

Gingivitis [jin ji VIE tis]: Inflammation (disease) of the gingiva.

Ginglymoarthrodial joint [Jing gle mo ar THRO di al]: Movement of the temporomandibular joint that combines both hinge (rotational) and gliding (translational) movements.

Glass ionomer [eye ON a mer]: Tooth-colored restorative filling material used to restore preparations made when removing dental decay especially on the root; it bonds chemically to dentin and contains fluoride.

Glenoid fossa: Articular fossa where head of condyle articulates with the disc in the TMJ.

Glossopalatine arch [GLOS o PAL a tine]: An arch of tissue with pillars around the fauces in the back of the oral cavity; extends from the palate toward the tongue. Also called the anterior arch.

Glossopharyngeal nerve [GLOS oh fa rin JEE al]: CN IX leaves skull via jugular foramen; provides taste and general sensation to the posterior one third of the tongue, motor fibers to pharynx muscles, and secretory fibers to the parotid gland.

Grade I, II, o r III fur cation involvement: **Grade I** furcation involvement is barely detectable; **grade II** is when a probe can hook the furcation roof; and **grade III** is where the probe can pass through the furcation.

Granuloma: Mass of chronic inflammatory tissue enclosed within a fibrous capsule.

Greater palatine foramen: Passage through posterior hard palate for greater palatine nerves to provide feeling to the mucosa between posterior teeth.

Greater palatine nerve: Branch of maxillary division of CN V enters palate via greater palatine foramen to provide feeling to the posterior palatal tissues.

Groove: Linear channel in enamel, often found in the depth of a sulcus.

Group function: Occlusal relationship where multiple teeth (not just canines) contact evenly when the mandible moves laterally toward that side.

Guided tissue regeneration: Treating a periodontal defect with a membrane or matrix for regenerative cells to migrate from the periodontal ligament and bone.

Gutta-percha [GUT ta PERCH a]: Filling material used to fill root canals after removal of diseased pulp.

H

Hamular notch: Depression between the maxillary tuberosity and adjacent pterygoid process of the sphenoid bone (with its projection called the pterygoid hamulus).

Hard palate: Portion of palate with underlying bone (of the maxillae and palatine bones).

Height of contour: Greatest bulge of a crown contour where a line drawn parallel to the midroot axis line touches the crown outline. Also called crest of curvature.

Hinge axis line: Imaginary line around which the two condyles of the mandible rotate. Also called horizontal axis or terminal hinge axis.

Hinge movement, of TMJ: Rotary movement of the TMJ that occurs around a hinge axis line.

Horizontal overlap: Incisal edges of maxillary incisors are labial to edges of mandibular incisors. Also called normal overjet.

Hutchinson incisor: Abnormal incisor shape resulting from exposure to congenital syphilis during incisor formation. Incisors are shaped like a screwdriver, broad cervically and narrowing incisally, with a notched incisal edge.

Hyoid bone [HI oid]: Single U-shaped bone in neck above the laryngeal prominence (Adam's apple); is attachment of supra- and infrahyoid muscles.

Hypercementosis [HI per see men TOE sis]: (Anomaly) Excessive formation of cementum on a tooth root after eruption.

Hyperplasia [HI per PLAY zhah]: Abnormal increase in the number of normal cells resulting in increased volume.

Hypodontia [HI po DON shia]: Partial congenital absence of teeth, primary or permanent.

Hypoglossal nerves [HI po GLOS al]: CN XII exits brain via hypoglossal canals; motor branches to muscles of the tongue.

Hypophysial fossa [hi po FIZ ee al]: Depression on superior surface of sphenoid bone where body of the pituitary gland (called the hypophysis) fits. Also called sella turcica.

Hypoplasia [HI poe PLAY zhah]: Form of dysplasia; incomplete formation of a tissue (tooth).

I

Impacted tooth: Tooth fails to erupt due to a mechanical obstruction; can be confirmed using radiographs.

Implant (dental): Artificial root embedded in the jawbone for an implant-supported dental restoration.

Incipient decay: Early stages of decay formation.

Incisal [in SIGH sal]: Referring to the cutting edge of anterior teeth.

- **Incisal cusp tip**: Tip of the cusp of a canine, the only type of tooth with an incisal edge and a cusp.
- **Incisal edge or ridge**: Cutting surface or edge of anterior teeth.
- **Incisal embrasure** [em BRAY zhur]: Space between adjacent anterior teeth that is incisal to the proximal contact; where the floss fits before using it.
- **Incisal guidance**: Ideal relationship of overlapping anterior teeth where, during protrusion of the mandible, the incisal edges of mandibular incisors glide against the lingual surfaces of maxillary incisors resulting in a separation of posterior teeth. Is a type of anterior guidance or anterior protected articulation.
- **Incisal view**: View of the tooth looking toward the incisal surface, viewing along the midroot axis.

Incising: Contacting of incisal edges together as when biting off a piece of food.

Incisive nerve (and vessels): Terminal branch of inferior alveolar nerve branches of the mandibular division of CN V; nerves to mandibular anterior teeth. Accompanied by incisive vessels.

Incisive fossa: Shallow depression over maxillary lateral incisors, just medial to canine eminence.

Incisive foramen: Opening located on anterior part of intermaxillary suture for passage of branches of the incisal branches of the maxillary division of CN V to the palatal tissue between anterior teeth; along with incisive vessels.

Incisive papilla: Small rounded elevation of tissue on the midline of the palate just lingual to the central incisors; covers the incisive foramen where nasopalatine nerve enters the mouth.

Incisors [in SIGH serz]: Class of teeth designed to incise food; located first and second from the midline in each quadrant: central incisor and then a lateral incisor.

Inferior (and preface infra): Located below or beneath; lower than.

- **Inferior alveolar nerves (and associated vessels)**: Branches of mandibular division of CN V enter mandible via mandibular foramen and canal to reach mandibular teeth and associated structures. Accompanied by inferior alveolar vessels.
- **Inferior nasal conchae bone** [CONG kee], singular concha [KONG kah]: Pair of scroll-shaped bones in nasal cavity that increase mucous membrane area in nose for warm, moist air.
- **Infrahyoid muscle**: Group of muscles attaching to, and/or inferior to, the hyoid bone. Include omohyoid, sternohyoid, sternothyroid, and thyrohyoid muscles.
- **Infraocclusion**: Tooth that is abnormally short relative to the occlusal plane of adjacent teeth in the ideal arch. Also called infraversion.
- **Infraorbital fissure, canal, and foramen**: Passageway in floor of the eye orbit for infraorbital branches of the maxillary division of CN V. Branches into MSA and ASA branches.
- **Infraorbital nerve**: Branches of the maxillary division of CN V; passes via intraorbital canal where the MSA and ASA branches go to part of the first molar, premolars, and anterior teeth; terminal branches exit through infraorbital foramen onto the face.
- **Infratemporal space**: Space inferior to temporal bones and lateral to lateral pterygoid plate.

Infiltration, of anesthetic: Spreading out of numbing solution from the site of injection to adjacent tissue and even into some bones.

Infraversion [in fra VER zhun]: Tooth with occlusal surface positioned below the occlusal plane of adjacent teeth.

Inlay: Restoration constructed outside of the mouth; fits within the tooth preparation, but does not cover the cusp tips (as opposed to an onlay, which covers some cusps).

Insertion (of a muscle): Attachment of muscle to the bone that moves (such as its attachment to the moveable mandible).

Interdental papilla [pa PILL ah], plural **papillae** [pa PILL ee]: Collar of free gingiva which, in health, fills the interproximal space or gingival embrasure. Also called gingival papilla.

Intermaxillary suture: Immovable connection between the horizontal right and left palatine processes of the maxillae and horizontal plates of the palatine bones. Also called midpalatine suture.

Internal acoustic meatus [a KOO stik me A tus]: Passage of the facial nerve (CN VII) from brain into the petrous portion of the temporal bone.

Internal jugular vein [JUG yoo lar]: Vessels that drain blood from the face and jaws.

Internal oblique line [ob LEEK]: Inferior one fourth of the temporal crest; seen as an opaque line on a radiograph.

International numbering system: System used in many countries to identify each tooth: using numbers 1 to 8 to denote each of the 8 permanent and primary quadrants, plus 1 to 8 to denote each tooth within the quadrant. Also called World Dental Federation notation.

Interproximal space or embrasure: Space between teeth, in health filled with the interdental papilla. Also called gingival embrasure.

Intracoronal restoration [IN tra COR o nal]: Dental filling that is placed within a tooth preparation and does not cover cusps and does not cover buccal or lingual surfaces.

Intraoral examination: Examination of the structures within the oral cavity.

Irreversible pulpitis: Inflammation of the pulp that cannot be treated conservatively and requires removal of the pulp (such as with a root canal) to eliminate symptoms.

Isometric contraction: Muscle contraction while maintaining the muscle length; as when teeth touch but closing muscles continue to contract but can get no shorter.

Isotonic contraction: Muscles that become shorter in order to move a structure, such as muscles that are moving (raising) the mandible when closing the mouth.

J

Jaw relation: Bone-to-bone position of the mandible relative to the maxillae not influenced by the teeth touching. Also called maxillomandibular relationship.

Jugular foramen [JUHG yuh ler]: Passageway located lateral to the foramen magnum, between temporal and occipital bones, where blood from brain drains from brain through internal jugular vein; and the glossopharyngeal nerve (CN IX) passes.

Jugular vein, internal [JUHG yuh ler]: Vessels that carry blood from the brain toward heart; exits via jugular foramen.

Junctional epithelium: Band of tissue at the most apical portion of the gingival sulcus that attaches gingiva to cementum with specialized epithelial cells. Along with the connective tissue attachment, forms the dentogingival junction.

K

Keratinized epithelium or gingiva: Oral mucous membrane (gingiva and palate) that is covered by a dense fibrous connective tissue called keratin, which provides toughness.

L

Lactobacillus [LAK tow bah SIL us]: Type of acid-forming bacteria found in dental plaque.

Labial [LAY bee al]: Related to, or in proximity with, the lips.

Labial approach (of a tooth preparation): Removing proximal decay between anterior teeth by gaining access through the labial surface.

Labial nerves (and vessels): Nerve branches of CN V to the lips; accompanied by labial vessels.

Labial embrasure [em BRAY zhur]: Space between anterior teeth facial to the proximal contact.

Labial frenum [FREE num]: T in sheet of tissue at the midline that attaches the upper and lower lip to the mucosa covering the maxillae and mandible.

Labial surface: Anterior tooth surface closest to the lips. Also called facial surface.

Labiomental groove: Horizontal tissue groove between the lower lip and the chin; is the inferior border of the lower lip.

Labioversion [LAY bee o VER zhun]: Tooth that is positioned labially relative to the ideal parabolic arch form of other teeth.

Lacrimal bones [LAK ri mal]: Pair of small rectangular facial bones with depressions that hold tear glands next to inner eye orbit. Also spelled lachrymal.

Lambdoid suture: Immovable connection between the occipital and parietal bones shaped like the Greek letter lambda (λ).

Lamina dura: T e radiopaque (white) lining of the alveolus seen on a radiograph; is the compact bony layer called alveolar bone proper.

Laryngeal prominence [la RIN jee al] or [la rin JEE al]: In the neck, the bulge over the voice box.

Larynx [LAR inks]: Upper part of the air passage through the mouth to pharynx to lungs (through trachea) that contains the vocal cords; underlies the laryngeal prominence.

Lateral: Pertaining to, or situated at, the side.

Lateral excursion or translation: Mandible moves to the right or left (and slightly downward) as when chewing food.

Lateral incisor: Type of incisor located lateral to the central incisor in each quadrant.

Lateral ligament: T ickened ligament on lateral surface of fibrous capsule of TMJ that helps limit movement of the TMJ. Also called TMJ ligament.

Lateral pterygoid muscles: Chewing muscles that help move the mandible laterally when working one at a time; and when working together, they help protrude and depress the mandible; origin attaches to sphenoid bone, insertion on pterygoid fovea and articular disc.

Leeway space: Space normally provided for the smaller permanent premolars due to the wider primary molars they replace.

Leaf gauge: Device of varying thickness useful for stabilizing the mandible in a reproducible, neuromuscularly relaxed position.

Lesser palatine foramina: Pair of openings in palatal bones just lateral and posterior to the greater palatine foramen; passage for lesser palatine nerves to tonsils and soft palate. Also called middle and posterior palatine nerves.

Lesser palatine nerves: Pair of branches of the maxillary division of CN V that pass via lesser palatine foramina to the tonsils and soft palate.

Levator [le VA tor]: Acts to raise or elevate.

Levator anguli oris muscles: Pair of upper oral group of facial expression muscles that raise the angle of the lips, as in a smile.

Levator labii muscles: Pair of upper oral group of facial expression muscles that raise the upper lip.

Ligaments: Tough fibrous bands that connect bones; are pliant but cannot be stretched so they serve to prevent excessive movement in joints like the TMJ.

Linea alba [LIN e a AL ba]: Horizontal white line in some people on the mucosa of the cheeks at the level where the upper and

lower teeth occlude, often ending at the commissural papule. May be associated with biting the cheek.

Line angle: Linear junction between two external tooth surfaces, or two cavity preparation walls.

Lingual [LIN gwal]: Related to, or in proximity with, the tongue.

- **Lingual approach (of a tooth preparation)**: Removing proximal decay between anterior teeth by gaining access through the lingual surface.
- **Lingual cusps**: On multicusped teeth, the lingually positioned cusp(s).
- **Lingual embrasure** [em BRAY zhur]: T e lingual portion of the space that surrounds the contact of two adjacent teeth.
- **Lingual fossa**: Shallow, broad depression between the mesial and distal marginal ridges on the lingual surfaces of many anterior teeth.
- **Lingual frenum** [FREE num]: T in sheet of tissue at the midline attaching the undersurface of the tongue to the floor of the mouth; may limit tongue movement.
- **Lingual groove**: Developmental groove located between two lingual cusps.
- **Lingual nerve (and vessels)**: Branch of mandibular division of CN V provides general sensation of touch and pain to anterior two thirds of tongue. Accompanied by lingual vessels.
- **Lingual ridge**: On the cusps of some canines, a ridge extending from its cusp tip onto its lingual surface; divides lingual surface into mesial and distal fossae.
- **Lingual root**: Most lingually positioned root on some teeth with multiple roots.
- **Lingual surface**: Tooth surface closest to the tongue. On teeth in upper arch next to the palate, also called palatal surface.

Lingula [LING gyoo la]: Tongue-shaped projection of bone just anterior and slightly superior to the mandibular foramen; attachment of sphenomandibular ligament.

Linguoversion [LING gwo VUR zhun]: Tooth that is positioned lingually relative to the ideal parabolic arch form of other teeth.

Lips: Two fleshy parts of the face that surround the opening of the mouth; together form the anterior boundary of the oral cavity.

Lobes, developmental: Primary growth centers of the tooth that form major morphological structures of the crown.

Local anesthetic [AN es THET ik]: Drug that can be injected into tissues or around nerves to prevent feeling pain by inhibiting nerve conduction.

Long buccal nerve: Branch of mandibular division of CN V; provides feeling to the cheek and gingiva buccal to mandibular molars. Also called buccinator nerve.

Luxation, of mandible [luk SAY shun]: When opening the mouth too far, the condyles of the mandible and discs may slip out of the articular fossae forward beyond the articular eminences; if muscles contract, the mouth may lock open and in pain. Also called condylar subluxation.

Lymph nodes [LIMF]: Small nodules where tissue fluids outside of blood vessels are collected and filtered and returned to blood vessels via the lymph system.

M

Macrodontia [MAK re DON sha]: Very large but normally shaped teeth.

Major connector: Portion of the framework that connects the right and left halves of a removable dental prosthesis.

Malar [MAY lar]: Related to cheek or cheek bone.

Malocclusion [mal ahk KLOO zhun]: Literally "bad" occlusion; a deviation from ideal occlusion due to improper alignment of teeth within an arch, or lack of harmony between sizes of the upper and lower jaws.

Mamelons [MAM ah lonz]: T ree bumps of enamel found on the incisal ridges of many newly erupted incisors; form from three facial developmental lobes.

Mandible [MAN di b'l]: Lower jawbone.

Mandibular [man DIB yoo ler]: Referring to the lower jawbone or mandible.

- **Mandibular arch**: Teeth in the lower jawbones that form an arch shape.
- **Mandibular condyle** [KON dile]: In the TMJ, the two rounded superior processes of the mandible that articulate into the articular fossae of the temporal bones in the TMJ.
- **Mandibular deviation**: Direction that the mandible takes when closing from a relaxed position into a maximal intercuspal position after premature contacts deflect the mandible.
- **Mandibular foramen**: Prominent opening on medial surface of the mandibular ramus inferior to the sigmoid notch and centered anteroposteriorly; passage for inferior alveolar branches of the mandibular division of CN V (and accompanying inferior alveolar vessels) to all lower teeth and some adjacent gingiva.
- **Mandibular fossa**: In the TMJ, a shallow concavity in each temporal bone that includes the articular fossa where the mandibular condyles articulate.
- **Mandibular lateral translation**: Bodily movement of the mandible from side to side.
- **Mandibular nerve (and vessels)**: Division III nerve branches of CN V that exit the skull via foramen ovale; sensory branches to lower teeth and surrounding structures; motor branches to muscles of mastication (masseteric, posterior and anterior temporal nerves, and medial and lateral pterygoid nerves). Vessels accompany these nerves.
- **Mandibular torus, plural tori** [TOR eye]: Bulbous enlargement of bone seen as a mass beneath thin mucous membrane on the medial sides of the mandible near the premolar roots; may be inherited. Is a type of exostosis.

Marginal ridges: Ridges that form the mesial and distal borders of the lingual surfaces on anterior teeth and the mesial and distal borders of occlusal surfaces on posterior teeth.

Marginal ridge grooves: Grooves that cross over some marginal ridges, often appearing as a continuation of the central groove.

Masseter muscle [MASS se ter] or [mass SEE ter]: A pair of superficial muscles of mastication that powerfully close the mouth; origin on zygomatic arch and insertion on the lateral surface of mandibular angle.

Mastication [mass ti KAY shun]: Chewing of food.

Mastoid process: Process of temporal bone located inferiorly and posteriorly to each mandibular fossa; is attachment of sternocleidomastoid muscle of the neck.

Maxilla [mak SILL a], plural maxillae [MACK si lee]: Paired facial bones with sinuses that contain the upper teeth in alveolar processes. Also, each has a nasofrontal process (of nose), zygomatic process (of cheek bone), and palatal process (forming part of hard palate).

Maxillary [MACK si lair ee]: Related to the upper jawbones.

- **Maxillary arch**: Teeth in the upper jawbones (maxillae) that form an arch shape.
- **Maxillary artery**: Branch of external carotid artery whose branches provide blood to the upper and lower teeth and surrounding structures.
- **Maxillary nerves**: Division II nerve branches of CN V exit skull via foramen rotundum; then accompanied by maxillary vessel branches to upper teeth and surrounding structures.

Maxillary sinus: Hollow space within each maxilla that opens into the nasal cavity.

Maxillary tuberosity [too be ROSS i tee]: Firm tissue over a bulge of bone posterior to maxillary third molar.

Maxillary vein: Vessels that drain blood from the pterygoid plexus.

Maximal intercuspal position (abbreviated **MIP**): Tooth-to-tooth relationship of teeth when they come together into their best fitting together of cusps into opposing tooth fossae. Also called maximal intercuspation. Used to be called centric occlusion.

Medial [ME dee al]: Surface toward the midline (or median) plane of the body. Do not confuse with mesial, which is toward the midline of the dental arch.

Medial pterygoid muscles: Pair of muscles of mastication that elevate the mandible; origin is mostly on medial surface of lateral pterygoid plate and insertion on medial surface of mandibular angle.

Median plane: Longitudinal plane that divides the body into right and left halves. Also called midsagittal plane.

Mediolateral curve: Curve formed by connecting the buccal and lingual cusps of posterior teeth of the same type on the right and left sides of an arch; the curve is convex in the upper arch and concave in the lower arch. Also called the curve of Wilson.

Melanin pigmentation [MEL a nin]: Dark brown to black pigment found in the gingiva (and skin) of persons with dark colored skin.

Mental: Associated with the chin.

Mental nerves and vessels: Terminal branch of inferior alveolar nerve that exits mandible via mental foramen to facial gingiva of anterior teeth and of premolars and skin of lower lip and chin where it is accompanied by mental vessels.

Mental foramen: Hole in the external surface of the mandible near the root apex of the second premolar; passage of mental nerve to chin.

Mentalis muscles [men TA lis]: Lower oral group of facial expression muscles in the chin.

Mental protuberance: Single small bulge of bone centered on the midline of the external surface of the mandible; between and superior to the two mental tubercles.

Mental spines: Slight projections in the middle, internal surface of the mandible, attachment of the genioglossus, and geniohyoid (suprahyoid) muscles.

Mental tubercles: Pair of bulges located on the external, inferior surface of the mandible on either side of the midline.

Mesial [MEE zi al] or preface **mesio-**: Related to the tooth surface nearer to the center of the dental arch; on the opposite side from the distal tooth surface.

Mesial cusp ridge: Cusp ridge that extends from a cusp tip toward the mesial.

Mesial root: On some two-rooted teeth, the root that is more mesial.

Mesial root depression: Depression on the mesial surface of a root.

Mesiobuccal (developmental) groove [MEE zee o BUCK k'l]: Developmental groove on five-cusp mandibular molars located between the mesiobuccal and distobuccal cusps.

Mesiobuccal root or cusp [MEE zee o BUCK k'l]: Root or cusp near the junction of the mesial and buccal surfaces.

Mesiolingual root or cusp [MEE zee o LING gwal]: Root or cusp near the junction of the mesial and lingual surfaces.

Mesiolingual groove: On mandibular first premolars, the groove between the mesial marginal ridge and the mesial ridge of the lingual cusp (or a triangular fossa groove that is directed toward the mesiolingual line angle).

Mesiodens [MEE zi oh denz]: Supernumerary tooth located between the maxillary central incisors; may be impacted.

Mesio-occlusion: Skeletal type of malocclusion where the mandible is too large or the maxillae are too small, or both. T is results in a protruded or prognathic chin profile. Also generally considered the same as Angle's class III occlusion.

Mesognathic occlusion [MEZ ug NATH thik]: Facial profile of person with class I occlusion where top half of face and mandible form a rather straight line. Same as orthognathic.

Metal ceramic restorations: Crowns that are made from cast metal and covered in part with tooth-colored ceramic porcelain to improve esthetics.

Microdontia [MIE kro DON sha]: Very small but normally shaped teeth.

Middle superior alveolar nerves abbreviated **MSA (and vessels)**: Branches of maxillary division of CN V that branch off of the infraorbital nerve while within the inferior orbital canal; pass through maxillary sinus toward maxillary premolars and part of the first molar and surrounding structures. Accompanied by MSA vessels.

Midline (of the d ental arch): Location between right and left central incisors (separating right and left quadrants).

Midpalatine suture: Immovable connection between the horizontal right and left palatine processes of the maxillae and horizontal plates of the palatine bones. Also called intermaxillary suture.

Midroot axis line: Imaginary line through the center of the tooth root.

Midsagittal plane [mid SAJ i t'l]: Longitudinal plane that divides the body into right and left halves. Also called median plane.

Mixed dentition: Dentition with a mix of permanent and primary teeth; normally occurs between the ages of about six through twelve.

Molars [MO lerz]: Class of teeth designed to chew food: located sixth, seventh, and eighth from the midline in each quadrant of the permanent dentition, a first molar, second molar then third molar, and located fourth and fifth from the midline in the primary dentition: a first molar, then second molar.

MSA: Abbreviation for middle superior alveolar nerves or vessels.

Mucocutaneous junction [MYOO koe kyoo TAY nee us]: External boundary of the vermilion border of the lips; the line denoting a junction between skin of the face and the vermilion border of the lips.

Mucogingival defects [MYOO ko JIN ji val]: Now identified as lack of attached keratinized gingiva, which can put the tooth at risk for accelerating gingival recession.

Mucogingival junction or line [MYOO ko JIN ji val]: Scalloped junction between attached gingiva and loosely attached alveolar mucosa.

Mucosa, oral [myoo KO za]: Moist mucous membrane that lines the oral cavity; some may be keratinized.

Motor nerve fibers: Type of efferent nerves fibers that provide stimulus from the brain to contract muscles.

Mulberry molars: Molars with occlusal surfaces shaped like a mulberry due to congenital syphilis during molar formation.

Muscles of facial expression: Muscles that move parts of the face to result in unique expressions of emotion; innervated by motor branches CN VII.

Muscles of mastication: Chewing muscles.

Mylohyoid [MY lo HI oyd]: Related to the molar region and the hyoid bone.

Mylohyoid groove: Small groove running inferior and anterior from the mandibular foramen for mylohyoid nerve.

Mylohyoid muscles: Pair of suprahyoid muscles that help to depress and retrude the mandible and elevate the floor of the mouth. T ey attach along the mylohyoid ridge on the internal surface of the mandible and the hyoid bone.

Mylohyoid nerve: Branch of mandibular division of CNV with motor fibers to the mylohyoid muscle.
Mylohyoid ridge: Ridge running inferior and anterior from the mandibular foramen; attachment of mylohyoid muscle.
Myofascial trigger points [MY o FASH i el]: Areas of hypersensitive fascia and muscles that can result from overuse of jaw muscles.

N

Nasal: Related to the nose.
Nasal nerves and vessels: Branches of the maxillary division of CN V to the nose accompanied by nasal vessels.
Nasal bones: Pair of facial bones forming the bridge of the nose.
Nasal conchae bone, inferior [CONG kee]: Pair of scroll-shaped bones within the nasal cavities that increase the surface area of mucosa to warm and moisten the air we breathe. Also called nasal turbinates.
Nasal septum: Bone separating the right and left halves of the nasal cavity; made up of vomer bone and a vertical process of the ethmoid bone.
Nasal turbinates, inferior: Pair of scroll-shaped bones within the nasal cavities that increase the surface area of mucosa to warm and moisten the air we breathe. Also called nasal conchae.
Nasofrontal process: Process of each maxilla that extends toward the frontal bone and helps form the bony support for the nose.
Nasolabial groove: Groove on the skin of the face between the side of the nostrils of the nose and the commissure of the lips; is the lateral border of the upper lip.
Nasopalatine nerve: Branch of maxillary division of CN V that enters the palate via incisive foramen to supply anterior palatal tissue.
Necrotic pulp: Death of pulpal tissue due to injury or disease; requires treatment that may include a root canal.
Nerves: Bundle of fibers that can transmit sensations (such as pain) to the central nervous system and brain, called afferent fibers, or can send messages from the brain (such as to move a muscle or for a gland to secrete) called efferent fibers.
Neurocranium [NOOR o CRAY ne um]: Bones of the skull that surround the brain.
Neutroclusion [NOO tro KLOO zhun]: Ideal class I occlusion.
Nonworking side: Side opposite that which the mandible moves toward when it moves laterally; when the mandible moves to the right, the left side is the nonworking side.

O

Oblique ridge [OB leek]: Ridge on the occlusal surface of most maxillary molars running diagonally (obliquely) from mesiolingual cusp toward the distobuccal cusp.
Occipital bone [ahk SIP eh tal]: Bone on posterior and inferior surface of braincase providing the articulating surface with uppermost vertebra of the spinal cord.
Occipital condyle: Articulating surface of occipital bone with vertebral column.
Occipitofrontalis muscle [ahk SIP I toe fron TAL is]: Muscle that draws back the scalp, wrinkling the forehead and raising eyebrows, as in surprise.
Occlusal [ahk KLOO zal]: Related to the chewing surfaces of posterior teeth.
Occlusal table: Chewing surface of posterior teeth bounded by continuous marginal ridges and mesial and distal cusp ridges. Also called occlusal surface.
Occlusal crown outline: Entire outline of a posterior tooth when viewed from the occlusal view, larger than the occlusal surface or occlusal table.
Occlusal device: Removable artificial occlusal surface used to stabilize occlusion, reduce pain from TMDs, and prevent tooth wear. Also called bite guard or night guard.
Occlusal embrasure [em BRAY zhur]: Occlusal part of the space that surrounds the proximal contacts between adjacent teeth; where the floss fits before using it.
Occlusal equilibration: Process where dentist modifies occlusal and incisal surfaces by grinding away enamel at sites of undesirable tooth contact prematurities.
Occlusal surface: Chewing surface of posterior teeth bounded by the joining of two marginal ridges and all mesial and distal cusp ridges. Also called occlusal table.
Occlusal trauma: Injury to the periodontium from damaging occlusal forces.
Occlusion [ah KLOO zhun] (of teeth): Relationship of upper and lower teeth when they come in contact.
Oculomotor nerves [AHK yu lo MO tor]: CN III, to orbital muscles for eye movement.
Odontoblasts [oh DON toe blasts]: Specialized cells lining the pulp chamber that produce dentin.
Olfactory nerve [ol FAk toe ree]: CN I; for smell; passes through cribriform plate of ethmoid bone.
Omohyoid muscle [O mo HY oyd]: Pair of infrahyoid muscles that help to depress the mandible by stabilizing the hyoid bone.
Onlay: Restoration constructed outside of the mouth and covers some or all cusps. An inlay does not cover cusps.
Open bite: When posterior teeth are closed tightly together, there is a vertical space between opposing anterior teeth.
Operative dentistry: Branch of dentistry that includes diagnosis and restoration of defects of hard tissues of individual teeth.
Operculum [o PUR kyuh lum]: Flap of tissue overlying a partially erupted tooth, especially third molars. When irritated, can cause pericoronitis.
Ophthalmic nerve: Division 1 of CN V, exits skull via superior orbital fissure to skin of forehead and eyebrows.
Optic nerves: CN II, for sight.
Oral cavity: Space of the mouth bounded anteriorly by the lips, laterally by the cheeks, superiorly by the palate, inferiorly by the floor of the mouth, and posteriorly by the fauces; can be divided into oral vestibule and oral cavity proper.
Oral cavity proper: Only the inner part of the oral cavity: bounded anteriorly and laterally by the teeth and alveolar processes.
Oral vestibule [VEST i byool]: Only the outer part of the oral cavity: between the teeth with alveolar processes and the lips or cheeks.
Orbicularis [or BIK u LAR is]: Round, surrounding, like an orbit.
Orbicularis oculi muscle [AH kyoo le]: Muscle of facial expression surrounding the eye, squints the eyes.
Orbicularis oris muscle: Muscle of facial expression surrounding the mouth; closes the lips around a straw.
Origin, of muscle: Fixed end of attachment of a muscle, to the bone that does not move (opposite end from the insertion).
Oropharynx [Or o FAR inks]: Part of the throat (behind the fauces) where air passes to the lungs and food passes to the esophagus.
Orthodontic treatment: Bodily movement of teeth to improve tooth alignment, function and esthetics.
Orthognathic profile [OR thog NATH ik]: Facial profile of person with class I occlusion where top half of face and mandible form a rather straight line. Same as mesognathic.
Orthognathic surgery [OR thog NATH ik]: Surgical reshaping of jawbones to correct severe skeletal malocclusions.

Osseointegration, of dental implant: [AH see o in te GRAY shun]: Process whereby living bone and implant root become fused.
Outline form: External shape of a tooth preparation where prepared tooth meets unprepared tooth.
Overbite, normal: When posterior teeth are in tightest occlusion, less than one third of the incisal edges of mandibular incisors are hidden from view by overlapping maxillary incisors. Also called normal vertical overlap.
Overbite, severe: Excess overlap of maxillary incisors beyond the incisal edges of mandibular incisors by well over one third. Also called deep bite.
Overjet, normal: When posterior teeth are in tightest occlusion, incisal edges of maxillary incisors are labial to edges of mandibular incisors. Also called normal horizontal overlap.
Overjet, severe: When posterior teeth are in tightest occlusion, maxillary incisors are considerably anterior to mandibular incisors as in class II occlusal relationships.

P

Palatal root (gingival) grooves: (Anomaly) Deep groove extending onto the lingual root surface.
Palatal surface: Surface of upper teeth closest to the palate. Also called lingual surface.
Palate: Roof of the oral cavity; can be divided into hard palate (with underlying bone) and soft palate (with no underlying bone).
Palatine [PAL a tine]: Related to the palate.
- **Palatine arches**: Two arches of tissue supported by pillars in the back of the oral cavity: posterior palatine arch (called pharyngopalatine arch from the palate to pharynx) and anterior palatine arch (called glossopalatine arch from the palate to tongue).
- **Palatine bones**: Paired bones that form the posterior one fourth of the hard palate; (anterior portion formed by the horizontal palatine processes of the maxillae).
- **Palatine process**: Bony plates of each maxilla that, with the palatine bone, form the hard palate.
- **Palatine raphe** [RAY fee]: Slightly elevate ridge of firm tissue running anteroposteriorly along the midline of the hard palate, over the intermaxillary suture.
- **Palatine rugae** [ROO guy] or [ROO jee]: Series of palatal tissue elevations or wrinkles located just posterior to the maxillary anterior teeth.
- **Palatine tonsils**: Two lymphatic tissue masses located between the anterior and posterior pillars in the back of the oral cavity.
- **Palatine torus**: Smooth, benign, hereditary, rounded bulge of bone near the midline on the palate.

Palatomaxillary space [PAL ah toe MACK si lar ee]: Space between the pterygoid process of sphenoid bone and posterior wall of the maxillae that includes vertical processes of the palatine bone; also called pterygopalatine space.
Palatomaxillary suture [PAL ah toe MACK si lar ee]: Immovable connection between the palatal processes of the maxillae and the palatal bones. Also called transverse palatine suture.
Palmer Notation System: System used to identify each tooth used in many orthodontic of ces: using different bracket shapes to denote each quadrant and numbers 1 to 8 or letters A to E to denote each tooth in that permanent or primary quadrant.
Palpebral nerve [PAL pe bral]: Branches of maxillary division of CN V to the eyelid.
Panoramic radiograph: Radiograph that obtains an image of the entire jawbones and surrounding structures. Also called a Panorex.
Panorex, of the mouth: Single large x-ray of the maxillae and mandible and their teeth.
Parafunctional contacts of teeth: Undesirable opposing tooth contacts not involved in chewing or swallowing.
Paramolar [PAIR a MO lar]: (Anomaly) Extra or supernumerary molar.
Paranasal sinuses: Hollow spaces located within bones around the nasal passages: maxillae, frontal, ethmoid, and sphenoid bones.
Parietal bone [par EYE i t'l]: Paired bones that surround the brain superiorly, laterally, and posteriorly.
Parotid [pah RAH tid]: Related to the parotid gland.
- **Parotid duct**: Duct of the parotid salivary gland that empties through the parotid papilla on each cheek. Also called Stensen duct.
- **Parotid salivary glands**: Located anterior and inferior to each ear lobe; produce watery (serous) saliva.
- **Parotid nodes**: Lymph nodes located over the parotid gland that drain fluid from the adjacent scalp, ear, cheek, and eyelids.
- **Parotid papilla** [pa ROT id pah PILL a]: Rounded flap of tissue on the mucosa of the cheek next to the maxillary first and second molars; it covers the opening of the parotid duct (Stensen duct).

Partial anodontia [an oh DON she ah]: (Anomaly) Partial congenital absence of teeth.
Peg-shaped lateral incisors: (Anomaly) Maxillary lateral incisor crowns shaped like a cone.
Percussion sensitivity: Diagnostic test that confirms tooth sensitivity by tapping on the occlusal surface with a dental instrument.
Periapical disease: Spread of infection from the dental pulp through the apical foramina into the tissues surrounding the apex.
Periapical radiolucence: Dark area surrounding the root apex on a radiograph indicating bone destruction.
Pericoronitis [pair i KOR o ni tis]: Inflammation of the tissue around the crown (including operculum) of a partially erupted third (last) molar.
Peri-implant tissues: Hard and soft tissues surrounding a dental implant.
Peri-implant mucositis: Inflammation of the keratinized tissue around an implant (compare to gingivitis around a tooth).
Peri-implantitis: Inflammation with destruction of supporting bone around an implant (compare to periodontitis around a tooth).
Perikymata [pear ee KY mah tah]: Minute horizontal ridges seen on the enamel of newly the erupted teeth, formed by layers of enamel formation.
Periodontal [Pair ee o DON tal]: Refers to tissues surrounding and supporting the tooth**.**
- **Periodontal disease**: Pathologic processes affecting the periodontium, most often gingivitis and periodontitis.
- **Periodontal ligament**: T in band of tissue connecting cementum of the tooth root and alveolar bone. Abbreviated PDL. Includes apical, oblique, horizontal, and alveolar crest fibers.
- **Periodontal charting**: Part of the patient's dental record that includes measurements considered critical for evaluating the periodontal health of a patient.
- **Periodontal f ap**: Surgery involving folding back a superficial layer of tissue to provide access to treat deeper diseased tissues and bone.
- **Periodontal pocket**: Pathological deepening of a gingival sulcus in the presence of periodontal disease.
- **Periodontal probe**: Instrument designed to measure the depth of a gingival sulcus.

Periodontal scaling and root planing [PLAY ning]: Removal of calculus and some cementum to smooth the root using specially designed dental instruments.

Periodontics [Pair ee o DON tix]: Dental specialty that includes the prevention, diagnosis, and treatment of diseases of supporting tissues of teeth or their substitutes (dental implants).

Periodontist: Dentist who specializes in the prevention, diagnosis, and treatment of periodontal disease and in the placement of dental implants.

Periodontitis [Pair ee o don TI tis]: Inflammation of the tissues of the periodontium.

Periodontium [pair ee o DON she um]: T e tissues that surround, envelop, or embed the teeth.

Peristalsis [Pair i STOL sis]: Waves of contraction of the walls of the digestive tract that move food through for digestion.

Permanent dentition [den TISH un]: The adult set of teeth that begin erupting around age six. Also called secondary dentition.

Petrotympanic fissure [PEE tro tim PAN ik]: Fissure that separates the mandibular fossa into the anterior 2/3 called the articular fossa and the posterior 1/3. Is the passage of the chorda tympani branch for CN VII providing taste to anterior 2/3 of tongue.

Petrous portion: Part of temporal bone containing the auditory canal and bones of inner ear: malleus, incus, and stapes. Contains openings for CV VII (facial nerve) from brain via internal acoustic meatus and out into infratemporal space through the stylomastoid foramen.

Pharyngopalatine arch [fah RING go PAL a tine]: Arch of tissue with pillars next to the fauces in the back of the oral cavity; extends from the palate toward the pharynx. Also called the posterior arch.

Pharynx [FAR inks]: Superior part of digestive tube between the nasal passageways or oral cavity and the esophagus.

Philtrum [FIL trum]: Depression in the midline of the upper lip running from the nose to the tubercle of the upper lip.

Phonetics [fo NE tiks]: Articulation of sounds and speech.

Physiological rest position: Position of the mandible when all of its supporting muscles are in their resting position. Also called vertical dimension of rest position.

Piriform [PEER I form]: Pear-shaped opening in the skull into the nasal passageways.

Pit: A pinpoint depression, often found at the junction or end of grooves on tooth enamel. When defective, it is the site for decay.

Pit and fissure decay (caries): Decay that begins in caries-prone enamels defects (pits and fissures) where enamel is incompletely fused.

Planes of the he ad: Midline sections of the head: midsagittal (median) plane runs anteroposteriorly; frontal plane runs mediolaterally.

Plaque, dental [PLAK]: Organized layer mostly of microorganisms that adhere to teeth and contribute to gingival and periodontal diseases as well as tooth decay. Also known as biofilm.

Plaque index or score [PLAK]: Using a disclosing solution or dye to stain plaque in order to determine the percentage of sites on a tooth crown with plaque divided by the total number of sites measured.

Platysma muscle [pla TIZ mah]: Broad muscle over the anterior and lateral neck; contracts during a grimace.

Plica fimbriata [PLY kah fim bri AH tah]: Delicate fringes of mucous membrane on each side of the frenum on ventral surface of tongue.

Point angle: Point formed at the junction of three external tooth surfaces, or three adjacent cavity preparation walls.

Pontic: False tooth (teeth) that is part of a fixed partial denture that is attached to the crowns (retainers) on adjacent (abutment) teeth.

Porcelain [PORS e lin]: Tooth-colored, ceramic material used to construct inlays, onlays, and crowns.

Porcelain veneer [ven NEER]: Tooth-colored material that covers the facial surface of a tooth.

Post and core restorations: Restoration consisting of a post that fits snuggly into a prepared root canal and a core that reproduces a crown preparation in order to retain an artificial crown.

Posterior: Toward the rear of the mouth, head, or body.

Posterior fibers, temporalis muscle: Horizontal fibers of the temporalis chewing muscles that retrude the mandible.

Posterior superior alveolar nerves (and vessels), abbreviated **PSA**: Branches of maxillary division of CN V via alveolar canals to the pulp of most adult maxillary molar roots and adjacent tissues. Accompanied by PSA vessels.

Posterior teeth: Teeth in the back of the mouth, namely, premolars and molars.

Postmortem examination: Record made of the condition of the oral structures and teeth (including restorations) on a deceased person: used to identify an unrecognizable body.

Premature contact: Teeth that occlude before other teeth in the mouth.

Premaxilla: Embryonic part of the maxillae that contain the incisors; may be separated from the rest of the maxillae by suture lines in some adults.

Premolars: Class of permanent teeth designed to chew food, located fourth and fifth from the midline in each quadrant, anterior to molars: a first premolar and second premolar.

Preparation (of a tooth): Tooth structure removed from a tooth in order to remove decay and place a dental restoration.

Prevention, patient education: Teaching a person about techniques used to prevent dental disease including brushing, flossing, and diet, in an effort to reduce dental disease in that person.

Primary cusp triangle: Triangular shape formed by connecting the cusp tips of the three largest cusps of maxillary molars: the mesiolingual (or lingual), mesiobuccal, and distobuccal.

Primary dentition (teeth): First set of 20 teeth that erupt between about 6 months and 2 years, also called deciduous dentition.

Primate spaces: Space provided for permanent premolars due to growth of jawbones and wider primary molars compared to their replacement teeth, permanent premolars.

Probing depth: Depth of a gingival sulcus, or of the pocket depth in the presence of periodontal disease as determined with a measuring device called a periodontal probe.

Procerus [pro SE rus]: Muscle from bridge of nose that lowers the medial eyebrow and wrinkles the nose.

Prognathic profile [prog NATH ik]: Facial profile of person with class III occlusion where the mandible is forward relative to the upper part of the face.

Prophylaxis, dental [pro fi LAX es]: Professional cleaning of the teeth; in order to prevent gingivitis and decay.

Proprioceptive nerve fibers [PRO pree o SEP tiv]: Nerve fibers that permit the unconscious perception of posture and position in space; they help to coordinate jaw movement.

Prosthesis [pros THEE sis]: Artificial replacement of a missing body part.

Prosthodontics [pros tha DON tiks]: Branch of dentistry involves the treatment of patients with missing or deficient teeth; can be fixed or removable prosthodontics.

Protrude; protrusive movement or protrusion: Moving the mandible anteriorly relative to the maxillae.

Protuberance [pro TOO ber ahns]: Bulge, as of a bone.

Proximal [PROK si mal]: Related to the tooth surfaces where adjacent teeth normally touch one another; includes both mesial and distal surfaces.

- **Proximal box (of tooth preparation)**: Boxlike design of a tooth preparation between posterior teeth.
- **Proximal contact areas**: Area on a tooth where it touches an adjacent tooth in the arch.
- **Proximal height of contour**: Greatest bulge of the proximal contour, which, in ideal alignment, is the location of the proximal contact area.
- **Proximal surface**: Tooth surface (mesial or distal) that, in ideal alignment, touches an adjacent tooth.

Proximal views: View of the surface of a handheld tooth that in the mouth would contact an adjacent tooth.

PSA: Abbreviation for posterior superior alveolar nerves or vessels.

Pseudopocket [SOO doe pah ket]: Literally a "false" pocket. A gingival sulcus depth of 4 mm or deeper due to an overgrowth of gingiva, even in the absence of periodontitis.

Pterygoid [TER i goyd]: Related to the processes of bone that extend inferiorly from the body of the sphenoid bone and are posterior to the maxillae.

- **Pterygoid fossa**: Depression between the two pterygoid plates (lateral and medial); attachment for medial pterygoid muscles.
- **Pterygoid fovea**: Small depression on the anterior neck of the ramus just inferior to the condyle; is area of attachment for each lateral pterygoid muscle.
- **Pterygoid hamulus**: Hooklike projection off of the medial pterygoid plates**.**
- **Pterygoid muscles**: Two pairs of muscles of mastication that move the mandible: medial pterygoids elevate the mandible; lateral pterygoids move the mandible forward (protrude) or move the mandible laterally.
- **Pterygoid processes**: Paired projections of bone off of the sphenoid bone inferiorly; one is medial and one is lateral.
- **Pterygoid plates or lamina**: Two thin plates of each pterygoid process: lateral plates are the attachment of lateral pterygoid muscles, and the medial plates, surrounding a pterygoid fossa, are the attachment for medial pterygoid muscles.
- **Pterygoid plexus of veins**: Network of thin-walled veins medial to the upper ramus of the mandible and susceptible to being hit by a syringe needle during certain injections. Collect blood from the face and jaws.

Pterygomandibular fold [TER I go man DIB you lar]: Fold of tissue that connects the retromolar pad of the mandible with the pterygoid process just posterior to the maxillary tuberosity; a landmark for anesthetic placement.

Pterygopalatine nerve: First branch of the maxillary division of CN V; its branches go to posterior and anterior palatal tissues and adjacent gingiva.

Pterygopalatine space: Space between the pterygoid process of sphenoid bone and posterior wall of the maxillae that includes vertical processes of the palatine bone; also called palatomaxillary space.

Pulp: Tissue in the middle of the tooth containing nerves and vessels and surrounded by dentin.

- **Pulp canal**: Portion of the pulp cavity located within the roots of teeth, also called root canal.
- **Pulp canal configurations**: Shapes of pulp cavities: type I, one canal and one foramen; type II, two canals join into one foramen; type III, two canals and two foramina; and type IV, one canal but splits into two foramina.
- **Pulp cap**: Dental procedure using a dental material (calcium hydroxide) designed to stimulate the formation of new dentin. T e dental material can be placed directly over exposed pulp (a direct pulp cap) or over a thin layer of remaining dentin (called an indirect pulp cap).
- **Pulp cavity**: Space in the inner portion of the tooth filled with nerves and blood supply to the tooth made up of pulp canal(s) and a pulp chamber.
- **Pulp chamber**: Wider portion of the pulp cavity closer to the crown.
- **Pulp horns**: Incisal or occlusal extensions on the roof of the pulp chamber under cusps or mamelons.

Pulpal f oor: Horizontal floor (or wall) of a tooth preparation that is over the pulp.

Pulpitis, irreversible: Inflammation of the pulp that cannot be resolved or reversed; is often painful and requires removal of the diseased pulp tissue (endodontics).

Q

Quadrant: One quarter of the teeth in the mouth, that is, the teeth in the right or left side of each arch.

R

Radiograph (of a tooth or jaw): X-ray image that shows internal structures. Can be a bitewing (showing coronal part of tooth), periapical (showing crowns and roots), or panoramic (Panorex) showing structures within the entire jaws.

Radiolucent [ray dee o LOOS ent]: Relatively dark areas on an x-ray image indicating an area of lower density, soft tissue–like pulp and gingiva.

Radiopaque [ray dee o PAKE]: Relatively whiter areas on an x-ray image indicating areas of higher density, hard tissues like enamel and bone.

Ramus [RAY mus], plural **rami** [RAY mie]: Two broad vertical processes of the mandible that include the mandibular condyles and coronoid processes.

Recession, gingival: Loss of gingiva usually with loss of underlying bone resulting in exposure of the anatomic root.

Rehabilitation, full mouth: Extensive dental treatment requiring that all teeth are restored with new occlusal surfaces in order to improve the occlusion.

Remineralization: Uptake of minerals into tooth tissues that had previously lost minerals.

Removable dental prosthesis [pros THEE sis]: Tooth restoration that replaces missing teeth and can be readily removed from the mouth; like a removable partial denture or a complete denture.

Regenerative periodontal surgery: Surgery intended to form new cementum, bone, and a new functionally oriented ligament.

Reparative dentin: Irregular dentin laid down in response to an irritant like decay or drilling to remove decay. Also called tertiary dentin.

Resective periodontal surgery: Surgery involving removal and/or recontouring of gingiva, supporting bone or root.

Resistance form (of a t ooth preparation): Design of the preparation that assures resistance to breaking of remaining tooth and restorative material.

Resorption of bone: Bone loss.

Restorations (in a t ooth): Using dental materials (such as amalgam or composite) to fill in tooth preparations that were designed when decay was removed. Restorations can be direct (placed directly in a tooth preparation) or indirect (formed outside of mouth and then attached/cemented to the tooth.

Restorative dentistry: Branch of dentistry that involves diagnosis and restoration of defects of hard tooth structure of individual teeth plus replacement of lost teeth.

Rest seats (of removable dental prosthesis): Part of framework that adapts into small occlusal crown depressions to keep the denture from seating too firmly into soft tissue.

Rest space, interocclusal: Space between the mandibular and maxillary teeth when all of its supporting muscles are in their resting position. T is space occurs when the mandible is in physiological rest position. Vertical dimension of rest position is the distance between a selected point on the mandible and one on the maxilla during physiological rest.

Retained deciduous or primary tooth: Primary tooth that is not lost at the expected time and is kept in the mouth into adulthood, which often happens when no replacement tooth is forming to replace it.

Retainer: Crown restoration that covers the supporting teeth (abutment teeth) and is attached to the replacement tooth (pontics) for a fixed dental prosthesis.

Retention form (of a tooth preparation): Design of the preparation that prevents the restoration from dislodging.

Retentive grooves: Linear depressions within line angles of a tooth preparation; designed to keep the restoration from being dislodged.

Retro (as prefix): Back or behind.

- **Retrognathic profile** [RET rog NATH ik]: Facial profile of person with class II occlusion where the mandible is posterior relative to the upper part of the face.
- **Retromolar fossa**: Roughened, shallow bony depression distal to the last mandibular molar and bounded medially by the temporal crest and laterally by the external oblique ridge.
- **Retromolar pad**: Elevation of moveable tissue distal to the mandibular third molar; landmark for placing anesthetic.
- **Retromolar triangle**: Lowest, most anterior, horizontal part of the retromolar fossa; attachment of cheek (buccinator) muscle.
- **Retromylohyoid curtain** [REH tro my lo HI oid]: Wall of mucous membrane along the medial posterior mandible; extends between the anterior pillar of the fauces and the pterygomandibular fold; important landmark when constructing a complete mandibular denture.

Retrude; retrusive movement: Retracting or pulling back; mandible moves posteriorly.

Reverse articulation: Mandibular posterior teeth are considerably too far buccal or too far lingual compared to opposing maxillary posterior teeth. Also called posterior crossbite.

Risorius muscle: Pair of upper oral group of facial expression muscles that retract or spread the angles of the mouth.

Root: Anatomic root of a tooth.

- **Root axis line**: Imaginary line through the middle of a tooth root.
- **Root canal**: Portion of the pulp cavity located within the roots of teeth. Also called pulp canal. Also refers to the filling placed within the pulp canals by a dentist.
- **Root depression**: Longitudinal depressions found on the surfaces of some root; if deep, may indicate two pulp canals within that root.
- **Root resection**: Removal of periodontally involved root on a multirooted tooth.
- **Root resorption**: Gradual loss of root structure. In primary teeth, this provides room for eruption of the underlying permanent tooth.
- **Root surface decay**: Decay that forms on the cementum of the anatomic root.
- **Root-to-crown ratio**: Root length divided by crown length; is an indicator for the usefulness of that tooth as an abutment for a bridge.
- **Root of the tongue**: Posterior third of tongue, not usually visible during an oral exam.
- **Root trunk**: T e part of a multirooted tooth closest to the crown that has not yet split.

S

Sagittal suture: Immovable attachment between the right and left parietal bones along the midsagittal line.

Salivary glands: Glands with ducts that secrete saliva: thin serous saliva; or thick, mucous saliva; or mixed.

Scalers, dental [SKAY lerz]: Dental instruments designed to remove hard deposits off of teeth.

Scaling and root planing [SKA ling] [PLAY ning]: Removal of calculus and plaque from the crown and root as well as smoothing of the root to remove bacterial toxins; done in a dental of ce, using specially designed instruments.

Sclera [SKLER a]: Tough fibrous covering of the white portion of the eyeball.

Sealant: A flowable restorative material that flows into and then hardens to attach into the roughened acid-etched enamel around pits and fissures; used to prevent decay.

Second molars: Type of molar located one tooth behind (distal to) the first molar in each quadrant.

Second premolars: Type of premolar located just behind (distal to) the first premolar.

Secondary dentin: Normally maturing dentin laid down throughout life.

Secondary dentition: Adult set of teeth that begin erupting around age six. Also called permanent dentition.

Secretory nerves: Specialized efferent nerves that can send messages to glands to secrete, such as salivary glands to secrete saliva.

Self cleansing: Parts of a tooth exposed to the natural rubbing action of the lips, cheeks, and tongue.

Sella turcica [SELL a TER si ka]: Depression on superior surface of sphenoid bone where pituitary gland fits. Also called hypophyseal fossa.

Septum: Partition that separates, such as the nasal septum that separates the right and left nasal cavities.

Shovel-shaped incisors: Incisors with prominent lingual marginal ridges resembling a shovel; occur most frequently in Asian, Mongoloid, Arctic, and Native American populations.

Sialolith [si AL o lith]: Calcified blockage in a salivary gland duct.

Sigmoid notch [SIG moyd]: Depression between the condylar and coronoid processes of each mandibular ramus. Also called semilunar or mandibular notch.

Skull: Bones of the face and neurocranium.

Slot preparation: Box-shaped conservative tooth preparation designed to remove decay located between adjacent posterior teeth; does not extend into occlusal grooves.

Sluiceways: Depressions and grooves on the occlusal surfaces of teeth that allow food to squeeze out to maximize chewing. Also called spillways.

Smooth surface decay: Decay that occurs on smooth surfaces of the anatomic.

Soft palate: Posterior, moveable part of palate with no underlying bone; separated from hard palate by the vibrating line.

Sphenoidal spine: Two projection of bone on the inferior surface of the sphenoid bone where the sphenomandibular ligaments attach.

Sphenoid bone: Complex singular bone with sinuses forming part of the floor and walls of braincase, has areas of attachment for three major pairs of muscles of mastication, and has passageways for branches of the important fifth cranial nerve to the teeth.

Sphenomandibular ligament [SFE no man DIB yoo lar]: Ligament from angular spine of sphenoid bone to the lingula of mandible; helps limit movement of TMJ.

Spillways: Depressions and grooves on the occlusal surfaces of teeth that allow food to squeeze out to maximize chewing. Also called sluiceways.

Spinal accessory nerves: CN XI helps with neck movements.

Squamosal suture [skwa MO sal SOO chur]: Junction of squamous (fish scale–shaped) portion of the temporal bones and the parietal bones.

Stensen duct: Duct of the parotid salivary gland that empties through the parotid papilla on each cheek. Also called parotid duct.

Sensory nerve fibers: Type of afferent nerve fibers that convey impulses such as felling, touch, and pain from peripheral organs like skin or mucosa.

Sternocleidomastoid muscle [stur no kly doe MAS toyd]: Neck muscle attaching from mastoid process of temporal bone to the sternum (breast bone) and clavicle (collarbone). Many lymph nodes surround the area of this muscle.

Sternohyoid muscle: Pair of infrahyoid muscles that help to depress and retract the mandible; attaches on hyoid bone and sternum.

Sternothyroid muscle: Pair of neck muscles below the hyoid bone attaching from the thyroid cartilage to the sternum; acts to depress the larynx.

Sternum [STUR num]: Breast bone.

Streptococcus mutans [strep tah KOK us MU tanz]: Type of acid-forming bacteria prevalent in dental plaque (or biofilm) that contributes to dental decay.

Stuart groove: Groove or depression located between the transverse ridge and the portion of the oblique ridge located on the mesiolingual cusp of a four-cusped maxillary molar.

Stylohyoid muscle: Pair of suprahyoid muscles that help to depress and retract the mandible; attach from hyoid bone to the styloid process of the temporal bone.

Styloid process: T in bony processes on inferior surface of temporal bone; attachment of stylomandibular ligament and stylohyoid muscle.

Stylomandibular ligament [STY lo man DIB you lar]: Ligament from styloid process of temporal bones to the posterior border of the angle of the mandible; limits movement of TMJ.

Stylomastoid foramen [STY lo MAS toyd]: Passageway of facial nerve (CN VII) out of petrous portion of temporal bone into infratemporal space.

Sub (prefix): Under or beneath; similar to infra.

Subgingival: Located within the gingival sulcus or pocket.

Sublingual: Under the tongue.

Sublingual caruncle [KAR ung k'l]: Pair of bulges on either side of the lingual frenum at junction of right and left sublingual folds; has opening of submandibular duct, carrying saliva from mandibular salivary glands.

Sublingual folds: Fold of tissue on each side of the floor of the mouth from the first molar region to the lingual frenum; contain duct openings from underlying sublingual salivary gland.

Sublingual fossa: Broad shallow depression on medial surface of mandible, superior to mylohyoid ridge; location of sublingual salivary glands.

Sublingual salivary gland: Located under sublingual fold; secretes predominantly thick, mucous saliva.

Subluxation, condylar [sub luk SA shun]: When opening the mouth too far, the condyles of the mandible may slip out of the articular fossae beyond the articular eminences; if muscles contract, may cause the mouth to lock open. Also called luxation.

Submandibular: Beneath or lower part of the mandible.

Submandibular fossa: Broad shallow fossa on medial surfaces of the mandible just inferior to the mylohyoid ridge; location of submandibular salivary gland.

Submandibular nodes: Chain of lymph nodes over the submandibular gland, medial and anterior to the angle of the mandible, that drain fluid from all maxillary and mandibular teeth, and much of the oral cavity.

Submandibular salivary glands: Pair of salivary glands located just inferior to mylohyoid ridge in a submandibular fossa producing mostly thinner (serous) and some mucous type of saliva via Wharton duct or submandibular duct.

Submental artery: Blood vessels that accompany the mental nerve through the mental foramen of the mandible to the chin and lower lip.

Submental nodes: Group of lymph nodes located just lingual to the mandibular symphysis area (midline); drains into the submandibular nodes.

Succedaneous teeth [suk seh DAY nee ous]: T e 20 permanent teeth (incisors, canines, and premolars) that replace (succeed) the 20 primary teeth.

Sulcular groove: V-shaped depression formed by the continuation of the sulcuses of adjacent posterior teeth in a quadrant.

Sulcus [SUL kuss]: V-shaped depression or valley evident between buccal and lingual cusps of a posterior tooth.

Superior orbital fissure: Passageway in superior surface of eye orbit for the ophthalmic nerve branch of CN V.

Supernumerary tooth [soo per NOO mir a ree]: (Anomaly) Tooth that forms in excess to the normal number of teeth in that quadrant.

Suppuration [sup ur RAY shun]: Formation or discharge of pus, which is also called exudate.

Supplemental grooves: Secondary, shallow, irregular grooves in the enamel that vary greatly from tooth to tooth.

Supra (prefix): Located above or over, higher or upper.

Supraeruption: Tooth that is overerupted: with a higher occlusal surface than adjacent teeth in the ideal arch. Also called extrusion.

Supragingival: Coronal to the gingiva; not in the gingival sulcus.

Suprahyoid muscles: Group of muscles attaching to, and superior to, the hyoid bone, including stylohyoid, digastric, mylohyoid, and geniohyoid muscles.

Suture line [SOO chur]: Line of immoveable union of adjoining skull bones.

Symphysis [SIM fi sis]: Fibrocartilaginous joint connecting opposing bony surfaces that grew together.

Synovial f uid [si NO vee al]: Slippery fluid that lubricates and nourishes the fibrous covering surrounding the TMJ.

Synovial cavities [si NO vee al]: In the TMJ, upper (above the disc) and lower (below the disc) joint spaces lubricated by synovial fluid.

T

Talon cusp: (Anomaly) Maxillary or mandibular anterior tooth crown has a projection on its lingual surface shaped like the claw of a bird of prey.

Tartar: Another name for dental calculus.

Taurodontia [TOR o DON shah]: (Anomaly) Molar that has a very long pulp chamber without constriction near the cementoenamel junction.

Temporal: Region of the skull above the ear**.**

Temporal bones: Paired skull bones over the ears that form part of the cheek bone, part of the TMJ, and attachment of temporalis chewing muscle.

Temporal crest: Ridge of bone on the mandible from tip of coronoid process extending onto the medial surface of the ramus toward the third molar region; attachment of temporalis muscle.

Temporal fossa: Large, shallow depression located primarily in the temporal bone where the temporalis muscles attach.

Temporalis muscle [tem po RA lis]: Fan-shaped muscle of chewing with anterior (vertical) fibers that elevate the mandible and posterior (horizontal) fibers that retrude the mandible; origin is the temporal fossa and insertion is ramus and temporal crest of mandible.

Temporomandibular joint (abbreviated **TMJ**) [TEM po ro man DIB yu lar]: Articulation between the mandible and the two temporal bones; the only free movement articulation in the head.

Temporomandibular disorders (abbreviated **TMDs**): Dysfunction of the TMJ.

Terminal hinge axis: T e imaginary line around which the two condyles of the mandible rotate. Also called hinge axis line or horizontal axis.

Terminal sulcus (of tongue): Shallow groove, just posterior to the circumvallate papillae, that separates the body of the tongue (anterior two thirds) from the root (posterior one third).

Tetracycline [te tra SY kleen] **stain**: Discoloration of teeth caused by exposure to tetracycline antibiotics during time of tooth formation: by the mother during pregnancy, or by the young child during enamel formation of adult teeth.

T ird molars: Type of permanent tooth located eighth from the midline (last) in each arch, also called a wisdom tooth.

T yroid gland: Butterfly-shaped gland near midline of neck below the Adam's apple; produces regulating hormones.

Tinnitus [ti NI tis]: Ringing in the ears.

Tongue [TUNG]: Moveable organ in the floor of mouth that functions in eating, tasting, and speaking; it can be divided into a body (visible during an oral examination) and a root.

Torsiversion [TOR si VUR zhun]: Tooth that is twisted or rotated around its axis relative to ideal alignment.

Torus (palatine or mandibular): Smooth, benign, hereditary, rounded bulge of bone. Palatine torus is near the midline on the palate; mandibular is on the medial surface of the mandible.

Trabecular bone: Less dense bone of the mandible sandwiched between the more dense outer and inner layers of cortical plates. Also called cancellous or spongy bone.

Transillumination: Use of a light source directed through proximal anterior tooth structure to detect decay.

Translational movement (of TMJ): Bodily movement of the entire mandible forward or from side to side.

Transverse groove of the o blique ridge: Groove that extends across the oblique ridge of some maxillary molars connecting the central pit to the distal pit.

Transverse palatine suture: Immovable connection between the palatal processes of the maxillae and the palatal bones. Also called palatomaxillary suture.

Transverse ridge: Ridge transversing the tooth from a buccal cusp to a lingual cusp, comprised of two connecting triangular ridges.

Triangular fossa [FAH sah]: Somewhat triangular-shaped depressions surrounding mesial and distal pits on some posterior teeth; may also contain small triangular grooves.

Triangular ridge: Ridge of a posterior tooth that extends from a cusp tip toward the depression or sulcus near the middle of the occlusal surface.

Trifurcation, root: Separation of a root into three roots.

Trigeminal nerve [tri JEM i nal]: Fifth cranial nerve (CN V) is the major sensory nerve of the face and scalp; with maxillary and mandibular branches to all of the teeth and surrounding periodontium. It has three divisions: I (ophthalmic), II (maxillary), and III (mandibular).

Trismus [TRIZ mus]: Spasm of chewing muscles associated with dif culty opening the mouth or locking of the jaws.

Trunk, of tooth: Coronal portion of a tooth root that has not yet split into multiple roots.

Tubercle [TOO ber k'l]: (Anomaly) Small rounded projection (or small extra cusp) on a tooth; also a nodule of tissue in the center of the fleshy part of the upper lip.

Tuberculum intermedium [too BUR kyoo lum - in ter MEE di um]: An anomaly where an accessory enamel projection appears like a sixth cusp, on a mandibular first molar located between the two lingual cusps.

Tuberculum sextum [too BUR kyoo lum - SEKS tum]: An anomaly where an accessory enamel projection appears like a sixth cusp on a mandibular first molar, located on the distal marginal ridge between the distal cusp and distolingual cusp.

Tug-back: Perceived resistance of the tip of an explorer when removed from a carious pit or fissure.

Turner hypoplasia (Turner's tooth) [hi poe PLA zhah]: Defect in a permanent tooth formation usually caused from an infection of the pulp and surrounding tissues of the primary tooth it replaces. Also called focal hypoplasia.

Twinning: (Anomaly) Splitting of a single forming tooth; tooth crown is doubled but there is a common root canal. Also called gemination.

Types of teeth: Classification that distinguishes different teeth within a class: incisors have two types, a central and lateral; premolars have a first and second; and molars have a first, second, and third.

U

Ultrasonic instrumentation: Instruments with high-frequency vibrations used to dislodge calculus and break apart bacterial cell walls.

Unattached gingiva: Collar of tissue that surrounds each tooth with a potential space (sulcus) between it and the tooth; includes free gingiva and interdental papillae. Also called free gingiva.

Unerupted tooth: Tooth that is not yet visible in the mouth, but has been confirmed to be present in the jawbones using radiographs.

Universal Numbering System: System endorsed by the American Dental Association to identify each tooth: using numbers 1 to 32 for permanent tooth and letters A to T for primary teeth.

Uvula [YOU view la]: Small fleshy structure hanging from the center of the posterior border of the soft palate.

V

Vagus [VAY gus] **nerve**: CN X to pharynx and laryngeal movements and digestive tract.

Ventral of tongue: Inferior or undersurface surface of the tongue.

Vermilion border: Reddish-colored zone of the lips where traditionally women placed lipstick; this zone of tissue is bounded internally by the wet line and externally by the mucocutaneous junction.

Vertical dimension of occlusion: Vertical distance between a selected point on the mandible and a selected point on a maxilla.

Vertical overlap, normal: When viewed facially, a small portion of the incisal edges of mandibular incisors are hidden from view by overlapping maxillary incisors. Also called normal overbite.

Vestibule [VEST I byool]: Part of the oral cavity between the teeth with supporting alveolar bone and the lips or cheeks.

Vibrating line: Junction of the hard and moveable soft palate; seen when a person forcefully says "AH," which moves the soft but not the hard palate.

Vomer bone: Single midline bone separating right and left nasal cavities; forms nasal septum along with vertical plate of ethmoid bone.

W

Wet line: Junction between the outer vermilion borders of the lips, which are usually dry, and the inner, smooth, moist mucosa. Also called wet–dry line.

Wharton duct: Ducts of the submandibular salivary gland that empty into the mouth through openings in the caruncles next to the lingual frenum. Also called submandibular ducts.

WinID program: Computer-based program used to compare postmortem (after death) and antemortem (before death) dental findings for identifying unknown victims of a crime or accident.

Wisdom teeth: Another name for third molars, located eighth from the midline (last) in each arch of the permanent dentition.

Working side: T e side toward which the mandible moves when it moves laterally; when the mandible moves to the right, the right side is the working side since cusps of opposing teeth line up cusp tip to cusp tip. T e opposite side is the nonworking side.

World Dental Federation Notation: System used in many countries to identify each tooth: using numbers 1 to 8 to denote each of the 8 permanent and primary quadrants, plus 1 to 8 to denote each tooth within the quadrant. Also called Federation Dentaire Internationale System or International Numbering System.

X

Xerostomia [zir e STO me a]: Dry mouth due to reduced enamel flow.

Z

Zirconia: New generation of tooth-colored, translucent, and biocompatible dental material used to construct crowns.

Zygomatic [ZIE go MA tik]: Related to the cheek bone.

Zygomatic arch: Arched "cheek" bone formed by the zygomatic bone and processes of the temporal bones and maxillae. Is attachment of the masseter chewing muscle.

Zygomatic bones: Paired facial bones that form part of the prominence of each cheek. Also called malar bones.

Zygomatic nerve: Paired branches of the maxillary division of CN V with branches to the skin of the temporal region and lower part of orbit.

Zygomatic process: Processes of the temporal bone and of the maxillae that joins each zygomatic bone to form the zygomatic arch (of cheek).

Zygomaticus muscle: Two pairs of upper oral group muscles of facial expression; major and minor: help to deepen the nasolabial fold in sadness.

Index

Page numbers in italics indicate figure and page numbers followed by 't' indicate table.

A
Abducens nerve, 429t
Abfraction, 326
Abnormal crown morphology
  accessory cusps, 342–343, 344, 345
  fusion, 341, 342, 343
  gemination/twinning, 340, 342
  Hutchinson's incisors, 341, 343
  peg-shaped lateral incisors, 340, 341
  shovel-shaped incisors, 345, 345
  third molar malformations, 340
  variations, 343, 345, 345
Abnormal root morphology
  concrescence, 346, 347
  dens in dente, 346, 347
  dilaceration, 346, 346, 347
  dwarfed roots, 347
  enamel pearls, 345, 346
  extra (accessory) roots, 347, 348, 349
  hypercementosis, 347, 348
  taurodontia, 345–346, 346
Abrasion, 354, 354
Abuse and neglect, forensic dentistry in, 364, 364, 365
Abutment teeth, defined, 330
Access openings, for endodontics, 259
Accessory, 347, 348
Acoustic, defined, 393
Acoustic meatus
  external, 406, 407
  internal, 436, 437
Aduld dentitions, 183 (See also Permanent teeth)
Afferent (sensory) nerves
  facial nerve, 436
  glossopharyngeal nerve, 438
  trigeminal nerve, 428
Air-abrasion system, 315
Alveolar artery
  anterior superior, 431
  middle superior, 431
Alveolar bone, 14, 15
Alveolar canals, 431, 432
Alveolar eminences, 401, 404
Alveolar mucosa, 219, 219, 220
Alveolar nerve
  anterior superior, 431, 432
  inferior alveolar, 433, 433–435, 434, 435
  middle superior, 431, 432
  posterior superior, 430–431, 432
Alveolar process, 400, 401, 401–402
Alveolar vein, inferior, 442
Alveolingual sulcus, 471
Alveolus (alveoli), 217
Amalgam, restoration materials, 308, 308
Ameloblasts, 47, 351
Amelogenesis imperfecta, 352, 352
American Academy of Forensic Sciences (AAFS), 359
Anatomic crown
  definition, 15
  morphology
    depression and grooves, 27–30, 28–31
    elevation and ridges, 21–27, 22–28
Anatomic root, morphology, 30–31, 31
Anesthetic injections
  anterior superior alveolar nerve, 431, 432
  greater palatine foramina, 430
  inferior alveolar nerve, 433, 433–435, 434, 435
  long buccal nerve, 433
  middle superior alveolar nerve, 431, 432
  nasopalatine nerve, 430, 462
  posterior superior alveolar nerve, 430–431, 432
  technique, 456
Angle, Edward H, 269
Angular artery, 441
Angular spine, 397, 398, 405
Ankylosis, 350, 351
Anodontia
  partial, 337, 337–338, 338
  total, 337
Anomalies (See also Dental anomalies)
  anodontia, 337–338, 337–338
  crown
    accessory cusps, 342–343, 344, 345
    fusion, 341, 342, 343
    gemination/twinning, 340, 342
    Hutchinson's incisors, 341, 343
    peg-shaped lateral incisors, 340, 341
    shovel-shaped incisors, 345, 345
    third molar malformations, 340
    variations, 343, 345, 345
  dentin dysplasia, 353, 353
  enamel dysplasia, 352, 353
  root
    accessory roots, 347, 347, 348
    concrescence, 346, 347
    dens in dente, 346
    dilaceration, 346, 346, 347
    dwarfed, 347
    hypercementosis, 347, 348
  supernumerary teeth (extra teeth), 338–340, 339, 340
  in tooth positions
    ankylosis, 350, 351
    impacted, 348, 350
    rotation, 350, 351
    transposition, 348, 350, 350
  tooth size, 343, 345
  unusual dentitions, 355, 355–356
Antemortem records
  for human identification, 362, 362
  in mass disasters, 368, 368
Anterior arch, 465
Anterior cranial fossa, 394
Anterior deprogramming, 293, 294
Anterior fibers (of temporalis muscle), 421
Anterior guidance, 283
Anterior protected articulation, 283
Anterior superior alveolar nerve, 431, 432
Anterior teeth, 436t
Anteroposterior curve, 33, 34
Anthropology, forensic, 359, 370, 371
Antrum, 399, 400
Aperture, defined, 401
Apical foramen, 256
Apical foramina, 31
Arteries, 405, 431, 434, 440–442, 440–442
  to mandible, 441
  to maxillae, 442
  to muscle, 442
Articular disc, 412–413, 413, 414
Articular eminence, 407, 411, 412, 412, 416
Articular fossa, 407, 411, 412, 412, 413, 416, 416
Articulation, long centric, 296
Articulator, 281
Ascending palatine artery, 441
Attached gingiva, 14, 15
Attachment loss
  defined, 228
  technique for measuring, 230, 230
Attrition, 354, 354
Auditory nerves, 429t
Auriculotemporal nerve, 432, 433

B
Behavior therapy, 288
Bennett's movement, 285
Bevels, 320
Bifurcation, root, 143
Bilaminar zone, 413, 414
Biofeedback, 288
Biologic width, of gingiva, 237
Bite mark analysis, 365–366, 366
Black, G.V., 310, 312, 333, 334
Bleeding on probing (BOP), 226–227, 230, 231
Bolus, 286
Bonding agents, 311
Bone (See Skull)
BOP (See Bleeding on probing (BOP))
Bruxism, 273
Buccal cusps, 270
Buccal, defined, 433
Buccal embrasure, 38
Buccal frenum, 455, 459
Buccal mucosa, 455, 456
Buccal nerve, local anesthetic technique, 433, 433, 434
Buccal ridge, 105, 106, 116
Buccal shelf, 405
Buccal surface, 270
Buccinator crest, 406, 425–426
Buccinator muscle, 433, 433
Buccinator nerve, local anesthetic technique, 433, 433

C
Calculus, defined, 216
Canal orifice, 250
Canine eminence, 397, 401
Canine fossa, 401
Canine guidance angle, 302t
Canine-protected articulation, 285
Canine-protected occlusion, 285
Canines
  arch traits, 82–85, 83, 85t–86t
  class traits, 80–82
  crown proportions, 82
  functions, 80
  general description, 78–95
  incisal ridges and cusp tips, 81–82, 82
  incisal view
    cingulum and marginal ridges, 91
    crown proportions, 90, 90
    incisal edge (cusp tip) contour, 90–91
    labial contour, 90, 91
    lingual ridge, 91

Canines (Continued)
labial contour, 82
labial view
canine morphology, 82, 84, 84t
cusp tip and incisal ridges, 83–84, 84–85
proximal contact areas, 84, 85, 85t
root contour, 85
shape and size, 84, 84–85
tooth proportions, 85
lingual view
cingulum, 85, 86, 87
marginal ridges, 87, 87
ridges and fossae, 85, 87
roots, 87
location of, 79–80
primary teeth
incisal view, 196, 197
labial view, 195–197, 197
lingual view, 195–197
proximal views, 194, 197
proximal views
canine outline, 87
cervical lines, 89
height of contour, 87, 88–89
incisal ridge and cusp tip, 87, 89
root shape and depressions, 88, 89, 89, 89t
roots, 81, 85, 89
size, 80
variations in, 92–93, 92–93
Capsular ligament, 414, 415
Carabelli cusp, 158, 162, 175, 176t, 254, 370, 373
Caries (See Dental caries)
Carotid artery, external, 441
Carotid canal, 407
Carving teeth
advice, 384
materials for, 381
maxillary central incisor, 382, 382–384, 383–386
wax carvings, 381, 382
Cast metal restorations, 308–309, 309
Cavosurface margins, 320, 324
Cementoblasts, 47
Cementodentinal junction, 13, 260, 260
Cementoenamel junction, 13
Cementum, 12–13
Centric relation (CR), 280–282, 280–282
Centric relation jaw recording, 293–296, 294, 295
Ceramic restorations, 309–310, 310, 330
inlay, 309–310
onlay, 309–310
Cervical chain of lymph nodes, 444
Cervical curvature, 179t, 180t
Cervical line
canines, 89, 197, 204
incisors
mandibular, 63, 69
maxillary, 61, 63
molar, 143, 143, 144, 147, 157
premolars, 99, 110, 122
primary teeth, 192, 193, 197, 202, 204
Cervical ridge, 25
Cervix of tooth, 34, 376
Chamfer, 330
Cheeks, oral examination of, 453, 454, 455
Chewing, 418–423 (See also Mastication)
Cingulum, incisors, 59, 67
Circumvallate papilla (papillae), 469, 470, 470
definition, 469
Civil litigation, forensic dentistry, 364, 364, 365
Clasps, of dental prosthesis, 332
Class I occlusion, 39, 40, 269–271, 270, 271, 274, 286
Class II occlusion, 273, 273–274, 274
Class III occlusion, 273–275, 274–275
Clavicle, 409, 424
Clenching, 287
Clinical attachment loss, 230, 230
Clinical crown, definition, 15
Clinical root, 15–16
Commissural papule, 455
Commissure, 453
Common facial vein, 443
Complete removable dental prosthesis, 307, 332, 332
Composite resin, 308
Concrescence, 346, 347
Condylar subluxation, 279
Condyle, defined, 393
Condyloid process, 405
Congenitally absent, 209
Connective tissue attachment, 220, 475
Conservative resin restoration, 315
Contact areas, proximal
canines, 84, 85, 196–197
incisors
mandibular, 66–67, 67t
maxillary, 57
molars
mandibular, 139, 143
maxillary, 157, 157t–158t
premolars, 100, 104, 113, 116
Conventional preparation, 310
Coronal sutures, 394
Coronoid, defined, 393
Coronoid process, 403
Corrugator supercilii muscle, 426
Cortical plate, 401, 401
Cranial nerves
abducent, 429t
auditory, 429t
facial, 429t
glossopharyngeal, 429t
hypoglossal, 429t
oculomotor, 429t
olfactory, 429t
optic, 429t
spinal accessory, 429t
trigeminal, 429t (See also Trigeminal nerve)
trochlear, 429t
vagus, 429t
Crepitation, 279
Crepitus, 302t
defined, 413
prevalence of, 414t
Crest, defined, 392
Crest of contour (See Height of contour)
Crest of curvature, 34–37, 35, 35t, 69
Cribriform plate, 395
Criminalistics, defined, 359
Crista galli, 395
Crossbite
anterior, 272, 272, 275, 275
posterior, 272, 272
Crown
anomalies
accessory cusps, 342–343, 344, 345
fusion, 341, 342, 343
gemination/twinning, 340, 342
Hutchinson's incisors, 341, 343
peg-shaped lateral incisors, 340, 341
shovel-shaped incisors, 345, 345
third molar malformations, 340
variations, 343, 345, 345
primary teeth
calcification, 187, 188
formation, 189
Crown calcification, primary teeth, 187, 188
Crown lengthening, 237
Curve of Spee, 33, 34, 298
Curve of Wilson, 34, 34, 142
Cusp of Carabelli, 158, 162, 175
Cusp ridges, 21, 22, 23
Cusp slopes, 81
Cusps (buccal), 270

D

Deciduous definition, 182–183
Deciduous teeth, 209 (See also Primary teeth)
Deep facial vein, 443
Definition (buccal), 433
Deglutition, 286
Dehiscence, root, 225, 225
Demineralization, 305
Dens in dente, 346, 347
Dental anomalies (See also Anomalies)
abrasion, 354, 354
accessory cusps, 342–343, 344, 345
ankylosis, 350, 351
attrition, 354, 354
dentin dysplasia
dentinogenesis imperfecta, 353, 353
tetracycline stain, 353, 353
enamel dysplasia
amelogenesis imperfecta, 352, 352
fever, 352, 352
fluorosis, 352, 352
focal hypoplasia, 352–353, 353
erosion, 354, 355
fusion, 341, 342, 343
gemination/twinning, 340, 342
Hutchinson incisors, 341, 343
mandibular premolar area, 326, 327, 327
maxillary incisor area, 338, 339
partial anodontia, 337, 337–338, 338
peg-shaped lateral incisors, 340, 341
shovel-shaped incisors, 345, 345
third molar area, 326, 326
third molar malformations, 340
tooth rotation, 350, 351
total anodontia, 337
transposition, 348, 350, 351
unerupted (impacted) teeth, 348, 350
unusual dentitions, 355, 355–356, 356
variations, 343, 345, 345
Dental calculus (tartar), defined, 240
Dental caries
class I, 312–316, 313–315
class II, 316–320, 317–321
class III, 321–323, 321–324
class IV, 324, 324–325, 325
class V, 325–327, 325–328
class VI, 328
Dental caries, spread pattern, 313
Dental formulae, 183
Dental implants, 244–245, 331, 332
Dental plaque, 305
defined, 216
in dental caries, 216
plaque index, 236
Dental prosthesis
complete removable, 332
fixed, 307, 330, 331
removable, 332
Dentin, 13
Dentin dysplasia
dentinogenesis imperfecta, 353, 353
tetracycline stain, 353, 353
Dentinoenamel junction, 13
Dentinogenesis imperfecta, 353, 353
Dentistry
operative, 307–308
restorative, 257, 258, 307–308
Dentition
mixed, 185
permanent (See Permanent teeth)
primary (See Primary teeth)
Depressor, defined, 418
Depressor septi nasi muscle, 426
Descending palatine artery, 403, 442
Developmental groove, 27, 28
Developmental lobes, canines, 41
Developmental lobes, incisors, 52

Developmental lobes, molars, 42
Developmental lobes, premolars, 98
Diastema, 36
Digastric muscles, 424, 426
Dilaceration, 346, 346, 347
Disasters, forensic dentistry
  antemortem records, 359
  case studies, 370–372, 371–372, 382
  dental identification, 367–370, 368–369
  forensic anthropology, 370, 371
  initial response, 367
  morgue operation, 367–370, 368–369
Dislocation, 279–280
Distal surface (defined), 33
Distal views, 376, 377, 378
Distobuccal root, 140, 160, 162, 162, 163, 231, 263
Distomolar, 338, 339
DNA analysis for humans, 360
Dorsum of tongue, 469–470, 469–470
Drawing teeth
  distal views, 376, 377, 378
  facial views, 376–377, 377
  incisal view, 377, 378–379
  lingual views, 377, 377
  materials needed, 375
  from memory, 379, 379–381
  mesial, 376, 377, 378
  outline, 375–376, 376–378
Dura, defined, 393
Dwarf root, 345, 347
Dysplasia
  dentin dysplasia, 353
  enamel dysplasia, 351–353

E

Eccentric occlusal, 303t
Efferent (motor) nerves, 428, 432, 436
Embrasure (buccal), 38
Embrasure spaces, 37–38, 38, 221
Eminence (defined), 392
Enamel, 12
Enamel dysplasia
  amelogenesis imperfecta, 352, 352
  fever, 352, 352
  fluorosis, 352, 352
Enamel extension, 143, 143, 239, 239
Enamel pearls, 239, 345, 346
Endodontics, 257–261
Endodontist, 258
End-to-end occlusion, 272
Envelope of motion, 292–293
Epithelium, 219, 220, 346, 473, 475
Erosion, 291, 305, 308, 326, 327, 354, 355
Eruption order, 189
Eruption, timing, 185
Esthetic restorative materials, 308, 309
Ethmoid bone, 395, 395–397
Exfoliation, 187, 189, 191
Exostosis, 224, 471
External acoustic meatus, 407, 451
External carotid artery, 440, 441, 441, 442
External oblique ridge, 405, 406
Extraoral examination
  eyes, 451
  general appearance, 450
  head, 450
  lips, 453–454, 454
  lymph nodes, 451–452, 453
  muscles of mastication, 450, 450–451
  neck, 451, 452
  salivary glands, 452, 452
  temporomandibular joint, 450, 451
Extruded, 365
Eyes, oral examination, 451

F

Facet, 54, 81, 147, 272, 273, 287
Facial artery, 441, 443, 444
Facial bones
  conchae (inferior nasal), 409
  hyoid, 409, 424
  lacrimal, 409
  mandible, 397, 403–405, 404–406
  maxillae, 397, 399–403, 400–402
  nasal, 408, 409
  palatine, 400, 402, 403
  vomer, 407, 407, 408
  zygomatic, 403, 403–404
Facial, defined, 17, 32
Facial expression, muscles of, 425, 425, 436, 438
Facial nerve, 424, 425, 429t, 436–438, 437
Facial veins, 442–443
Facial views, 376–377, 377
Fascia, 283, 287, 425
Fauces, 464, 465–466
Federation Dentaire Internationale (FDI system), 9, 10
Fibrous capsule, 278
Filiform papillae, 469, 470
Filling materials, 311, 328, 330
Final tooth preparation, 311, 311–312
Fissure, 28, 306, 306, 313, 392, 398, 399, 407, 412, 430, 436
Fixed dental prosthesis, 282, 307, 330, 331
Flexion, 177, 177
Floor of mouth, oral examination, 471–473, 471–473
Fluoride, 305, 307, 308, 316, 326–328, 352
Fluorosis, 352, 352
Focal hypoplasia, 353, 353–353
Foliate papillae, 470, 470
Foramen cecum, 470
Foramen magnum, 394, 438
Foramen ovale, 392, 398, 430, 432
Foramen rotundum, 392, 398, 430
Foramen spinosum, 398
Fordyce granules, 455, 456
Forensic anthropology, defined, 359
Forensic dentistry
  bite marks, 365–366, 366
  civil litigation, 364, 364, 365
  defined, 359
  forensic anthropology, 370, 371
  human identification, 359–360, 360–363, 362–363
  importance, 373
  mass disasters
    case studies, 370–372, 371–372
    initial response, 367
    preparation and training, 367
  morgue operations, 367–370, 368–369
Forensic engineering, defined, 359
Forensic jurisprudence, defined, 359
Forensic odontology, defined, 359
Forensic pathology, defined, 359
Forensic psychiatry, defined, 359
Forensics, general, 359
Fornix, defined, 449
Fossa (fossae)
  articular, 407, 411, 412, 412, 413
  canine, 401
  defined, 392
  hypophysial, 396, 398
  incisive, 401
  mandibular, 412, 414
  mandibular molars, 150, 150, 151
  maxillary molars, 166, 167, 167
  pterygoid, 397, 398
  retromolar, 406
  sublingual, 406
  submandibular, 406
  of teeth, incisors, 57, 59, 67
  temporal, 406, 406
Fourth molar, 338, 339
Fovea, defined, 392
Fovea palatini, 462, 465
Framework, of dental prosthesis, 332
Free gingiva, 14
Free gingiva margin, 14
Free gingival groove, 473
Freeway space, 282
Fremitus, 287
Frenum (buccal), 455, 459
Frenum, defined, 235, 449
Frontal bone, 394
Frontal envelope, 292
Frontal process, 401
Full-mouth rehabilitation, 289
Functional movements, of temporomandibular joint
  incising, 286
  masticating (chewing), 286
  swallowing (deglutition), 286
Fungiform papillae, 469, 470
Furcal region, 31
Furcation, 31
Furcation involvement, 231–234, 231–234, 232t, 235t
Fusion, 341, 342, 343

G

Gemination, 340, 342
General forensics, 359
Genial spines, 406, 424
Geniohyoid muscle, 409, 424
Gingiva
  attached, 14, 219, 234–236
  biologic width, 237
  keratinized, 219, 220
  oral examination, 473–475, 474–475
  recession, 221, 223–225, 224–225
  thin tissue, 224
Gingival embrasure, 38
Gingival margin, 14, 15
Gingival recession, 16, 16, 221, 223–225, 224–225, 228–229, 240, 306, 326
Gingival sulcus, 218–219, 227, 248, 474–475
Gingivitis, 216, 221–222, 222
Ginglymoarthrodial joint, defined, 275
Glass ionomer, 308
  restorations, 328
Glenoid, defined, 275, 393, 407, 412
Glossopharyngeal nerve, 429t, 437, 438, 441
Granuloma, 258, 259
Greater palatine foramina, 430, 467
Greater palatine nerve, 430
Grooves
  molar
    mandibular, 149–150, 151, 152
    maxillary, 166, 168
  premolars
    mandibular, 119, 119
    maxillary, 108, 110, 112
Group function, 285, 302
Gutta percha, 260

H

Hamular notch, 402
Hard palate, oral examination, 461, 461–464
Head, oral examination, 450
Height of contour
  canines, 80, 84, 85t, 87
  in drawing teeth, 379, 380
  molars
    mandibular, 147, 147
    maxillary, 160, 162
  premolars, mandibular, 120, 121, 122

Human identification, forensic dentistry for
antemortem records, 359
DNA analysis, 360
postmortem examination, 359, 360, 361
techniques for, 359
Hutchinson incisors, 341, 343
Hutchinson teeth, 341, 343
Hyoid bone, 409, 424
Hypercementosis, 347, 348
Hypoglossal canals, 437, 438
Hypoglossal nerve, 394–395, 437, 438
Hypophysial fossa, 396, 398

I
Ideal occlusion
class I occlusion, 269–271, 270, 271
definition, 269
Identification of human teeth
antemortem records, 359
DNA analysis, 360
postmortem examination, 359, 360, 361
techniques for, 359
Impacted (unerupted) tooth, 348, 350
Incisal edge, maxillary incisors, 60, 62
Incisal embrasure, 38, 38
Incisal guidance, 283, 302t
Incisal view, 377, 378–379
Incising, 285, 286
Incisive artery, 442
Incisive foramen, 402, 402, 430, 461, 462
Incisive fossa, 401
Incisive nerve, 433, 434
Incisive papilla, 461
Incisor(s)
arch traits, 53–55
central, 4
crowns, 52, 53
functions, 50
general description, 50, 51
lateral, 4
mandibular
incisal view, 59, 71, 72
labial view, 64–67, 65, 66, 67t
lingual view, 67, 69
proximal views, 59, 60, 71
size of, 76
maxillary
incisal view, 62–64
labial view, 55, 57
lingual view, 57–60
proximal views, 60–62, 61, 62
size of, 76
morphology, 50
primary teeth
crowns, 194, 194, 195
incisal view, 195, 196
labial view, 194, 194–195, 195
lingual view, 195, 196
marginal ridges, 195, 196
maxillary vs mandibular, 205t
proximal views, 194, 195
root-to-crown, 195
roots, 52, 53
variations and differences, 72
Index, plaque, 236, 236
Inferior alveolar artery, 441
Inferior alveolar nerve, 405, 433–435
Inferior alveolar vein, 442
Inferior, defined, 392
Inferior nasal conchae bone, 409
Infrahyoid muscle, 409
Infraorbital artery, 442
Infraorbital canal, 399, 432
Infraorbital fissure, 399
Infraorbital foramen, 399, 459
Infraorbital nerve, 399, 431–432, 459
Initial tooth preparation, 310–311, 311
Injections, anesthetic (See Anesthetic injections)
Injury, 225
Inlay, cast metal restorations, 308–309
Insertion, defined, 418, 420
Interdental papilla, 14, 15
Intermaxillary suture, 462
Internal acoustic meatus, 407, 436
Internal jugular vein, 395, 443, 444
Internal oblique line, 406
International numbering system, 8–11
Interproximal space, 38, 38
Intracoronal restoration, 258
Intraoral examination
alveolar process, 473
floor of mouth, 471–473, 471–473
gingiva, 473–475, 474–475
hard palate, 461, 461–464
oropharynx, 464–468, 465–466
salivary glands, 472, 473
sof palate, 464, 464–465
teeth, 475–476
tongue, 469–470, 469–471
vestibule and cheeks, 454–460, 455–460
Irreversible pulpitis, 258
Isometric contraction, 427
Isotonic contraction, 427

J
Jaw relation
centric relation, 280–282, 280–282
horizontal movements
mandibular lateral translation, 284–285, 285
protrusive, 283, 283–284, 284, 284t
maximal intercuspal position, 280, 280, 281
Jugular foramen, 407, 437
Jugular vein, internal, 395, 443, 444
Junctional epithelium, 219, 220
Jurisprudence, forensic, 359

K
Keratin layer, 454
Keratinized epithelium, 218
Keratinized gingiva, 219, 235, 474

L
Labial arteries, 441
Labial, defined, 17
Labial embrasure, 37
Labial frenum, 455
Labial mucosa, oral examination, 454
Labial nerve, 432
Labiomental groove, 453
Labioversion, 271
Lacrimal bones, 409
Lacrimal, defined, 393, 409
Lambdoid suture, 395
Lamina, defined, 393
Lamina dura, 217, 221, 475
Laryngeal prominence, oral examination, 452
Larynx, oral examination of, 451
Lateral ligament, 415, 415
Lateral mandibular movement, 284–285
Lateral mandibular relation, 284–285
Lateral pterygoid muscles, oral examination of, 413, 414, 418, 421, 422, 451
Laterotrusion, 285
Leaf gauge, 294
Leaf wafer, 293
Lesser palatine foramina, 403
Lesser palatine nerve, 430
Levator anguli oris muscles, 425, 426
Levator labii muscles, 426
Ligaments of temporomandibular joint, 414–416, 415
Line angle, 18, 57
Linea alba, 455
Lingual artery, 441
Lingual cusps, 270
Lingual embrasure, 37, 38
Lingual frenum, 472
Lingual nerve, 433, 433, 434
Lingual root, 263
Lingual surface, defined, 17
Lingual veins, 443
Lingula, 393, 405
Linguoversion, 271
Lips, oral examination, 453–454, 454
Lobes, developmental
canines, 41
incisors, 52
of incisors, 52, 53t
molars, 42, 138, 139t
premolars, 98
Local anesthetic technique, buccal nerve, 433, 433, 434
Long buccal nerve, 433, 460
Long centric articulation, 296
Luxation, of mandible, 279
Lymph nodes, oral examination, 451–452, 453

M
Macrodontia, 343, 345
Major connector, of dental prosthesis, 332, 332
Malar, defined, 393
Malocclusion
anterior crossbite, 272, 272, 275
buccoversion, 271
class II, 273–274, 274
class III, 274–275, 275
definition, 269
deflective occlusal contacts, 273, 280–281
edge-to-edge bite, 273
vs. ideal occlusion, 269–275
infraocclusion, 271
jaw relation (See Jaw relation)
labioversion, 271
linguoversion, 271
open bite, 273, 273
overbite, 270, 270, 272, 273
posterior crossbite, 272, 272
premature contacts, 273
supraeruption, 271, 272
teeth poor alignment, 271, 271
tooth-to-tooth malocclusion, 272–273
treatment
occlusal device, 288, 289
patient education and behavior therapy, 288
stress management and muscle relaxation, 288
teeth shapes, 289–291, 290
tooth location, 281, 291, 291
Mamelons, in incisors, 52
Mandible, 397, 403–405, 404–406
angle of, 405
body, 404
internal surface, 405, 405–406
ramus (rami), 404, 405, 405
Mandibular arch, 97, 97
Mandibular branch, 398, 429
Mandibular canine crown, 55, 57
Mandibular canines
facial view, 376–377
incisal view, 378–379
cingulum, 91
crown proportions, 90, 90
incisal edge, 90–91

labial outline, 90, 91
lingual ridge, 91
labial view
canine morphology, 82, 84, 84t
crown shape and size, 84, 85–85
cusp tip and incisal ridges, 83–84, 84–85
proximal contact areas, 84, 85, 85t
root contour, 85
tooth proportions, 85
lingual view, 377
canine roots, 87
cingulum, 85, 86, 87
lingual ridges and fossae, 85, 87
marginal ridges, 87, 87
mesial and distal view, 378
proximal views
canine outline, 87
cervical lines, 89
height of contour, 87, 88–89
incisal ridge and cusp tip, 87, 89
roots, 88, 89, 89, 89t
Mandibular central and lateral incisors, 262
Mandibular condyle, 275
Mandibular deviation, 280
Mandibular foramen, 405, 405
Mandibular fossa, 412, 414
Mandibular incisors
incisal view
crown outline and incisal ridge alignment, 71
incisal ridge contour, 71
labial view
crown shape, 65, 66, 66
incisal proximal angles, 66
proximal contact area, 66–67, 67t
root shape, 65, 67
root-to-crown proportions, 67
lingual view
cingulum, 67
marginal ridges and fossae, 67
root contours, 67, 69
proximal views
cervical line, 69
crest of curvature, 69
incisal edge, 69, 71
root shape and depressions, 69
size of, 76
Mandibular lateral translation, 284
Mandibular molars
buccal view
cervical lines, 143, 143
crown proportions, 141
proximal contacts, 139, 143
relative number and height, 141–143, 142–143
roots, 139, 143, 144
taper, 141
lingual view
cervical line, 144
narrower lingual crown, 144
relative size, 144, 145
roots, 144, 145
occlusal view
fossae, 150, 150, 151
grooves, 149–151, 152
numbers and size of cusps, 149, 150
outline shape and taper, 149, 149–150, 150
proximal contact areas, 150, 151, 152
ridges, 150, 151
proximal views
cervical lines, 147
crown shape and tilt, 145
height (crest) of contour, 147, 147
marginal ridges, 147, 148
numbers and size of cusps, 146–147, 147
roots and root depressions, 146, 148, 148
tapers, 146, 147
Mandibular nerves, 398, 428, 460
auriculotemporal nerve, 432, 433
buccal nerve, 433, 433, 434
distribution of, 436t
inferior alveolar nerve, 433, 433–435, 434
lingual nerve, 433, 433, 434
Mandibular premolars
buccal view
crown size and shape, 115, 116
cusp ridge notches and depressions, 117
location of, 116, 117t
roots, 117
lingual view
crown shape, 117
cusps and grooves, 117, 119, 121, 134t
grooves, 119, 119
marginal ridges, 118, 119
roots, 119
occlusal view
occlusal morphology, 124–127
outline shape, 124, 124
proximal views
cervical lines, 122
crown shape, 119, 120, 121, 121
height (crest) of contour, 120, 121
marginal ridge grooves and mesiolingual grooves, 120, 121–122
ridges, 120, 121, 121
roots and root depressions, 122, 122
size of, 133t
Mandibular torus, 471
Marginal ridges
incisors, 59–60, 67
molar
mandibular, 148
maxillary, 147, 148
Mass disasters, forensic dentistry in
antemortem records, 359
case studies, 370–372, 371–372
dental identification, 367–370, 368–369
forensic anthropology, 370, 371
initial response, 367
morgue operation, 367–370, 368–369
postmortem examination, 368, 369
preparation and training, 367
Masseter muscle, 418, 419
attachments, 404, 405, 419
oral examination of, 407
Masticating (chewing), 286
Mastication
defined, 286
muscles of
lateral pterygoid, 421, 422, 422, 423
masseter, 418, 419
medial pterygoid, 421, 421–423
oral examination of, 438
temporalis, 419, 420, 420–421
Mastoid process, 406, 407
Maxilla (maxillae)
body, 397, 399
maxillary sinus, 399, 400
processes of
alveolar, 401, 401–402
frontal, 401
palatine, 402, 402–403
zygomatic, 401
Maxillary arch, 270, 270, 271
Maxillary artery, 441–442
Maxillary canines, 262
incisal view
cingulum, 91
crown proportions, 90, 90
incisal edge (cusp tip) contour, 90–91
labial contour, 90, 91
lingual ridge, 91
labial view
canine morphology, 82, 84, 84t
cusp tip and incisal ridges, 83–84, 84–85
proximal contact areas, 84, 85, 85t
root contour, 85
shape and size, 84, 84–85
tooth proportions, 85
lingual view
canine roots, 87
cingulum, 85, 86, 87
lingual ridges and fossae, 85, 87
marginal ridges, 87, 87
proximal views
canine outline, 87
cervical lines, 89
height of contour, 87, 88–89
incisal ridge and cusp tip, 87, 89
roots, 88, 89, 89, 89t
Maxillary incisors
incisal view
crown proportion faciolingually vs. mesiodistally, 62, 63
incisal ridge contour, 64
outline shape and cingulum location, 62–63, 63
labial view
crown shape, 55, 57
proximal contact areas, 57
proximoincisal line angles, 57
root thinner and longer, 57
root-to-crown ratio, 57
lingual view
accessory ridges, 58, 60, 60
cingulum, 59
lingual fossae, 57, 59
marginal ridges, 59–60
pits, 58, 60
root shape, 58, 60
proximal views
cervical line, 60, 62
incisal edge, 60, 61, 62
root shape and root depressions, 60–62, 61
size of, 76
Maxillary molars
buccal view
numbers and size of cusps, 155, 155, 157
proximal contacts, 157, 157t–158t
relative crown size and shape, 155, 157
roots, 155, 157
lingual view
molar roots, 159, 160
numbers and lingual cusps, 158–160, 159
relative size and taper, 158, 159
occlusal view
fossae, 166, 167, 167
grooves, 168, 168
numbers and cusp size, 164–165, 165
proximal contacts, 168–169, 169
ridges, 166–167, 167
proximal views
cervical lines, 162, 163
crest of curvature, 160, 161
marginal ridges, 160–161, 161
molar cusps, 160
relative number and size of, 160, 161
roots, 162, 163
taper, 160, 161
Maxillary nerve, 398, 403, 428
anterior superior alveolar nerve, 431
infraorbital nerve, 431–432, 432
middle superior alveolar nerve, 431
posterior superior alveolar nerve, 430–431, 432
pterygopalatine nerve, 430, 431
zygomatic nerve, 429, 432

Maxillary premolars
  buccal view
    buccal cusp shape, 105, 106
    buccal ridge and adjacent depressions, 105, 106
    location, 105, 106
    pentagon-shaped crown, 104, 106
    roots, 106
  lingual view
    cusp ridges, 106
    lingual cusp position, 106
    marginal ridges, 106
    relative cusp size, 106, 107
    roots, 108
  occlusal view
    contact areas and heights of contour, 113, 114
    grooves and fossae, 112
    outline, 111, 112–113, 113
    relative proportions, 111, 112
    relative size, 112
  proximal views
    cervical lines, 110
    crown shape and morphology, 108
    height (crest) of contour, 108, 109
    marginal ridge grooves, 108, 110
    relative cusp height, 108
    roots and root depressions, 110
  size of, 132t
Maxillary sinus, 399, 400
Maxillary tuberosity, 402, 465
Maxillary vein, 443
Maximal intercuspal position (MIP), 280, 280, 281
Meatus, defined, 392
Medial pterygoid muscles, 421
  attachments, 398
  oral examination of, 426
Median plane, defined, 393
Mediolateral curve, 34, 34
Melanin pigmentation, 218, 473
Mental artery, 441–442
Mental foramen, 405, 433
Mental nerve, 433, 434
Mental protuberance, 404
Mental spines, 406
Mental tubercles, 404
Mentalis muscles, 425, 426
Mesial cusp ridges, 23, 84, 85
Mesial root, 148, 177, 199
Mesial root depression, 163t
Mesial surface, 80
Mesiobuccal root, 157, 162, 255, 263, 431
Mesiobuccal root, molar, 157, 162
Mesiodens, 338
Mesio-occlusion, 274
Mesognathic occlusion, 269–270
Metal ceramic restorations, 309, 330, 330
Microdontia, 343, 345
Middle cranial fossa, 394
Middle superior alveolar artery, 442
Middle superior alveolar nerve, 431, 432
Mid-root axis, 32–34, 33–34
Midsagittal plane, defined, 393
Misplaced tooth, 348, 350, 351
Mixed dentition
  defined, 185
  tooth emerge timing, 189
Mobility of teeth
  charting, 226–227
  functional mobility, 227
Modified preparation, 310
Molars
  arch traits, 138–140, 139, 139t, 140t
  class traits, 137–138
  functions, 137, 137
  general description, 136–137, 136–137
  mandibular
    buccal view, 141–144
    lingual view, 144
    occlusal view, 148–152
    proximal views, 144–147
  maxillary
    buccal view, 155–157
    lingual view, 158–160
    occlusal view, 162–169
    proximal views, 160–162
  molar crowns, 171, 173
  molar roots, 171
  primary teeth
    first molar mandibular, 201–204
    first molar maxillary, 202, 202–203, 203
    second molar mandibular, 199–200, 200
    second molar maxillary, 199–201, 200
  pulp shape, 254–256, 255, 256
  size and shape, 171
  type traits, 171–174, 172, 173
  variations of, 175–177
Morgue operation, in mass disaster, 367–370, 368–369
Mouth, floor of, oral examination, 406
Movement of jaw
  functional of temporomandibular joint, 285–286
  parafunctional, 287–288
Mucocutaneous junction, 453
Mucogingival defects
  charting, 226–227
  circumstances for, 235
  technique for measuring, 235–236
Mucogingival line, 474
Mucosa, 218–220, 219, 235, 431, 433, 453, 455, 456, 461, 466, 473, 474
Mucosa (buccal), 455, 456
Mulberry molars, 341
Muscle(s)
  advanced topics, 426–427
  affecting mandibular movement, 424–425
  of facial expression, 425, 425–426, 438
  of mastication
    lateral pterygoid, 421, 422, 422, 423
    masseter, 418, 419
    medial pterygoid, 421, 421–423
    oral examination of, 438, 450, 450–451
    temporalis, 419, 420, 420–421
  mouth
    buccinato, 425–426
    depression of mandible, 426
    elevation of mandible, 426
    fascia, 425
    lateral excursion, 426
    lateral pterygoid muscle, 419–423, 422
    lower oral group, 426
    masseter muscle, 418, 419
    medial pterygoid muscle, 421, 421–423
    occipitofrontalis, 426
    orbicularis oris, 425
    platysma, 426
    protrusion, 426
    retrusion, 426
    suprahyoid muscles, 424
    temporalis muscle, 419, 420, 420–421
    upper oral group, 426
  of the neck, 424
Muscle relaxation, 272, 288
Muscle tone, 427
Muscles of mastication, oral examination, 438, 450, 450–451
Mylohyoid groove, 405
Mylohyoid muscle, 406
Mylohyoid nerve, 433
Mylohyoid ridge, 406
Myofacial trigger points, 287

N

Nasal artery, 441
Nasal bones, 409
Nasal conchae bone, inferior, 399, 409
Nasal nerve, 431
Nasal septum, 395, 397
Nasal turbinates, inferior, 399
Nasofrontal process, 401
Nasolabial groove, 453
Nasopalatine nerve, 430, 462
Neck
  lymph nodes of, 424, 425, 444
  muscles of the, 424
  oral examination, 451, 452
Necrotic pulp, 257
Nerves
  afferent (sensory), 428
  cranial
    abducent, 429t
    auditory, 429t
    facial, 429t
    glossopharyngeal, 429t
    hypoglossal, 429t
    oculomotor, 429t
    olfactory, 429t
    optic, 429t
    spinal accessory, 429t
    trigeminal, 429t (See also Trigeminal nerve)
    trochlear, 429t
    vagus, 429t
  efferent (motor), 428
Neurocranium
  defined, 393
  ethmoid bone, 396
  frontal bones, 394
  occipital bone, 394
  parietal bones, 394
  sphenoid bone, 394, 396
  temporal bones, 406
Neutroclusion, 269
Nonworking side, 285

O

Oblique ridge, 23
Occipital bone, 394, 394–395, 395
Occipital condyle, 438
Occipitofrontalis muscle, 426
Occlusal devices, 288, 289
Occlusal embrasure, 38, 38
Occlusal equilibration, 289
Occlusal surface, 17
Occlusal trauma, 225
Occlusal vertical dimension, 282
Occlusion, 39 (See also Malocclusion)
  class I occlusion, 39, 40
  ideal, 39–41, 40–41
Oculomotor nerves, 429t
Odontoblasts, 14
Odontology, forensic, 359
Olfactory nerve, 395
Omohyoid muscle, 424
Onlay
  cast metal restoration, 309, 309
  porcelain restoration, 309–310
Open bite, 273, 273
Open occlusal relationship, 273
Operative dentistry, 307–308
Operculum, 174, 174
Ophthalmic nerve, 429, 430, 430
Optic nerves, 429t
Oral cavity, 454
Oral cavity proper, 454
Oral examination
  extraoral
    eyes, 451

general appearance, 450
head, 450
lips, 453–454, 454
lymph nodes, 451–452, 453
muscles of mastication, 450, 450–451
neck, 451, 452
salivary glands, 452, 452
temporomandibular joint, 450, 451
intraoral
alveolar process, 473
floor of mouth, 471–473, 471–473
gingiva, 473–475, 474–475
hard palate, 461, 461–464
oropharynx, 464–468, 465–466
salivary glands, 472, 473
sof palate, 464, 464–465
teeth, 475–476
tongue, 469–470, 469–471
vestibule and cheeks, 454–460, 455–460
Oral mucous membrane, 454
Oral vestibule, 454
Orbicularis, 426
Orbicularis oculi muscle, 424
Orbicularis oris muscle, 441
Origin, of muscle, 418, 420, 421, 422
Oris, 425
Oropharynx, oral examination, 464–468, 465–466
Orthodontic treatment, 291
Orthognathic profile, 270
Overbite
normal, 270, 270, 272
severe, 272, 273
Overjet
normal, 270, 270
severe, 273, 273

P

Palatal surface, 17
Palate
hard, 402, 461, 461–464
sof , 464, 464–465
Palatine arches, oral examination of, 465
Palatine artery
ascending, 441
descending, 442
Palatine bones, 400, 402, 403
Palatine foramina
greater, 403
lesser, 403
Palatine nerve
greater, 463, 464
lesser, 430
Palatine process, 402, 402–403
Palatine raphe, 461, 462
Palatine rugae, 461, 462
Palatine suture, transverse, 403
Palatine tonsils, oral examination, 465
Palatine torus, 471, 473
Palatomaxillary suture, 403
Palmer Notation System, 10, 10
Palpebral, defined, 393
Palpebral nerve, 431
Panoramic radiograph, of the mouth, 446
Panorex, of the mouth, 365, 446
Papilla
circumvallate, 438
circumvallate, 469, 470, 470
filiform, 469, 470
foliate, 470, 470
fungiform, 469, 470
Parafunctional movement
bruxing, 287
clenching, 287
defined, 287
Paramolar, 338, 339
Parietal bones, 394, 394
Parotid duct, 455
Parotid glands, oral examination of, 438, 441, 441
Parotid nodes, 444
Parotid papilla, 455
Partial anodontia, 337, 337–338, 338
Pathology, forensic, 359
Patient education
prevention and, 305
related to malocclusion, 288
Peg-shaped lateral incisors, 340, 341
Periapical disease, 258, 259
Periapical radiolucency, 258, 259
Peri-implant mucositis, 244
Perikymata, 26, 28
Periodontal anatomy
alveolar bone, 217
bleeding on probing, 226, 230, 231
clinical attachment loss, 230, 230
dental implants, 244–245, 244–245
furcation involvement, 231–234, 231–234, 232t, 235t
gingiva, 218–221, 218–221, 219t
gingival margin level, 228, 230
gingival recession, 223–225, 224–225
gingivitis, 221–222, 222
mucogingival defect, 234–236, 235, 236
oral hygiene instruction, 240–243, 240–243
periodontal disease, 237, 240
periodontal ligament, 217, 217
periodontitis, 222–223, 223
plaque score, 236, 236
root anatomy and anomalies, 238–239, 239
root morphology, 237–238, 238
tooth mobility, 225–227, 227, 228t
tooth root surface, 217
tooth support, 237–238, 238
Periodontal disease
bone loss and, 223, 223
defined, 216
gingival recession, 223–225, 224–225
gingivitis, 219t, 221–222, 222
periodontitis, 222–223, 223
restoration (fillings) and, 237
root anatomy and, 238–239, 239
root attachment and, 237
Periodontal ligament, 15, 15
Periodontal measurements
bleeding on probing (BOP), 226–227, 230, 231
charting, 226–227
clinical attachment loss, 230, 230
fremitus
charting, 226–227
defined, 227
furcation involvement
categories for, 235t
charting, 226–227
defined, 231
location of, 232t
mandibular molar, 231, 233
maxillary molar, 231, 233, 233
probing for, 231, 232
gingival margin position, 224, 228, 230
charting, 226–227
mucogingival defects, 234–236, 235, 236
charting, 226–227
circumstances for, 234–235
technique for determination, 235–236
plaque index
charting, 226–227, 236
technique for determination, 227, 236
probe depths
charting, 226–227
technique, 227–228, 228, 229
tooth mobility
charting, 226–227
functional mobility, 227
technique for determination, 226–227, 227, 228t
Periodontal pocket, defined, 228, 239
Periodontal probe, 219, 220, 228, 228
Periodontics
defined, 216
root planning, 240, 241
surgical procedures, 237
Periodontist, defined, 216
Periodontitis
aggressive, 223
bone loss and, 223
chronic, 223
defined, 216
Periodontium (See also Gingiva)
alveolar bone, 217, 217, 221
cementum, 217, 221
defined, 14, 216, 217
diseased
characteristics of, 218, 219t
gingival recession, 223–225, 224–225
gingivitis, 219t, 221–222, 222
periodontitis, 222–223, 223
gingiva zones, 218–220, 219, 220
healthy, characteristics of, 218, 219t
periodontal ligament, 217, 217, 221
Peristalsis, 286
Permanent dentition, 5–6, 6
Permanent incisors (See Incisor(s))
Permanent teeth (See also specific tooth)
classes, 5
complete, 50
crown formation, 189
number of, 10
primary teeth compared to, 192, 192–193
Petrotympanic fissure, 407, 407
Petrous portion, 407, 408
Pharyngopalatine arch, 465
Pharynx, 286, 465
Piriform, defined, 393
Pit caries, 306, 306, 313
Pits, maxillary incisors, 58, 60
Planes of the head, 393
Plaque, dental
defined, 216
in dental caries, 236
Plaque index
charting, 226–227, 236
technique for determination, 227, 236
Platysma muscle, 424, 436
Plica fimbriata, 470
Point angles, 18
Pontic, defined, 330
Porcelain, 309–310
Porcelain restorations, 309, 369
Porcelain veneer crown, 331
Post and core restorations, 328
Posterior arch, 465
Posterior cranial fossa, 394
Posterior fibers, temporalis muscle, 420
Posterior superior alveolar artery, 456
Posterior superior alveolar nerve, 430–431, 432
Posterior teeth, 6, 17, 18
Postmortem examination
for human identification, 360, 362–363
in mass disasters, 368, 369
Posture, jaw relation and, 293–296, 294, 295
Premature contact, 273, 280, 280–281, 294, 296
Premaxilla, 403

Premolars, 41
  arch traits, 102–104, 103
  class traits, 98–102
  crown shape, 99
  functions, 98, 98
  location of, 97, 97–98, 98
  mandibular
    buccal view, 116–117
    lingual view, 117–119
    occlusal view, 122–127
    proximal views, 119–122
  maxillary
    buccal view, 104–106
    occlusal view, 110–114
    proximal views, 108–110
  orifices, 253–254, 254, 255
  pulp horns, 253, 254
  pulp shape, 253–254, 254, 255
  roots, 99, 100, 122t
Prevention, patient education and, 305
Preventive resin restoration (PRR), 315
Primary dentition, 4–5, 5
Primary teeth
  canines
    incisal view, 196, 197
    labial view, 195–197, 197
    lingual view, 197
    proximal views, 194, 197
  classes
    primary canine traits, 195–197
    primary incisor traits, 194–195
    primary molar traits, 197–204
  compared to permanent teeth, 192, 192–193
  crown and root development, 187–192
  crown calcification, 187, 188
  definitions, 182–183
  dental formulae, 183
  erupt, 187
  exfoliation, 187, 189, 191
  first molars
    mandibular, 201–204
    maxillary, 202, 202–203, 203
  formulae, 183
  functions, 184, 184–185
  general characteristics
    anterior, 193, 194
  identification systems, 183, 183–184, 184
  incisors
    crowns, 194, 194, 195
    incisal view, 195, 196
    labial view, 194, 194–195, 195
    lingual view, 195, 196
    marginal ridges, 195, 196
    maxillary vs. mandibular, 205t
    proximal views, 194, 195
    root-to-crown, 195
  pulp cavities, 204–205, 205
  root development, 188, 189
  second molars
    mandibular, 199–200, 200
    maxillary, 199–201, 200
  tooth emergence, 188, 188t
  tooth eruption, 185
  traits of, 192–193
Primate spaces, defined, 188
Probing
  for attachment loss, 230, 230
  bleeding on, 226–227, 230
  for furcation involvement, 231
  for gingival recession, 230
  for mucogingival defects, 235
Probing depths
  charting, 226–227
  technique, 227–228, 228, 229
Procerus, 426
Prognathic profile, 274
Proprioception, 428
Proprioceptive fibers, 278
Proprioceptors, 293
Prosthodontics, 307–308
Protrusion, 426
Protrusive movement, 283
Protuberance, 392
Proximal contact areas
  canines
    mandibular, 85
    maxillary, 85
  incisors
    mandibular, 66–67, 67t
    maxillary, 57
  molars
    mandibular, 139, 141, 149–150
    maxillary, 157, 157t–158t
  premolars
    lingual view, 106–108
    mandibular, 116
    maxillary, 104
Proximal height of contour, 67t, 117t, 157t–158t
Proximal surface, 17, 18, 316, 321
Pseudopocket, 228
Psychiatry, forensic, 359
Pterygoid fossa, 421, 423
Pterygoid fovea, 405
Pterygoid hamulus, 398
Pterygoid muscles
  lateral
    attachments, 396, 398, 405, 405, 413
    examination of, 421–423, 422
  medial
    attachments, 421
    examination of, 421, 421–423
Pterygoid plate
  lateral, 396, 398
  medial, 398
Pterygoid plexus of veins, 442
Pterygomandibular fold, 466, 467
Pterygopalatine nerve, 430
Pterygopalatine space, 430, 431
Pulp
  cavity, 13
  dental pulp functions, 13–14
Pulp canal, 250, 250–251 (See also Root canal (pulp canal))
Pulp cap, 257
Pulp chamber
  canines, 251, 253, 254
  incisors, 251, 253, 253
  molar, 254–256, 255–256
  premolar, 253–254, 254
  primary teeth, 204
Pulp horns
  canines, 251, 253, 254
  incisors, 251, 253, 253
  molar, 254–256, 255–256
  premolar, 253–254, 254
Pulp morphology
  endodontics, 257–261, 258–261
  ethnic variations, 264
  mandibular
    canines, 262
    central and lateral incisors, 262
    first and second molars, 262–263
    first premolars, 262
    second premolars, 262
  maxillary
    canines, 262
    central incisors, 261
    first and second molars, 263, 264t
    first premolars, 262
    lateral incisors, 261
    second premolars, 262
  pulp cavities
    older teeth, 256–257
    shape, 250, 250–256, 251t, 252–256, 257t
  restorative dentistry, 257, 258
Pulpitis, irreversible, 257, 258
Pupil, of eye, 451

Q
Questioned documents, 359

R
Radiograph, panoramic, of the mouth, 446
Ramus (rami), 275
Recession, gingival, 221, 223–225, 224–225
Rehabilitation, full mouth, 289
Remineralization, 305
Removable dental prosthesis, 332
Resin restorations, conservative, 308, 309
Resistance form
  class I, 316
  class II, 318–319, 320
Rest position
  physiologic, 282–283, 283
  vertical dimension of, 282
Rest seats, 332
Rest space, interocclusal, 282
Restoration materials
  amalgam, 308, 308
  cast metal, 308–309, 309
  composite resin, 308
  glass ionomer, 308
  porcelain, 309–310
Restoration outline, 311
Restorations
  all ceramic, 330
  cast restorations, 308–309, 319, 320
  cavity preparation
    outline, 310
    resistance form, 310, 312
    retention form, 310–311, 311, 312
  class I
    cavity preparation, 315, 315–316, 316
    indications for, 314
  class II
    cavity preparation, 318–319, 318–321
    indications for, 316
    indirect, 319–321, 320, 321
  class III
    cavity preparation, 323, 323–324
    indications for, 321
  class IV
    cavity preparation, 325, 325
    indications for, 324
  class V
    cavity preparation, 327, 328
    indications for, 326
  filling materials
    amalgam, 308, 308
    cast metal, 309, 309
    composite resin, 308
    glass ionomer, 308
    porcelain, 309–310
Restorative dentistry, 257, 258, 307–308 (See also Restorations)
Retained deciduous teeth, 209
Retainer, 332
Retention form
  class I, 316
  class II, 319, 319
  class III, 323–324
Retentive grooves, 319
Retraction, defined, 284
Retro, defined, 393
Retrognathic profile, 274

Retromolar fossa, 406
Retromolar pad, 465, 466
Retromolar triangle, 406
Retromylohyoid curtain, 466
Retrusion (retraction), defined, 284
Reverse articulation, defined, 272
Ridge (buccal), 105, 106, 116–117
Risorius muscle, 426
Root (See also specific tooth)
  definition of, 15
Root axis line, 32
Root canal (pulp canal)
  accessory canals, 250, 252
  anterior teeth, 251, 253
  canines, 262
  incisors, 261
  molars, 254–256, 255, 256, 262
  premolars, 253–254, 254, 262
  types of, 250, 252
Root dehiscence, 225
Root depression, 89
Root planing, 240
Root restoration, 328, 333, 361
Root surface caries, 306
Root trunk, 31
Root-to-crown ratio, 19–20, 20, 379
Rotation, tooth, 350, 351

S
Sagittal envelope, 292
Sagittal suture, 394
Salivary glands, oral examination, 452, 452, 472, 473
Sclera, 451
Sealant, 314
Secondary dentition, 5
Secretory nerves, 429t, 436, 438
Sella turcica, 398
Septum, defined, 393
Shelf (buccal), 405
Shovel-shaped incisors, 73
Sigmoid notch, 405
Silent period, 302
Sinus, maxillary, 396, 399
Skull
  facial bones
    hyoid, 409, 424
    inferior nasal conchae, 409
    lacrimal, 409
    mandible, 397, 403–405, 404–406
    maxillae, 397, 399–403, 400–402
    nasal, 408, 409
    palatine, 400, 402, 403
    vomer, 407, 407, 408
    zygomatic, 403, 403–404
  neurocranium
    ethmoid bone, 396
    frontal bone, 394
    occipital bone, 394
    parietal bones, 394
    sphenoid bone, 394, 396
    temporal bones, 406
Sliding guide, 294
Slot preparation, 319, 319
Sluiceways, 286
Smooth surface restorations, 312, 321, 325, 333
Sof palate, oral examination of, 464, 464–465
Sphenoid bone, 395–398, 397
Sphenoidal spine, 405, 416
Sphenomandibular ligament, 415, 416
Spillways, 117, 286
Spinal accessory nerves, 429t
Squamosal suture, 406
Stensen duct, 455
Sternocleidomastoid muscle, 407, 453
Sternohyoid muscle, 425
Sternothyroid muscle, 425
Sternum, 424
Stress management, 288
Stuart groove, 167
Stylohyoid muscle, 424, 436
Styloid process, 406, 407
Stylomandibular ligament, 405
Stylomastoid foramen, 436, 437
Sublingual caruncles, 471
Sublingual fold, 472
Sublingual fossa, 406
Sublingual salivary gland, 406
Subluxation, condylar, 279
Submandibular chain of nodes, 444
Submandibular fossa, 406
Submandibular nodes, 444, 444
Submandibular salivary glands, oral examination, 406
Submental artery, 441
Submental nodes, 444
Succedaneous teeth, 184
Sulcular groove, 32
Sulcus
  alveolingual, 471, 471
  gingival, 14, 218–219, 220, 248
  terminal, 470
  of tooth, 27
Superficial, defined, 393
Superior, defined, 393
Superior orbital fissure, 398
Superior position, 394, 394
Supernumerary teeth, 42, 338–340, 339–340
Supplemental grooves, 27
Supraeruption, 271, 274
Suprahyoid muscles, 409
Surface (buccal), 40, 201–204, 270
Suture line, defined, 393
Sutures
  coronal, 394
  intermaxillary, 403
  lambdoid, 395
  palatomaxillary, 403
  sagittal, 394
  squamosal, 406
  transverse palatine, 403
Swallowing (deglutition), 286
Symphysis, 393
Synovial fluid, temporomandibular joint, 278
Synovial membrane, 414
Syringe, aspirating, 454

T
Talon cusp, 342
Tartar, defined, 216
Taurodontia, 345–346, 346
Teeth (See also specific tooth)
  carving
    advice, 384
    materials for, 381
    maxillary central incisor, 382, 382–384, 383–386
    wax carvings, 381, 382
  counting, 475–476
  drawing
    distal views, 376, 377, 378
    facial views, 376–377, 377
    incisal view, 377, 378–379
    lingual views, 377, 377
    materials needed, 375
    measurements for, 376, 376
    from memory, 379, 379–381
    mesial views, 376, 377, 378
    occlusal views, 381
    outline, 375–376, 376–378
    proximal view, 381
  oral examination, 475–476
Temporal bones, 406–407, 406–408
Temporal crest, 405
Temporal fossa, 394, 394
Temporalis muscle
  attachments, 398
  oral examination of, 419–420, 420–421
Temporomandibular disorders, 287
Temporomandibular joint
  advanced topics, 416, 416–417
  articular disc, 277, 277–278, 412–413, 413, 414, 414t
  articular fossa, 275–277, 276, 411, 412, 412, 413
  development, 416, 416
  fibrous capsule, 278, 278, 414, 415
  lateral ligament, 415, 415
  mandible dislocation, 279–280
  mandibular condyle, 275, 276, 411, 411–413
  movements
    lower joint space, 278
    total, 279
    upper joint space, 278–279, 279
  oral examination, 450, 451
  sphenomandibular ligament, 415, 416
  stylomandibular ligament, 415, 415
Temporomandibular ligament, 414
Terminal hinge, 301t
Terminal sulcus, 470
Tetracycline stain, 353, 353
T yrohyoid muscle, 425
T yroid gland, oral examination of, 452
Tinnitus, defined, 287
Tongue, oral examination, 469–470, 469–471
Tooth
  preparation
    clean, 312
    convenience form, 311
    dental cement base, 311, 311
    final evaluation, 312
    outline form, 310
    resistance form, 310, 312
    retention form, 310–311, 311, 312
    sound enamel, 312
    walls, 312
  restoration of (See Restoration)
  restoration preparation
    class I, 315, 315–316, 316
    class II, 318–319, 318–320
    class III, 323, 323–324
    class IV, 325, 325
    class V, 327, 328
    outline, 310
    resistance form, 310, 312
    retention form, 310–311, 311, 312
Tooth development
  permanent
    crown formation, 189
    emergence order and timing, 186t
  primary
    crown formation, 187, 188
    eruption, 186t
    tooth emergence timing, 188, 188t
Tooth dimension, 18
Tooth eruption, 185
Tooth identification systems
  International Numbering System, 8–11
  Palmer Notation System, 10, 10
  Universal Numbering System, 8, 8–9, 11
Tooth mobility
  charting, 226–227
  functional mobility, 227
  technique for determination, 226–227, 227, 228t

Tooth morphology
anatomic vs. clinical crown and root, 15–16
cervical line (CEJ) curvature, 31–32, 32t
complete permanent dentition, 5–6, 6
complete primary dentition, 4–5, 5
contact areas, 34, 36–37, 36–37
depressions and grooves, 27–30, 28–31
elevations and ridges, 21–27, 22–28
embrasure spaces, 37–38, 38
heights of contour, 33, 34, 35, 35t
human vs. animal teeth, 44, 44t
ideal occlusion, 39–41, 40–41
mid-root axis line, 32–34, 33–34
periodontium, 14–15, 15
relative sizes, 32, 32t, 48t
tooth development, lobes, 41–42, 42, 43t
tooth identification systems, 8–11
tooth root external morphology, 30–31, 31
tooth surfaces
anterior vs. posterior teeth, 17, 18
approximate surfaces, 17–18, 18
crown/root divisions, 19, 19
junctions/dimensions, 18, 19
maxillary vs. mandibular teeth, 17, 18
root-to-crown ratio, 19–20, 20
tooth tissues, 12–14
Tooth replacement, 328–332, 328–332
Tooth rotation, 350, 351
Torus palatinus, 471, 473
Total anodontia, 337
Toxicology, defined, 359
Trabecular bone, 401
Transillumination, 321
Translation, defined, 278
Transposition, tooth, 348, 350, 351
Transverse palatine suture, 403
Transverse ridge, 23
Triangular ridges, 23
Trifurcation, root, 31
Trigeminal nerve
mandibular nerve
auriculotemporal nerve, 432, 433
buccal nerve, 433, 434
inferior alveolar nerve, 433, 433–435, 434, 436t
lingual nerve, 433, 433, 434
maxillary nerve
infraorbital nerve, 431–432, 432
posterior superior alveolar nerve, 430–431, 432
pterygopalatine, 430, 431
zygomatic nerve, 429, 432
ophthalmic nerve, 429, 430, 430
Trismus, 279
Trochlea, defined, 393
Trochlear nerve, 429t
Trunk, of tooth, 31
Tubercles, 161
Tuberculum intermedium, 175
Tuberculum sextum, 175
Tug-back, 312
Turner's tooth, 353
Twinning, 340, 342

U
Unerupted tooth, 348, 350
Universal Numbering System
for permanent teeth, 8
for primary teeth, 8
Uvula, 465, 465

V
Vagus nerve, 429t
Veins, 440, 442–443
of face, 443
flow of blood from teeth, 442
Veneer crown, complete, 331
Vermilion border, 454
Vertical overlap, 39
Vestibular fornix, 454, 457
Vestibule
defined, 454
oral examination, 454–460, 455–460
Vibrating line, 465
Vomer bone, 395, 407, 407, 408

W
Wet line, 454
Wharton's ducts, 473
WinID program, 368
Wisdom teeth, 174
Working side, 284, 285
World Dental Federation, 9, 10

X
X-ray, panoramic, of the mouth, 446

Z
Zygomatic arch, 403, 404, 407
Zygomatic bone, 403, 403–404
Zygomatic nerve, 429, 432
Zygomatic process, 401
Zygomaticus muscle, 426