CLINICAL HEMATOLOGY ATLAS

[redacted]

SIXTH EDITION

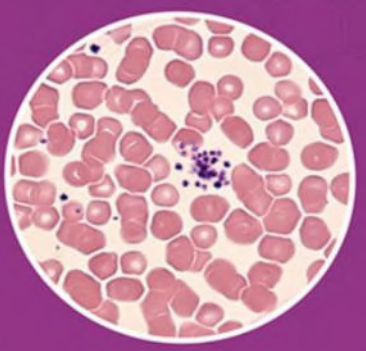

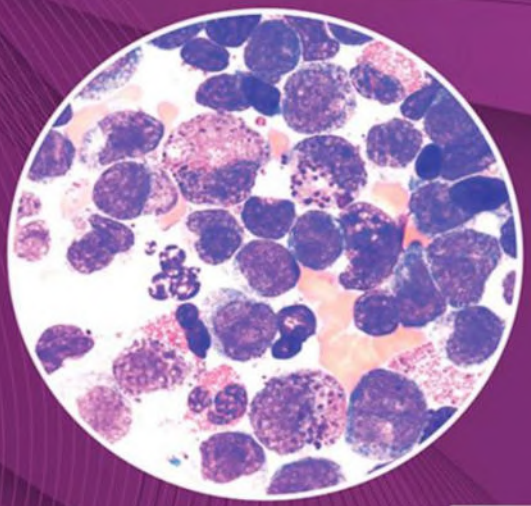

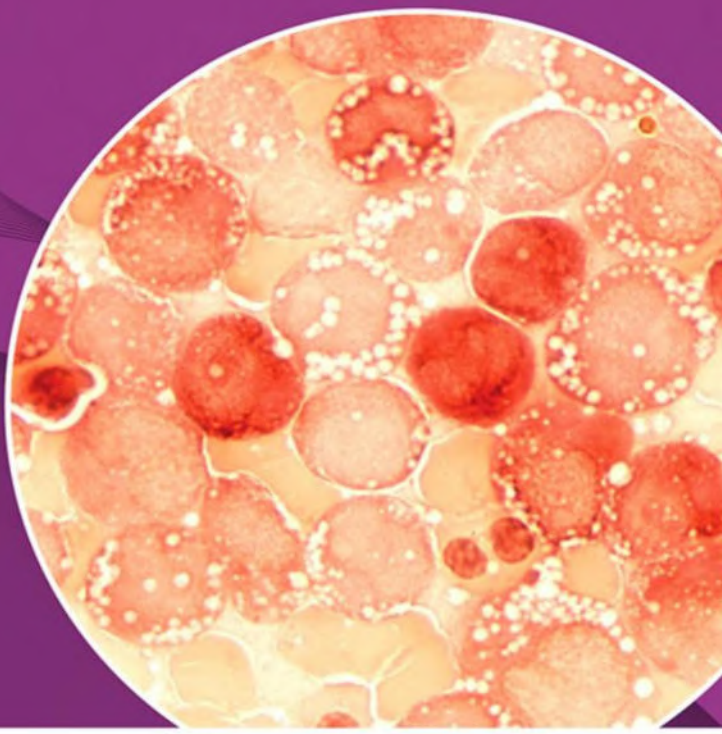

ELSEVIER

Evolve®

Student Resources on Evolve

Access Code Inside

Evolve®

YOU'VE JUST PURCHASED MORE THAN A TEXTBOOK!

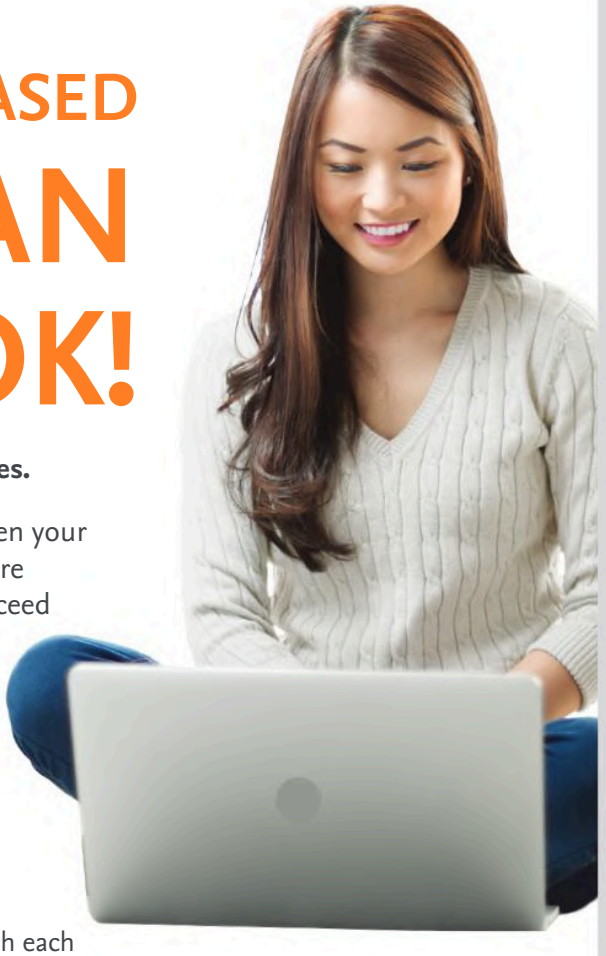

Enhance your learning with Evolve Student Resources.

These online study tools and exercises can help deepen your understanding of textbook content so you can be more prepared for class, perform better on exams, and succeed in your course.

Activate the complete learning experience that comes with each NEW textbook purchase by registering with your scratch-off access code at

http://evolve.elsevier.com/Carr/atlas/

If your school uses its own Learning Management System, your resources may be delivered on that platform. Consult with your instructor.

If you rented or purchased a used book and the scratch-off code at right has already been revealed, the code may have been used and cannot be re-used for registration. To purchase a new code to access these valuable study resources, simply follow the link above.

Place Sticker Here

REGISTER TODAY!

ELSEVIER

You can now purchase Elsevier products on Evolve!
Go to evolve.elsevier.com/shop to search and browse for products.

2019v1.0

SIXTH EDITION

CLINICAL HEMATOLOGY ATLAS

Jacqueline H. Carr, MS MT(ASCP)SH

Laboratory Manager (Retired)
Department of Pathology and Laboratory Medicine
Indiana University Health
Indianapolis, Indiana



Elsevier
3251 Riverport Lane
St. Louis, Missouri 63043

CLINICAL HEMATOLOGY ATLAS, SIXTH EDITION ISBN: 978-0-323-71192-0

Copyright © 2022 by Elsevier, Inc. All rights reserved.

No part of this publication may be reproduced or transmitted in any form or by any means, electronic or mechanical, including photocopying, recording, or any information storage and retrieval system, without permission in writing from the publisher. Details on how to seek permission, further information about the Publisher's permissions policies and our arrangements with organizations such as the Copyright Clearance Center and the Copyright Licensing Agency, can be found at our website: www.elsevier.com/permissions.

This book and the individual contributions contained in it are protected under copyright by the Publisher (other than as may be noted herein).

Notice

Practitioners and researchers must always rely on their own experience and knowledge in evaluating and using any information, methods, compounds or experiments described herein. Because of rapid advances in the medical sciences, in particular, independent verification of diagnoses and drug dosages should be made. To the fullest extent of the law, no responsibility is assumed by Elsevier, authors, editors or contributors for any injury and/or damage to persons or property as a matter of products liability, negligence or otherwise, or from any use or operation of any methods, products, instructions, or ideas contained in the material herein.

Previous editions copyrighted 2017, 2013, 2009, 2004 and 1999.

Library of Congress Control Number: 2021943959

Content Strategist: Heather Bays-Petrovic
Senior Content Development Manager: Luke Held
Senior Content Development Specialist: Maria Broker
Publishing Services Manager: Julie Eddy
Senior Project Manager: Abigail Bradberry
Design Direction: Ryan Cook

Printed in Canada

Last digit is the print number: 9 8 7 6 5 4 3 2 1



Dedicated to my dear friend and colleague,
Bernadette Rodak,
who ended her battle with cancer on March 22, 2016.
Also
My husband,
Charles Carr,
who has supported me through this adventure
as well as our daughters,
Kimberly Mayrose and Alexis Carr.

REVIEWERS

Rebecca Lewellyn Beckmann, MLS(ASCP)cm
Instructor/Clinical Coordinator
Medical Laboratory Technician
Minnesota State College Southeast
Winona, Minnesota

Jimmy L. Boyd, MLS (ASCP), MS/MHS
Program Director/Department Head
Medical Laboratory Sciences
Arkansas State University-Beebe
Beebe, Arkansas

Susan L. Conforti, EdD, MLS(ASCP)SBB
Chairperson/Program Director Medical Laboratory Science
Farmingdale State College
Farmingdale, New York

Rose Ann Crawford, MSMT, MLS(ASCP)CM
Education Coordinator retired
Cooperative Medical Technology Program of Akron
Cleveland Clinic Akron General Medical Center
Akron, Ohio

Angelique Decatur, BS, CPhT
Certified Pharmacy Technician
Denver, Colorado

Lisa DeCeuninck, MT(ASCP)
Special Instructor Clinical and Diagnostic Science
MLS
Oakland University
Rochester, Michigan

Meghan S. East, MSPAS, PA-C, MLS (ASCP)CM
Instructor
Health Sciences
Salisbury University
Salisbury, Maryland

David Falleur, MEd, MT(ASCP)
Associate Professor
Clinical Laboratory Science
Texas State University
San Marcos, Texas

Michele G. Harms, MS, MLS(ASCP)
Program Director
Medical Laboratory Science Program
UPMC Chautauqua
Jamestown, New York

Virginia C. Hughes, PhD, MLS(ASCP)CMSBB
Associate Professor
Medical and Molecular Sciences
University of Delaware
Newark, Delaware

Jeanne M Isabel, EdD, MLS (ASCP)cm SH (ASCP)cm
Chair and Associate Professor
School of Health Studies
Northern Illinois University
DeKalb, Illinois

Marisa K. James, MA, MLS(ASCP)CM
Program Director
School of Medical Laboratory Science
North Kansas City Hospital
North Kansas City, Missouri

Stephen M. Johnson, MS, MT (ASCP)
Program Director
School of Medical Technology
Saint Vincent Hospital
Erie, Pennsylvania

Jennifer Jones, BS, MLS(ASCP)CM
Clinical Instructor
Clinical Laboratory Sciences
University of Kansas Medical Center
Kansas City, Kansas

Dwane A. Klostermann, MSTM, MT(ASCP)SBB
Medical Laboratory Technician Instructor
Health Sciences
Moraine Park Technical College
Fond du Lac, WI

Bernardino D. Madsen, MS, MLS (ASCP)
MLT Program Director
Health Science
Casper College
City and State (Location of Affiliation)
Casper, Wyoming

Margaret Mayo, MEd, MLT (ASCP)
Faculty
Allied Health
Columbus State Community College
Columbus, Ohio

Susan McQuiston, JD, MS, MT(ASCP)
Faculty
Biomedical Laboratory Diagnostics
Michigan State University
East Lansing, Michigan

Pamela D. Meadows, EdD, MT(ASCP)
Associate Professor
Clinical Laboratory Sciences
Marshall University
Huntington, West Virginia

Rita Miller, EdD, MS(CLS), MLS(ASCP), CHRM
Program Director/Instructor
Medical Laboratory Technician Program
Minnesota West Community & Technical College
Luverne, Minnesota

Cory J Neill, MS, CMD, RT(R)(T)
Certified Medical Dosimetrist
Advanced Medical Imaging
Carson-Tahoe Cancer Center
Carson City, Nevada

Kathleen Park, PhD, MT(ASCP)
Assistant Department Chair/Professor
Medical Laboratory Technology
Austin Community College
Round Rock, Texas

Samantha Peterson, MS, MLS(ASCP)CM
North Dakota State License
Assistant Professor
Medical Laboratory Science
University of North Dakota
Grand Forks, North Dakota

Alisa Jean Petree, MHSM, MLS(ASCP)cm
Program Director/Professor
Medical Laboratory Technician/Phlebotomy Programs
McLennan Community College
Waco, Texas

Pamela B Primrose, PhD, MLS, ASCPcm
Professor
Health Sciences
Ivy Tech Community College
South Bend, Indiana

Bentley Reid, MBA, MT (ASCP)
Instructor & Clinical Coordinator
Department of Clinical Laboratory Science
College of Nursing and Allied Health Science Howard University
Washington, District of Columbia

Erin C. Rumpke, MS, MLScm
Assistant Professor Medical Laboratory Scientist
Clinical and Health Information Sciences
University of Cincinnati
Cincinnati, Ohio

Brooke Solberg, PhD, MLS(ASCP)CM
Associate Professor & Chair
Medical Laboratory Science
University of North Dakota
School of Medicine & Health Sciences
Grand Forks, North Dakota

Harvey D. Suski, MLT CAE
Instructor
Allied Health Sciences
Red River College
Winnipeg, Manitoba Canada

Dick Y. Teshima, MPH, MT(ASCP)
Associate Professor & Chair
Medical Technology
University of Hawaii at Manoa,
John A. Burns School of Medicine
Honolulu, Hawaii

M. Lorraine Torres, EdD, MT(ASCP)
CLS Program Director
Clinical Laboratory Science Program
The University of Texas at El Paso
El Paso, Texas

Ronald Walker, PhD, MBA, CNMT, PET
Professor
College of Health Professions
University of Findlay
Findlay, Ohio

Janet Whitney, MEd, MLS(ASCP)cm SBB(ASCP)cm
Assistant Professor
Medical Laboratory Science Program
Mercy College of Health Sciences
Des Moines, Iowa

PREFACE

Because the emphasis of an atlas is morphology, the *Clinical Hematology Atlas* is intended to be used with a textbook, such as *Rodak's Hematology*, sixth edition, that addresses physiology and diagnosis along with morphology. This atlas is designed for a diverse audience that includes clinical laboratory science students, medical students, residents, and practitioners. It is also a valuable resource for clinical laboratory practitioners who are being retrained or cross-trained in hematology. It is not intended to be a detailed, comprehensive manual for diagnosis.

In this concise format, every photomicrograph and word has been evaluated for value to the microscopist. All superfluous information has been excluded in an attempt to maintain focus on significant microscopic findings while correlating this information with clinical diagnosis. What started as a primer for Clinical Laboratory Science students with no previous hematology education has evolved into an internationally recognized reference for multiple levels of expertise, from entry level to practicing professionals.

ORGANIZATION

As is frequently expounded, morphology on a peripheral blood film is only as good as the quality of the smear and the stain. Chapter 1 reviews smear preparation, staining, and the appropriate area in which to evaluate cell distribution and morphology. A table that summarizes the morphology of leukocytes found in a normal differential, along with multiple examples of each cell type, facilitates early instruction in blood smear review.

Chapter 2 schematically presents hematopoietic features of cell maturation. General cell maturation, along with an electron micrograph with labeled organelles, will help readers correlate the substructures with the appearance of cells under light microscopy. Visualizing normal cellular maturation is essential to the understanding of disease processes. This correlation of schematic, electron micrograph, and Wright-stained morphology is carried throughout the maturation chapters. Figure 2-1 has been formatted to reflect recent hematopoietic theory. In addition, the chart aids readers in recognizing the anatomical sites at which each stage of maturation normally occurs.

Chapters 3 to 9 present the maturation of each cell line individually, repeating the respective segment of the overall hematopoietic scheme from Chapter 2, to assist the student in seeing the relationship of each cell line to the whole. In these chapters, each maturation stage is presented as a color print, a schematic, and an electron micrograph. A description of each cell, including overall size, nuclear-to-cytoplasmic ratio, morphologic features, and reference ranges in peripheral blood and bone marrow, serves as a convenient summary. The final figure in each of these chapters summarizes lineage maturation by repeating the hematopoietic segment with the corresponding photomicrographs. Multiple nomenclatures for erythrocyte maturation are used to accommodate use in multiple settings and demographic groups.

Chapters 10 to 12 present discrete cellular abnormalities of erythrocytes, that is, variations in size, color, shape, and distribution, as well as inclusions found in erythrocytes. Each variation is presented along with a description of the abnormality, or composition of the inclusion, and associated disorders.

Because diseases are often combinations of the cellular alterations, Chapter 13 integrates morphologic findings into the diagnostic features of disorders primarily affecting erythrocytes.

In Chapter 14, nuclear and cytoplasmic changes in leukocytes are displayed and correlated with non-malignant leukocyte disorders.

Diseases of excessive or altered production of cells may be caused by maturation arrest, asynchronous development, or proliferation of one cell line, as presented in Chapters 15 to 19. Cytochemical stains are presented with disorders in which they are useful.

The therapeutic use of myeloid growth factors causes morphologic changes that mimic severe infections or malignancies. Chapter 20 presents examples of peripheral blood morphology following G-CSF or GM-CSF. It is the authors' design that the cellular defects in leukocyte disorders be visually compared with the process of normal hematopoiesis for a more thorough comprehension of normal and altered development. Readers are encouraged to refer to the normal hematopoiesis illustration, Figure 2-1, for comparison of normal and abnormal cells and the progression of diseases.

Microorganisms, including parasites, may be seen on peripheral blood smears. A brief photographic overview is given in Chapter 21. Readers are encouraged to consult a microbiology reference, such as Mahon CM, Lehman DC, Manuselis G: *Textbook of Diagnostic Microbiology*, fifth edition, for a more detailed presentation.

Chapter 22 includes photomicrographs that are not categorized into any one particular area, such as fat cells, mitotic figures, metastatic tumor cells, and artifacts.

Chapter 23 describes findings expected in the peripheral blood of neonates, including anticipated variations in morphology and cellular distribution. Comparison of the hematogone, normal for newborns, with the blast cell of acute leukemia is included.

Chapter 24 is intended to be an overview of the most frequent microscopic findings in body fluids. It is not proposed as a comprehensive review of the cytology of human body fluids, but rather a quick reference for the beginning microscopist as well as the seasoned professional.

As with previous editions, the sixth edition features spiral binding, making the atlas more convenient when used at the microscope bench.

All of these chapters combine into what we believe is a comprehensive and valuable resource for any clinical laboratory. The quality of the schematic illustrations, electron micrographs, and color photographs stand for themselves. We hope that this atlas will enrich the learning process for the student and serve as an important reference tool for the practitioner.

EVOLVE

The Evolve website provides free materials for both students and instructors. Instructors have access to an electronic image collection featuring all of the images from the atlas. Students and instructors have access to student review questions and summary tables.

ACKNOWLEDGMENTS

As in previous edition, the faculty and staff of the Department of Pathology and Laboratory Medicine, Indiana University School of Medicine have been supportive off this effort. An incredibly special thanks is owed to George Girgis who willingly and unselfishly shared his vast knowledge of microscopy in blood cell and body fluid morphology. Without his help and support, this edition of the Clinical Hematology Atlas would not have been possible. A special thanks to Linda Marler and Jean Siders who once again allowed us to publish their microbiology images.

The professionals at Elsevier who been incredibly patient during the last year as this atlas began to come to life. The following people deserve my gratitude for their kind assistance and advice:

Heather Bays-Petrovic, Content Strategist

Abigail Bradberry, Senior Project Manager

Maria Broeker, Senior Content Development Specialist

CONTENTS

Section 1 Introduction

1 Introduction to Peripheral Blood Film Examination 1

Section 2 Hematopoiesis

2 Hematopoiesis 11
3 Erythrocyte Maturation 17
4 Megakaryocyte Maturation 31
5 Neutrophil Maturation 41
6 Eosinophil Maturation 55
7 Basophil Maturation 65
8 Monocyte Maturation 69
9 Lymphocyte Maturation 79

Section 3 Erythrocytes

10 Variations in Size and Color of Erythrocytes 89
11 Variations in Shape and Distribution of Erythrocytes 93
12 Inclusions in Erythrocytes 107
13 Diseases Affecting Erythrocytes 115

Section 4 Leukocytes

14 Nuclear and Cytoplasmic Changes in Leukocytes 131
15 Acute Myeloid Leukemia 141
16 Precursor Lymphoid Neoplasms 161
17 Myeloproliferative Neoplasms 165
18 Myelodysplastic Syndromes 175
19 Mature Lymphoproliferative Disorders 185
20 Morphologic Changes After Myeloid Hematopoietic Growth Factors 195

Section 5 Miscellaneous

21 Microorganisms 199
22 Miscellaneous Cells 207
23 Normal Newborn Peripheral Blood Morphology 219
24 Body Fluids 223

Glossary 245
Index 265

CHAPTER 1

INTRODUCTION TO PERIPHERAL BLOOD FILM EXAMINATION

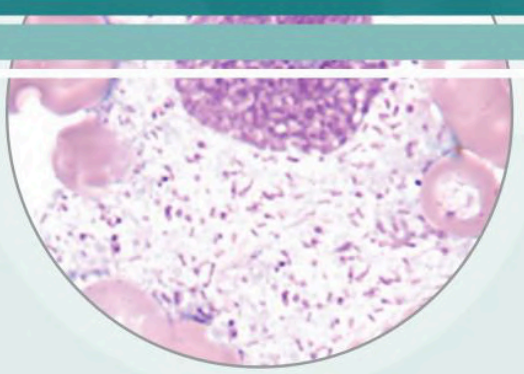

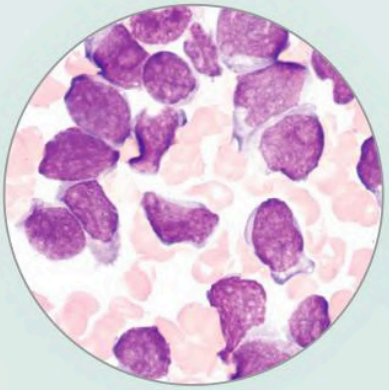

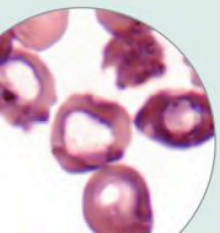

A properly prepared blood film is essential to accurate assessment of cellular morphology. A variety of methods are available for preparing and staining blood films, the most common of which are discussed in this atlas. It is beyond the scope of this atlas to discuss other methodologies; however, detailed descriptions of these procedures can be found in textbooks on hematology, such as *Rodak's Hematology: Clinical Principles and Applications*, sixth edition.

WEDGE FILM PREPARATION

MAKING THE PERIPHERAL BLOOD FILM

Although some automated analyzers prepare and stain blood films according to established criteria, manual blood film preparation is still used in many places. The wedge film is a convenient and commonly used technique for making peripheral blood films. This technique requires at least two 3 × 1-inch (75 × 25-mm) clean glass slides. High-quality, beveled-edge microscope slides are recommended. One slide serves as the blood film slide, and the other as the spreader slide. These can then be reversed to prepare a second film. A drop of ethylenediaminetetraacetic acid (EDTA) anticoagulated blood about 3 mm in diameter is placed at one end of the slide. Alternatively, a similar size drop of blood directly from a finger or heel puncture is acceptable. The size of the drop of blood is important. Too large a drop creates a long or thick film, and too small a drop often makes a short or thin film. In preparing the film, the technician holds the pusher slide securely in front of the drop of blood at a 30- to 45-degree angle to the film slide (Figure 1.1A). The pusher slide is pulled back into the drop of blood and held in that position until the blood spreads across the width of the slide (Figure 1.1B). It is then quickly and smoothly pushed forward to the end of the film slide, creating a wedge film (Figure 1.1C). It is important that the whole drop of blood is picked up and spread. Moving the pusher slide forward too slowly accentuates poor leukocyte distribution by pushing larger cells, such as monocytes and granulocytes, to the very ends and sides of the film. Maintaining a consistent angle between the slides and an even, gentle pressure is essential. It is frequently necessary to adjust the angle between the slides to produce a satisfactory film. For higher than normal hematocrit, the angle between the slides must be lowered so that the film is not too short and thick. For extremely low hematocrit, the angle must be raised. A well-made peripheral blood film (Figure 1.2) has the following characteristics:

1. About two-thirds to three-fourths of the length of the slide is covered by the film.
2. It is slightly rounded at the feather edge (thin portion), not bullet shaped.
3. Lateral edges of the film should be visible. The use of slides with chamfered (beveled) corners may facilitate this appearance.
4. It is smooth without irregularities, holes, or streaks.
5. When the slide is held up to light, the feather edge of the film should have a "rainbow" appearance.
6. The whole drop is picked up and spread.

Figure 1.3 shows examples of unacceptable films.

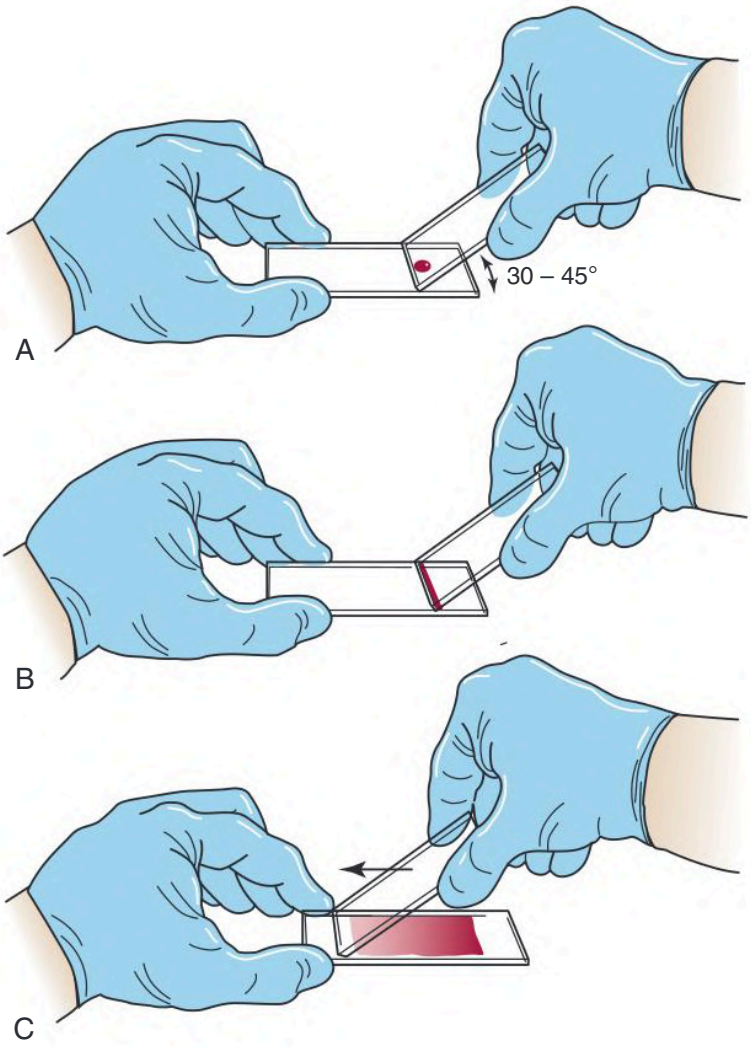

FIGURE 1.1 Wedge technique of making a peripheral blood film. (A) Correct angle to hold spreader slide. (B) Blood spread across width of slide. (C) Completed wedge film.
(From Keohane E.A., Smith L., Walenga J. (Eds.) (2016). *Rodak's hematology: clinical principles and applications*. (5th ed.). St. Louis: Saunders Elsevier.)

FIGURE 1.2 Well-made peripheral blood film.
(From Keohane E.A., Smith L., Walenga J. (Eds.) (2016). *Rodak's hematology: clinical principles and applications*. (5th ed.). St. Louis: Saunders Elsevier.)



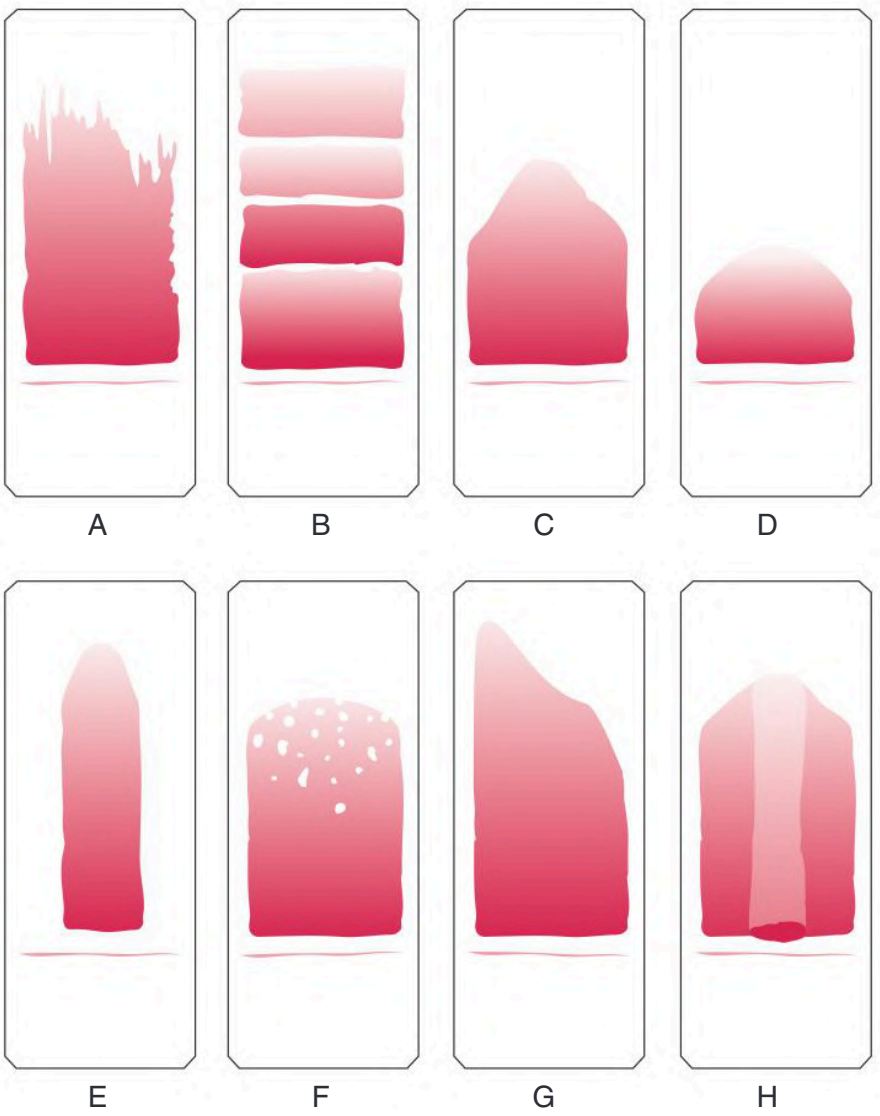

FIGURE 1.3 Unacceptable peripheral blood films. Slide appearances associated with the most common errors are shown, but note that a combination of causes may be responsible for unacceptable films. (A) Chipped or rough edge on spreader slide. (B) Hesitation in forward motion of spreader slide. (C) Spreader slide pushed too quickly. (D) Drop of blood too small. (E) Drop of blood not allowed to spread across the width of the slide. (F) Dirt or grease on the slide; may also be caused by elevated lipids in the blood specimen. (G) Uneven pressure on the spreader slide. (H) Time delay; drop of blood began to dry.
(From Keohane E.A., Smith L., Walenga J. (Eds.) (2016). *Rodak's hematology: clinical principles and applications*. (5th ed.). St. Louis: Saunders Elsevier.)

STAINING OF PERIPHERAL BLOOD FILMS

The purpose of staining blood films is to identify cells and recognize morphology easily through the microscope. Wright or Wright-Giemsa stains are the most commonly used for peripheral blood and bone marrow films. These stains contain both eosin and methylene blue and are therefore termed *polychrome stains*. The colors vary slightly from laboratory to laboratory, depending on the method of staining.

Slides must be allowed to dry thoroughly before staining. The cells are fixed to the glass slide by the methanol in the stain. Staining reactions are pH dependent, and the actual staining of the cellular components occurs when a buffer (pH 6.4) is added to the stain. Free methylene blue is basic and stains acidic cellular components, such as RNA, blue. Free eosin is acidic and stains basic components, such as hemoglobin or eosinophilic granules, red. Neutrophils have cytoplasmic granules that have a neutral pH and accept some characteristics from both stains. Details for specific methods of staining peripheral blood and bone marrow films, including automated methods, may be found in a standard textbook of hematology.

An optimally stained film (Figure 1.4) has the following characteristics:

1. The red blood cells (RBCs) should be pink to salmon.
2. Nuclei are dark blue to purple.
3. Cytoplasmic granules of neutrophils are lavender to lilac.
4. Cytoplasmic granules of basophils are dark blue to black.
5. Cytoplasmic granules of eosinophils are red to orange.
6. The area between the cells should be colorless, clean, and free of precipitated stain.

A well-stained slide is necessary for accurate interpretation of cellular morphology. The best staining results are obtained from freshly made slides that have been prepared within 2 to 3 hours of blood collection. Box 1.1 lists common reasons for poorly stained slides and may be used as a guide when troubleshooting.

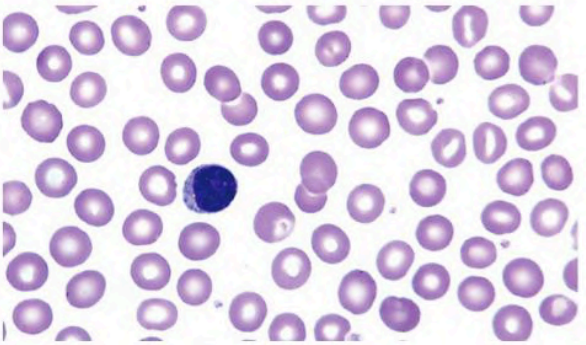

FIGURE 1.4 Optimally stained peripheral blood film demonstrating the appropriate area in which to perform the white blood cell differential and morphology assessment and the platelet estimate. Only the center of the field is shown; an entire field would contain 200 to 250 red blood cells (original × 1000).

Box 1.1

Troubleshooting Poorly Stained Blood Films

First Scenario

Problems

- Red blood cells appear gray
- White blood cells are too dark
- Eosinophil granules are gray, not orange

Causes

- Stain or buffer too alkaline (most common)
- Inadequate rinsing
- Prolonged staining
- Heparinized blood sample

Second Scenario

Problems

- Red blood cells too pale or red color
- White blood cells barely visible

Causes

- Stain or buffer too acidic (most common)
- Underbuffering (time too short)
- Over-rinsing

From Keohane E.A., Smith L., Walenga J. (Eds.) (2016). *Rodak's hematology: clinical principles and applications*. (5th ed.). St. Louis: Saunders Elsevier.

PERIPHERAL FILM EXAMINATION

10 × EXAMINATION

Examination of the blood film is a multistep process. Begin the film examination with a scan of the slide using the 10 × or low-power objective (total magnification = 100 ×). This step is necessary to assess the overall quality of the film, including abnormal distribution of RBCs, suggesting the presence of rouleaux or autoagglutination, and/or the presence of a disproportionate number of large nucleated cells such as monocytes or neutrophils at the edges of the film. If the latter exists, another film should be prepared. In addition, the 10 × film examination allows for the rapid detection of large abnormal cells such as blasts, reactive lymphocytes, and parasites.

40 × OR 50 × EXAMINATION

Using the 40 × (high dry) objective or the 50 × oil objective (400 × and 500 × total magnification, respectively), find an area of the film in which the RBCs are evenly distributed and barely touching one another (two or three cells may overlap; Figure 1.5). Scan 8 to 10 fields in this area of the film, and determine the average number of white blood cells (WBCs) per field. Although an exact factor varies with the make

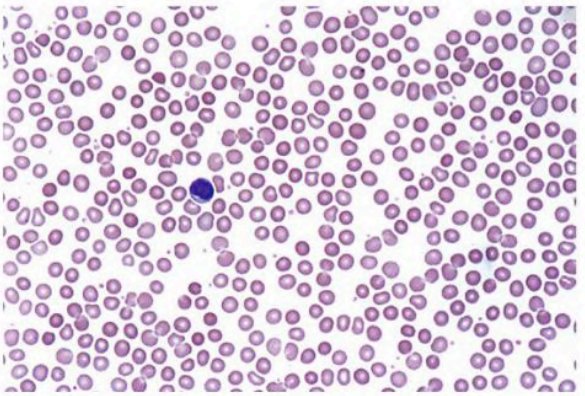

FIGURE 1.5 Correct area of blood film in which to evaluate cellular distribution and perform white blood cell estimate (× 400).

and model of microscope, in general, an approximate WBC count per cubic millimeter can be determined by multiplying the average number of WBCs per high-power field by 2000 (if 40 × is used), or 2500 (if 50 × is used). This estimate is a useful quality-control tool for validating WBC counts from hematology analyzers. Any discrepancy between the instrument WBC count and the slide estimate must be resolved. Some reasons for discrepancies include the presence of WBC or platelet clumps, fibrin strands, severe RBC agglutination, cryoglobulin and giant platelets, in addition to a mislabeled film, a film made from the wrong patient's sample, and an instrument malfunction.

100 × EXAMINATION

The next step in film evaluation is to perform the WBC differential. This is done in the same area of the film as the WBC estimate but using the 100 × oil immersion objective (1000 × total magnification). When the correct area of the film from a patient with a normal RBC count is viewed, about 200 to 250 RBCs per oil immersion field are seen (see Figure 1.4). Characteristically, the differential count includes counting and classifying 100 consecutive WBCs and reporting these classes as percentages. The differential count is performed in a systematic manner using the "battlement" track (Figure 1.6), which minimizes WBC distribution errors. The results are reported as percentages of each type of WBC seen during the count. An example of a WBC differential count is 3% bands, 55% segmented neutrophils, 30% lymphocytes, 6% monocytes, 4% eosinophils, and 2% basophils (Table 1.1). Any WBC abnormalities, such as toxic changes, Döhle bodies, reactive lymphocytes, and Aüer rods, are also reported. When present, nucleated red blood cells (NRBCs) are counted and reported as number of NRBCs per 100 WBCs. The RBC, WBC,

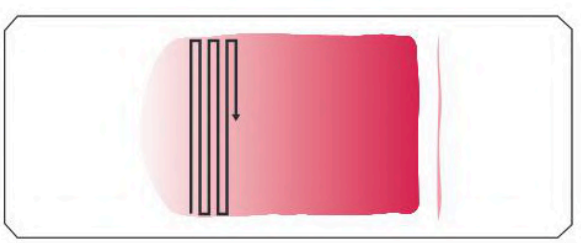

FIGURE 1.6 "Battlement" pattern for performing a white blood cell differential. (From Keohane E.A., Smith L., Walenga J. (Eds.) (2016). *Rodak's hematology: clinical principles and applications*. (5th ed.). St. Louis: Saunders Elsevier.)

TABLE 1.1

Cells Found in a Normal White Blood Cell Differential

Cell Type	Cell Size (μm)	Nucleus	Chromatin	Cytoplasm	Granules	Adult Reference Range: Peripheral Blood (%)	Adult Reference Range: Cells × 10^9/L
Segmented neutrophil (Seg), polymorphonuclear neutrophil (Poly, PMN)	10 to 15	2 to 5 lobes connected by thin filaments without visible chromatin	Coarsely clumped	Pale pink, cream colored, or colorless	1°: Rare 2°: Abundant	50 to 70	2.3 to 8.1
Band neutrophil (Band)	10 to 15	Constricted, but chromatin must be visible within the thinnest part	Coarsely clumped	Pale blue to pink	1°: Few 2°: Abundant	0 to 5	0.0 to 0.6
Lymphocyte (Lymph)	7 to 18*	Round to oval; may be slightly indented; occasional nucleoli	Condensed to deeply condensed	Scant to moderate; sky blue	± Few azurophilic	20 to 40	0.8 to 4.8
Monocyte (Mono)	12 to 20	Variable; may be round, horseshoe, or kidney shaped; often has folds producing "brainlike" convolutions	Moderately clumped; lacy	Blue-gray; may have pseudopods; vacuoles may be absent or numerous	Many fine granules, frequently giving the appearance of ground glass	3 to 11	0.5 to 1.3
Eosinophil (Eos)	12 to 17	2 to 3 lobes connected by thin filaments without visible chromatin	Coarsely clumped	Cream to pink; may have irregular borders	1°: Rare 2°: Abundant red to orange, round	0 to 5	0.0 to 0.4
Basophil (Baso)	10 to 14	Usually two lobes connected by thin filaments without visible chromatin	Coarsely clumped	Lavender to colorless	1°: Rare 2°: Lavender to dark purple; variable in number with uneven distribution; may obscure nucleus or wash out during staining, giving the appearance of empty areas in cytoplasm	0 to 1	0.0 to 0.1

*The difference in size from small to large lymphocyte is primarily a result of a larger amount of cytoplasm. See Chapter 9 for more detailed information on lymphocyte size.

1°, Primary; *2°*, secondary.

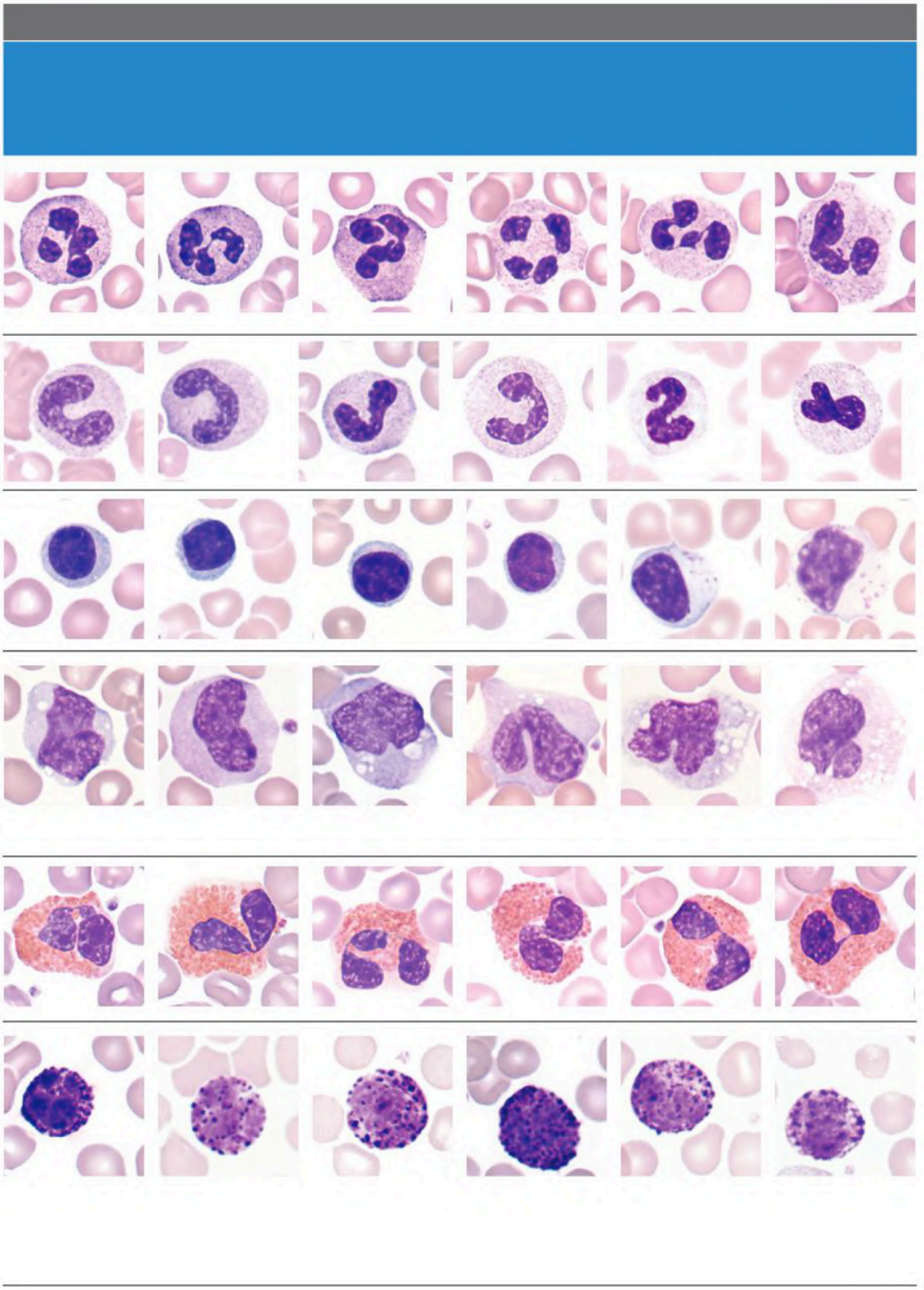

platelet morphology evaluation, and platelet estimates are also performed under the 100 × oil immersion objective. RBC inclusions, such as Howell-Jolly bodies, and WBC inclusions, such as Döhle bodies, can be seen at this magnification. Each laboratory should have established protocols for standardized reporting of abnormalities.

Evaluation of the RBC morphology is an important aspect of the film evaluation and is used in conjunction with the RBC indices to describe cells as normal or abnormal in size, shape, and color. Each laboratory should establish a standard reporting protocol. Most laboratories use concise statements describing overall RBC morphology that is consistent with the RBC indices. The microscopic evaluation of RBC morphology must be congruent with the information given by the automated hematology analyzer. If not, discrepancies must be resolved before reporting patient results.

The final step in the performance of the differential count is the estimation of the platelet number. This is done under the 100 × oil immersion objective. In an area of the film where RBCs barely touch, the number of platelets in 5 to 10 oil immersion fields is counted. The average number of platelets is multiplied by 20,000 to provide an estimate of the total number of platelets per cubic millimeter. This estimate is reported as adequate if the estimate is consistent with a normal platelet count, decreased if below the lower limit of normal for that laboratory, and increased if above the upper limit of normal. A general reference range is 150,000 to 450,000/mm^3 (150–450 × 10^9/L). When a patient is extremely anemic or has erythrocytosis, a more involved formula for platelet estimates may be used.

The estimate can be compared with an automated platelet count as an additional quality-control measure. If the estimate and the instrument platelet count do not agree, discrepancies must be resolved. Some causes for discrepancies include the presence of giant platelets, many schistocytes (RBC fragments), and platelet satellitism. Notably, high-quality 40 × or 50 × oil immersion objectives can be used by the experienced technologist to perform the differential analysis of the blood film. However, all abnormal findings must be verified under the 100 × objective.

SUMMARY

A considerable amount of valuable information can be obtained from properly prepared, stained, and evaluated peripheral blood films. Many laboratories use films made by the wedge technique from EDTA anticoagulated blood and stained with Wright or Wright-Giemsa stain. The films should be evaluated in a systematic manner using first the 10 ×, then 40 × high dry or 50 × oil, and finally the 100 × oil immersion objectives on the microscope. WBC differential and morphology and the RBC morphology and platelet estimate are included in the film evaluation.

CHAPTER 2

HEMATOPOIESIS

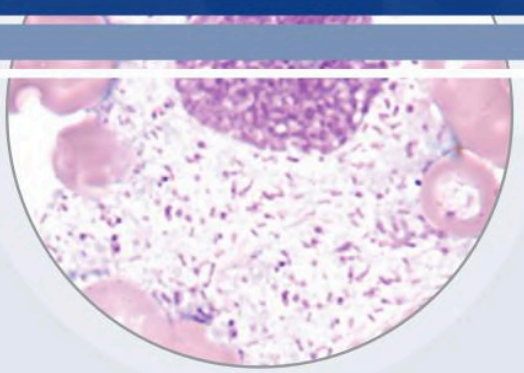

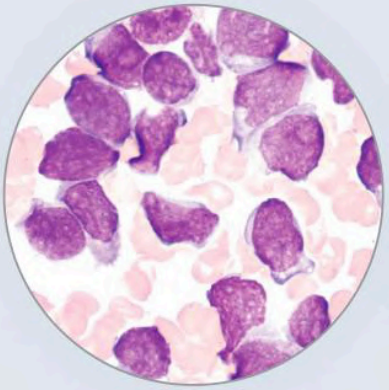

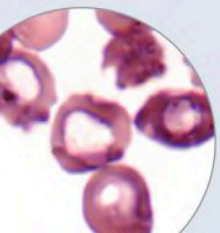

Hematopoiesis is a vigorous process of blood cell production and maturation that occurs primarily in the bone marrow in the adult. The process begins with the pluripotential hematopoietic stem cell (multipotent progenitor), which is capable of proliferation, replication, and differentiation. In response to cytokines (growth factors), the pluripotential stem cell will differentiate into a common myeloid or common lymphoid progenitor. Both the myeloid and lymphoid progenitors maintain their pluripotential capacity. The lymphoid progenitor proliferates and differentiates into T, B, and natural killer cells. The myeloid progenitor proliferates and differentiates into granulocyte, monocyte, erythrocyte, and megakaryocyte lineages. To this point in maturation, none of these stem cells can be morphologically identified, although it is postulated that they appear similar to a small resting lymphocyte. The light blue shaded area in Figure 2.1 highlights the stem cell populations. Each lineage and maturation stage will be presented in detail in the following chapters.

Hematopoiesis is a dynamic continuum. Cells gradually mature from one stage to the next and may be between stages when viewed through the microscope. In general, the cell is then identified as the more mature stage. General morphological changes in blood cell maturation are demonstrated in Figure 2.2.

Figure 2.3A–B illustrate cell ultrastructure. A review of organelles will facilitate correlation of morphological maturation with cell function. This topic is explored in depth in hematology textbooks, such as *Rodak's Hematology: Clinical Principles and Applications*, sixth edition. Table 2.1 delineates the location, appearance, and function of individual organelles.

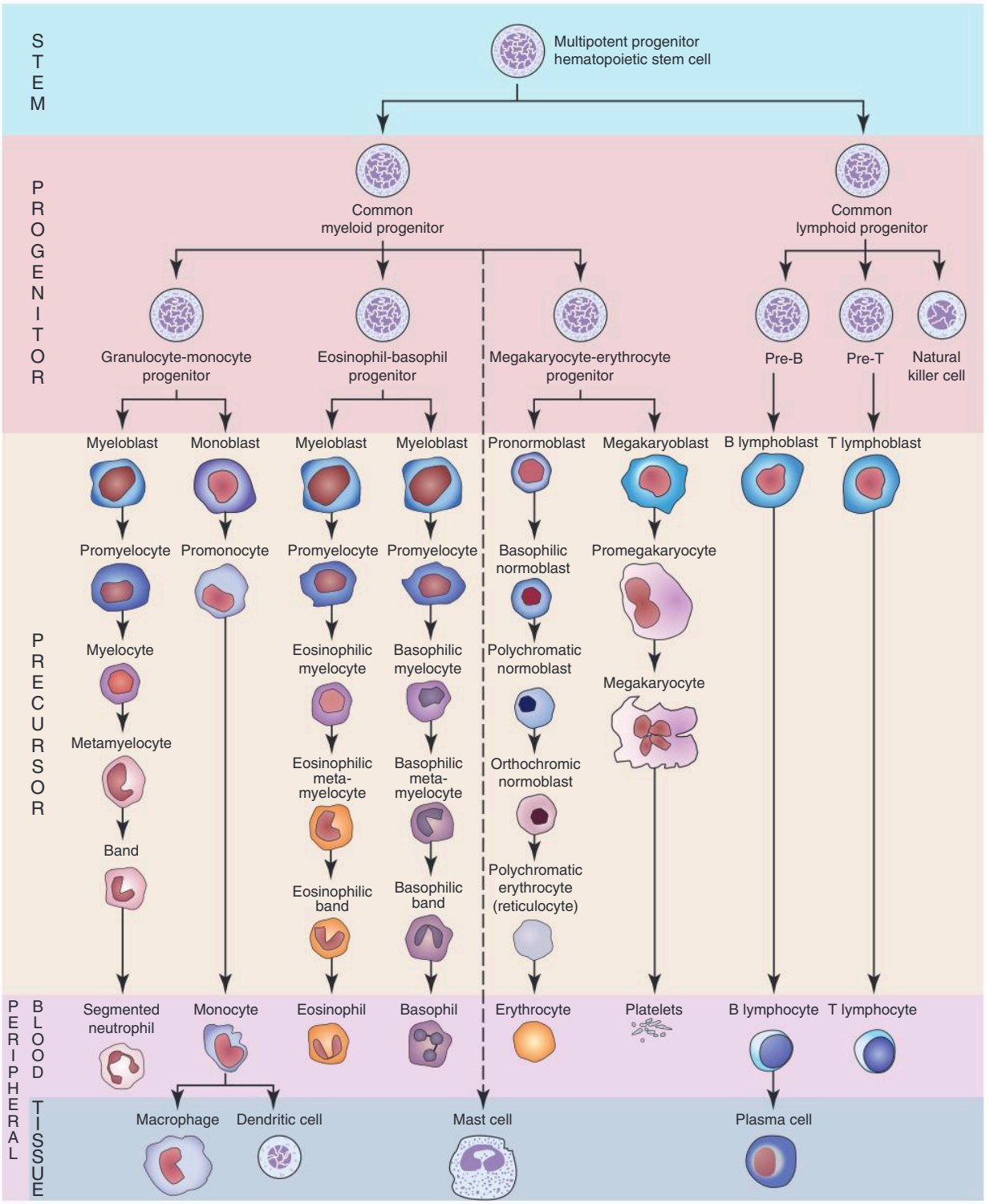

FIGURE 2.1 Chart of hematopoiesis.

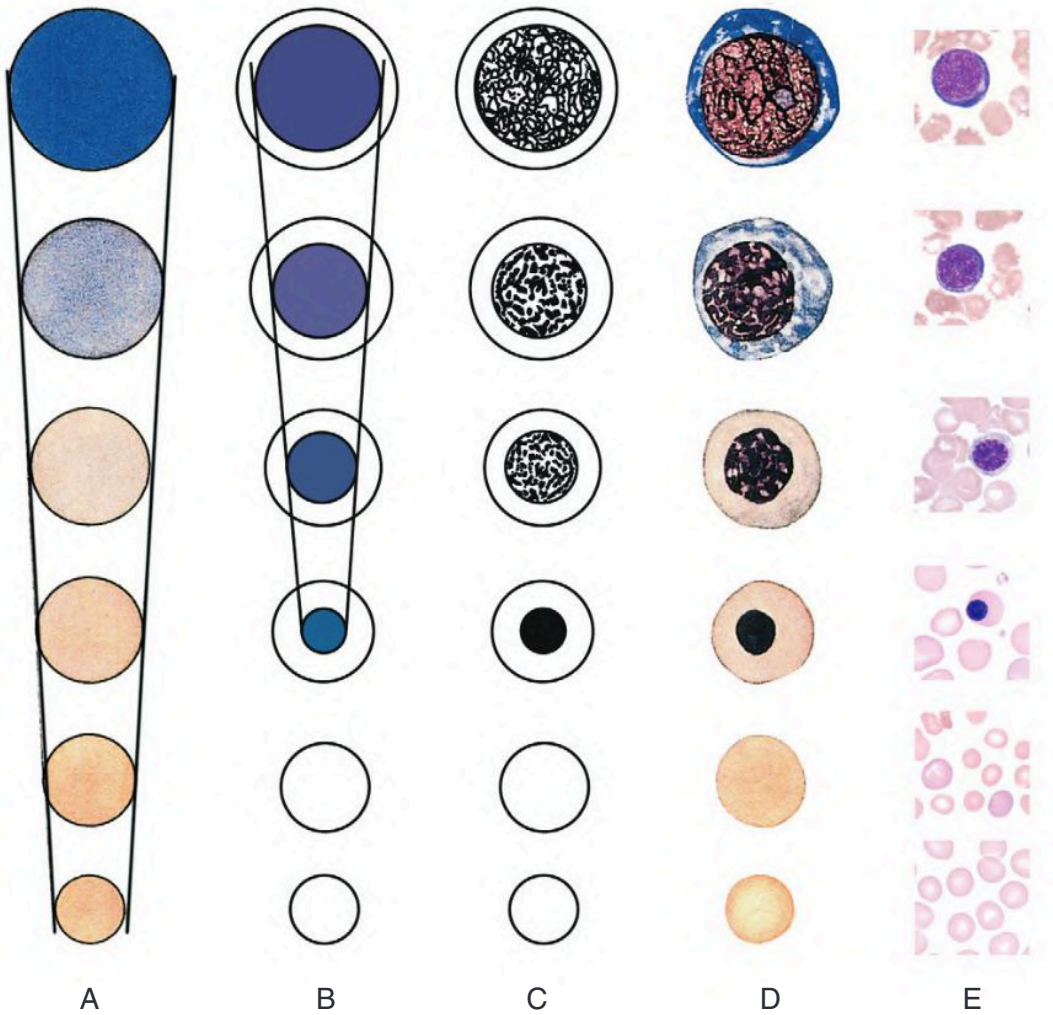

FIGURE 2.2 General trends that affect the morphology of blood cells during the developmental process.

(A) Cell diameter decreases and cytoplasm becomes less basophilic.
- An exception to the diameter decreasing is observed in the granulocytic series, the promyelocyte may be larger than its precursor, the myeloblast (see Chapter 5, Neutrophil Maturation).
- In the erythroid series, hemoglobin development in the cytoplasm imparts a pink/salmon color.

(B) Nuclear diameter decreases (N:C ratio decreases). Nuclear color changes from purplish red to dark blue.

(C) Nuclear chromatin becomes coarser, clumped, and condensed.
- Nucleoli disappear.
- In the granulocytic series, the nuclear shape changes and the nucleus becomes segmented. Granules appear in cytoplasm (see Chapter 5, Neutrophil Maturation).
- In the erythroid series, the nucleus becomes fully condensed and is ejected.

(D) Composite of changes during maturation process.

(E) Representative cells from the erythroid series, demonstrating maturation changes.

(Modified from Diggs, L.W., Sturm, D., Bell, A. (1985). *The morphology of human blood cells*. (5th ed.). Abbott Park: Abbott Laboratories. Reproduction of *The Morphology of Human Blood Cells* has been granted with approval of Abbott Laboratories, all rights reserved by Abbott Laboratories.)

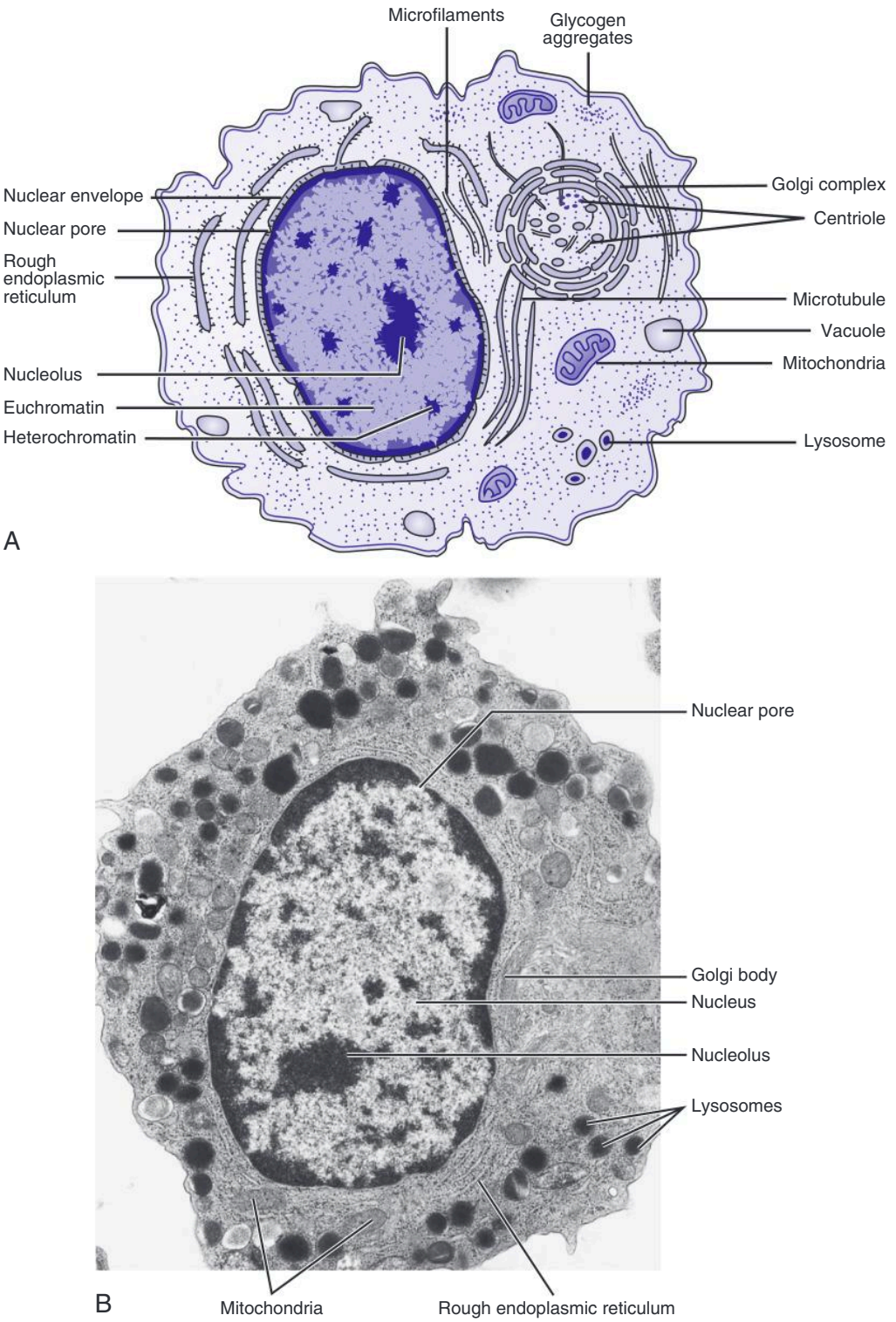

FIGURE 2.3 (A) Schematic of electron micrograph. (B) Electron micrograph with labeled organelles. ([A] From Keohane E.A., Smith L., Walenga J. (Eds.) (2016). *Rodak's hematology: clinical principles and applications.* (5th ed.). St. Louis: Saunders Elsevier.)

TABLE 2.1

Summary of Cellular Components and Functions

Organelle	Location	Appearance and Size	Function	Comments
Membranes: plasma, nuclear, mitochondrial, and endoplasmic reticulum	Outer boundary of cell, nucleus, endoplasmic reticulum, mitochondria, and other organelles	Usually a lipid bilayer consisting of proteins, cholesterol, phospholipids, and polysaccharides; membrane thickness varies with cell or organelle	Separates various cellular components; facilitates and restricts cellular exchange of substances	Membrane must be resilient and flexible
Nucleus	Within cell	Usually round or oval but varies depending on cell; varies in size; composed of DNA	Control center of cell containing the genetic blueprint	Governs cellular activity and transmits information for cellular control
Nucleolus	Within nucleus	Usually round or irregular in shape; 2 to 4 μm in size; composed of RNA; there may be 1 to 4 within nucleus	Site of synthesis and processing of ribosomal RNA	Appearance varies with activity of the cells; larger when cell is actively involved in protein synthesis
Golgi body	Next to nucleus	System of stacked, membrane-bound, flattened sacs; horseshoe shaped; varies in size	Involved in modifying and packaging macromolecules for secretion	Well developed in cells with large secretion responsibilities
Endoplasmic reticulum	Randomly distributed throughout cytoplasm	Membrane-lined tubules that branch and connect to nucleus and plasma membrane	Stores and transports fluids and chemicals	Two types: smooth with no ribosomes, rough with ribosomes on the surface
Ribosomes	Free in cytoplasm; outer surface of rough endoplasmic reticulum	Small granule, 100 to 300 Å; composed of protein and nucleic acid	Site of production of proteins, such as enzymes and blood proteins	Large proteins are synthesized from polyribosomes (chains of ribosomes)
Mitochondria	Randomly distributed in cytoplasm	Round or oval structures; 3 to 14 nm in length; 2 to 10 nm in width; membrane has two layers; inner layer has folds called *cristae*	Cell's "powerhouse"; make ATP, the energy source for the cell	Active cells have more present than do inactive ones
Lysosomes	Randomly distributed in cytoplasm	Membrane-bound sacs; size varies	Contain hydrolytic enzymes for cellular digestive system	If the membrane breaks, hydrolytic enzymes can destroy the cell
Microfilaments	Near nuclear envelope and within proximity of mitotic process	Small, solid structure approximately 5 nm in diameter	Support cytoskeleton and motility	Consist of actin and myosin (contractile proteins)
Microtubules	Cytoskeleton, near nuclear envelope and component part of centriole near Golgi body	Hollow cylinder with protofilaments surrounding the outside tube; 20 to 25 nm in diameter, variable length	Maintains cell shape, motility, and mitotic process	Produced from tubulin polymerization; make up mitotic spindles and part of structure of centriole
Centriole	In centrosome near nucleus	Cylinders; 150 nm in diameter, 300 to 500 nm in length	Serves as insertion point for mitotic spindle fibers	Composed of nine sets of triplet microtubules

(From Keohane E.A., Smith L., Walenga J. (Eds.) (2016). *Rodak's hematology: clinical principles and applications*. (5th ed.). St. Louis: Saunders Elsevier.)
ATP, Adenosine triphosphate; *DNA*, deoxyribonucleic acid; *RNA*, Ribonucleic acid.

CHAPTER 3

ERYTHROCYTE MATURATION

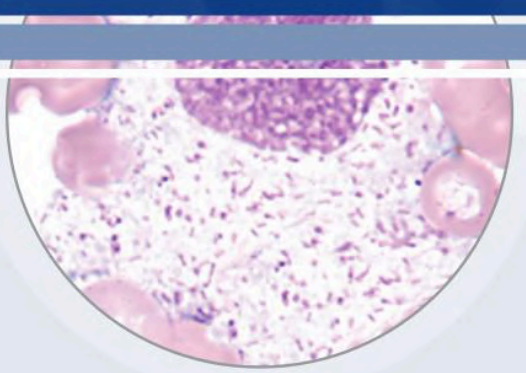

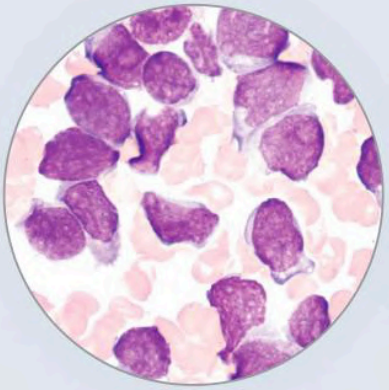

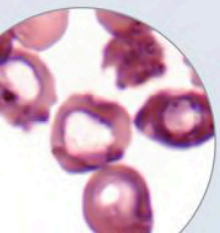

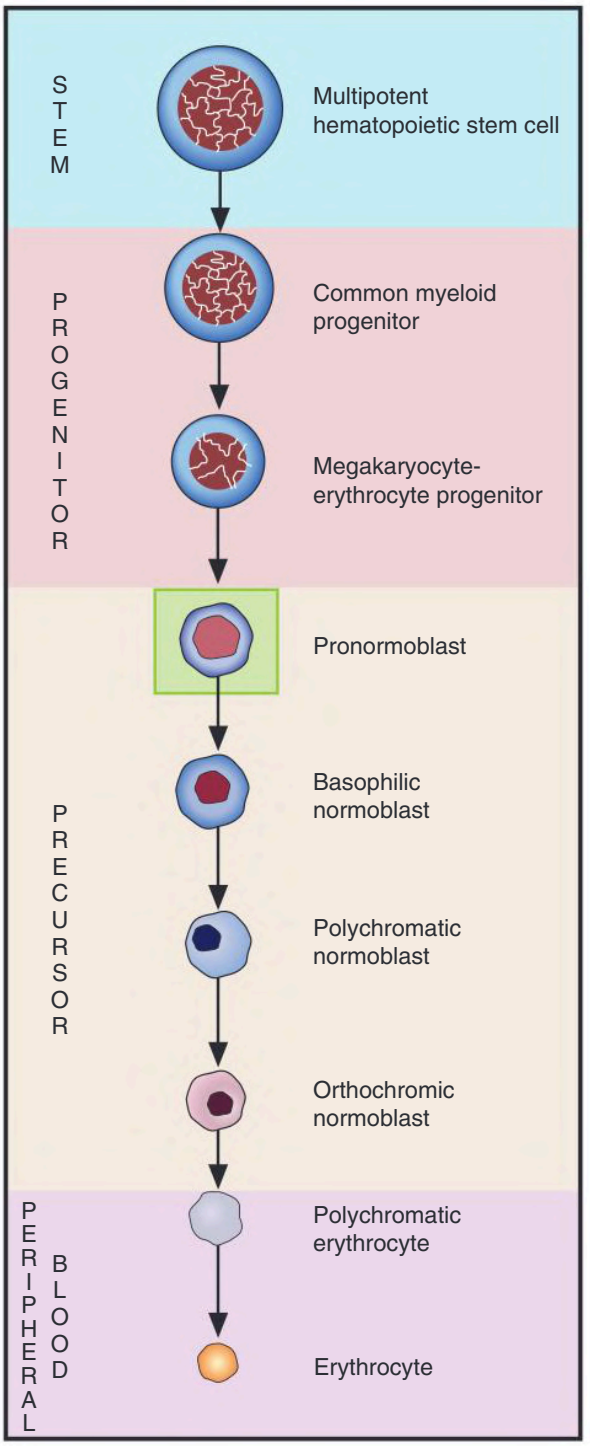

FIGURE 3.1 Erythrocyte sequence: pronormoblast.

All photomicrographs are ×1000 original magnification with Wright-Giemsa staining unless stated otherwise.

PRONORMOBLAST

Proerythroblast
Rubriblast

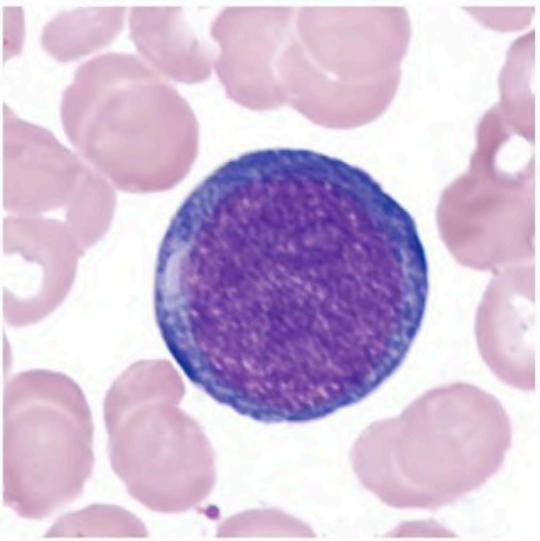

A

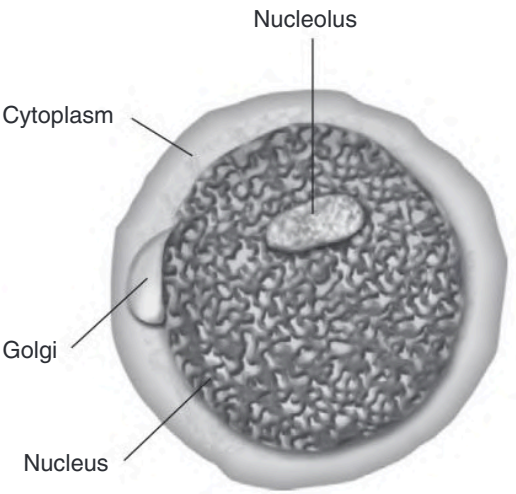

B

FIGURE 3.2A Pronormoblast.

FIGURE 3.2B Schematic of pronormoblast.

SIZE: 12 to 20 µm

NUCLEUS: Round to slightly oval
Nucleoli: 1 to 2
Chromatin: Fine

CYTOPLASM: Dark blue; may have prominent Golgi

N:C RATIO: 8:1

REFERENCE INTERVAL:
Bone Marrow: 1%
Peripheral Blood: 0%

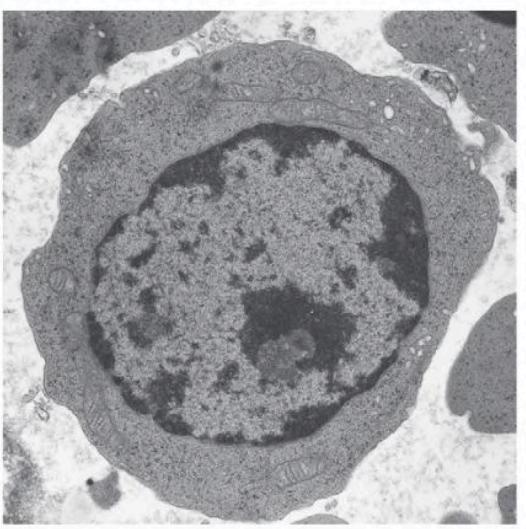

ÿ

FIGURE 3.2C Electron micrograph of pronormoblast (15,575).

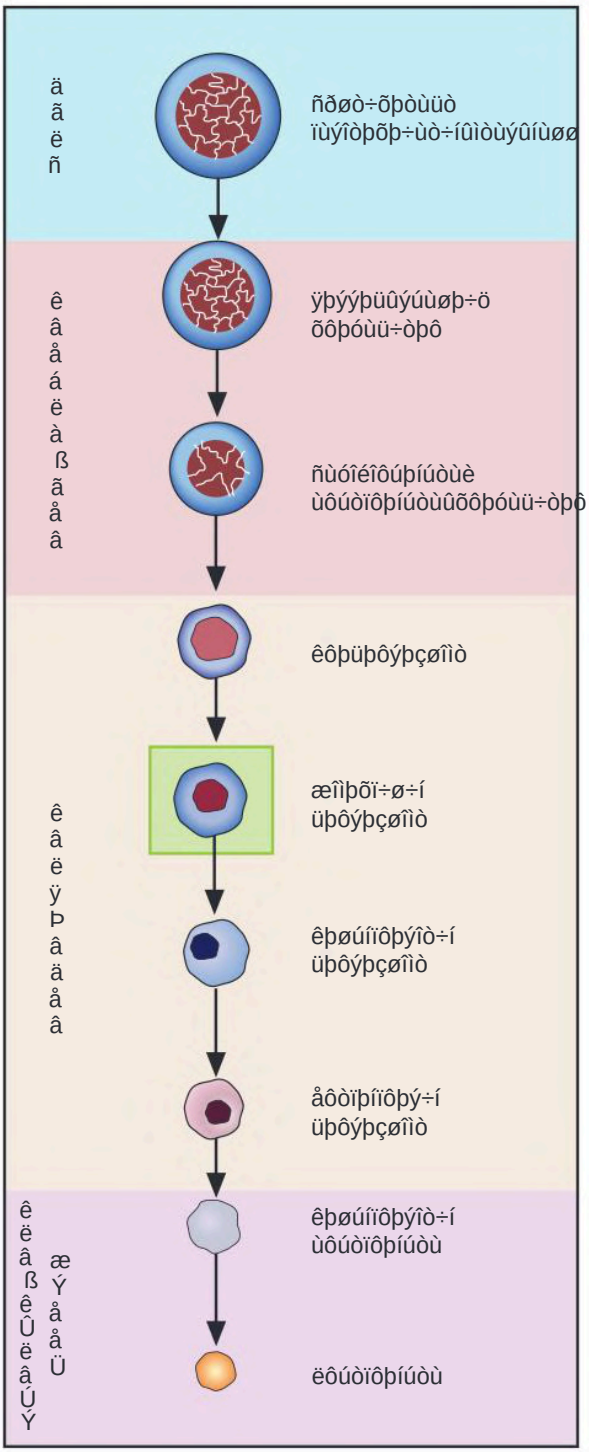

þýüûúùøÿ÷ÿþýüûúþúùýüø÷öøõôøóùøò÷ñðöúïûîíîù÷óúþìúñíðöüë

Lymphoma, 193, 193*f*
B lymphoblastic, 162*b*
Burkitt leukemia, 192, 192*f*
non-Hodgkin, 237*f*
Lysosomes, 15*f*, 16*t*

M

Macrocytes, 119*f*, 120
mean cell volume in, 90*f*
in newborns, 220, 221*f*
oval, 157
dyserythropoiesis, 177*f*
Macrocytic normochromic anemia, 119, 119*f*
Macroglobulinemia, Waldenström, 191
Macrophages, 76*f*, 77, 77*f*, 78*f*
after central nervous system hemorrhage, 229
body fluids with, 225–244
cerebrospinal fluids with, 230, 230*f*
in chart of hematopoiesis, 13*f*
erythrophagocytosis of, 216
Gaucher cell, 208
hemosiderin and hematoidin in, 230, 230*f*
Niemann-Pick cell, 208–209
sea blue histiocyte, 215–216
in serous body fluids, 232*f*, 233*f*
Malabsorption, 94–95
Malaria
cabot ring with, 111
developmental stages of, 200
Malignant cells
adenocarcinoma and, 238*f*
characteristics of, 236*t*
sometimes seen in serous fluids, 236*t*, 237–238, 237*f*, 238*f*
Mast cell, 212*f*
in chart of hematopoiesis, 13*f*
Mature lymphoproliferative disorders, 185
Burkitt leukemia/lymphoma, 192, 192*f*
chronic lymphocytic leukemia, 186*b*–193*b*, 186*f*, 187, 187*f*
hairy cell leukemia, 189, 189*f*
lymphoma, 193, 193*f*
plasma cell myeloma, 190–191, 190*f*
prolymphocytic leukemia, 188, 188*f*, 191*f*
May-Hegglin anomaly, 210*f*
MDSs. *See* Myelodysplastic syndromes (MDSs)
Mean cell volume, 220
Megakaryoblast (MK-I), 32*f*, 33, 33*f*, 40*f*
Megakaryocytes, 36*f*, 37, 37*f*, 40*f*
in chart of hematopoiesis, 13*f*
maturation of, 31
megakaryoblast (MK-I) in, 32*f*, 33, 33*f*, 40*f*
megakaryocyte (MK-III) in, 36*f*, 37, 37*f*, 40*f*
platelets in, 38*f*, 39, 39*f*, 40*f*
promegakaryocyte (MK-II) in, 34*f*, 35, 35*f*, 40*f*
mononuclear, 183*f*
Megaloblastic anemias, 102–103, 120, 120*f*
cabot ring with, 111
Howell-Jolly bodies in, 108
hypersegmentation in, 133
siderotic granules in, 110
Membranes, 16*t*
in neutrophil maturation, 42
Meningitis, 226–227
Mesothelial cells, 234–235
multinucleated, 235–236, 235*f*
serous fluids with, 234–236, 234*f*, 235*f*
Metamyelocyte
eosinophilic, 58*f*, 59–60, 59*f*, 64*f*
neutrophilic, 48*f*, 49–50, 49*f*, 54*f*
in normal newborn peripheral blood morphology, 220
Metarubricyte, 25
Metastases, breast tumor, 237*f*
Metastatic tumor, 215*f*
Methylene blue, 112–113, 113*t*
in staining peripheral blood films, 5
Microangiopathic hemolytic anemia, 126, 126*f*
erythrocytes in, 95–96
Microcytes, mean cell volume in, 90*f*
Microcytic hypochromic anemia, 116–119
Microfilaments, 15*f*, 16*t*
Micromegakaryocyte, 158, 158*f*
Microorganisms, 199
Babesia species, 201, 201*f*
bacteria, 205, 205*f*, 206*f*
fungi, 204, 204*f*
Loa loa, 202, 202*f*
Plasmodium species, 200–205, 200*f*
trypanosomes, 203, 203*f*
Microtubules, 15*f*, 16*t*
Mild erythrocytic hyperplasia, 172
Minimally differentiated acute myeloid leukemia, 143*b*–159*b*, 143*f*
Mitochondria, 15*f*, 16*t*
Mitosis, 213*f*
Mitotic figure, in malignancy, 238*f*
"Molding," of cells, 215
Molecular abnormalities, myeloproliferative neoplasms, 166*t*
Monoblast, 70*f*, 71–77, 71*f*, 78*f*
acute myeloid leukemia, 151, 153, 154*f*, 155
Monoblastic leukemia, acute, 154–156, 154*f*
Monocytes, 74*f*, 75–76, 75*f*, 78*f*
bacteria and, 205*f*
in cerebrospinal fluid, 226, 226*f*
in chart of hematopoiesis, 13*f*
in Chédiak-Higashi anomaly, 211*f*
Ehrlichia chaffeensis in, 206*f*
erythrophagocytosis of, 216

Monocytes *(Continued)*
maturation of, 69, 78*f*
macrophage in, 76*f*, 77, 77*f*, 78*f*
monoblast in, 70*f*, 71–77, 71*f*, 78*f*
monocyte in, 74*f*, 75–76, 75*f*, 78*f*
promonocyte in, 72*f*, 73–74, 73*f*, 78*f*
in normal newborn peripheral blood morphology, 220
in normal white blood cell differential, 8*t*
synovial fluid with, 239
Monocytic leukemia, acute, 154–156, 154*f*
Mononuclear megakaryocytes, 183*f*
Mononucleosis, infectious, 139*f*
Monosodium urate crystals, 239*f*, 240*f*
Morphologic changes, after myeloid hematopoietic growth factors, 195
Mott cell, 191*f*
Multilineage dysplasia, 176*b*
Multinucleated mesothelial cells, 235–236, 235*f*
Multiple eosinophils, 167*f*
Multiple sclerosis, 226
Myeloblast, 42*f*, 43*b*–53*b*, 43*f*, 54*f*
peripheral blood, 146*f*
Myelocyte
eosinophilic, 56*f*, 57–63, 57*f*, 64*f*
neutrophilic, 46*f*, 47–48, 47*f*, 54*f*
Myelodysplastic disorders, hyposegmentation of neutrophils in, 132
Myelodysplastic syndromes (MDSs), 120, 175
cabot ring in, 111
classification of, 176–183
dyserythropoiesis, 177, 177*f*, 178*f*, 179*f*
dysmegakaryopoiesis, 182–183, 182*f*, 183*f*
dysmyelopoiesis, 180–182, 180*f*, 181*f*
hypogranulation/agranulation in, 138
with isolated del(5q), 176*b*
unclassifiable, 176*b*
Myelofibrosis, primary, 166*t*, 173, 173*f*
Myeloid hematopoietic growth factors, 195
Myeloid leukemia. *See* Leukemia
Myeloma, plasma cell, 190–191, 190*f*
Myeloperoxidase stain, positive, 145*f*
Myeloproliferative disorders, hyposegmentation of neutrophils in, 132
Myeloproliferative neoplasms (MPN), 165
chronic myelogenous leukemia, BCR-ABL1 positive, 166*t*, 167–169, 167*f*
essential thrombocythemia, 166*t*, 172, 172*f*
hypogranulation/agranulation in, 138
laboratory features of, 166*t*
leukocyte alkaline phosphatase, 169–170, 169*f*
polycythemia vera, 166*t*, 171, 171*f*
primary myelofibrosis, 166*t*, 173, 173*f*
sea blue histiocyte in, 215–216

N

Naphthol-AS-D chloroacetate esterase (specific) stain, positive, 150*f*
α-naphthyl butyrate esterase (nonspecific) esterase stain, 154*f*
α-naphthyl butyrate esterase positive, 151*f*
Necrosis, 244*f*
Neonates. *See* Newborn
Neoplasms, myeloproliferative, 165
chronic myelogenous leukemia, BCR-ABL1 positive, 166*t*, 167–169, 167*f*
essential thrombocythemia, 166*t*, 172, 172*f*
hypogranulation/agranulation in, 138
laboratory features of, 166*t*
leukocyte alkaline phosphatase, 169–170, 169*f*
polycythemia vera, 166*t*, 171, 171*f*
primary myelofibrosis, 166*t*, 173, 173*f*
sea blue histiocyte in, 215–216
Neutrophilia, increased leukocyte count with, 128
Neutrophilic band, 50*f*, 51–52, 51*f*, 54*f*
Neutrophilic metamyelocyte, 48*f*, 49–50, 49*f*, 54*f*
Neutrophilic myelocyte, 46*f*, 47–48, 47*f*, 54*f*
Neutrophils
abnormal granulation, 180*f*
after central nervous system hemorrhage, 229
in Alder-Reilly anomaly, 209–210
bacteria engulfed by, 231*f*
in Chédiak-Higashi anomaly, 211*f*
with circular (donut) nucleus, 180*f*
hypersegmentation of, 120, 133, 133*f*, 180*f*
hypogranulation/agranulation of, 138, 138*f*
hyposegmentation of, 132–139, 132*f*
LAP score for, 170
lupus erythematosus cell and, 233
maturation of, 41, 54*f*
myeloblast in, 42*f*, 43*b*–53*b*, 43*f*, 54*f*
neutrophilic band in, 50*f*, 51–52, 51*f*, 54*f*
neutrophilic metamyelocyte in, 48*f*, 49–50, 49*f*, 54*f*
neutrophilic myelocyte in, 46*f*, 47–48, 47*f*, 54*f*
promyelocyte in, 44*f*, 45–46, 45*f*, 54*f*
segmented neutrophil in, 52*f*, 53, 53*f*, 54*f*
in normal newborn peripheral blood morphology, 220
platelets adhering to, 218
segmented, in cerebrospinal fluid, 226, 226*f*
synovial fluid with, 239
toxic granulation of, 137, 137*f*, 196–197, 196*f*, 197*f*
vacuolation in, 134, 134*f*
Newborn
hemolytic disease of the fetus and, 123, 123*f*
normal peripheral blood morphology in, 219
nucleated red blood cells in, 220, 221*f*

New methylene blue stain, of erythrocyte inclusions, 112–113, 113*t*
Niemann-Pick cell, 208–209, 208*f*
Niemann-Pick disease, 208–209
Non-Hodgkin lymphoma, 237*f*
Nonmegaloblastic anemia, 119, 119*f*
Normoblast
  basophilic, 20*f*, 21, 21*f*, 30*f*
  orthochromic, 24*f*, 25, 25*f*, 30*f*
  polychromatic, 22*f*, 23, 23*f*, 30*f*
Normochromic erythrocytes, 92*f*
Normocytes, 90*f*
Normocytic normochromic anemia, 121
NRBCs. *See* Nucleated red blood cells (NRBCs)
Nuclear degeneration, 218, 244
Nuclear envelope, 15*f*
Nuclear pore, 15*f*
Nucleated cell count, in cytocentrifugation, 224
Nucleated erythrocytes, 120
  in hemoglobin SS disease, 128
Nucleated red blood cells (NRBCs), 7–10
  acanthocytes with, 94*f*
  in cerebrospinal fluid, 228*f*
  dysplastic, 157
  in newborn, 220, 221*f*
Nucleolus, 15*f*
  in summary of cellular components and function, 16*t*
Nucleus, 15*f*
  of leukocytes, changes in, 131
  multinucleated mesothelial cells, 236
  non-segmented, 132*f*
  in summary of cellular components and function, 16*t*

O

Organelles, 15*f*, 16*t*
Organ transplantation, 139
Orthochromic erythroblast, 25
Orthochromic normoblast, 24*f*, 25, 25*f*, 30*f*
Osteoblasts, 214*f*
Osteoclasts, 214*f*
Ovalocyte, 102, 102*f*
Ovalocytosis, hereditary, 102–103

P

Pallor zone, of erythrocytes, 92*f*
Pancytopenia, 120
Pappenheimer bodies, 110–111, 110*f*, 113*t*
  in hemoglobin SS disease, 128
Parasites, 233. *See also* Microorganisms
PAS (periodic acid-Schiff) stain, 156*f*
Pelger-Hüet anomaly, 132
Pericardial fluids
  cells in, 232–233, 232*f*, 233*f*
  evaluation of, 224
Periodic acid-Schiff (PAS) stain, 156*f*
Peripheral blood film
  examination of, 6–10
    10×, 6
    100×, 7–10, 7*f*, 8*t*
    introduction to, 1
    40× or 50×, 6–7, 7*f*
  making, 2, 3*f*, 4*f*
  poorly stained, troubleshooting of, 5, 6*b*
  staining of, 5, 5*f*
  unacceptable, 2, 4*f*
  wedge film preparation of, 2–6, 3*f*
  well-made, 2, 3*f*
Peripheral blood lymphocytes, 209
Peripheral blood morphology
  acute myeloid leukemia, 142–159
  in newborn, 219
Peritoneal fluids
  cells in, 232–233, 232*f*, 233*f*
  evaluation of, 224
Plasmablast, 190*f*
Plasma cells, 86*f*, 87, 87*f*, 88*f*
  in chart of hematopoiesis, 13*f*
  myeloma, 190–191, 190*f*
  in serous body fluids, 232*f*
Plasmodium falciparum, 200*f*
Plasmodium species, 200–205, 200*f*
Plasmodium vivax, 200*f*
Platelets, 38*f*, 39, 39*f*, 40*f*, 168
  adhering to neutrophils, 218
  in chart of hematopoiesis, 13*f*
  clumped, 217*f*
  giant, 120, 182*f*
  with hypergranulation, 182*f*
  with hypogranulation, 182*f*
  in May-Hegglin anomaly, 210
  myelodysplastic syndromes and, 176
  myeloproliferative neoplasms, 166*t*
  number, estimation of, 10
  satellitism, 218*f*
Pleural fluids
  artifact in, 244*f*
  cells in, 232–233, 232*f*, 233*f*
  eosinophils and macrophages in, 232*f*, 233*f*
  lupus erythematosus cell in, 233*f*
  malignant cells in, 237*f*, 238*f*
  mesothelial cells in, 234*f*, 235*f*
  necrosis and, 244*f*
  plasma cells in, 232*f*
Pluripotential stem cell, 12

Poikilocytosis, 94
acanthocyte, 94, 94*f*
echinocyte, 96, 96*f*
elliptocyte/ovalocyte, 102, 102*f*
hemoglobin CC crystal, 100, 100*f*
hemoglobin SC crystal, 101, 101*f*
schistocyte, 95, 95*f*
sickle cell, 99, 99*f*
spherocyte, 97, 97*f*
stomatocyte, 104, 104*f*
target cell, 98, 98*f*
teardrop cell, 103, 103*f*
Poisoning, 90, 92, 134
Polarized light microscopy, 240*f*, 242*f*
Polychromasia, 92*f*
in hemoglobin SS disease, 128
in newborn, 220, 221*f*
Polychromatic erythroblast, 23
Polychromatic erythrocyte, 26*f*, 27, 27*f*, 30*f*
Polychromatic normoblast, 22*f*, 23, 23*f*, 30*f*
Polychrome stains, 5
Polycythemia vera (PV), 166*t*, 171, 171*f*
Polymorphonuclear neutrophils. *See also* Neutrophils
maturation of, 53
in normal white blood cell differential, 8*t*
synovial fluid with, 239
Positive myeloperoxidase stain, 145*f*
Precipitated stain, 217*f*
Precursor lymphoid neoplasms, 161
Pregnancy, 135
Primary myelofibrosis (PMF), 166*t*, 173, 173*f*
Proerythroblast, 19
Progranulocyte, 45–46
Prolymphocytes, 82*f*, 83–84, 83*f*, 88*f*
Prolymphocytic leukemia, 188, 188*f*, 191*f*
Promegakaryocyte (MK-II), 34*f*, 35, 35*f*, 40*f*
Promonocytes, 72*f*, 73–74, 73*f*, 78*f*, 151, 154*f*, 155
Promyelocyte, 44*f*, 45–46, 45*f*, 54*f*
Pronormoblast, 18*f*, 19, 19*f*, 30*f*
Proplasmacyte, 191*f*
Prorubricyte, 21
Prussian blue stain, 113*t*
Pseudogout, 241–242
Pure erythroid leukemia, 156–157, 156*f*
Purpura, thrombotic thrombocytopenic, 95–96, 126–127
PV (polycythemia vera), 166*t*, 171, 171*f*
Pyrophosphate gout, 241–242
Pyropoikilocytosis, hereditary, 125, 125*f*

R

RBC (red blood cell). *See* Erythrocytes
RDW (red blood cell distribution width), 91, 91*f*, 220
Reactive lymphocytes, 139, 139*f*, 227, 227*f*
Red blood cell (RBC). *See* Erythrocytes
Red blood cell distribution width (RDW), 91, 91*f*, 220
Refractory anemia, 176*b*
Refractory cytopenia, 176*b*
Renal graft rejection, 95–96
Reticulocytes, 26*f*, 27, 27*f*
in chart of hematopoiesis, 13*f*
staining qualities of, 112*f*, 113*t*
Reticulocytosis, 90
Rheumatoid arthritis, 232
Rh null phenotype, 104
Ribosomes, 16*t*
Ringed sideroblasts, 176*b*, 177, 179*f*
Rough endoplasmic reticulum, 15*f*
Rouleaux, 6, 105, 105*f*
Rubriblast, 19
Rubricyte, 23

S

Sanfilippo syndrome, 209*f*
Satellitism, platelets, 218*f*
Schistocytes, 10, 95, 95*f*, 99*f*, 120
in hemoglobin SS disease, 128
Sea blue histiocyte, 215*f*
Segmented neutrophils, 52*f*, 53, 53*f*, 54*f*
in cerebrospinal fluid, 226, 226*f*
in chart of hematopoiesis, 13*f*
in normal white blood cell differential, 8*t*
Sepsis
blue-green inclusion in, 136
Döhle body in, 135
toxic granulation in, 137
Serous fluids, 224
lupus erythematosus cell in, 233, 233*f*
malignant cells sometimes seen in, 236*t*, 237–238, 237*f*, 238*f*
mesothelial cells in, 234–236, 234*f*, 235*f*
multinucleated mesothelial cells, 235–236, 235*f*
pleural, pericardial, and peritoneal cells sometimes seen in, 232–233, 232*f*, 233*f*
Shape and distribution of erythrocytes, 93
acanthocyte, 94, 94*f*
autoagglutination and, 106, 106*f*
echinocyte, 96, 96*f*
elliptocyte/ovalocyte, 102, 102*f*
hemoglobin CC crystal, 100, 100*f*
hemoglobin SC crystal, 101, 101*f*
rouleaux and, 105, 105*f*
schistocyte, 95, 95*f*, 99*f*
sickle cell, 99, 99*f*
spherocyte, 97, 97*f*
stomatocyte, 104, 104*f*
target cell, 98, 98*f*
teardrop cell, 103, 103*f*
Sickle cell anemia, Howell-Jolly bodies in, 108*f*

Sickle cells, 99, 99*f*
in hemoglobin SS disease, 128
Sideroblastic anemia, 110
Siderophages, 229, 230*f*
Siderotic granules, 110, 110*f*
Size, of erythrocytes, 90
Smudge cells, 186–187, 186*f*, 187*f*
Smudged chromatin, 221*f*
Spherocytes, 97, 97*f*, 120
in newborn, 220, 221*f*
Spherocytosis, hereditary, 124, 124*f*
Splenectomy, 94–95
Howell-Jolly bodies in, 108
siderotic granules in, 110
Spur cell, 94
Stains
inclusions with supravital, 112–113, 113*t*
iron, 110*f*, 179*f*, 229
myeloperoxidase, 145*f*
new methylene blue, 112–113, 113*t*
periodic acid-Schiff (PAS), 156*f*
for peripheral blood film, 5, 5*f*
precipitated, 217*f*
Prussian blue, 113*t*
qualities of erythrocyte inclusion bodies, 113*t*
Stem cells, differentiation of, 12, 13*f*
Stomatocyte, 104, 104*f*
Stomatocytosis, hereditary, 104
Sudan Black B stain, positive, 145*f*
Supravital stain, inclusions with, 112–113, 113*t*
Synovial cells, 239
Synovial fluids, 224
crystals sometimes found in, 239–243, 239*f*, 240*f*, 241*f*, 242*f*, 243*f*
lupus erythematosus cell in, 233
Systemic disorders, hematologic manifestations of, 208–218
Alder-Reilly anomaly, 209*f*
Chédiak-Higashi anomaly, 211*f*
Gaucher cell, 208, 208*f*
May-Hegglin anomaly, 210*f*
Niemann-Pick cell, 208–209, 208*f*
Niemann-Pick disease, 208–209
Sanfilippo syndrome, 209*f*

T

Target cell, 98, 98*f*
Teardrop cell, 103, 103*f*
Thalassemia, 98–99, 102–104
α-, 118
β-major, 117, 117*f*
β-minor, 117, 117*f*
erythrocytes in
basophilic stippling of, 109
color of, 92
size of, 90
Thrombocythemia, essential, 166*t*, 172, 172*f*
Thrombocytopenia, 142
Thrombocytosis, in hemoglobin SS disease, 128
Thrombotic thrombocytopenic purpura, 95–96, 126–127
T lymphoblasts, 80*f*
T lymphocytes, 84*f*
in chart of hematopoiesis, 13*f*
Toxic granulation, 137, 137*f*, 196–197, 196*f*, 197*f*
T prolymphocytes, 82*f*
Transfusion reactions, 216
Transplantation, 139
Trauma, head, 244
Trypanosoma brucei gambiense, 203*f*
Trypanosoma cruzi, 203*f*
Trypanosomes, 203, 203*f*
Tubercular meningitis, 226
Tuberculosis, 232
Tumor, metastatic, 215*f*

U

Uneven cytoplasmic staining, 181*f*
Uterine cancer, 238*f*

V

Vacuolation, 134, 134*f*
Vacuoles, 15*f*, 134*f*, 205*f*, 212, 229
monocyte without, 75*f*
Viral infections, 139
Viral meningitis, 226
Vitamin B_{12} deficiency, 90, 120
Vitamin E deficiency, 94–95

W

Waldenström macroglobulinemia, 191
WBCs (white blood cells). *See* Leukocytes
Wedge film preparation, 2–6, 3*f*
White blood cell count, 142
White blood cells (WBCs). *See* Leukocytes
WHO classifications. *See* World Health Organization (WHO) classifications
"Windows," cell clumping with, 234–235, 235*f*
World Health Organization (WHO) classifications
acute myeloid leukemia, 142
myelodysplastic syndromes, 176*b*
myeloproliferative neoplasms, 166
precursor lymphoid neoplasms, 162, 162*b*
Wright-Giemsa stain, 5, 113*t*
Wright stain, 110*f*, 239*f*
Wright-stained cytocentrifuge slide, 225*f*

Y

Yeast, 204*f*, 225–244

COMMONLY USED ABBREVIATIONS IN HEMATOLOGY

ALL	Acute lymphoblastic leukemia
AML	Acute myeloid leukemia
Baso	Basophil
BM	Bone marrow
CD	Cluster of differentiation
CLL	Chronic lymphocytic leukemia
CML	Chronic myelogenous leukemia
CNS	Central nervous system
CSF	Cerebrospinal fluid
EDTA	Ethylenediaminetetraacetic acid
Eos	Eosinophil
ET	Essential thrombocythemia
FAB	French-American-British (classification of tumors of the hematopoietic and lymphoid systems)
G-CSF	Granulocyte colony-stimulating factor
LAP	Leukocyte alkaline phosphatase
LE	Lupus erythematosus
Lymph	Lymphocyte
M:E ratio	Myeloid:erythroid ratio
MCH	Mean corpuscular hemoglobin
MCHC	Mean corpuscular hemoglobin concentration
MCV	Mean corpuscular volume
MDS	Myelodysplastic syndrome
MK	Megakaryocyte
Mono	Monocyte
MPN	Myeloproliferative neoplasms
N/C ratio (or N:C ratio)	Nucleus/cytoplasm ratio
NRBC	Nucleated red blood cells
PB	Peripheral blood
PMF	Primary myelofibrosis
Poly, PMN	Polymorphonuclear neutrophil
PV	Polycythemia vera
RBC	Red blood cell
RDW	Red blood cell distribution width
Seg	Segmented neutrophil
WBC	White blood cell
WHO	World Health Organization